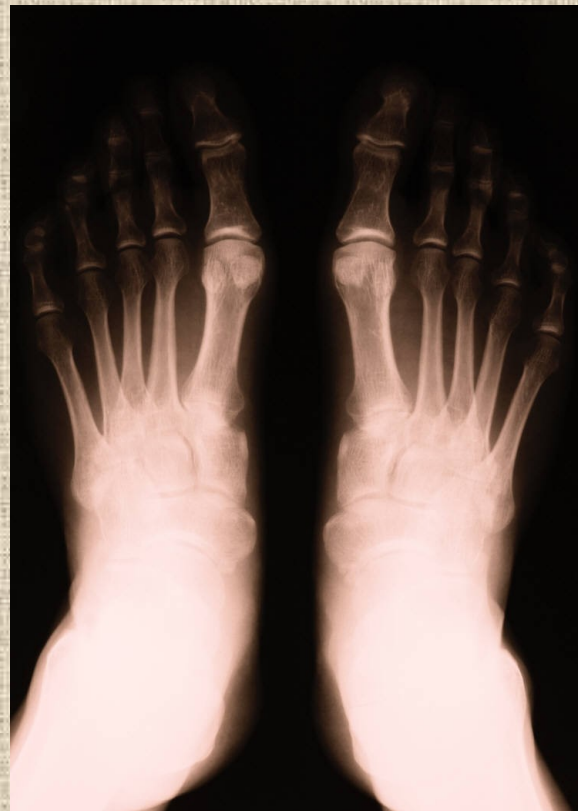

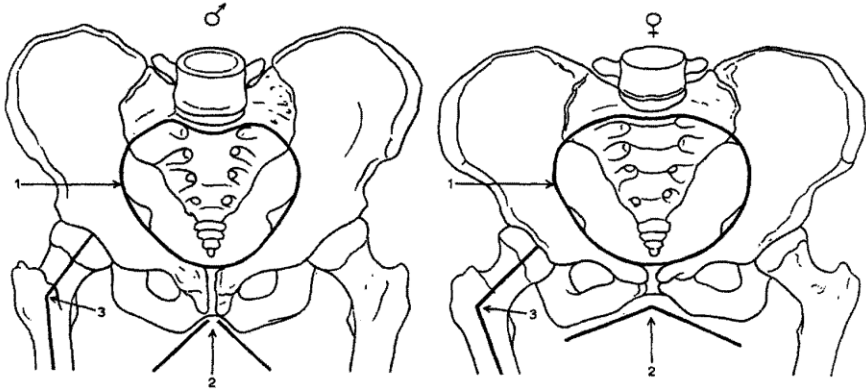
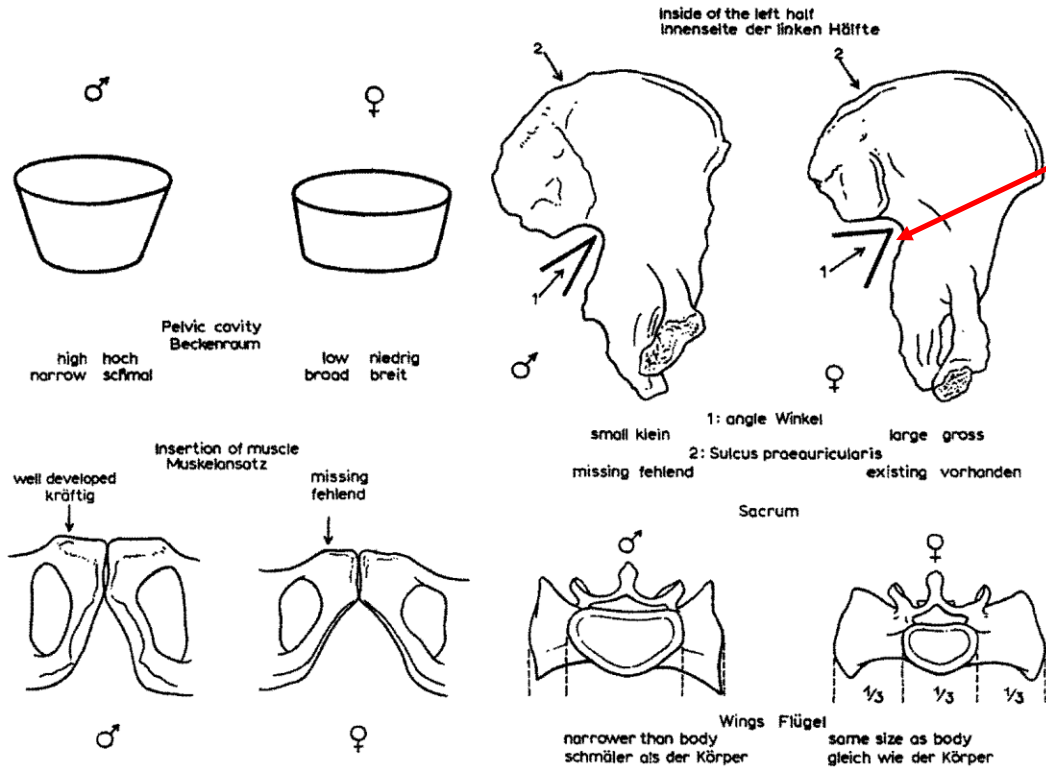
Základy osteologie

Pánev a kosti zadní končetiny



Incisura ischiadica major

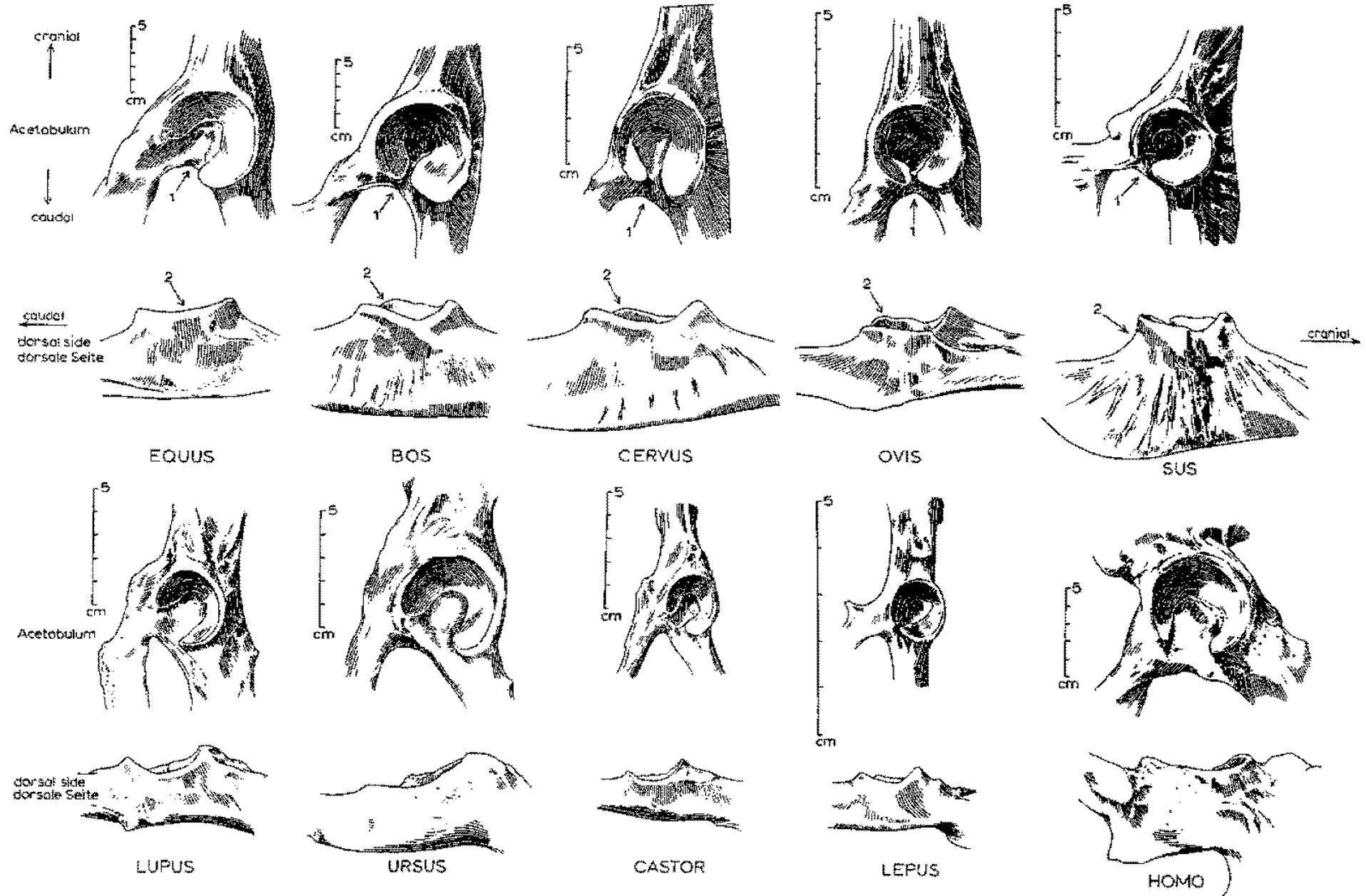
Pohlavní rozdíly na pánvi člověka



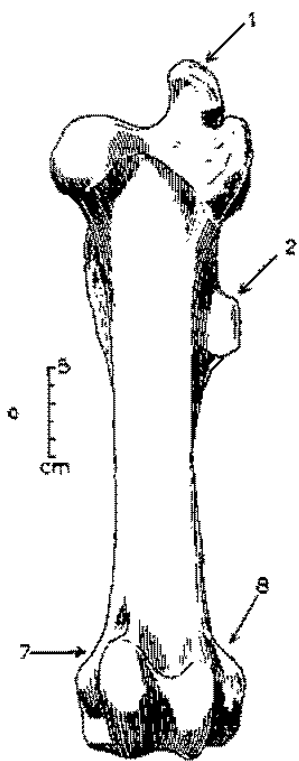
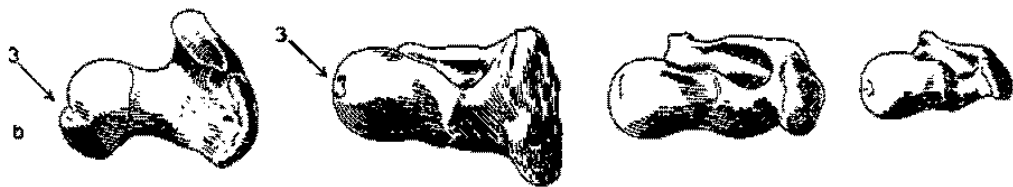
- | | | | |
|-----------------|--------------|----------------|--------------|
| 1. heart-shaped | herzförmig | 1. broad oval | breit oval |
| 2. small angle | Winkel klein | 2. large angle | Winkel gross |
| 3. large angle | Winkel gross | 3. small angle | Winkel klein |



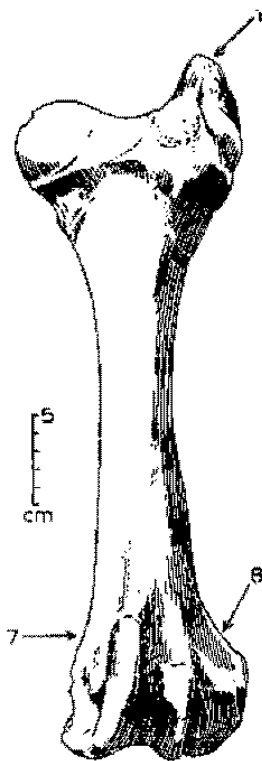
Pánve



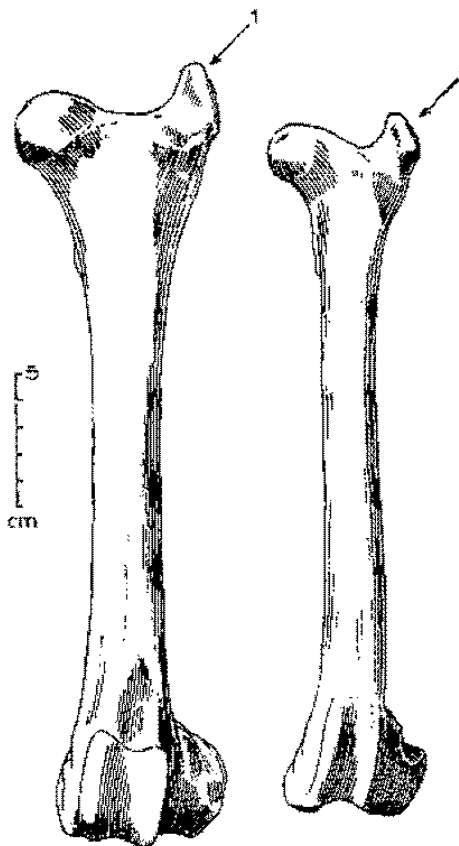
Stehenní kosti (*femur*)




EQUUS



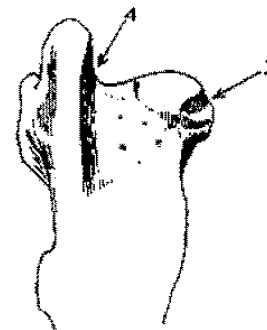
BOS



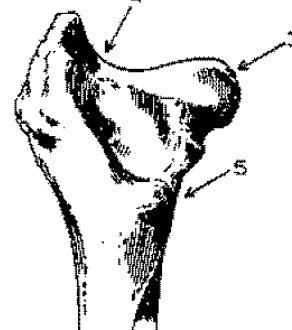
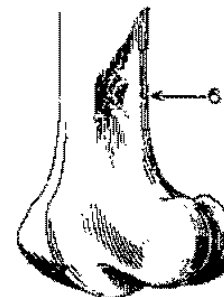
CERVUS



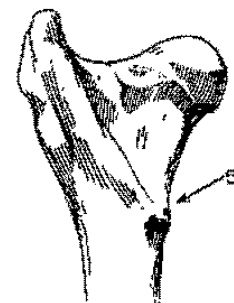
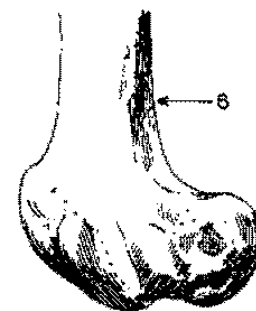
OVIS



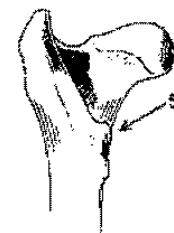

EQUUS



BOS



CERVUS



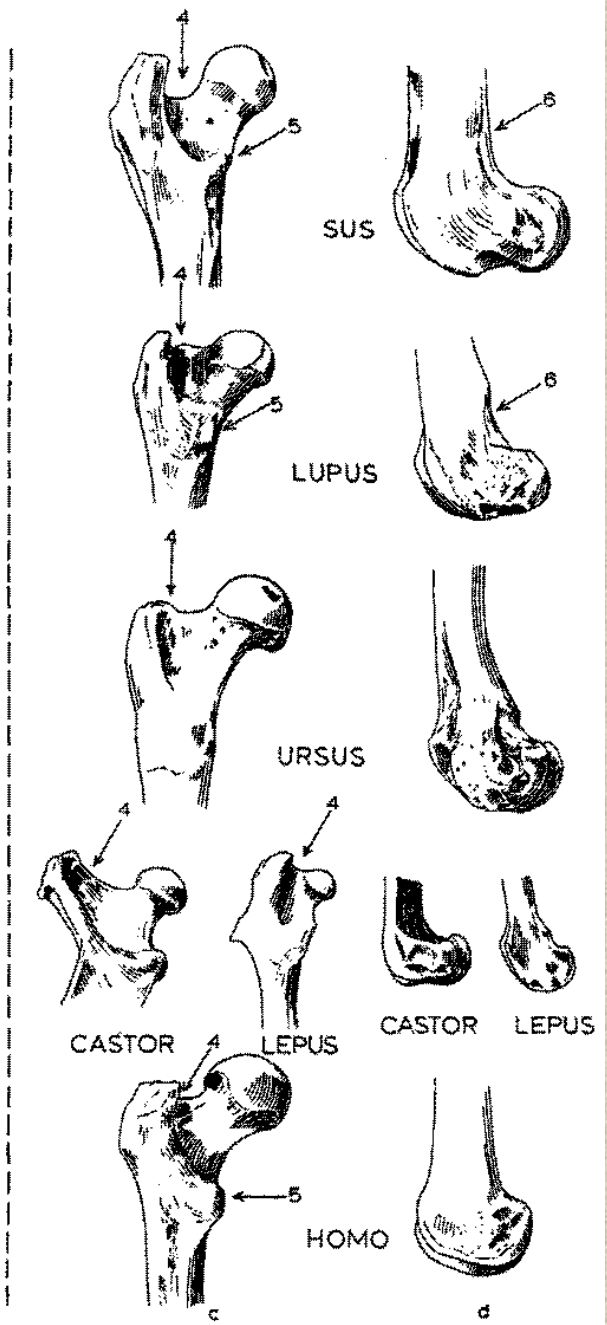
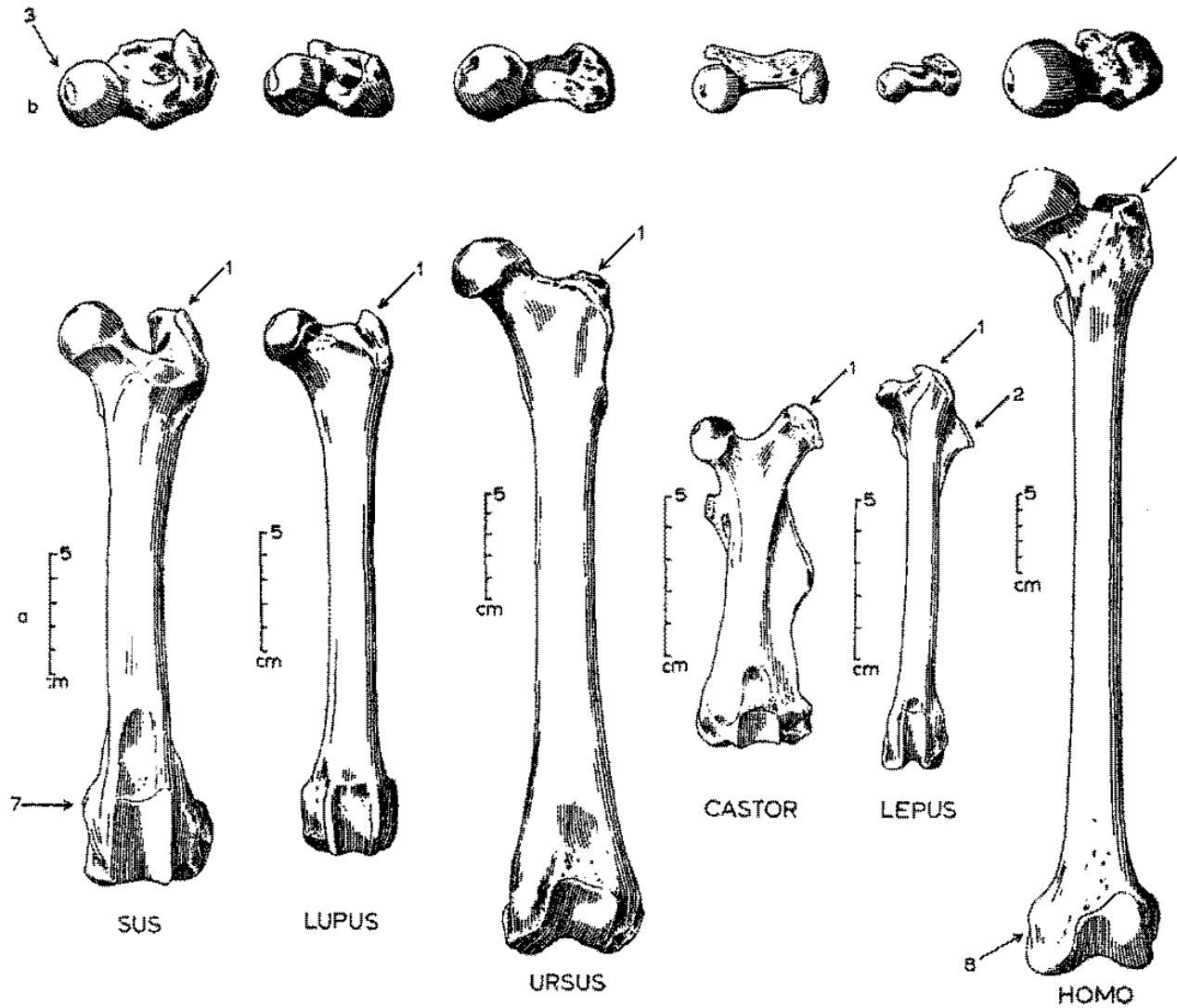
OVIS



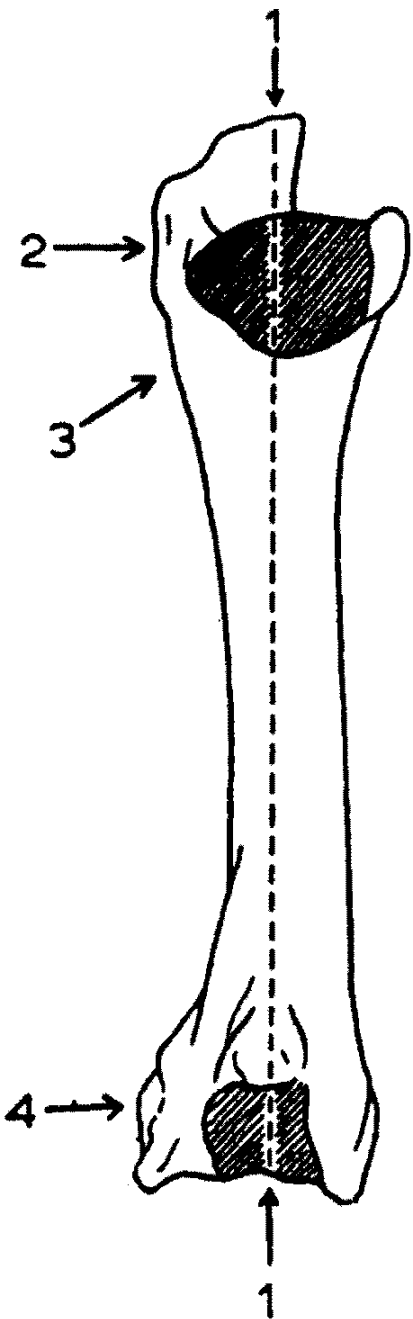
c

d

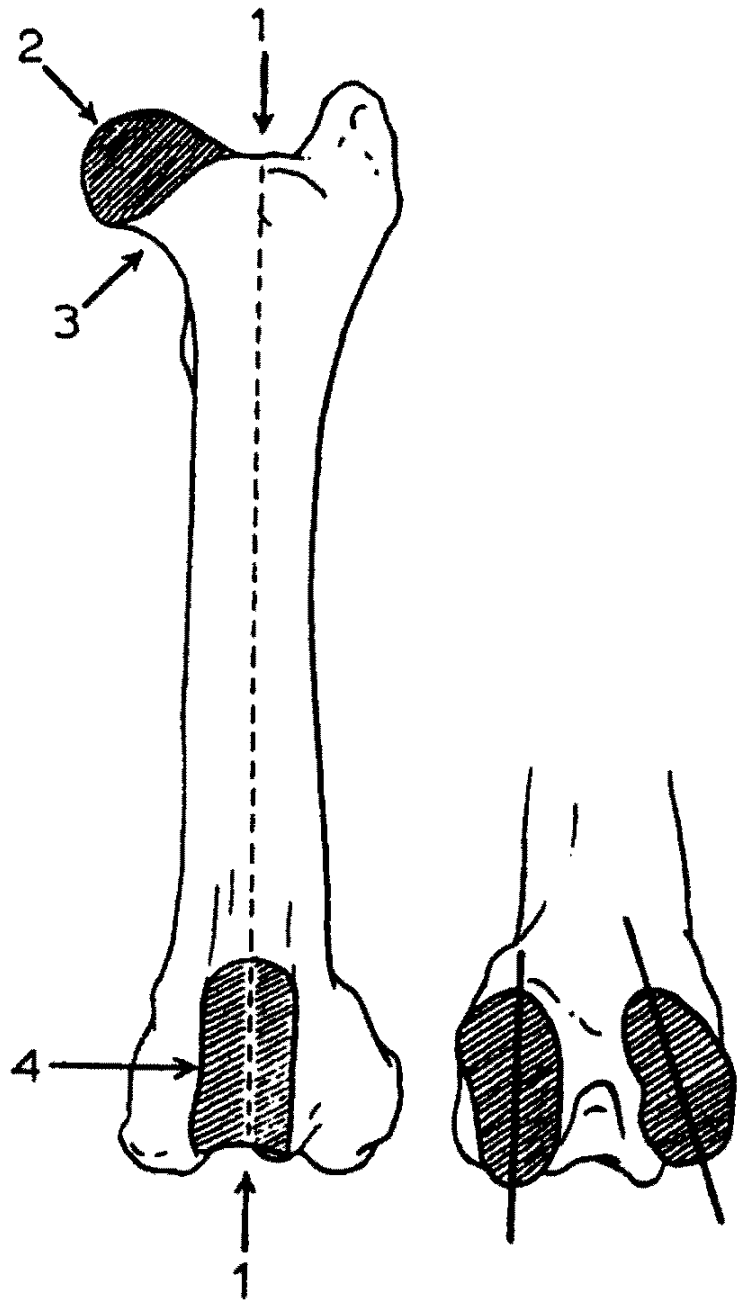
Stehenní kosti (femur)



Humerus
caudal



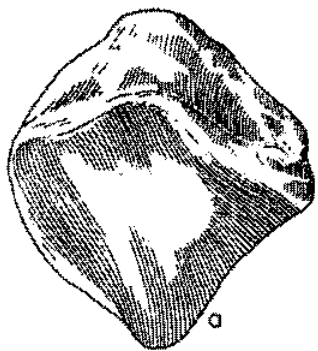
Femur
cranial



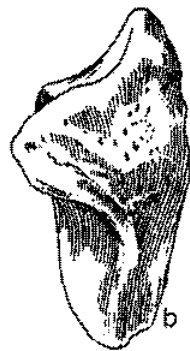
Jak rozeznat stehenní a pažní kost



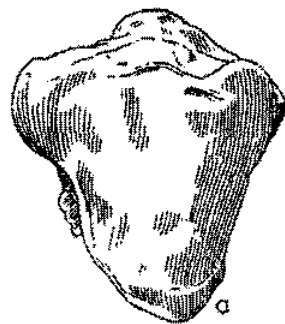
Češka (*patella*)



EQUUS



BOS



CERVUS



OVIS



SUS




LUPUS



URSUS



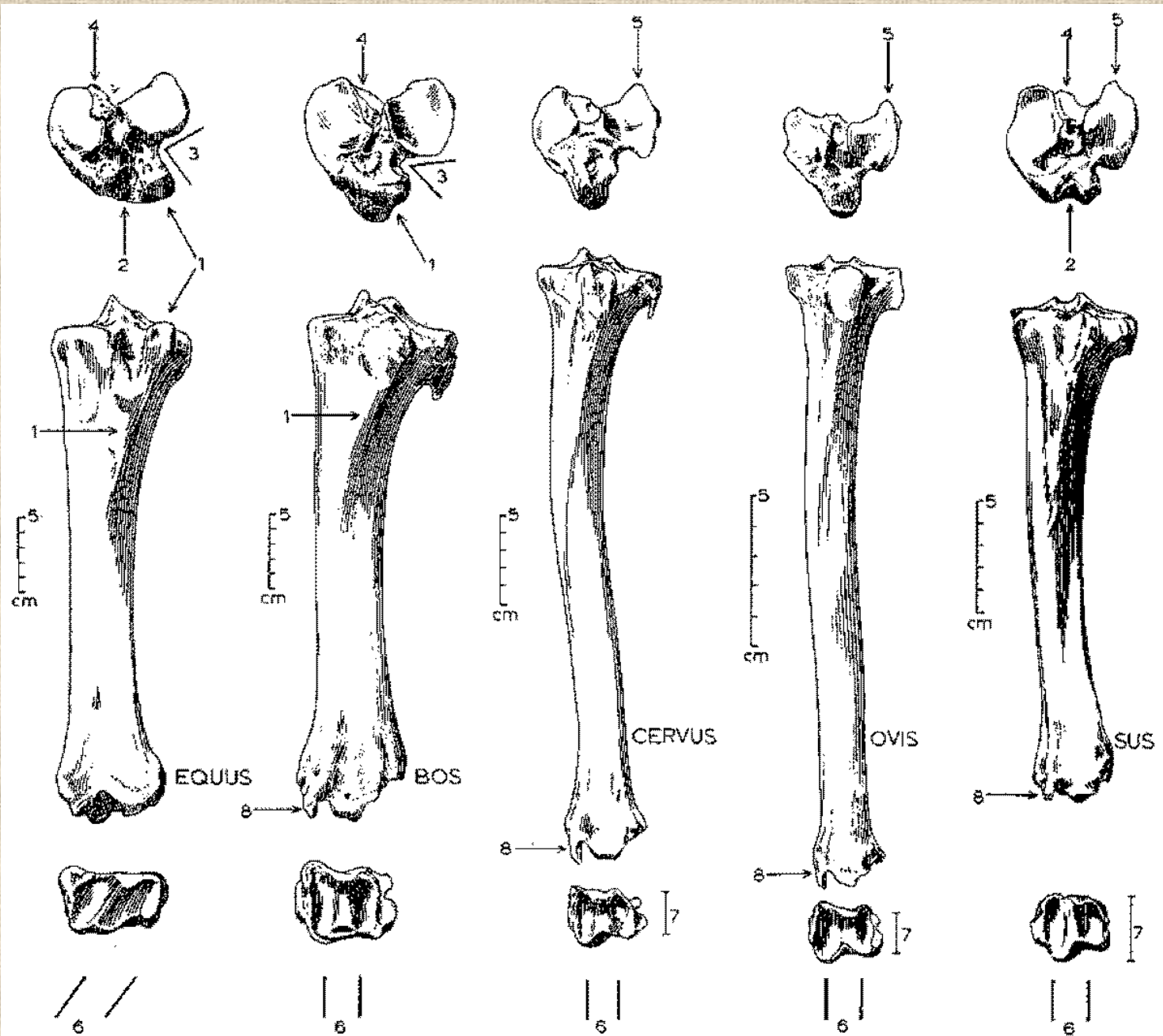
CASTOR



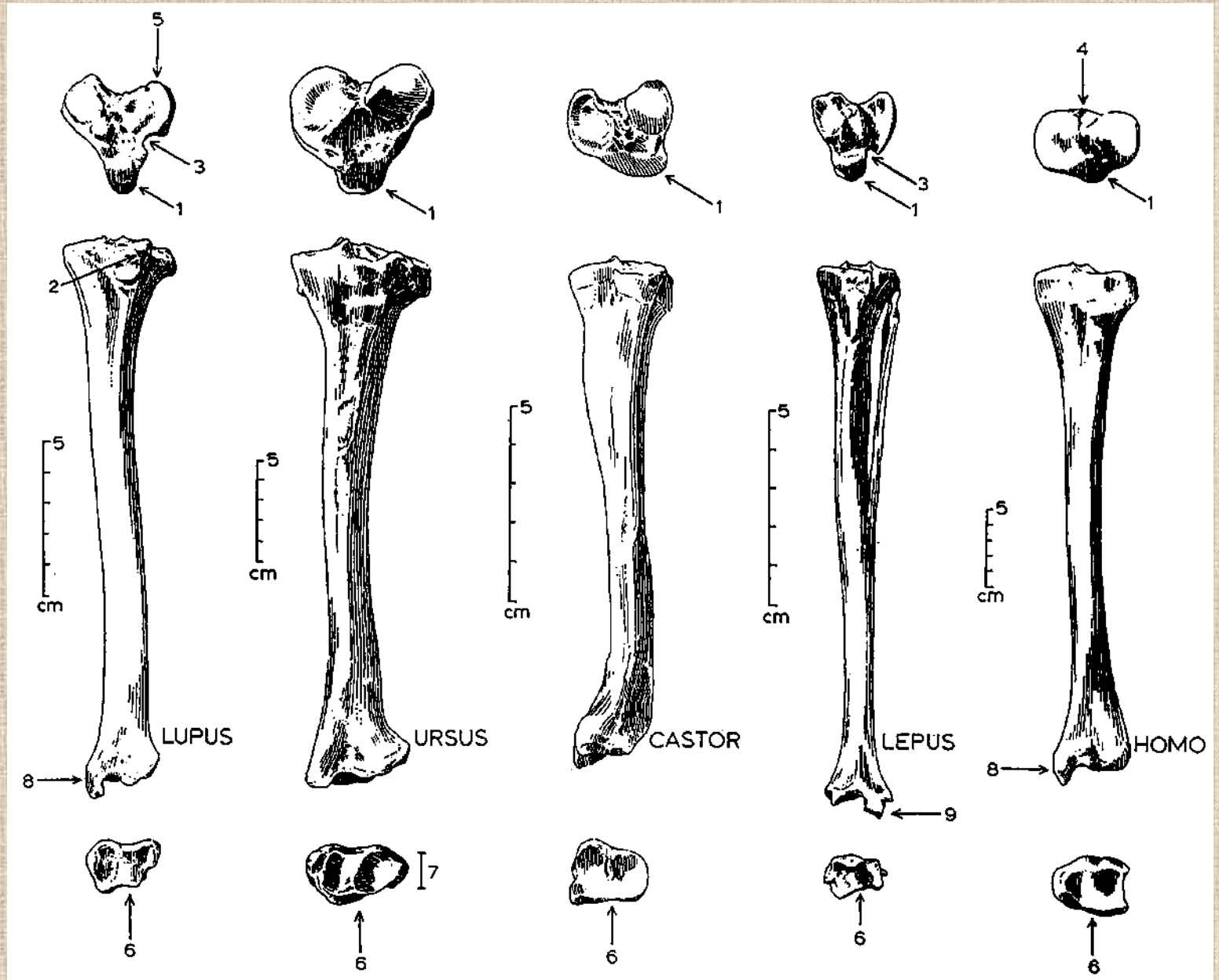
HOMO



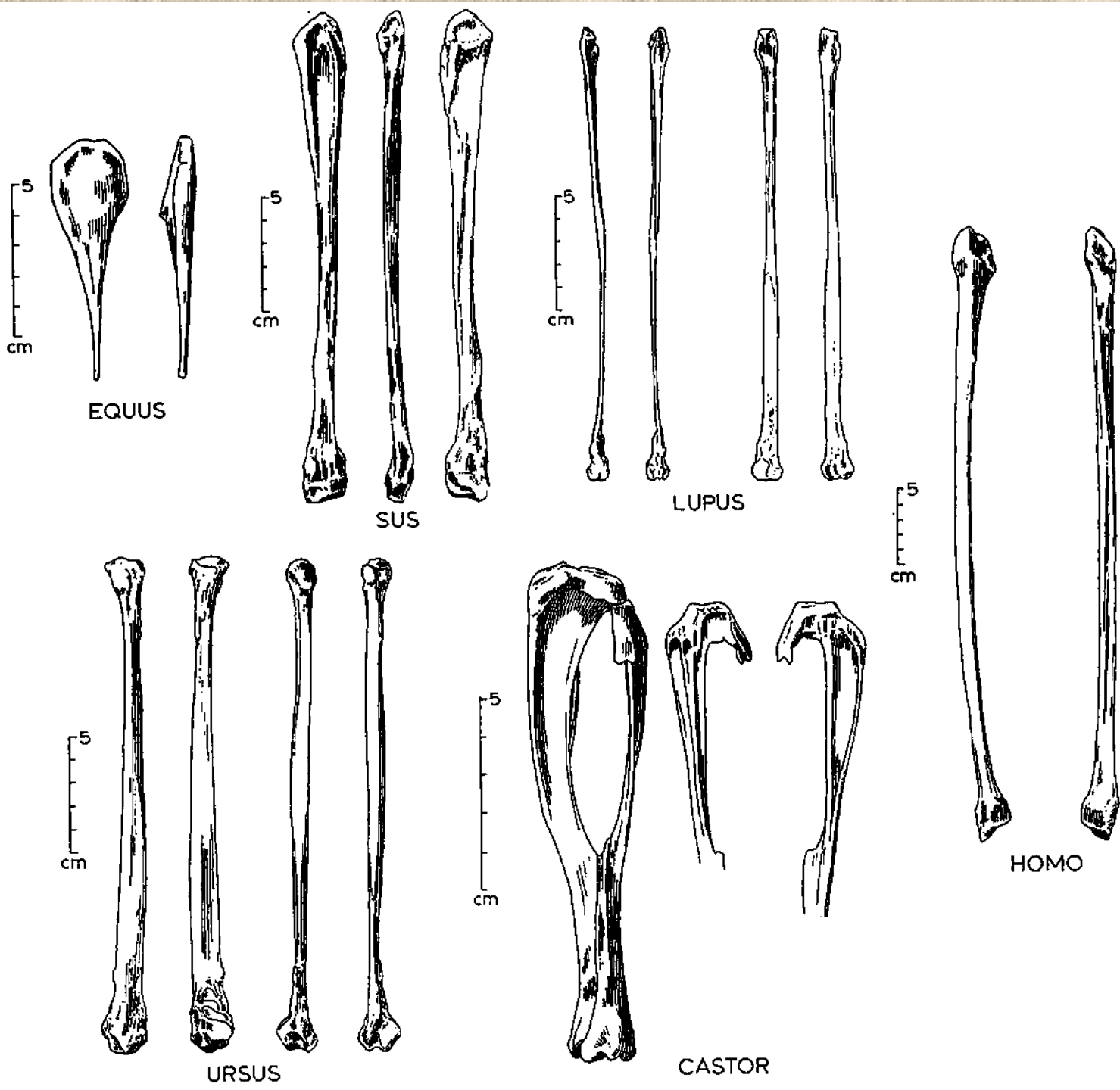
Holenní kosti (*tibiae*)



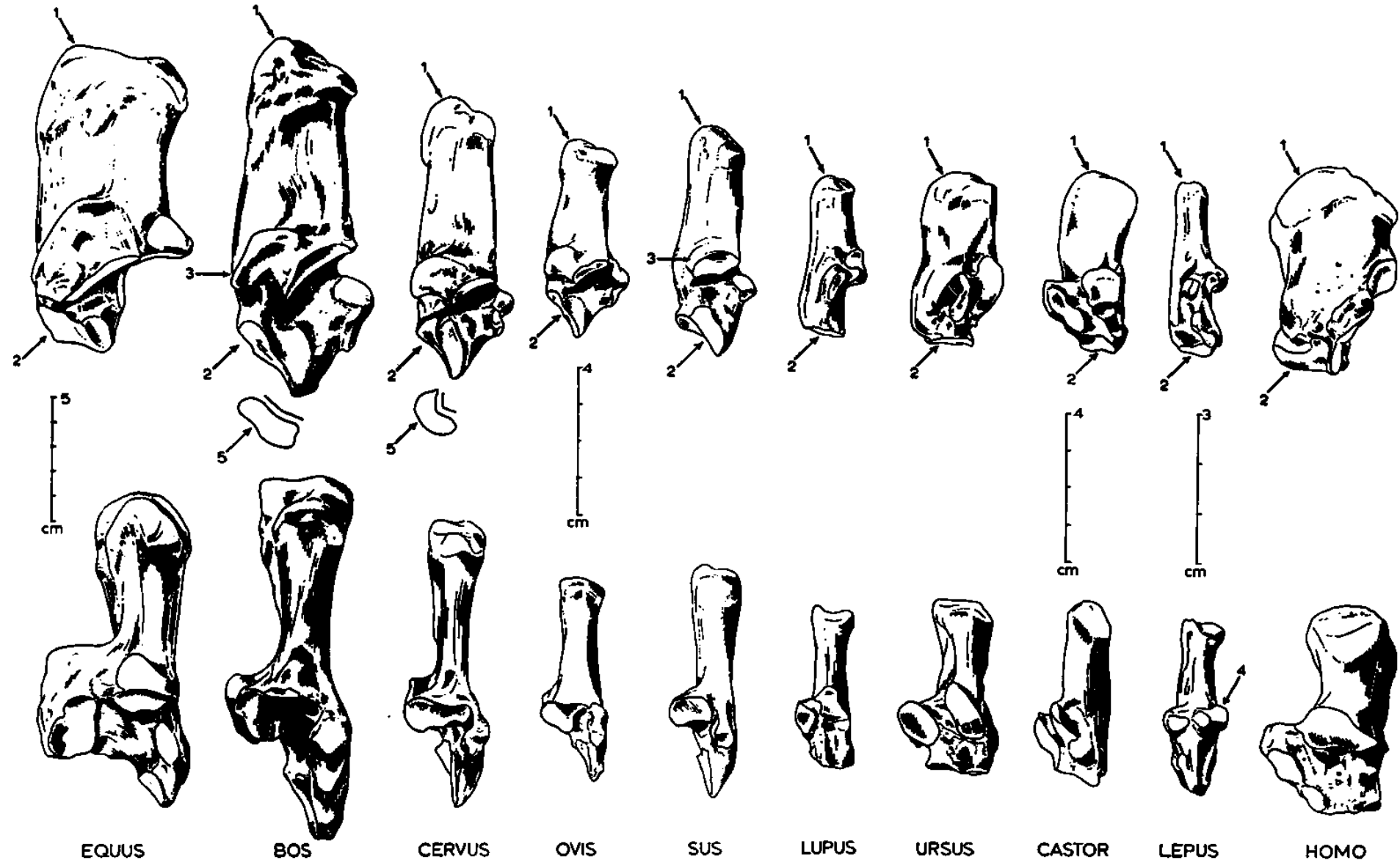
Holenní kosti (*tibie*)

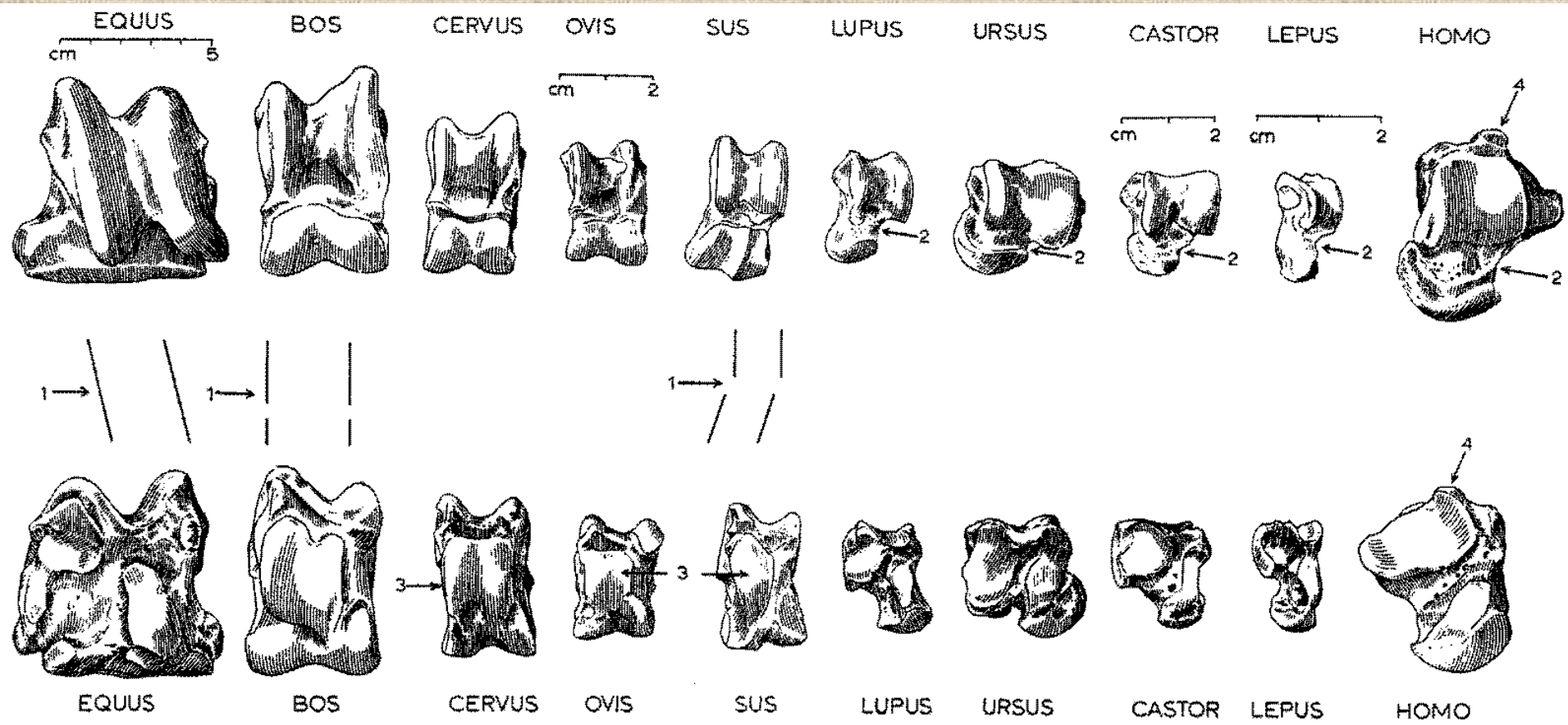


Lýtkové
kosti
(fibula)



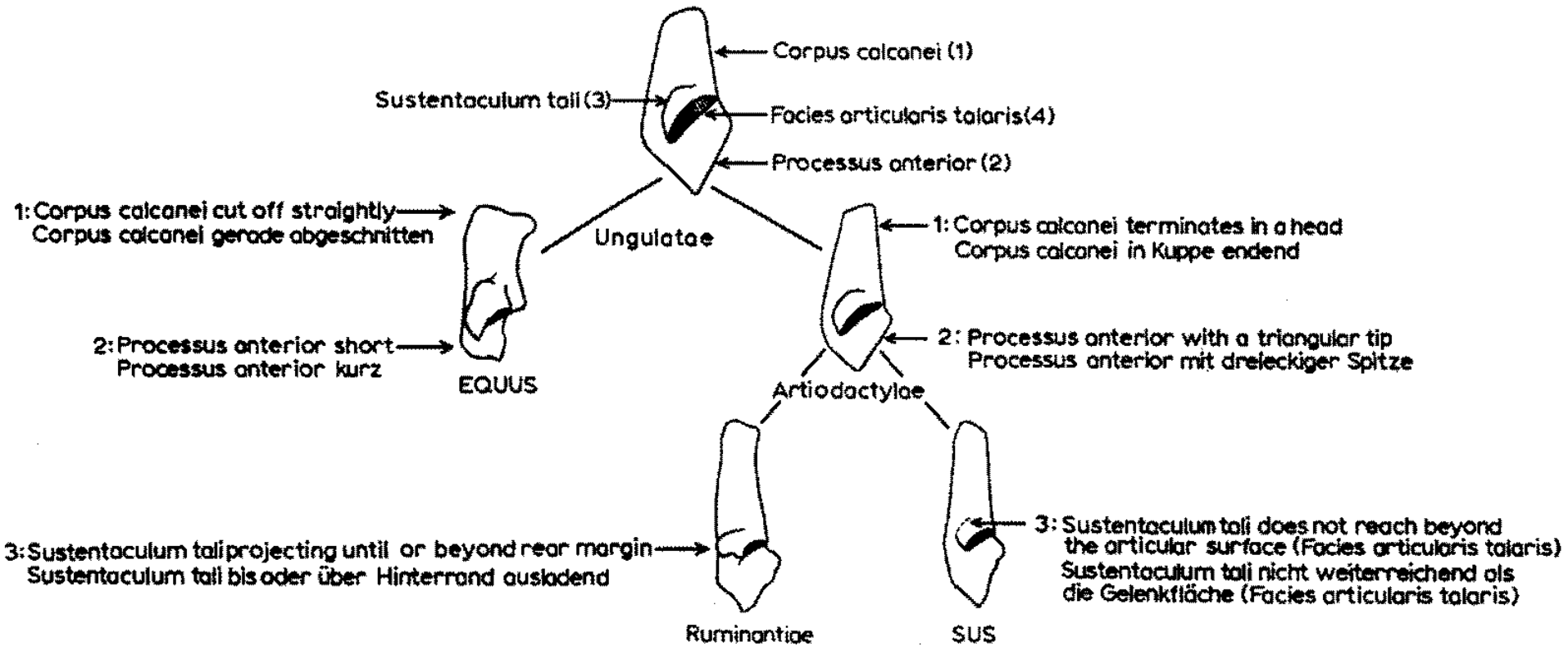
Kost patní (*calcaneus*)



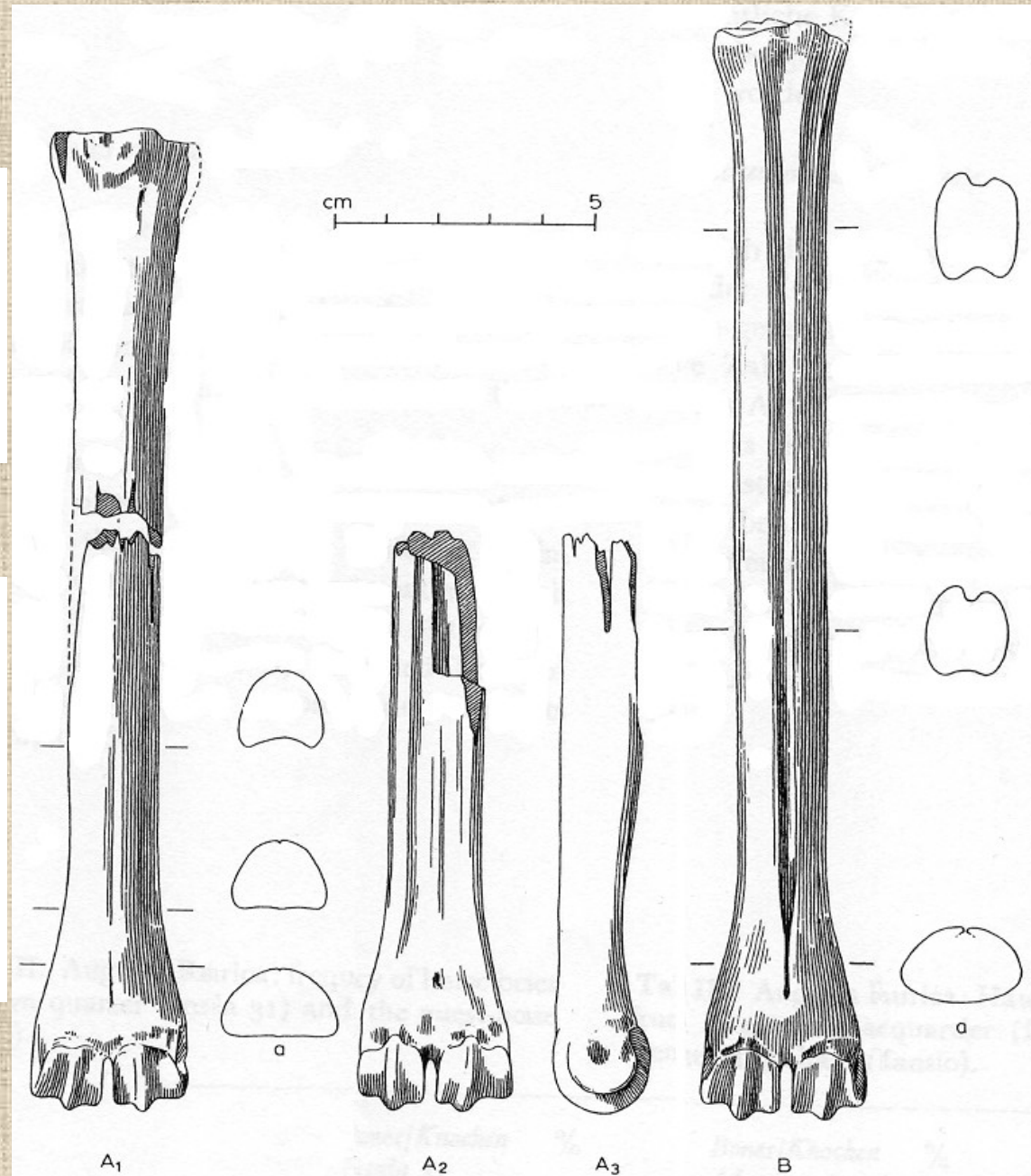
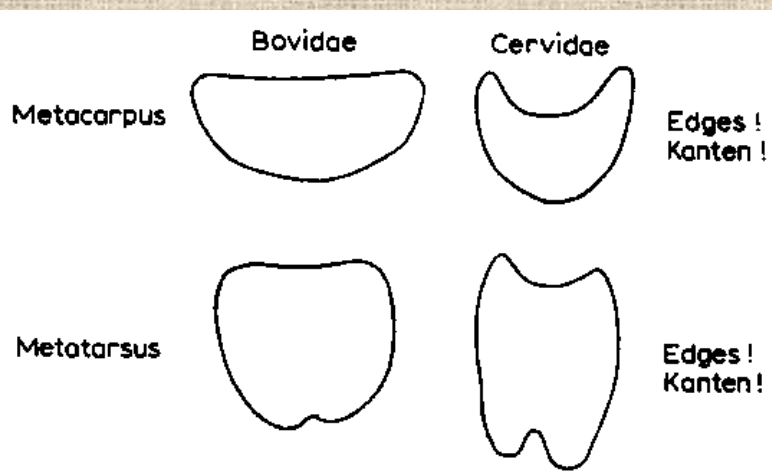
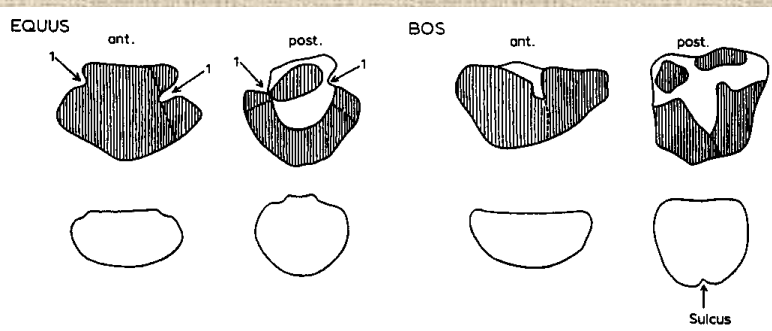


Kost hlezenní (*astragalus*)

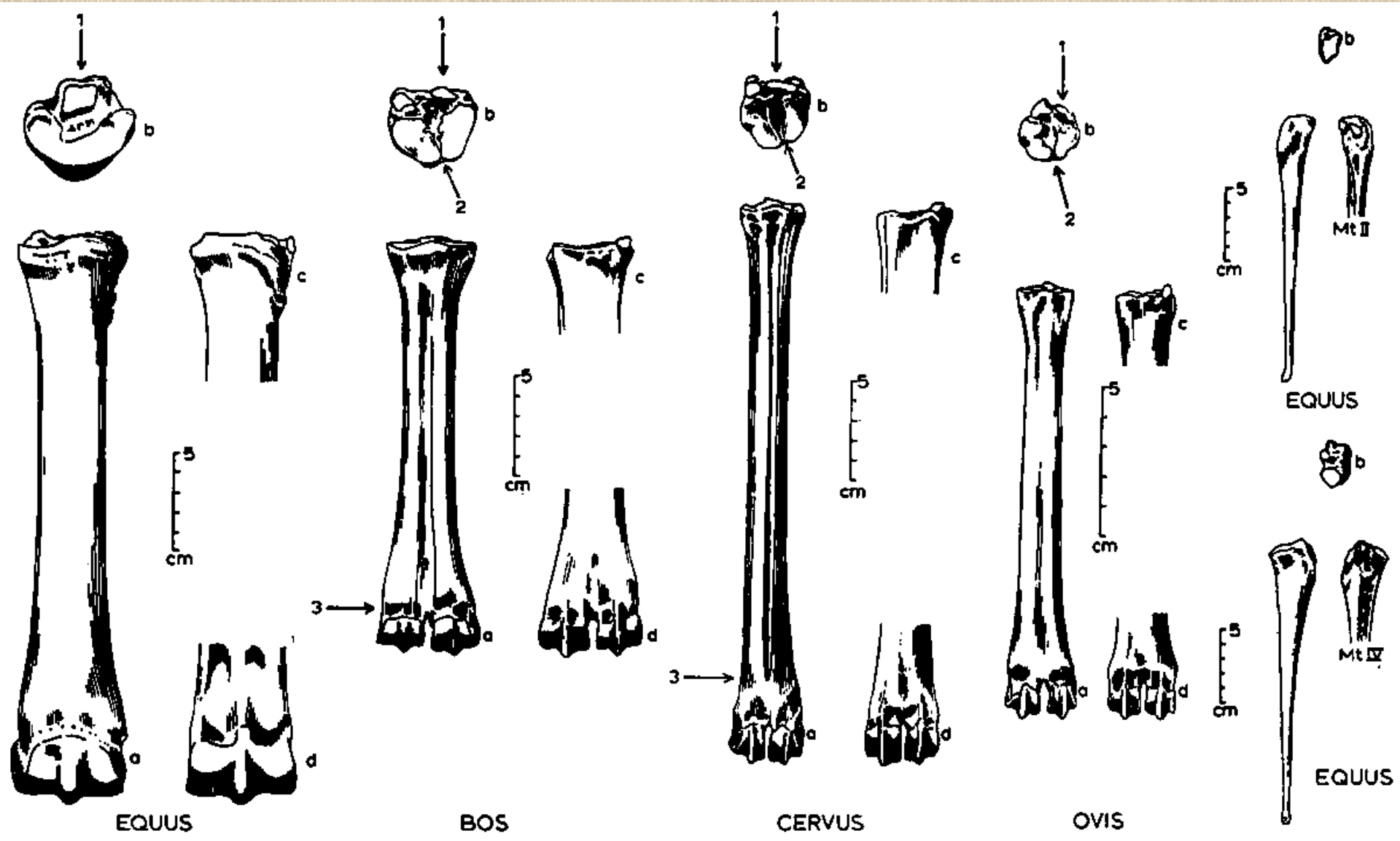
Rozdíly mezi kostmi patními býložravců a masožravců



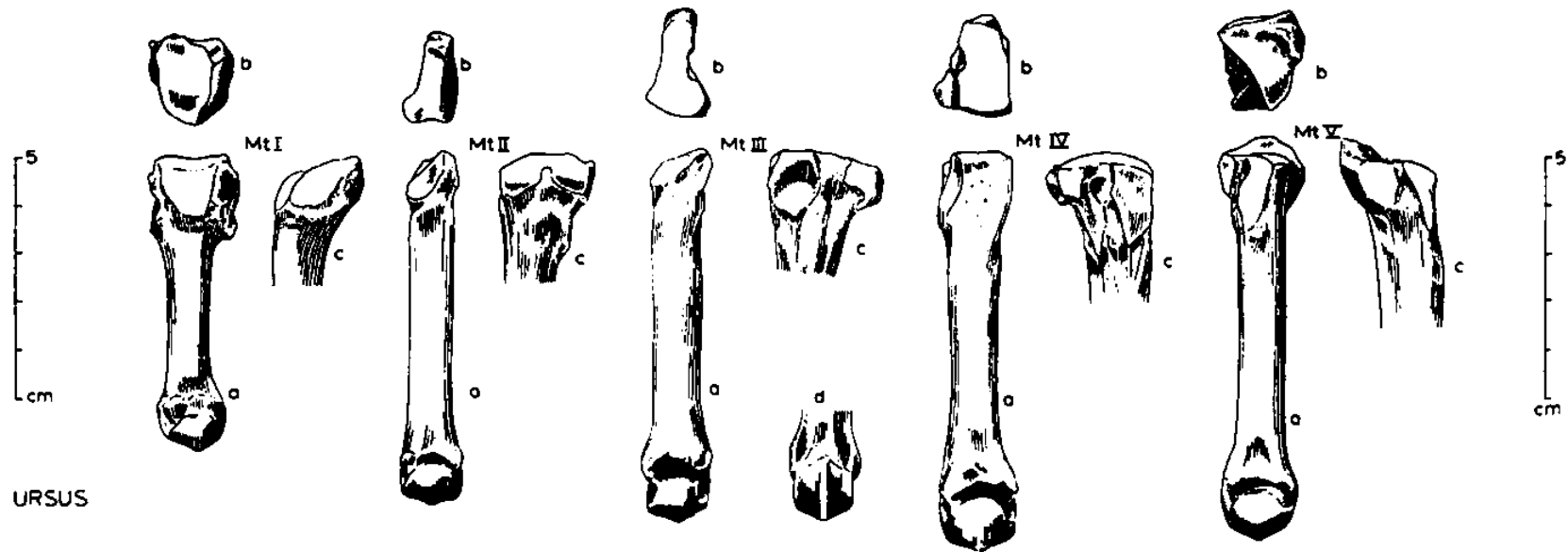
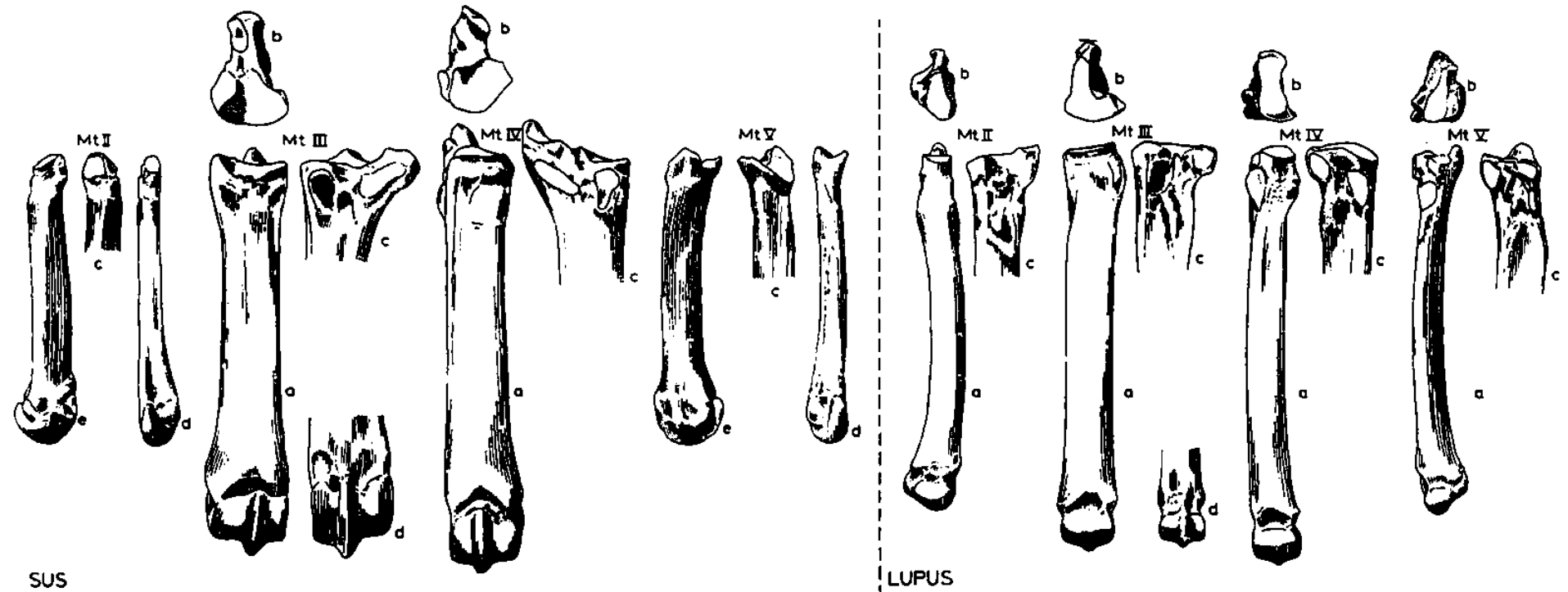
Rozdíl mezi záprstními a nártními kostmi



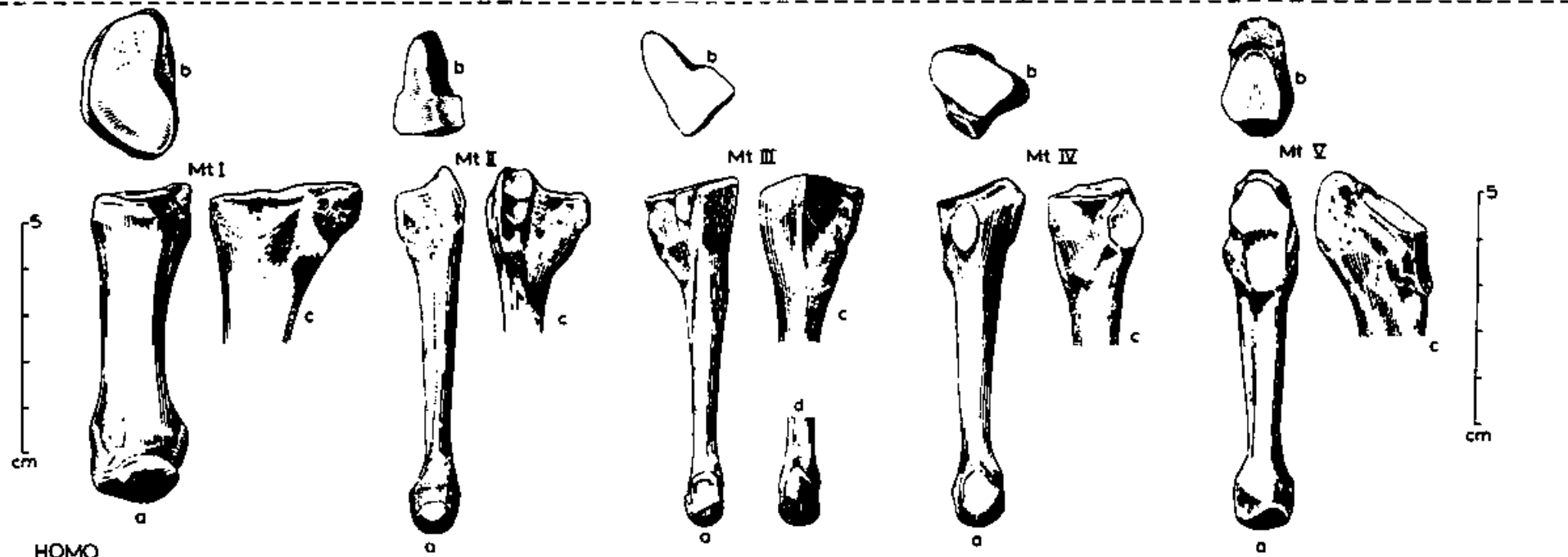
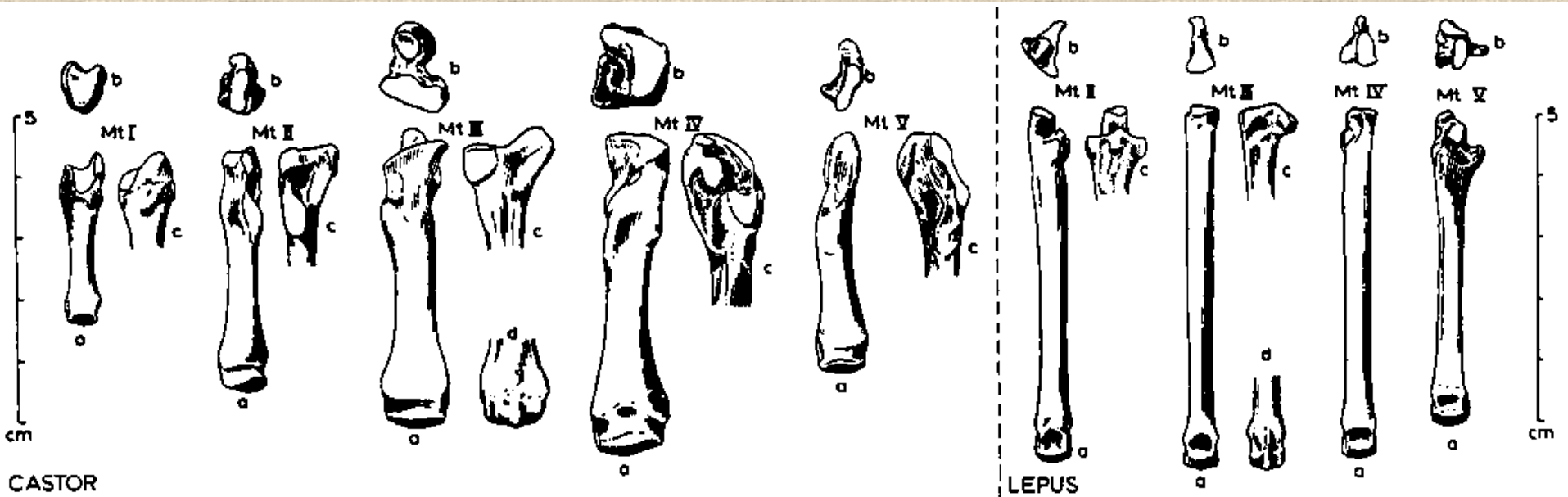
Nártní kost (*metatarsus*)

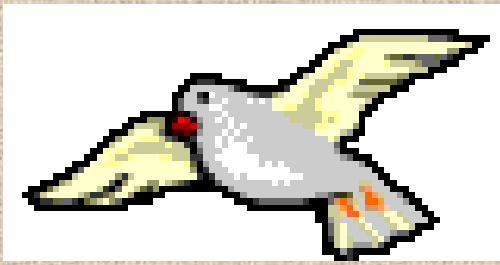

Nártní kost (*metatarsus*)

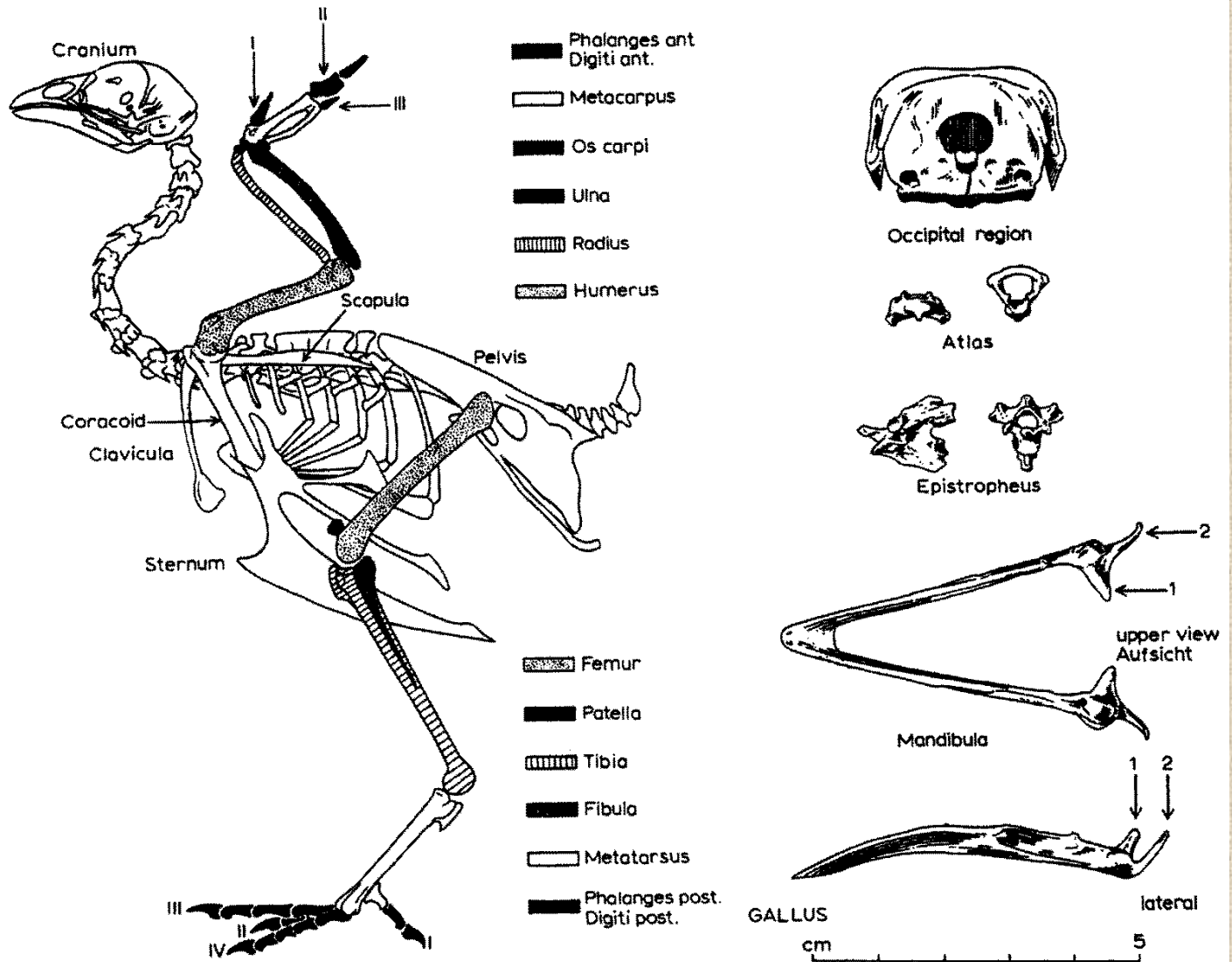


Nártní kost (*metatarsus*)

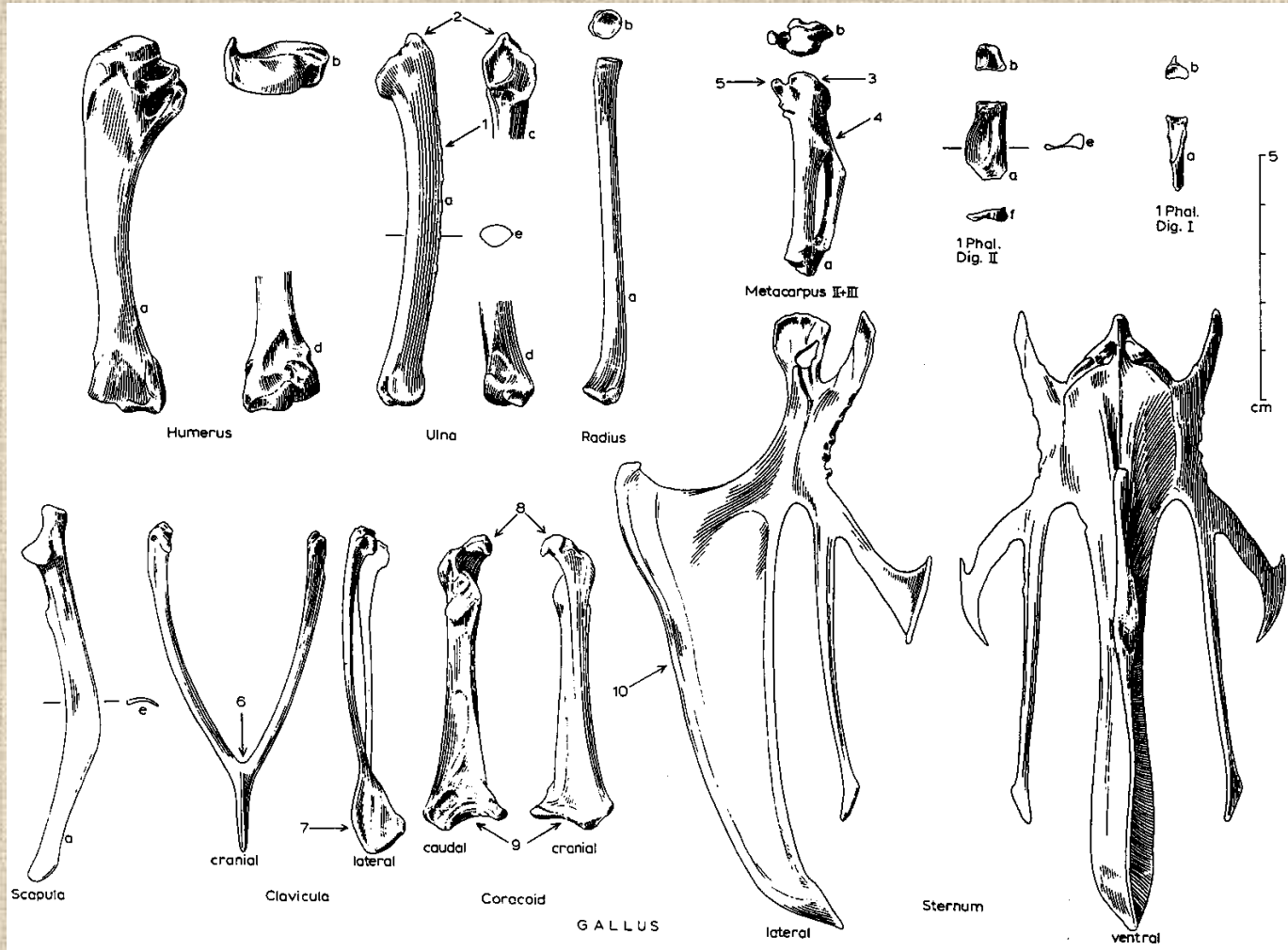




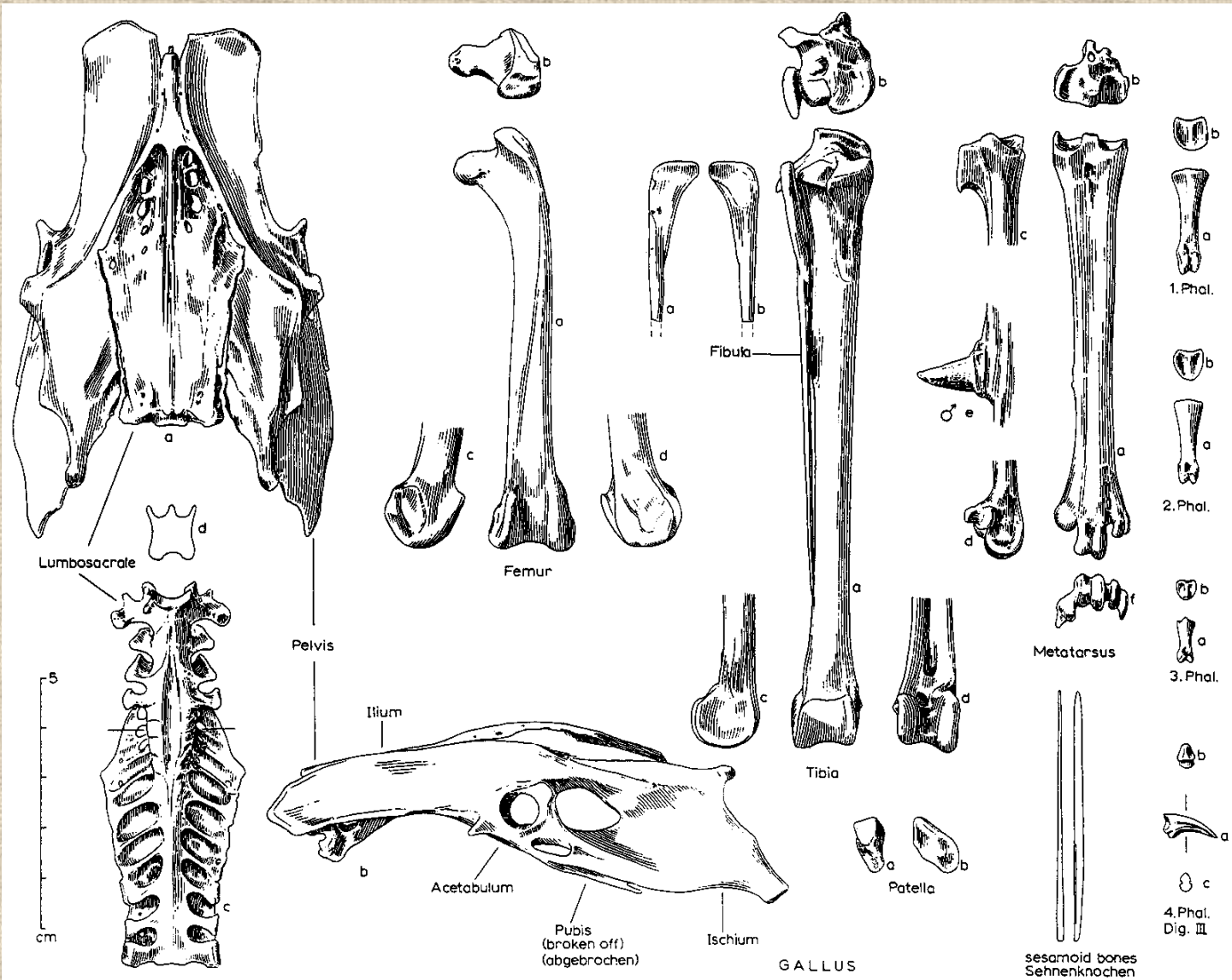
Ptačí kostra



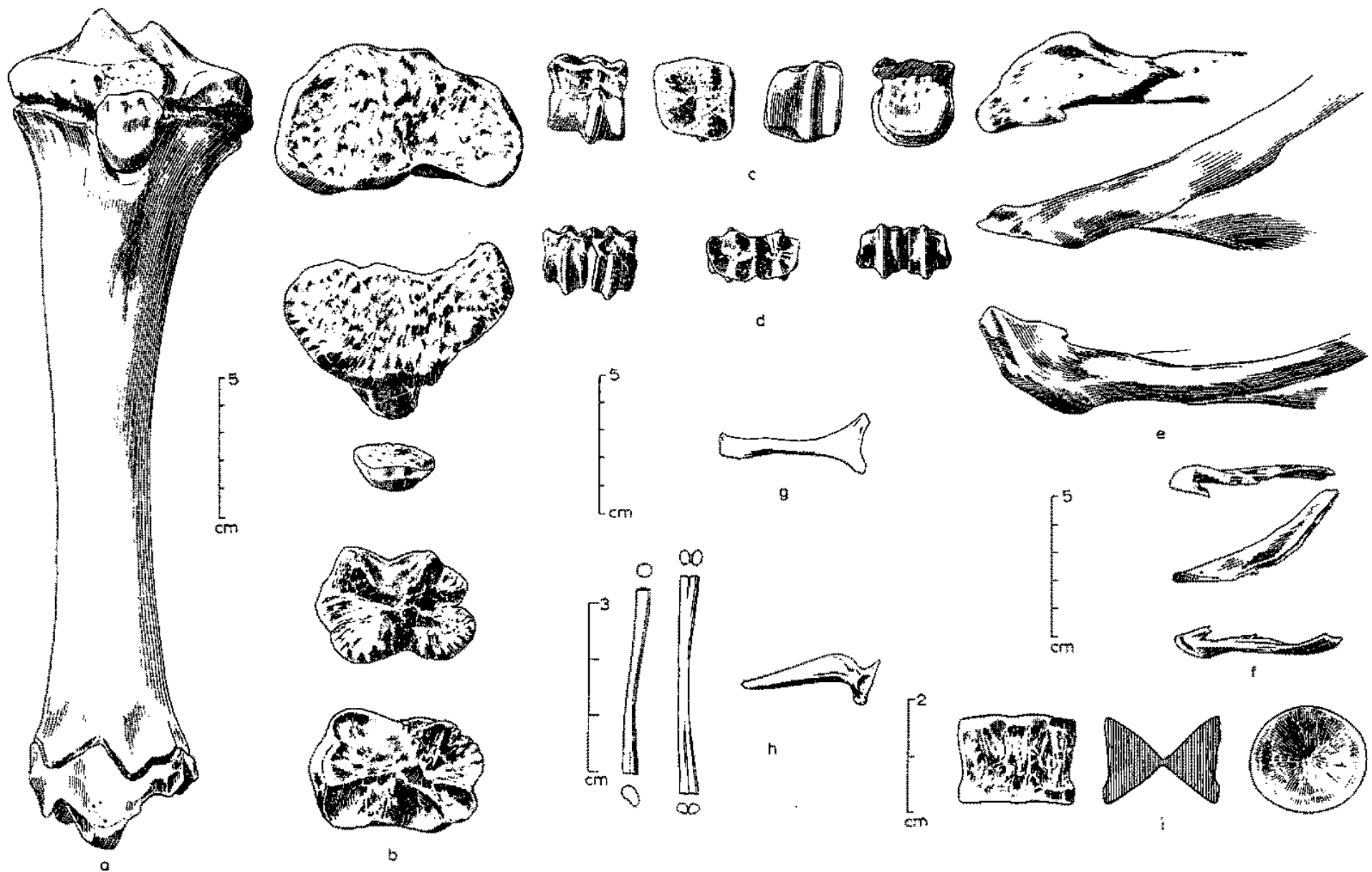
Kostra přední končetiny ptáka



Kostra zadní končetiny ptáka



Rozdílná morfologie kostí různých druhů zvířat



Děkuji za pozornost!

