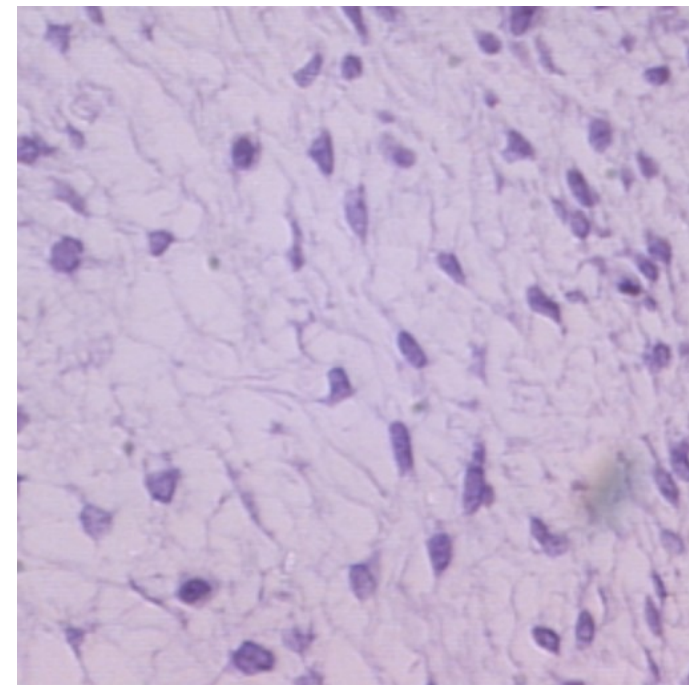
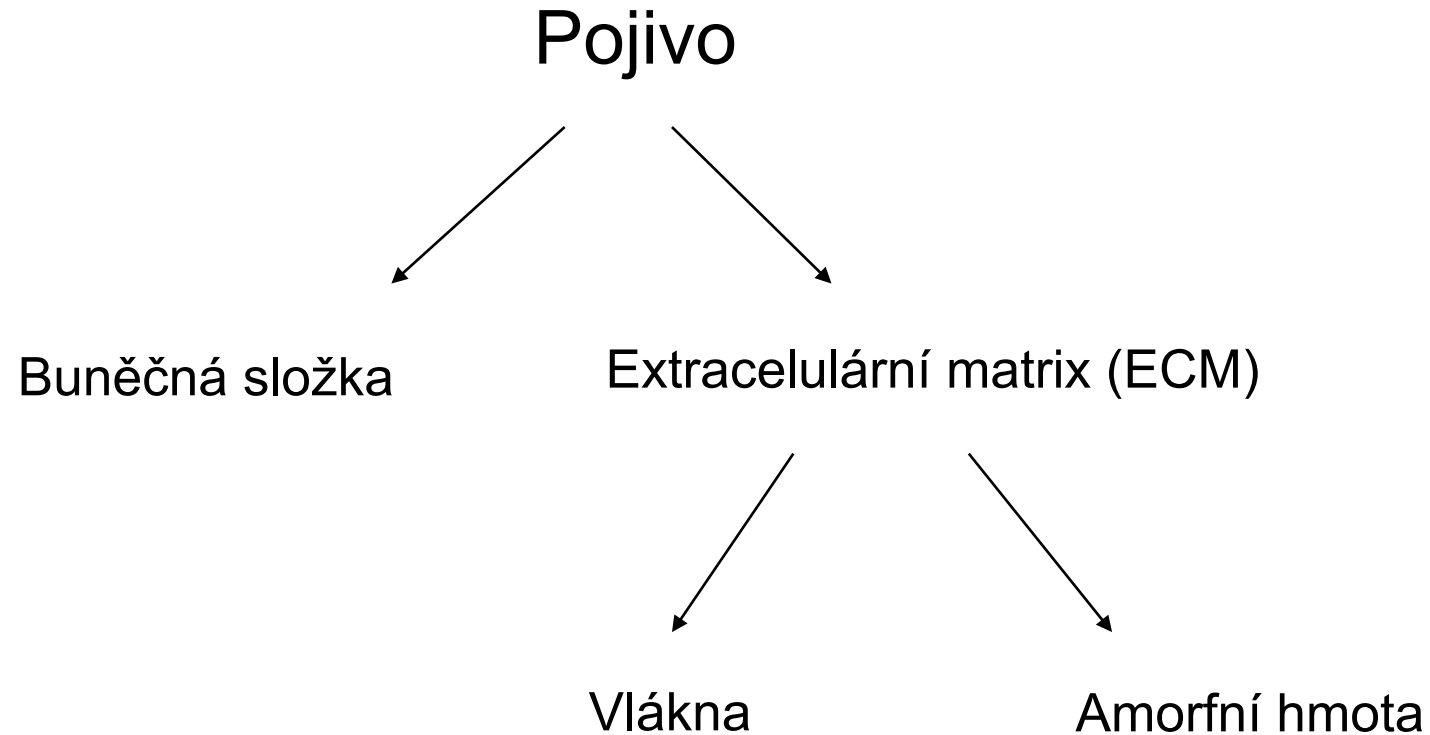


Pojivové tkáně, Vazivo

Charakteristika pojivové tkáně

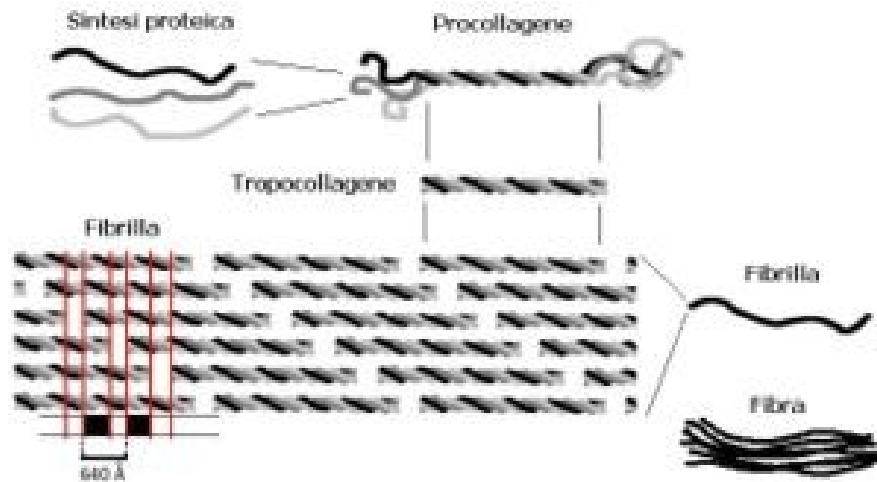


<http://www.anatomie.net/histowebatlas/m-139b.htm>

Typy vláken

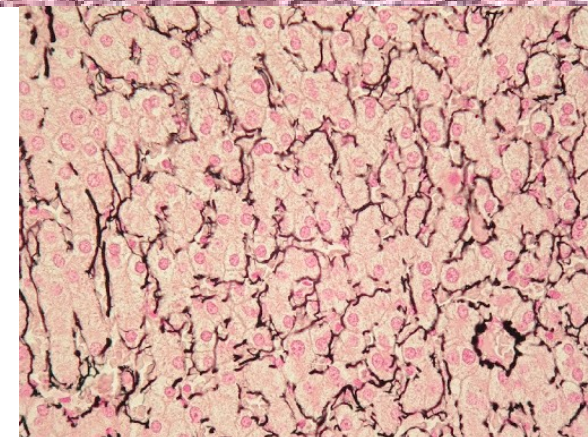


1. Kolagenní



<https://cs.wikipedia.org/wiki/Kolagen>

2. Elastická



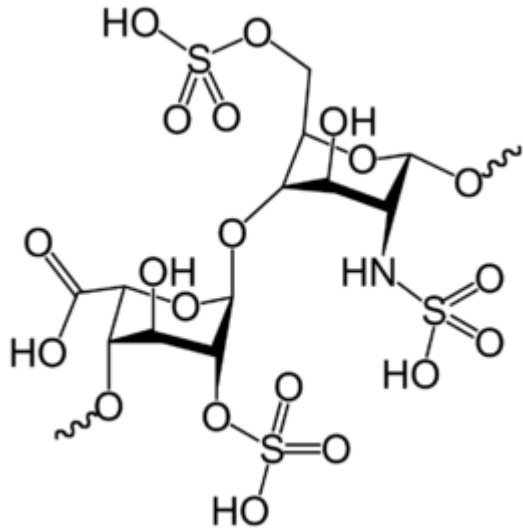
3. Retikulární

Základní hmota amorfní


Její součástí jsou:

- 1. Glykosaminoglykany**
- 2. Proteoglykany**
- 3. Glykoproteiny**

Glykosaminoglykany



<https://cs.wikipedia.org/wiki/Heparin>



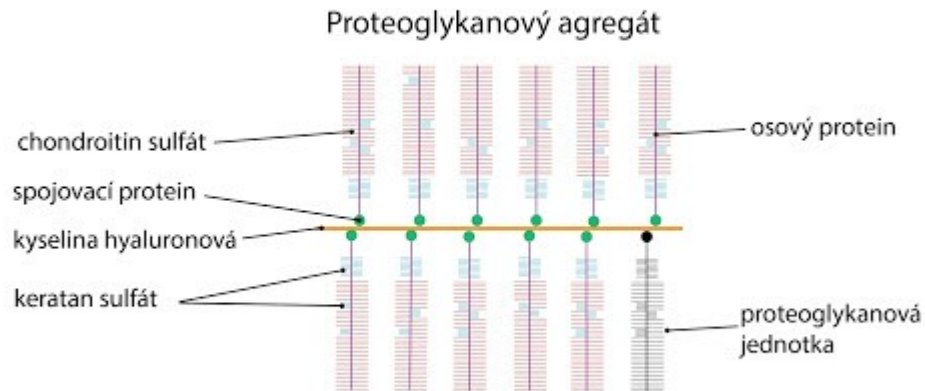
x 1000

https://cs.wikipedia.org/wiki/Kyselina_hyaluronov%C3%A1

Proteoglykany a glykoproteiny



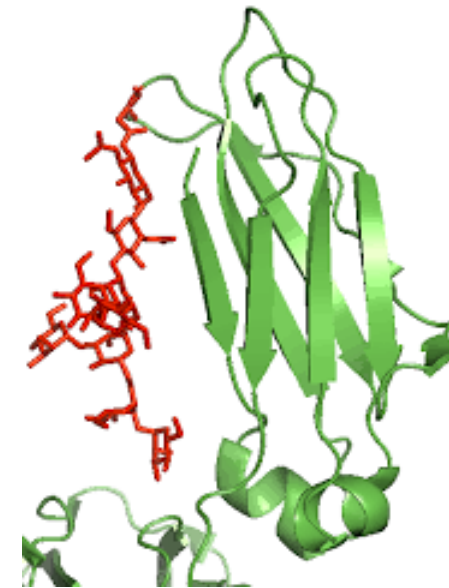Proteoglykany



<http://fblt.cz/skripta/ii-premena-latek-a-energie-v-bunce/140-2/>

Sacharidy > Proteíny

Glykoproteiny

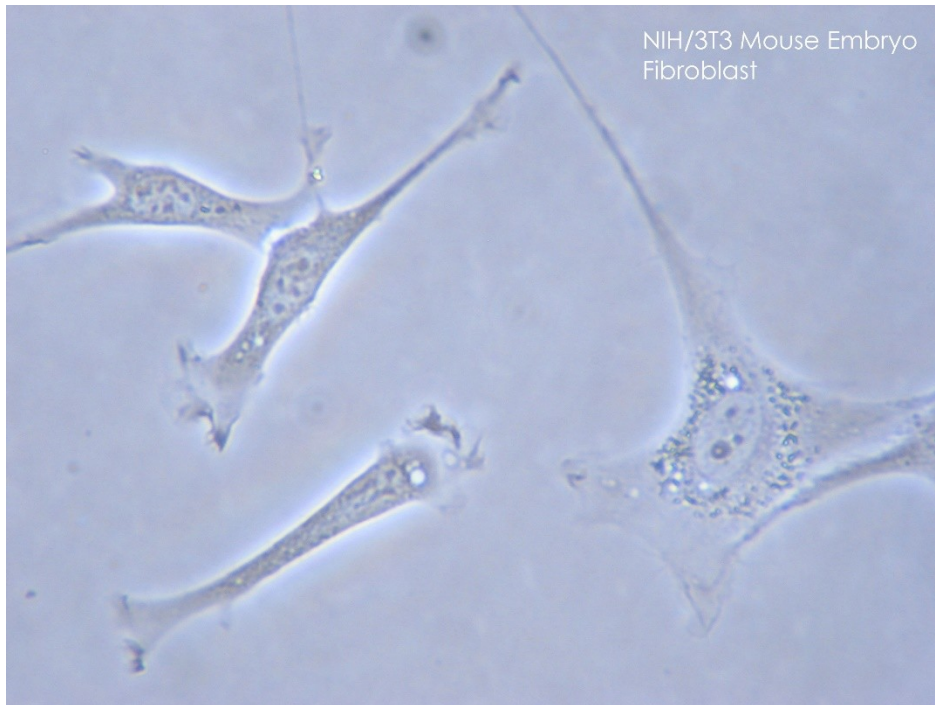

<https://www.intechopen.com/books/glycosylation/structural-biology-of-glycoproteins>

Sacharidy < Proteíny

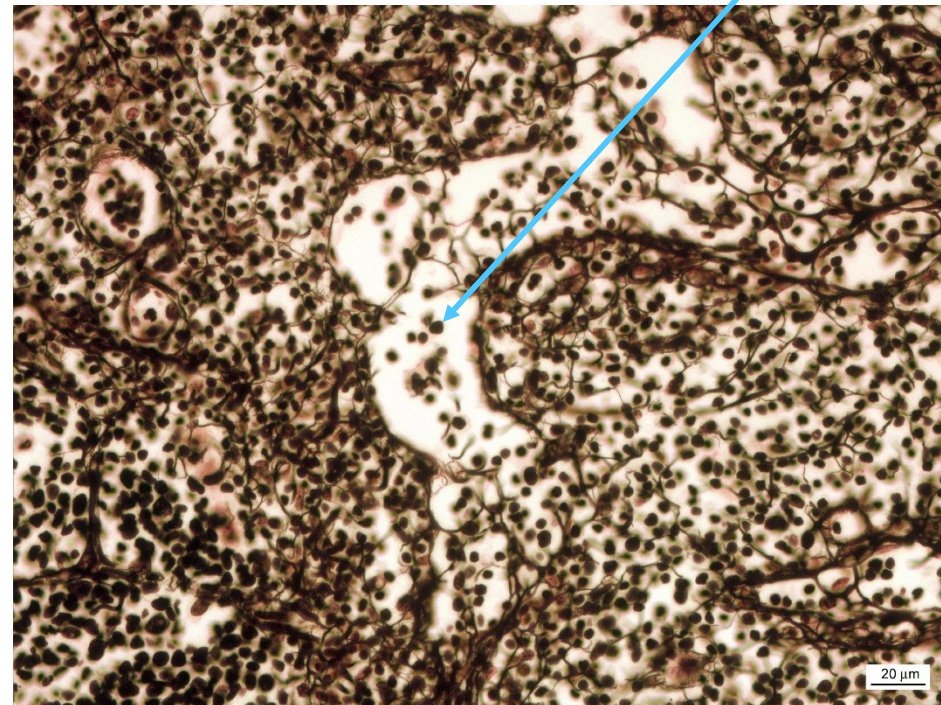
Buňky vaziva - producenti ECM

Fibroblasty



<https://en.wikipedia.org/wiki/Fibroblast>

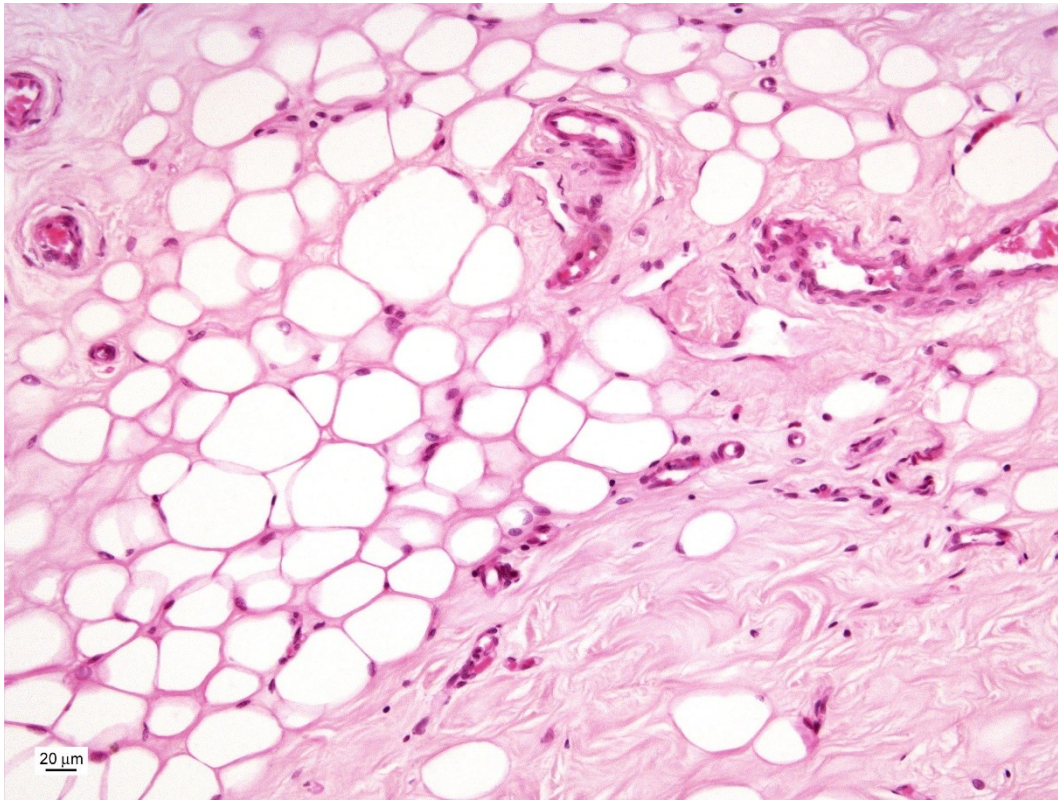
Retikulární buňky



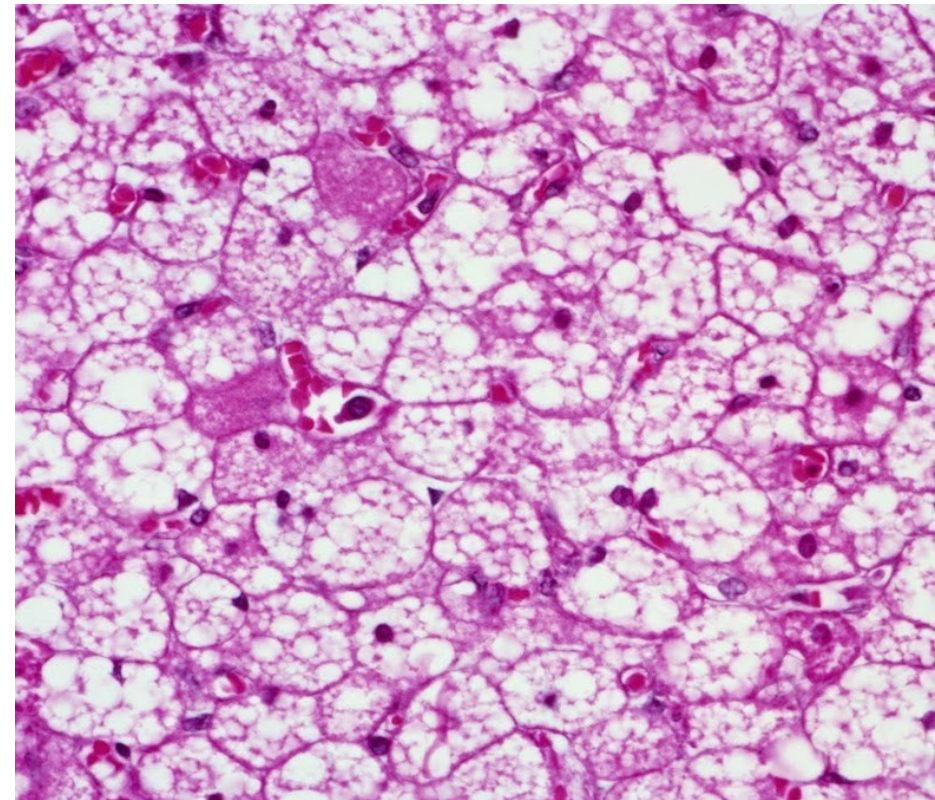
Buňky vaziva - adipocyty



Unilokulárne adipocyty



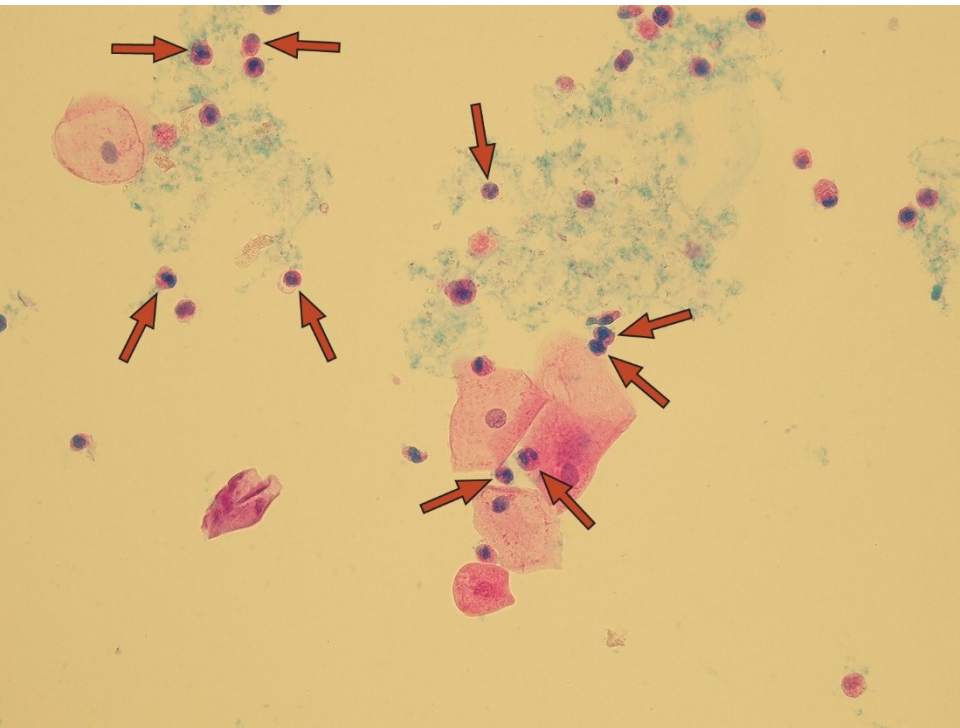
Multilokulárne adipocyty



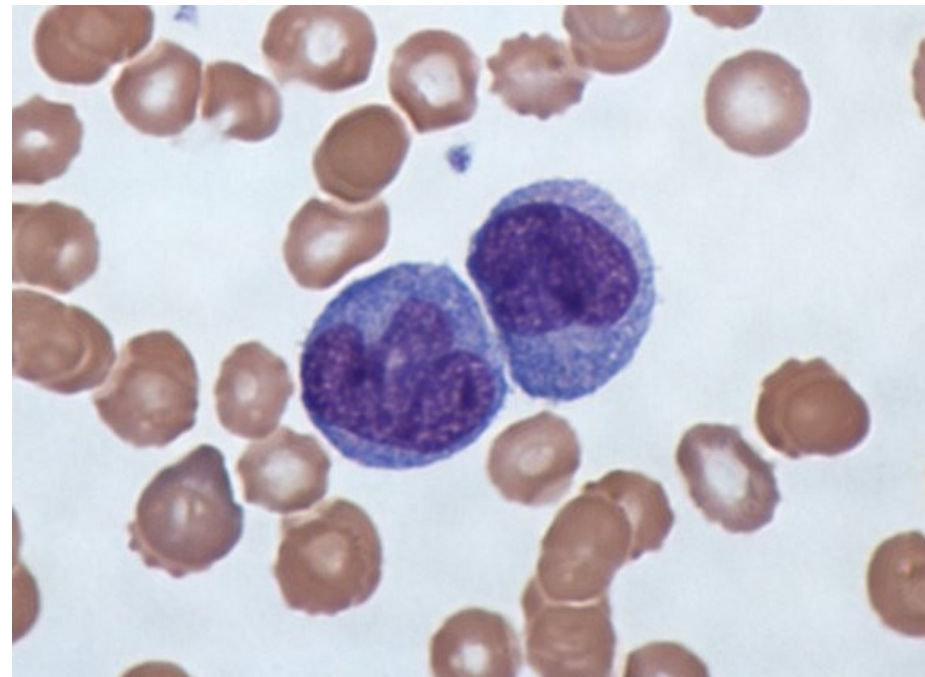
<https://focusonpath.com/in-vivo-noninvasive-detection-of-brown-adipose-tissue-through-intermolecular-zero-quantum-mri/>

Buňky vaziva - buňky imunitního systému

Granulocyty +
lymfocyty



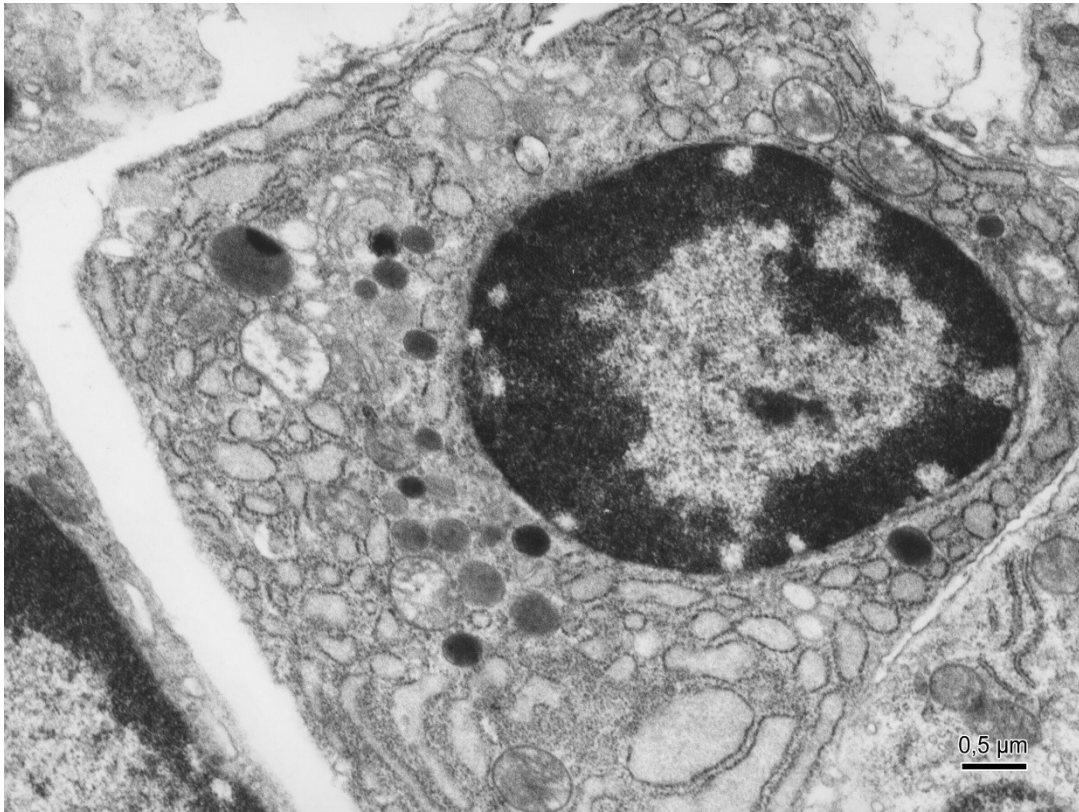
Makrofágy



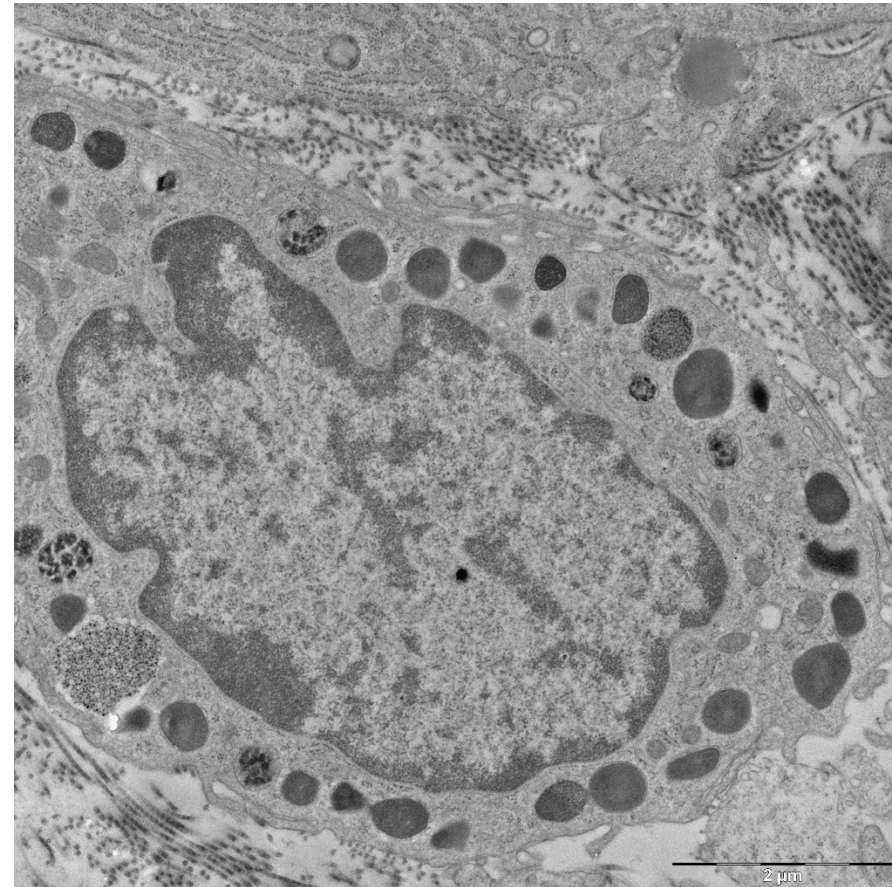
wikipedia.org/macrophages

Buňky vaziva - buňky imunitního systému

Plazmatické bunky



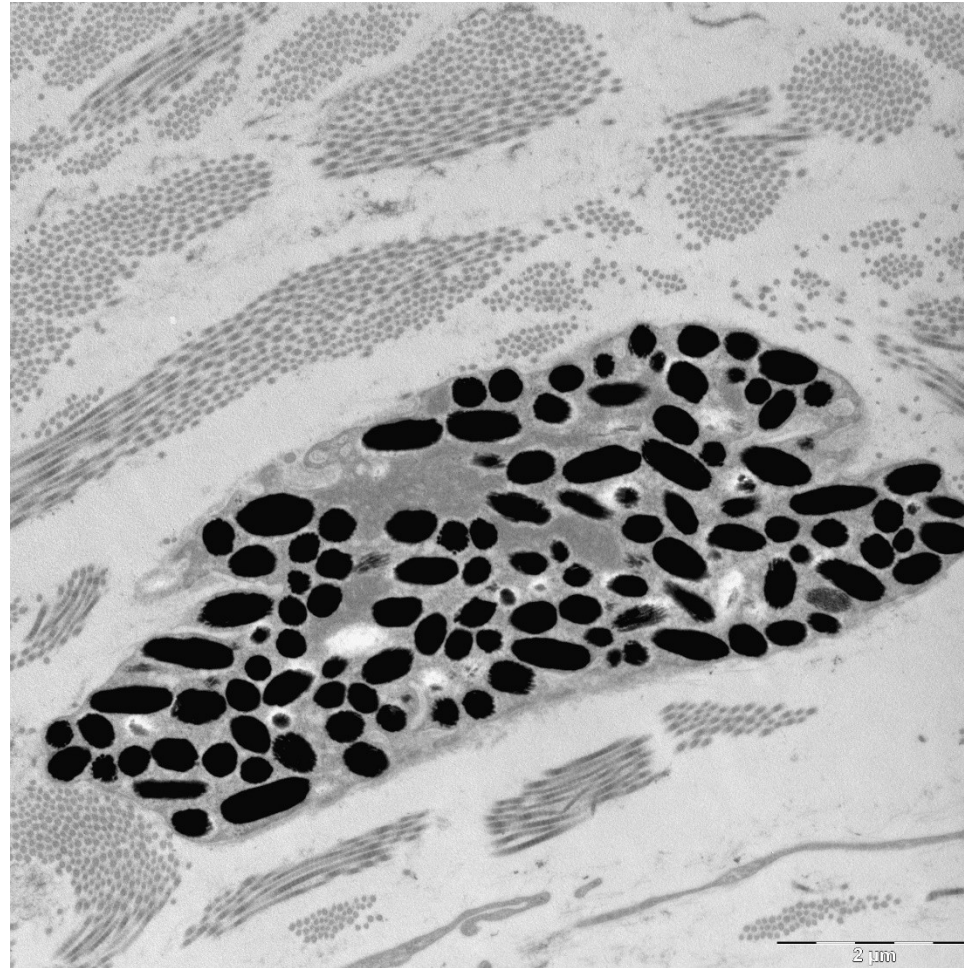
Žírné bunky



Buňky vaziva - pigmentové buňky



Melanocyty – původ z neurální lišty

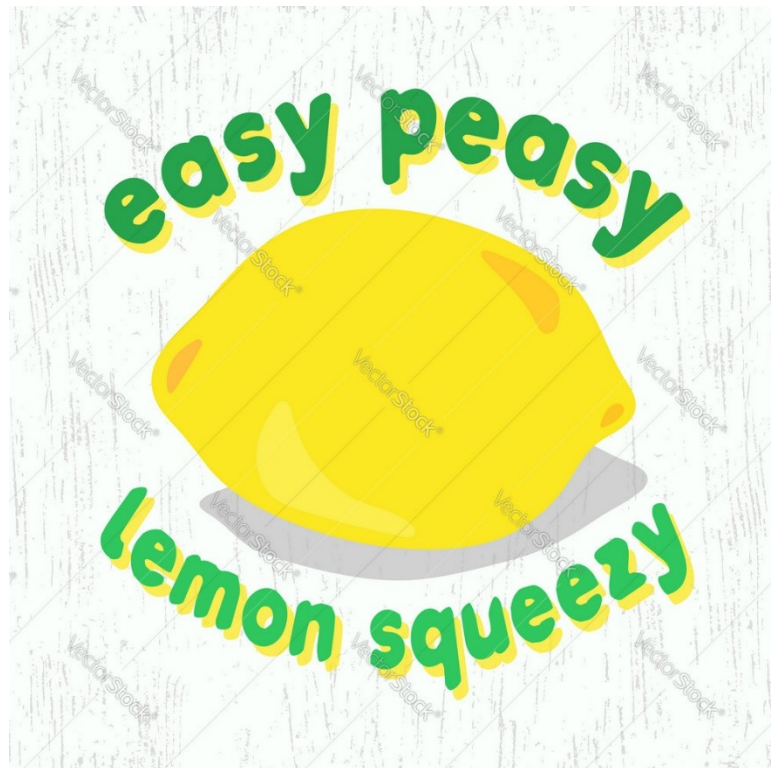

Funkce vaziva

Funkce vaziva je dána jeho složením, tedy jaké buňky a jaká ECM se v něm nachází:

1. **Mechanická** – daná hlavne kolagenem a další ECM
2. **Nutritivní** – složení vaziva podmiňuje tvorbu cév a vaskularizaci
3. **Imunitní** – interakce s imunitním systémem. Podmíněná mj. rozsahem vaskularizace
4. **Zásoba energie** – tukové buňky zajišťující metabolismus lipidů
5. **Nosná síť orgánů** – jemné mikroprostředí pro různé typy buněk

Typy a stavba vaziva



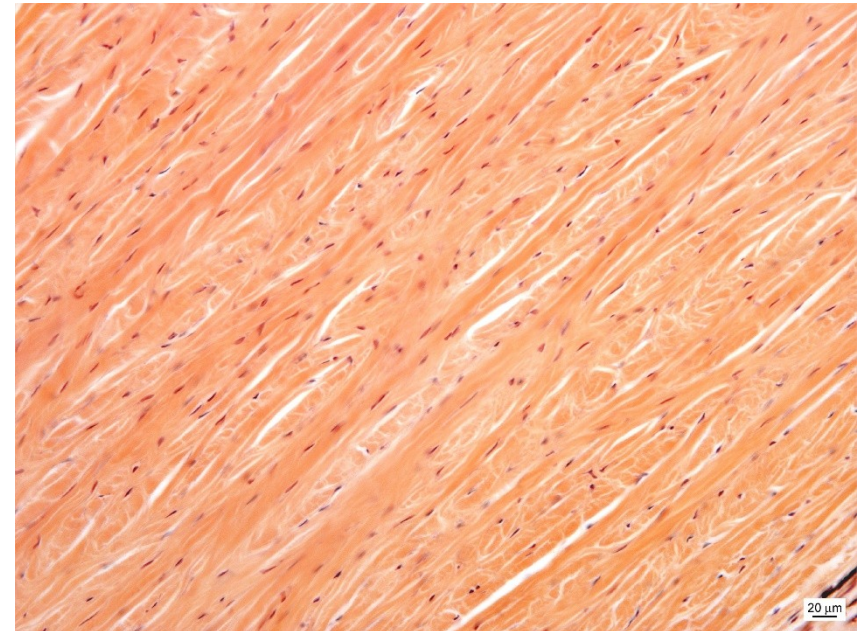
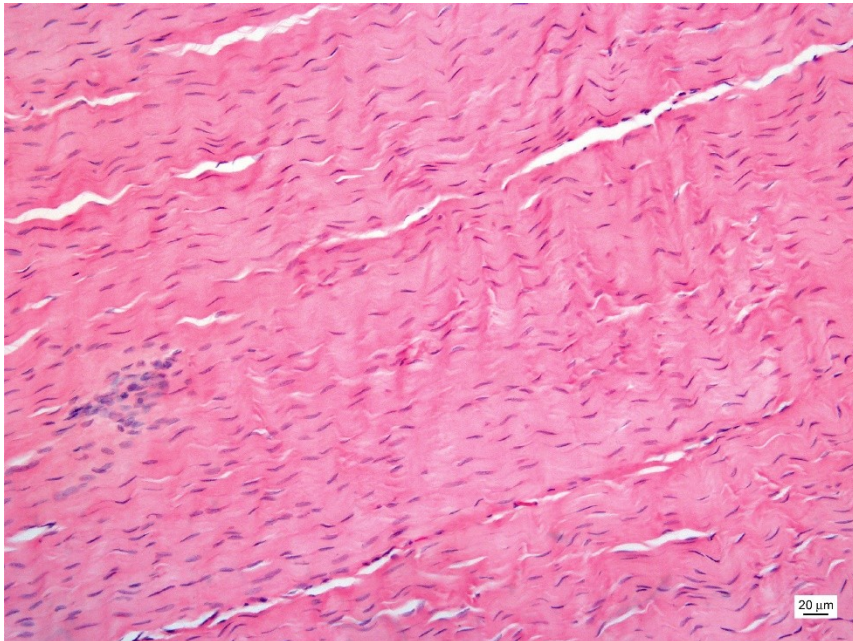
Typy vaziva



Husté kolagenní vazivo

Uspořádané

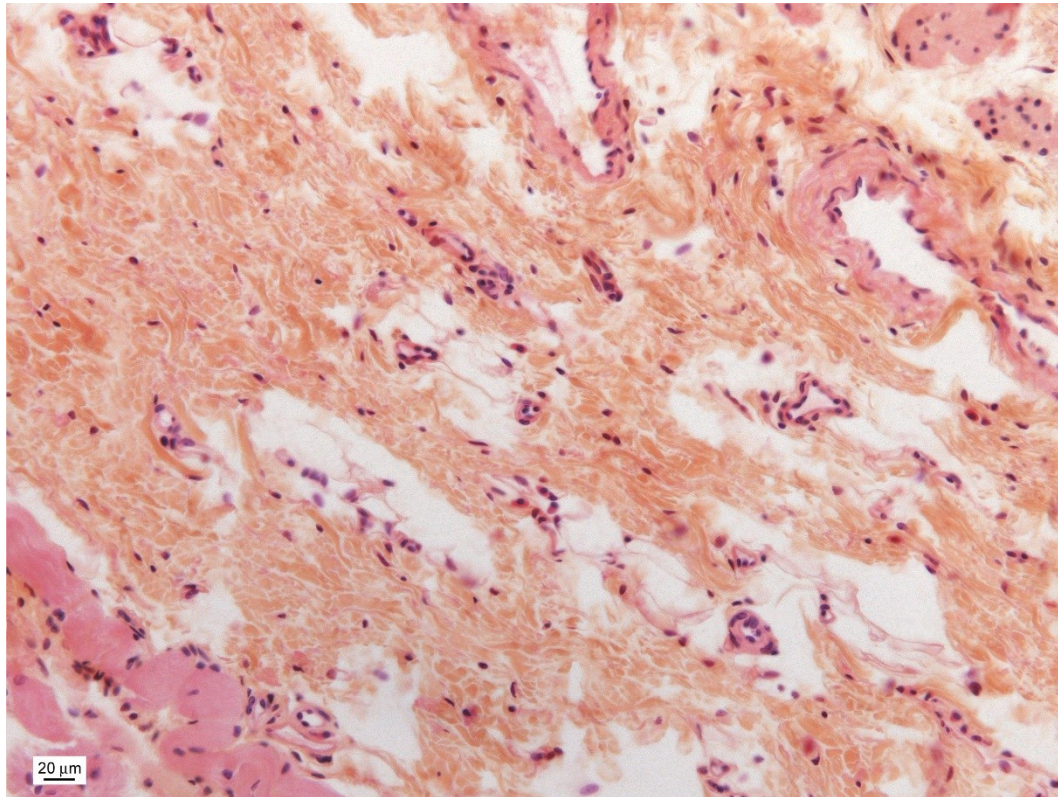
Neuspořádané



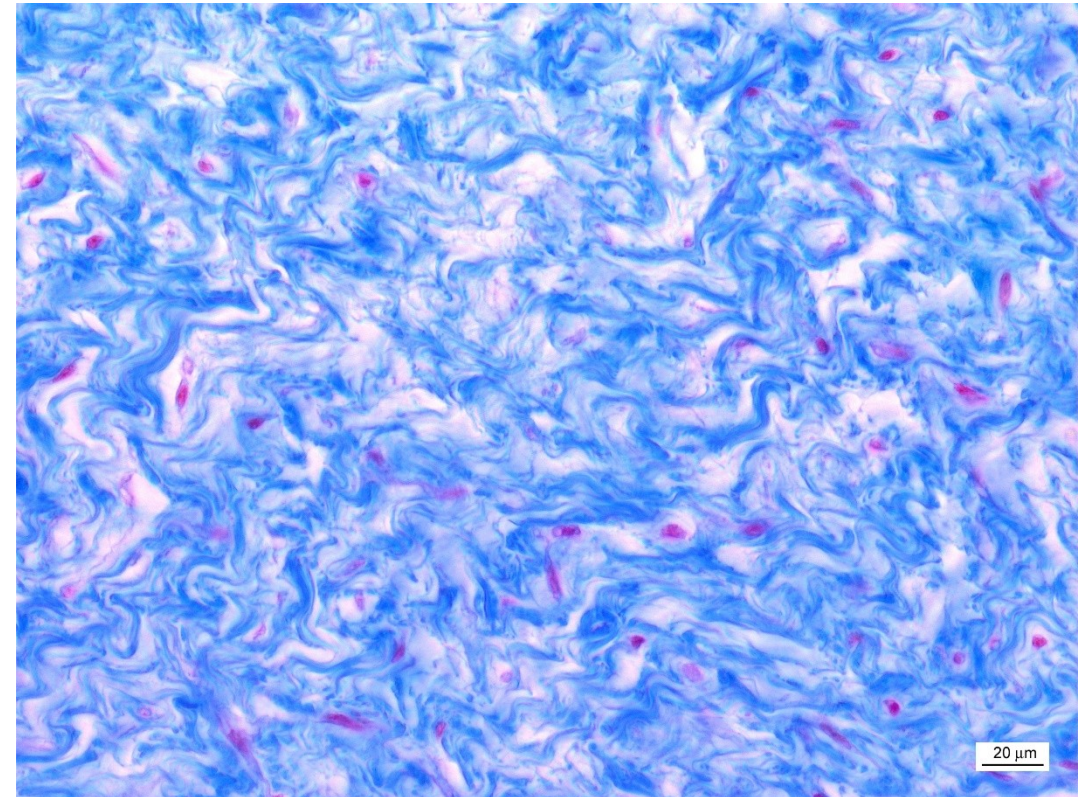
Typy vaziva



Řídké kolagenní



Rosolovitě

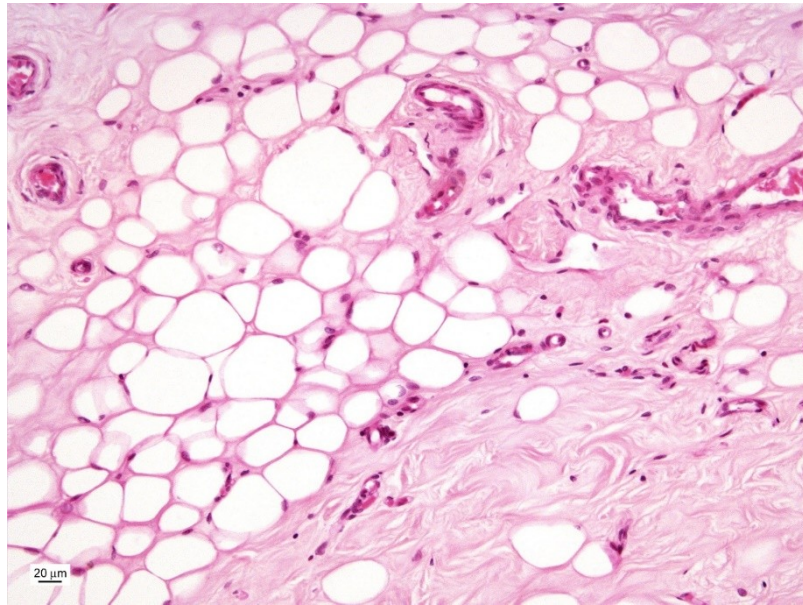



Typy vaziva

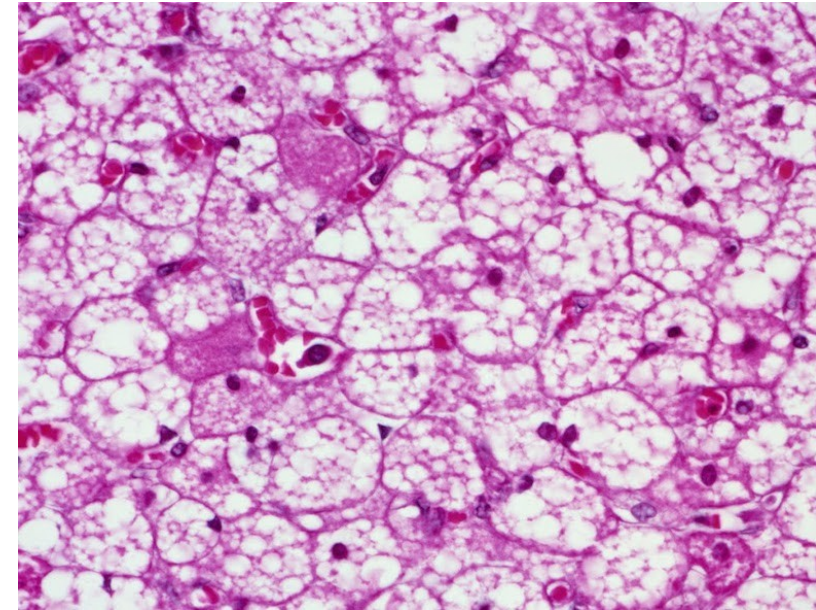



Tuková tkáň

Bílá

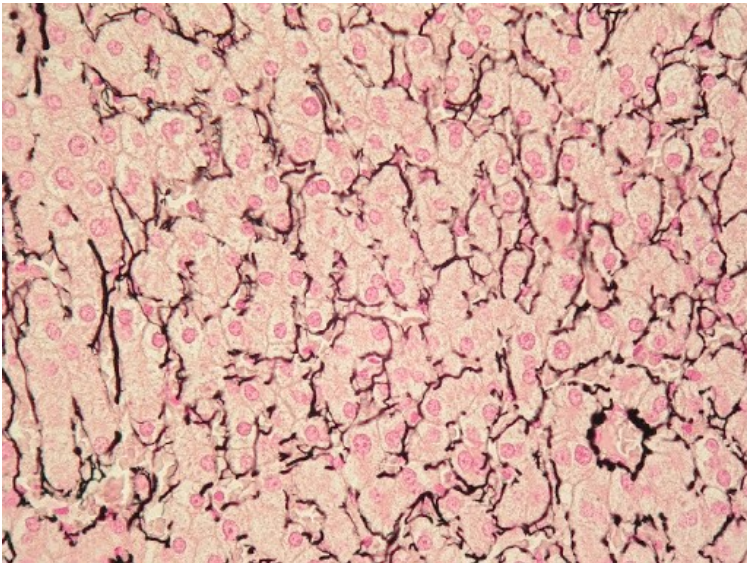


Hnědá

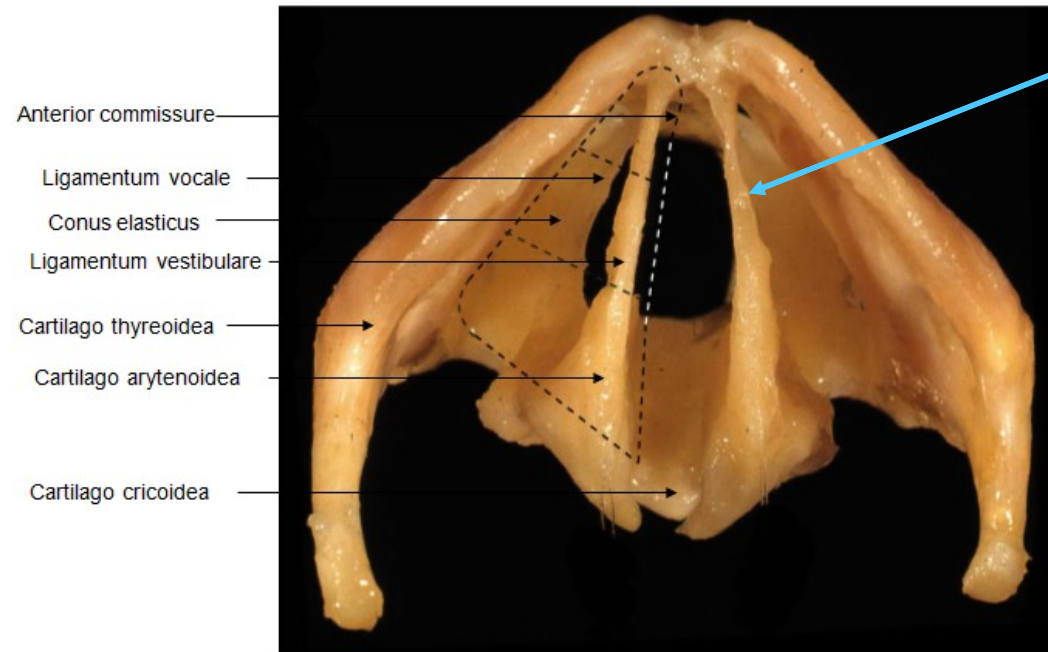


Typy vaziva

Retikulární vazivo



Elastické vazivo



https://www.researchgate.net/figure/Bony-and-fibroelastic-structures-of-the-larynx-Axial-view-Specimen-of-the-scientific_fig2_224899279



Klára Dolinová
Peter Staňo
Yehonatan Solomonov
Petr Vaňhara

2020