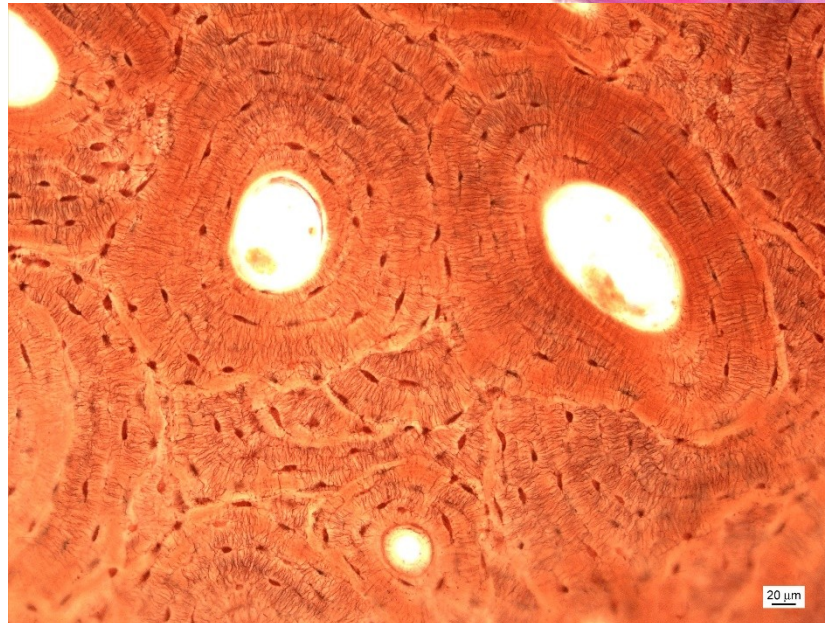
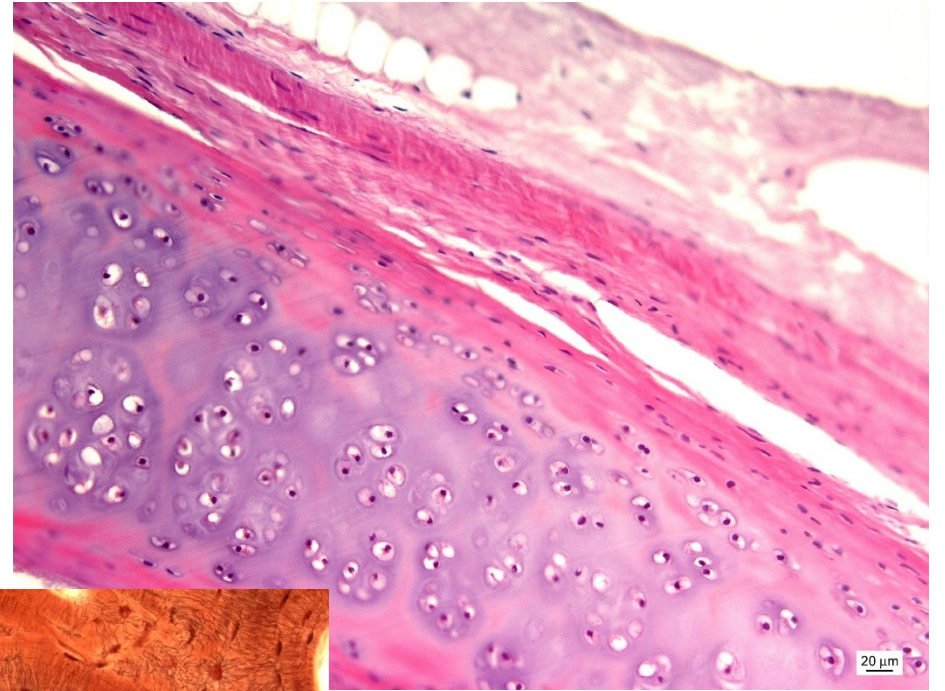
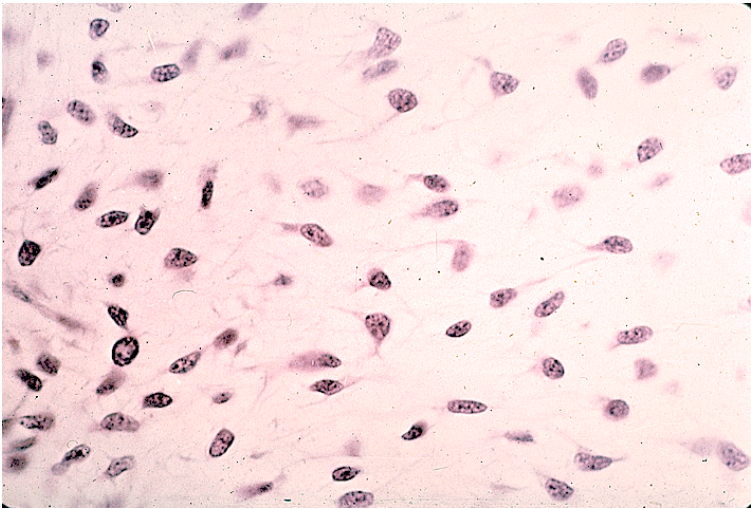


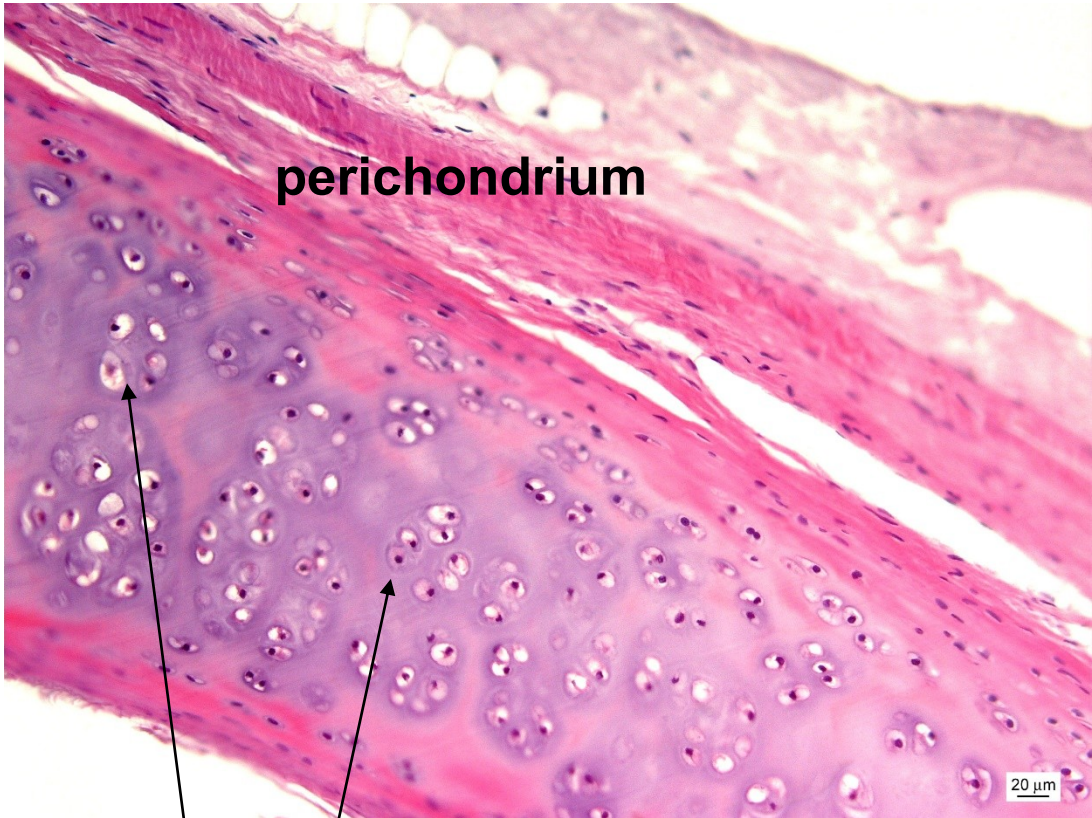
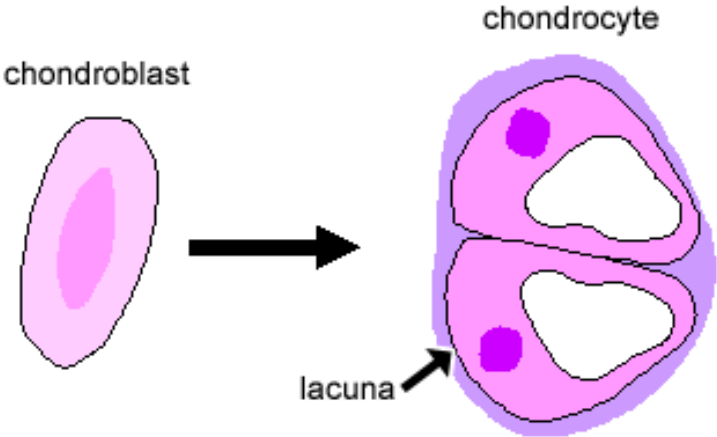
CHRUPAVKA & KOST



Hyalinní chrupavka



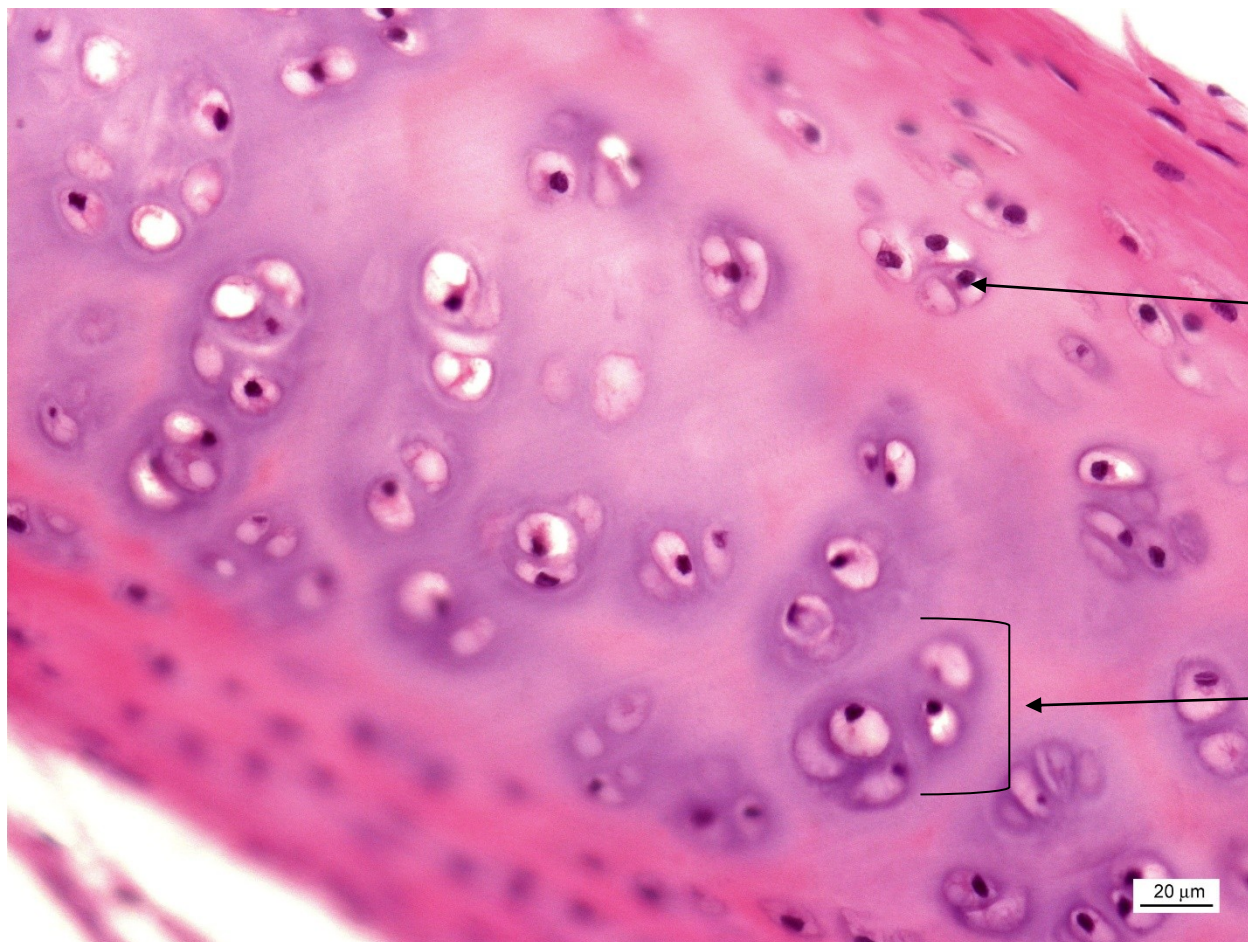
mesenchym



perichondrium

izogenetická skupina

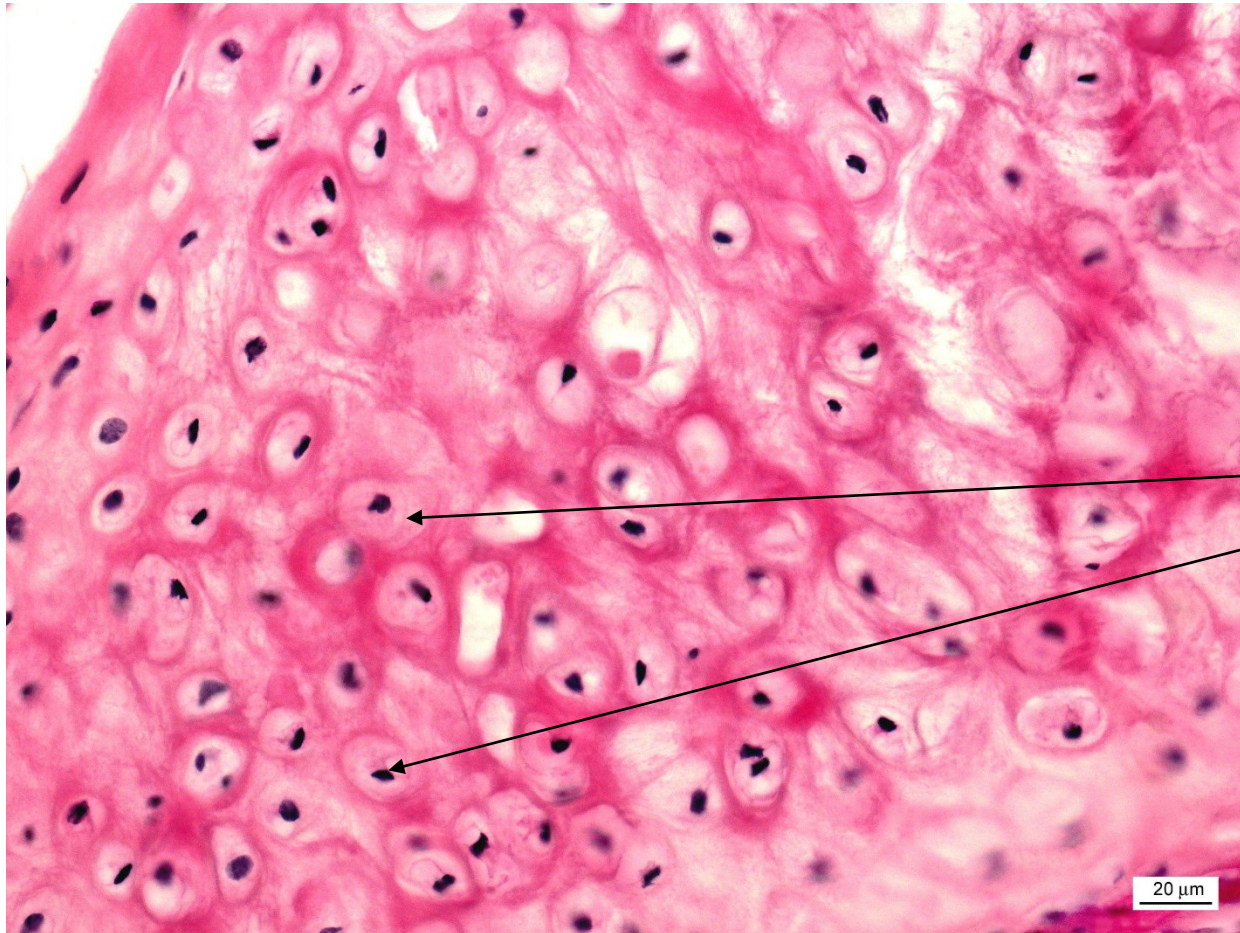
Hyalinní chrupavka



izogenetické skupiny

chondrony

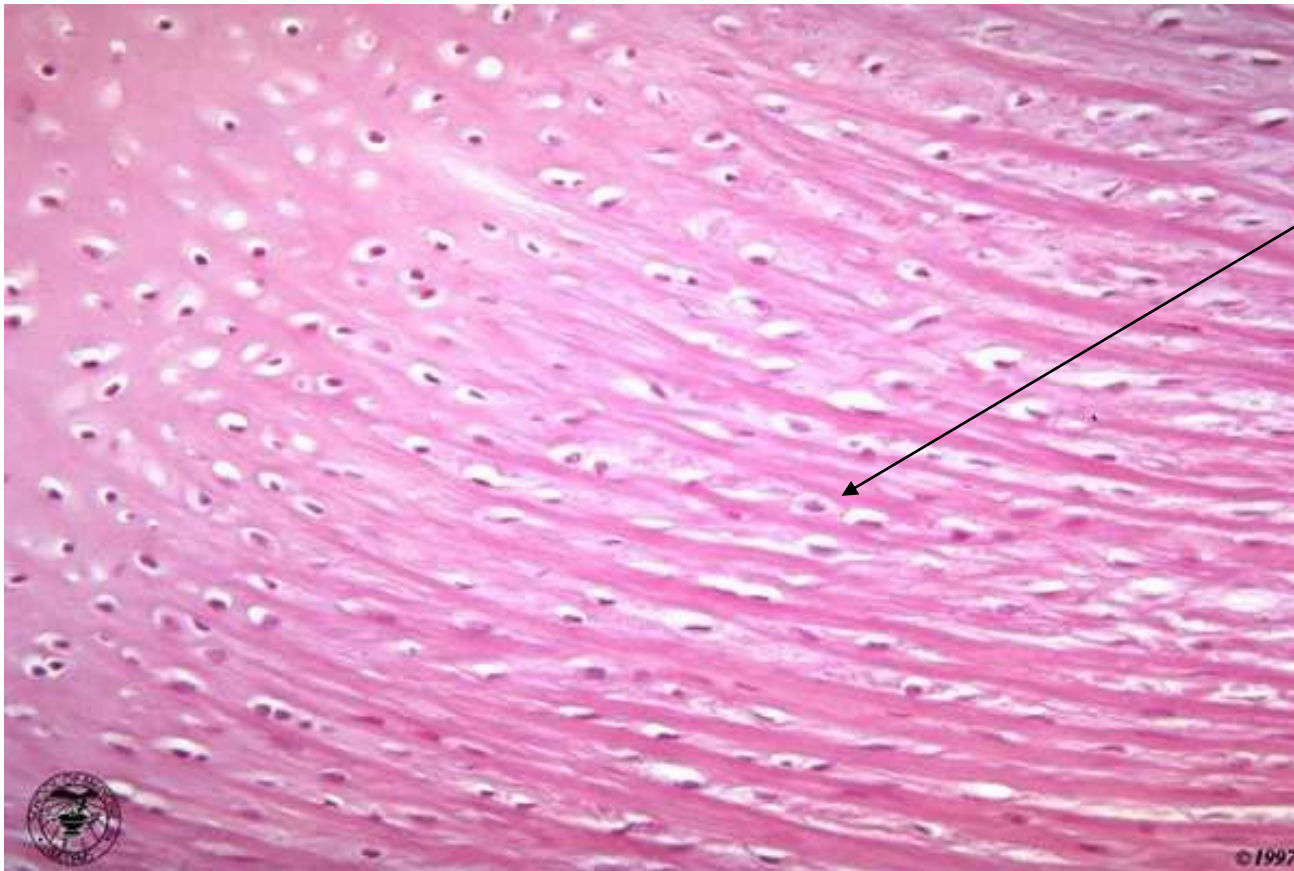Elastická chrupavka



BEZ izogenetických skupin

chondrocyty rozptýlené

Vazivová chrupavka


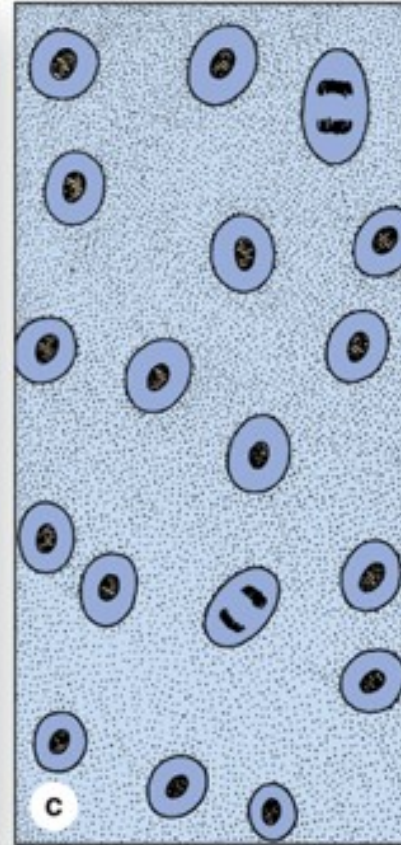

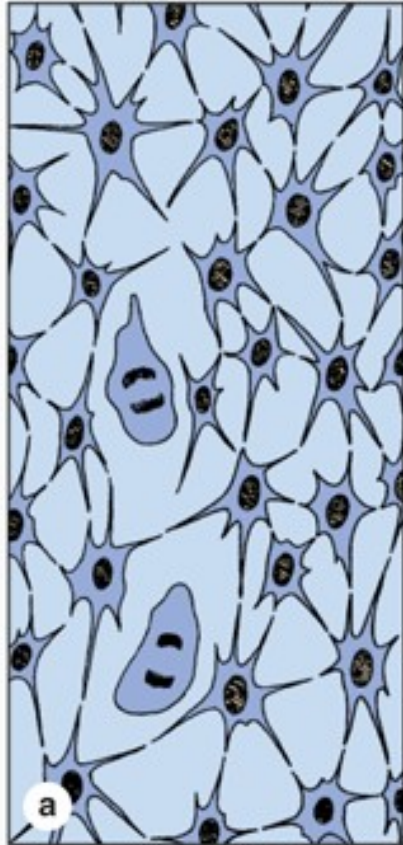


chondrocyty v řadě

bez perichondria

**podobná hustému kolagennímu
vazivu**

Chondrogeneze

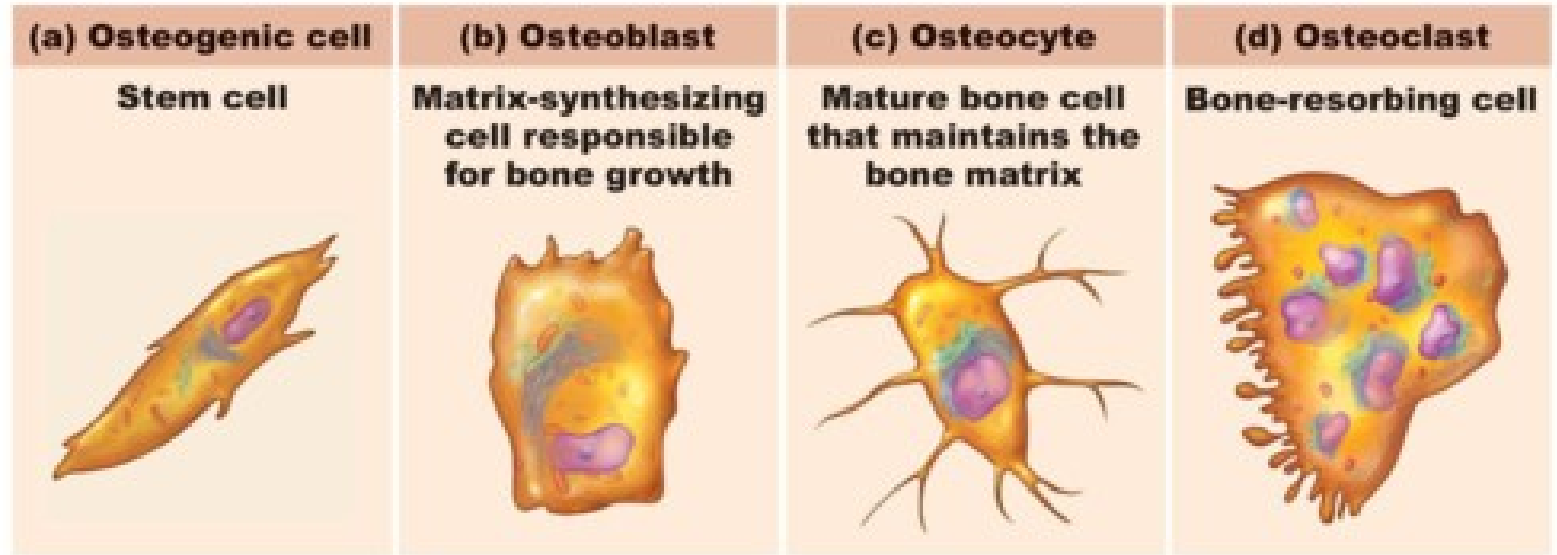


Mesenchym


Chrupavčitý blastém

Chrupavka

Kost

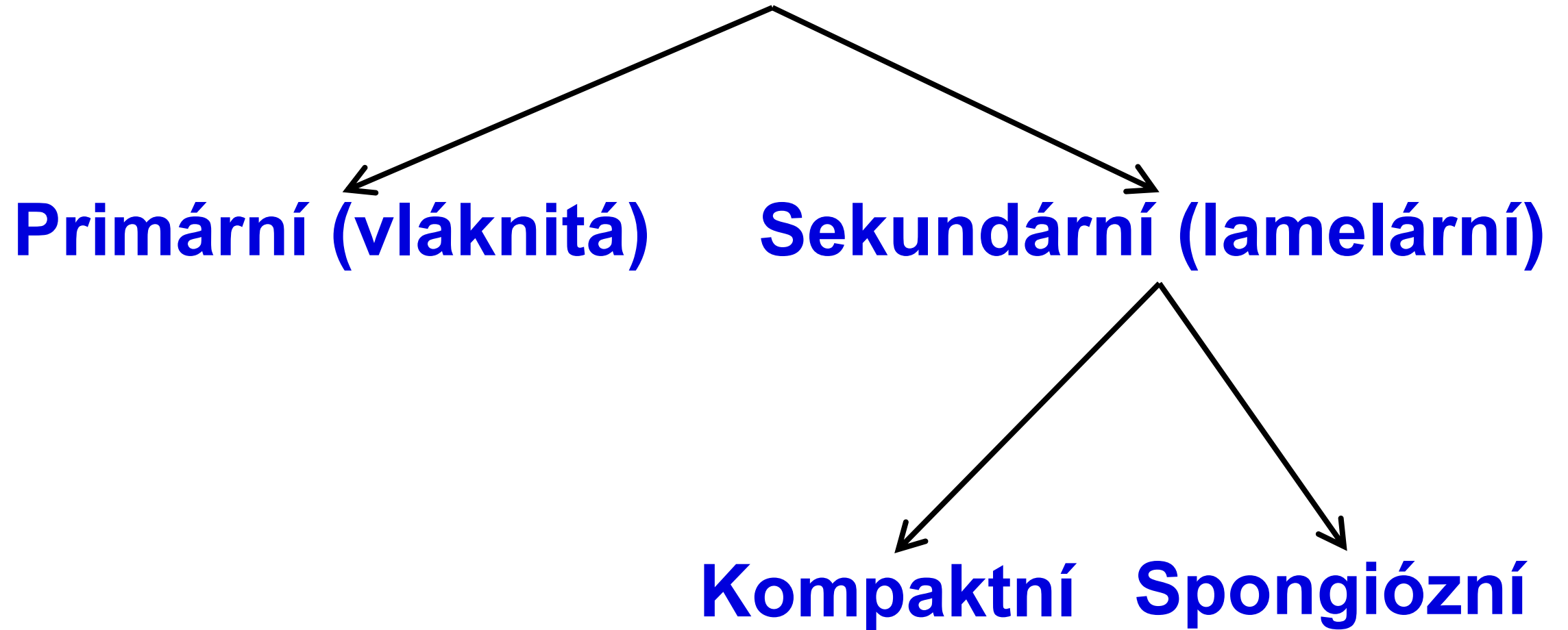


Copyright © 2010 Pearson Education, Inc.

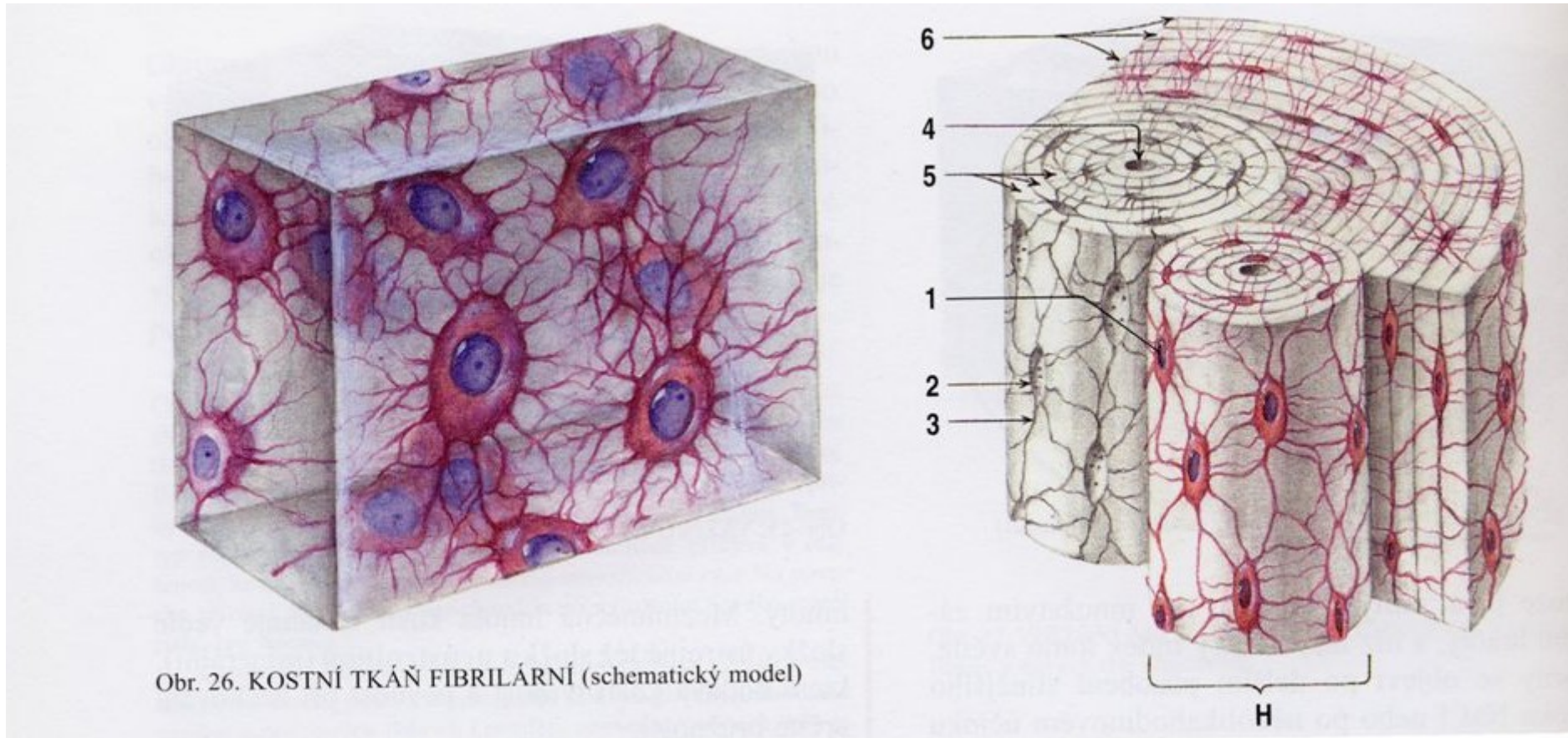


hydroxyapatitové krystaly

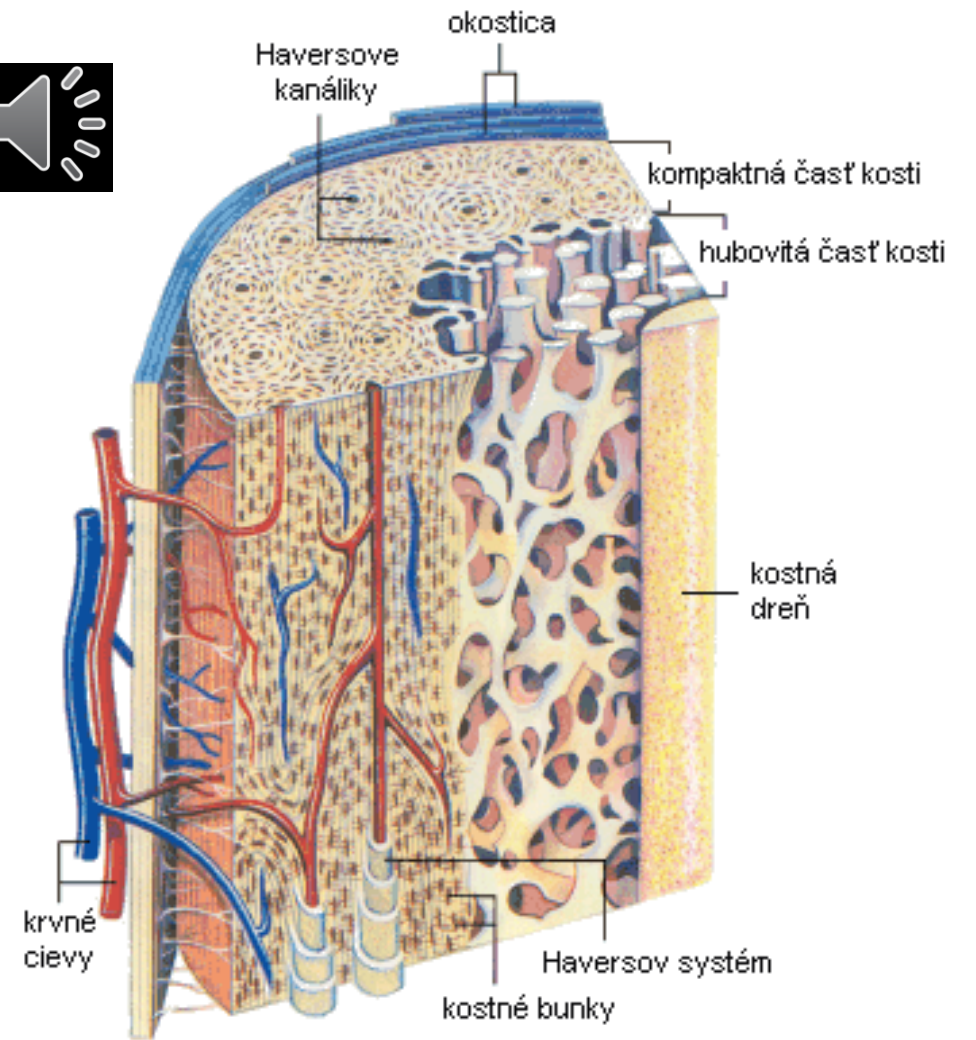

Kost



Vláknitá vs. lamelární kost



Kompakta vs. spongióza



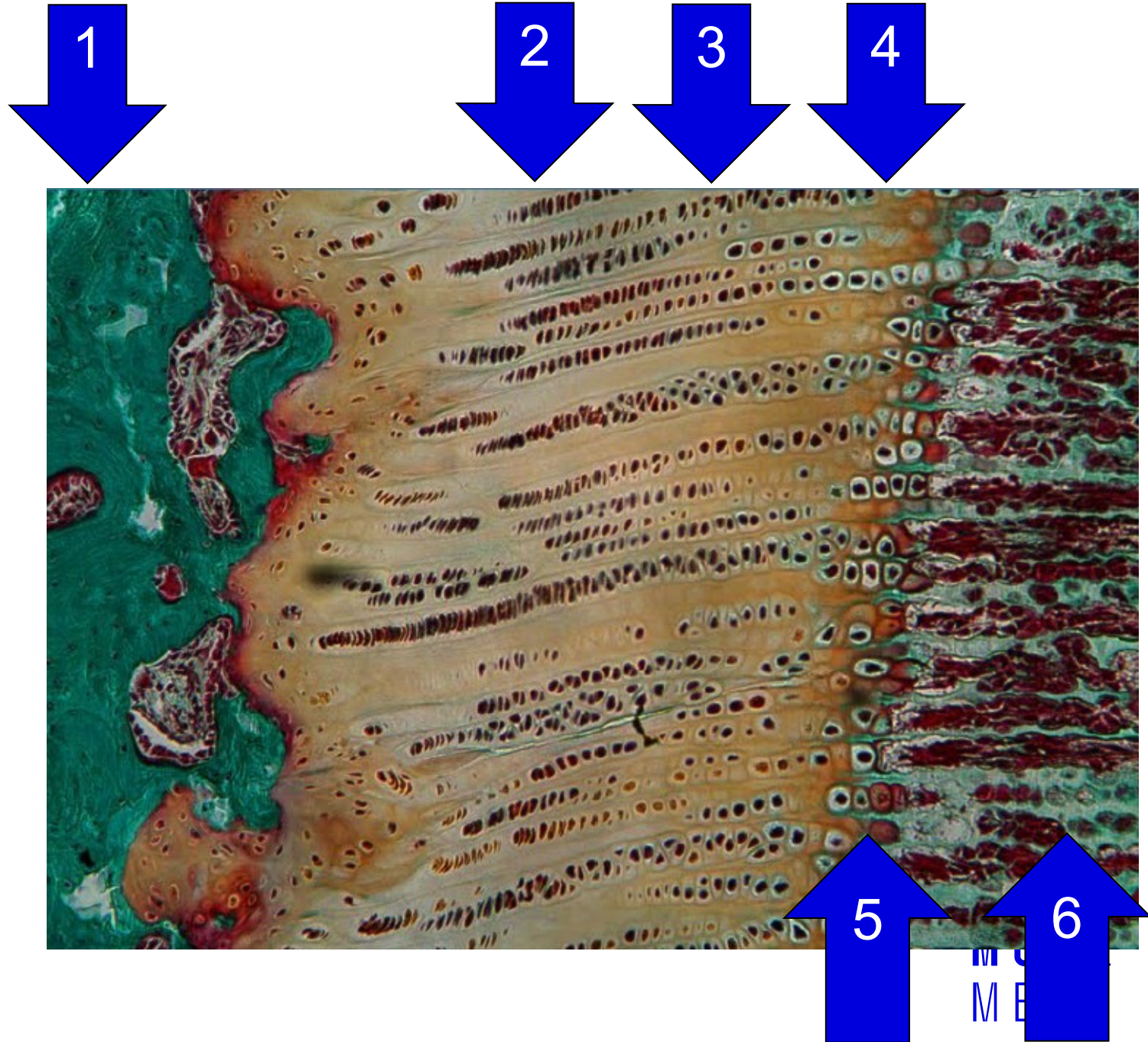
Obr. Stavba dlhej kosti

Osifikace



Zonace růstové ploténky

1. Rezervní chrupavka
2. Proliferace
3. Hypertrofie
4. Kalcifikace
5. Eroze
6. Kost





MUNI Department
of Histology
and Embryology
MED

Klára Dolinová

Yoni Solomonov

Peter Staňo

Petr Vaňhara