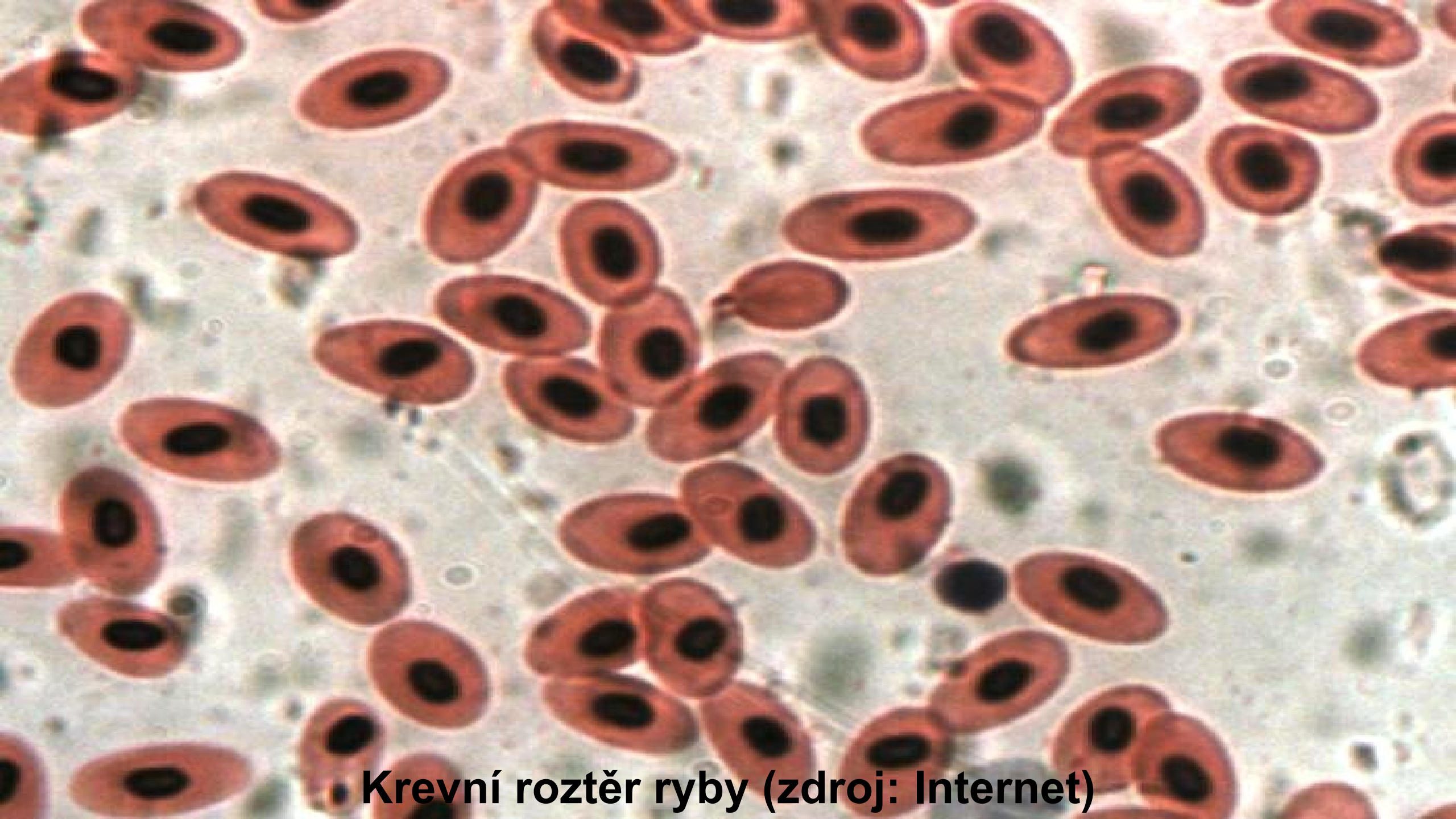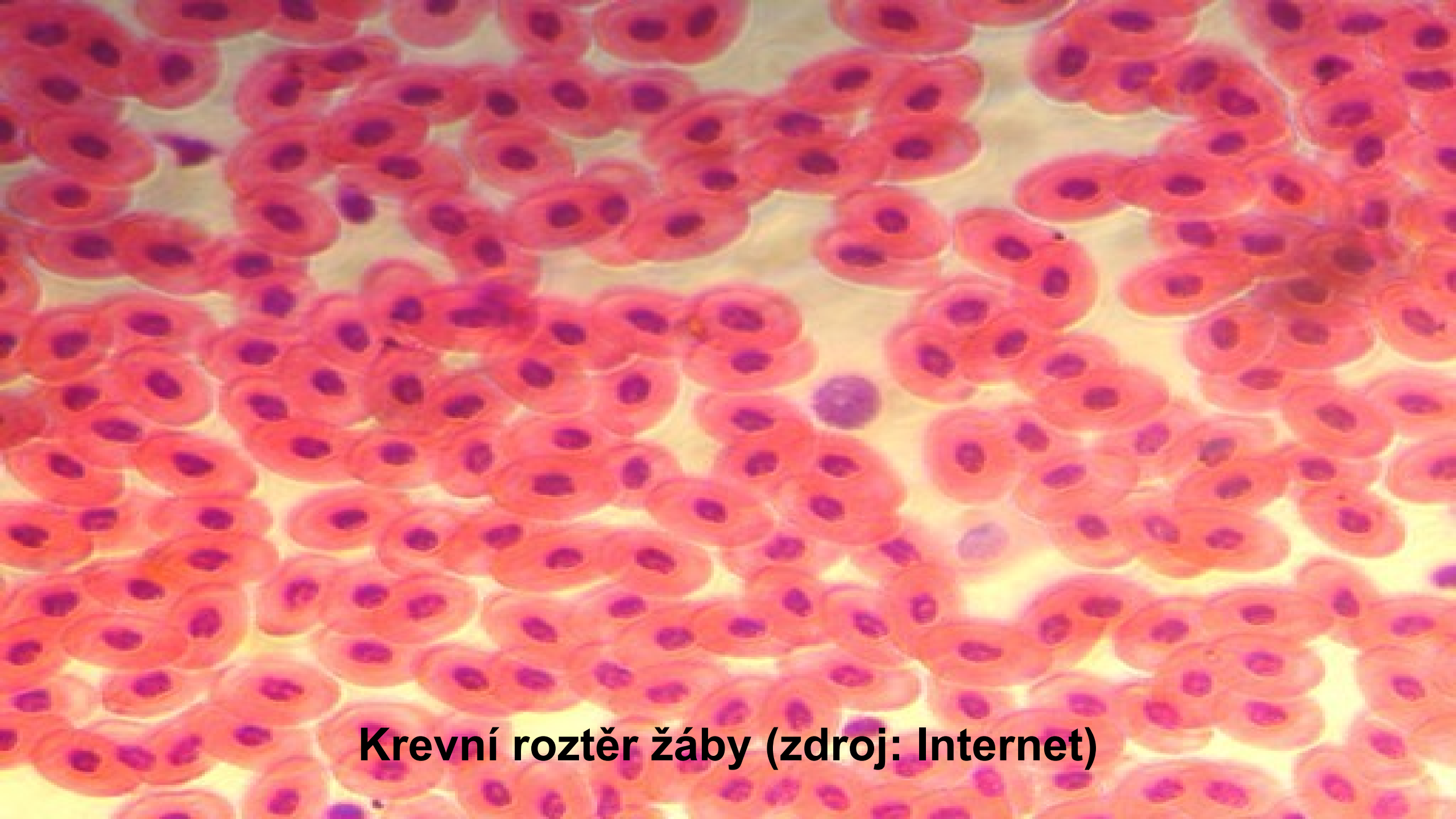


Krevní buňky

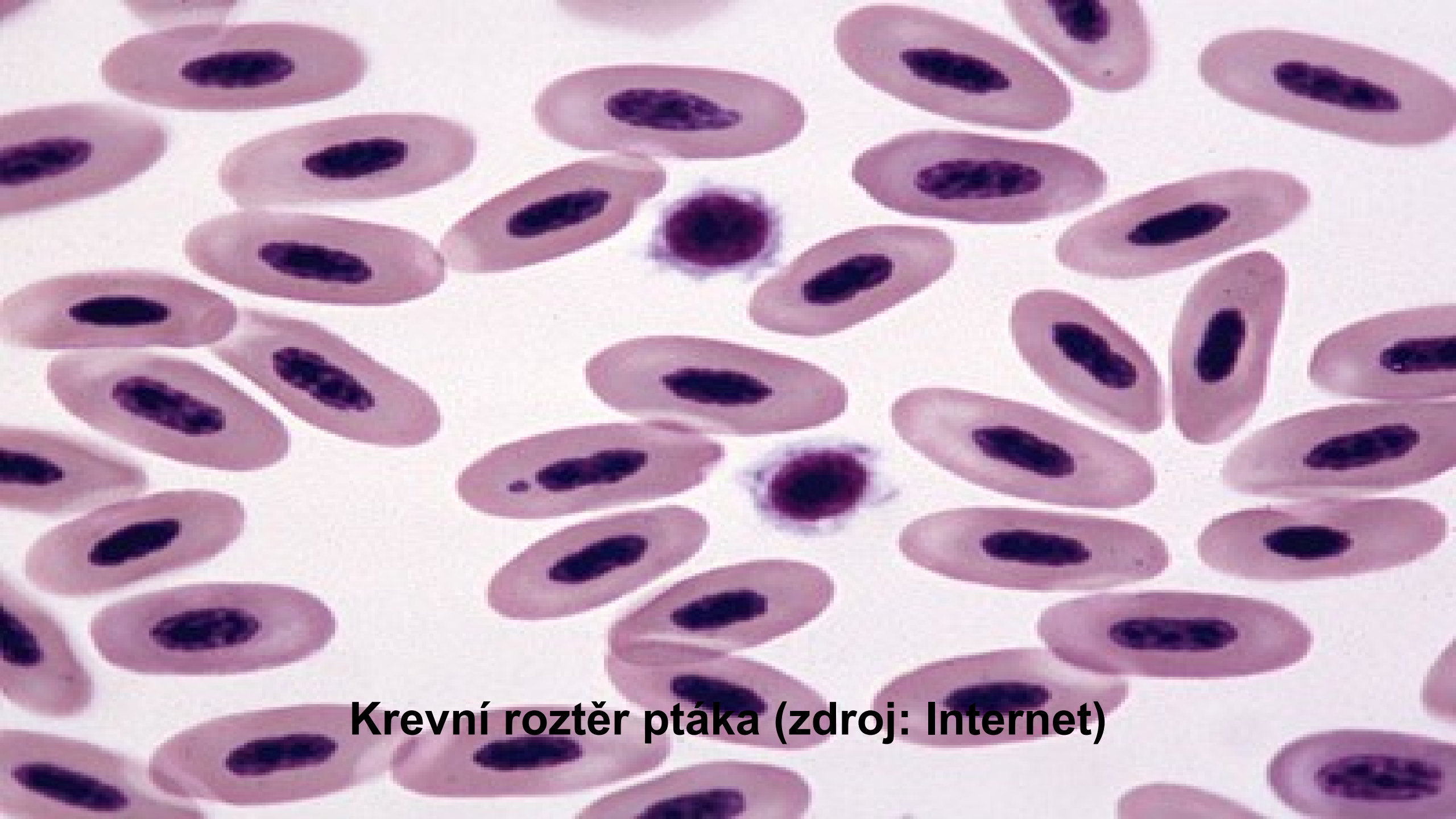
A. Žáková



Krevní roztěr ryby (zdroj: Internet)



Krevní roztěr žáby (zdroj: Internet)



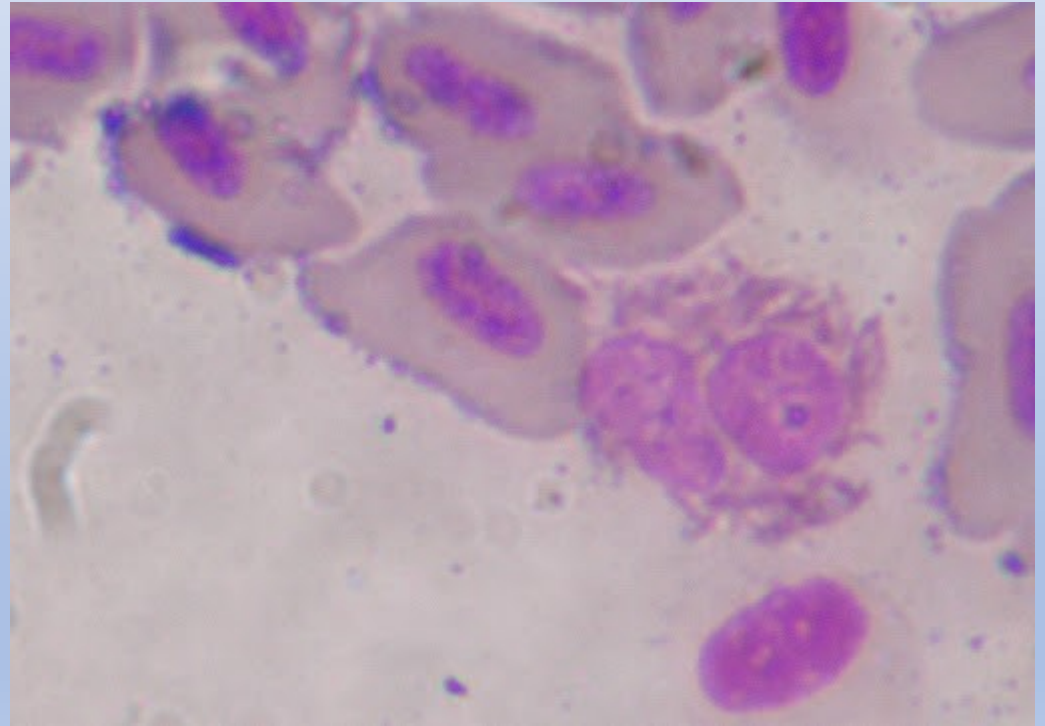
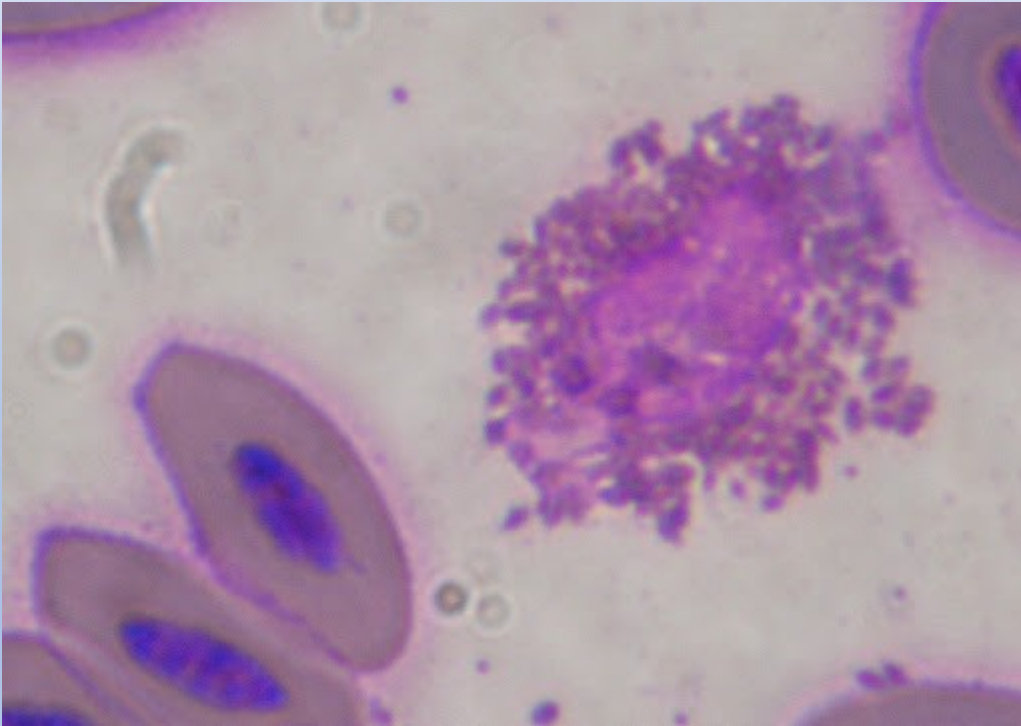
Krevní roztěr ptáka (zdroj: Internet)



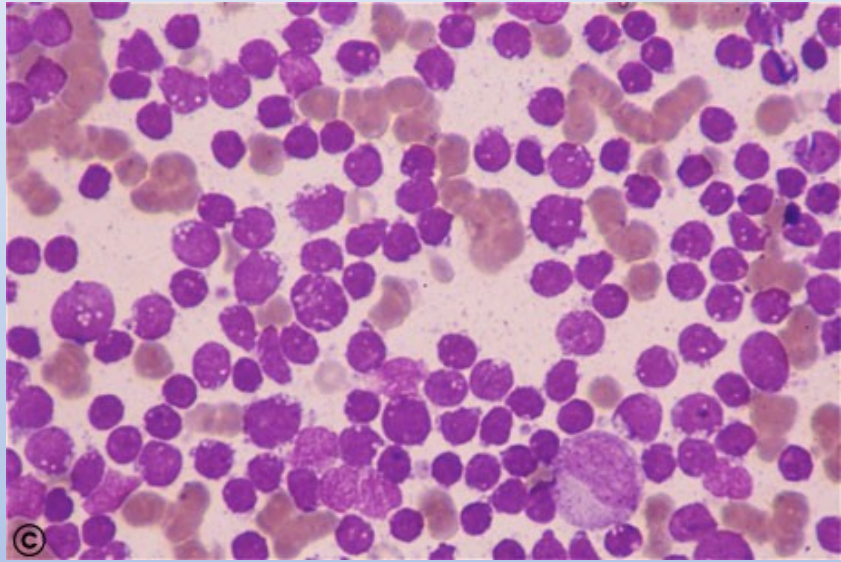
**Krevní roztěr savce – lidská krev
(zdroj:
Internet)**

**(zdroj:
Internet)**

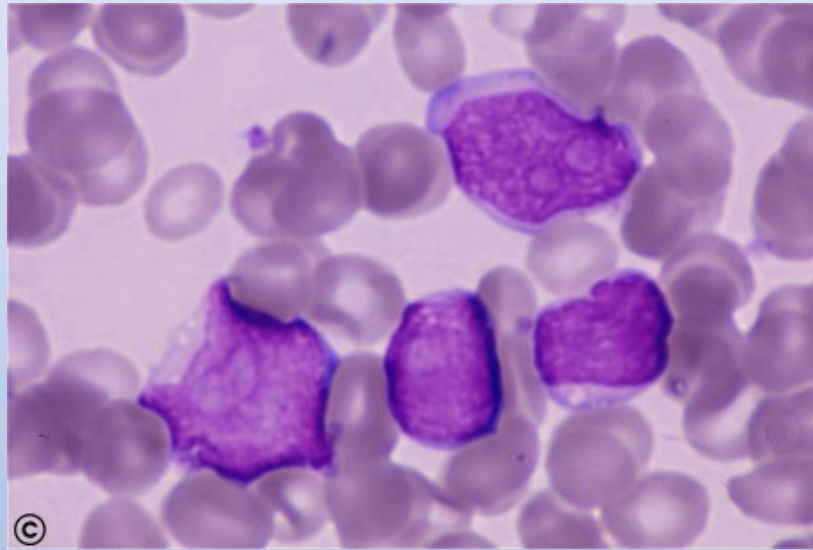
Heterofil u ptáků



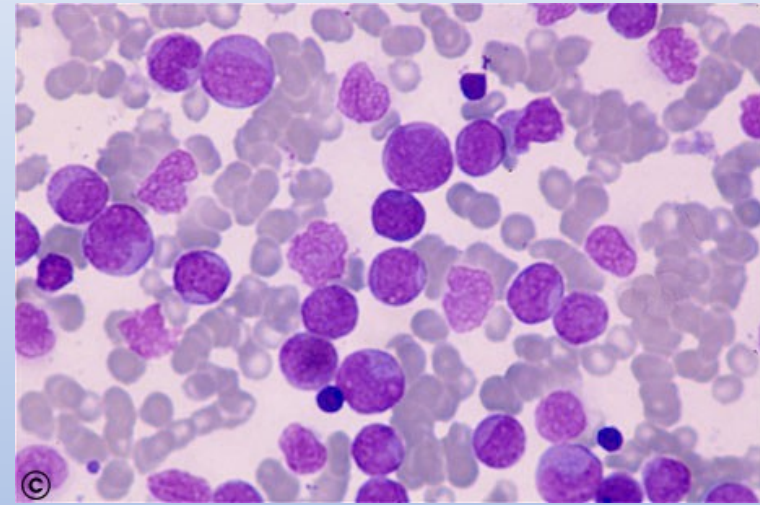
Leukemické buňky



Akutní lymfatická leukemie ALL-L3

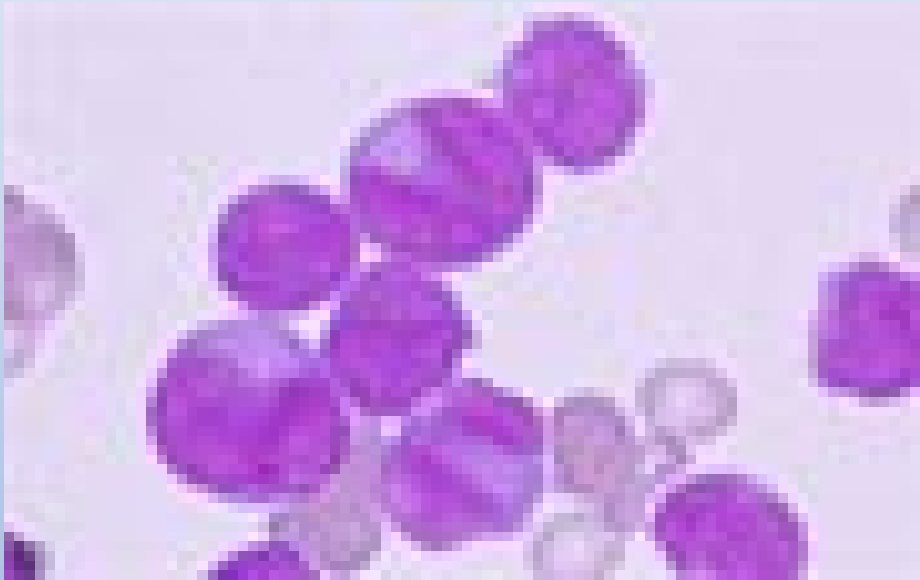

Akutní lymfatická leukemie ALL-L2

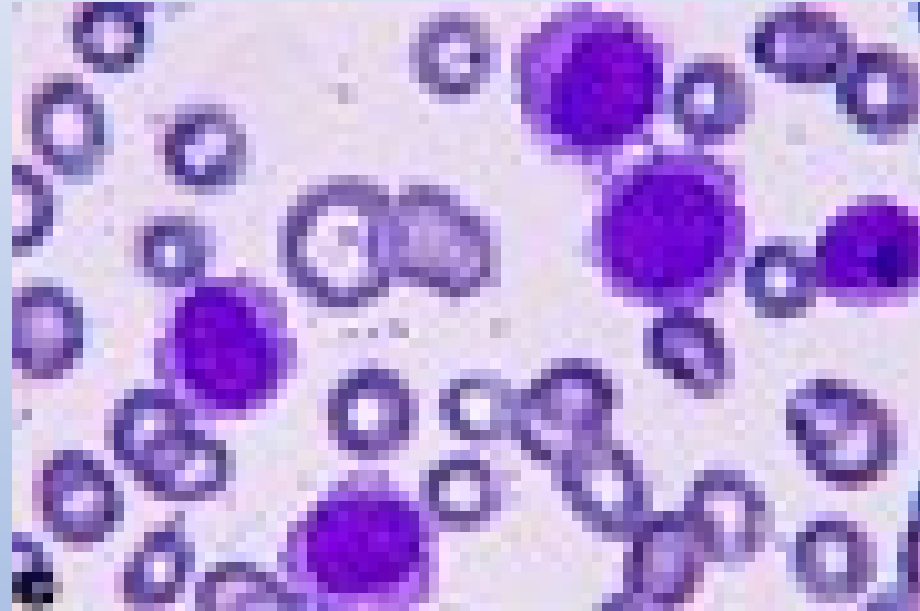


Akutní myeloidní leukemie AML-M2

Leukemické buňky

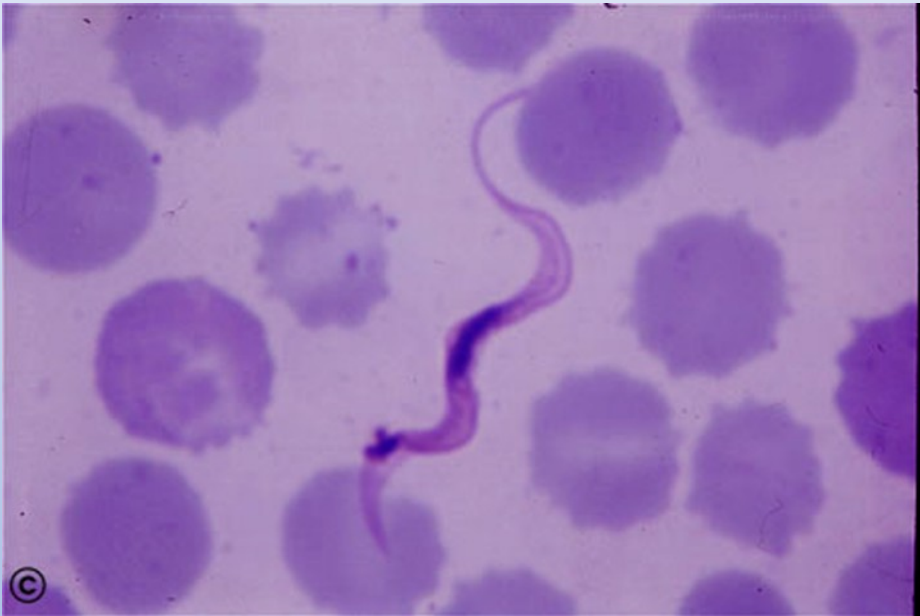

Akutní myeloidní leukemie AML M3

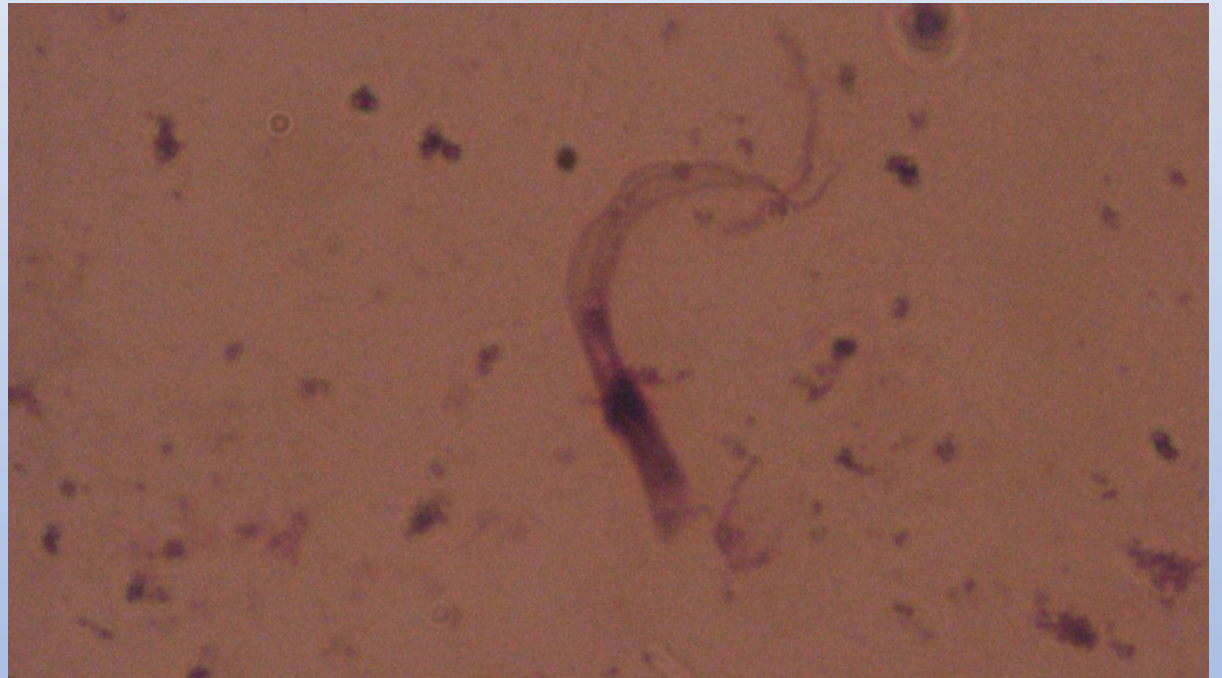

Vlasaté buňky - leukemie

Paraziti v krvi

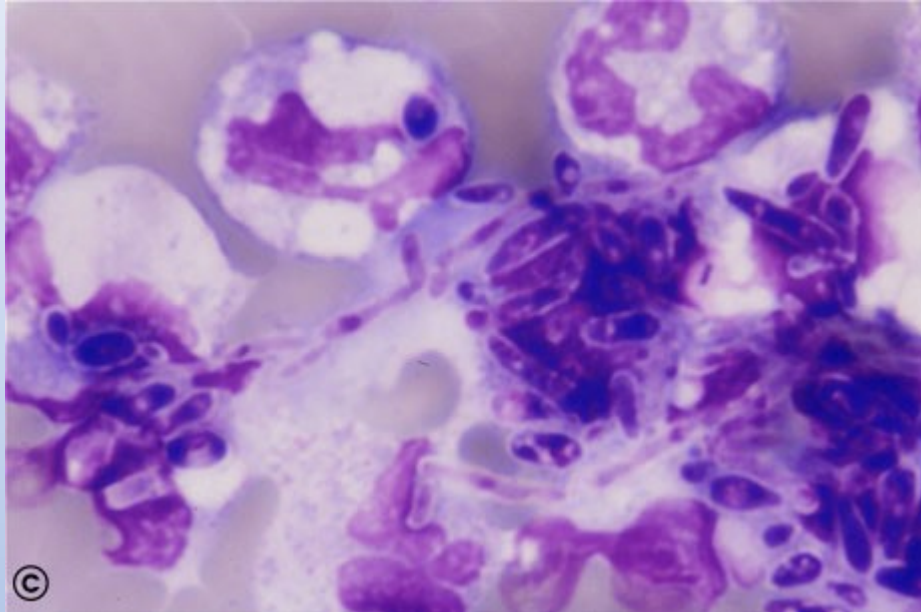


Trypanosoma gambiense

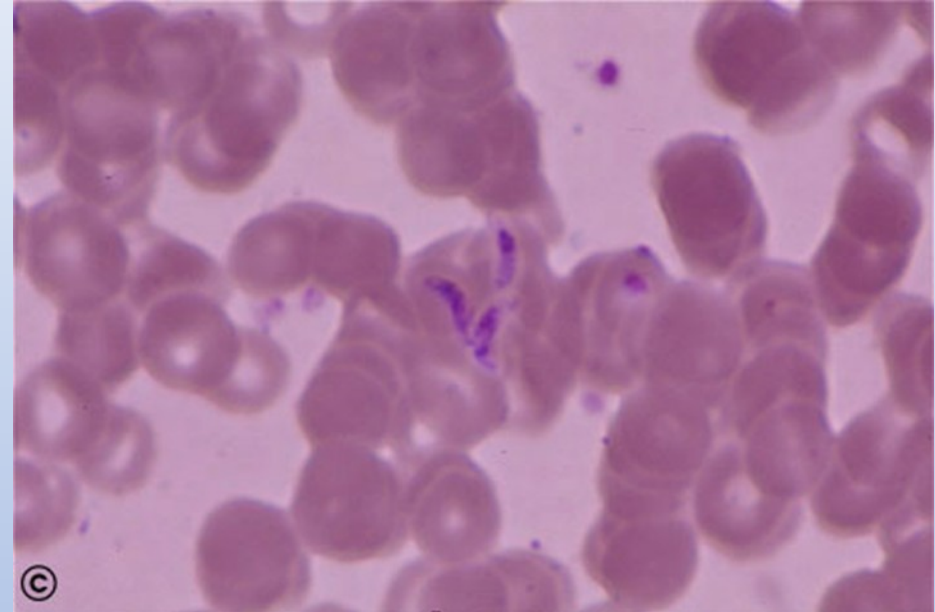


Trypanosoma sp. (z ptačího druhu) v klíštěti

Paraziti v krvi



Kvasinky (*Candida* sp.)



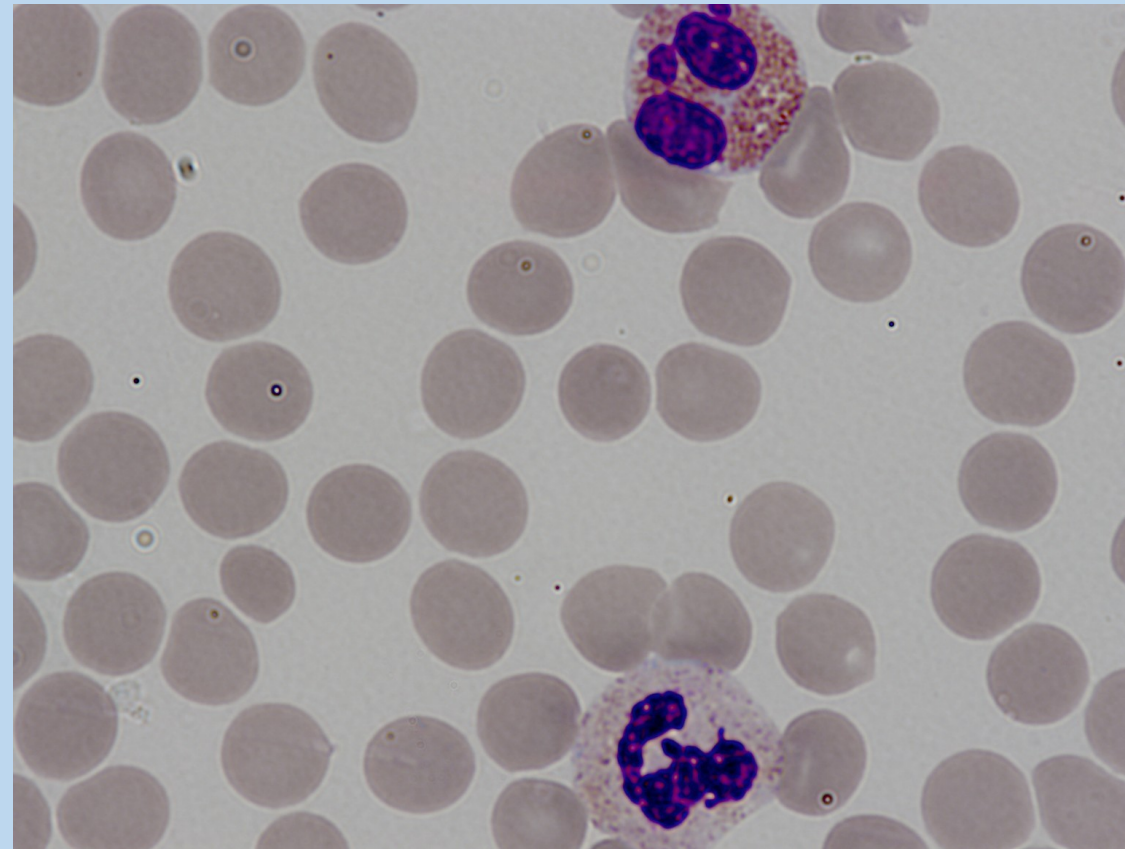
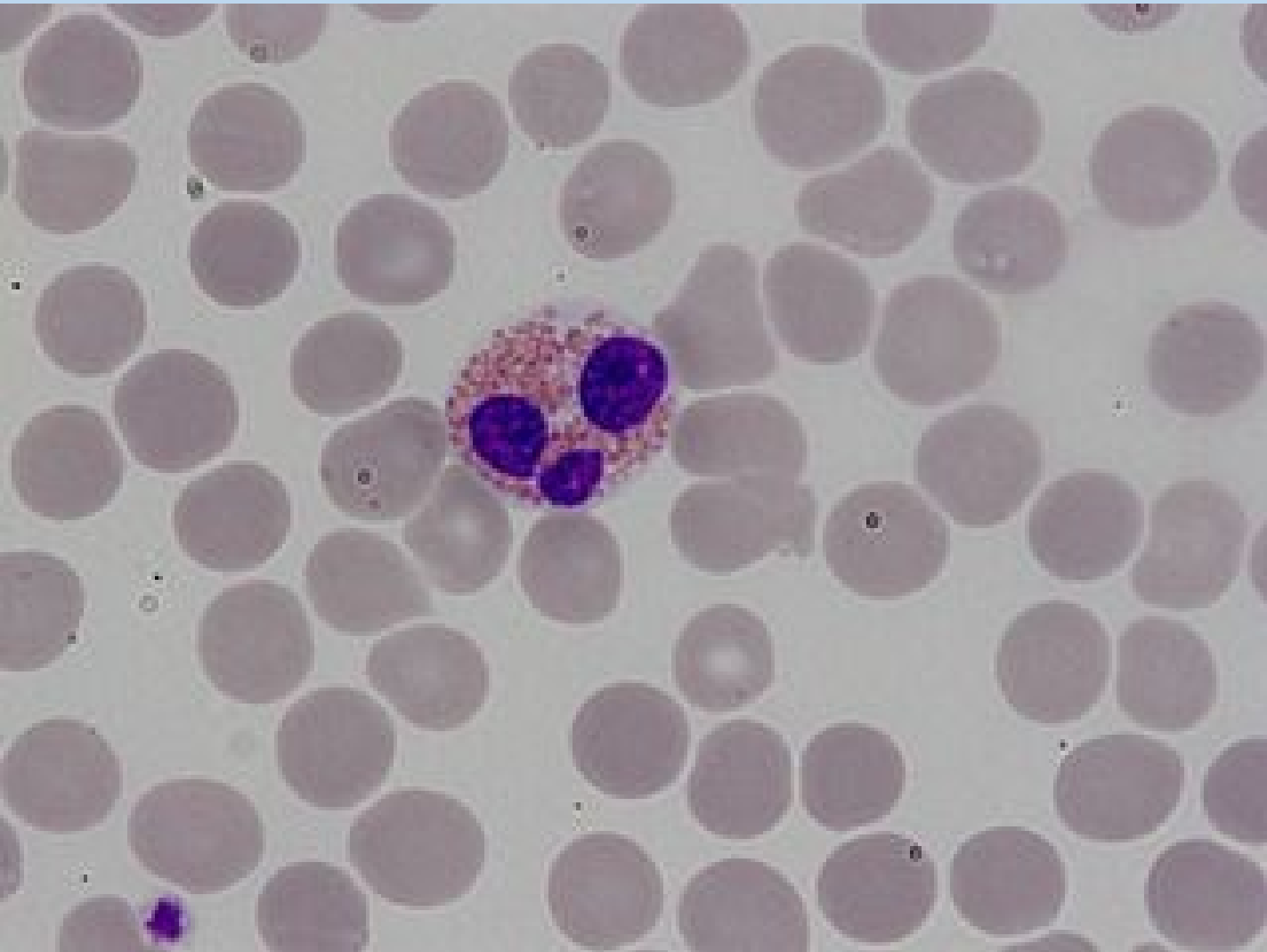
Toxoplasma gondii

Zdroje

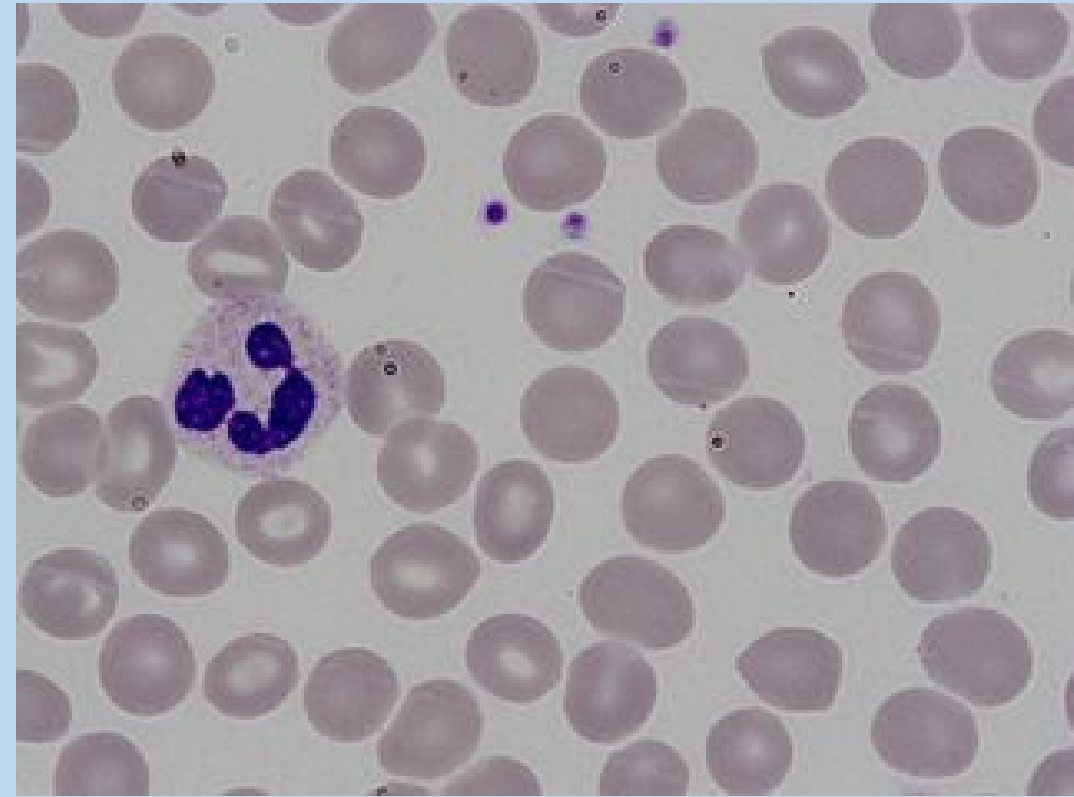
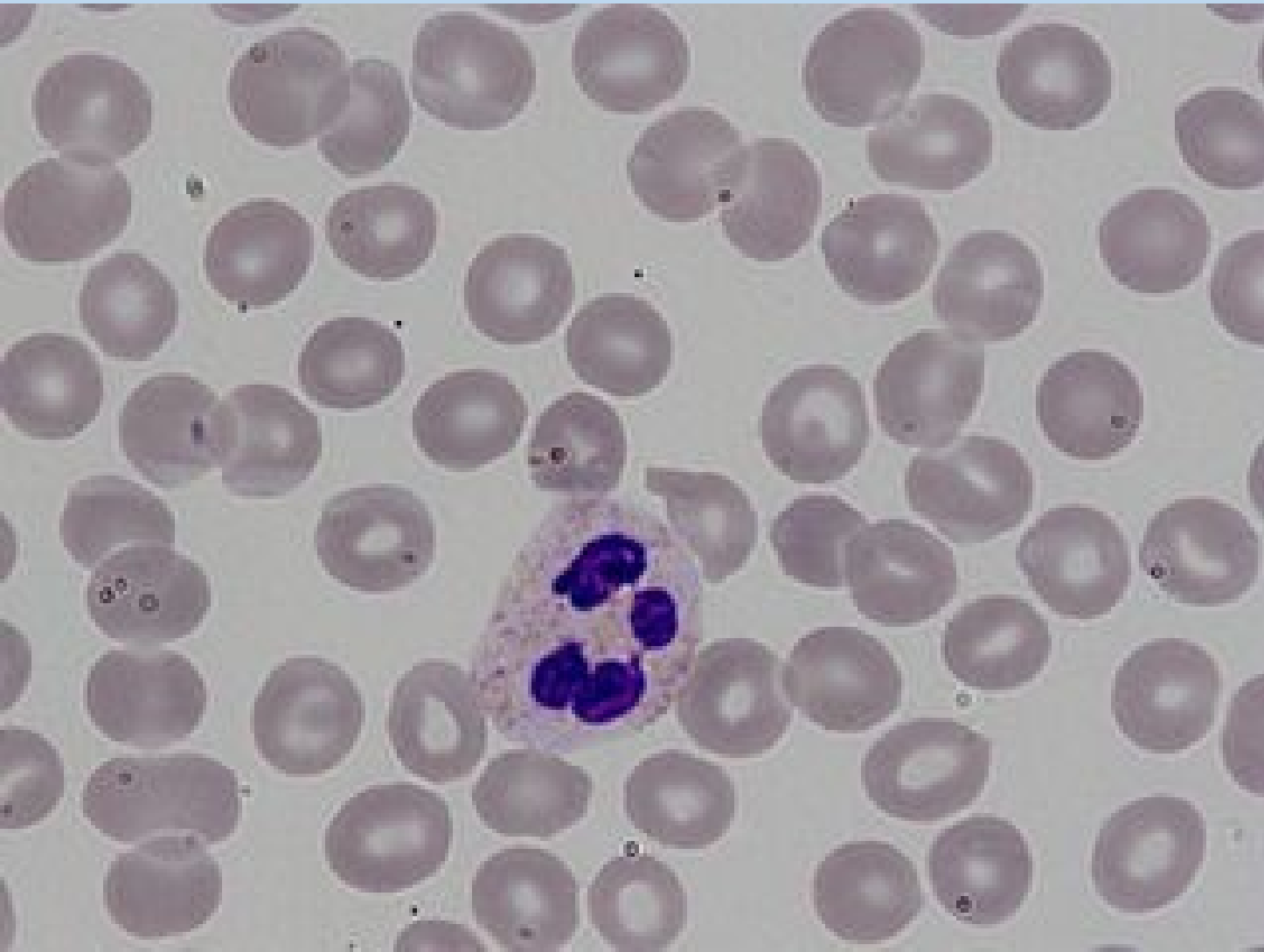
<http://www.hematologyatlas.com/>

lidské vzork+ patologie

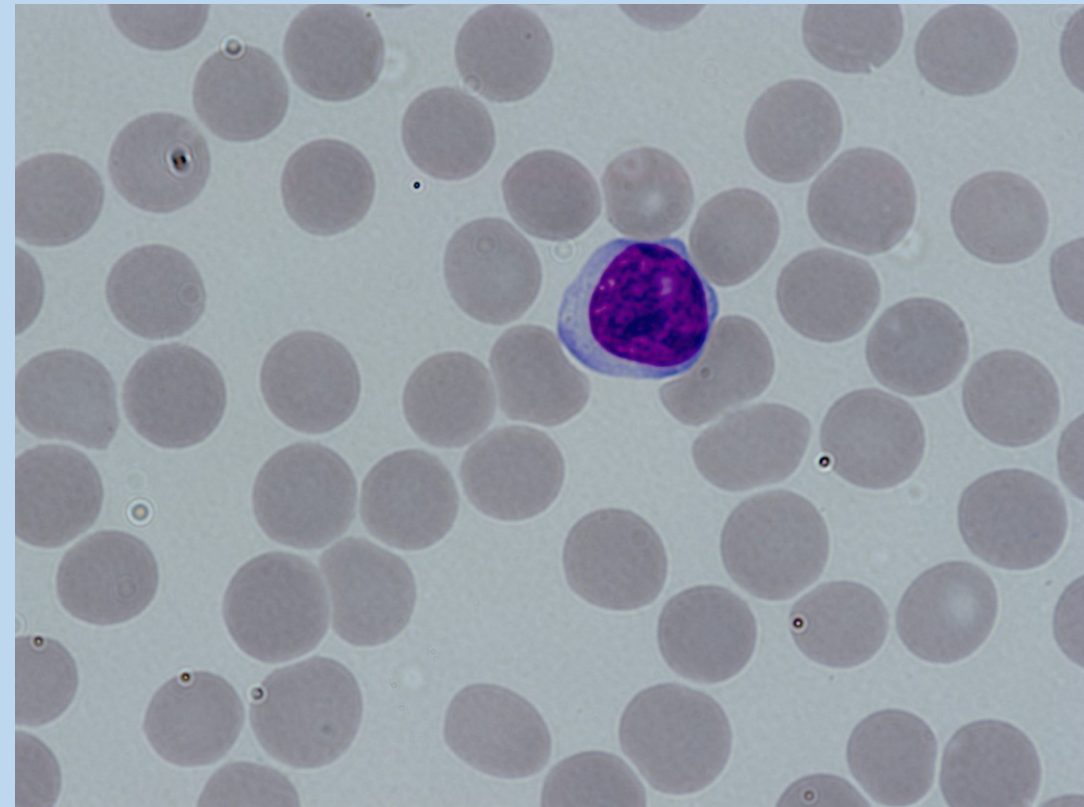
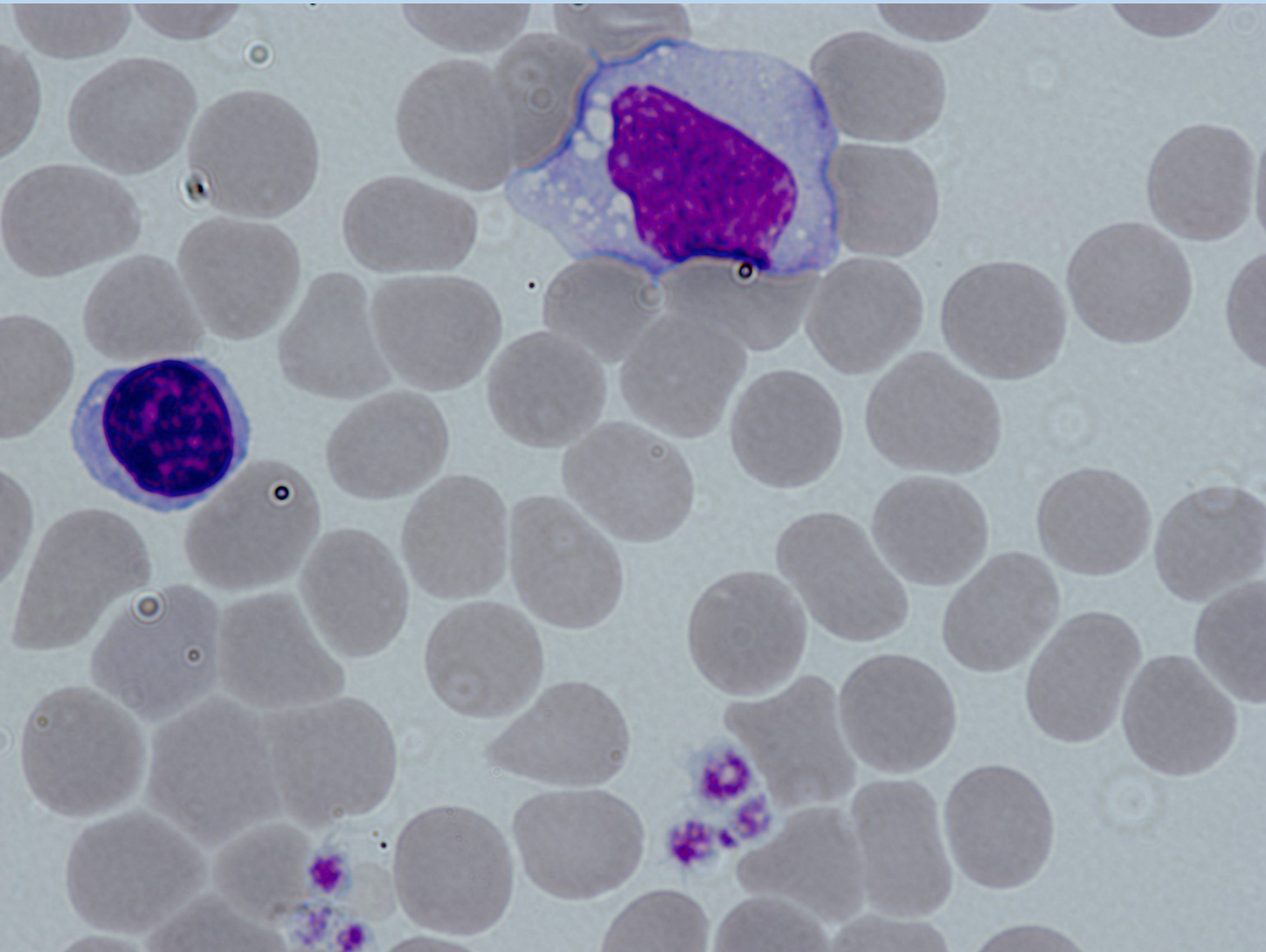
eozinofil



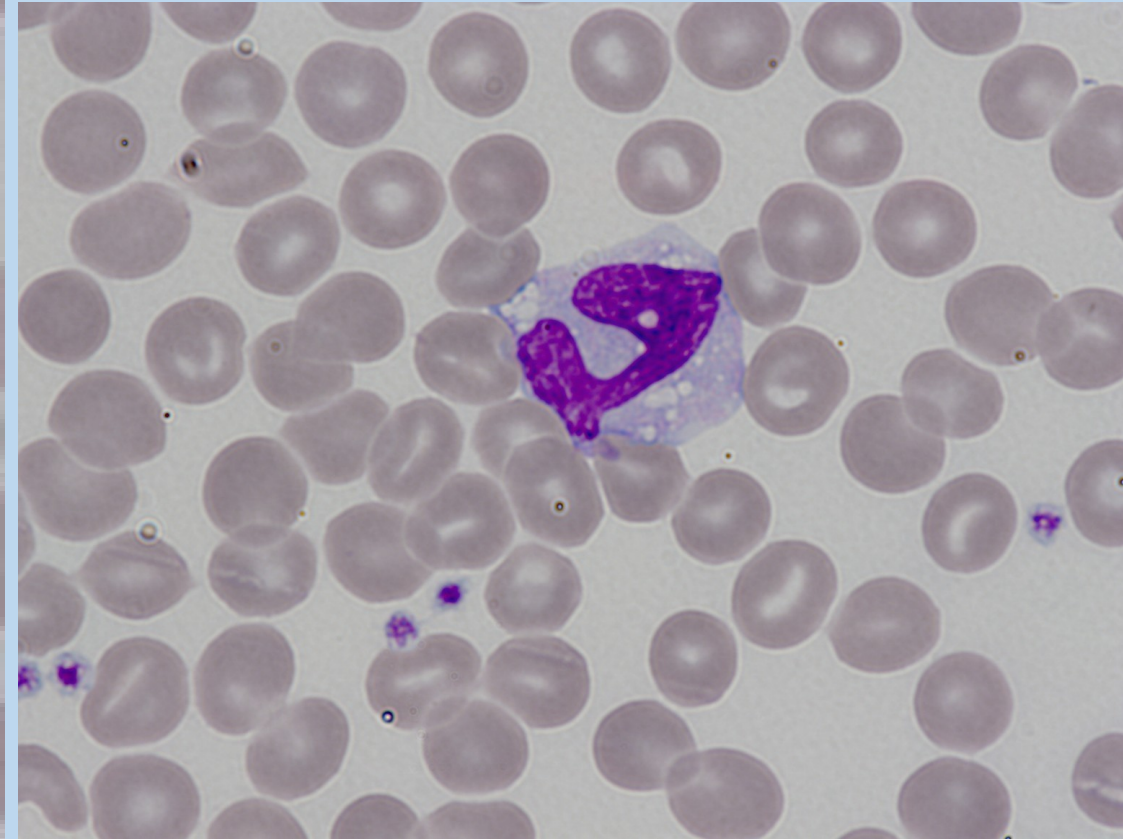
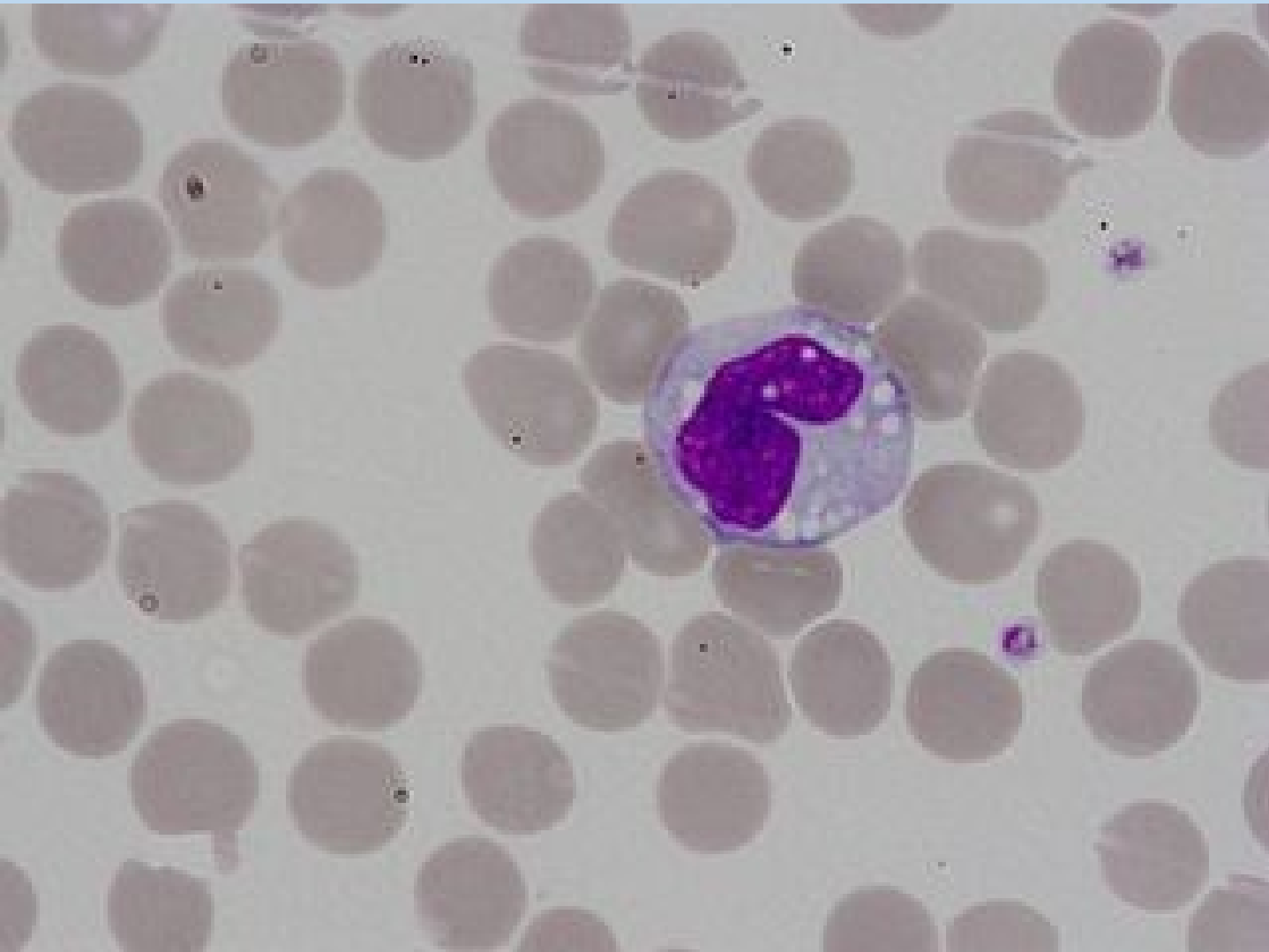
neutrofil



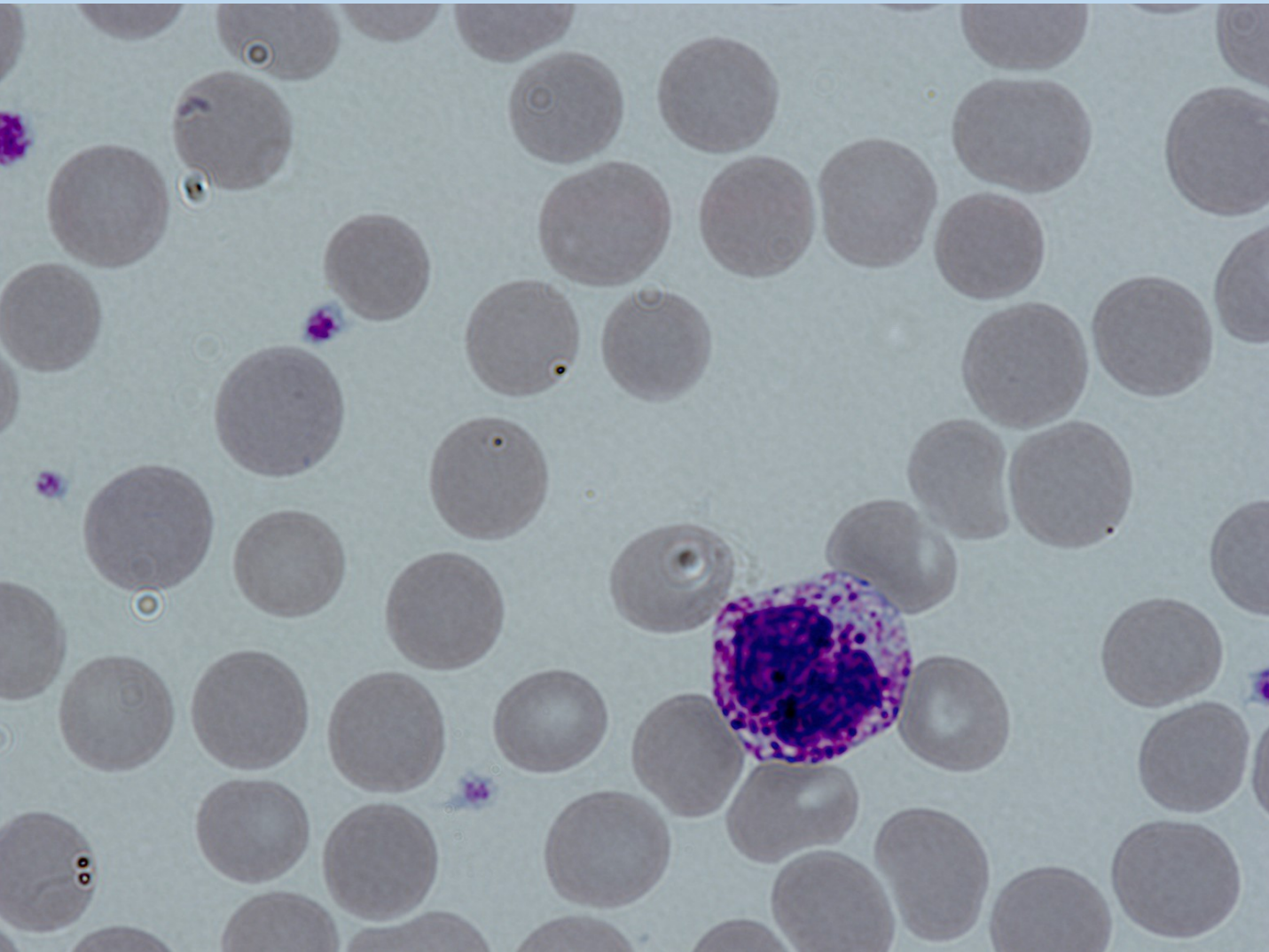
Lymfocyt a monocyt



monocyt



bazofil



Tyčka (nezralý neutrofil)

