

Extraembryonic organs

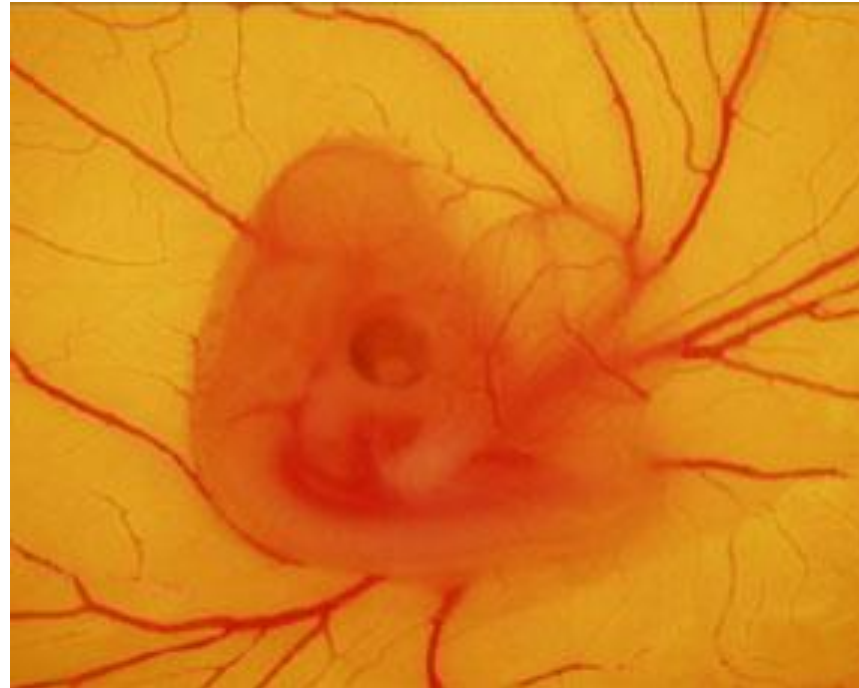MARCELA BUCHTOVA

30. 3. 2023

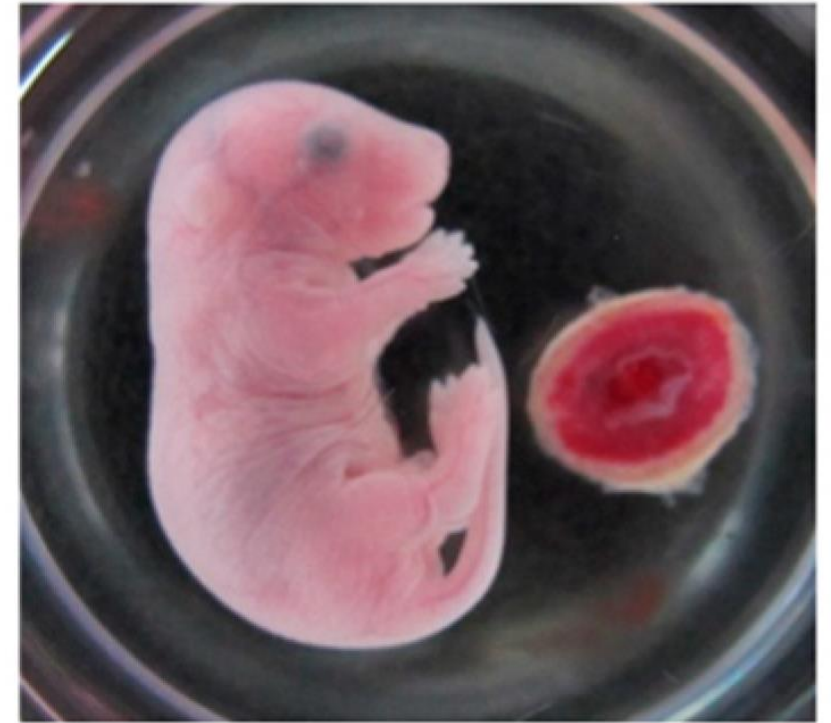

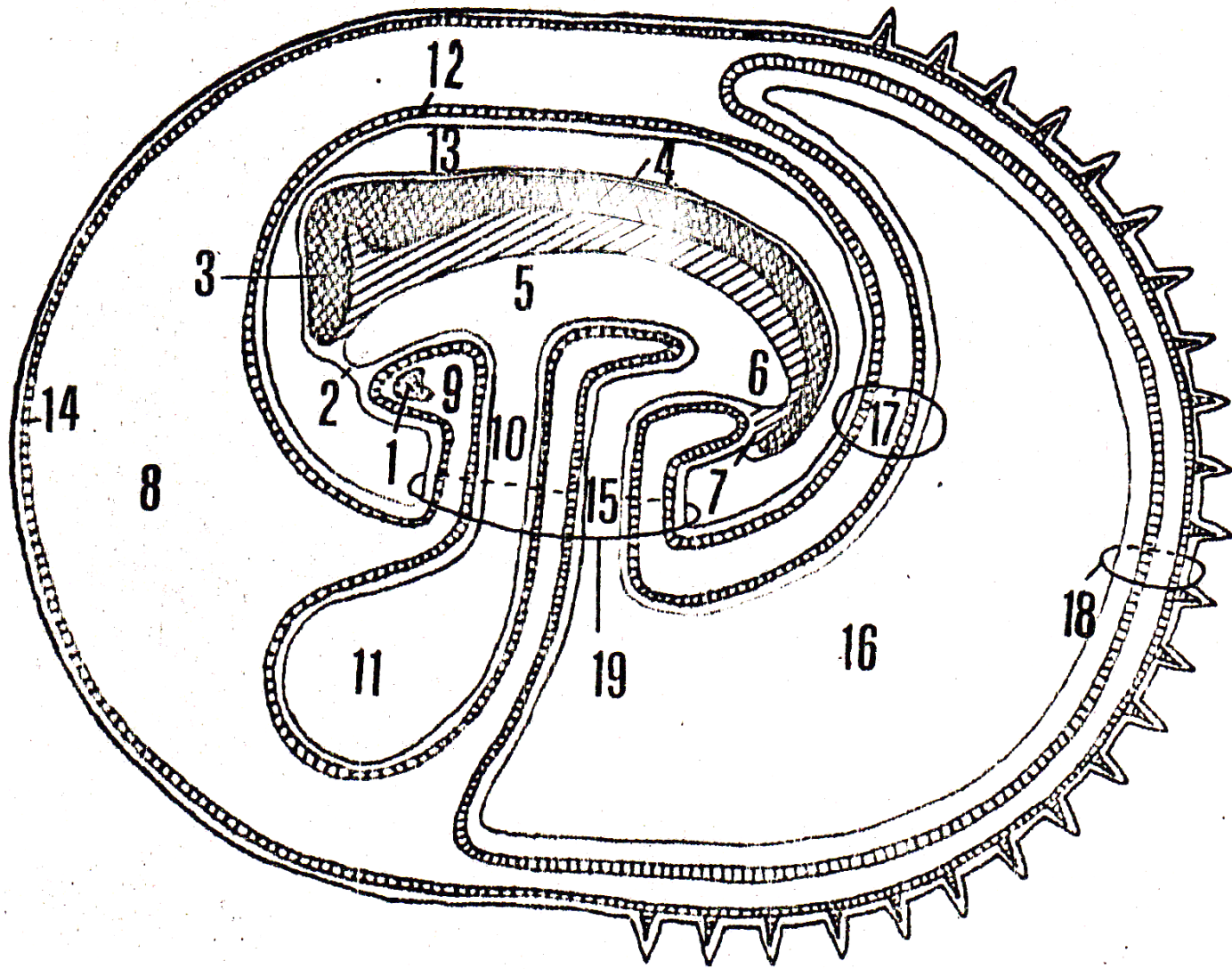
Extraembryonic organs

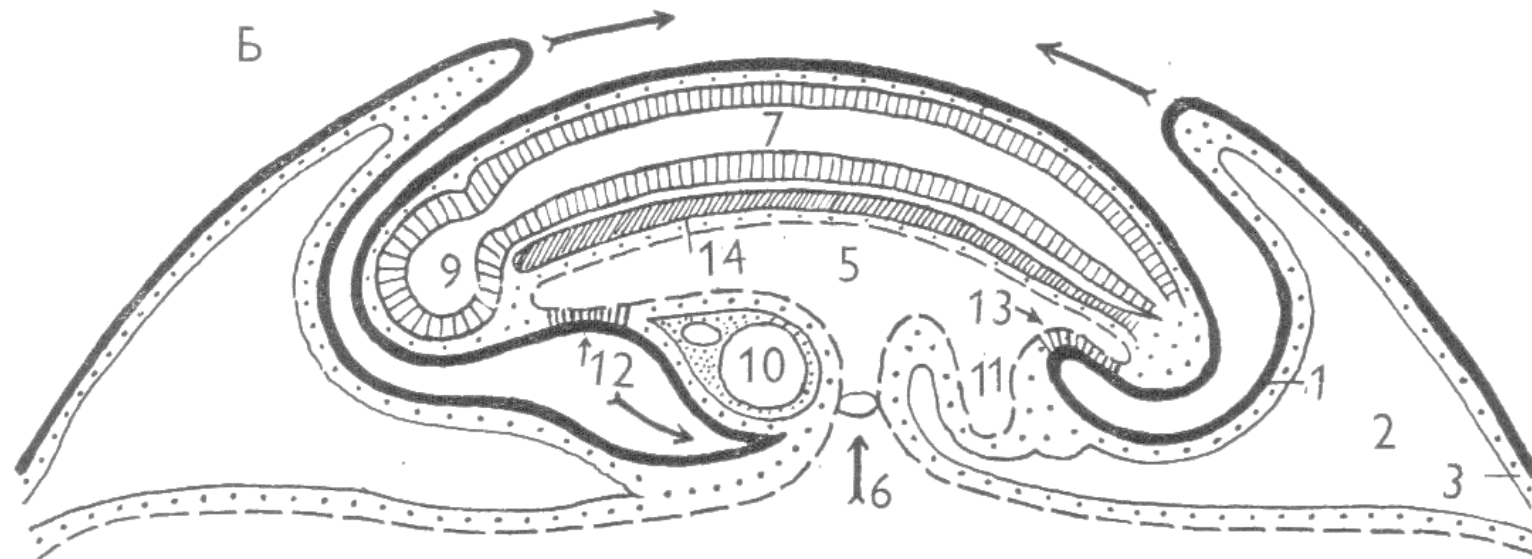
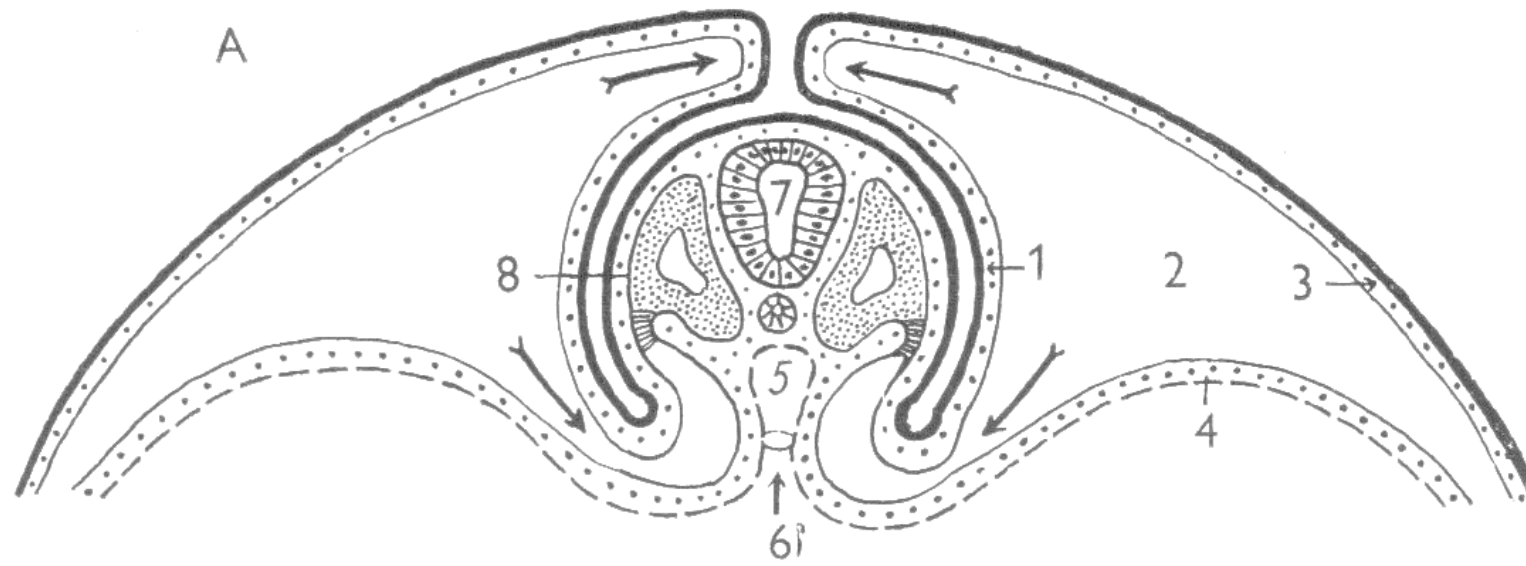
Yolk sack



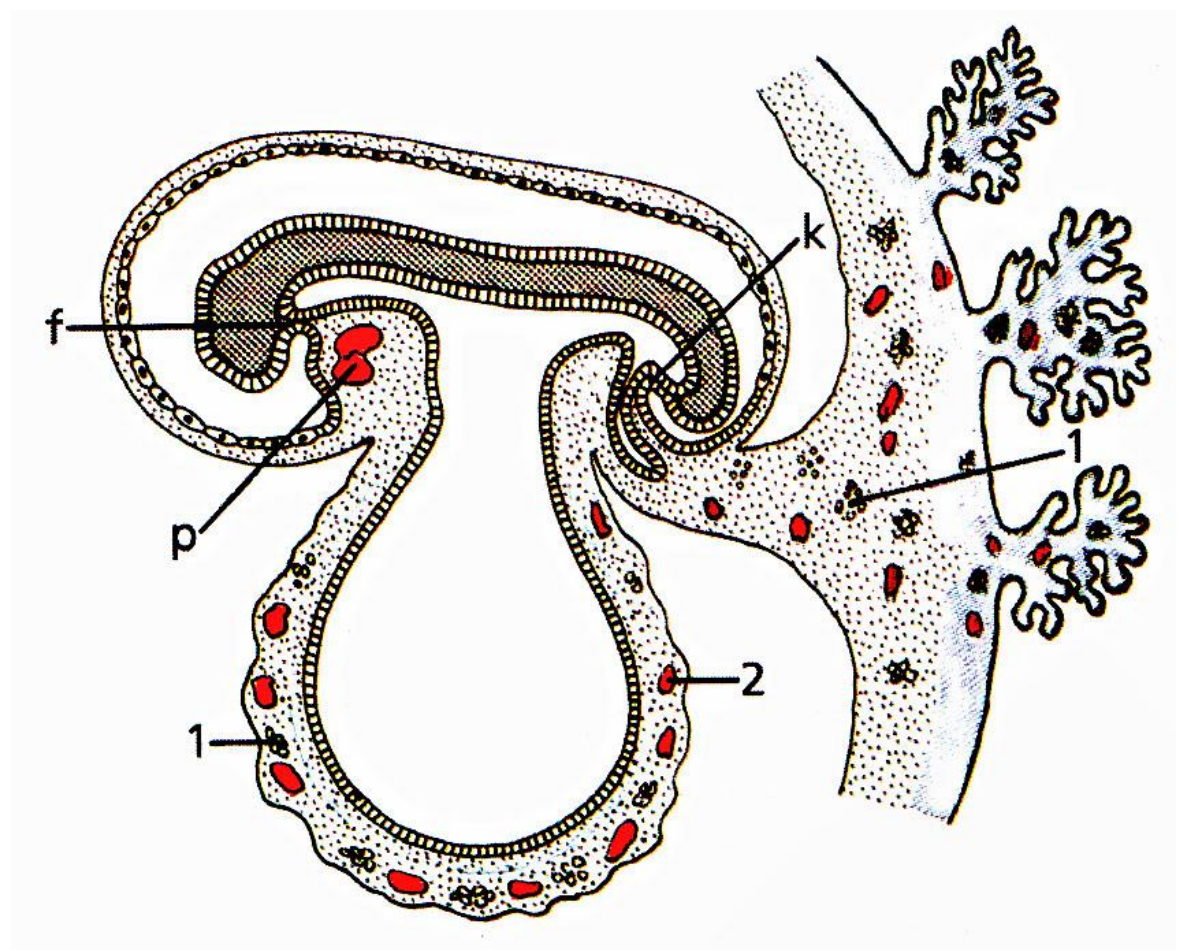
Placenta



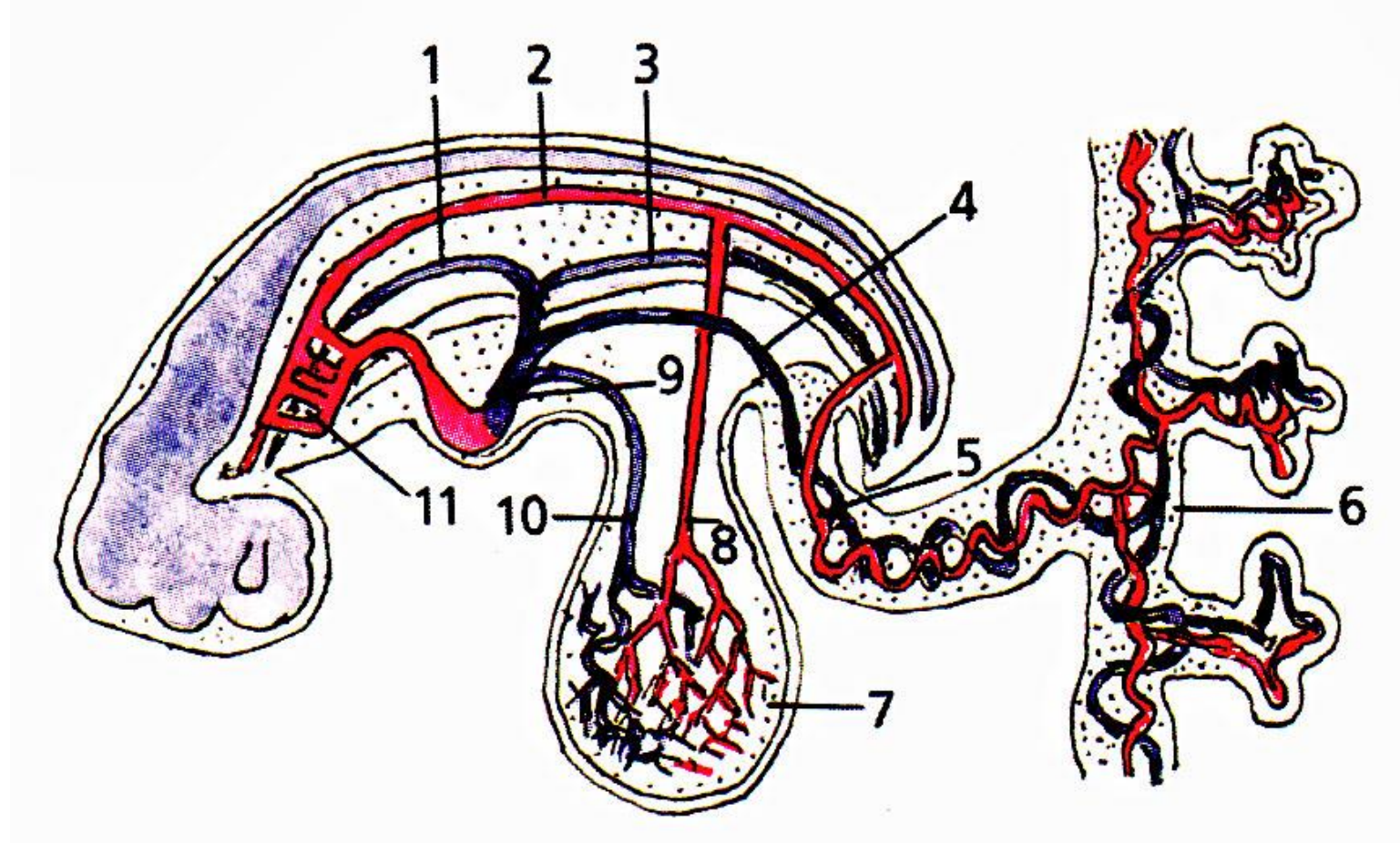




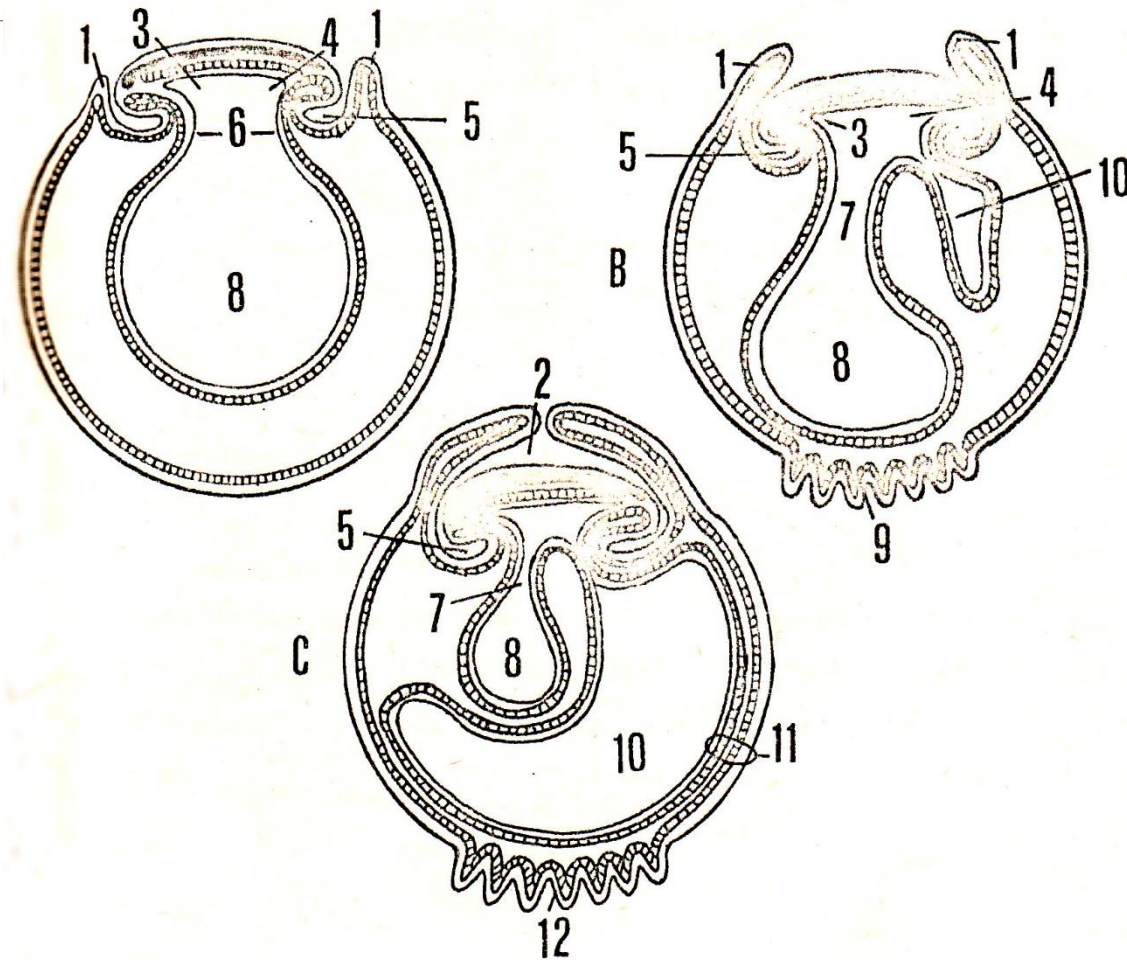
Yolk sack



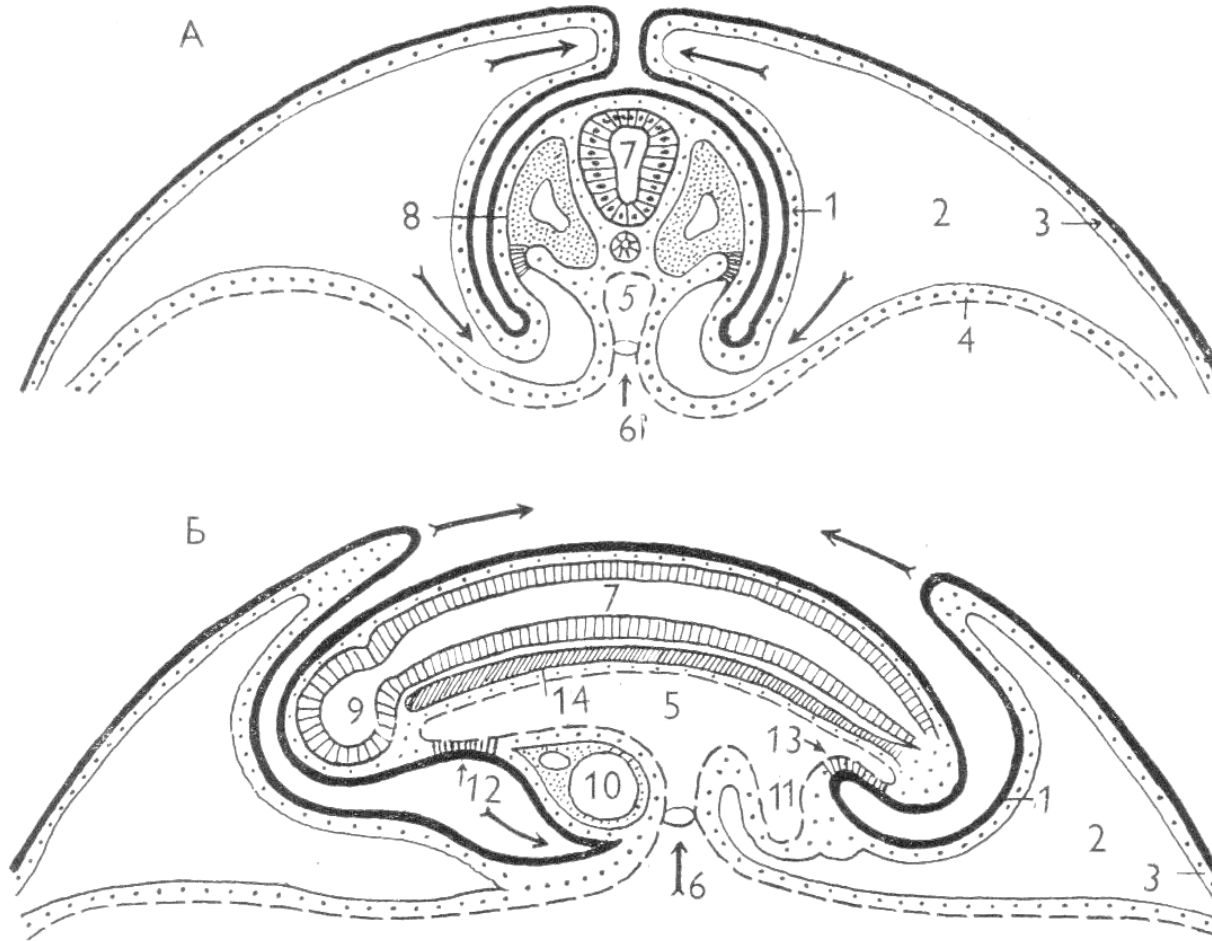
Yolk sack



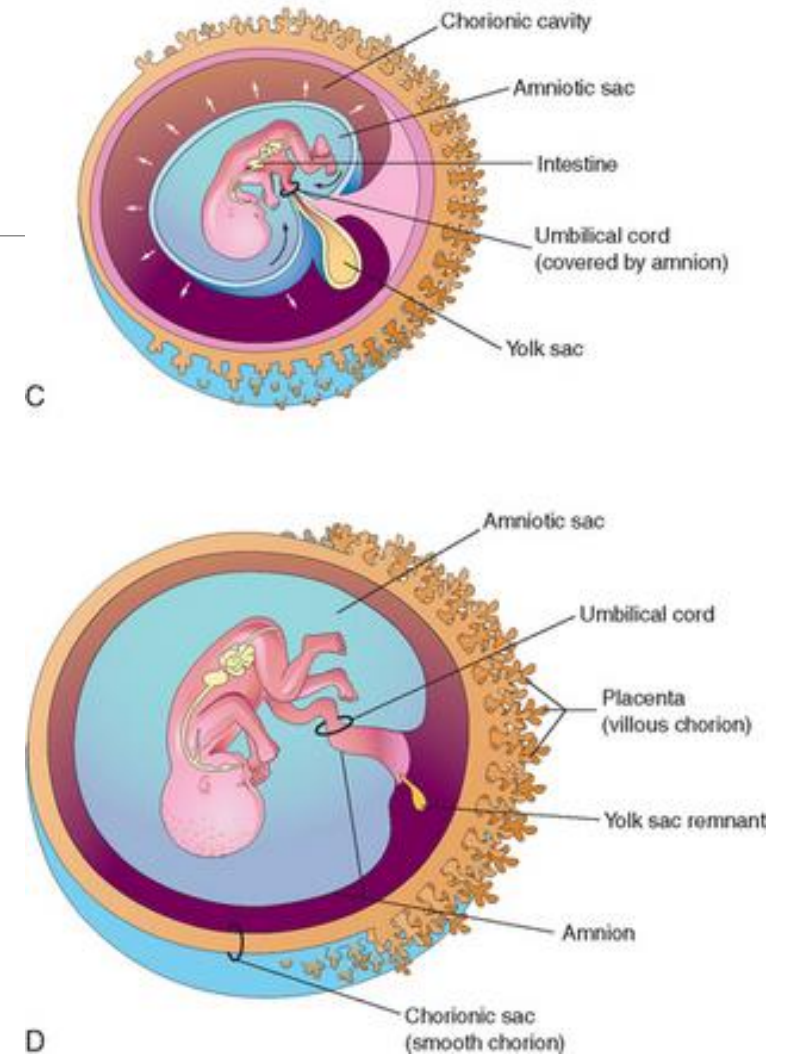
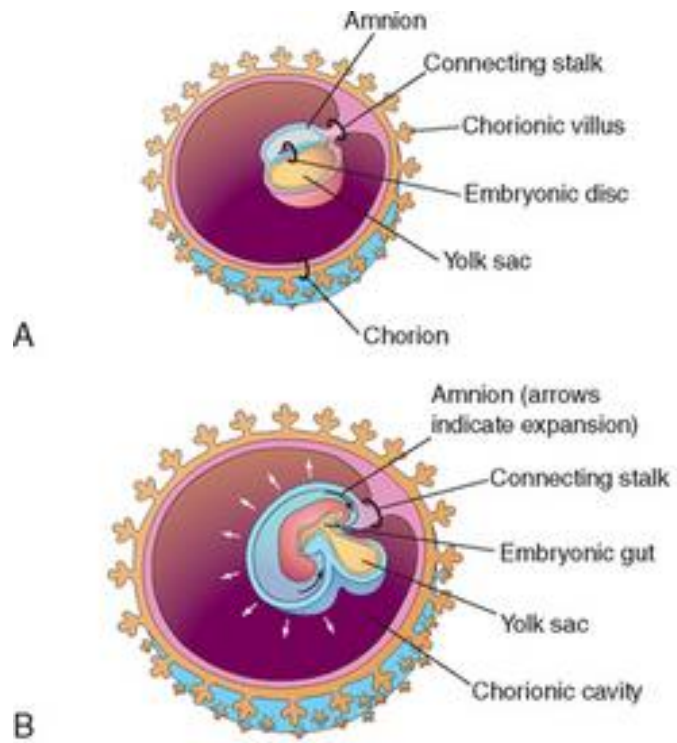
Yolk placenta



Amnion

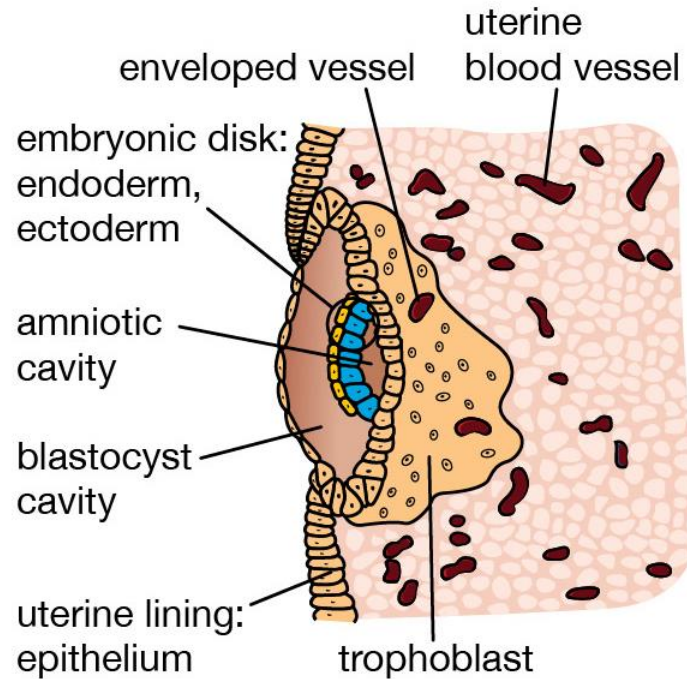


Amnion

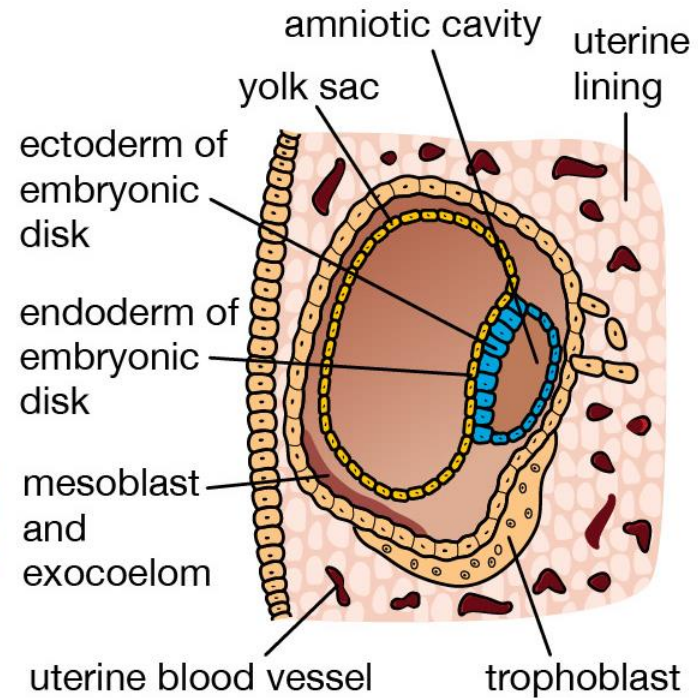


Chorion

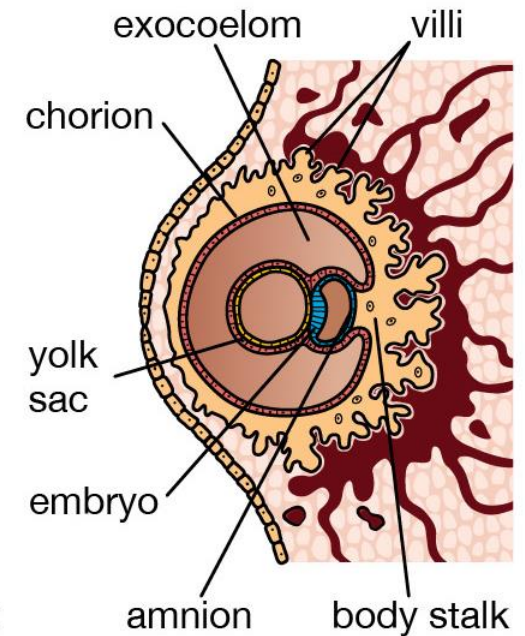
7½ days



13 days



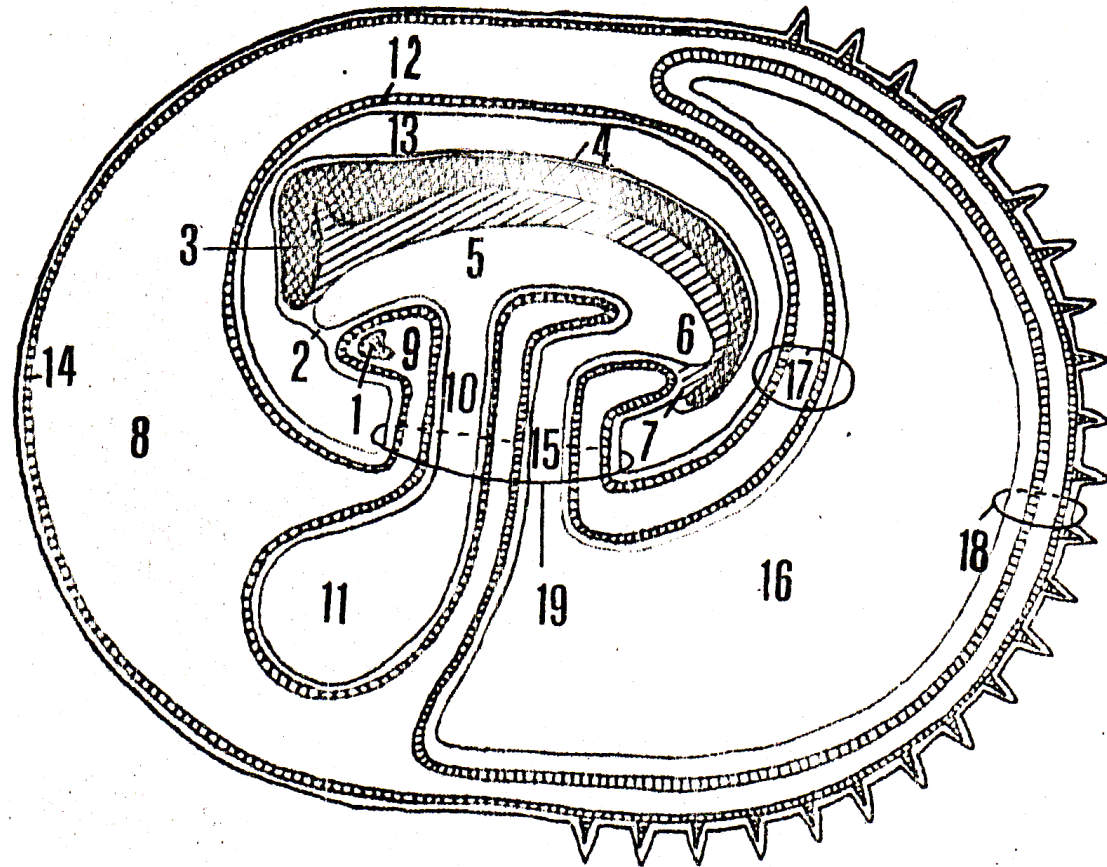
23 days



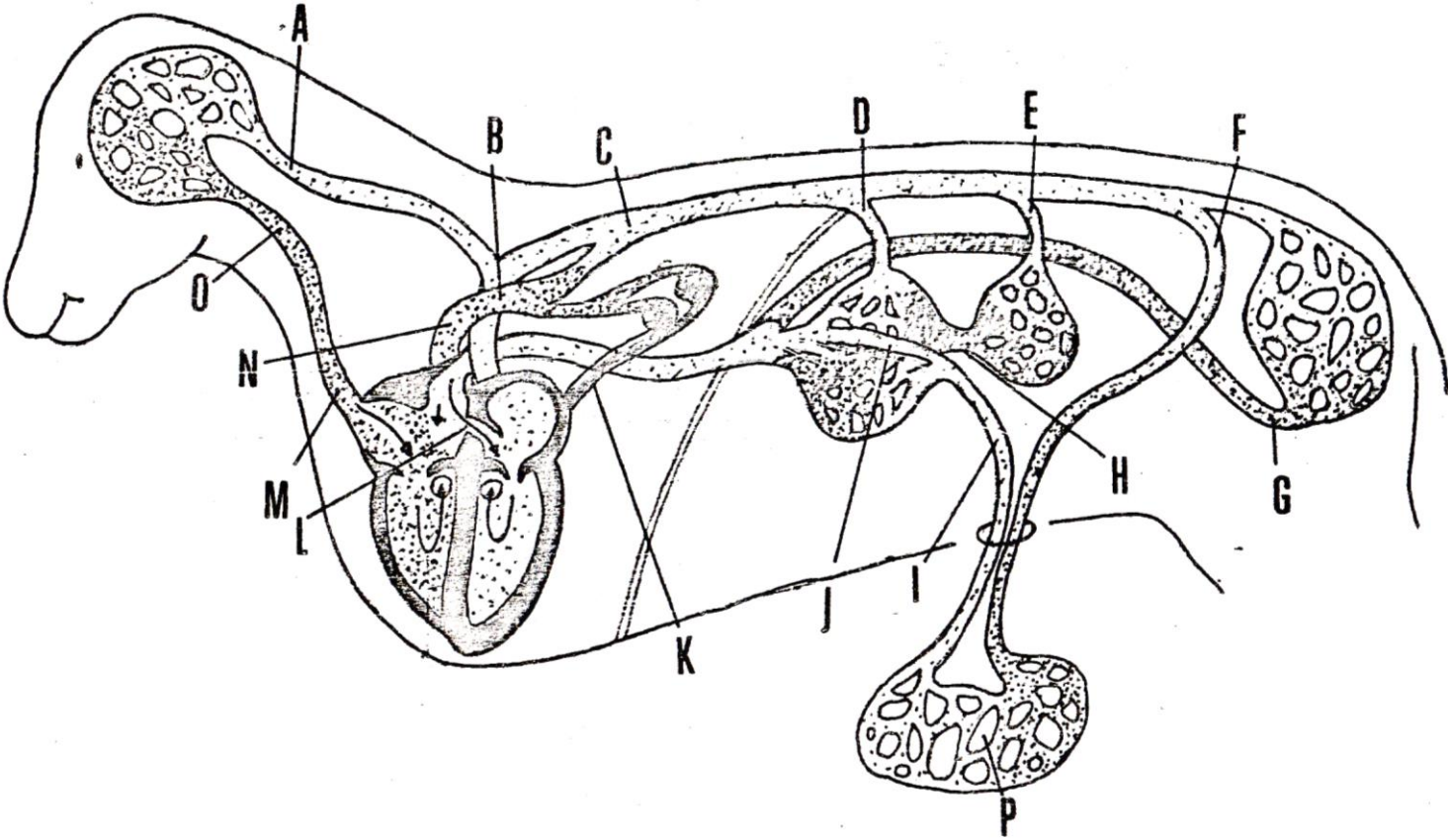
© 2012 Encyclopædia Britannica, Inc.



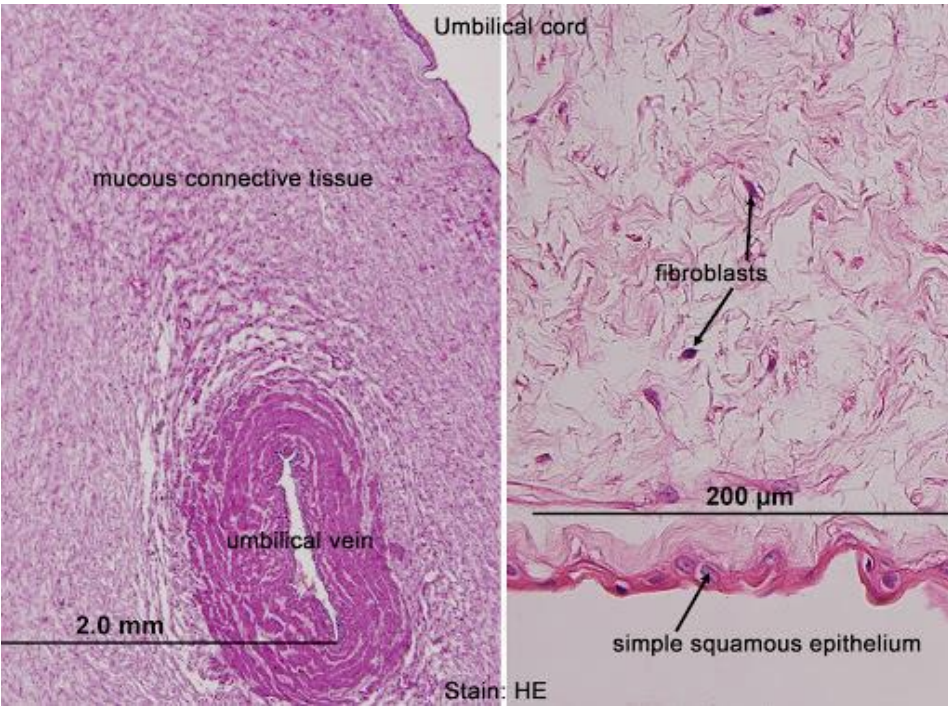
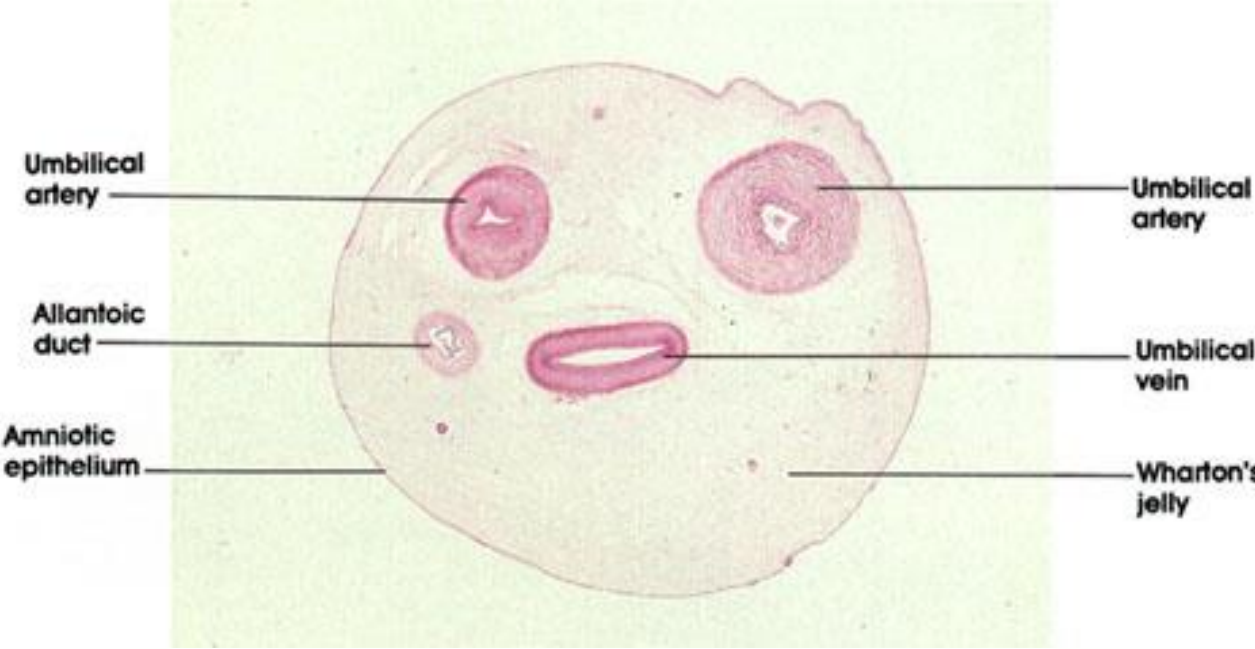
Allantois



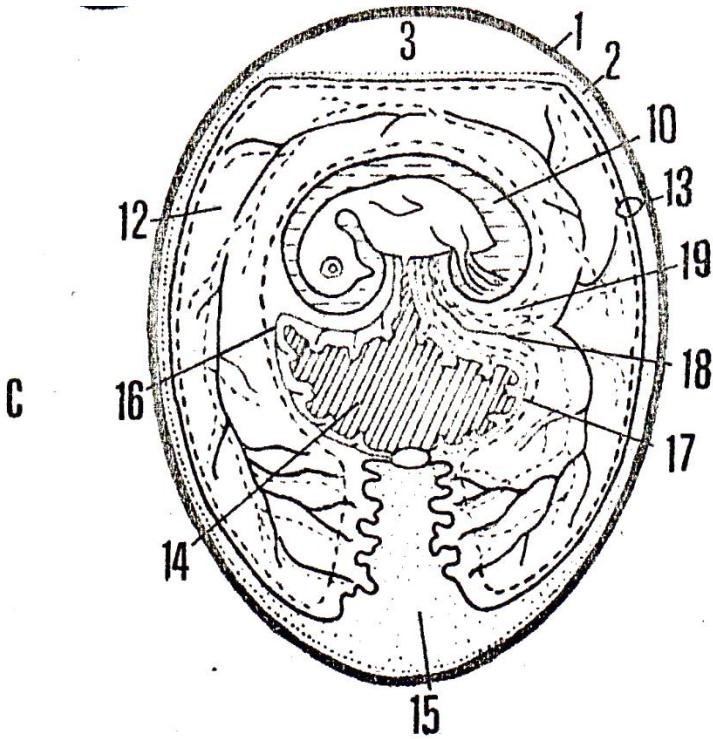
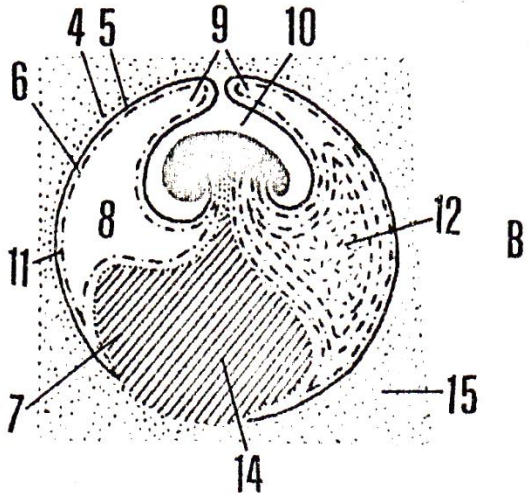
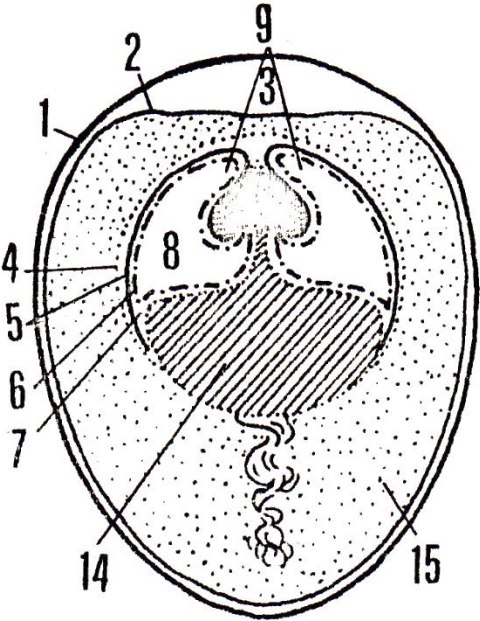
Fetal blood circulation

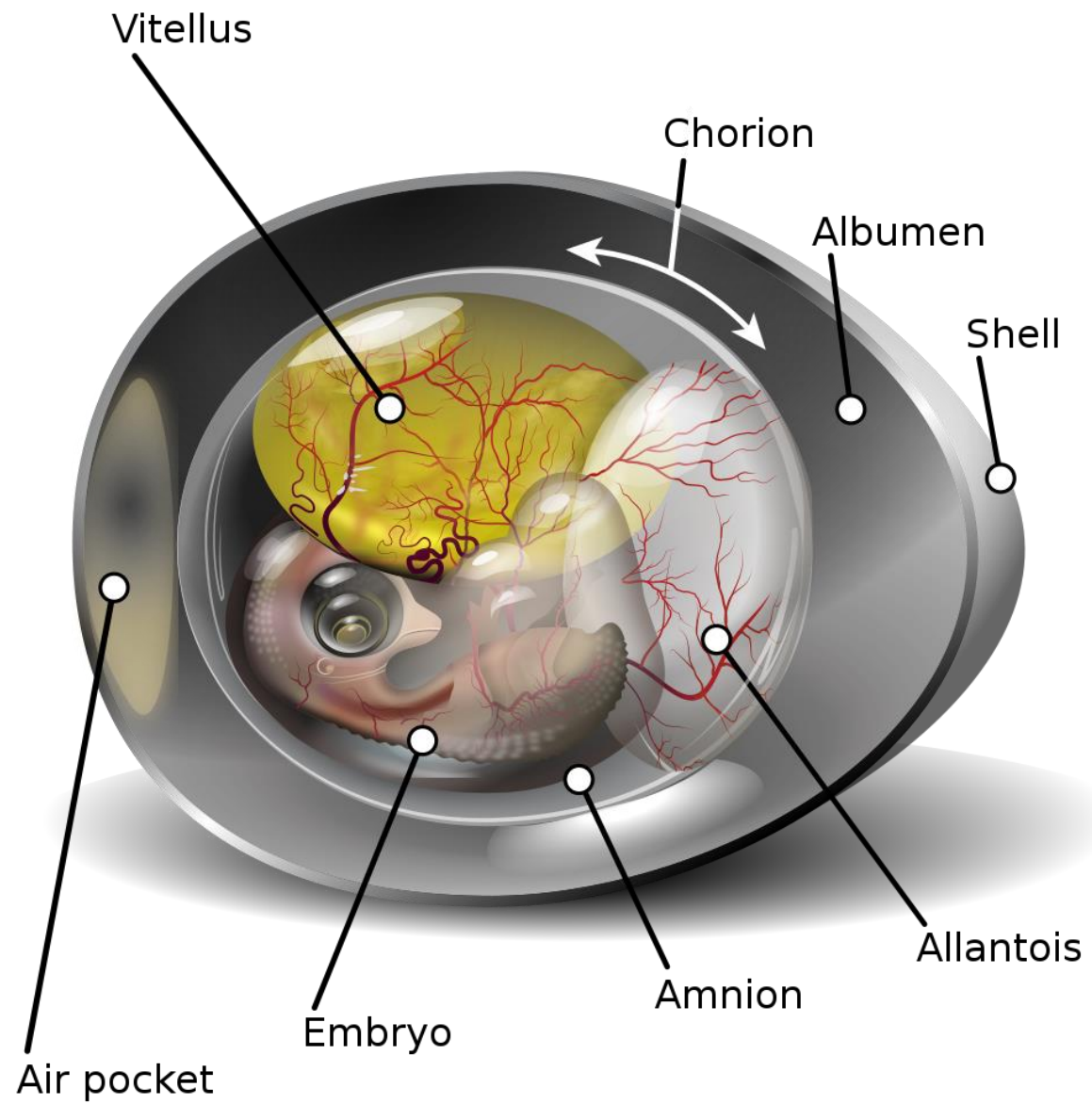


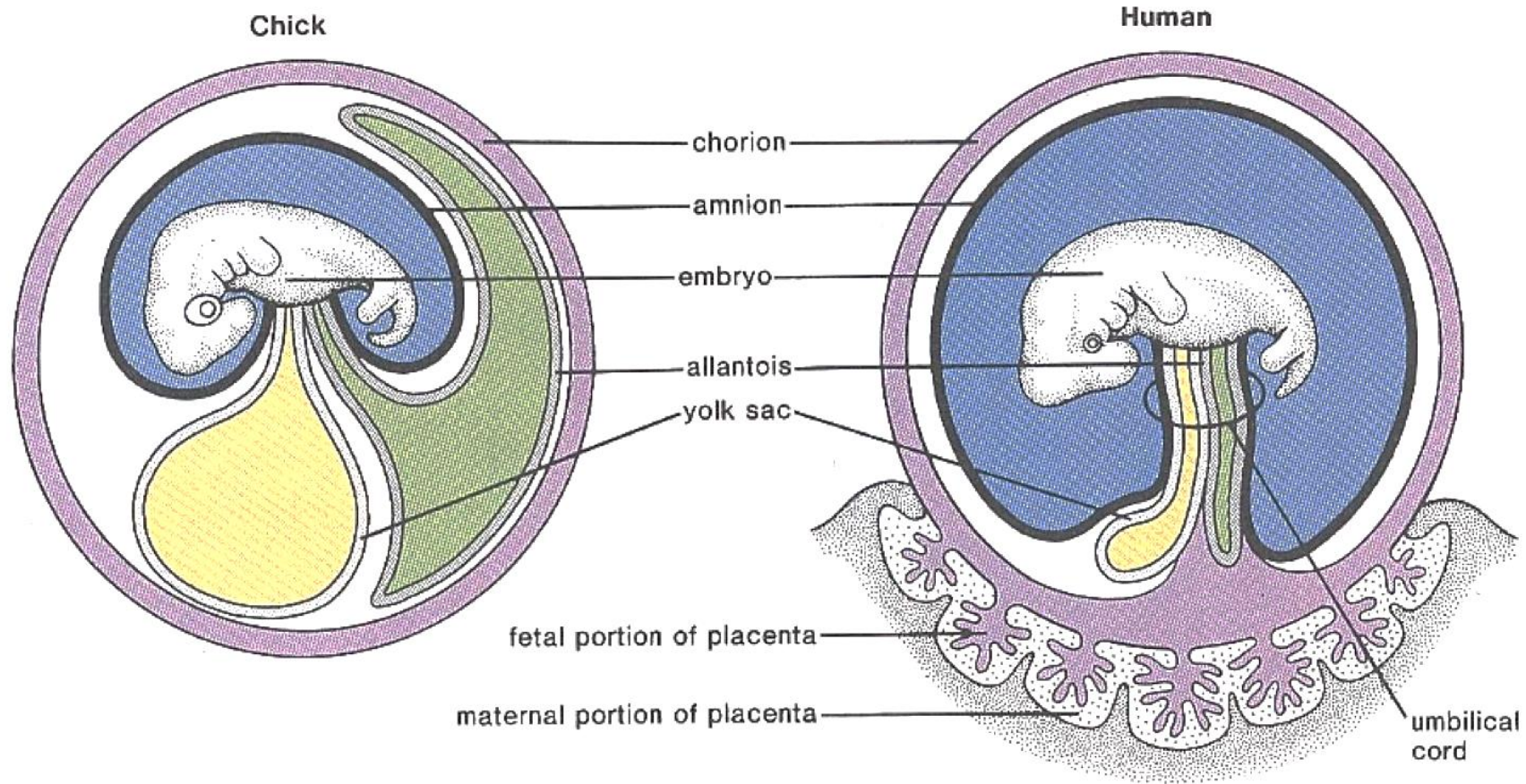
Umbilical cord



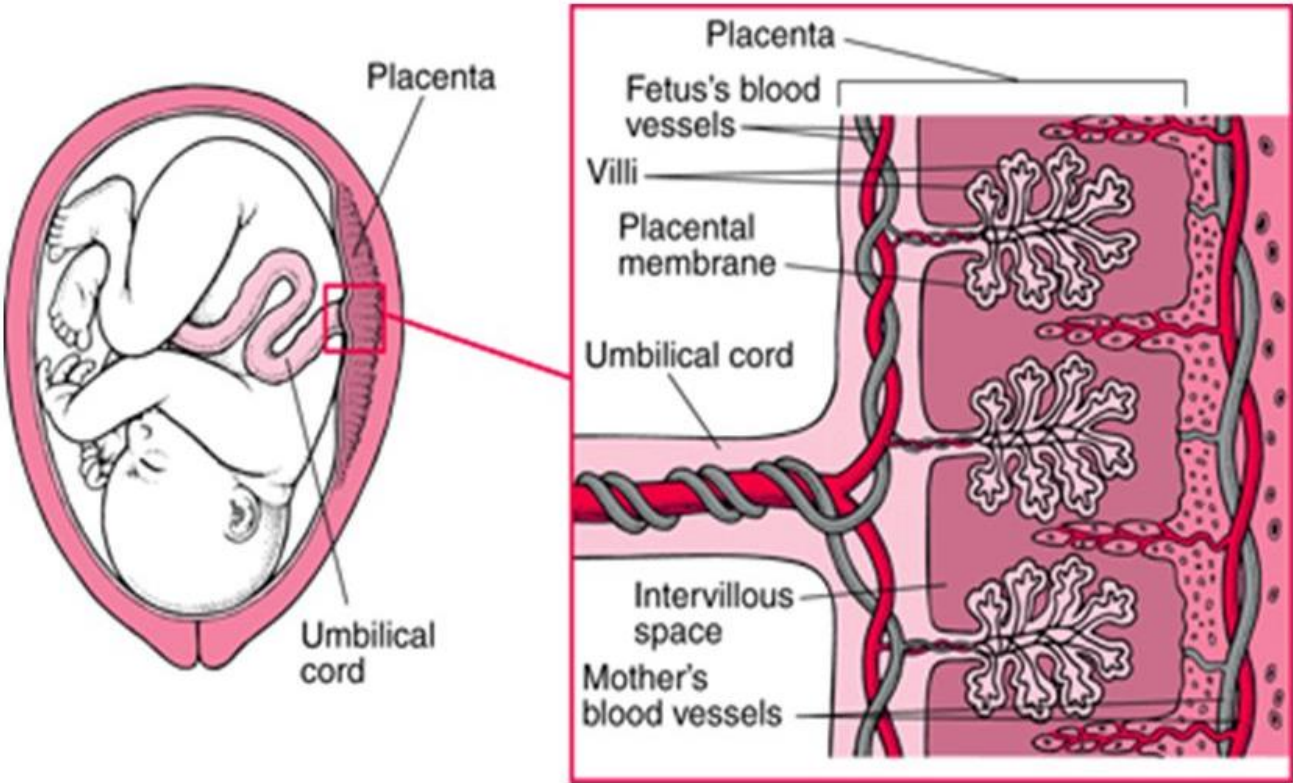
Birds







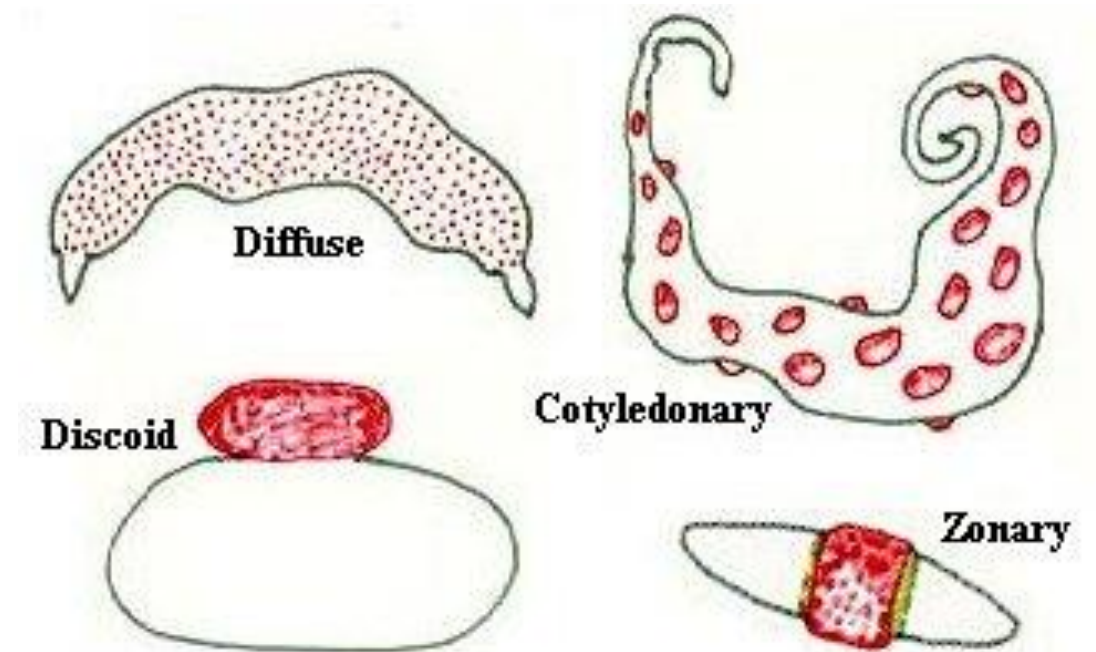
Placenta



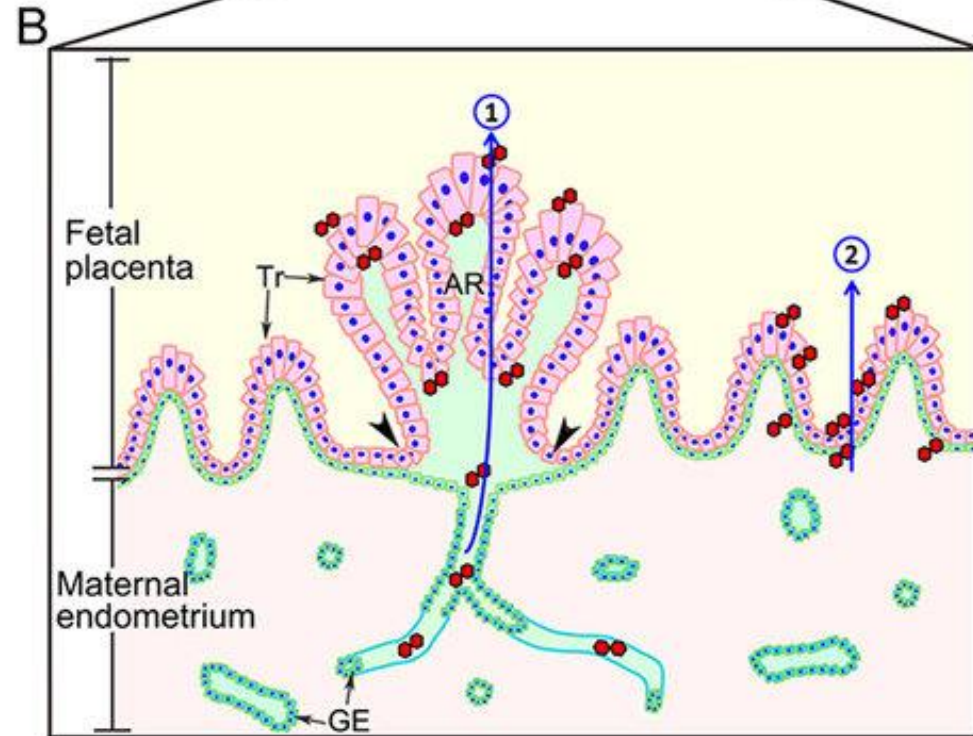
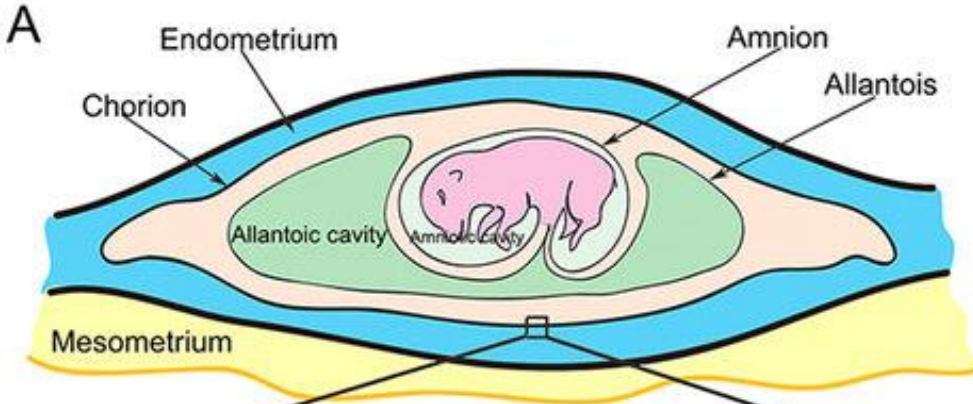
Placenta types

Chorion frondosum
Chorion laeve

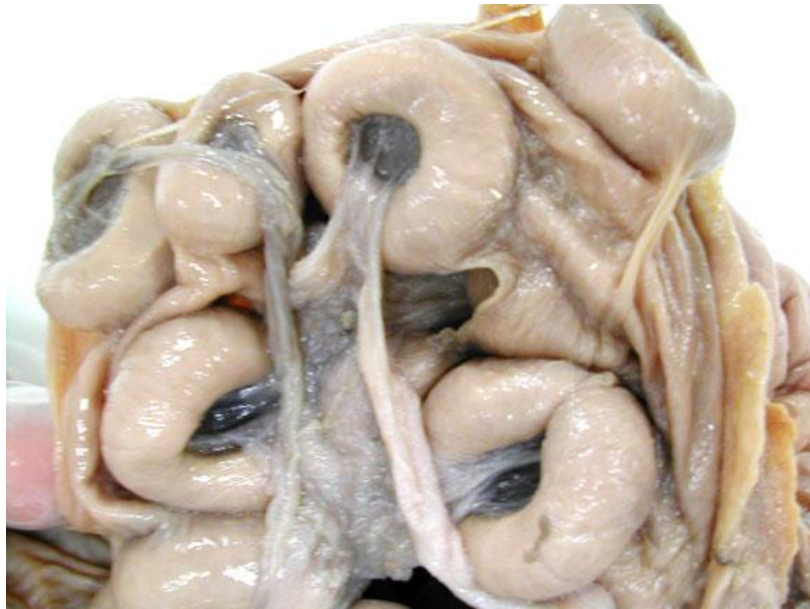Placenta diffusa (Eq, Su)
Placenta cotyledonata (Bo)
Placenta zonaria (Ca, Fe)
Placenta discoidea (Mu, Ho)



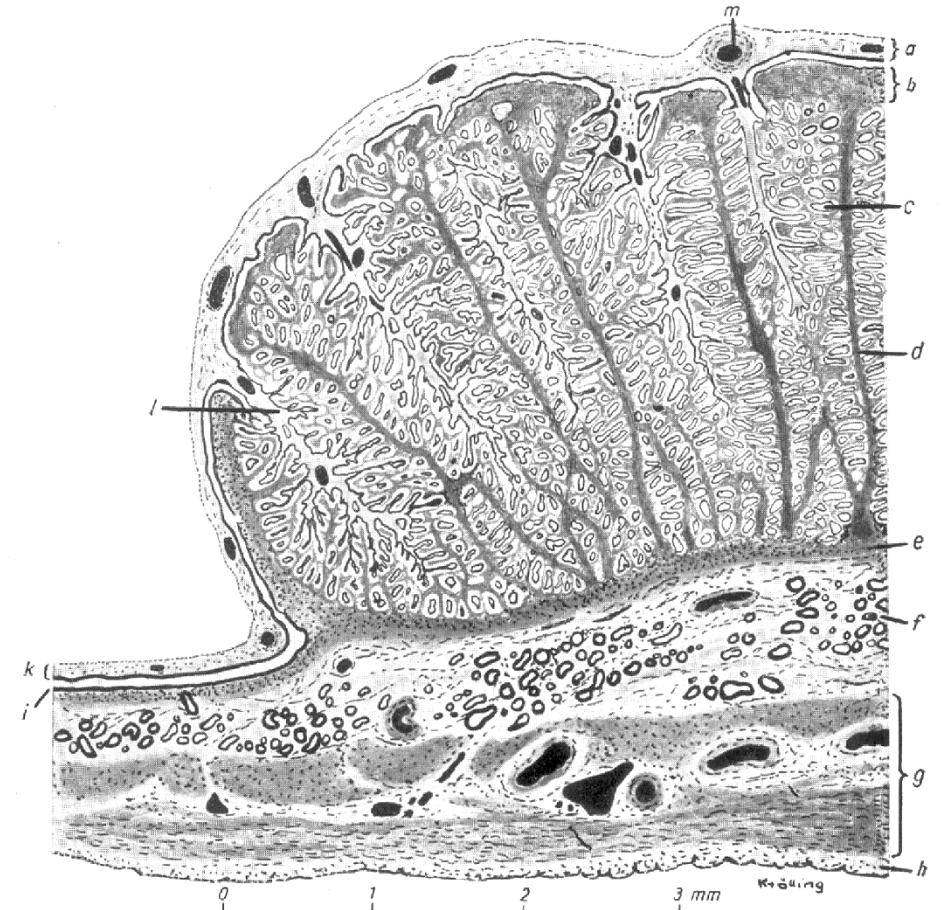
Placenta diffusa



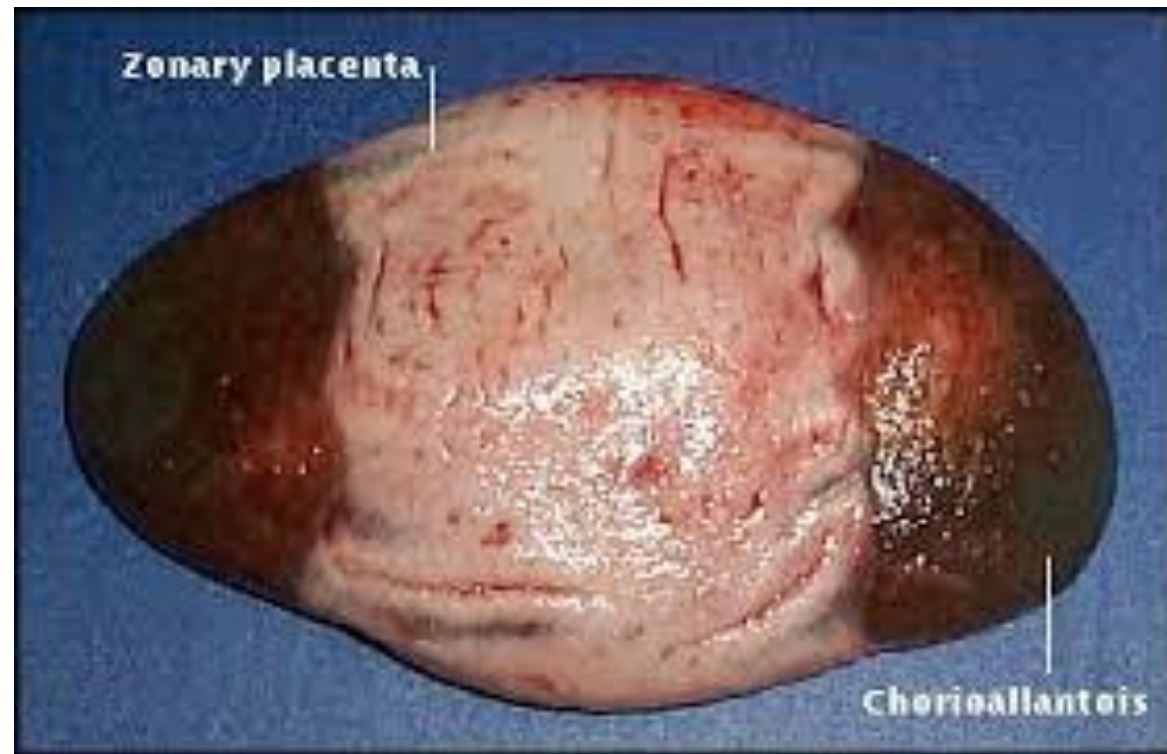Placenta cotyledonata



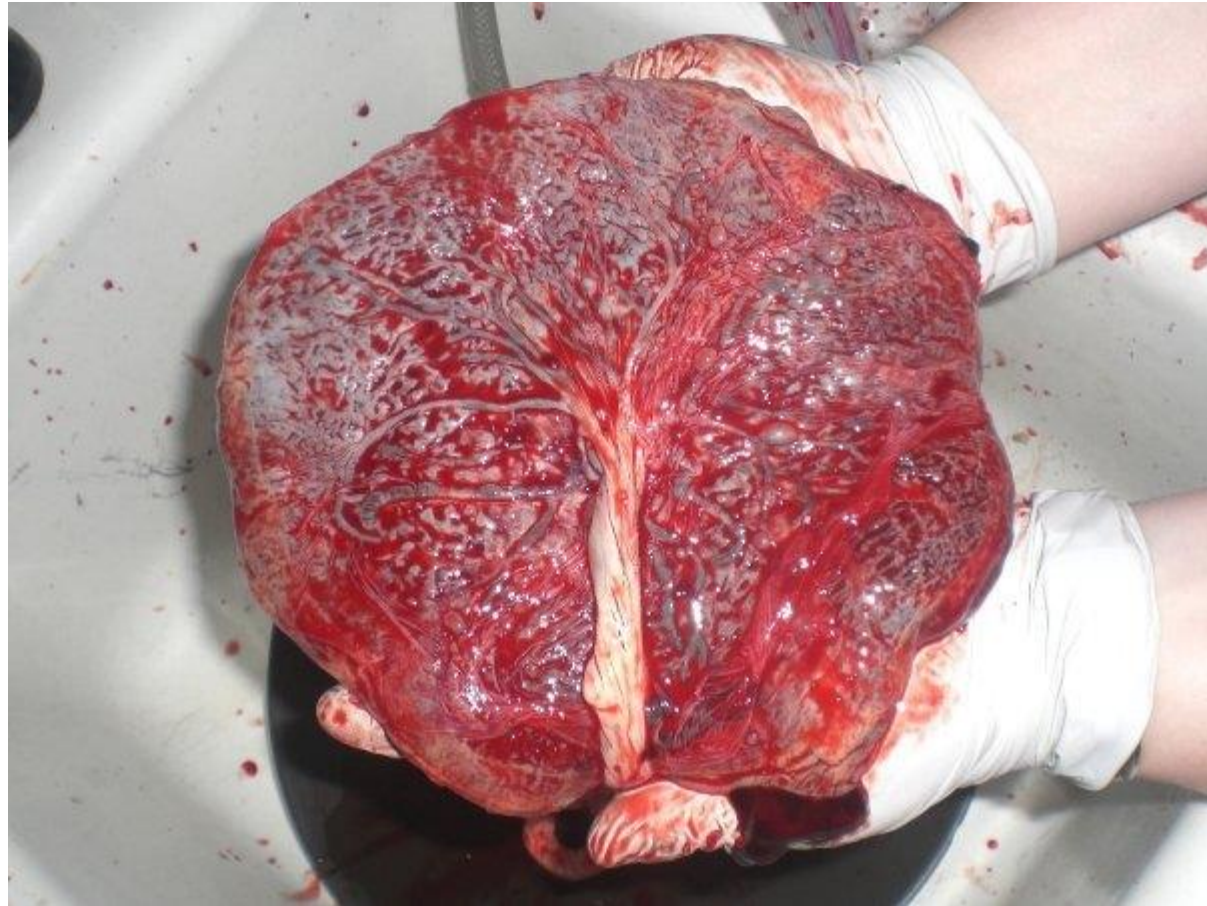
- Placentom:
- caruncle (M)
 - cotyledon (F)



Placenta zonaria

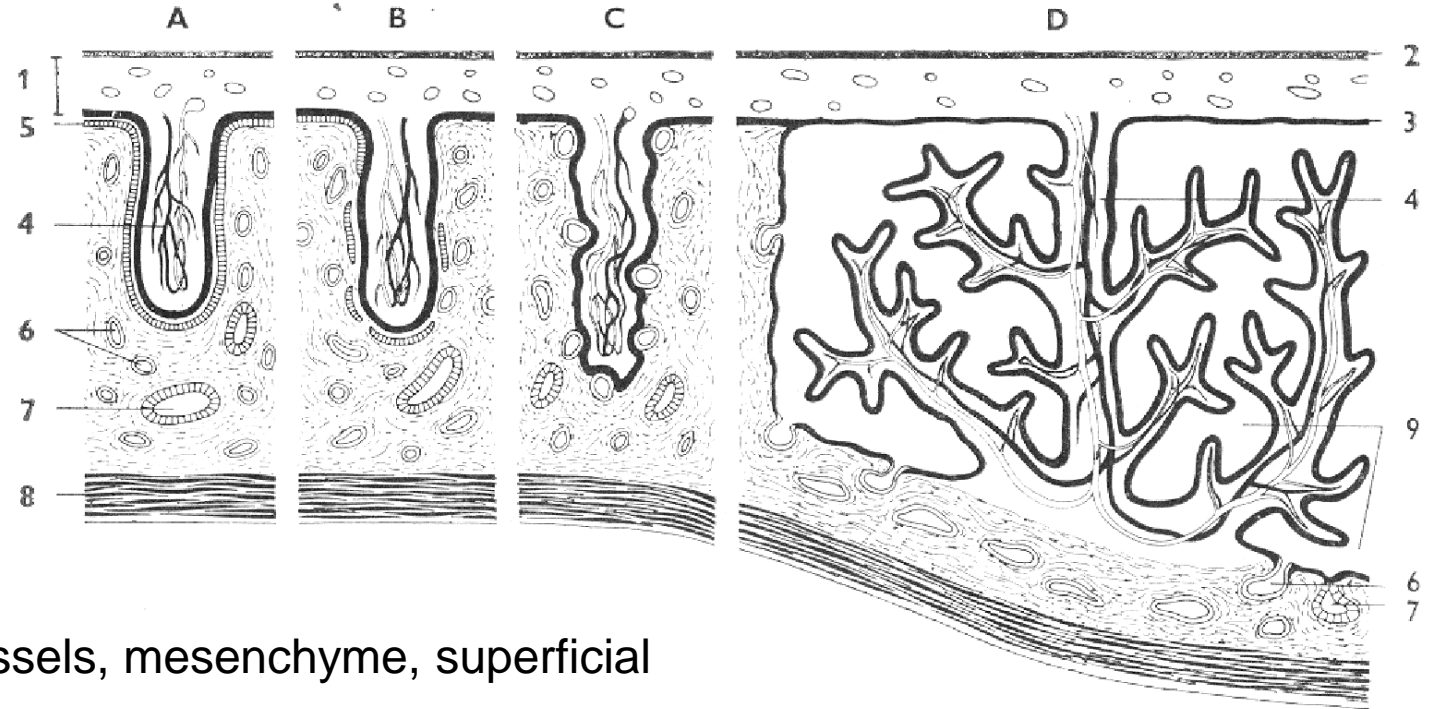


Placenta discoidea



Types of placentas – number of layers

semiplacenta x placenta vera

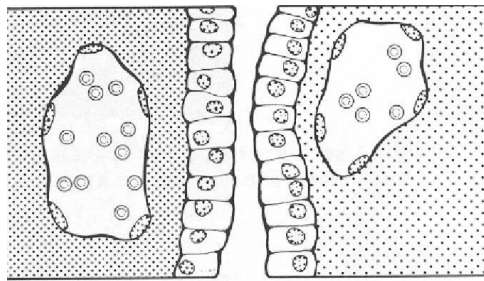


Pars fetalis: endothelium of chorion vessels, mesenchyme, superficial epithelium of chorion

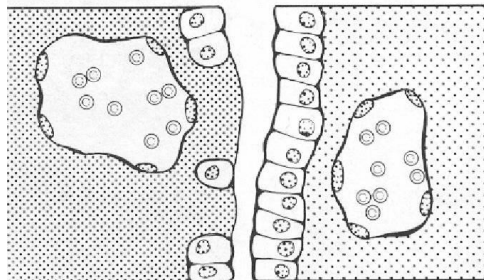
Pars materna: epithelium of endometrium, lamina propria mucosae, endothelium of vessels of endometrium



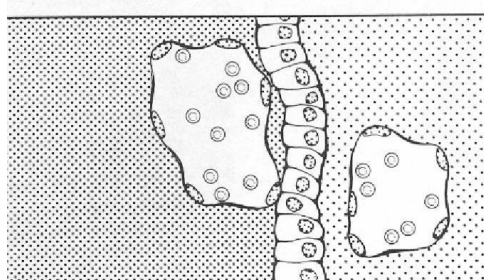
pars fetalis x pars materna



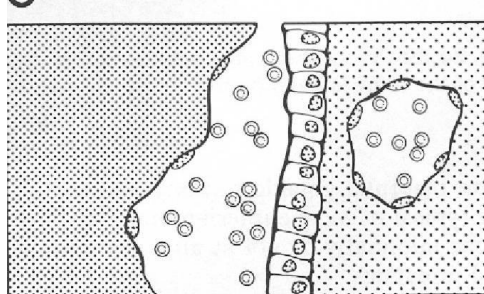
A



B



C



A – placenta epitheliochorialis (F-3, M-3)

– Su, Eq

B – placenta syndesmochorialis (F-3, M-2)

– Bo, Ov

C – placenta endotheliochorialis (F-3, M-1)

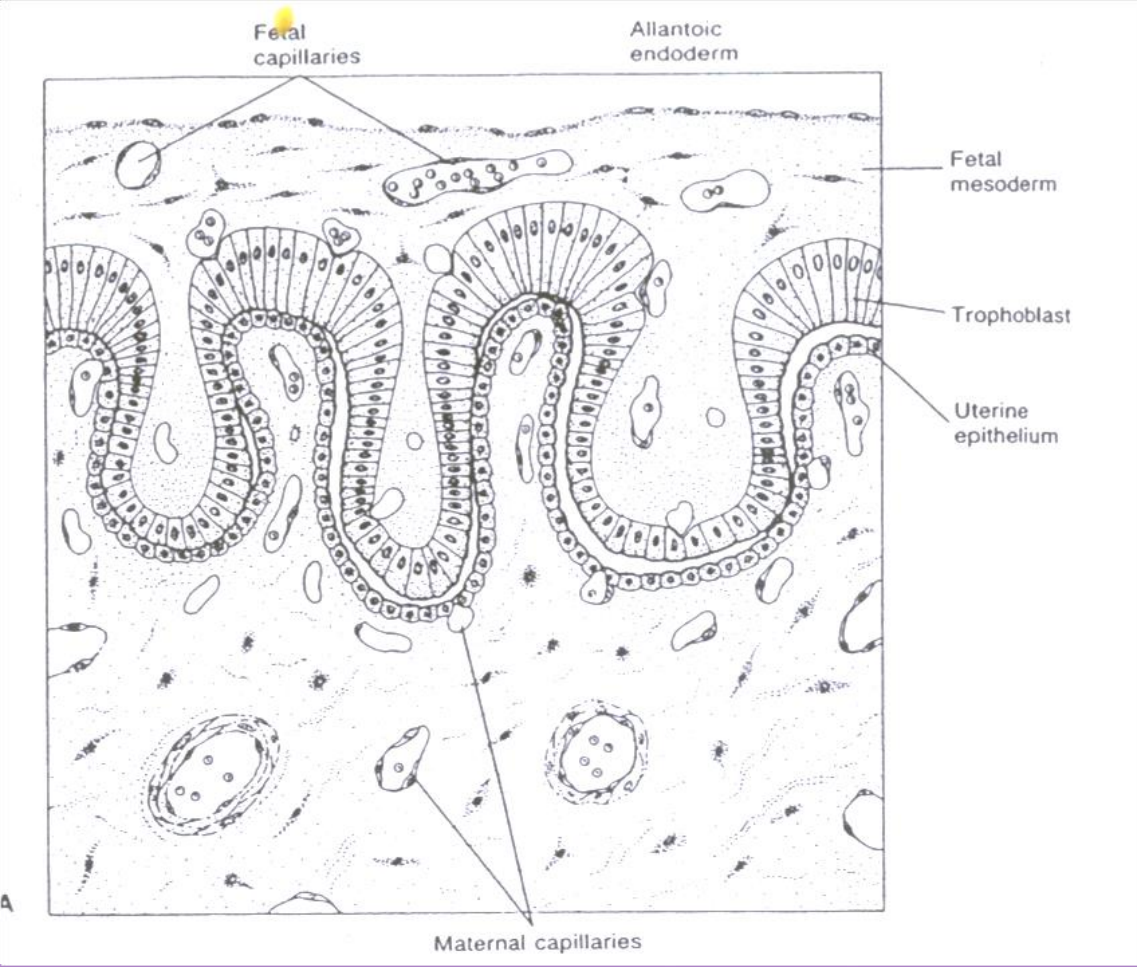
– Fe, Ca

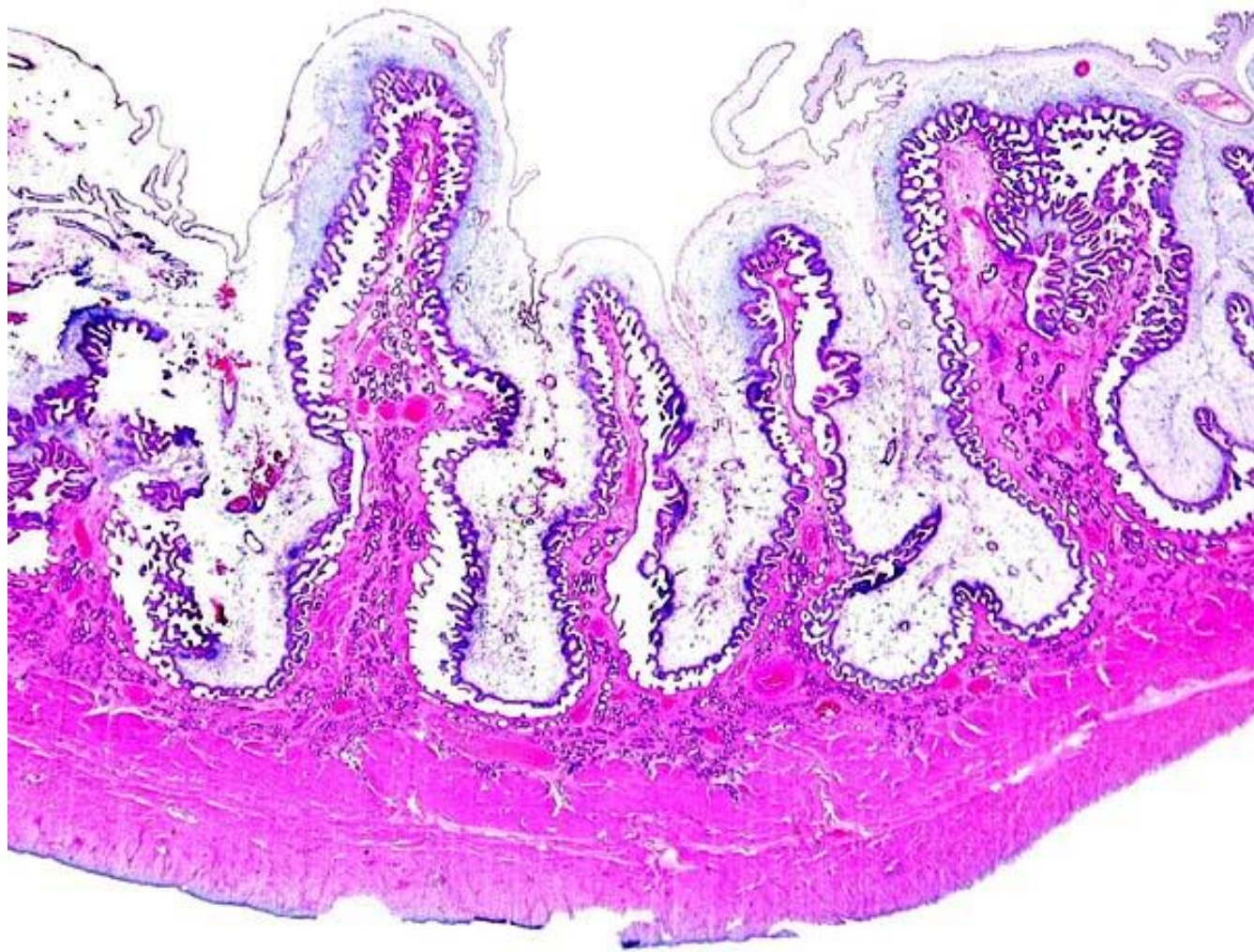
D – placenta haemochorialis (F-3)

– Ho, rodents

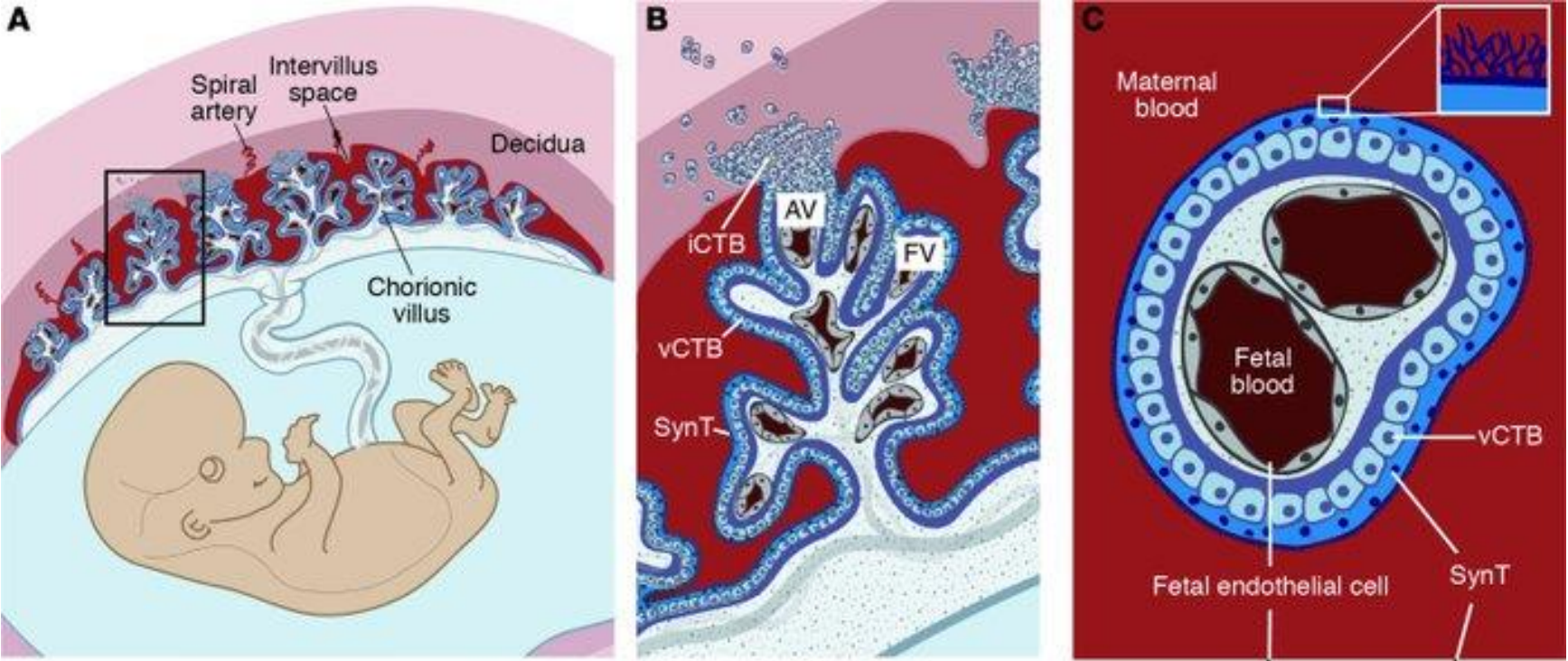


Placenta epitheliochorialis

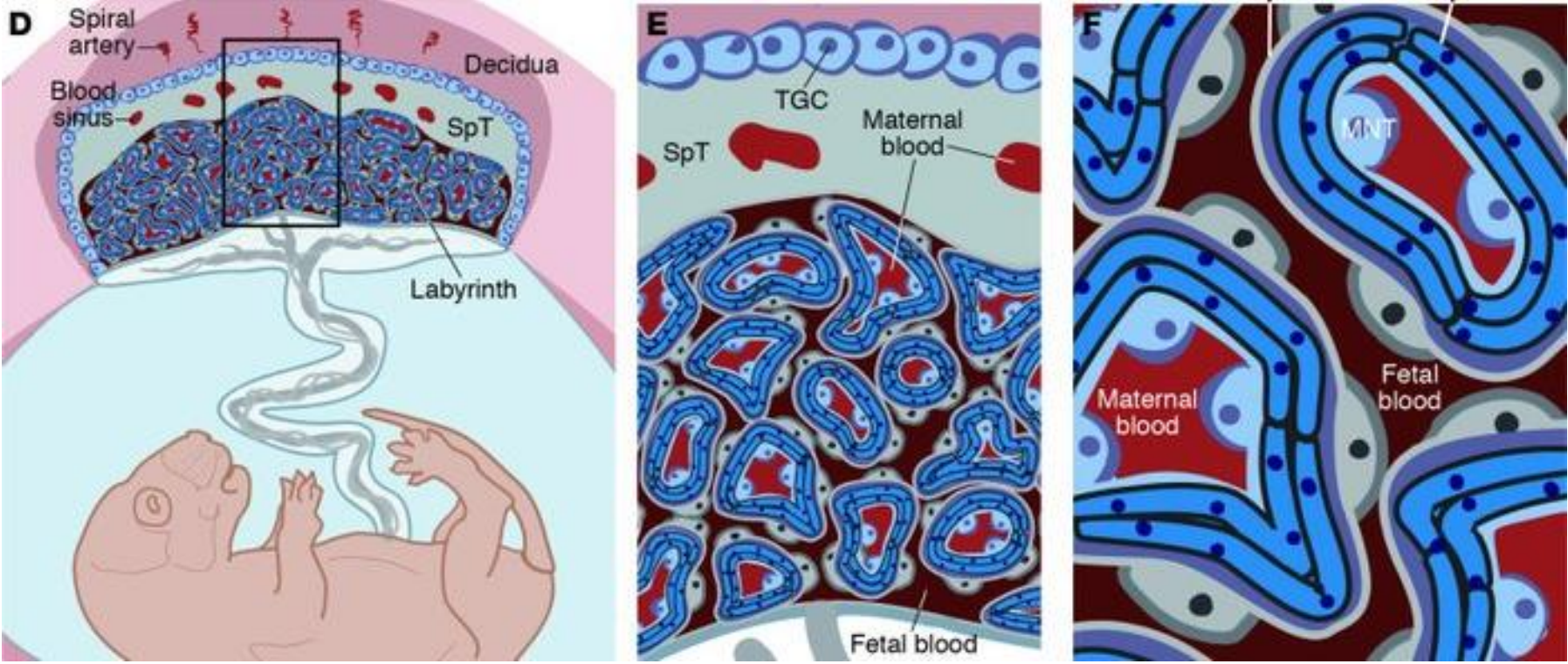




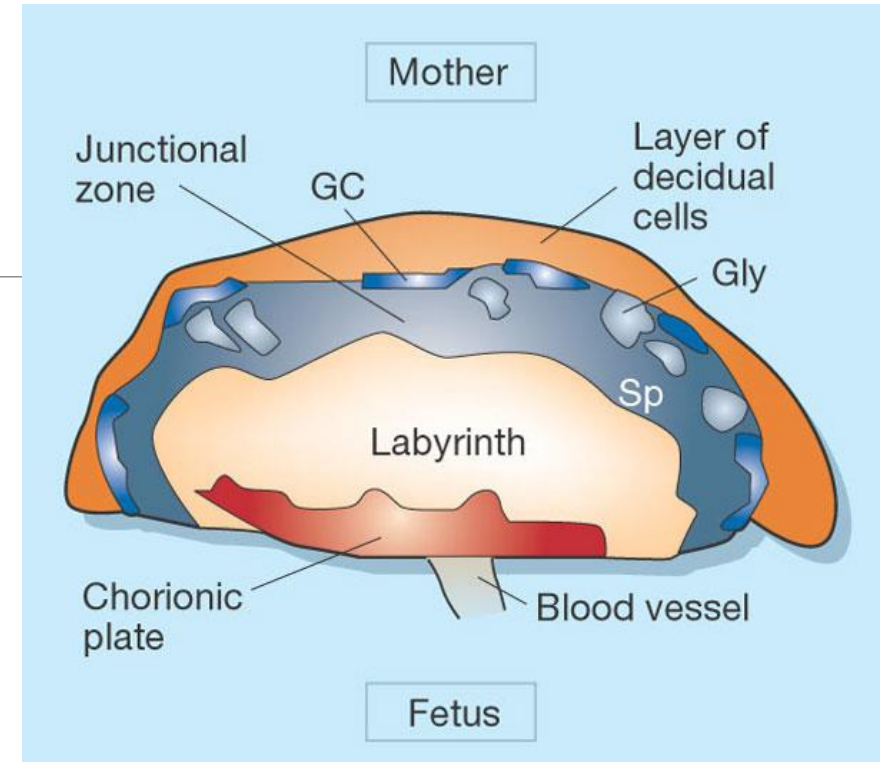
Placenta haemochorialis



Placenta haemochorialis



Placenta haemochorialis



a Mouse

