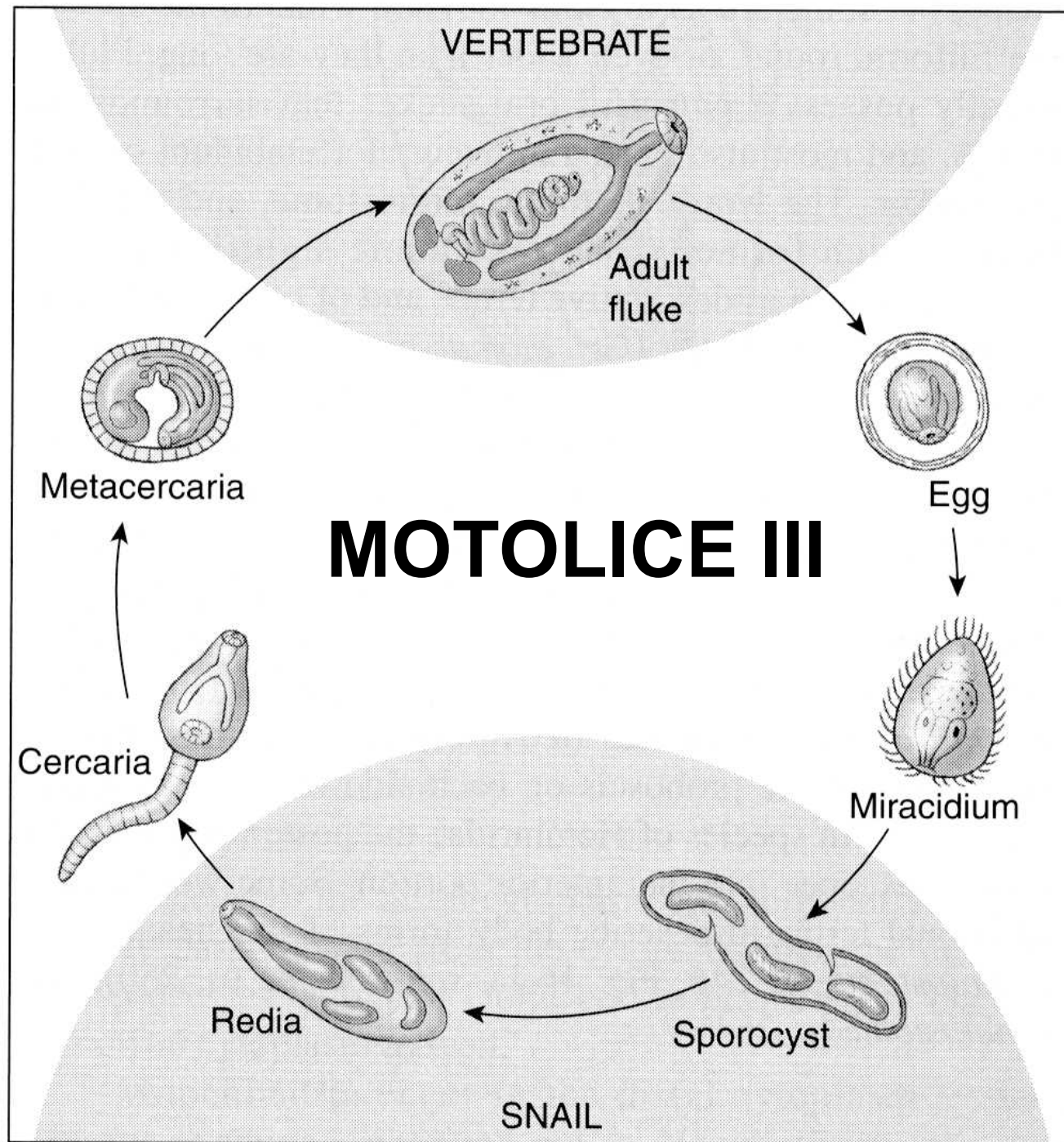

Motolice parazitující v zažívacím traktu

Paramphistomatidae



Paramphistomatidae

Charakteristika:

- Břišní přísavka velká, na konci těla
- Tělo kulovitého tvaru
- Cizopasí hlavně u savců, včetně hospodářských zvířat a člověka

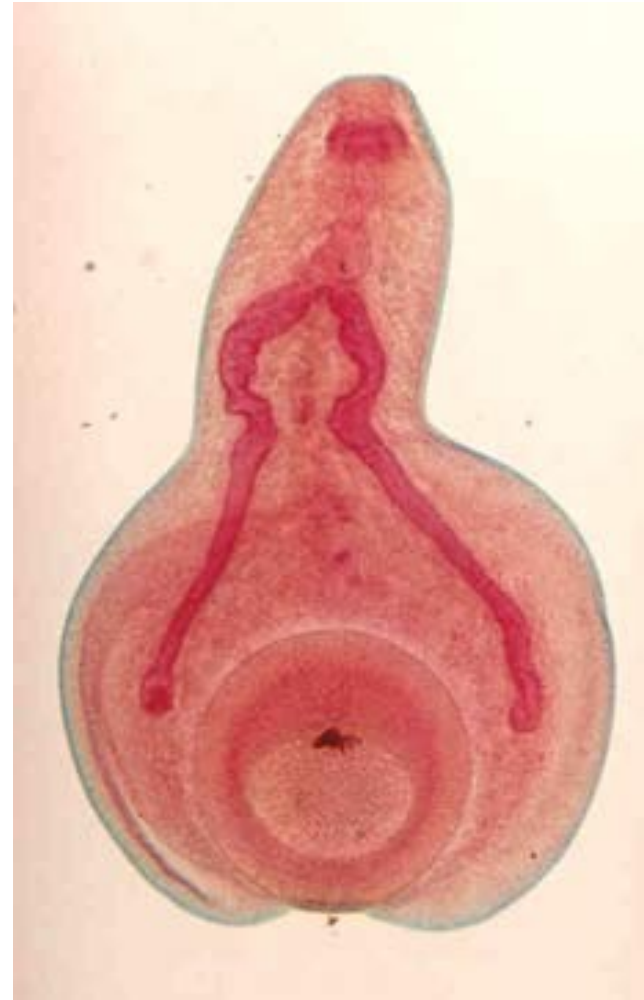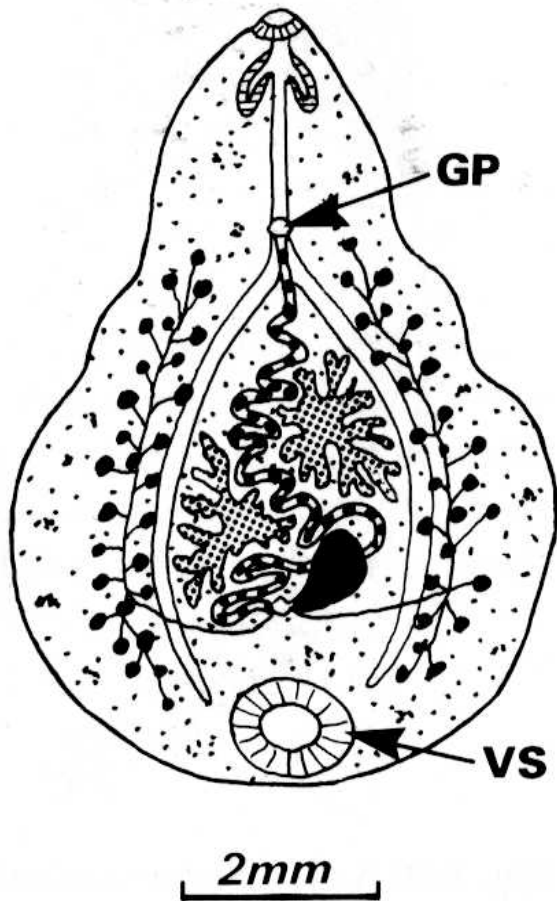
Vývoj:

- 1.Mz –plži (Planorbidae) – paramfistomní cercárie
- Metacercárie (adoleskarie) na vegetaci

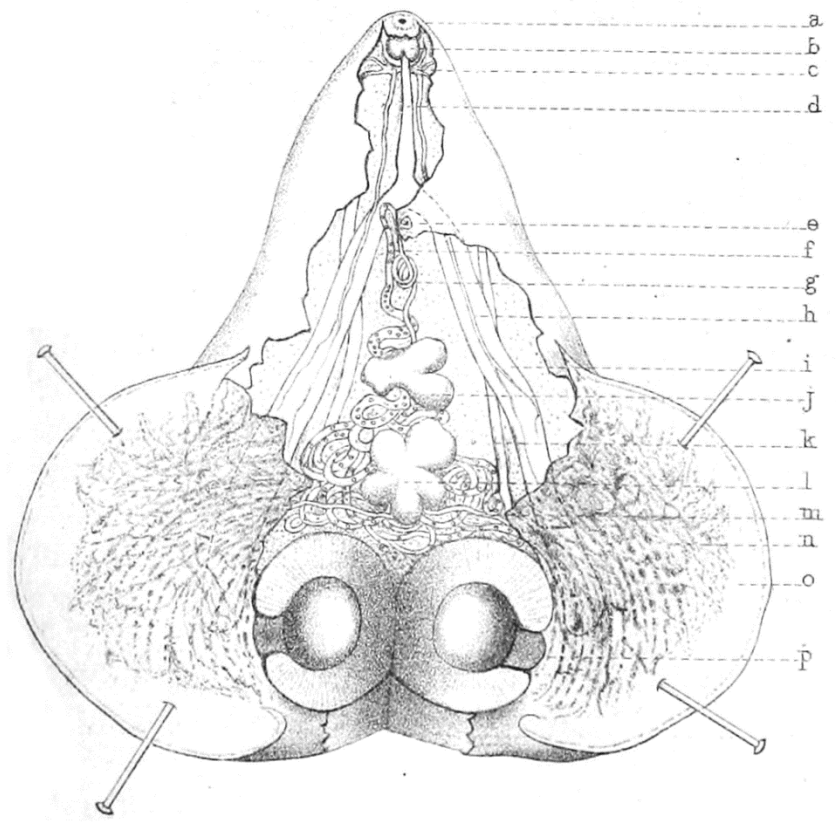
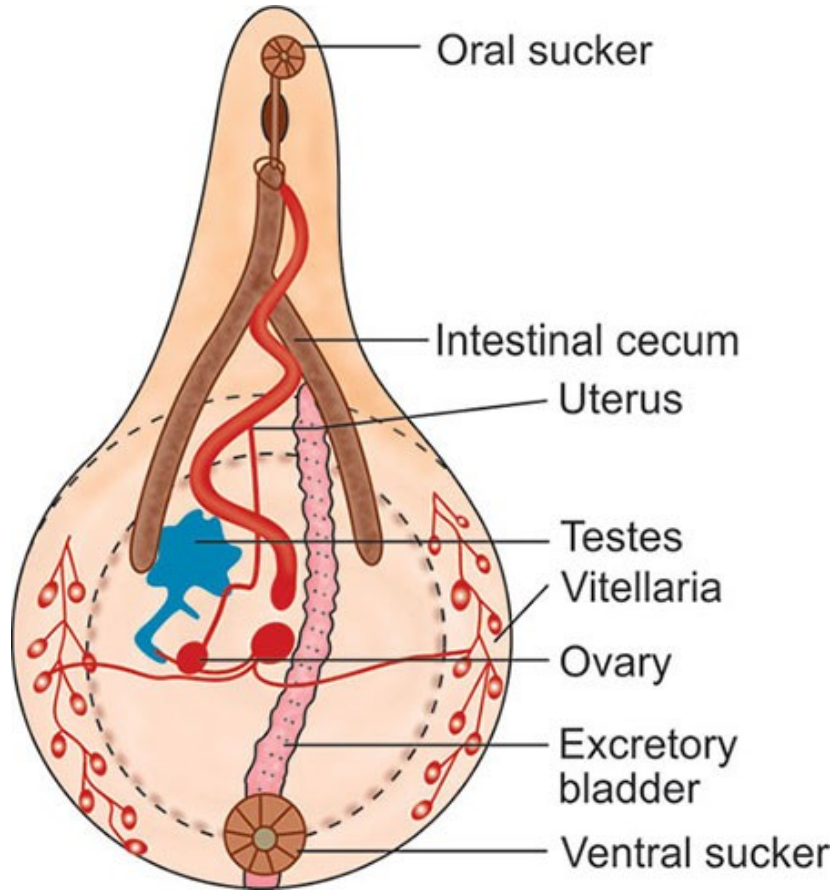
Zástupci:

- *Paramphistomum cervi* – skot, jeleni, ovce
- ***Gastrodiscoides hominis*** (subtropy) - člověk

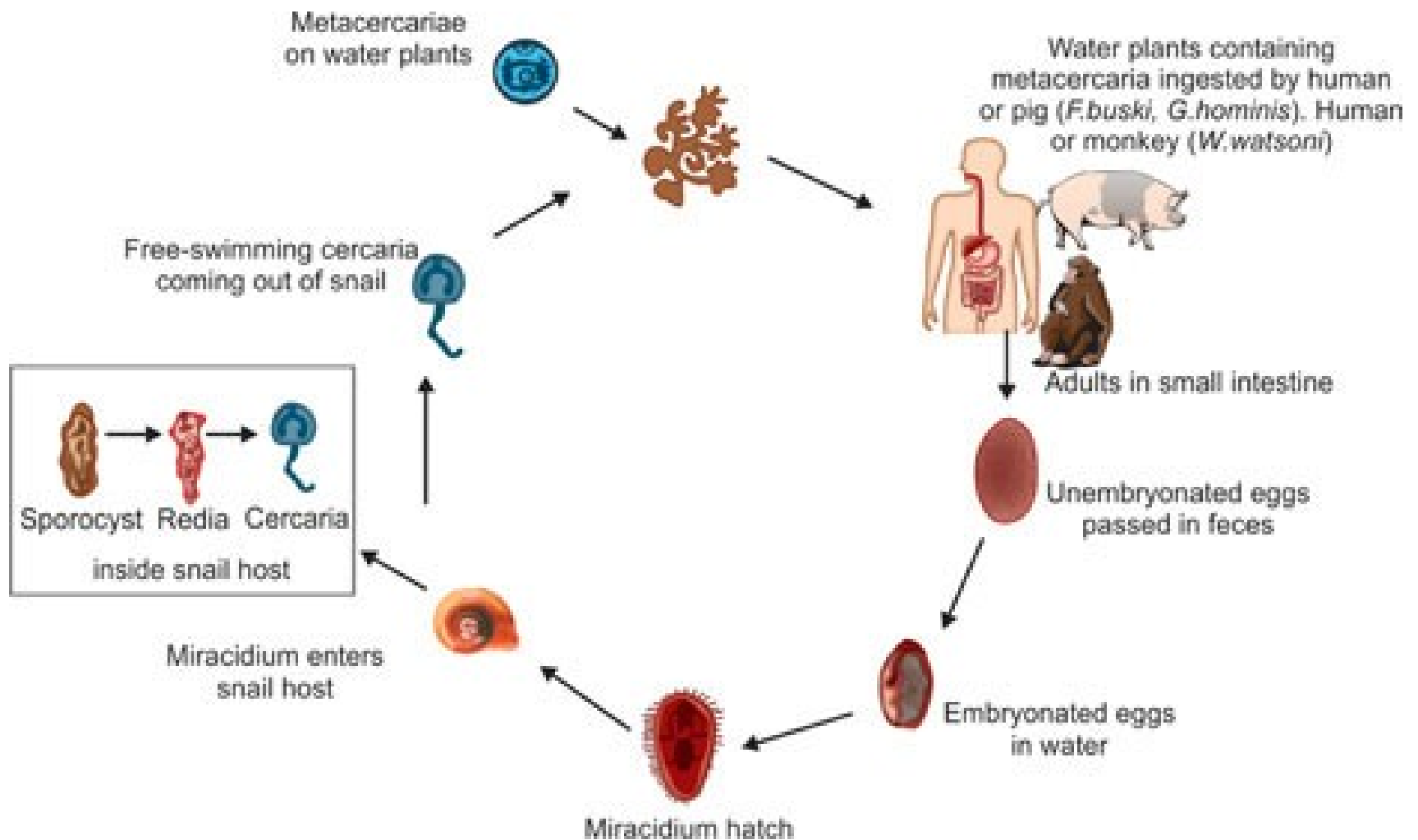
Gastrodiscoides hominis



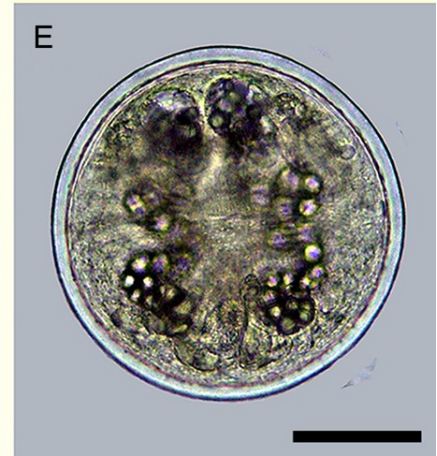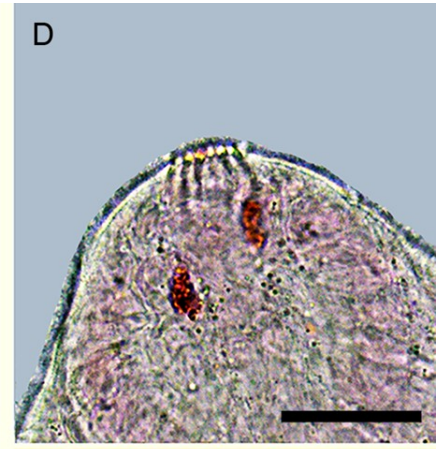
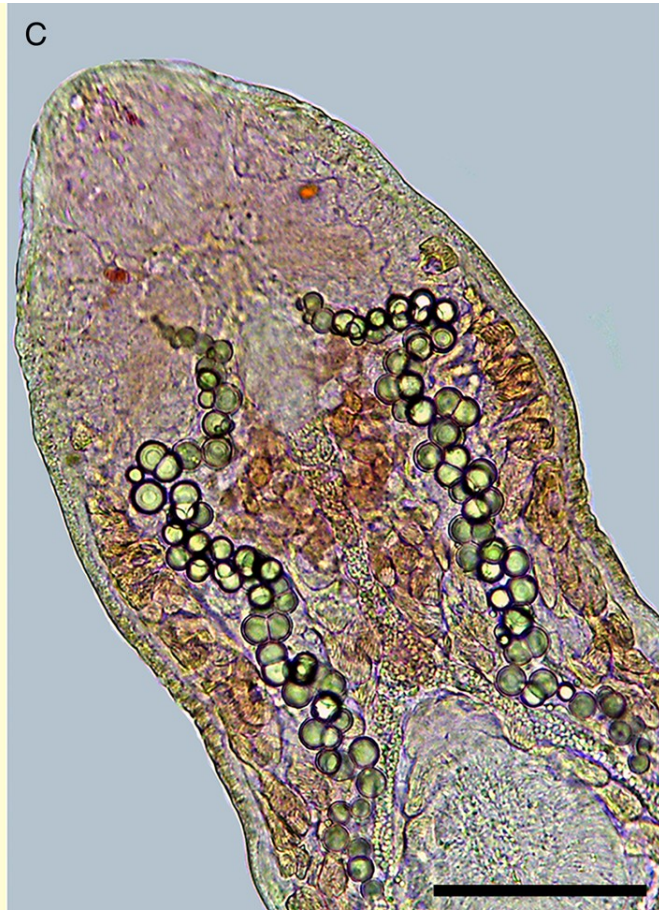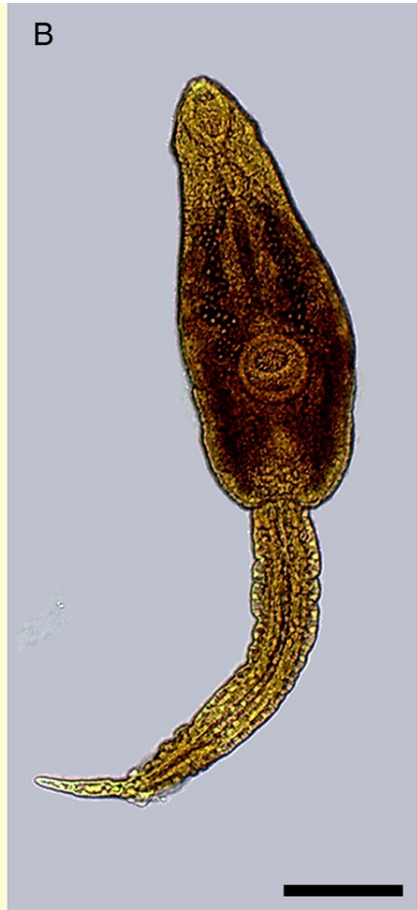
Gastrodiscoides homonis - morfologie



Životní cyklus *G. hominis*



Echinostomatidae



Echinostomatidae

Charakteristika:

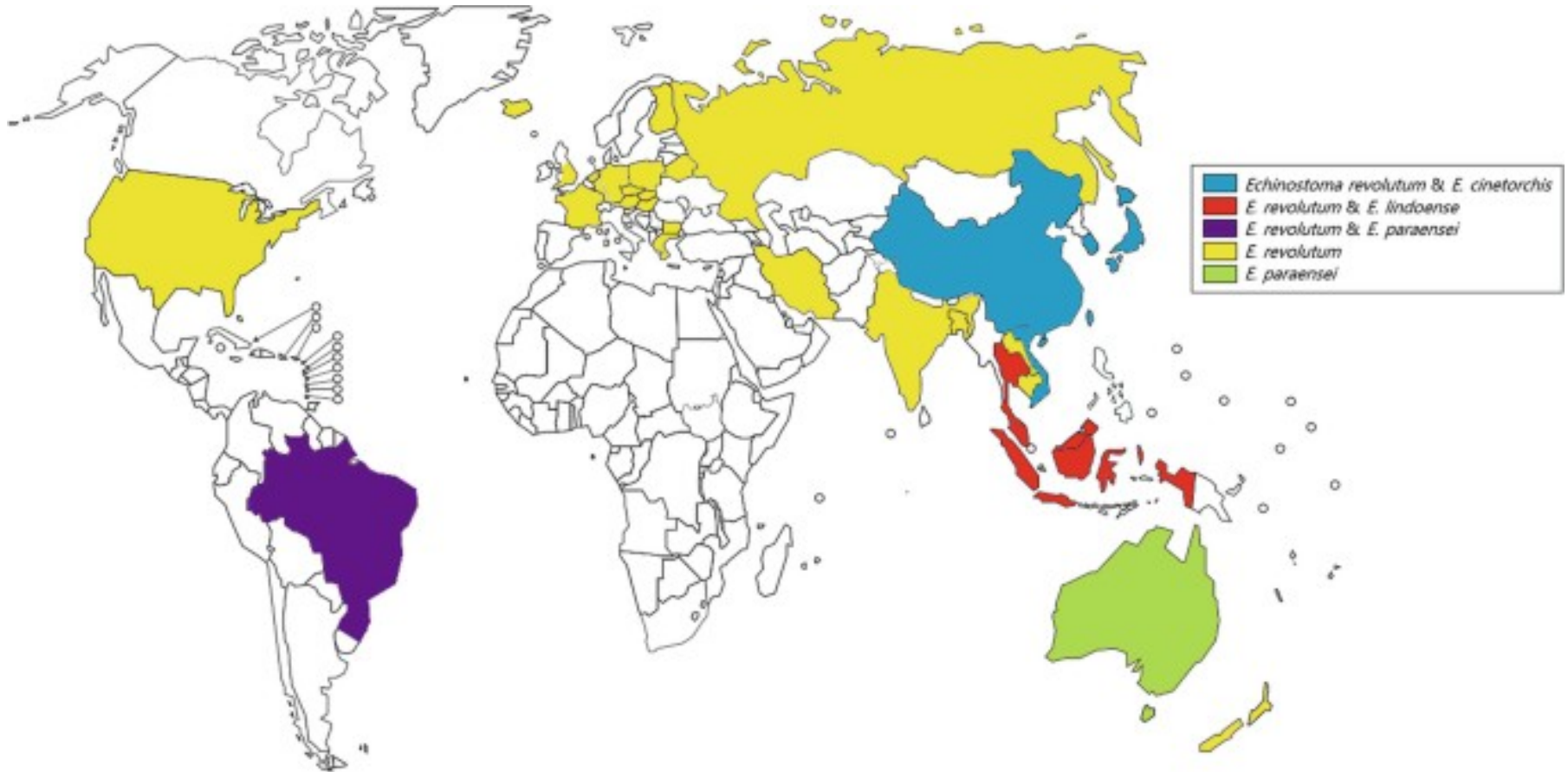
- Běžné střevní motolice ptáků a savců, vzácně u lidí
- Límeč s trny

Vývoj:

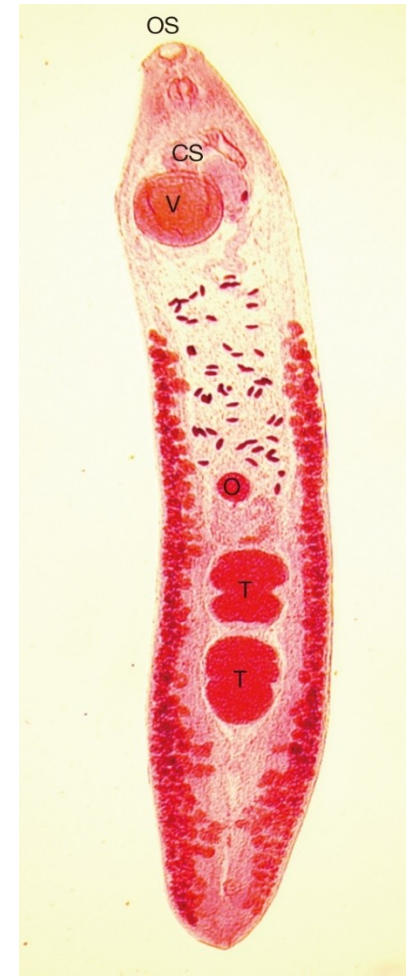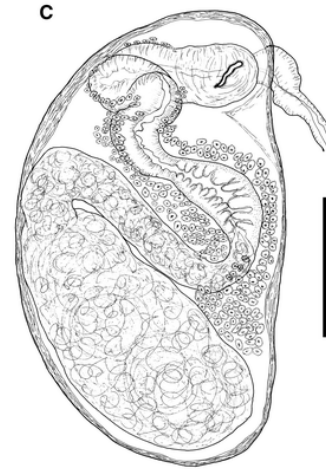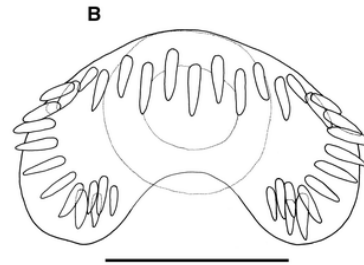
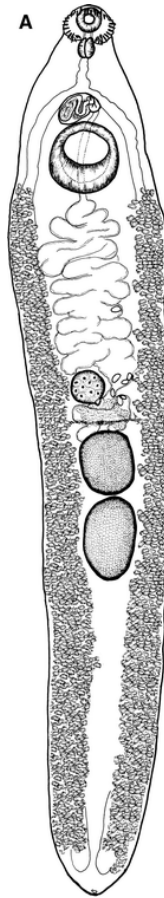
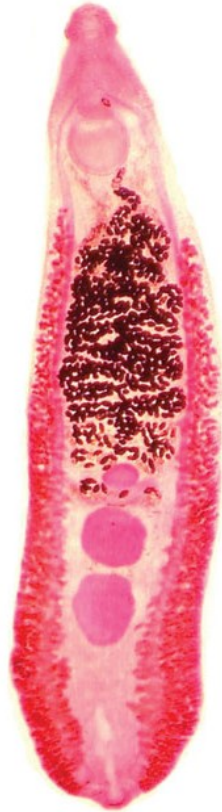
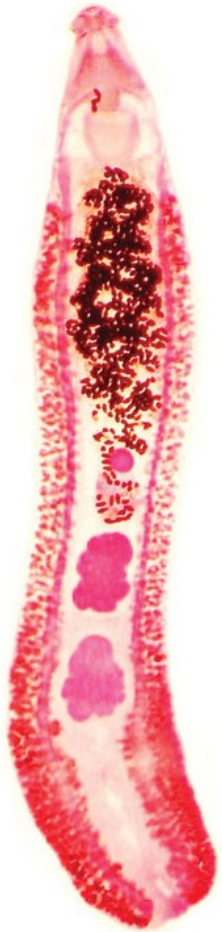- 1. Mz – plži (Lymnaea, Physa, Bithynia) – echinostomní cercárie
- 2. Mz – bezobratlí (především, měkkýši) ale i obratlovci (žáby, ryby)
- **Zástupci:**
- **Echinostoma revolutum**
- Echinoparyphium, Petasiger, Hypoderaeum

Rozšíření Echinostomatidae


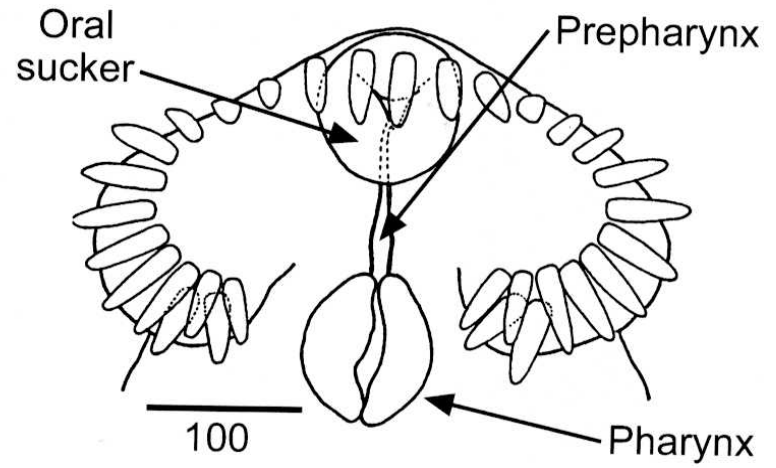
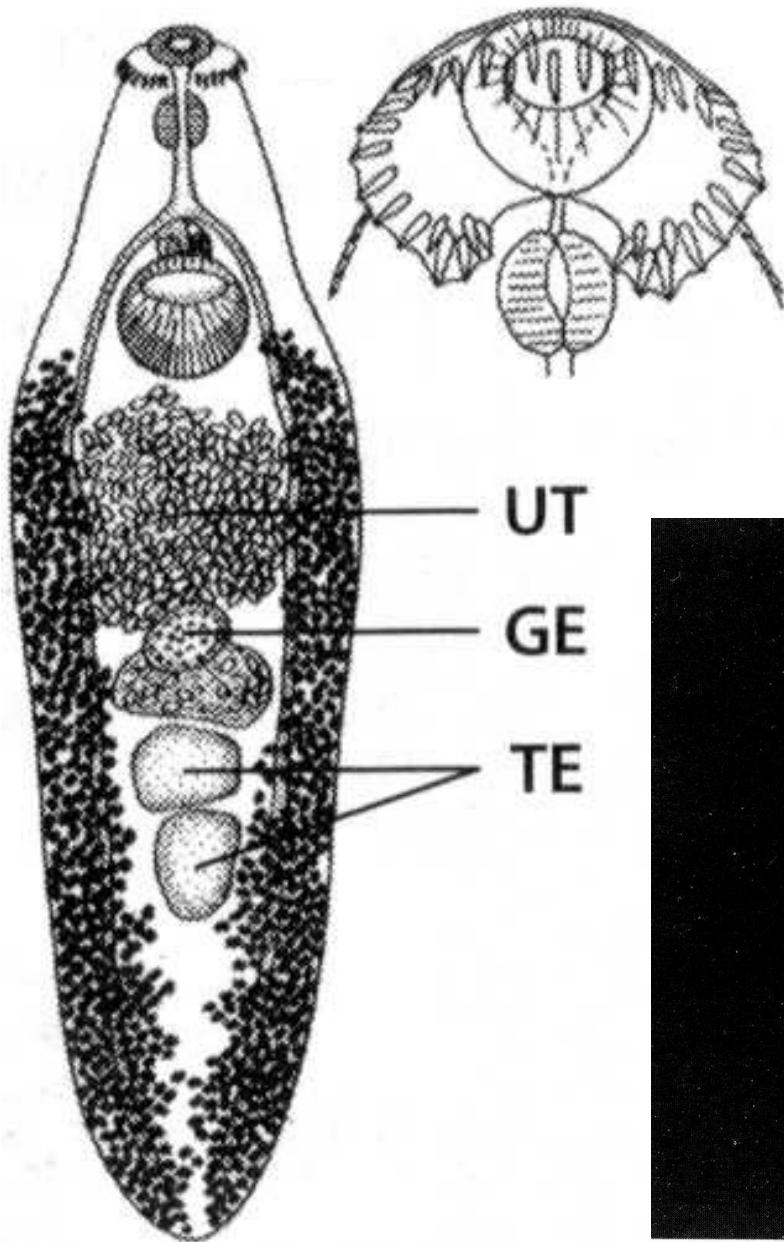
Echinostoma revolutum



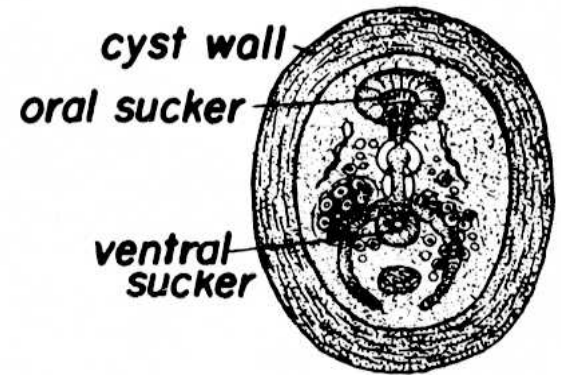
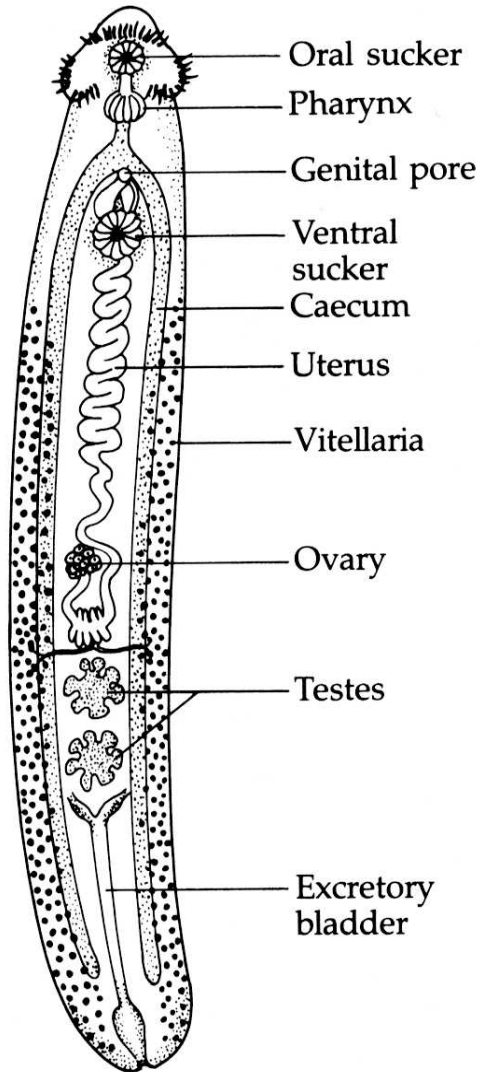
Echinostoma revolutum - morfologie



Echinostoma revolutum

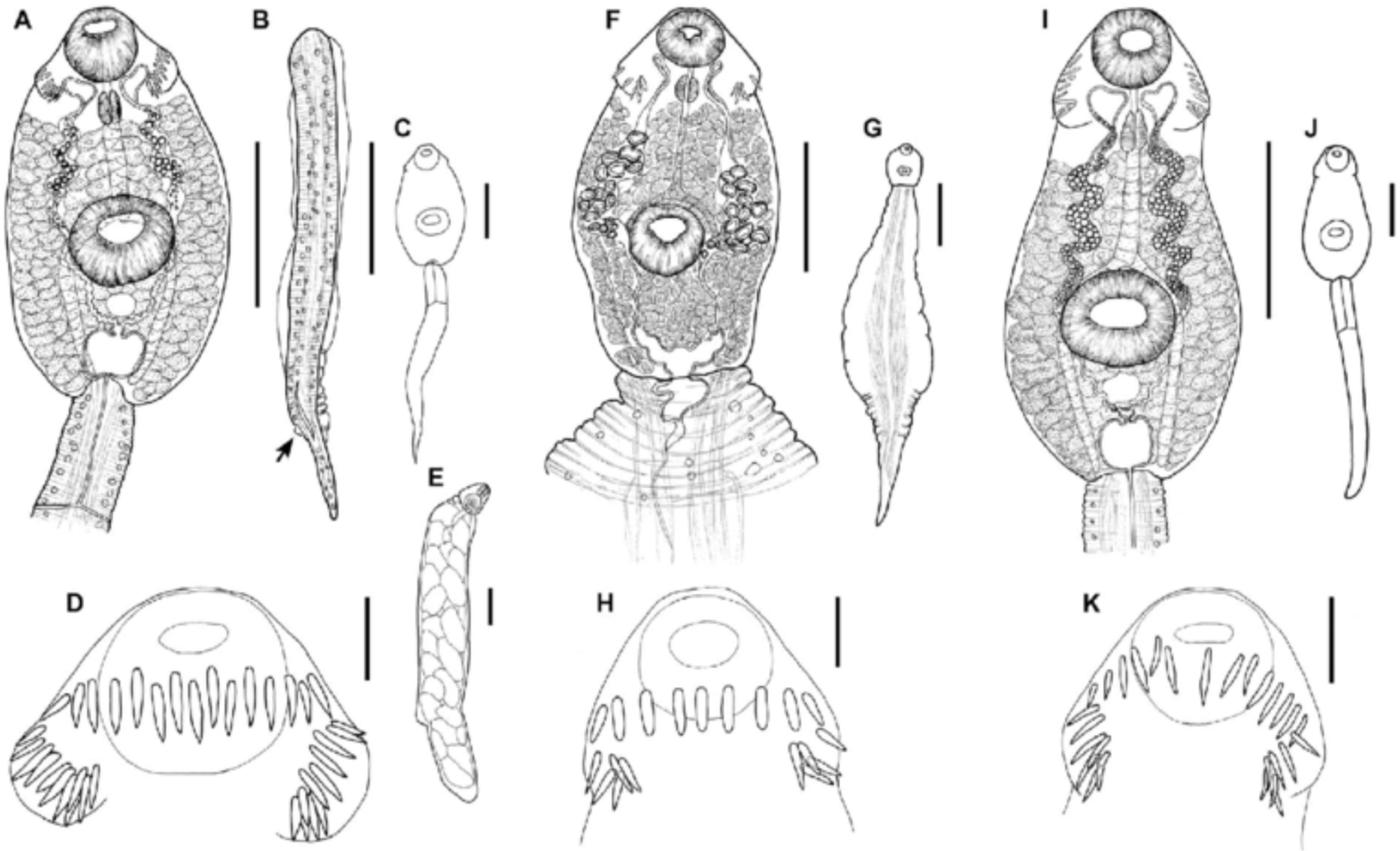


Echinostoma revolutum

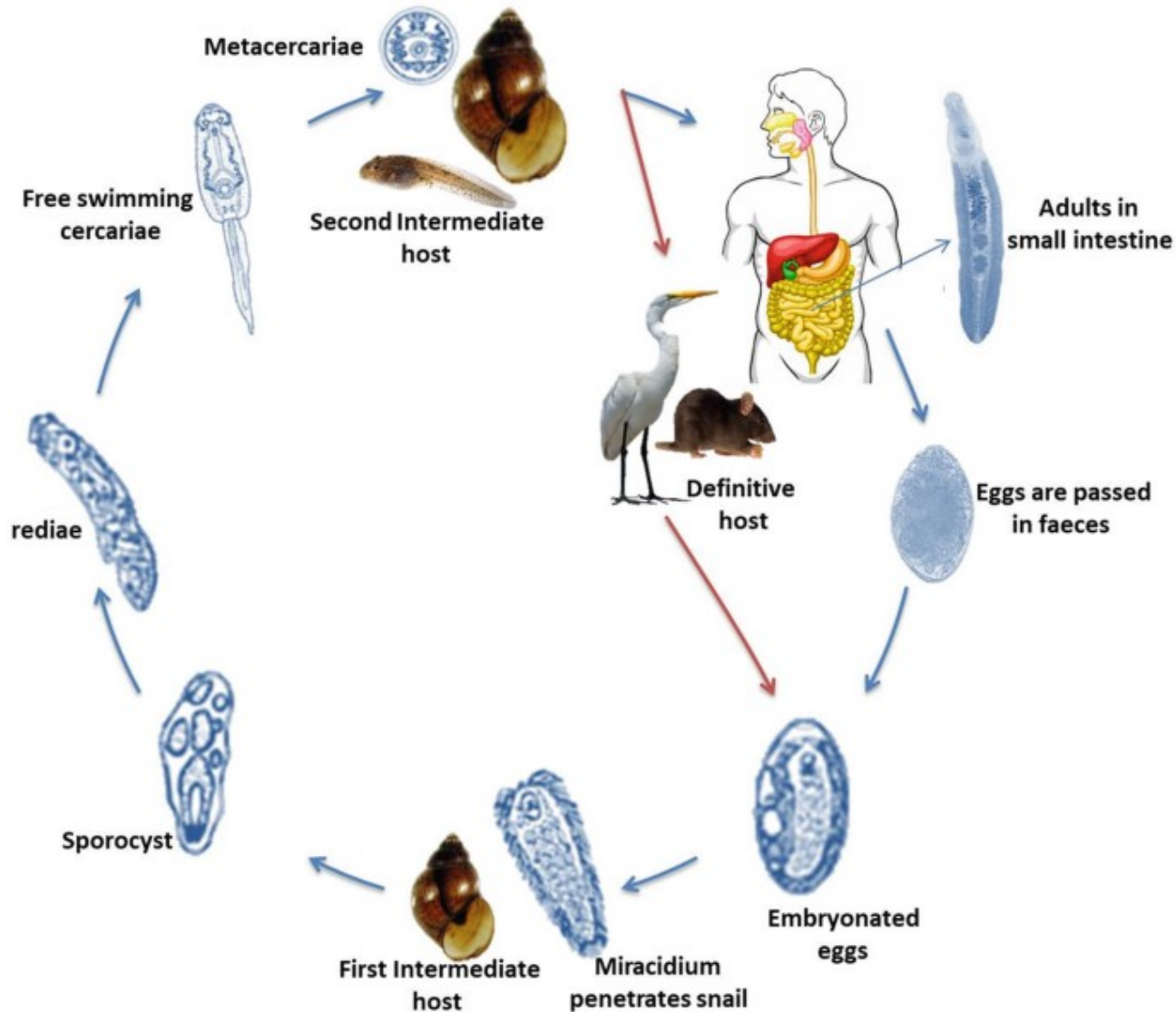


METACERCARIA
(X 100)

Echistomatidae - cerkarie

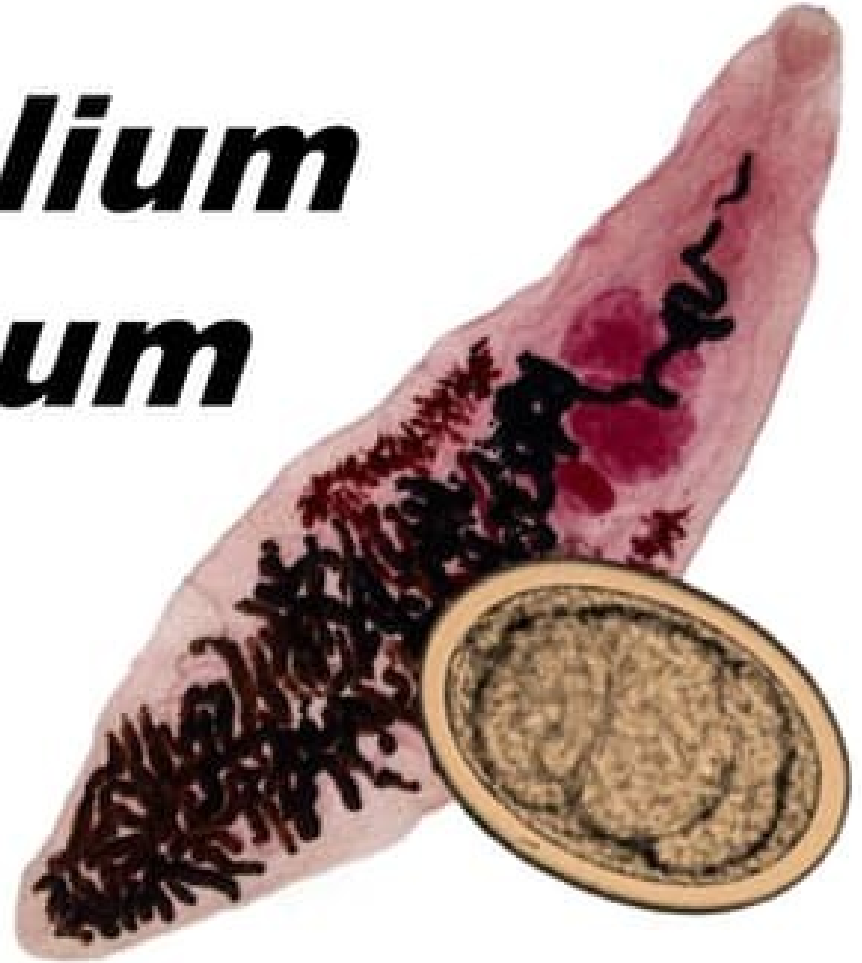

Životní cyklus *E. revolutum*



Dicrocoelidae

***Dicrocoelium
dendriticum***



Dicrocoelidae

Charakteristika:

- Cizopasníci jater a žlučových ptáků a savců
- Hospodářsky významné druhy
- Suchozemské prostředí

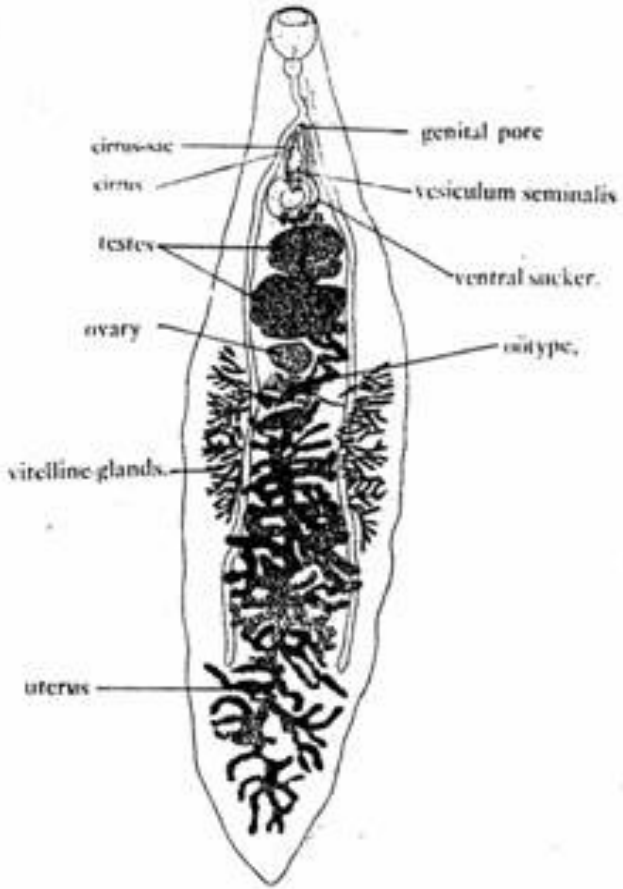
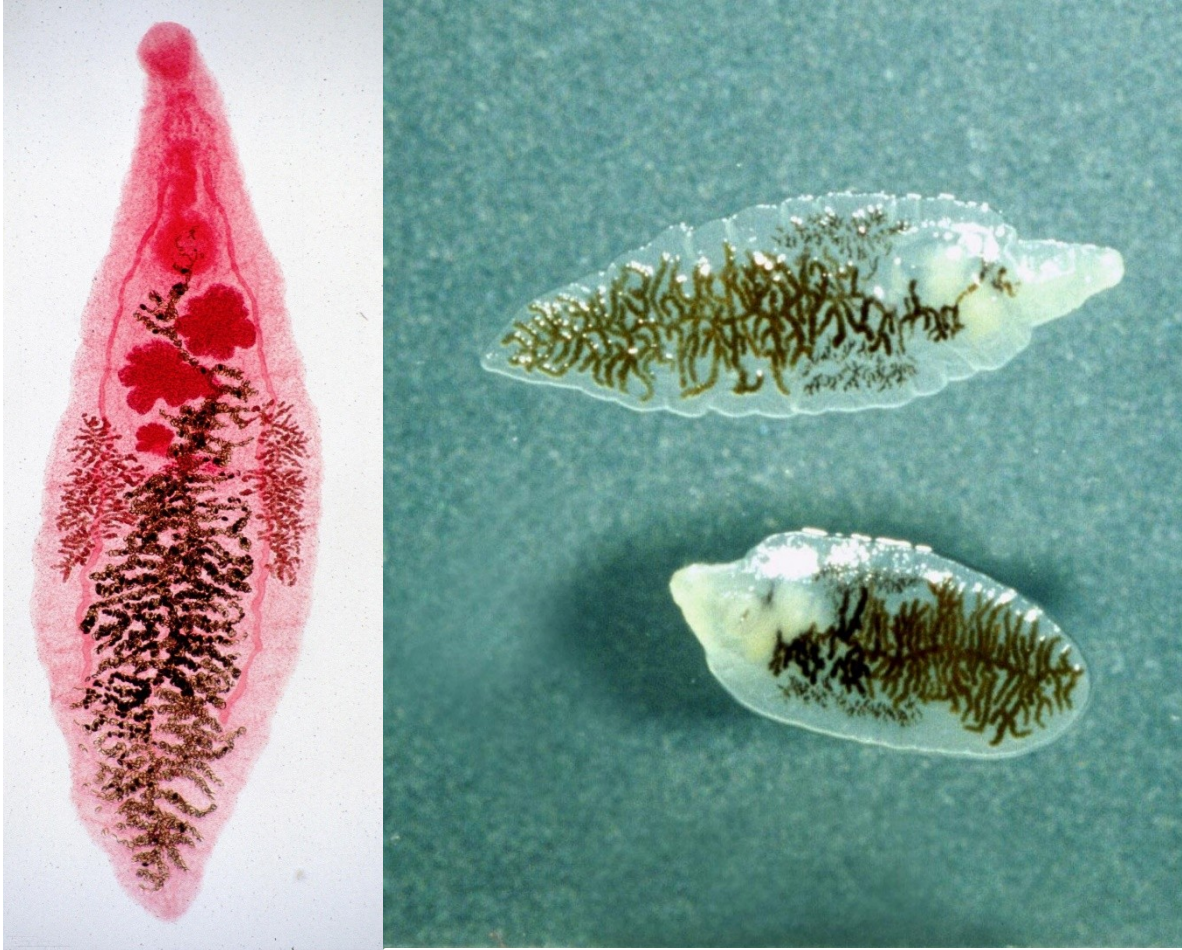Vývoj (*D. dentriticum*):

- 1. Mz – suchozemští plži (*Zebrina*, *Theba*, *Helicella*) – cercaria vitrina – se slizem v kuličkách na vegetaci
- 2. Mz – mravenci (*Formica*, *Tetramorium*)

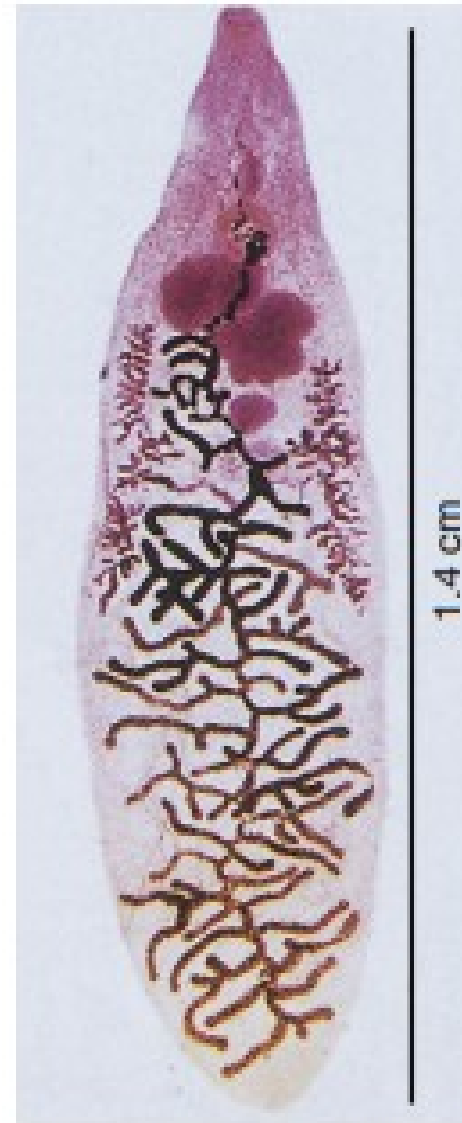
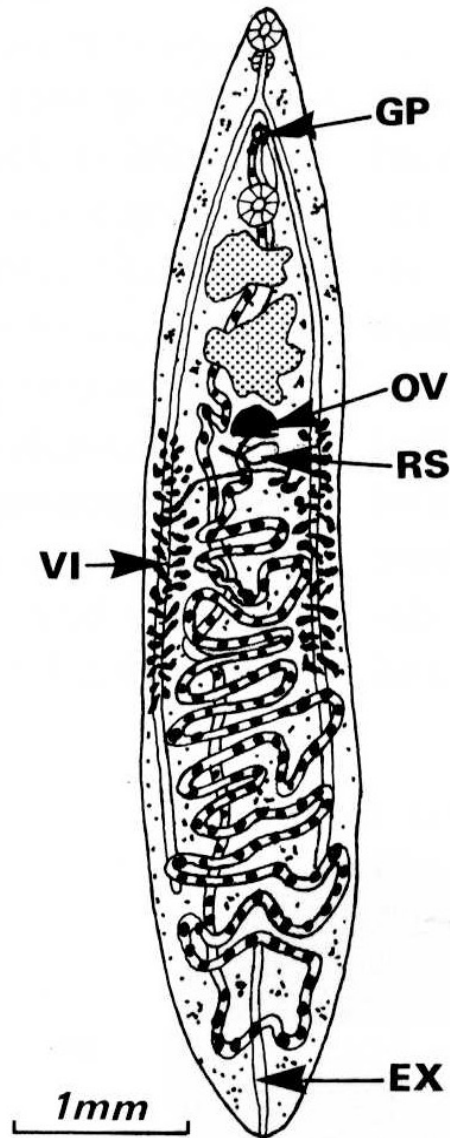
Zástupci:

- ***Dicrocoelium dentriticum*** (syn. *D. lanceolatum*)
- Přežvýkavci, divoká zvěř, člověk, záněty a rozšíření žlučových

Dicrocoelium dentiticum - morfologie

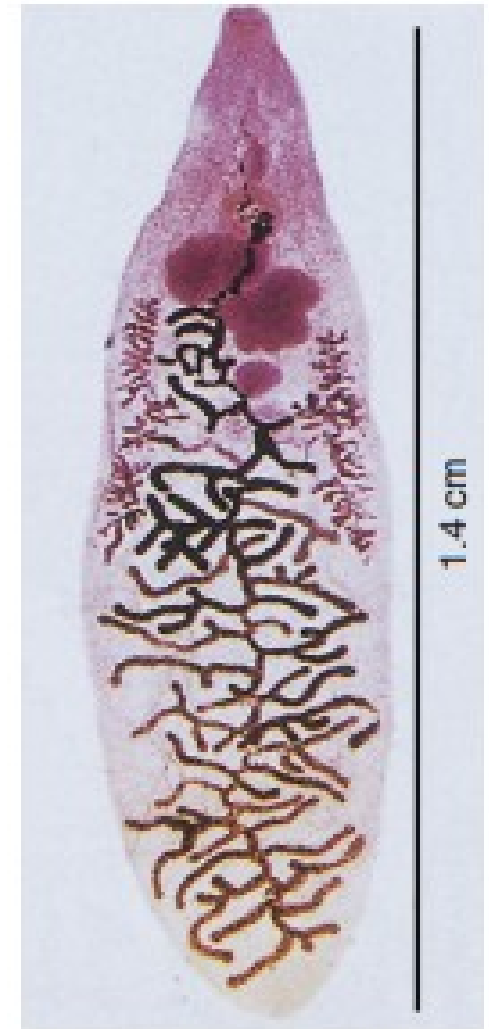
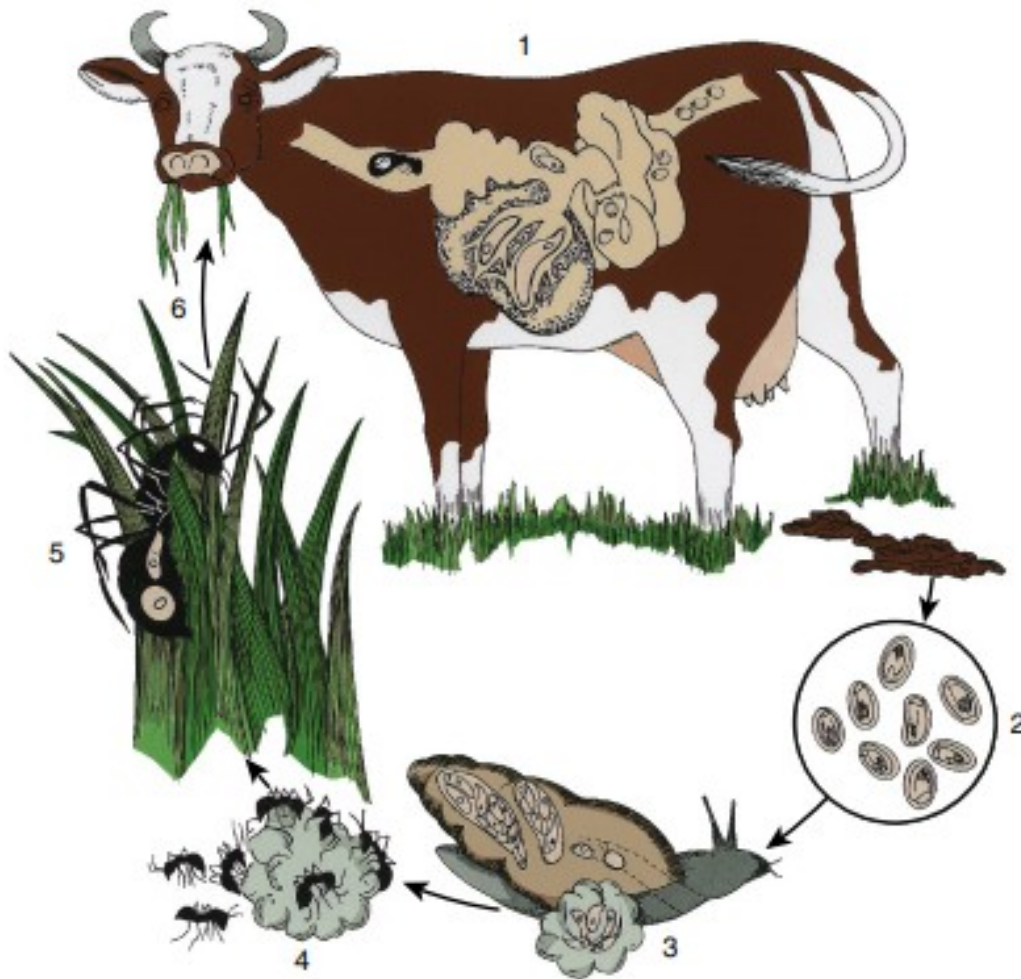


Dicrocoelium dentriticum

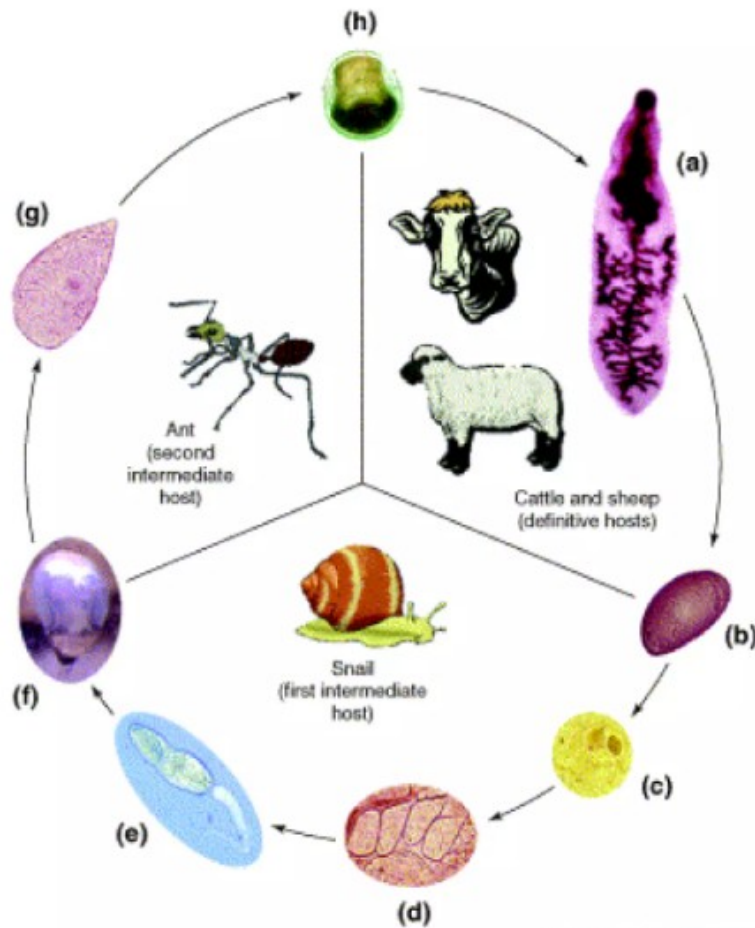


Dicrocoelium dentriticum

Dicrocoeliasis

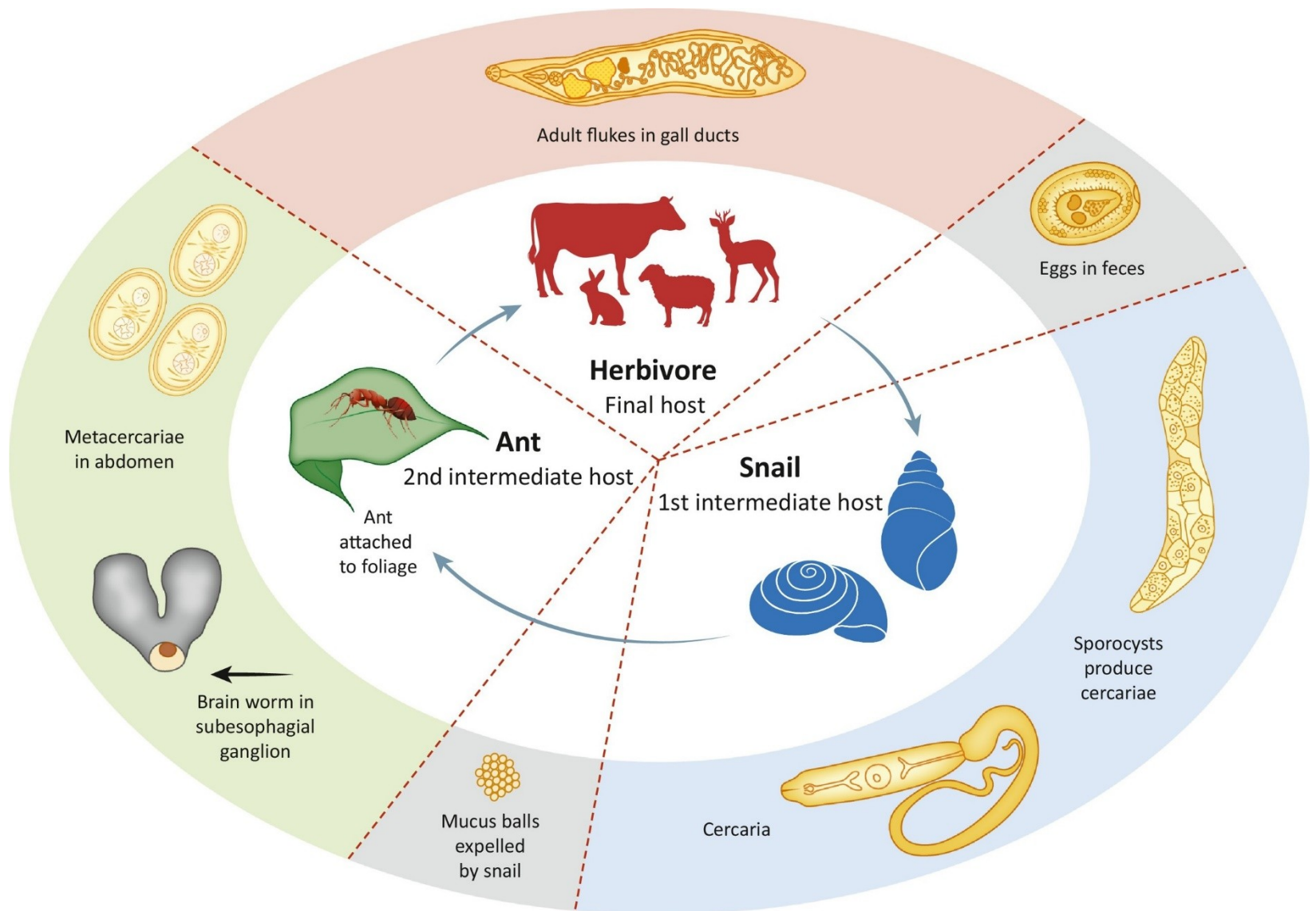


Vývojové fáze *D. dendriticum*



- a.) Adult
- b.) Egg
- c.) Miracidium
- d.) Daughter sporocyst
- e.) Mature Cercariae
- f.) slime-balls
- g-h.) transformation to metacercariae

Životní cyklus *D. dendriticum*



Manipulace chováním mezihostitele



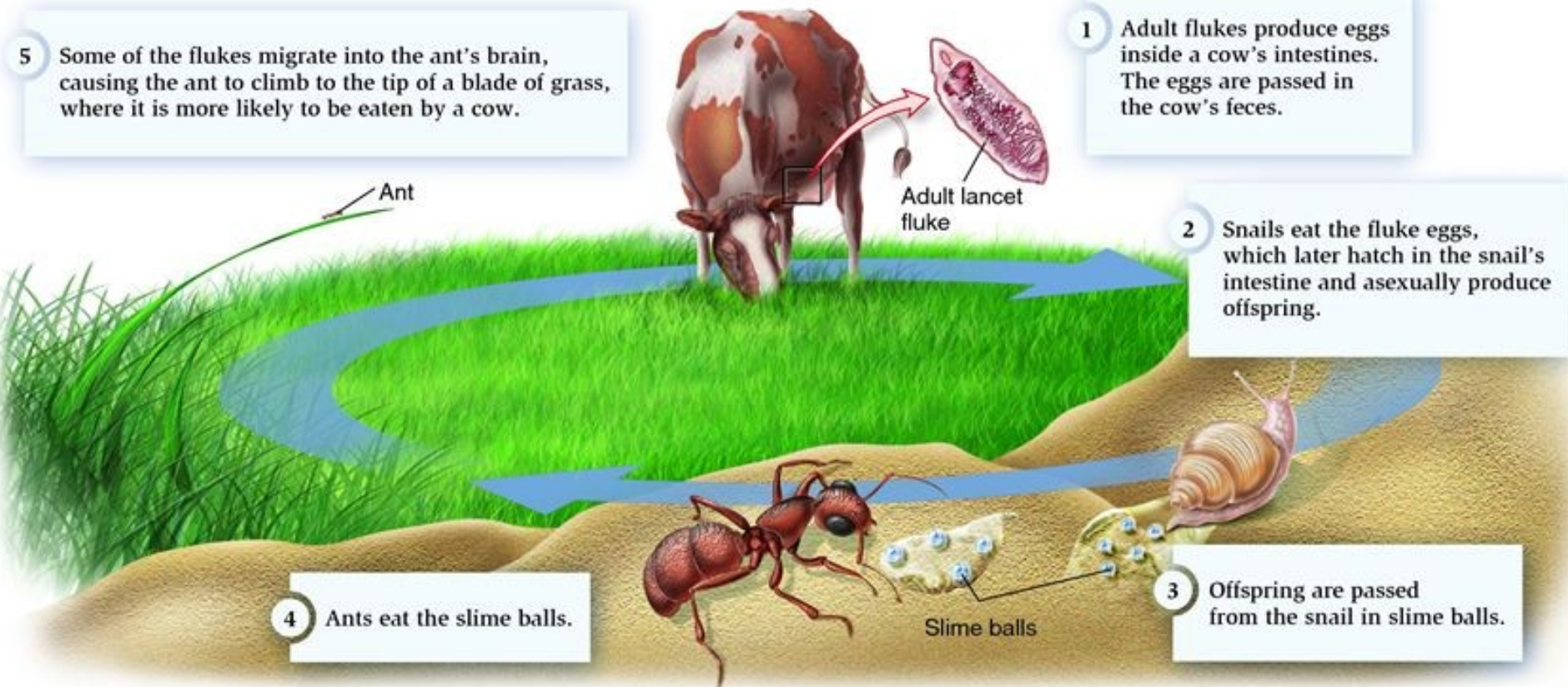
1 Adult flukes produce eggs inside a cow's intestines. The eggs are passed in the cow's feces.

2 Snails eat the fluke eggs, which later hatch in the snail's intestine and asexually produce offspring.

3 Offspring are passed from the snail in slime balls.

4 Ants eat the slime balls.

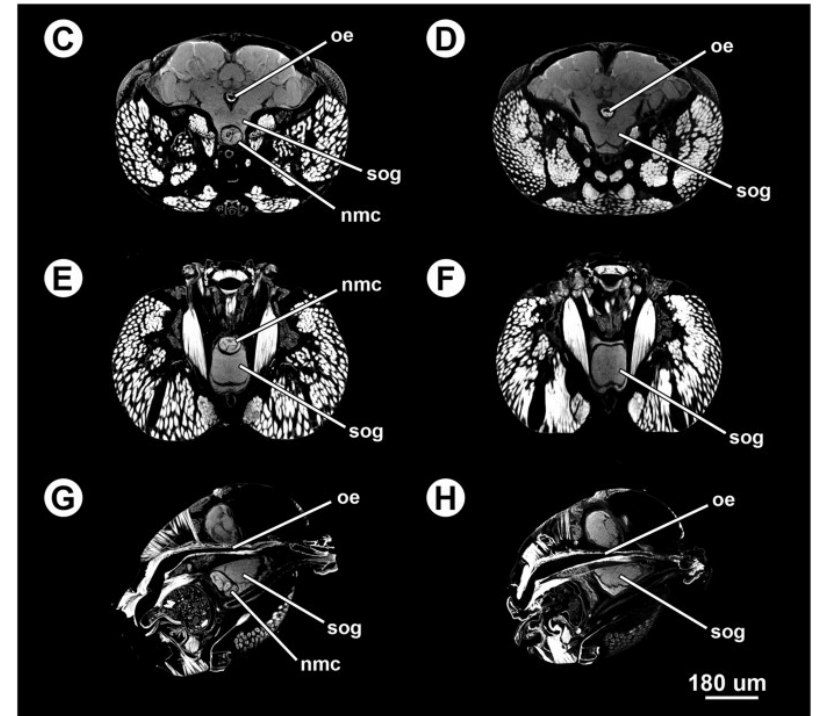
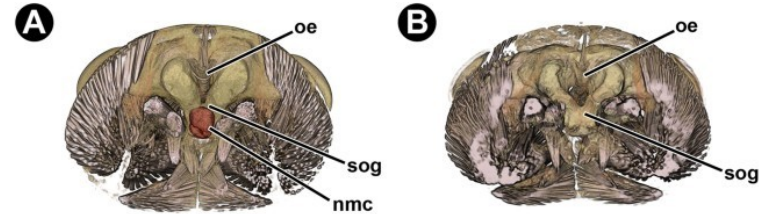
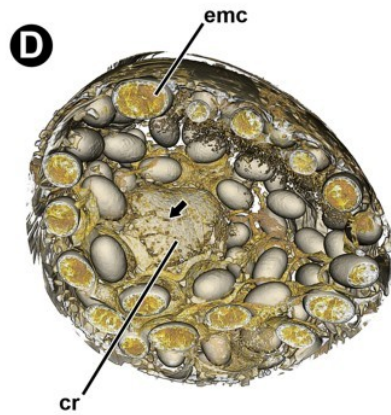
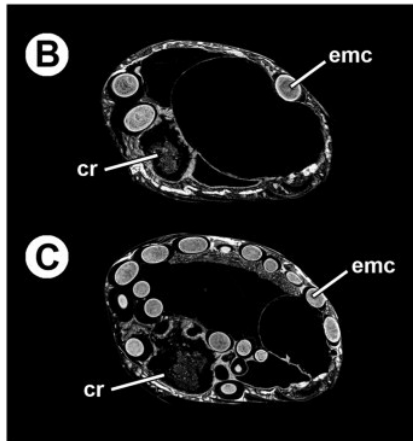
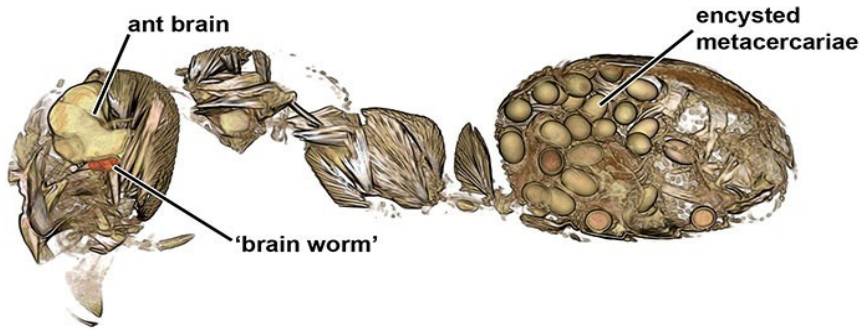5 Some of the flukes migrate into the ant's brain, causing the ant to climb to the tip of a blade of grass, where it is more likely to be eaten by a cow.



Manipulace chováním druhého mezihostitele - mravence




Metacerkarie v mozku mravence



FASCIOLIASIS



watercress



Fasciolidae I

Charakteristika:

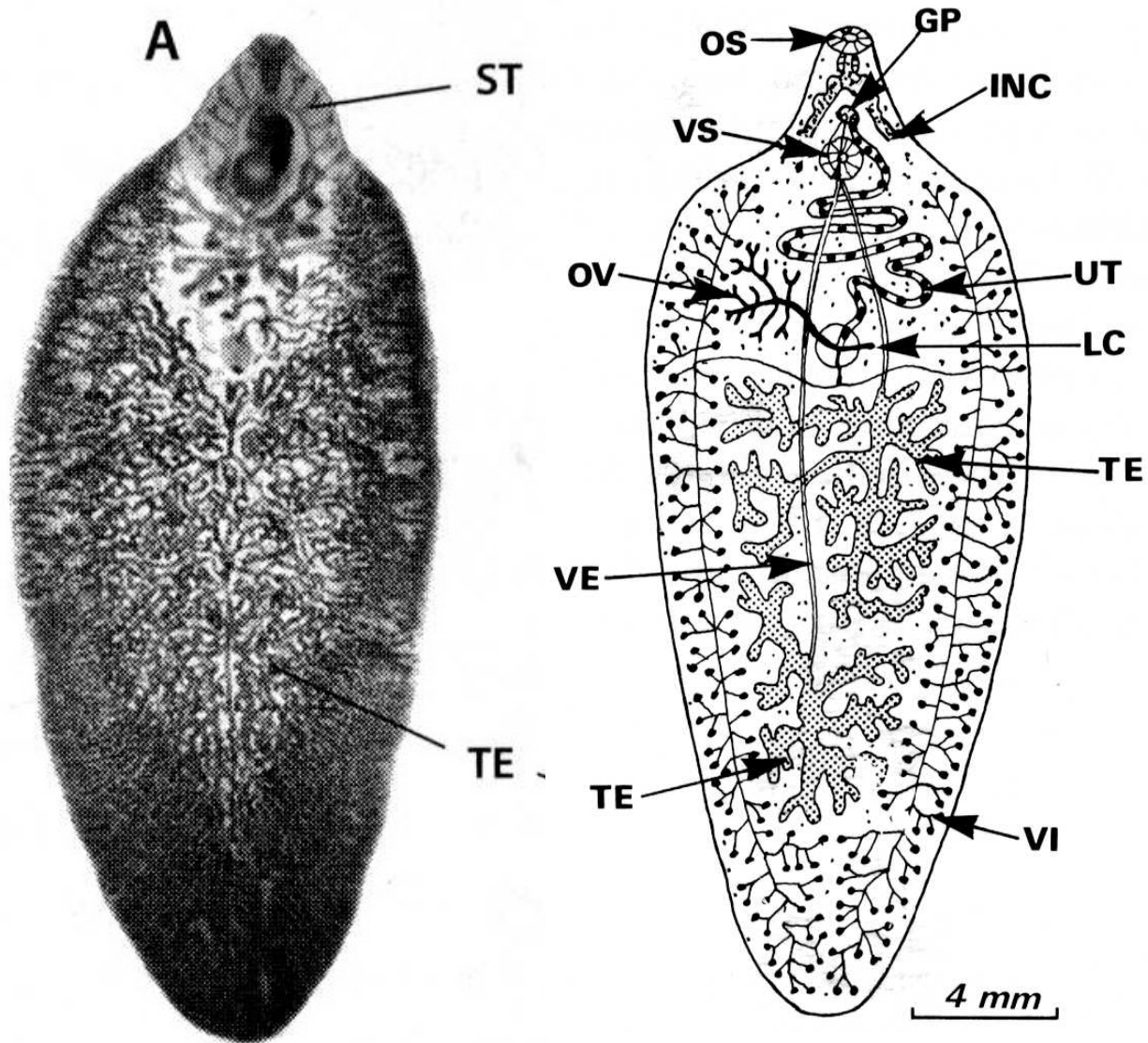
- Jaterní (Fasciolinae) nebo střevní (Fasciolopsinae) motolice
- Významní cizopasníci lidí, hospodářských zvířat i zvěře
- Velké tělo listovitého (kopinatého) tvaru
- Keříčková varlata i vaječník
- Střevo bohatě rozvětvené (pouze Fasciolinae)

Vývoj: 1. Mz – plži (Lymnaeidae, Planorbidae) – gymnocephalní cercárie

- Metacercárie (adoleskárie) na vegetaci

Fasciola hepatica

(motolice jaterní)



Historie studia motolice *Fasciola hepatica*

- 1379: „*Fasciola hepatica*“ – nález parazita v játrech ovce (**Jean de Brie**) – Francie (jaterní hniloba)
- 1688: **Francesco Redi** popsal skutečnost, že helminti kladou vajíčka (různé druhy včetně FH)
- 1698 **Govert Bidloo** - stejný druh motolice objevil nejen u ovcí, ale i skotu, jelenů a člověk
- 1700 **Anthony van Leeuwenhoek** - pokračoval ve výzkumech, domníval se, že zvířata se nakazí červy pitím vody
- 1758: *Fasciola hepatica* (**Linné**)
- 1758: **Johann Swammerdam** – objev neznámých organismů v plži)
- 1770: **Otto Müller** – objev plovoucích organismů ve vodě, které pojmenoval jako cercárie
- 1807–1819: **Christian Nietzsche** -referoval o encystaci cercarií na vegetaci
- 1816: Vztah: cercárie – motolice (**Nietzsch**)
- 1837: **Mehlis** - pozoroval líhnutí miracidí z vajíček motolic a domníval se, že důvodem jejich intenzivního pohybu ve vodě je snaha najít nějakého hostitele.
- 1881: **Algeron Thomas** a **Rudolfem Leuckart** (nezávisle a současně) - podán přelomový důkaz, že vývojový cyklus motolice jaterní probíhá přes plže *Galba truncatula*.
- 1914: **Sinitsin** - při svých experimentech s králíky popsal způsob migrace motolic ze střev do jater definitivního hostitele.

Celkem 535 let – plné pochopení životního cyklu parazita !

Fasciolidae

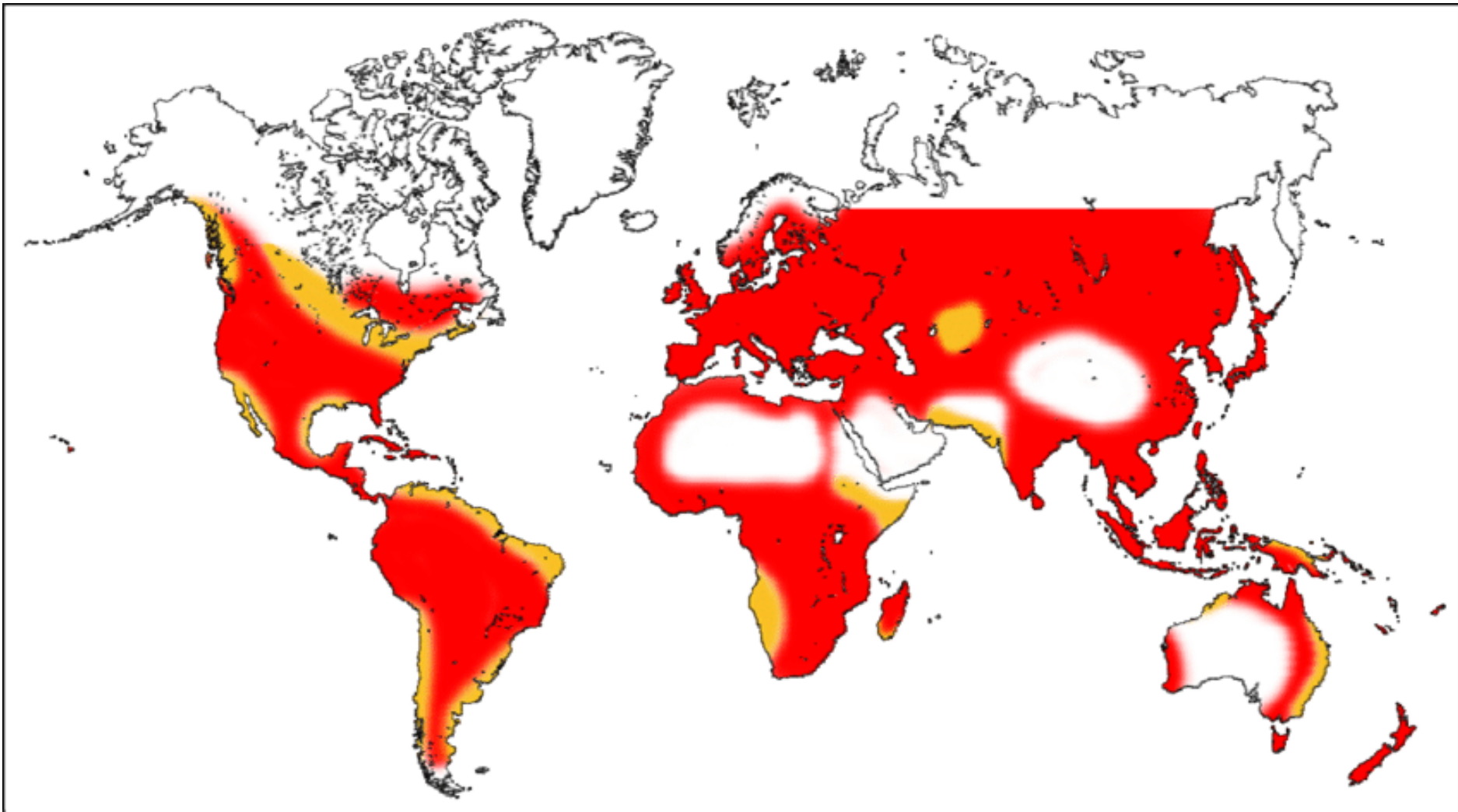


Fasciolidae II

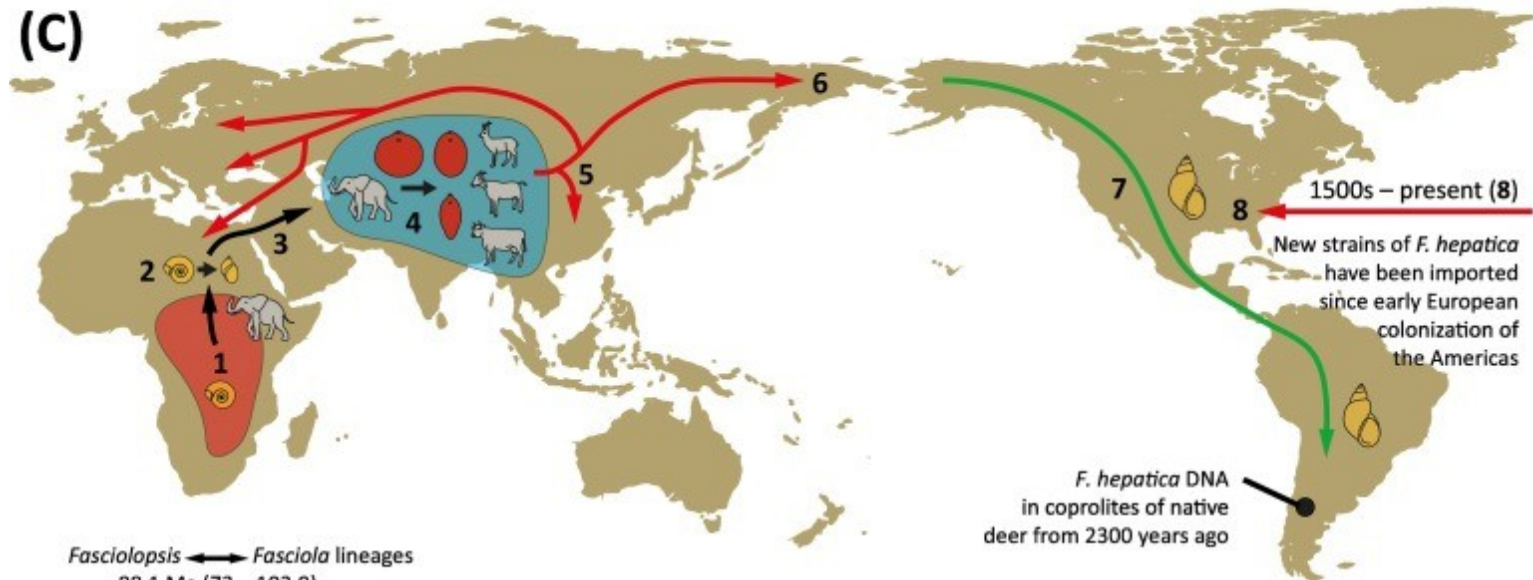
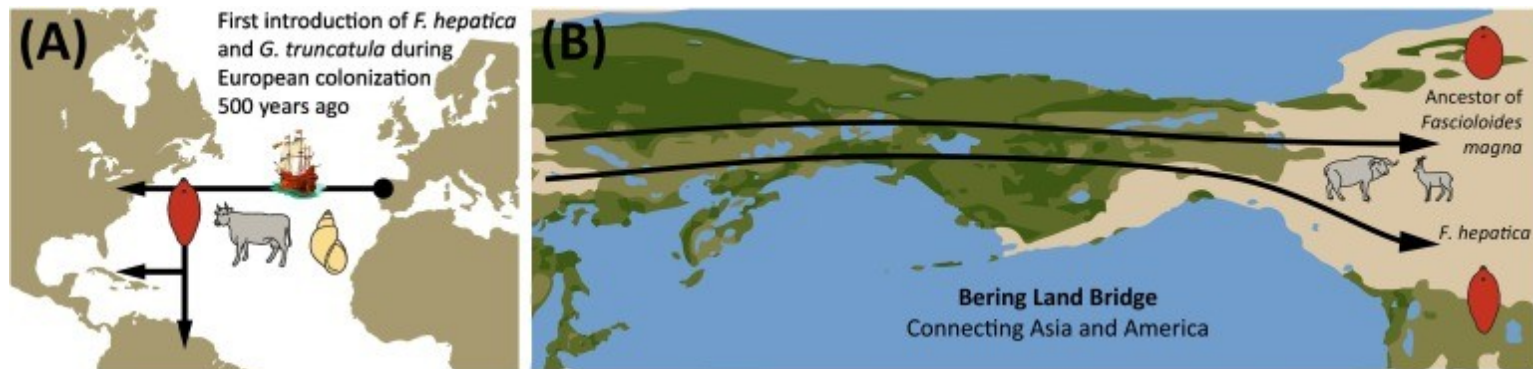
Zástupci:

- **Fasciola hepatica**
 - Ovce, skot, jeleni, člověk
 - Kosmopolitní rozšíření
 - Asi 2 mil vajíček za život
 - Mz Lymnaea (= Galba) truncatula (bažinný druh), Lymnaea, Physa,
 - Migrace v definitivním hostiteli (bránice, játra)
- **Fasciola gigantica** – až 8 cm, Bulinus truncatus

Rozšíření *Fasciola hepatica*

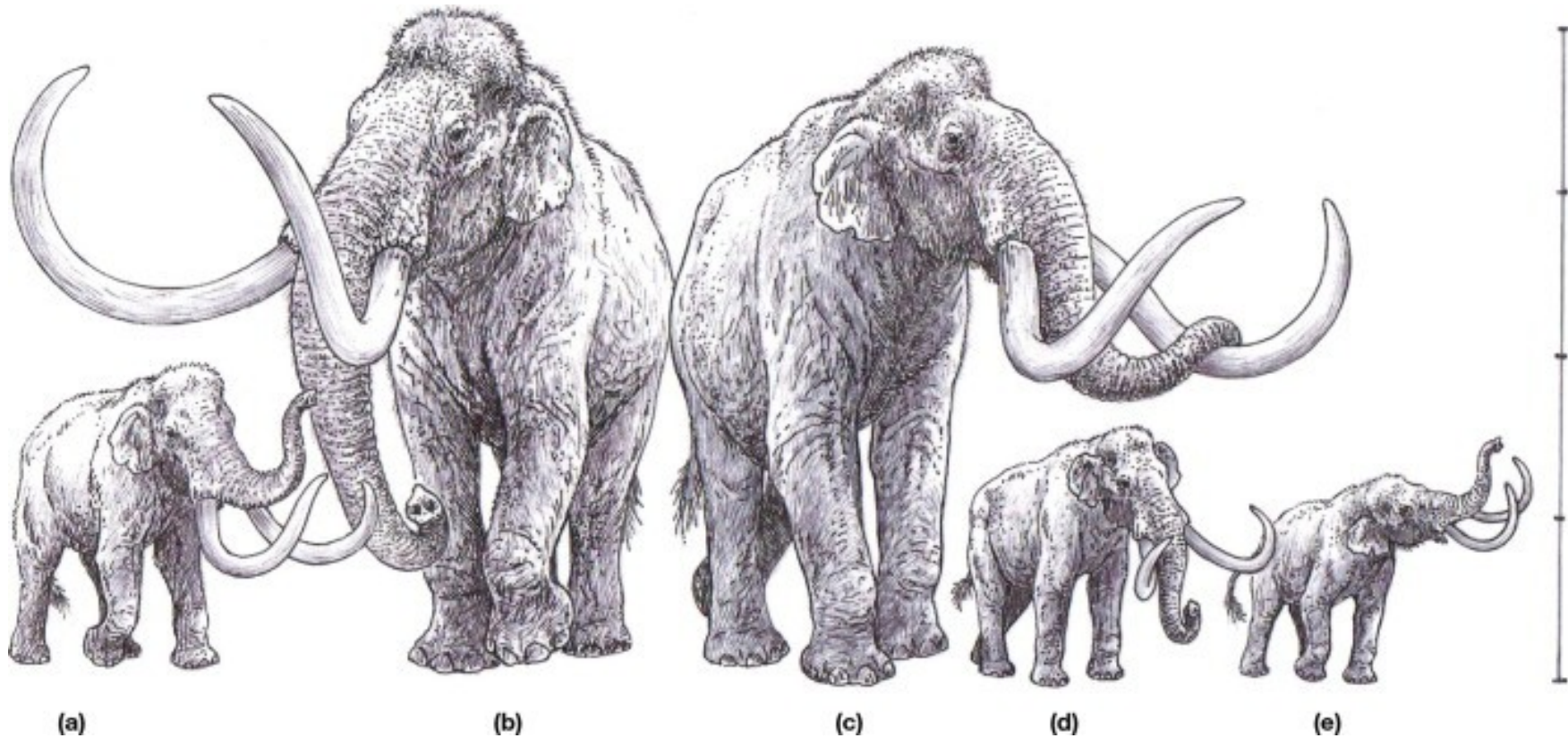


Zavlečení *Fasciola hepatica* do Ameriky

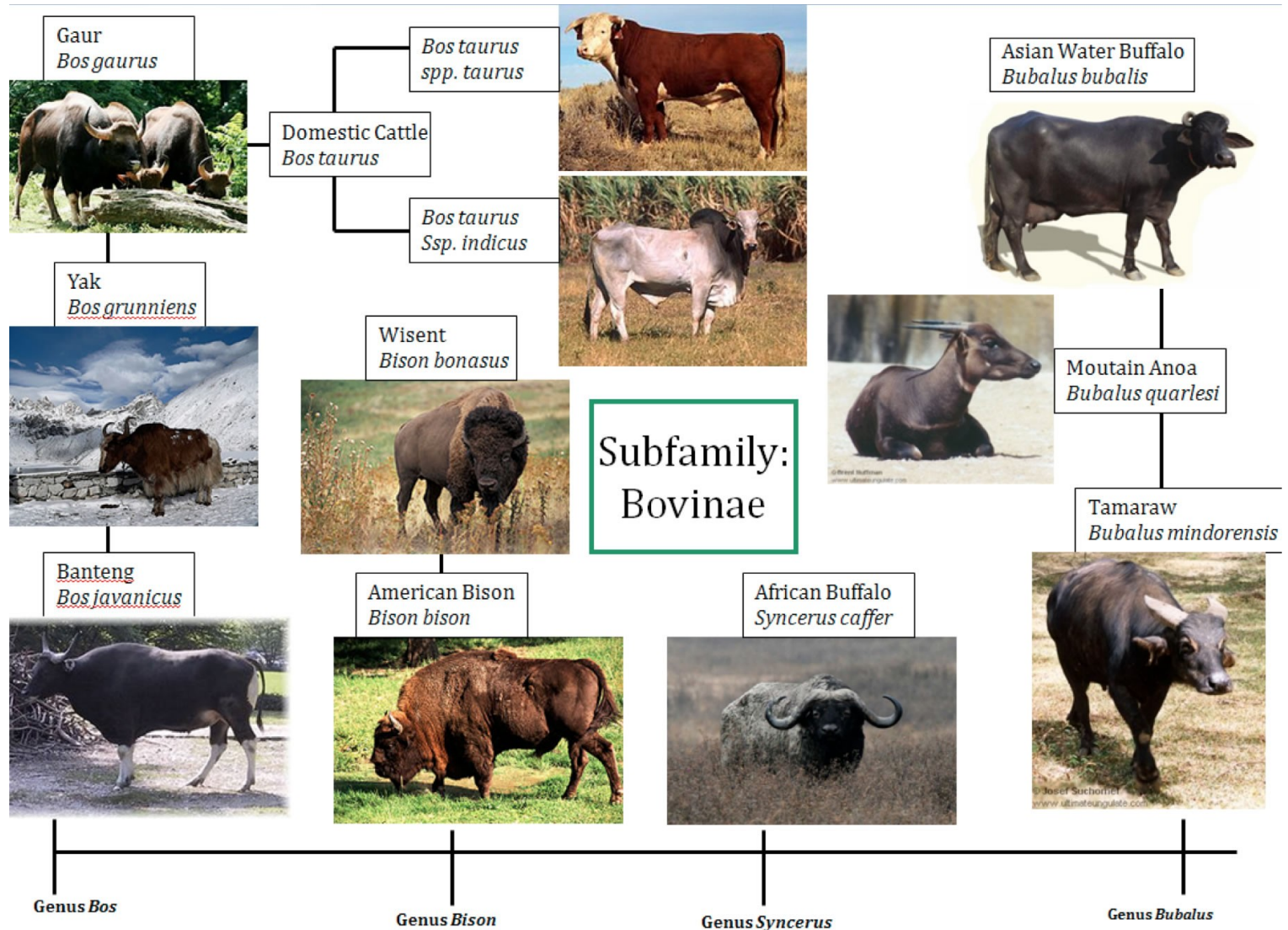


Before 100 Ma (1)	65 – 55.9 Ma (2)	18.5 Ma (3)	10 Ma (4)	5.3 Ma (7.2 – 3.4) (5)	5 – 2 Ma (6)	2 – 0 Ma (7)
Origin of basal fasciolids in African proboscideans	Snail host switches from Planorbidae to Lymnaeidae	Migration out of Africa of ancient proboscideans	Mammal host switches in Asia matching bovid diversification	<i>F. hepatica</i> splits from <i>F. gigantica</i> and spreads with bovid migration with later reintroduction of both species into Africa	Infected bovids cross the Bering Land Bridge into the Americas	<i>F. hepatica</i> adapts to local lymnaeid snails and spreads during the GABI events through several mammal species

Chobotnatci – prapůvodní hostitelé fasciolidních motolic



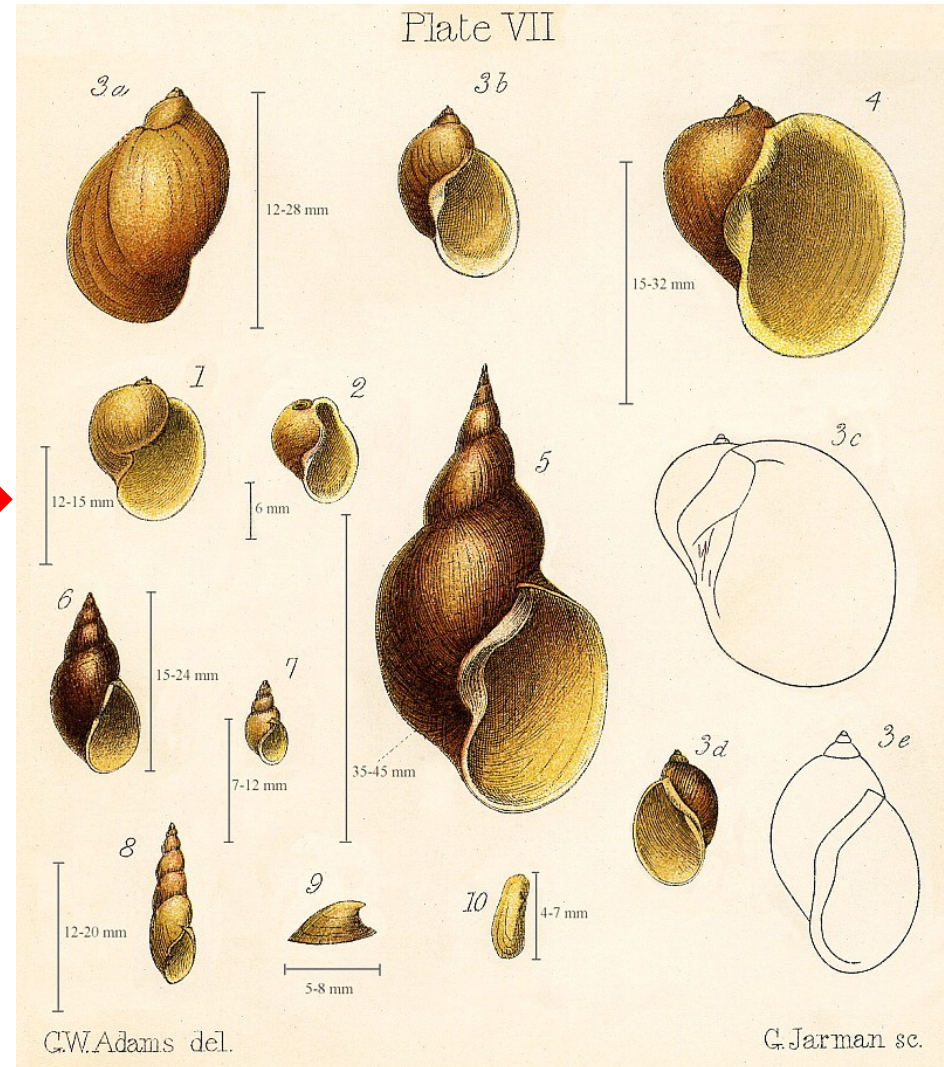

Spolu s migrací Bovidae rozšíření z Afriky



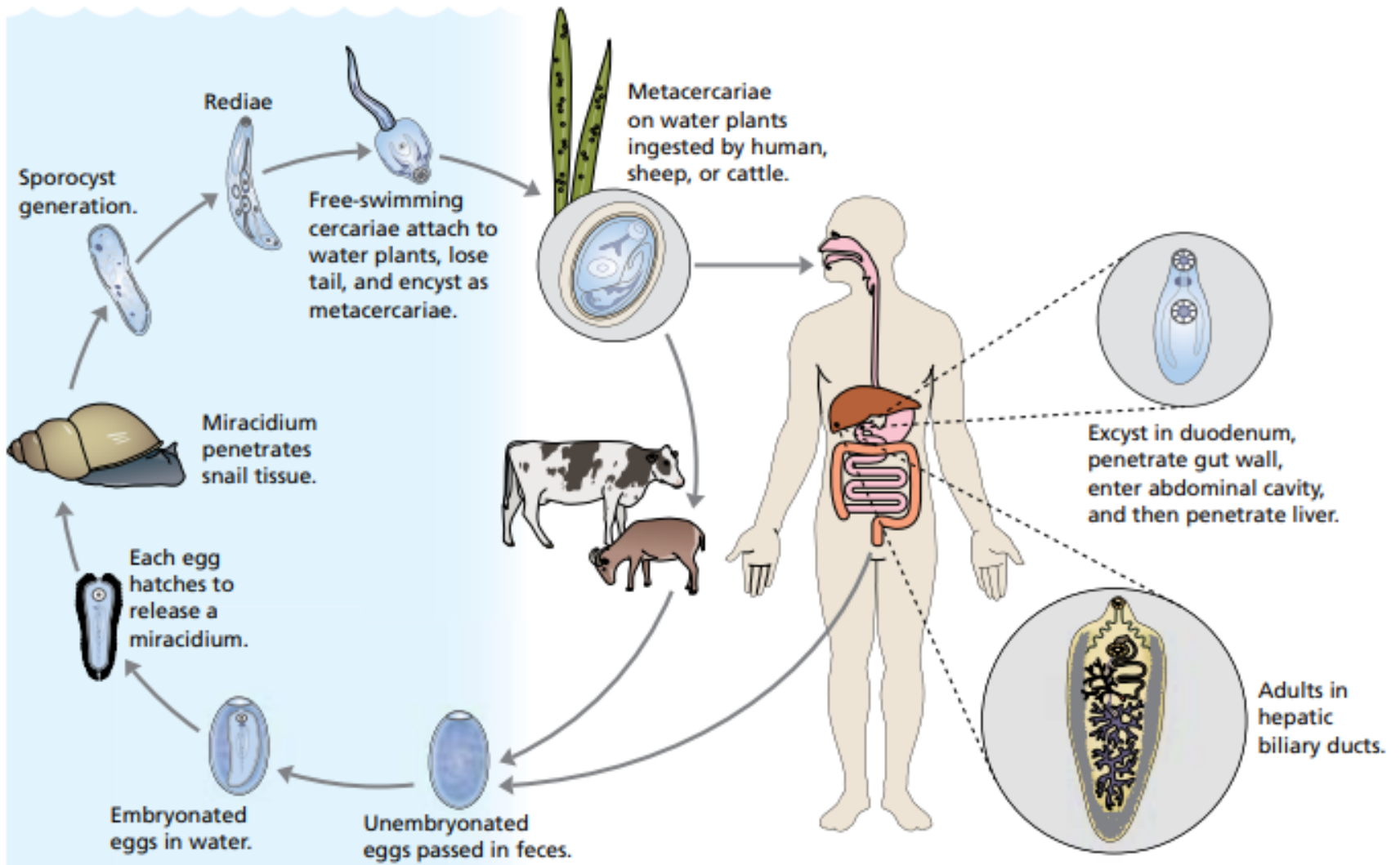
Člověk - náhodný hostitel



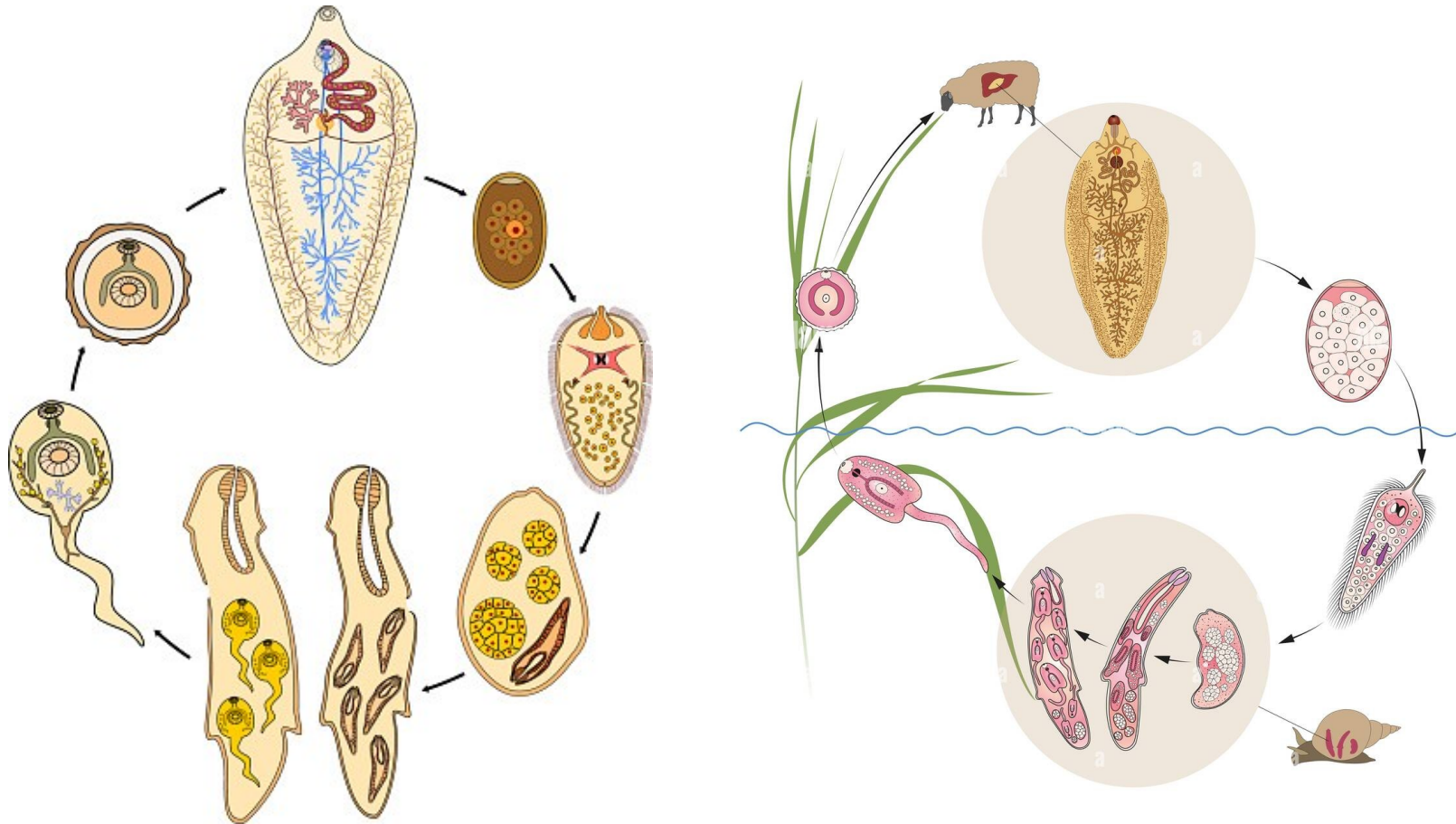
Paralelní přeskok z Planorbidae na Lymnaeidae



Fasciola hepatica

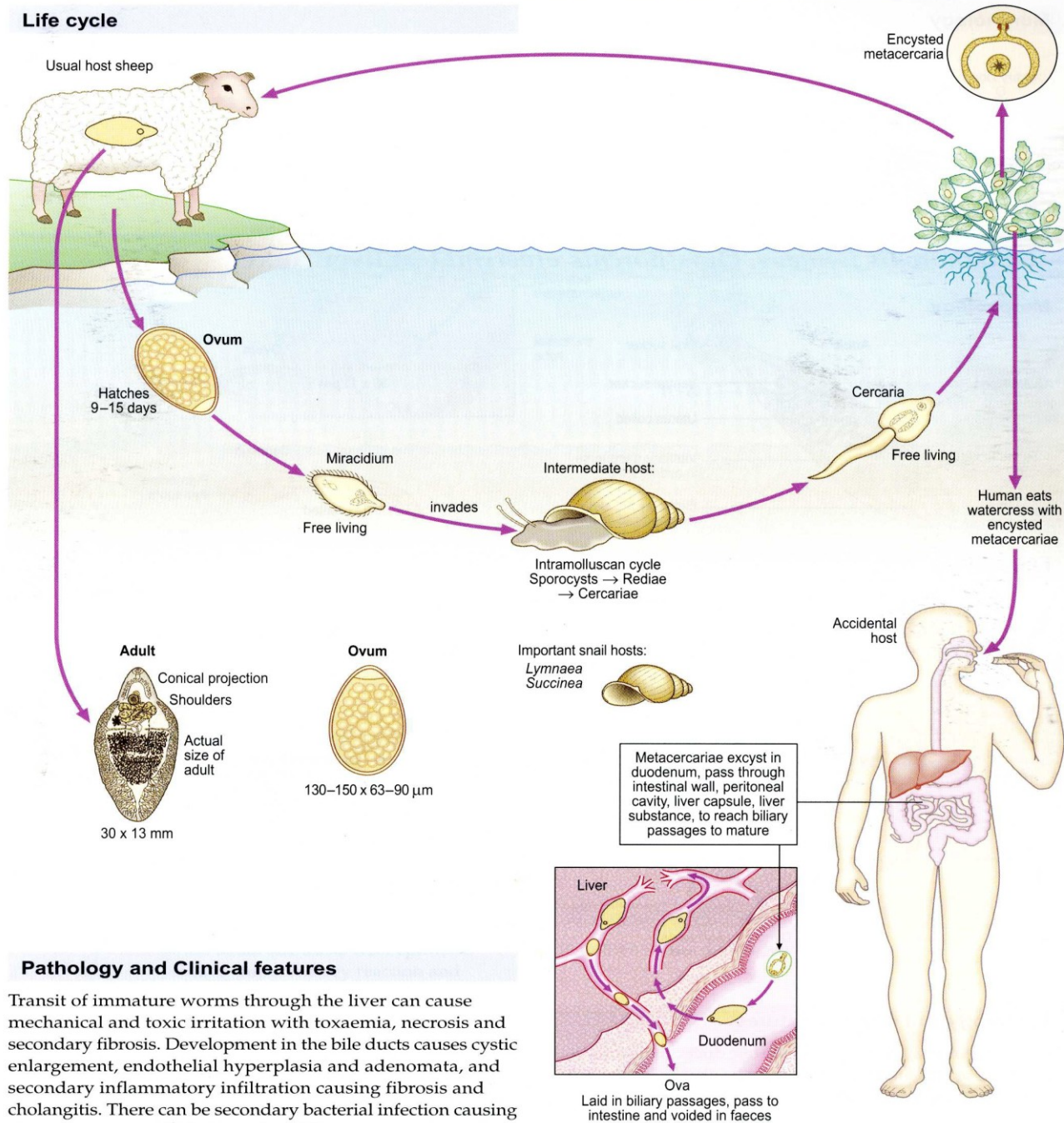


Vývojová stádia *F. hepatica*



Fasciola hepatica (sheep liver fluke)

Life cycle



Pathology and Clinical features

Transit of immature worms through the liver can cause mechanical and toxic irritation with toxæmia, necrosis and secondary fibrosis. Development in the bile ducts causes cystic enlargement, endothelial hyperplasia and adenomata, and secondary inflammatory infiltration causing fibrosis and cholangitis. There can be secondary bacterial infection causing abscesses. Eosinophilia is marked. Worms can appear

Experimentální vývoj *Fasciola gigantica*

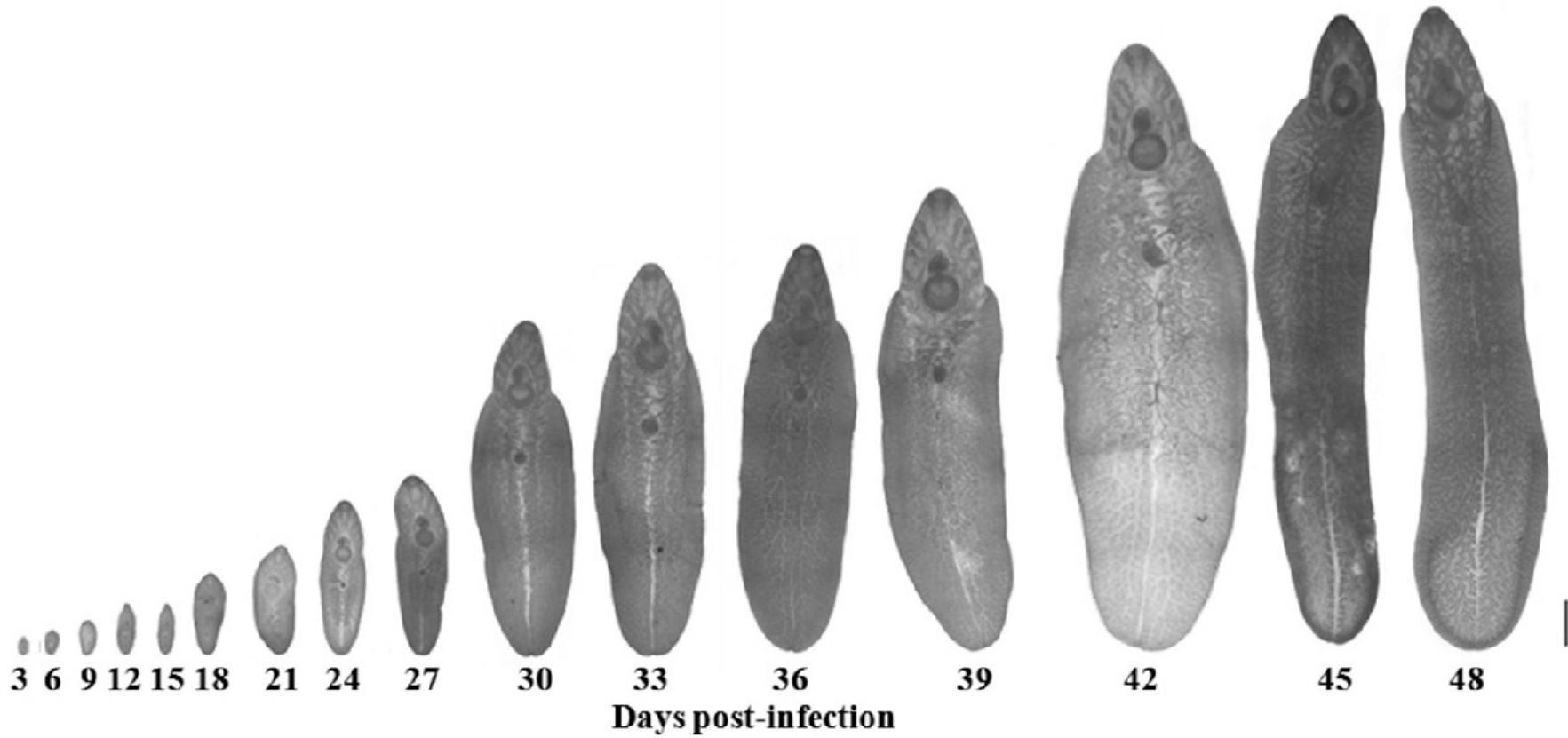
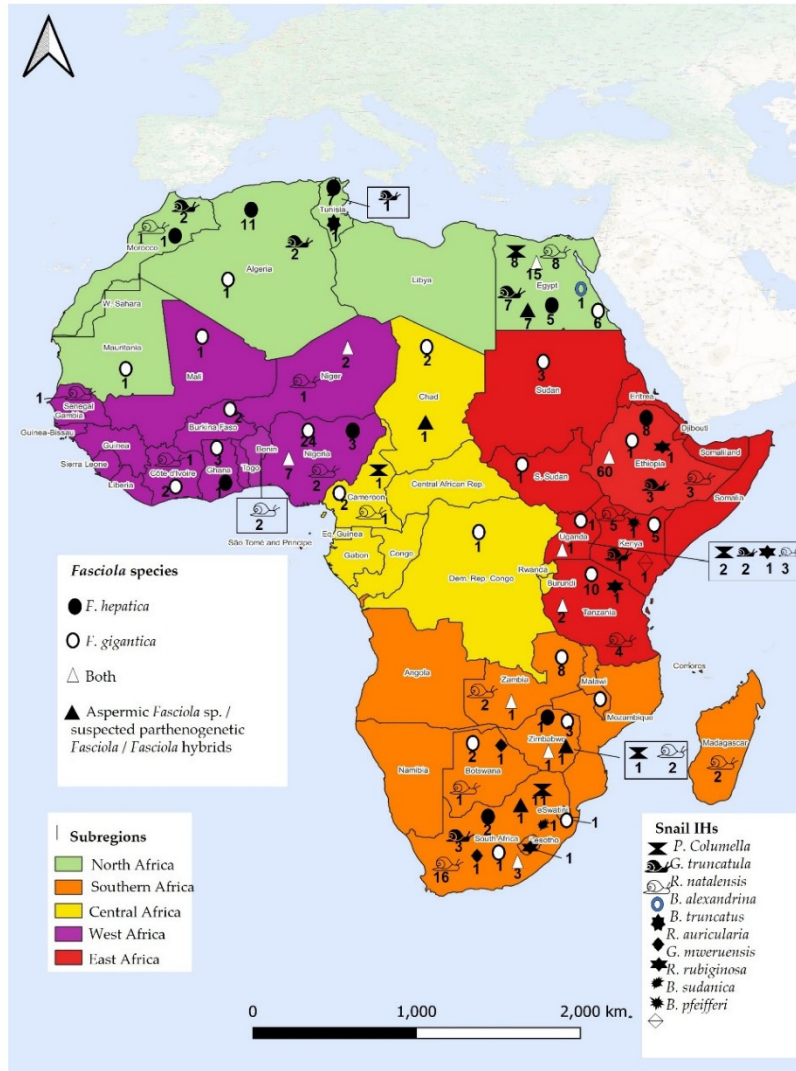


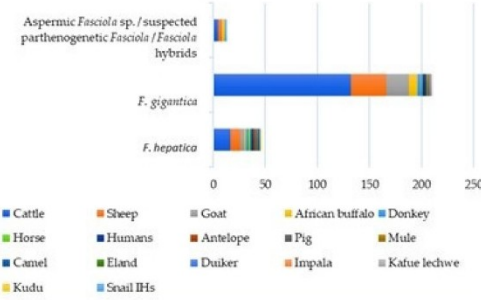
FIG. 5. Development of *F. gigantica* in the intermediate host, *B. pinnatus*, after infection with cercariae.

Fasciola hepatica a F. gigantica v Africe

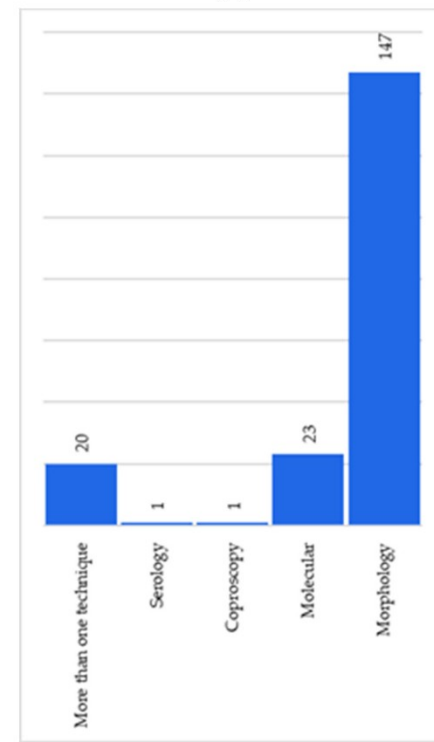
Potenciál pro hybridizaci



(a)

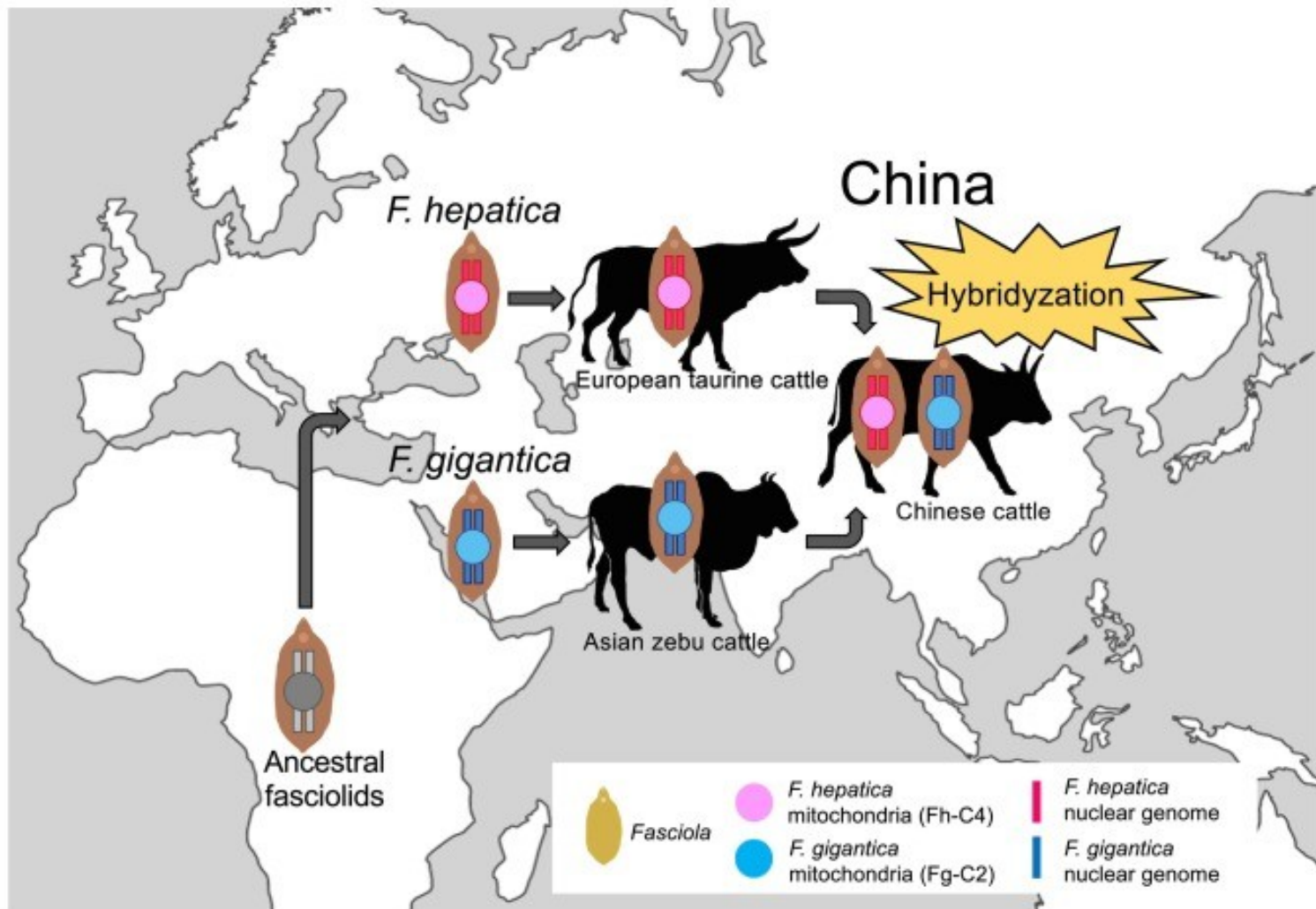


(b)

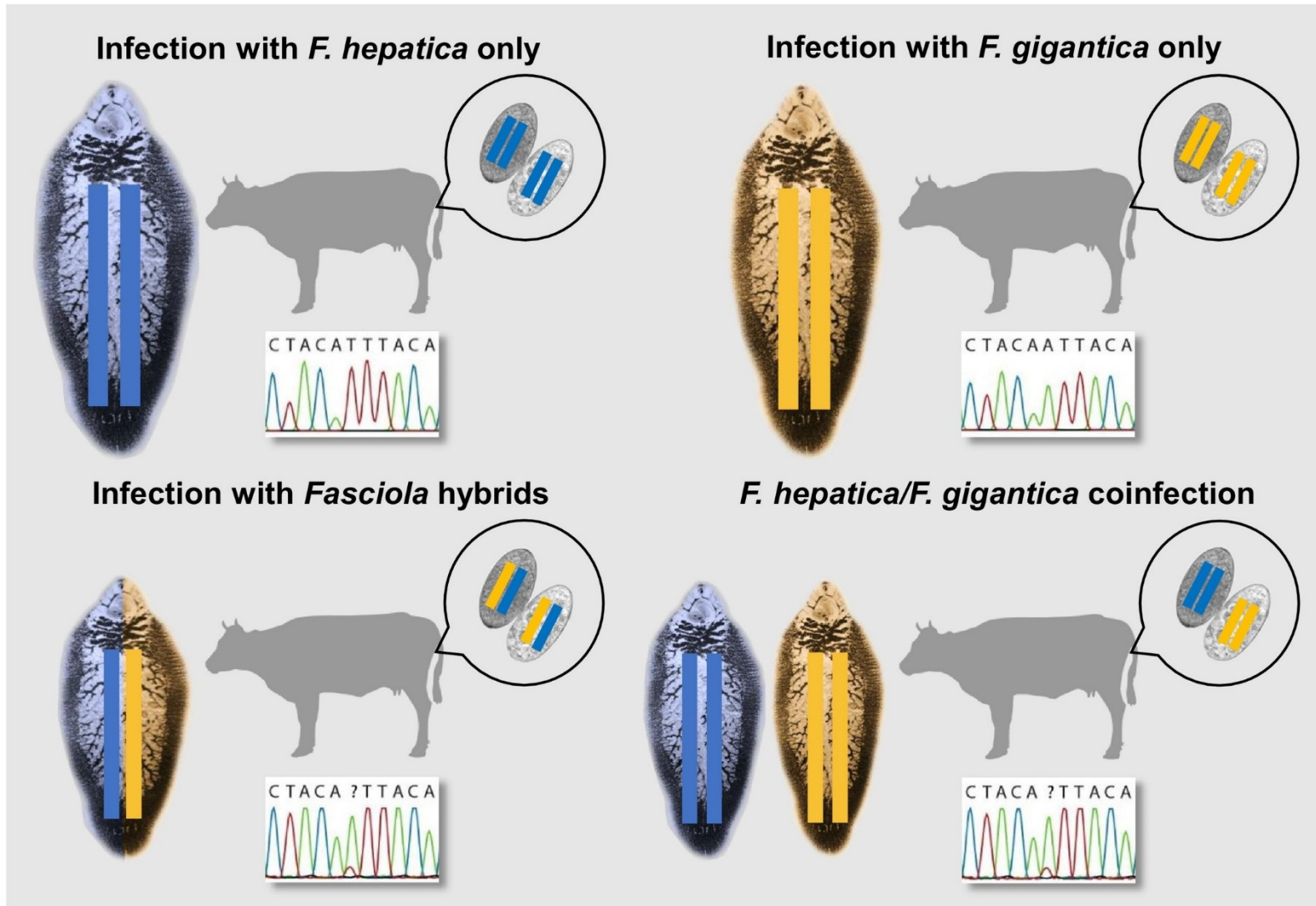


(c)

Patogenní původci fasciolosy v Asii



Fasciola hepatica versus Fasciola magna



Fasciola hepatica

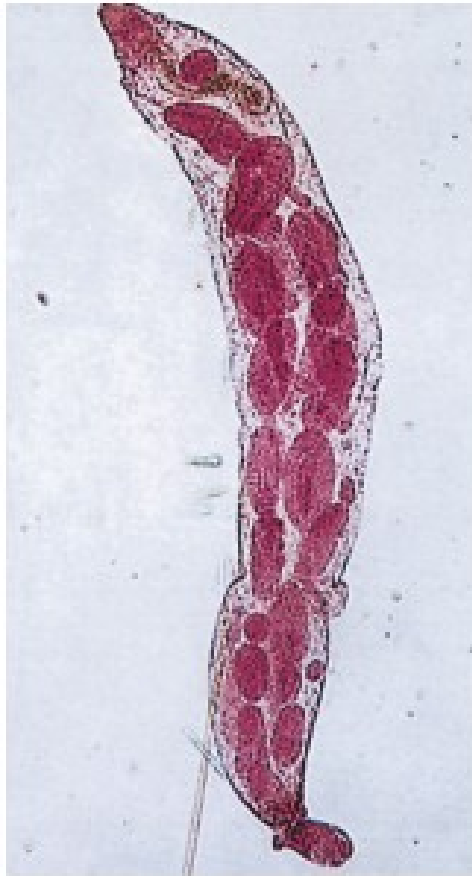

Fig. 3.221 Redia from intermediate host. In the snail host, redia develop from a sporocyst to become a cercaria. (x 30.)

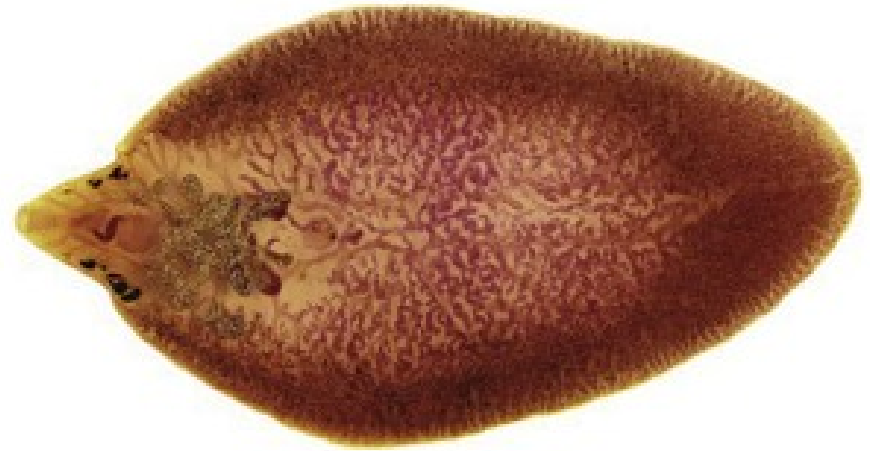


Fig. 3.224 Adult *Fasciola hepatica*.

Adult flukes of *F. hepatica* measure up to 30 mm in length in contrast to *F. gigantica* which can measure 75 mm. Note the cone-shaped anterior end which gives the parasite a leaf-like shape. (From Fürst, T., Duthaler, U., Sripa, B., et al. Trematode infections. Infectious Disease Clinics of North America, 2012-06-01, Volume 26, Issue 2, Pages 399-419, Figure 3, Panel C.)

Fasciola hepatica

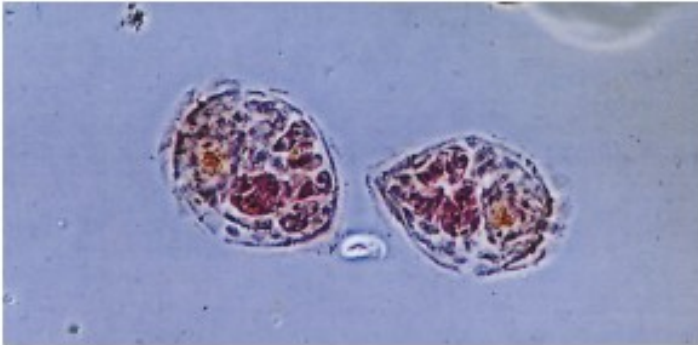


Fig. 3.219 Miracidia of *Fasciola hepatica*. Motile miracidia hatch from eggs passed in faeces and infect snails of the genus *Galba*. (x 225.)

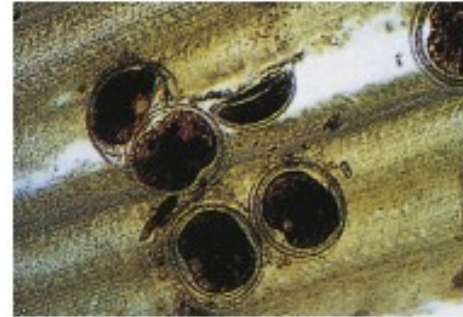

Fig. 3.222 Metacercariae on grass. Cercariae encyst on aquatic plants as metacercariae where they can be ingested by herbivores or humans. (x 75.) (Courtesy, Dr M. Murray.)

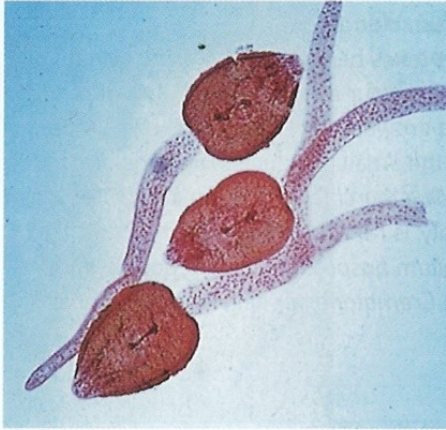


Fig. 3.220 *Galba truncatula* (formally *Lymnaea truncatula*). This snail is a common intermediate host of *F. hepatica*. The broad geographical and climate range of the family Lymnaeidae is in part responsible for the global distribution of fascioliasis. (x 5.) (Courtesy, Dr J. M. Jewsbury.)



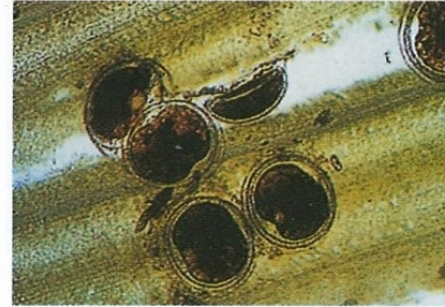Fig. 3.223 Watercress: a common source of *Fasciola* infection. Herbivores are infected by grazing wet pasture where the intermediate hosts are found. Humans are most often infected by eating wild watercress which grows commonly in swampy pasture by small

Fasciola hepatica



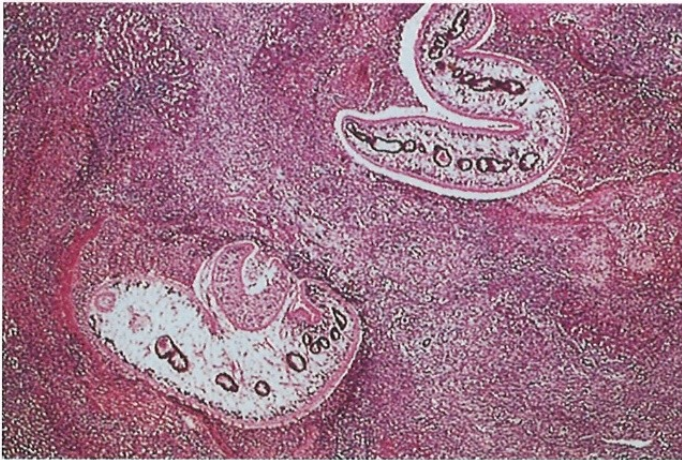584 Cercaria of *Fasciola hepatica*

The cercariae, which have unforked tails, encyst on aquatic vegetation to form metacercariae. ($\times 85$)



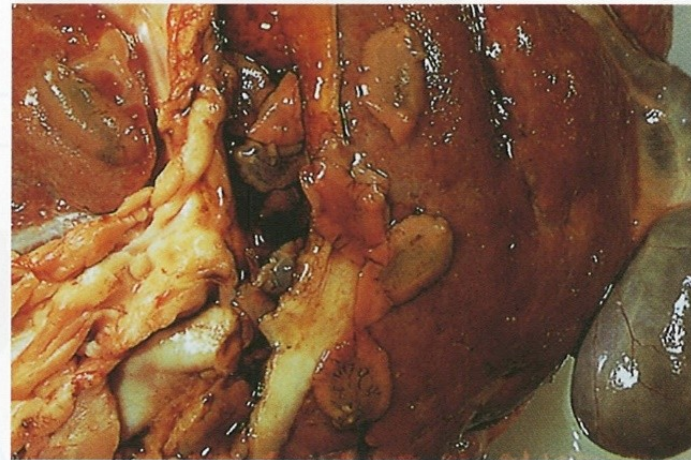
585 Metacercariae on grass

These are found on grass or other moist herbage such as watercress (580). When the metacercariae are ingested, the cycle recommences. ($\times 75$)



586 Migrating flukes in liver

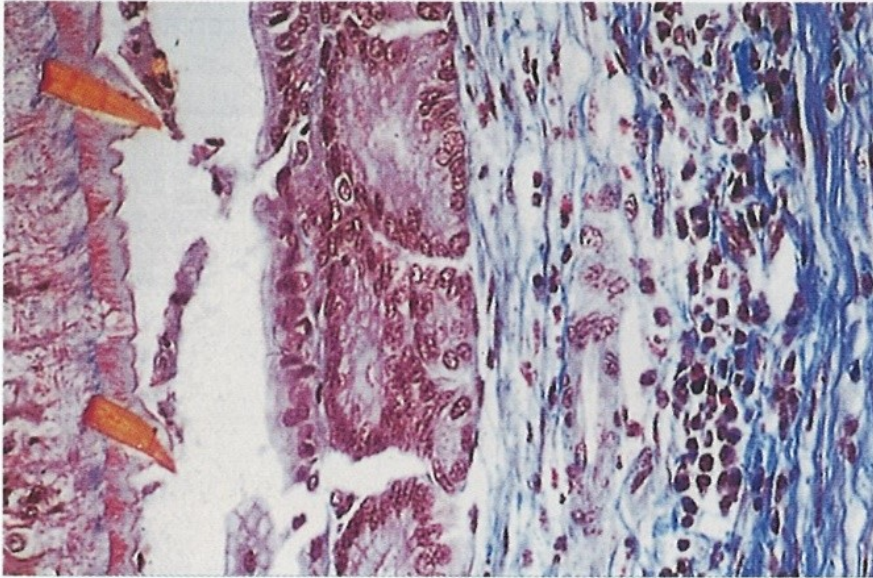
After being swallowed, the metacercariae pass through the intestinal wall and penetrate the liver capsule to enter the liver parenchyma. The figure shows a sheep liver with migrating, immature flukes. (H&E $\times 20$)



587 Adult flukes in bile ducts of a sheep liver

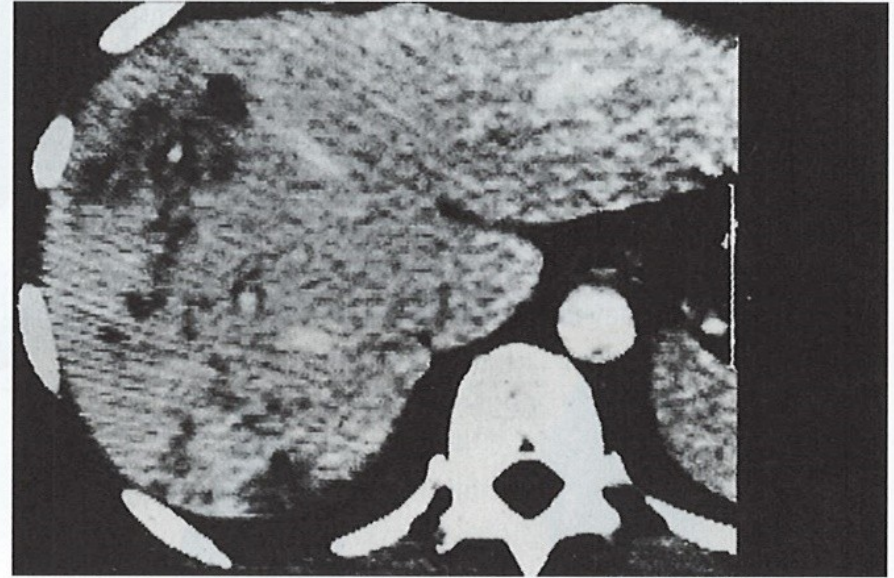
The adult flukes penetrate into the bile ducts, where they cause damage to the biliary tract. Eggs (see 407) are passed with the bile into the faeces. (Natural size)

Fasciola hepatica



588 Adult *Fasciola hepatica* in section of liver

The surface spines of the adult fluke produce mechanical damage to the biliary epithelium. (H&E $\times 350$)



589 Computed tomography scan of *F. hepatica* in human liver

Using contrast, cystic filling defects suggestive of this trematode infection can be visualised. They usually disappear after therapy.

Fasciola hepatica

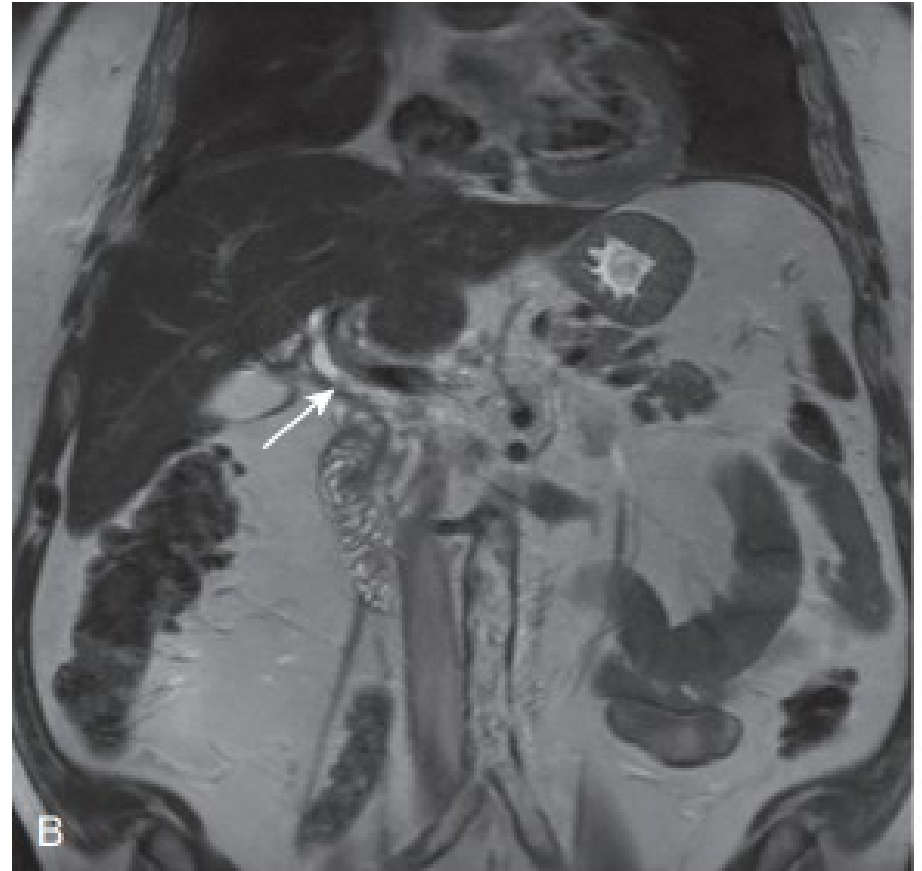
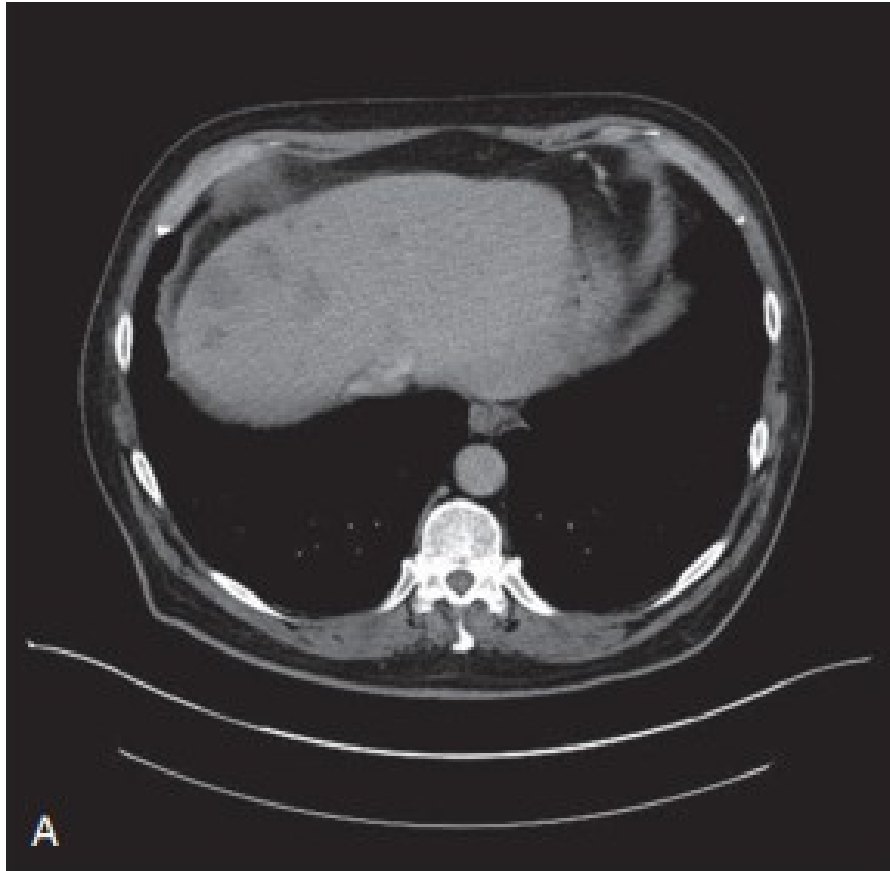


Fig. 3.228 (A, B) Acute *Fasciola hepatica* infection.

This patient presented with right upper quadrant pain, an eosinophilia and deranged liver function tests. CT imaging revealed patchy nodular abnormalities in both hepatic lobes which was initially thought to represent metastatic malignancy (A). Biopsy showed an eosinophilic infiltrate and eggs of *Fasciola spp.* were subsequently identified in the stool. Note the filling defect in the common bile duct (B). (Courtesy, P. L. Chiodini.)

Fasciola hepatica



Fig. 3.225 Ovum of *Fasciola hepatica*.

Eggs of *F. hepatica* are difficult to distinguish from those of *Fasciolopsis buski* (see Fig. 3.199). They measure 140 µm x 75 µm and are ellipsoid in shape with a thin shell. An operculum is present but this may be difficult to see. The abopercular end is sometimes irregular and roughened, a feature not seen in *F. buski*. (Courtesy, H. Edwards.)

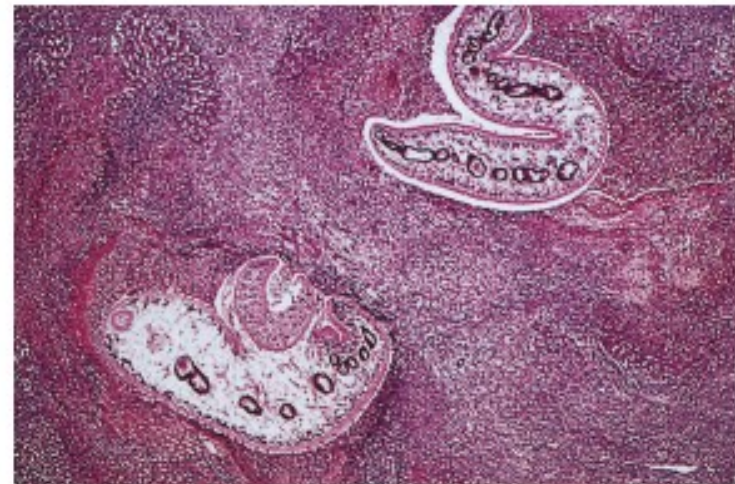

Fig. 3.226 Migrating immature flukes in sheep liver.

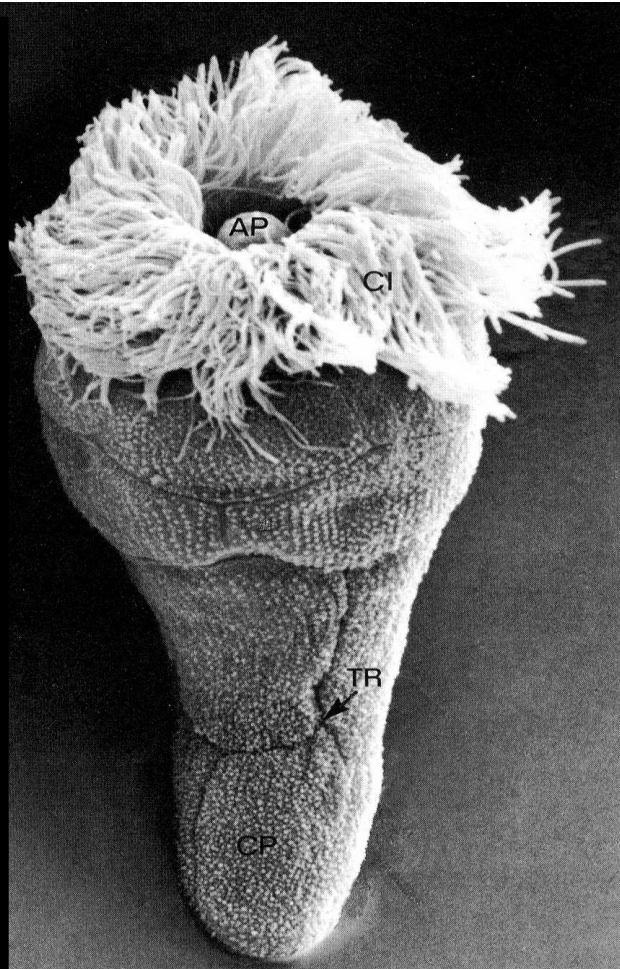
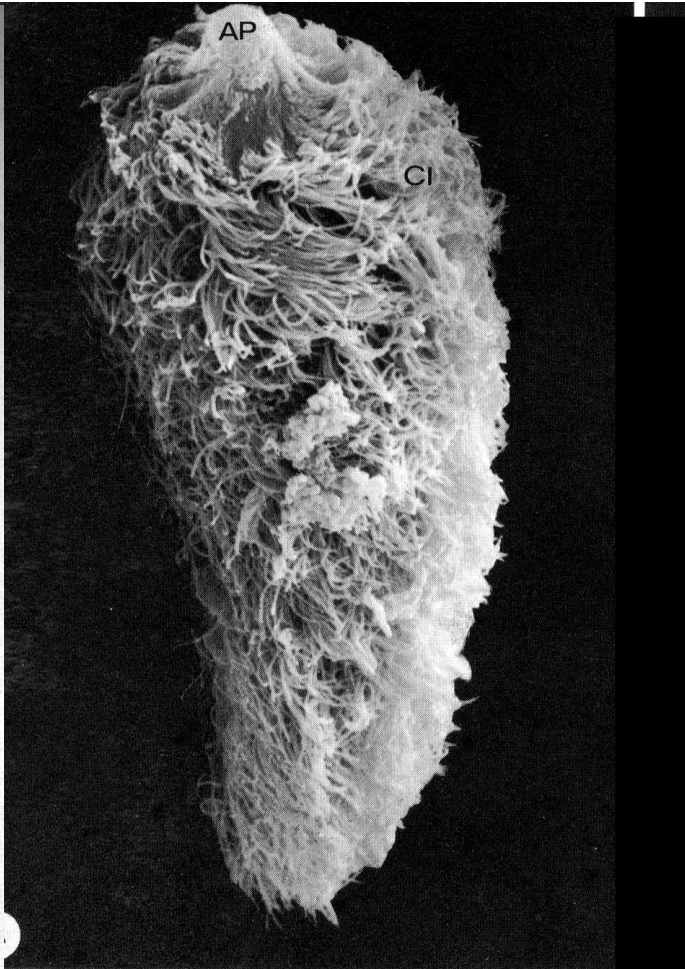
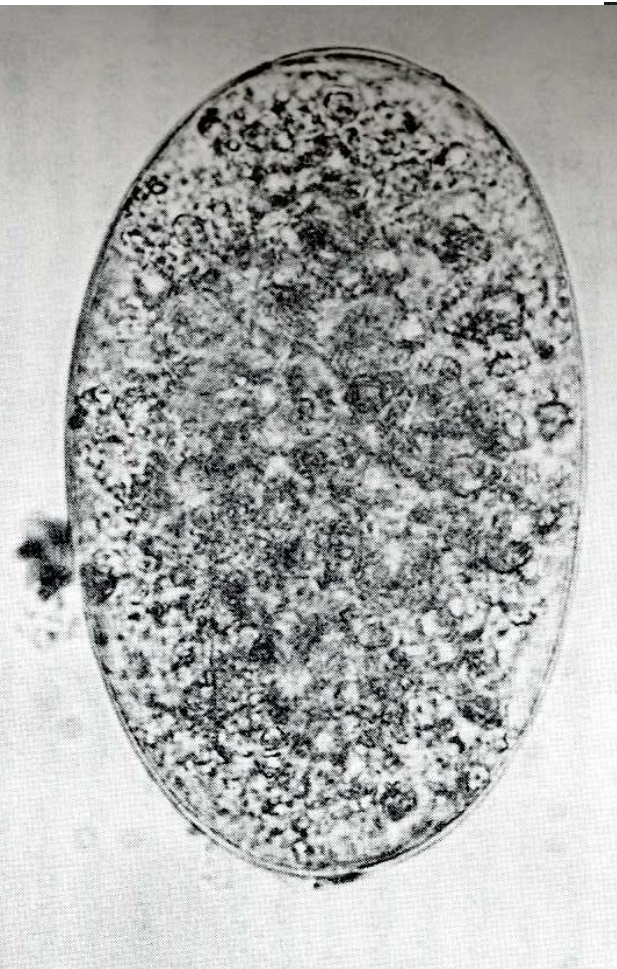
After ingestion, the metacercariae pass through the intestinal wall and the peritoneum before penetrating the liver capsule to enter the liver parenchyma. The fluke's transit track is often characterized by a prominent inflammatory response. (H&E x 20.)

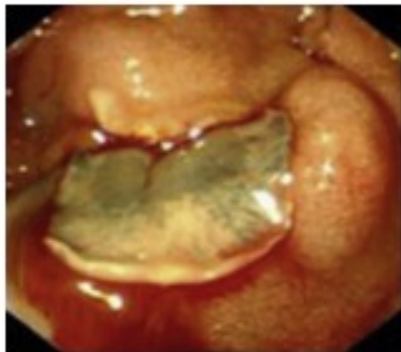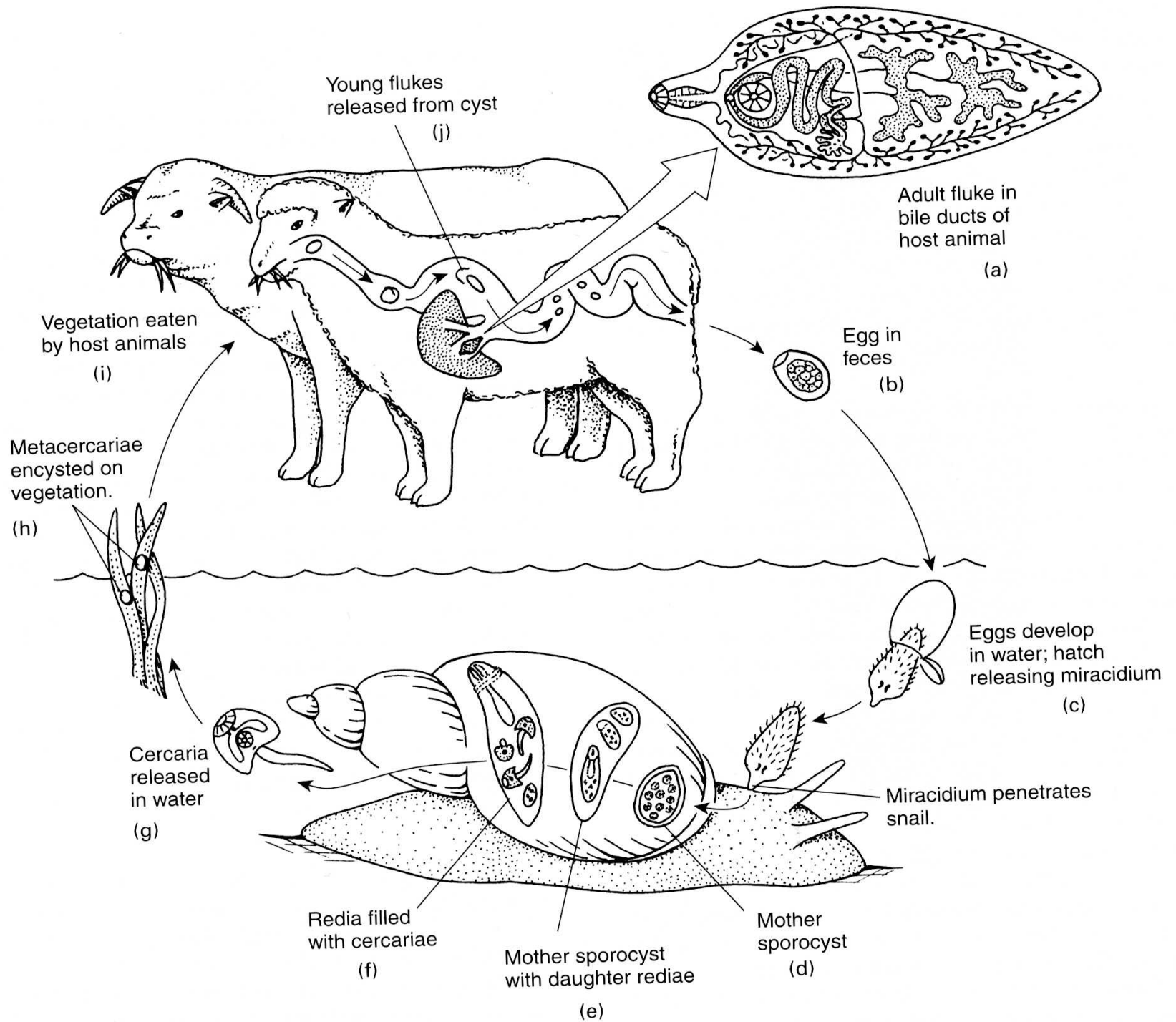


Fig. 3.227 Adult *Fasciola hepatica* in duodenum.

This adult *Fasciola hepatica* was seen on endoscopy. (Soga K, Handa O, Yamada M, et al. In vivo imaging of intestinal helminths by capsule endoscopy. *Parasitology International* 2014. 63 (1) Pages 221-228. Figure 1B.)

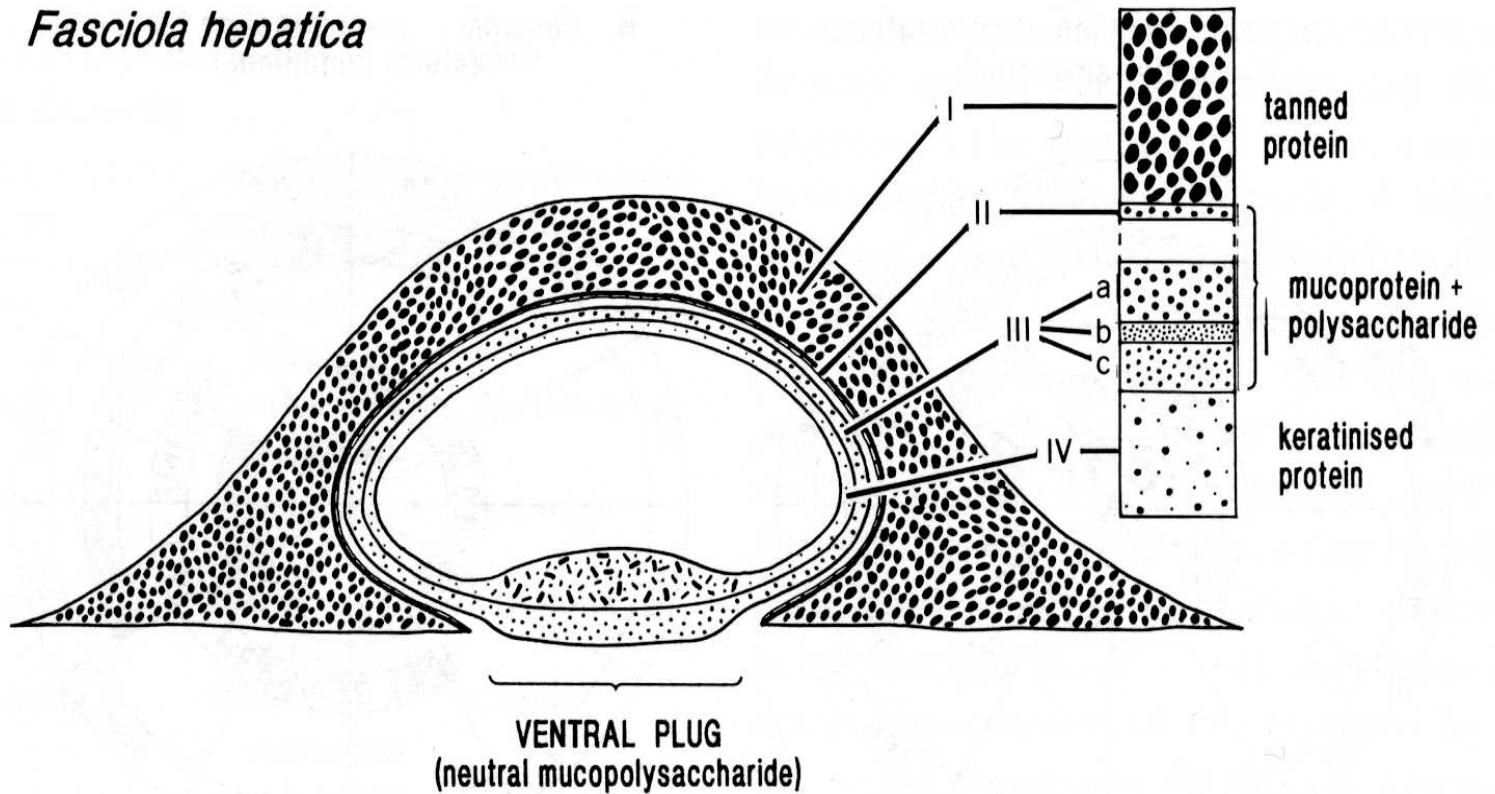
Vajíčko a miracidium





Tvorba metacerkárie - adoleskárie

Fasciola hepatica

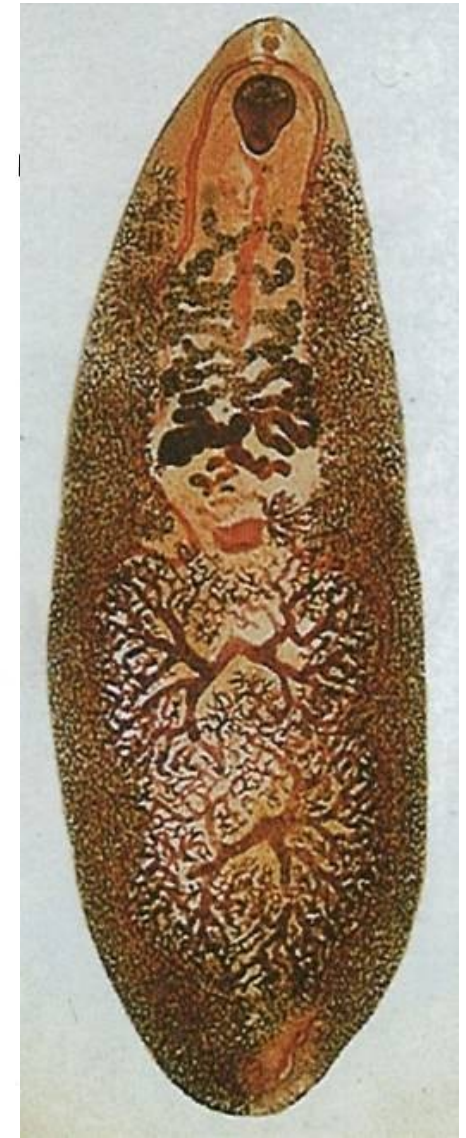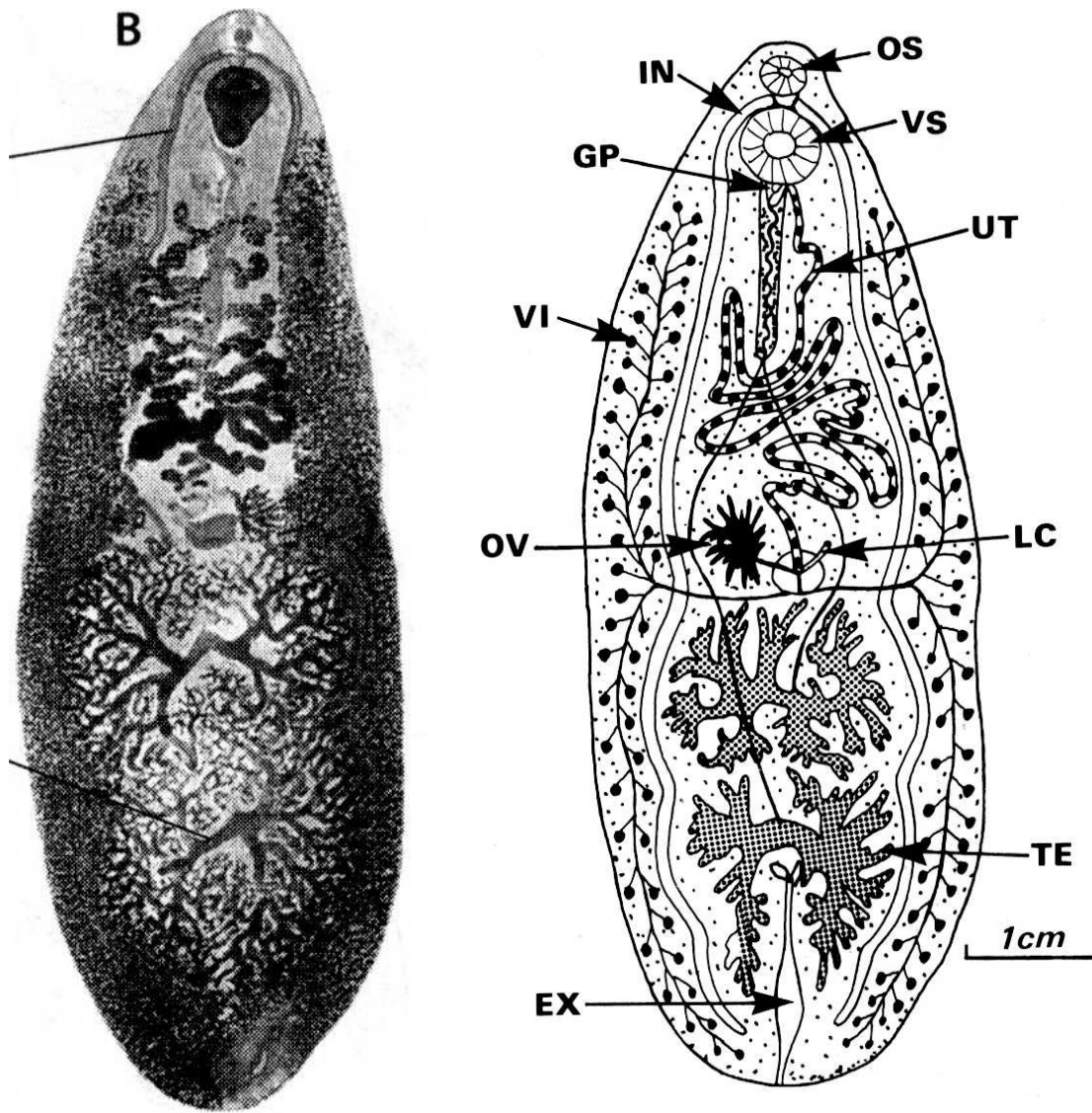


Fasciolidae III

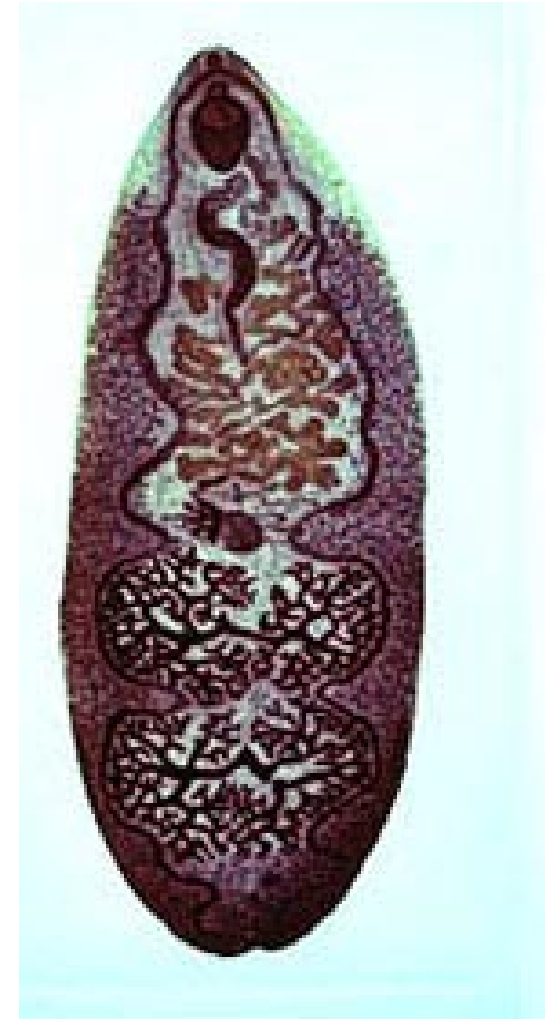
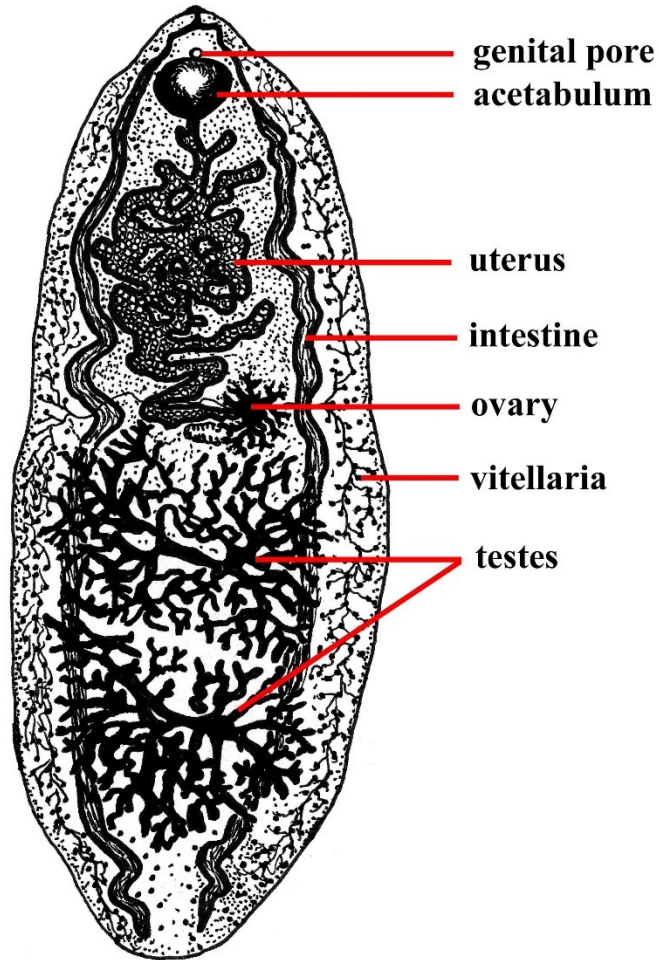
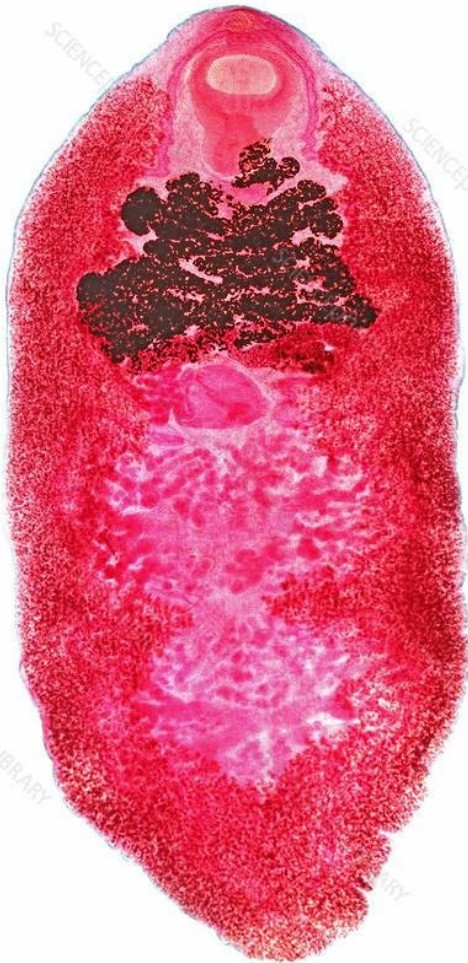
Zástupce:

- **Fasciolopsis busci**
- Velikost až 7 cm
- Střevní parazit prasat, psů, člověka v Asii
- Mz – Melania, Oncomelania, Planorbis
- Adoleskárie na Trapa natans, lotosu
- Těžké poškození střev
- 15 milionů lidí napadeno

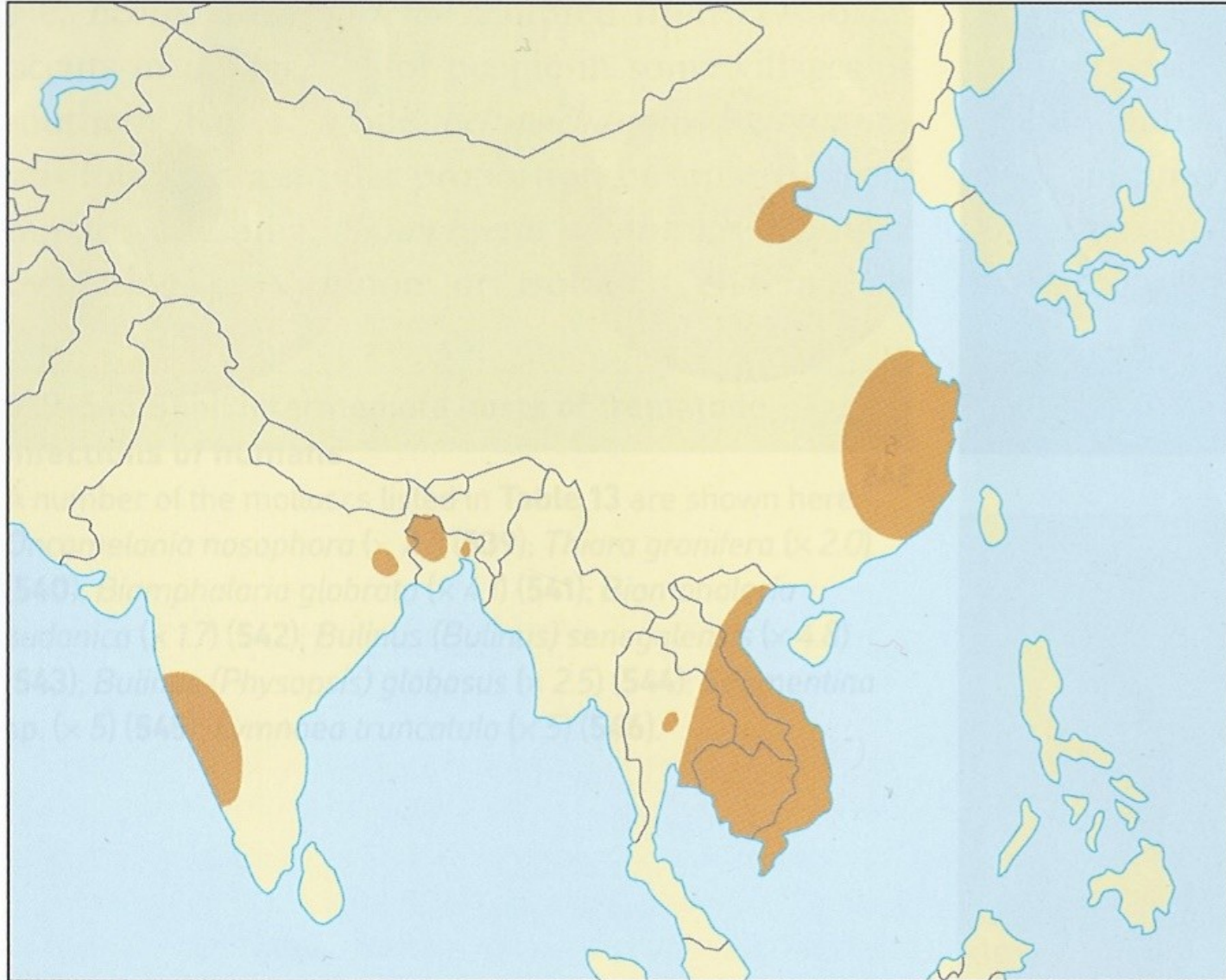
Fasciolopsis busci



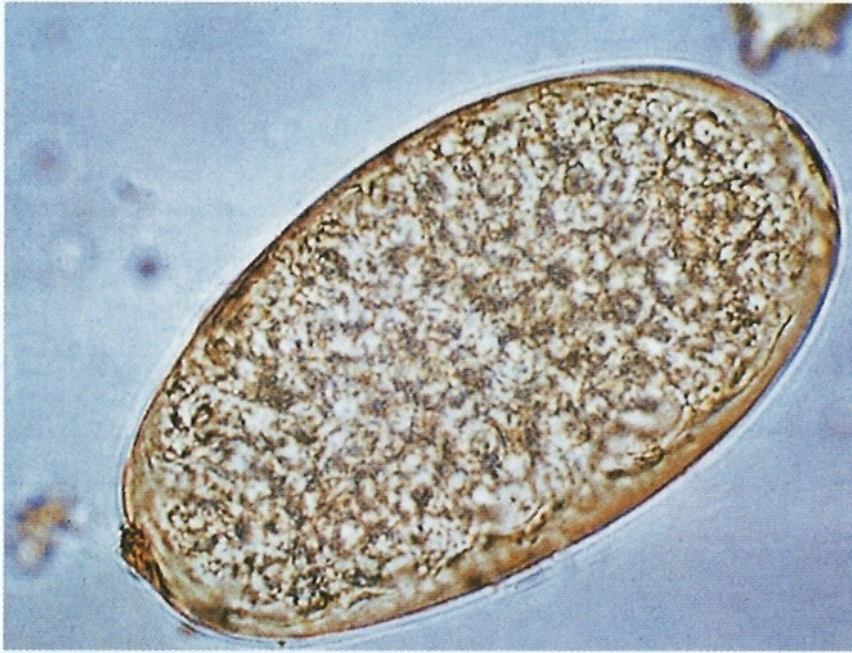Fasciolopsis busci - morfologie



Fasciolopsis buski - rozšíření

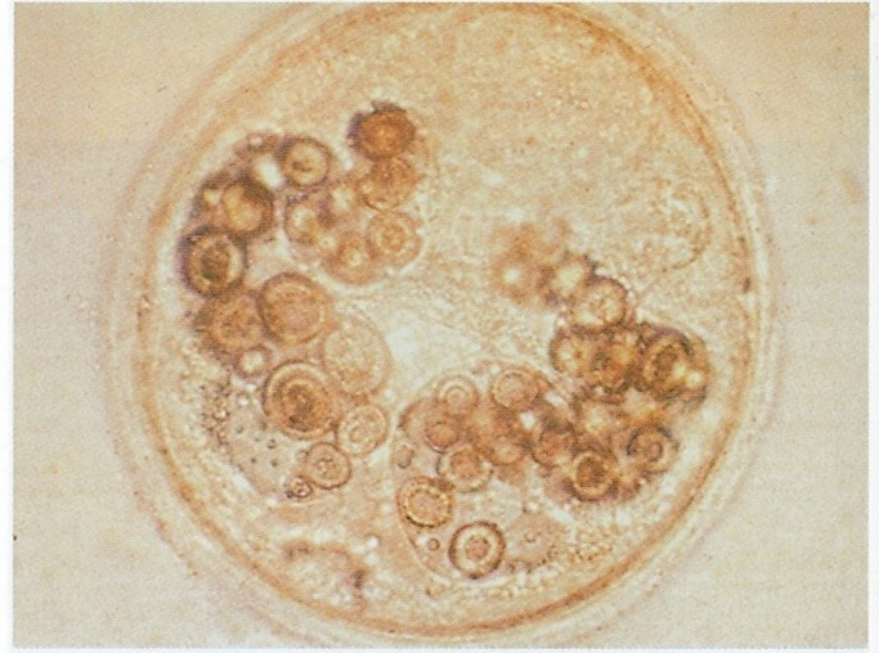


Fasciolopsis buski



549 Egg of *Fasciolopsis buski*

Miracidia, hatching from eggs passed in the faeces after shedding their ciliated coats, invade snails of various genera, including *Segmentina* and *Hippeutis*. The reproductive cycle in the snail differs from that of the schistosomes. After development through the sporocysts and two generations of rediae (see **560**), cercariae emerge into the water. They then encyst on aquatic plants such as the water caltrop (**552**) and water chestnut (**571**). (× 240)



550 Metacercaria of *Fasciolopsis buski*

The metacercaria of *F. buski* with its cyst wall. (× 220)

Fasciolopsis buski



551 *Segmentina hemisphaerula*

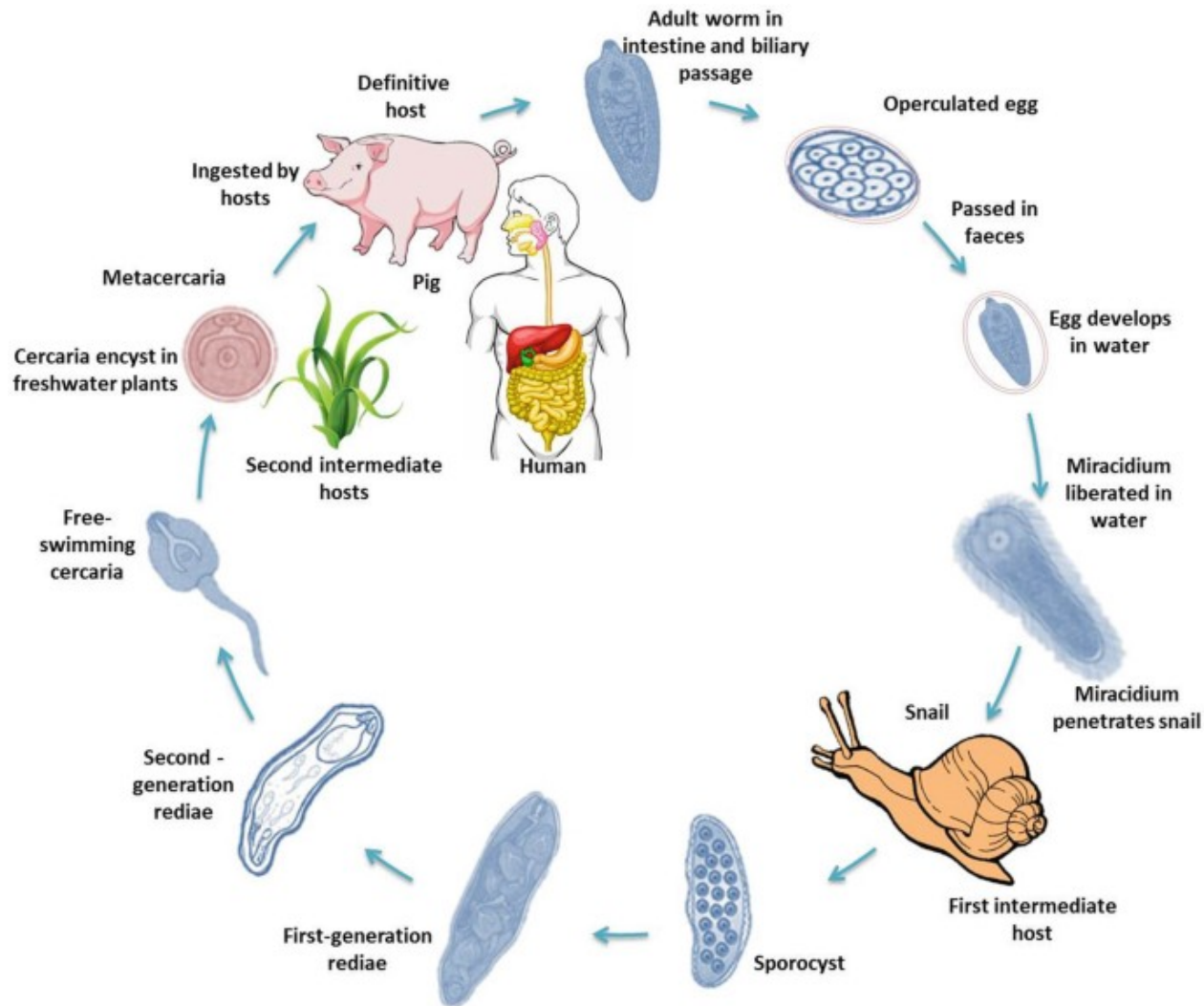
This snail and a number of species of *Hippeutis* are the first intermediate hosts of *F. buski*. ($\times 2.7$)



Segmentina hemisphaerula

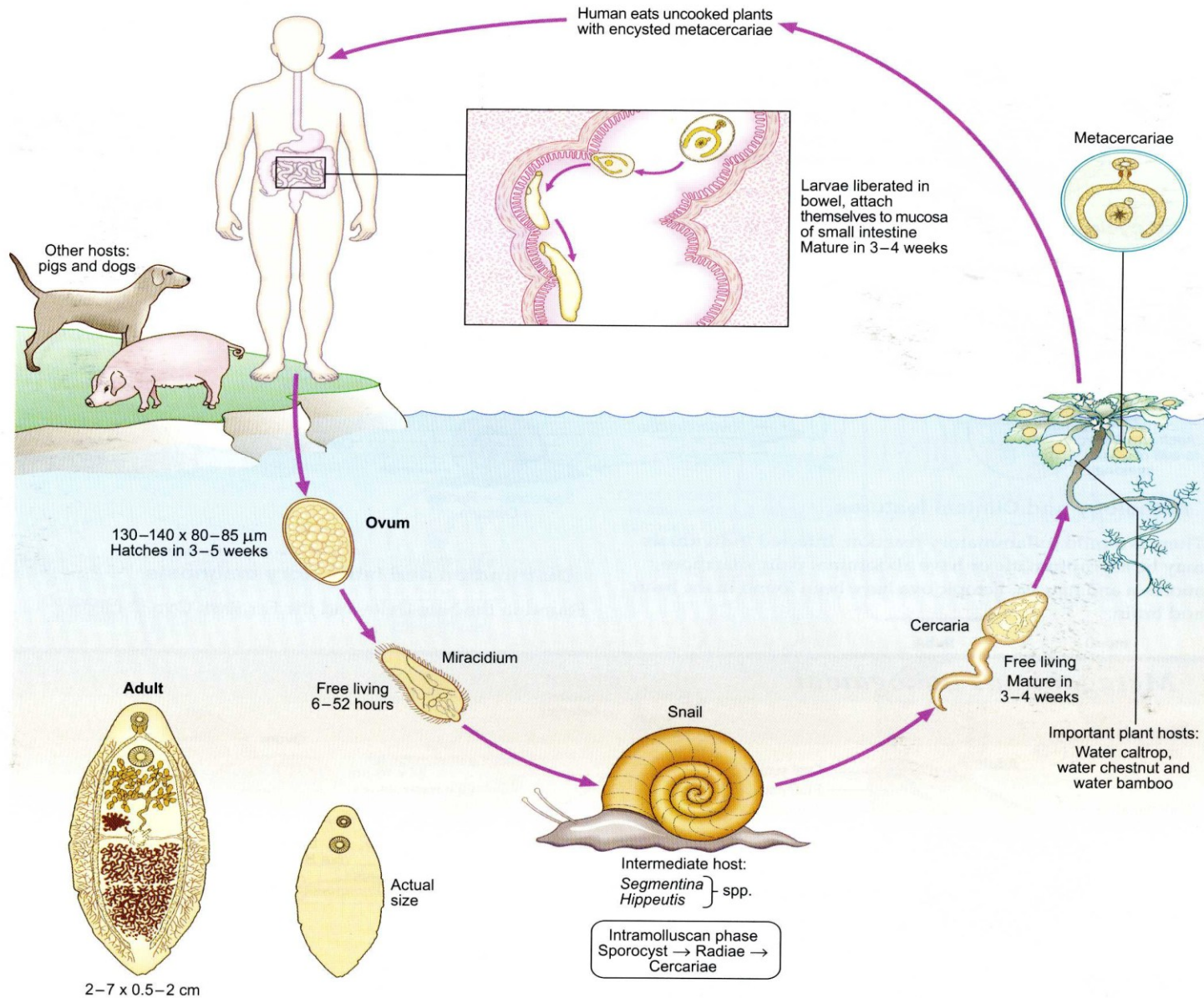
vegetace s metacerkariemi

Životní cyklus *Fascioloides busci*

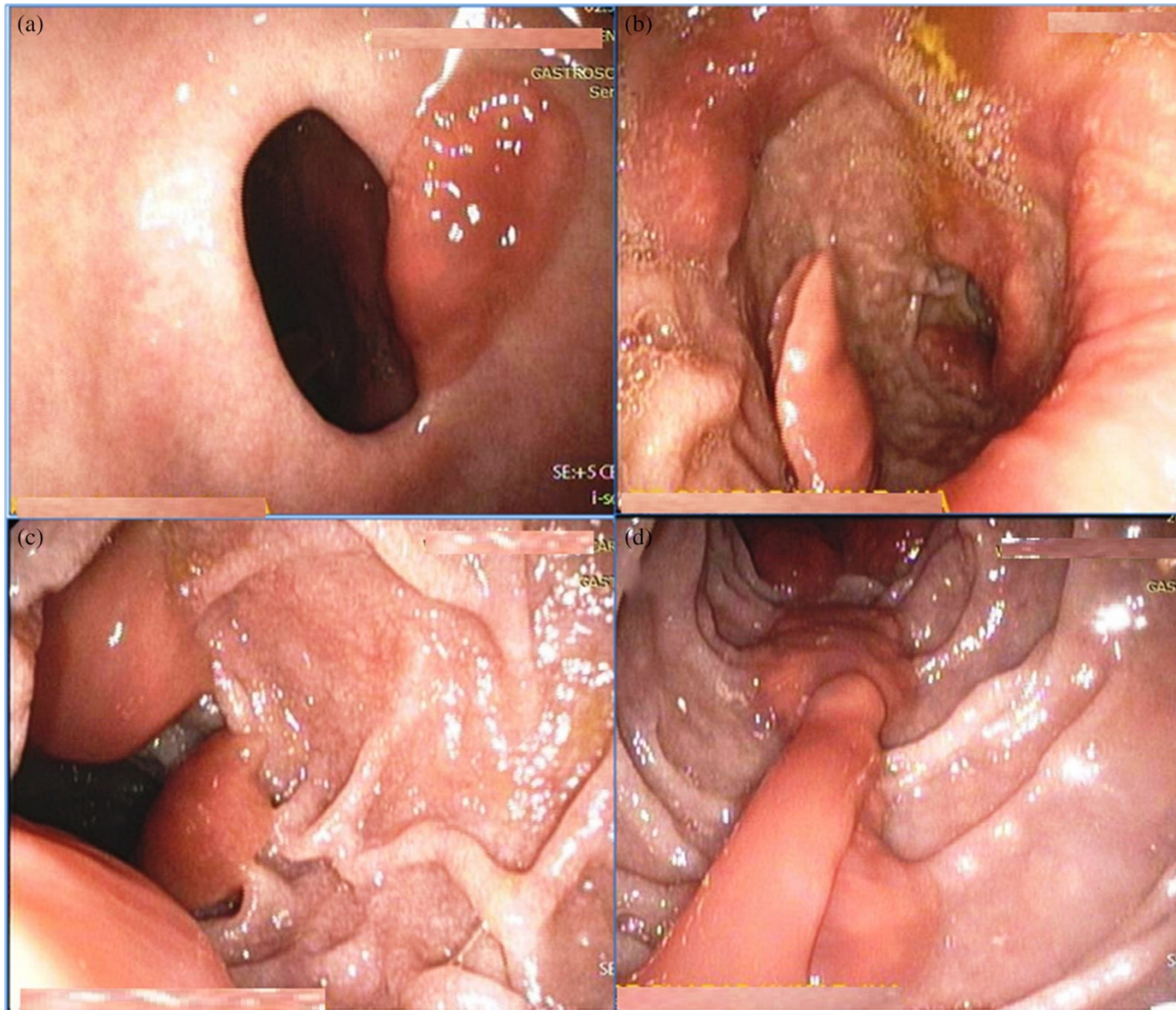


Fasciolopsis buski

Life cycle



Endoskopická diagnostika Fasciloides busci



Heterophyiasis

Heterophyidae

Charakteristika:

- Střevní motolice ptáků a savců, včetně člověka (fish-born diseases)
- Malé motolice
- Otrněný tegument
- Břišní přísavka modifikována (ventrogenitální komplex s trny a sklerity; někdy genitální přísavka)

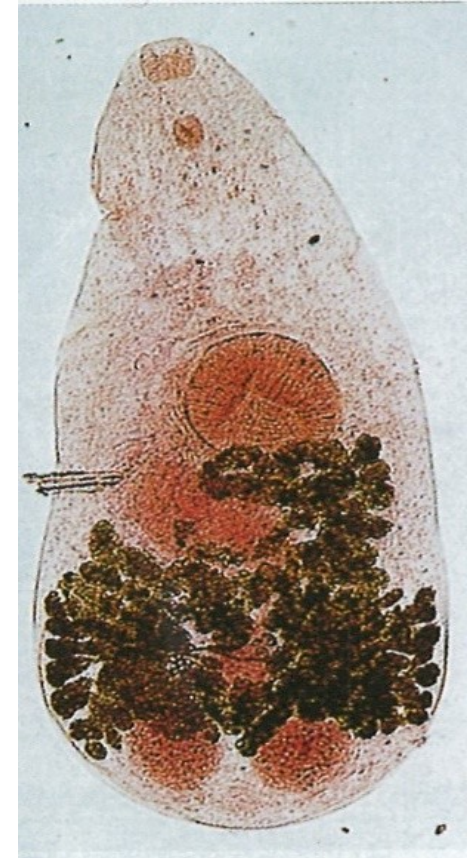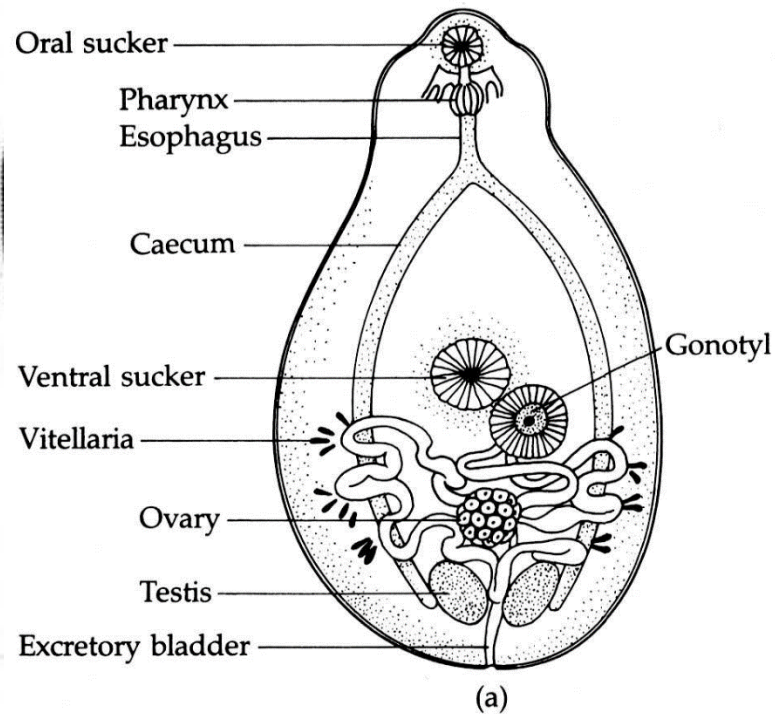
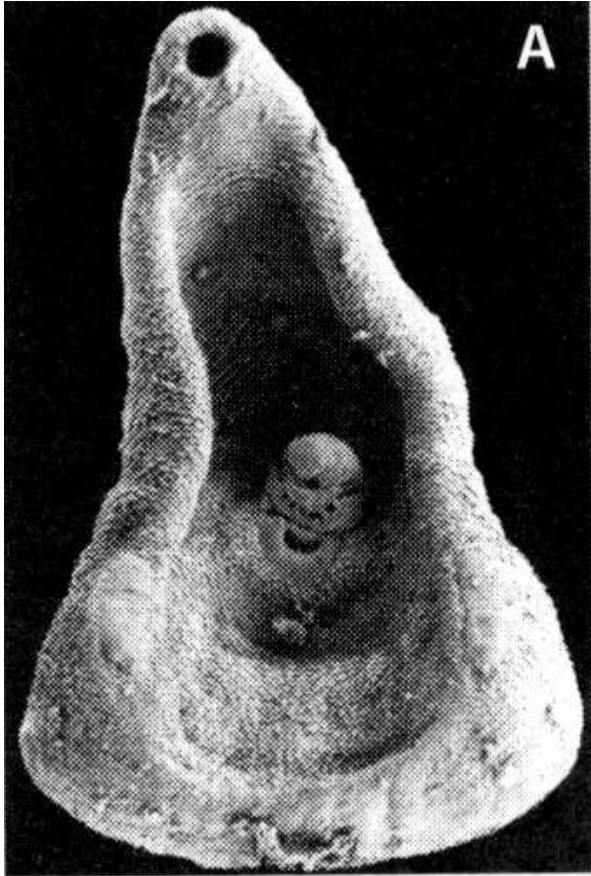
Vývoj:

- 1. Mz – plži – oculopleurocercárie
- 2. Mz – ryby

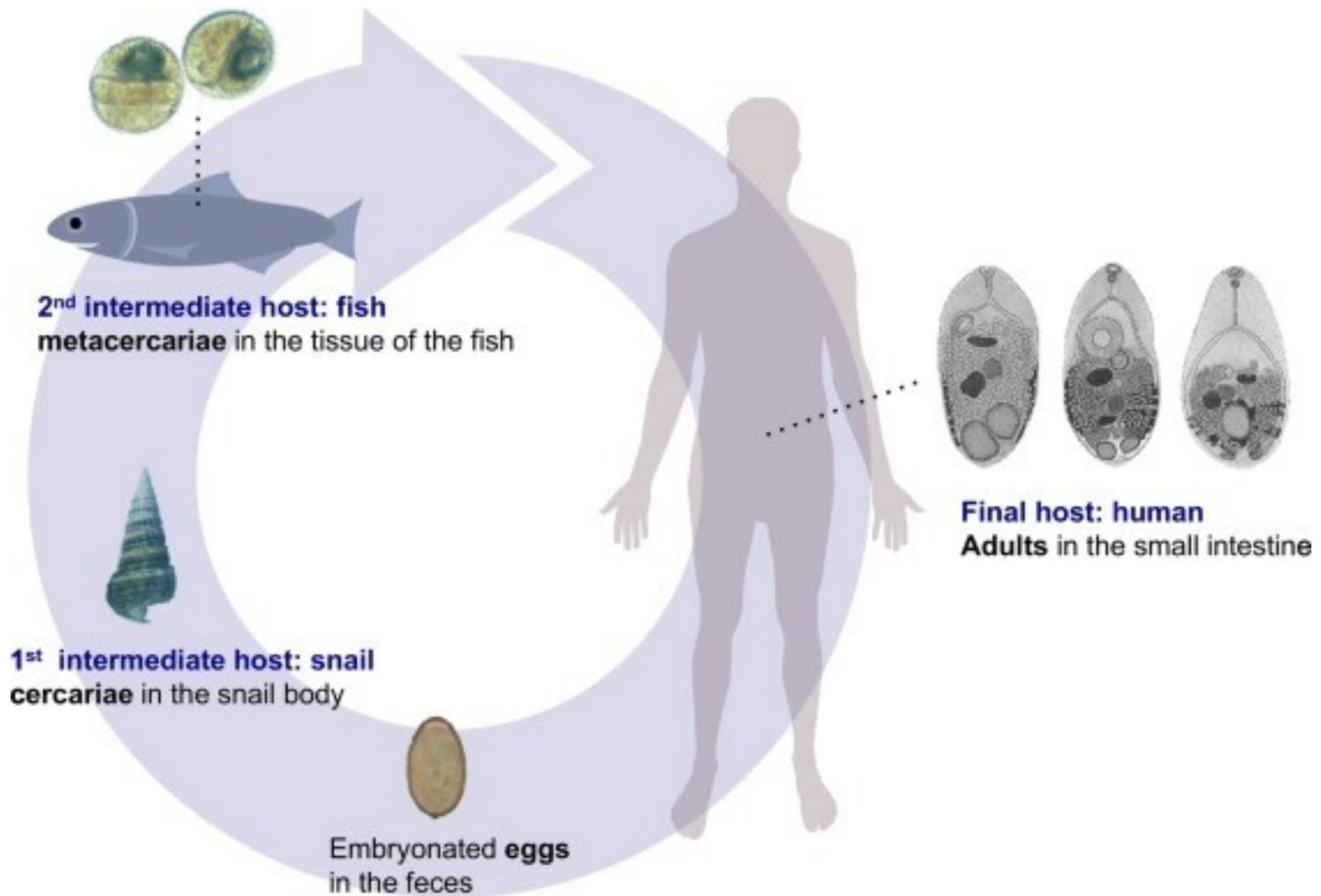
Zástupci:

- **Heterophyes heterophyes** – Asie, středomoří, 1,5mm
- **Metagonimus yokogawai** - šelmy, člověk, Asie, Podunají; Melania, Oncomelania, Melanoides; metacercárie pod šupinami
- **Haplorchis spp** – nákazy lidí v jv. Asii

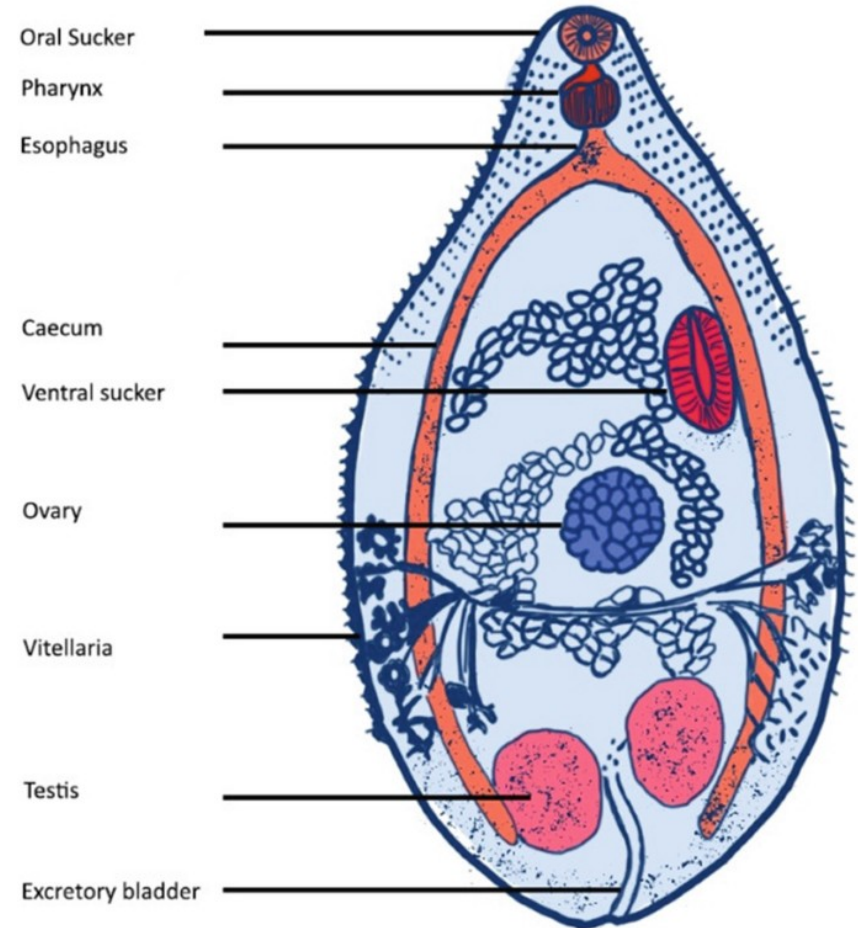
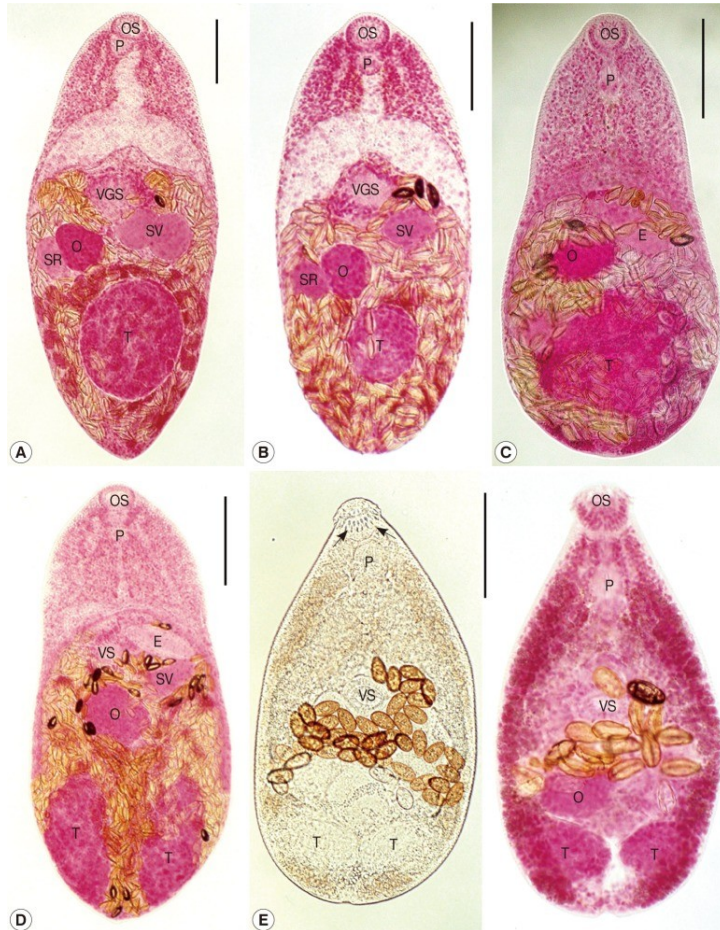Heterophyes heterophyes



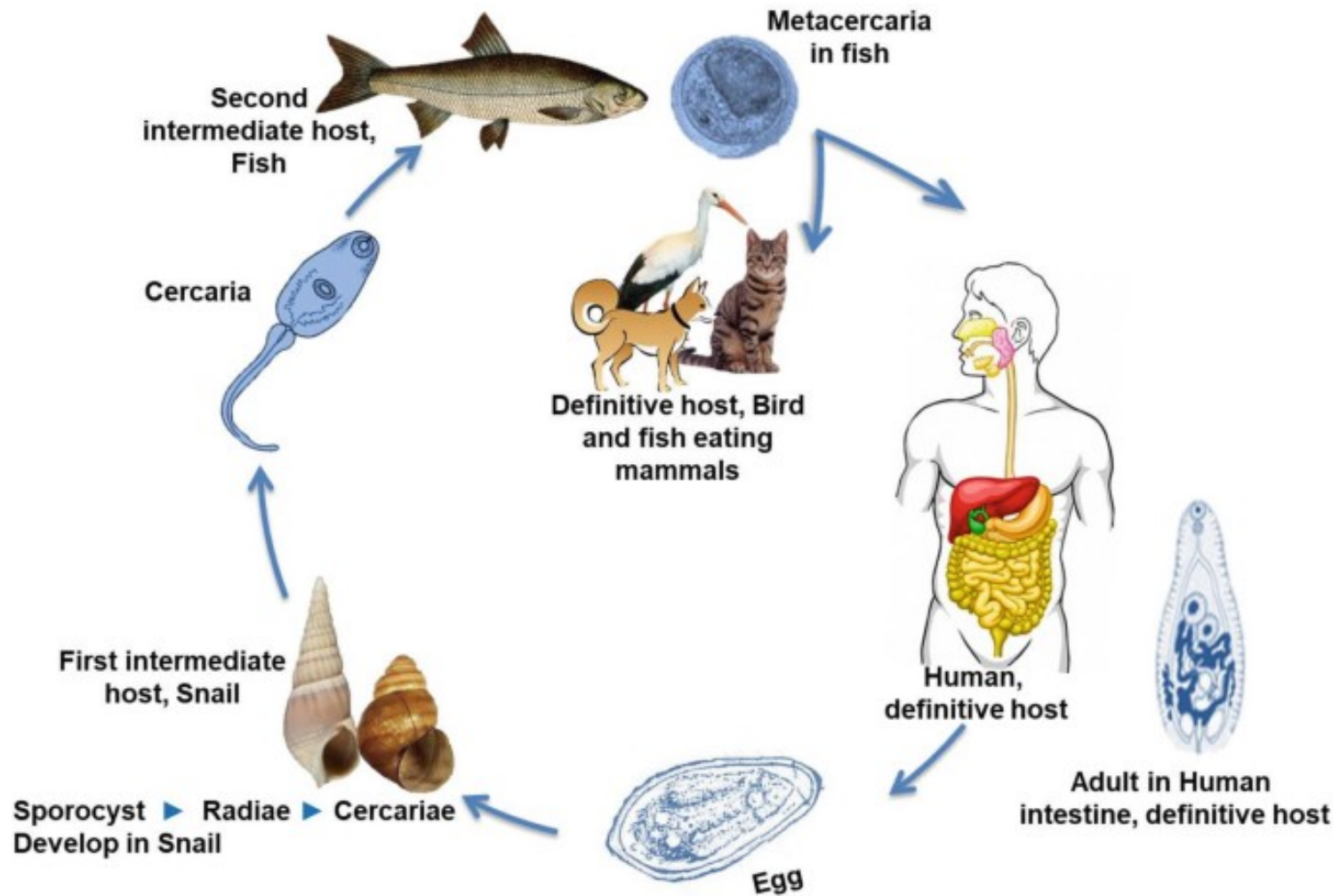
H. heterophyes – „fish born“ onemocnění



Heterophyes herophyes – fish born onemocnění

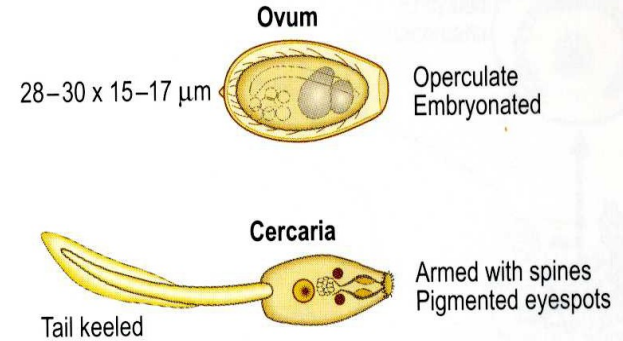
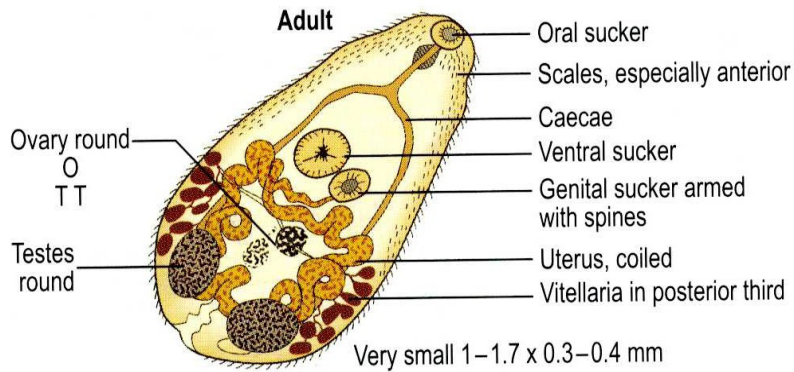


Životní cyklus *H. heterophyes*

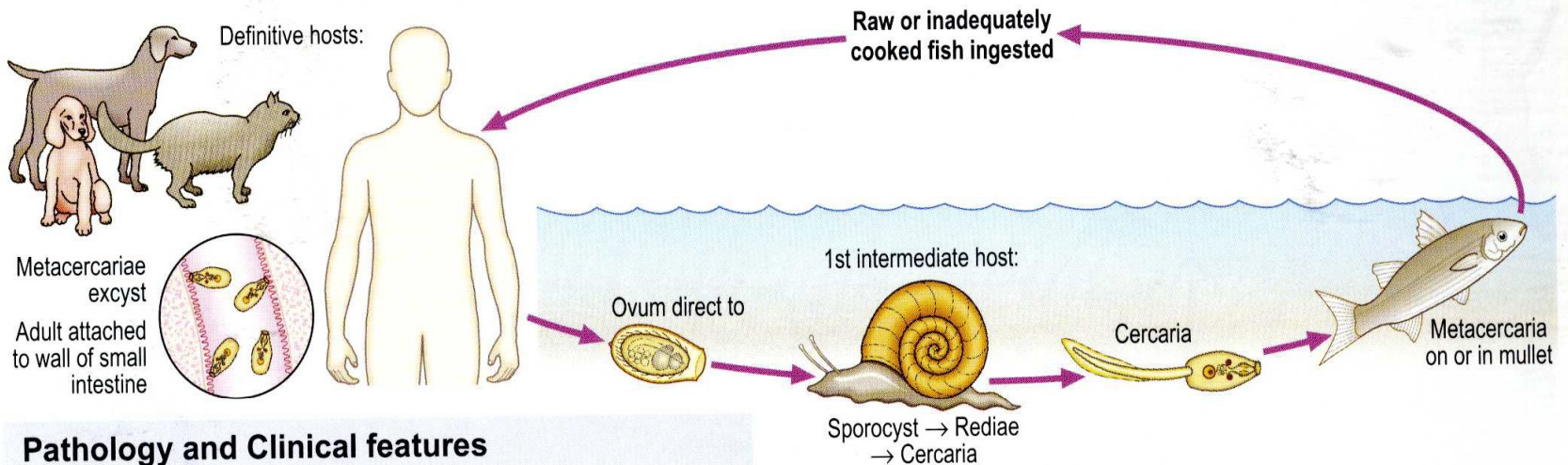


Heterophyes heterophyes

Morphology



Life cycle




Pathology and Clinical features

There is a mild inflammatory reaction. Infected individuals may be asymptomatic or have abdominal pain, diarrhoea, anorexia and nausea. Ectopic ova have been found in the heart and brain.

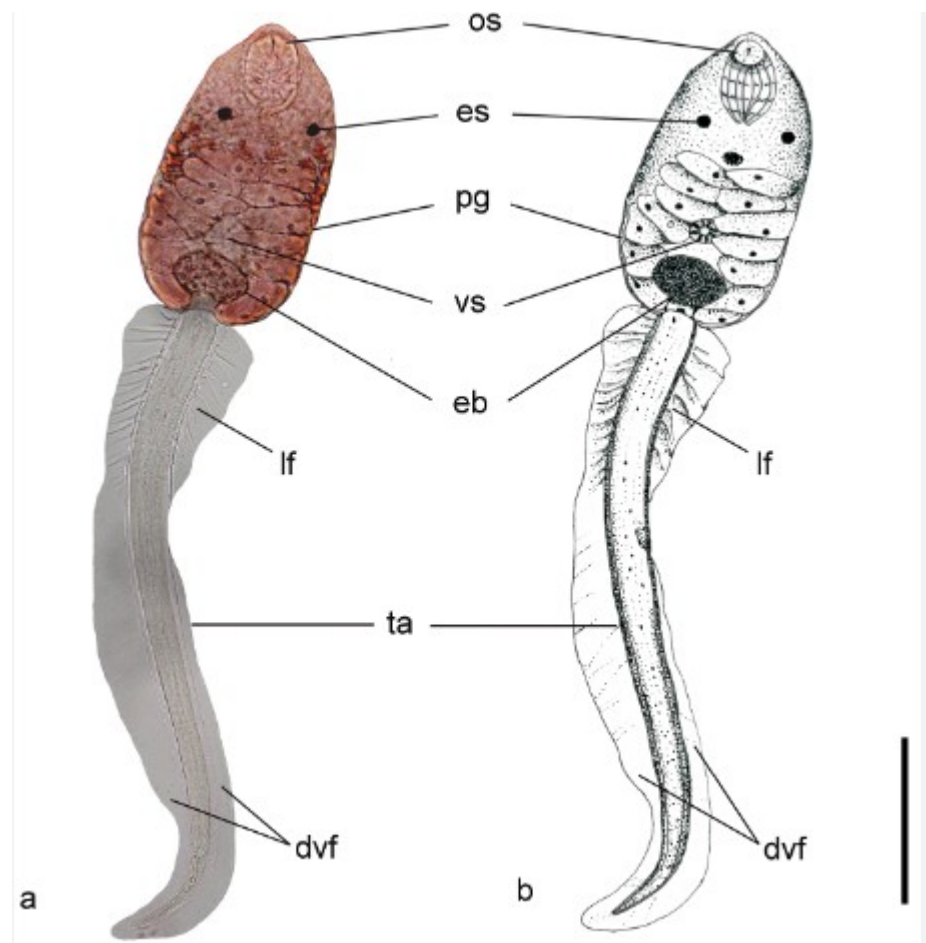
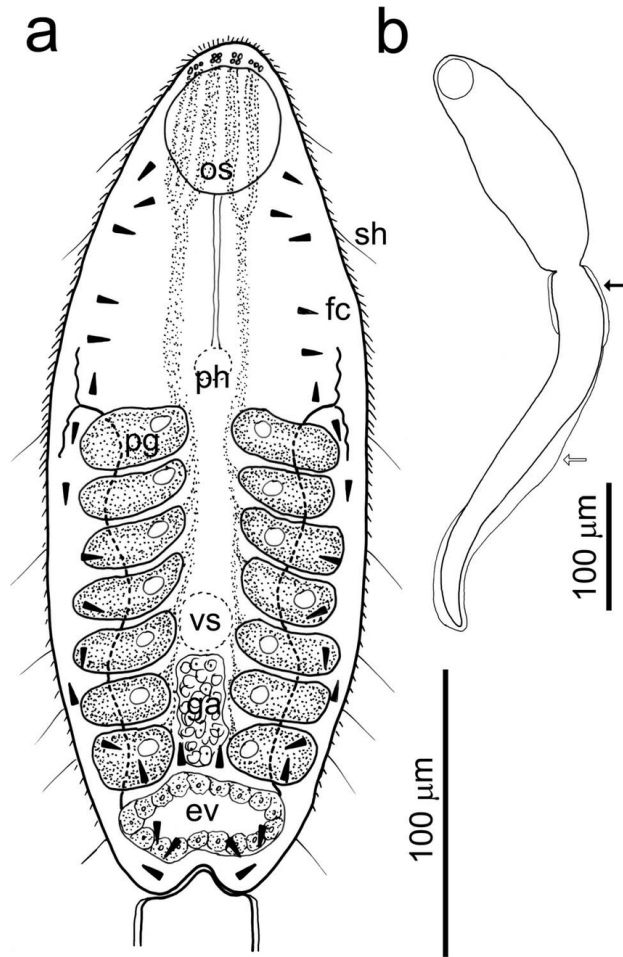
Distribution and laboratory diagnosis

Found in the Nile Delta and the Far East. Ova in faeces.

Sladkovodní plži – 1. mezihostitelé



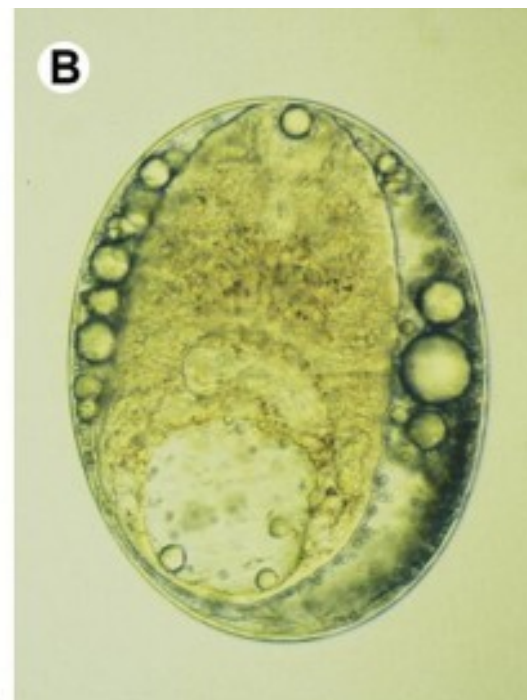
Heterophyes – invazní stádium cerkarie - metacerkarie



Kaprovidé ryby - mezihostitelé



Metacerkarie v rybách – 2. mezihostitel



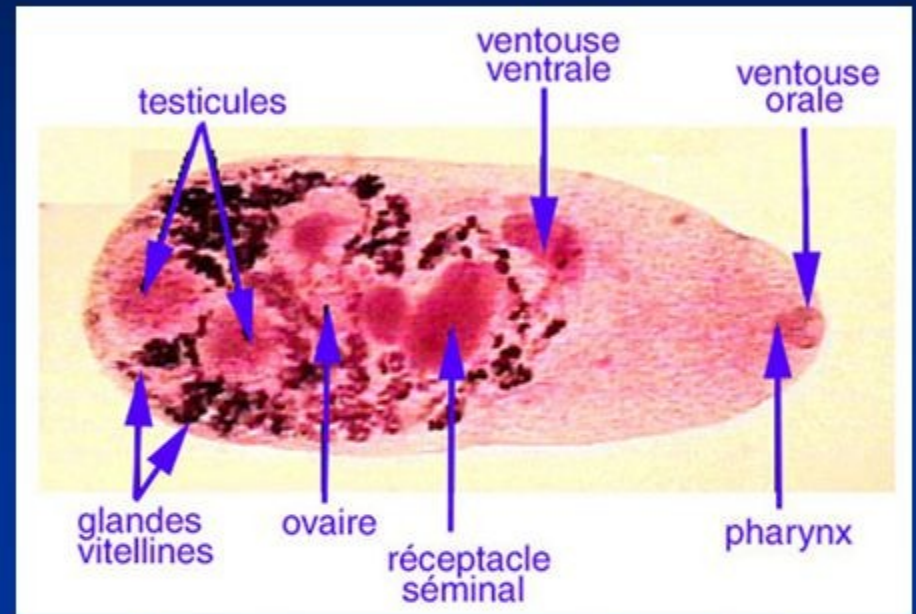
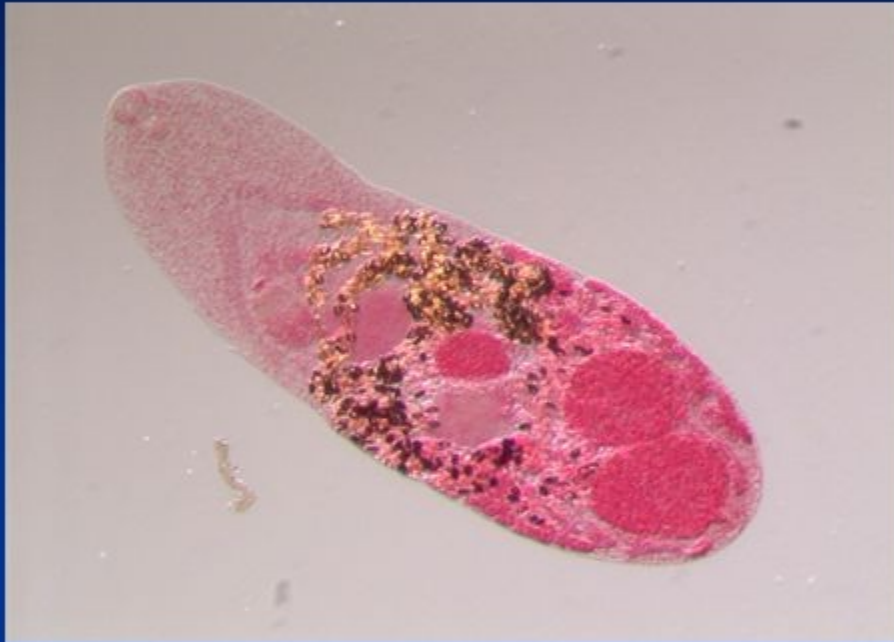Metagonimus yokogawai

Common name: Japanese fluke

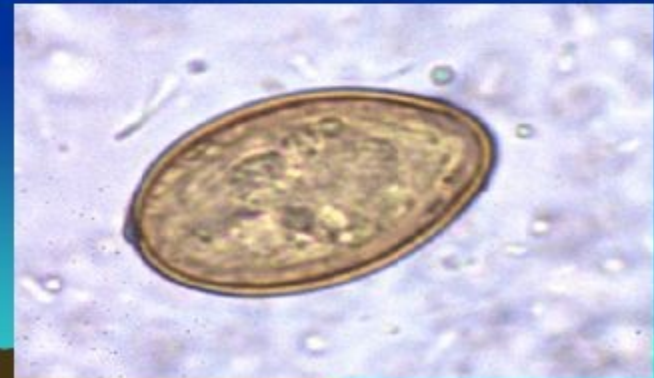
Common Associated Disease: Metagonimiasis



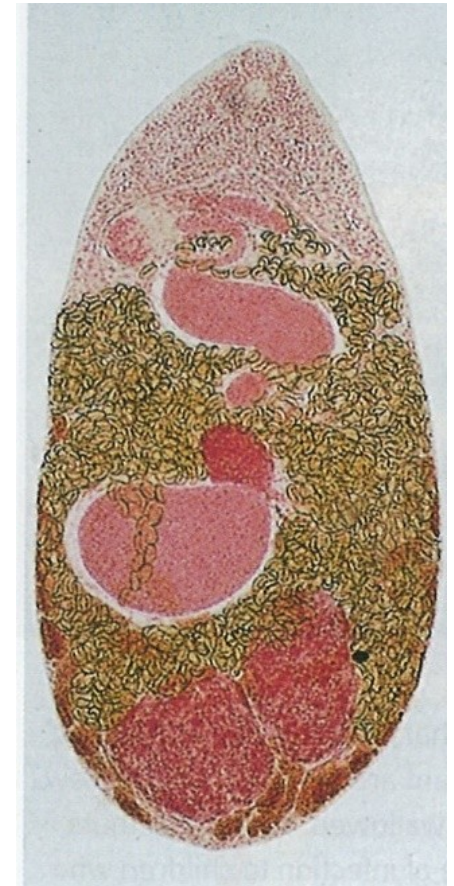
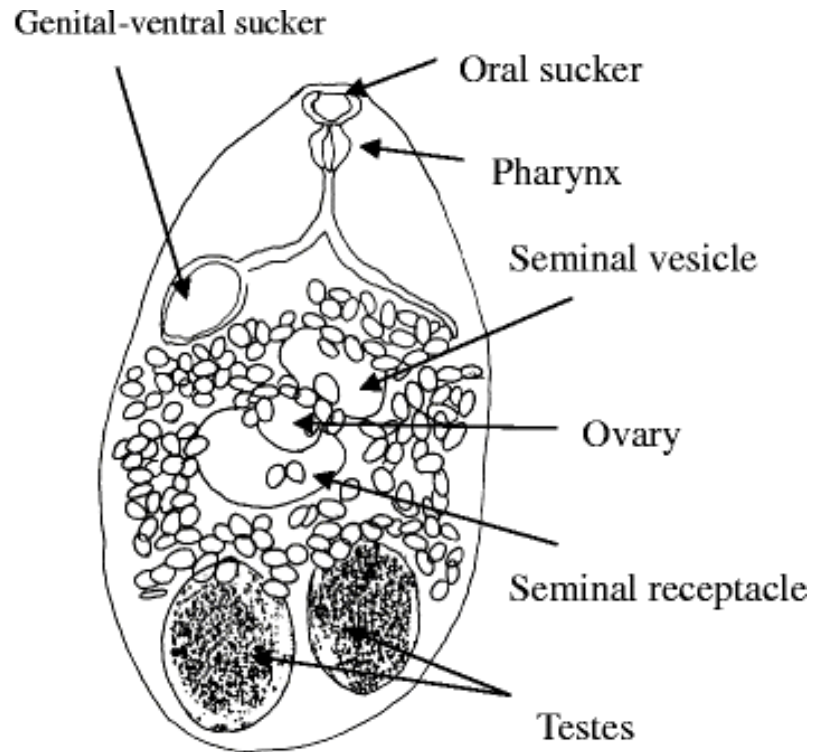
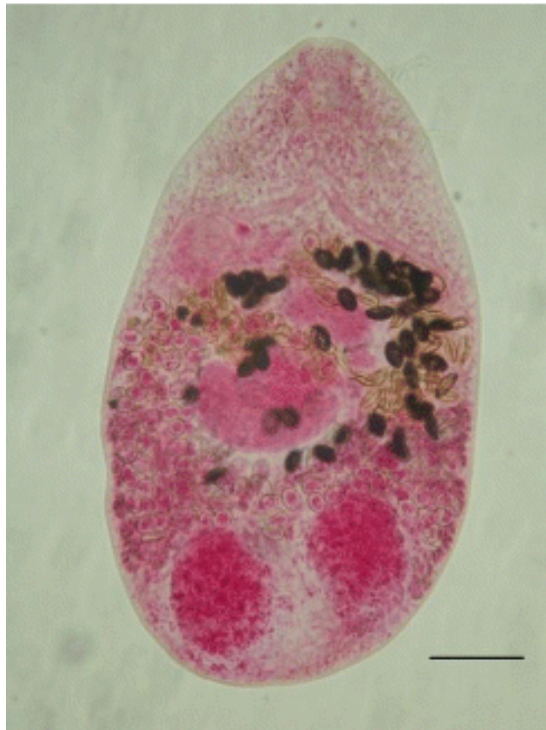
Metagonimus yokogawai Adult



Egg



Metagonimus yokogawai



Metagonimus yokogawai

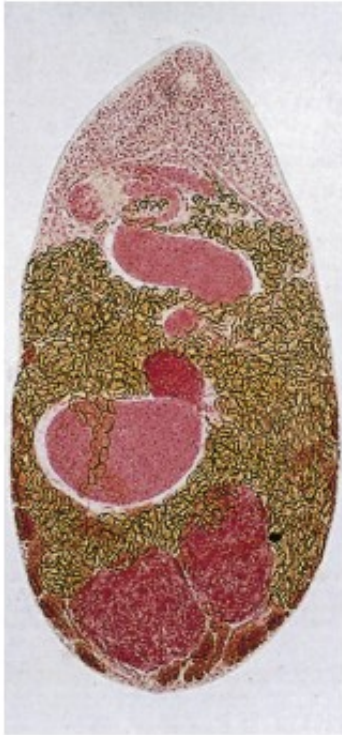

Fig. 3.200 Adult *Metagonimus yokogawai*: an example of a small intestinal fluke.

Many species of small intestinal flukes can infect humans. In general, these measure less than 2.5 mm in length and rarely cause symptoms except in very heavy infection. The best described are *M. yokogawai* in East Asia and *Heterophyes heterophyes* in the Middle East and North Africa. Adults inhabit the small intestine, producing less than 50 eggs per day. Stool examination for ova is insensitive and the diagnosis is often only made after the host receives a dose of praziquantel and adult flukes are passed in the stool. Note the anterior oral sucker, two posterior testes and multiple eggs seen in this adult *M. yokogawai* (x 45.) (Courtesy, Professor I. Miyazaki.)

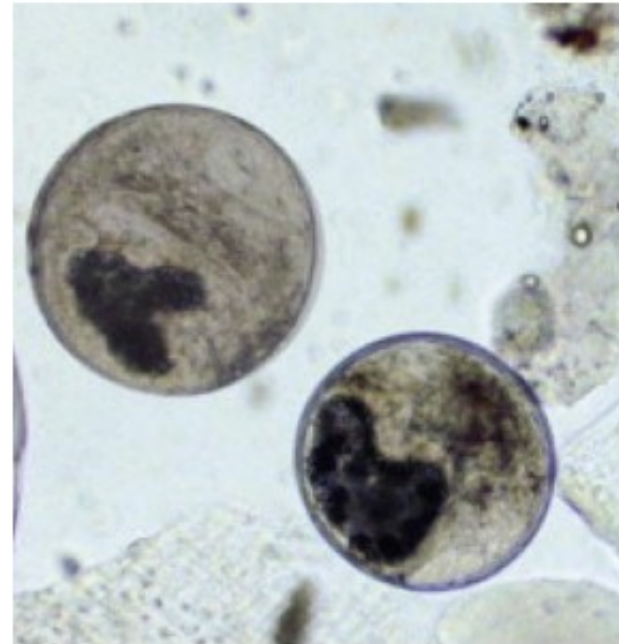
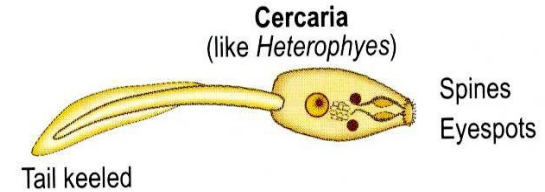
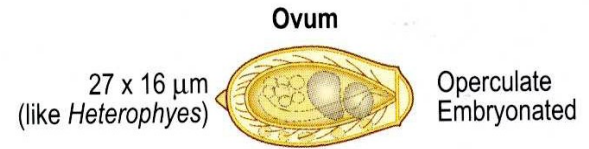
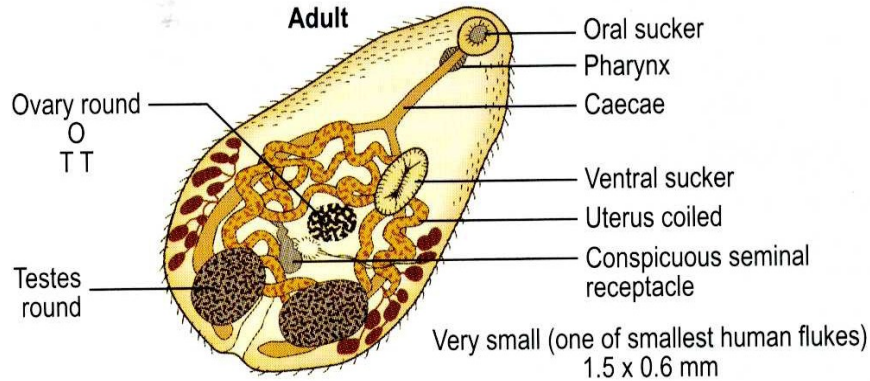


Fig. 3.201 *Metagonimus yokogawai* metacercariae removed from sweetfish.

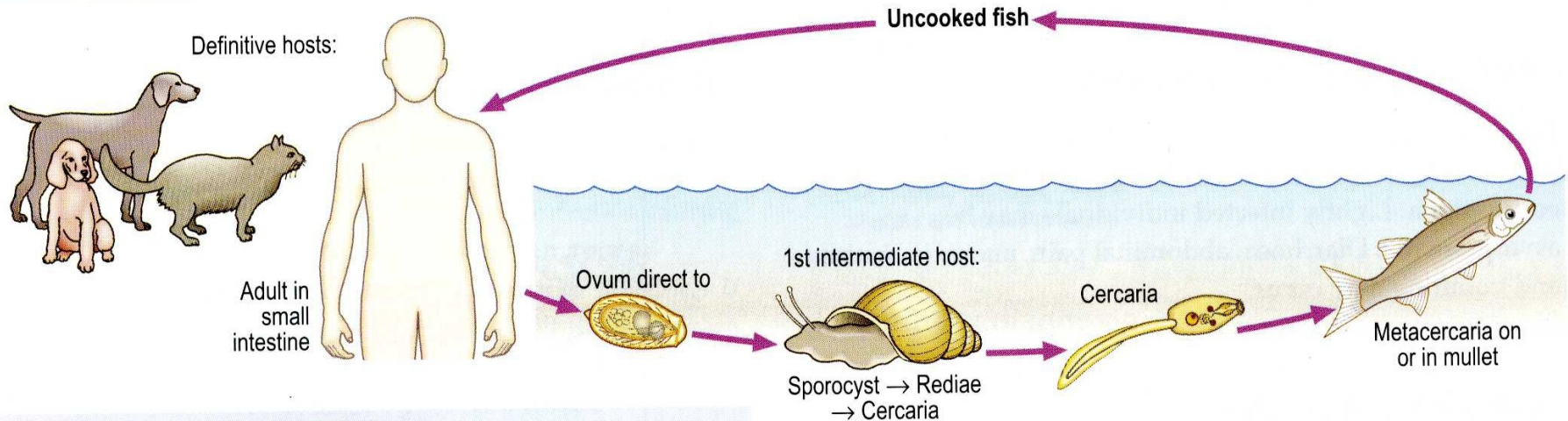
The life cycles of the *M. yokogawai* and *Heterophyes heterophyes* are similar to that of *Fasciolopsis buski*. However, rather than encysting on aquatic plants, cercariae penetrate the skin of freshwater fish and encyst in their tissue. Humans are infected by ingestion of raw or undercooked fish. These metacercariae were found in the flesh of sweetfish, *Plecoglossus altivelis*, a common delicacy in Korea and Japan. (From Tsubokawa, D., Sugiyama, H., Mikami, F. et al. Collection methods of trematode eggs using experimental animal models. *Parasitology International*, 2016-10-01, Volume 65, Issue 5, Pages 584-587, Figure 3, Panel A.)

Metagonimus yokogawai

Morphology



Life cycle



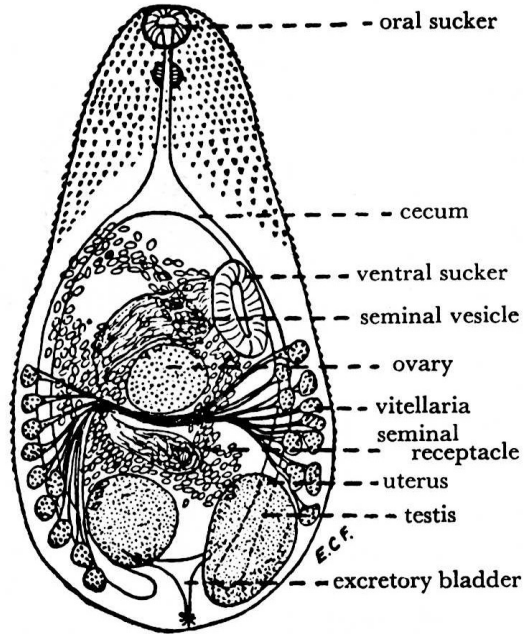
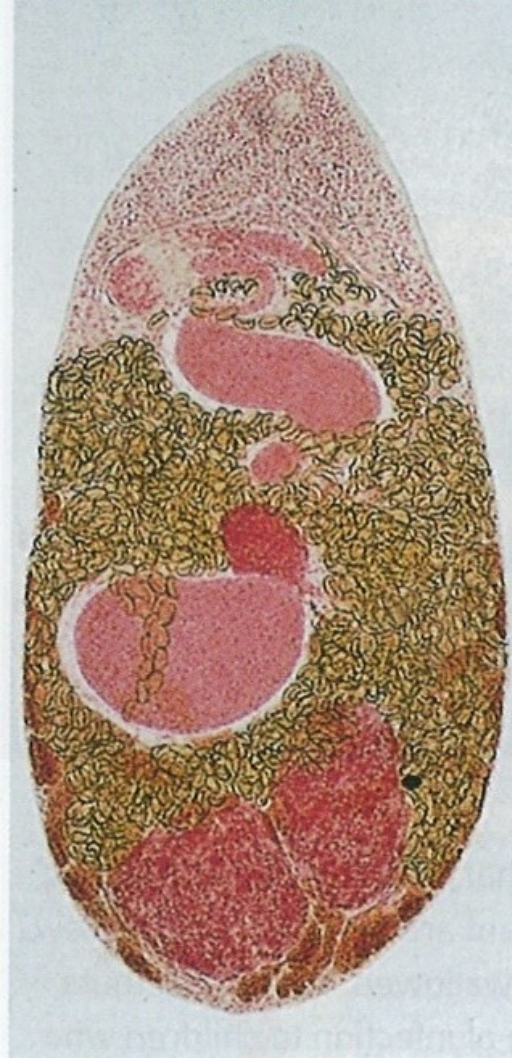Pathology and Clinical features

Causes mild inflammatory reaction in the intestine.
Occasionally ectopic ova can cause granulomata in other organs of the body, especially the liver and brain.

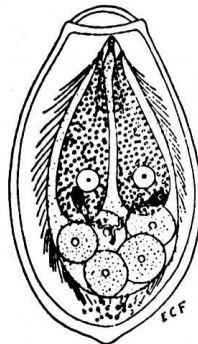
Distribution

Prevalent in the Far East.

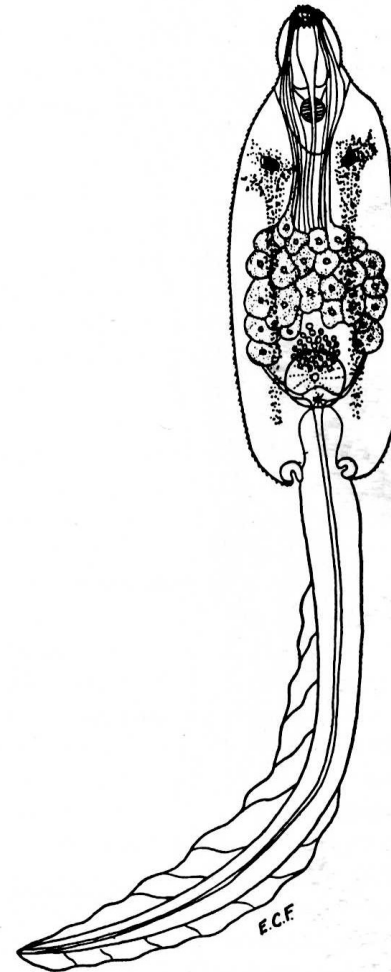
Vývojová stádia



A

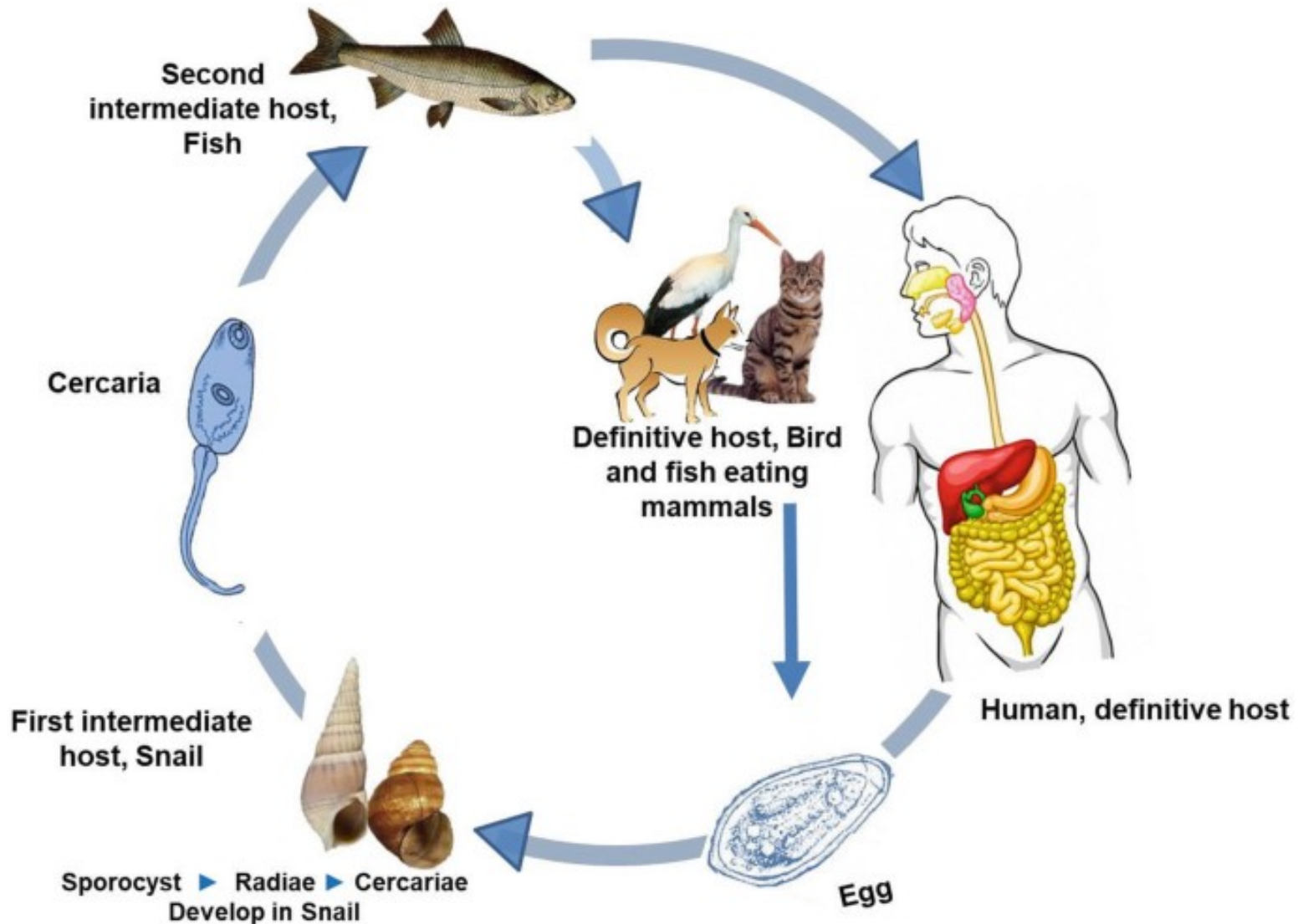


B



C

Životní cyklus *M. yokogawai*



Opisthorchiidae



Opisthorchidae

Charakteristika:

- Cizopasníci žlučového měchýře a žlučovodů savců včetně člověka, (fish-borne diseases)
- Dlouhodobé přežívání – podíl na vzniku karcinomu jater

Vývoj:

- 1 Mz. – předožábří plži (Bithynia) – oculopleurocercárie
- 2. Mz – ryby (svalovina)

Zástupci:

- **Opisthorchis felinus** – severní Evropa, Sibiř
- **Opisthorchis viverrini** – Thajsko, Indočína
- **Clonorchis sinensis** – Čína, Korea, Dalný východ

Clonorchis x Opistorchis

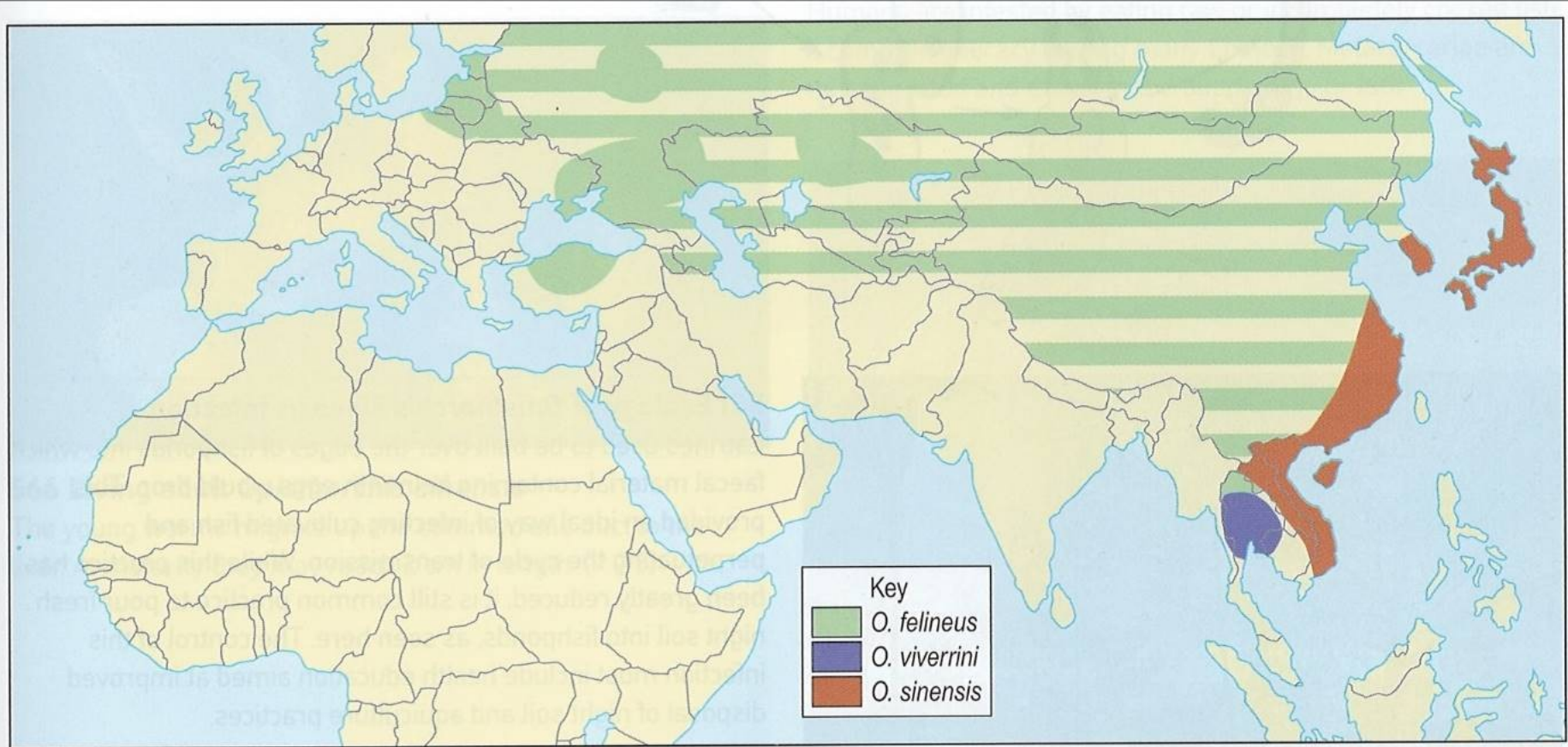
Clonorchiasis and opisthorchiasis

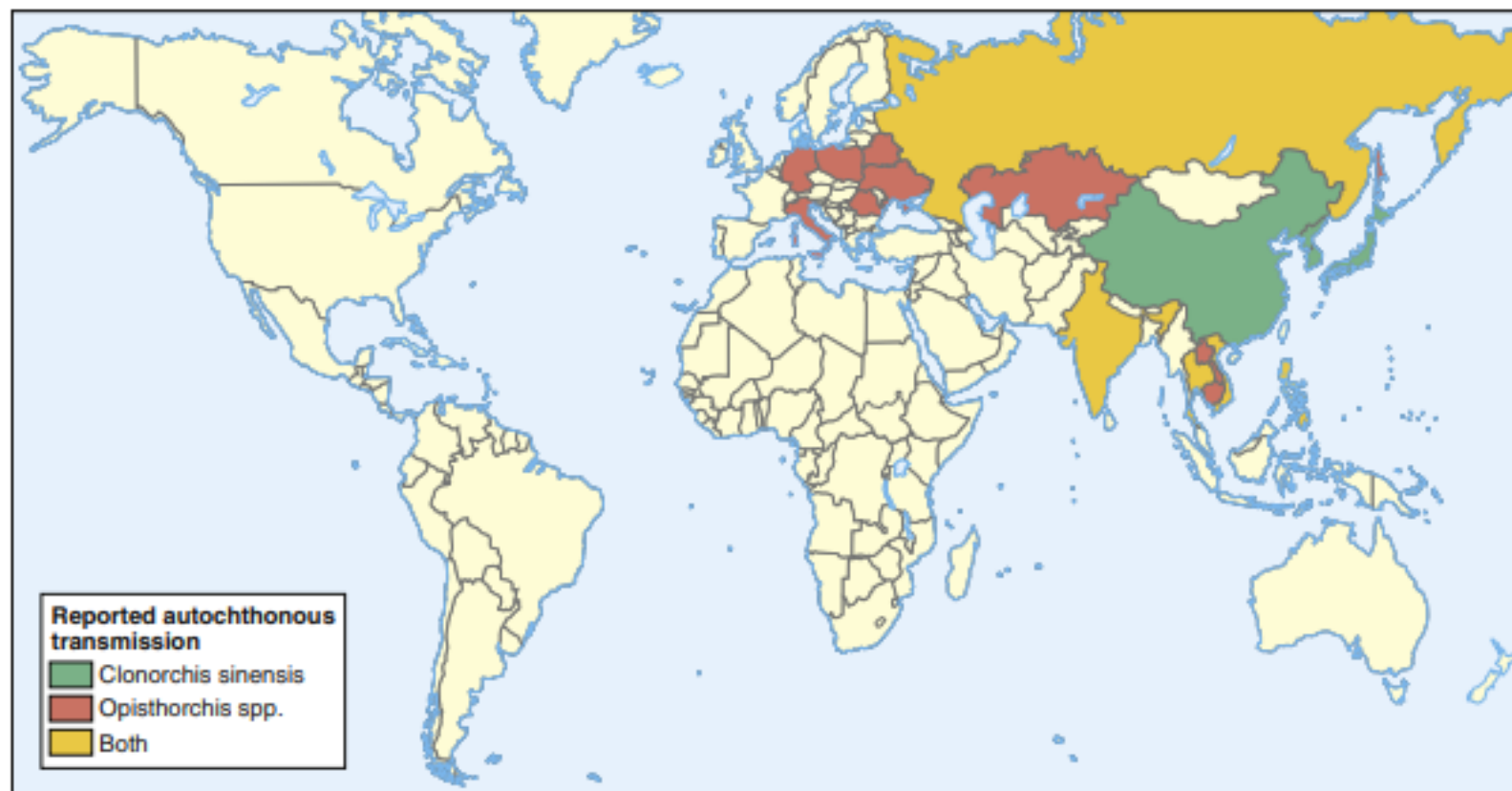

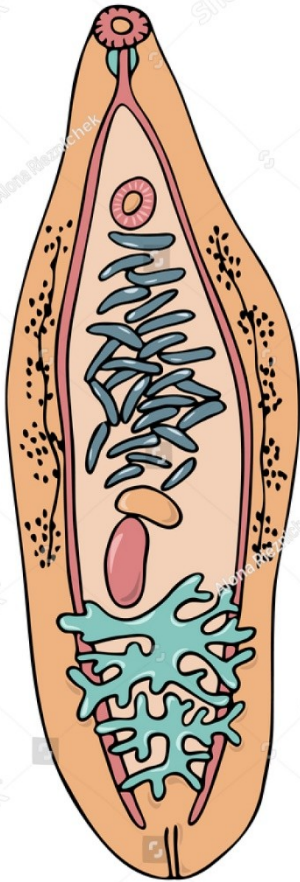
Fig. 3.203 Global distribution of *Clonorchis sinensis*, *Opisthorchis viverrini* and *Opisthorchis felineus*.

This map demonstrates countries reporting autochthonous transmission of various species of liver flukes. *Fasciola* species are not included as they are found worldwide. *C. sinensis* is the commonest liver fluke with an estimated 35 million people infected worldwide, 15 million of whom live in China. *O. viverrini* is predominantly found in South East Asia and India; in Thailand prevalence reaches 15% in some communities. *O. felineus* has a broad distribution stretching from Europe to the Far East with particularly high prevalence in rural fish-eating communities in Siberia. *Metorchis* species have been reported to infect humans in Russia, Greenland and North America but its distribution is currently unclear. (Adapted from Fürst, T., Duthaler, U., Sripa, B., et al. Opisthorchiasis and Clonorchiasis: the oriental liver flukes. *Trematode Infections: liver and lung flukes*. *Infectious Disease Clinics of North America* 2012, Volume 26, Pages 399–419.)

Rozšíření motolic rodu *Opistorchis* u lidí



Opisthorchidae - morfologie



Opisthorchis felinus



Clonorchis

Opisthorchis

Metorchis

Opisthorchis x Clonorchis

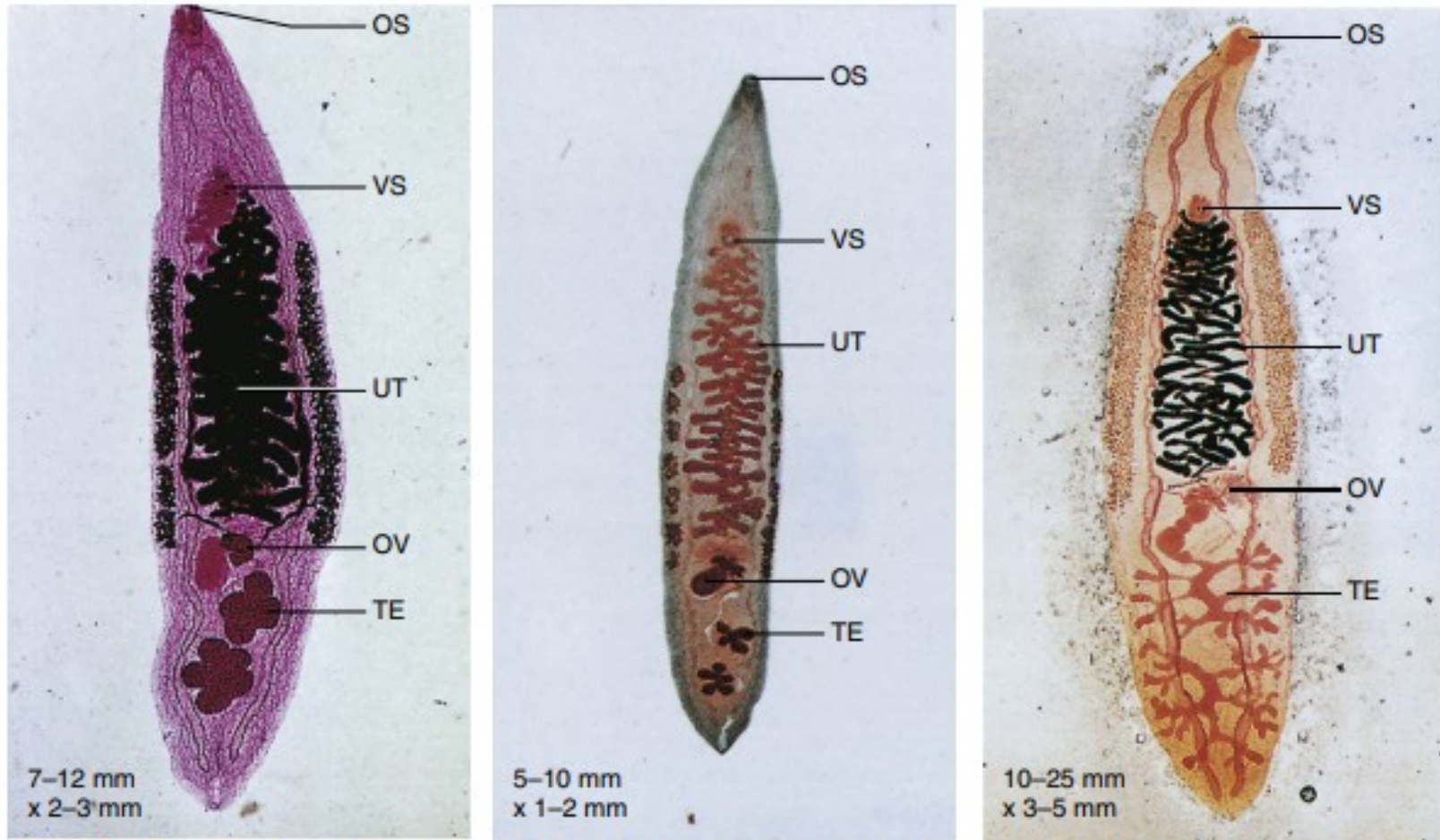
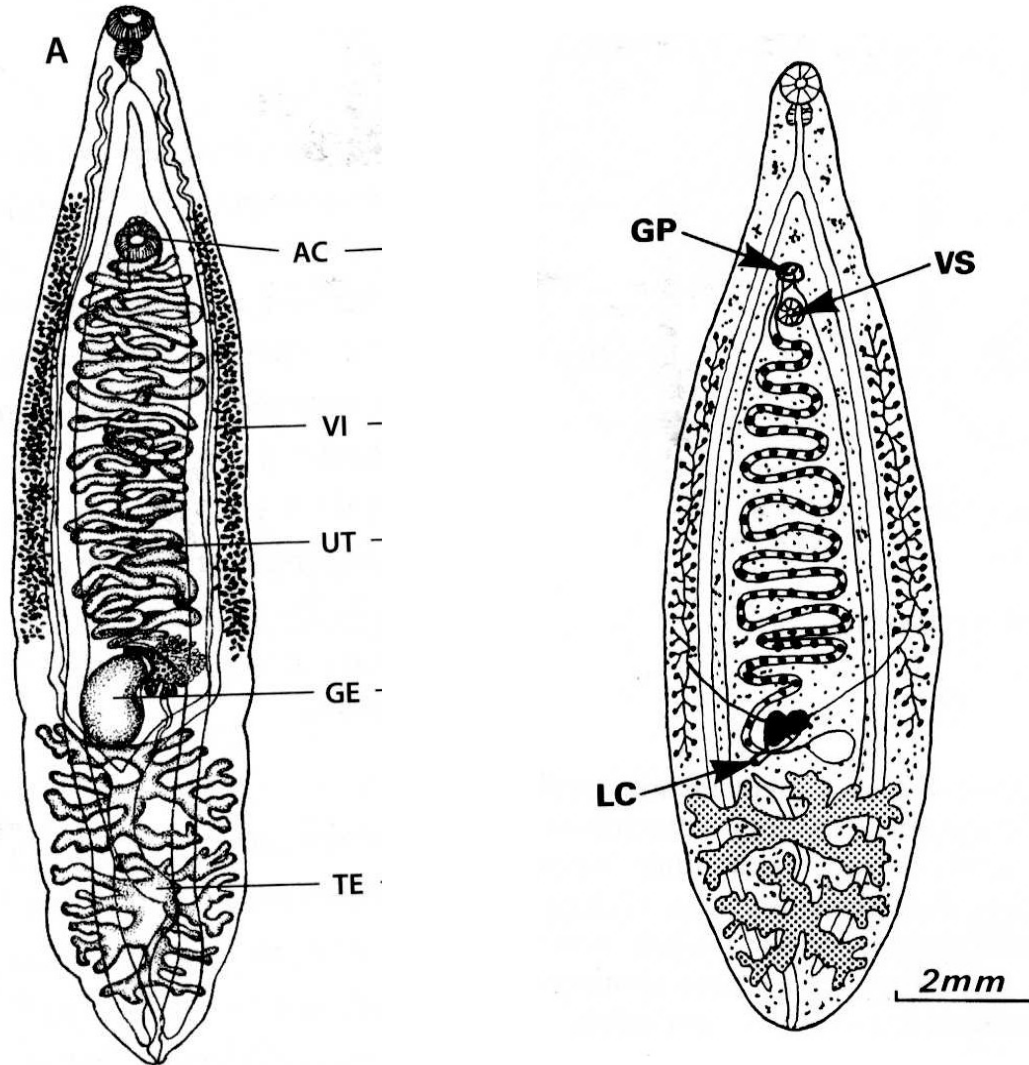


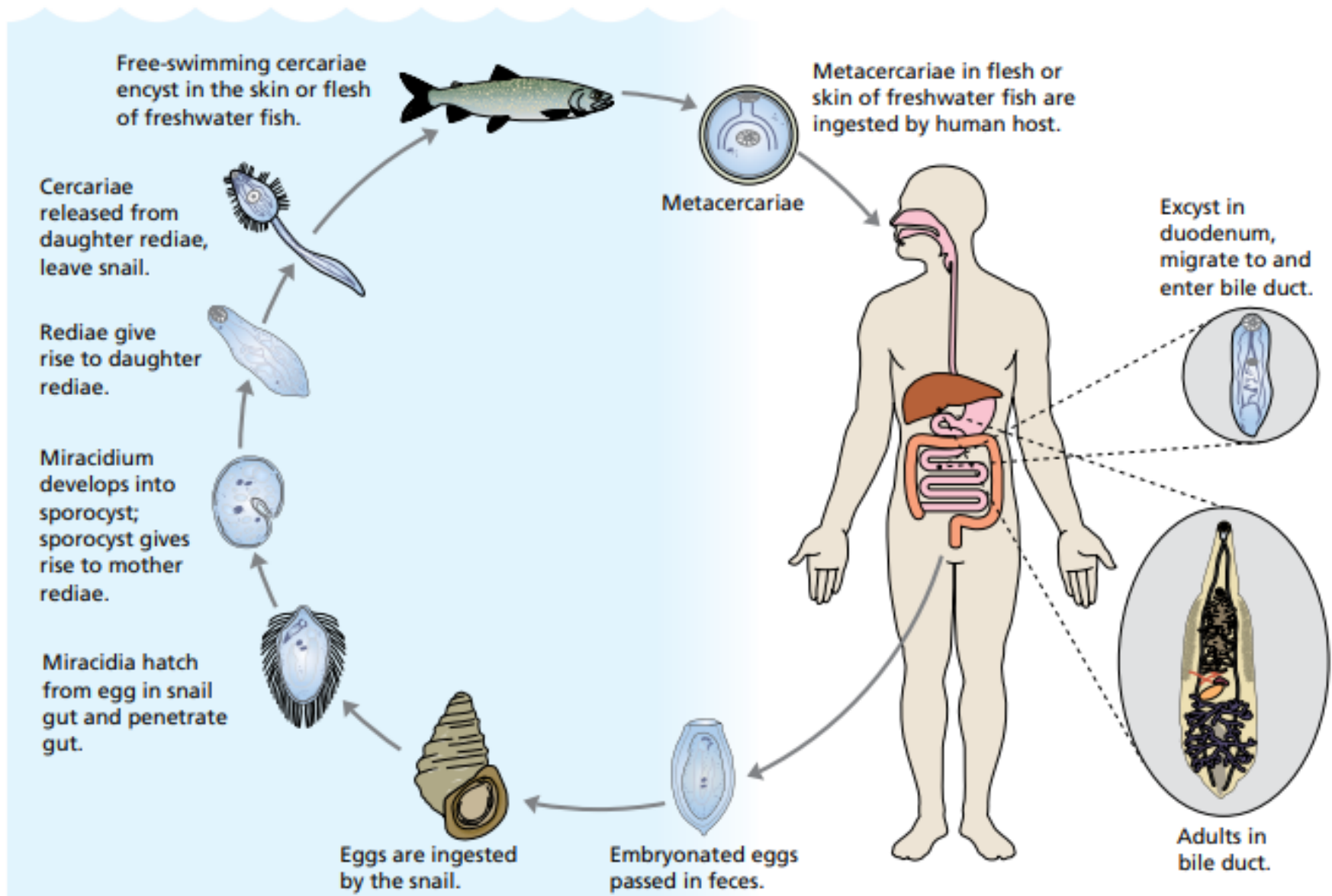
Fig. 3.210-212 Adult flukes of *Opisthorchis felineus* (left, 3.194), *Opisthorchis viverrini* (centre, 3.195), and *Clonorchis sinensis* (right 3.196). All three flukes have a similar life cycle, pathogenesis and egg morphology. However, adult flukes of each species can be distinguished morphologically. Both genera have a ventral sucker that is smaller than the oral sucker. The species differ in their overall size together with the shape of their testes (marked).

Key: OS - oral sucker, VS - ventral sucker, UT - uterus, OV - ovary, TE - testes.

Opistorchis x Clonorchis

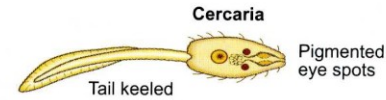
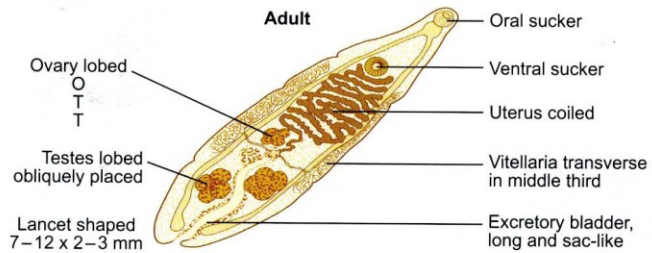


Clonorchis sinensis

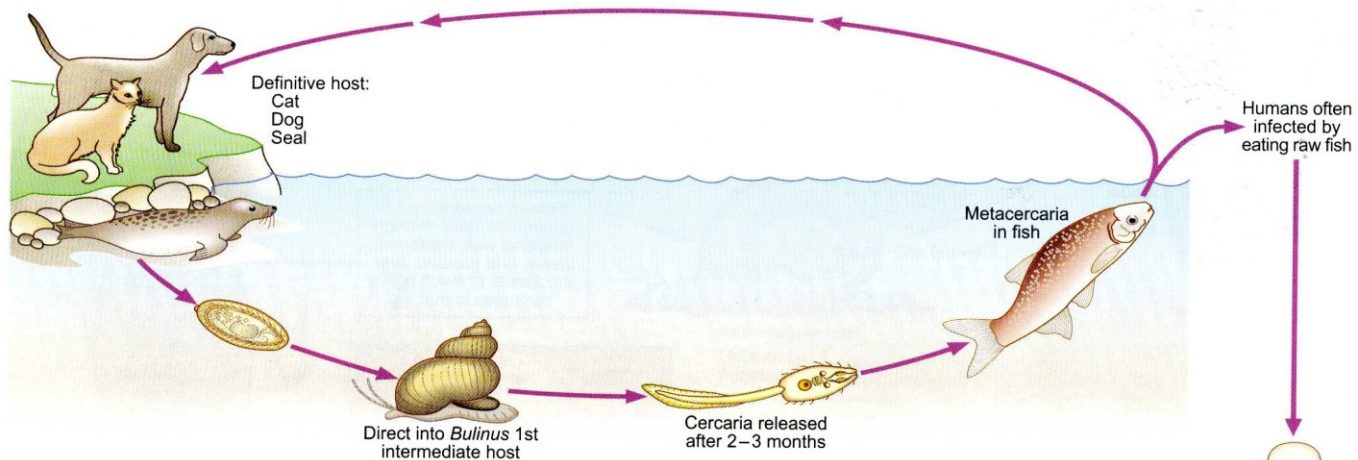


Opisthorchis felineus, *Opisthorchis viverrini* (cat liver fluke)

Morphology



Life cycle



Pathology and Clinical features

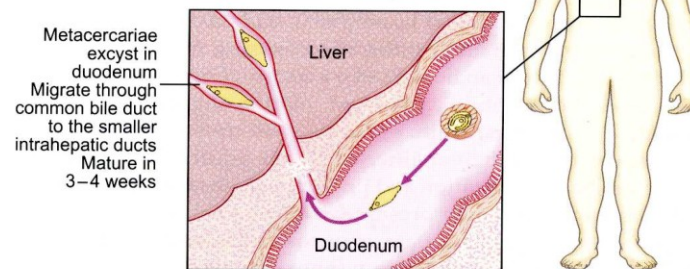
There are proliferative changes in the bile ducts. If the infection is massive or repeated then there may be chronic cholangitis. Clinical features are similar to those of clonorchiasis.

Laboratory diagnosis

Ova can be found in faeces.

Distribution

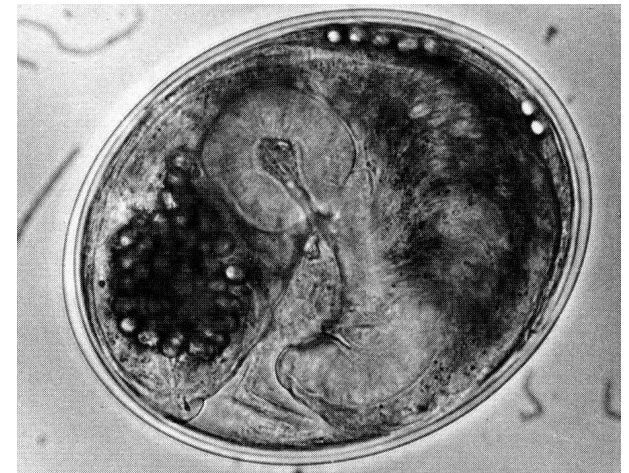
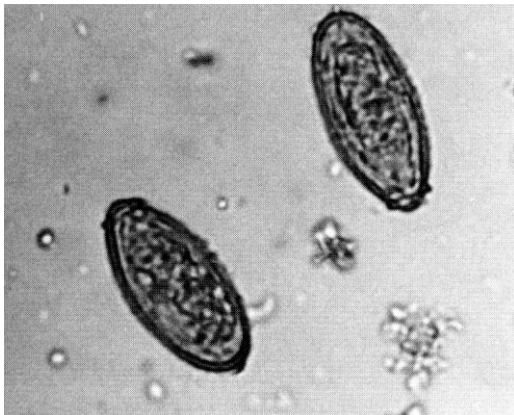
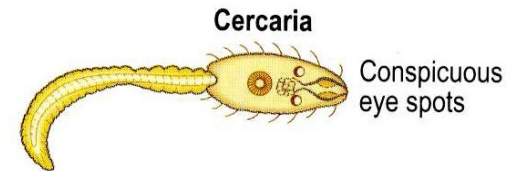
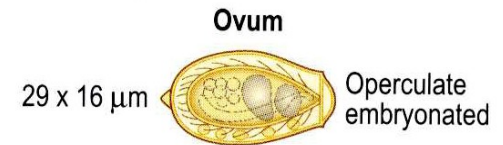
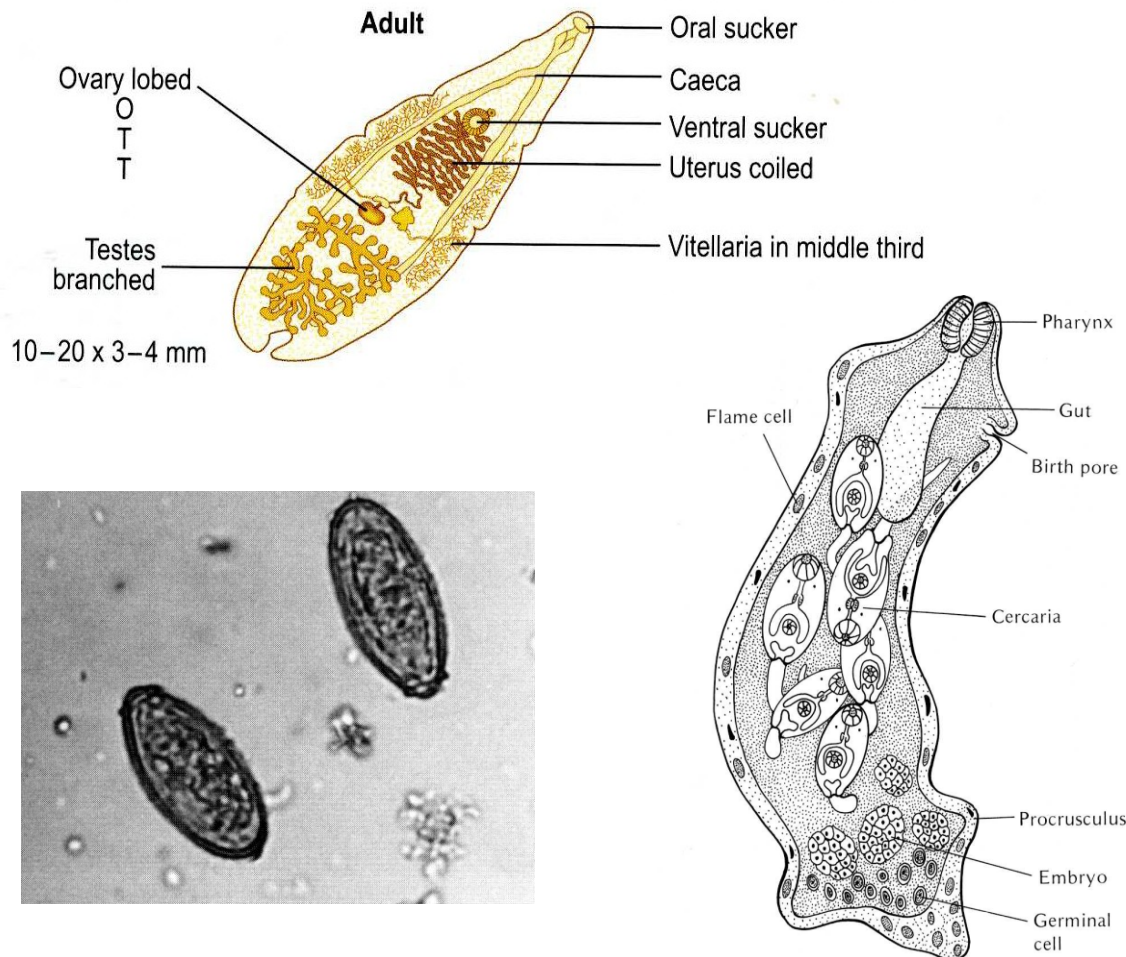
O. felineus is found mainly in Eastern Europe and Russia.
O. viverrini occurs in Thailand.



Clonorchis sinensis

Clonorchis sinensis (continued)

Morphology



Clonorchis sinensis



Fig. 3.205 Intermediate host of *Clonorchis sinensis* and *Opisthorchis* spp.

Bithynia funiculata is an intermediate host of *C. sinensis*, *Opisthorchis* spp. and *Echinostoma* species. (x 3.2.) (Courtesy, Dr S. Vajasthira.)

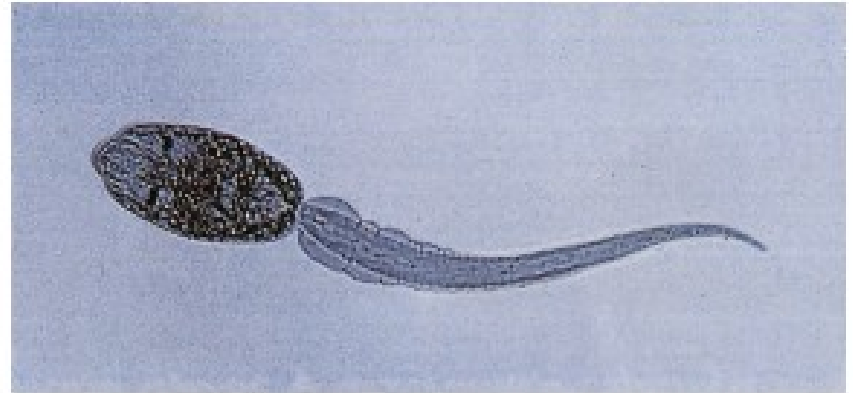


Fig. 3.206 Cercaria of *Clonorchis sinensis*.

Cercariae leave the snail to encyst under the scales of various species of freshwater cyprinoid fish. (x 62.) (Courtesy, Professor M. Suzuki.)



Fig. 3.207 *Ctenopharyngodon idella*.

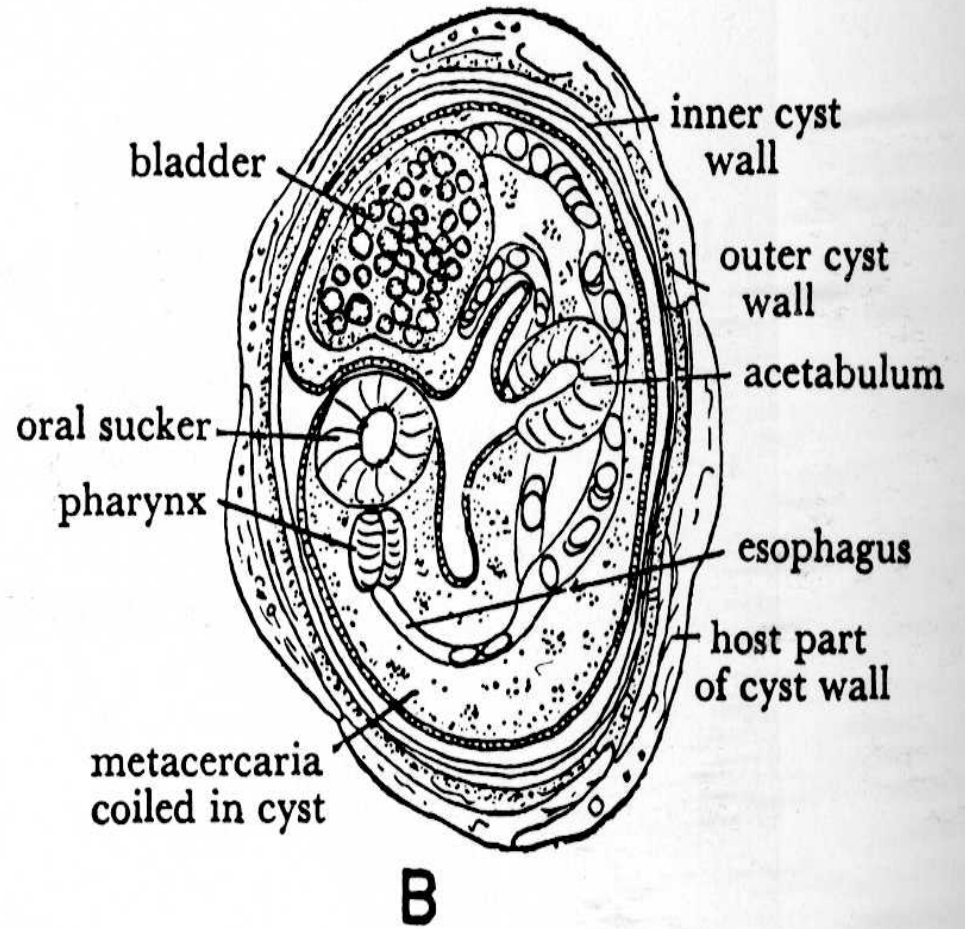
Ctenopharyngodon idella, the grass carp, is a regular host for metacercariae of *C. sinensis* and is a common food product, particularly in China. More than five million tonnes of this fish are produced through aquaculture each year, making it the most commonly farmed fish species worldwide. (Courtesy, Professor S-N. Chen.)

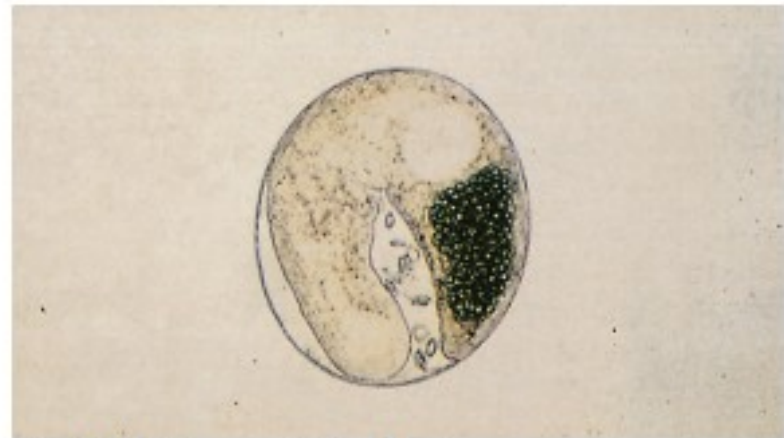

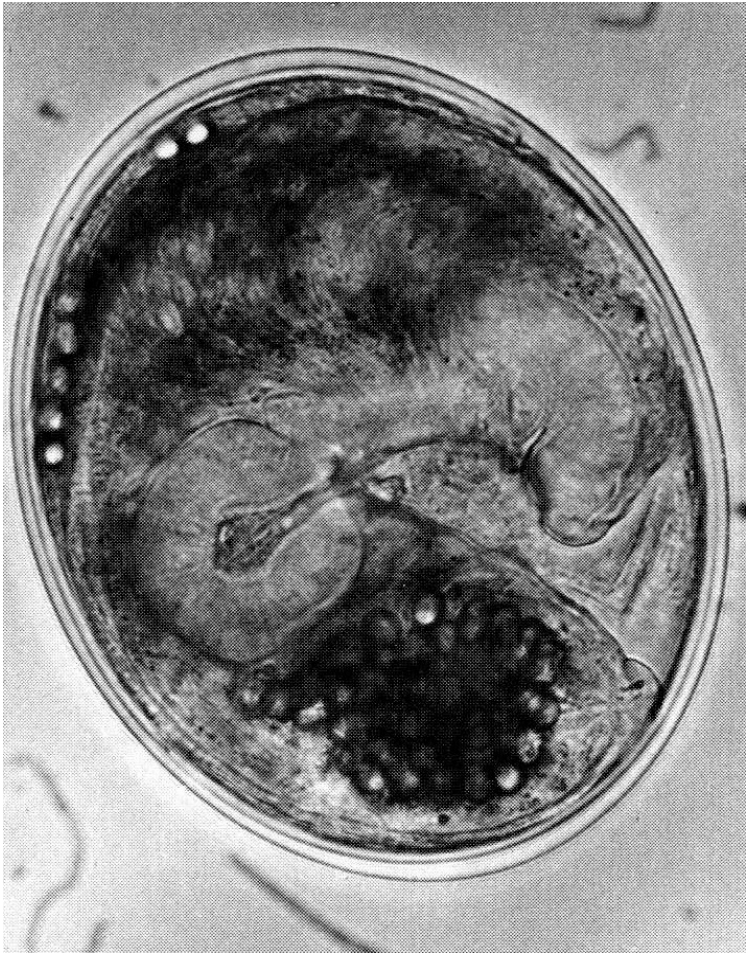Fig. 3.208 Metacercaria in fish flesh.

Humans are infested by eating raw or undercooked fish containing metacercariae. These excyst in the duodenum. (x 160.) (Courtesy, Professor M. Suzuki.)

Metacerkárie



Clonorchis sinensis

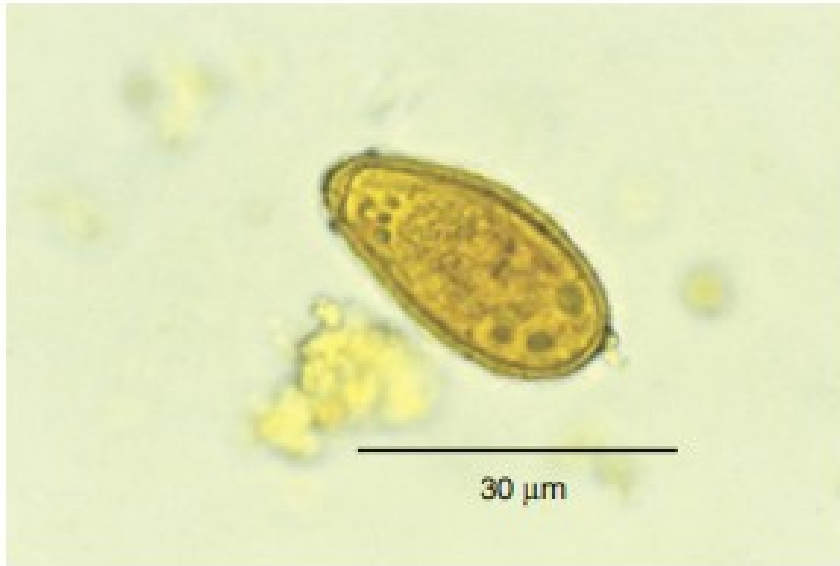


Fig. 3.213 Ovum of *Clonorchis sinensis*.

Ova measure 30 μm x 15 μm and are oval in shape. There is an operculum and a small abopercular knob. (From Fritsche, T. R., Pritt, B. S. Medical parasitology. In: Henry's Clinical Diagnosis and Management by Laboratory Methods. Chapter 63, Pages 1231-1283.e3, Figure 63-22, Panel D.)

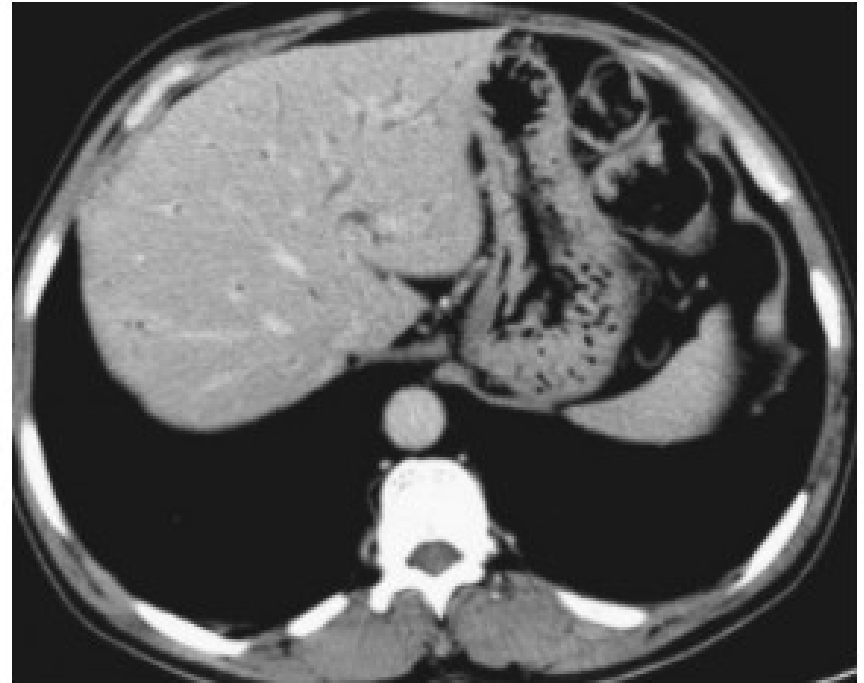
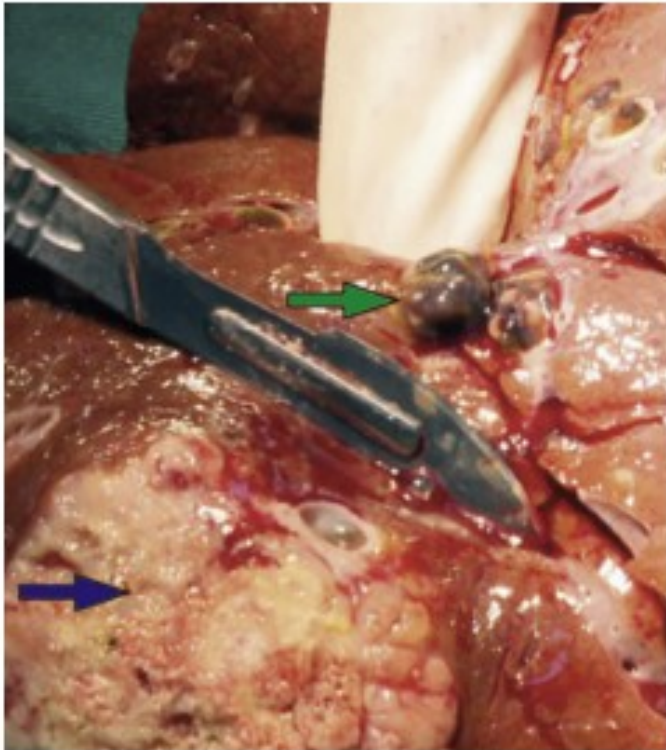


Fig. 3.215 CT changes in *Clonorchis sinensis* infection.

Many infected people remain asymptomatic, although some may develop right upper quadrant pain with biliary tract symptoms. Non-malignant complications include gallstones, cholecystitis, cholangitis and obstructive jaundice. Imaging typically shows dilatation of the peripheral intrahepatic bile ducts, which is diffuse

Clonorchis sinensis



Napadení jater:
vyvolává rakovinu jater
cholangiocarcinom

Fig. 3.217 Liver infected with *Clonorchis sinensis* causing cholangiocarcinoma.

C. sinensis and *Opisthorchis viverrini* are associated with a 5 to 15 times increased risk of cholangiocarcinoma. This is a major public health issue in some areas such as north-east Thailand where cholangiocarcinoma is one of the leading causes of death. There is increasing evidence for the association between *Opisthorchis felinus* and cholangiocarcinoma. Note the cholangiocarcinoma in the lower left corner (blue arrow) and a *C. sinensis* fluke in the upper right corner (green arrow). (From Qian, M.-B., Utzinger, J., Keiser, J., et al. Clonorchiasis. *The Lancet*, 2016-02-20, Volume 387, Issue 10020, Pages 800–810, Figure 2, Panel A.)

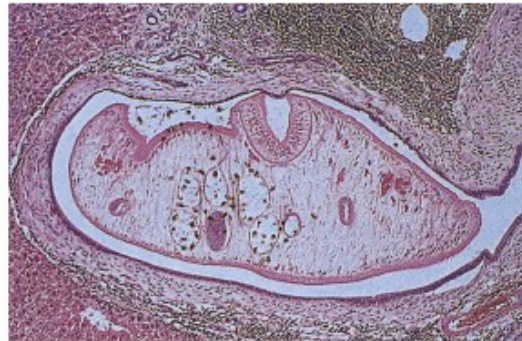


Fig. 3.214 Section of *Clonorchis sinensis* in the bile duct.

Direct mechanical damage, chemical irritation from excreted fluke products and immune-mediated inflammation result in fibrotic changes in the bile duct. (x25.) (Courtesy, Professor S. Lucas.)

Řez žlučovodem

Endoskopický průkaz
cholangiografie (ERCP) u
pacienta napadeného
Clonorchis sinensis

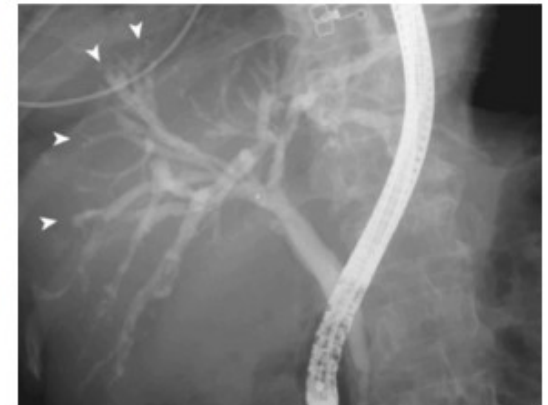
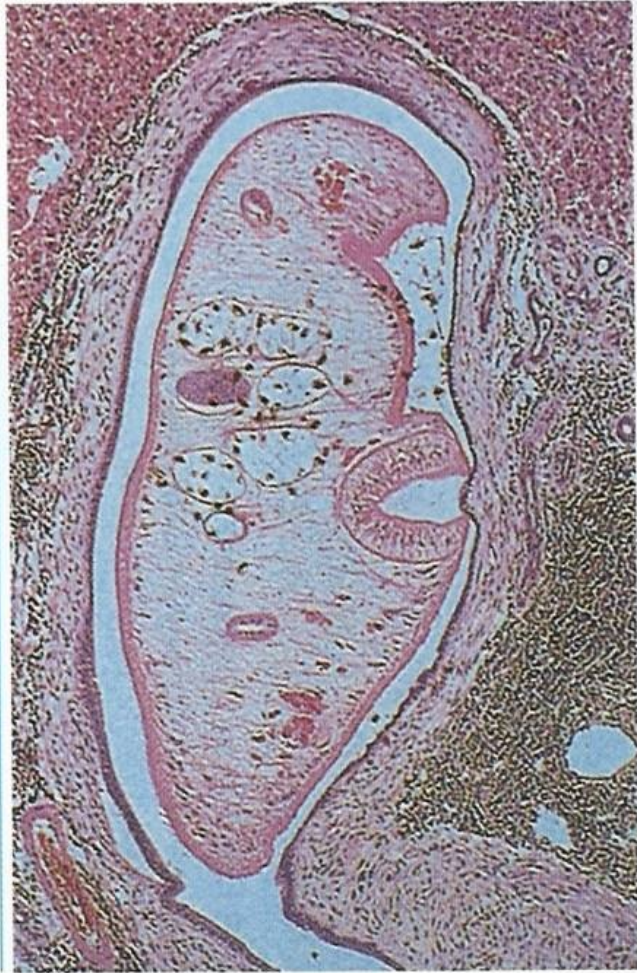
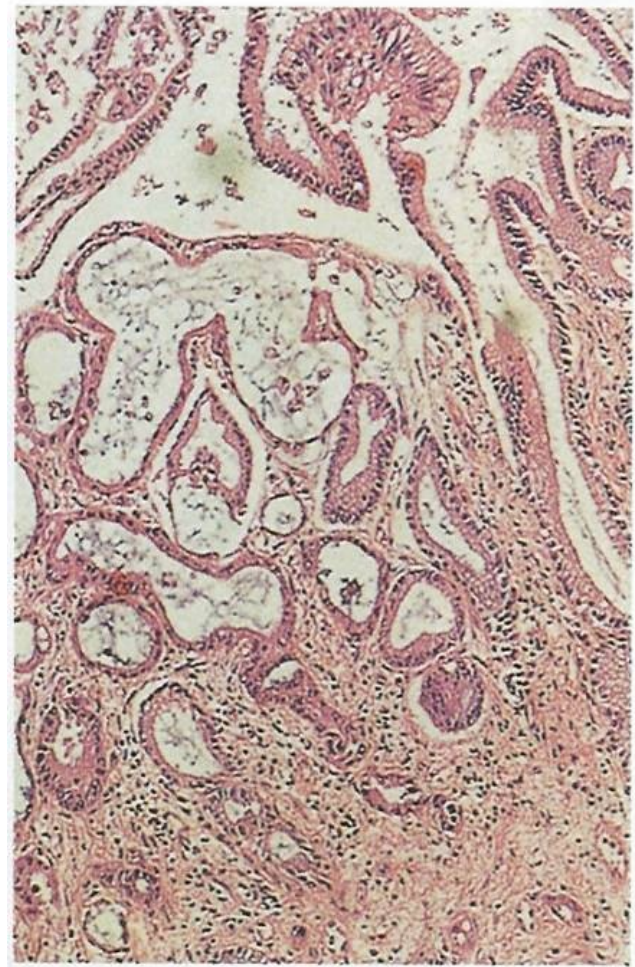
Fig. 3.216 Endoscopic retrograde cholangiography (ERCP) in a patient with *Clonorchis sinensis* infection.

ERCP, or magnetic resonance cholangiography, may reveal small leaflike filling defects measuring 2 mm to 10 mm in the intrahepatic bile ducts, indicated here by arrowheads. (From Lim, J. H., Kim, K. W., Choi, D.-i. Biliary tract and gallbladder. *CT and MRI of the Whole Body*. Chapter 42, Pages 1192–1267, Figure 42-44, Panel A.)

Opistorchis sinensis



O. sinensis ve žlučovodu



O. sinensis – cholangiocarcinom jater

Opistorchis sinensis - ekologie



Ctenopharyngodon idella – 2. mezhostitel



Motolice parazitující v plicích

Paragonimus westermani

Paragonimidae

Charakteristika:

- Plicní cizopasníci

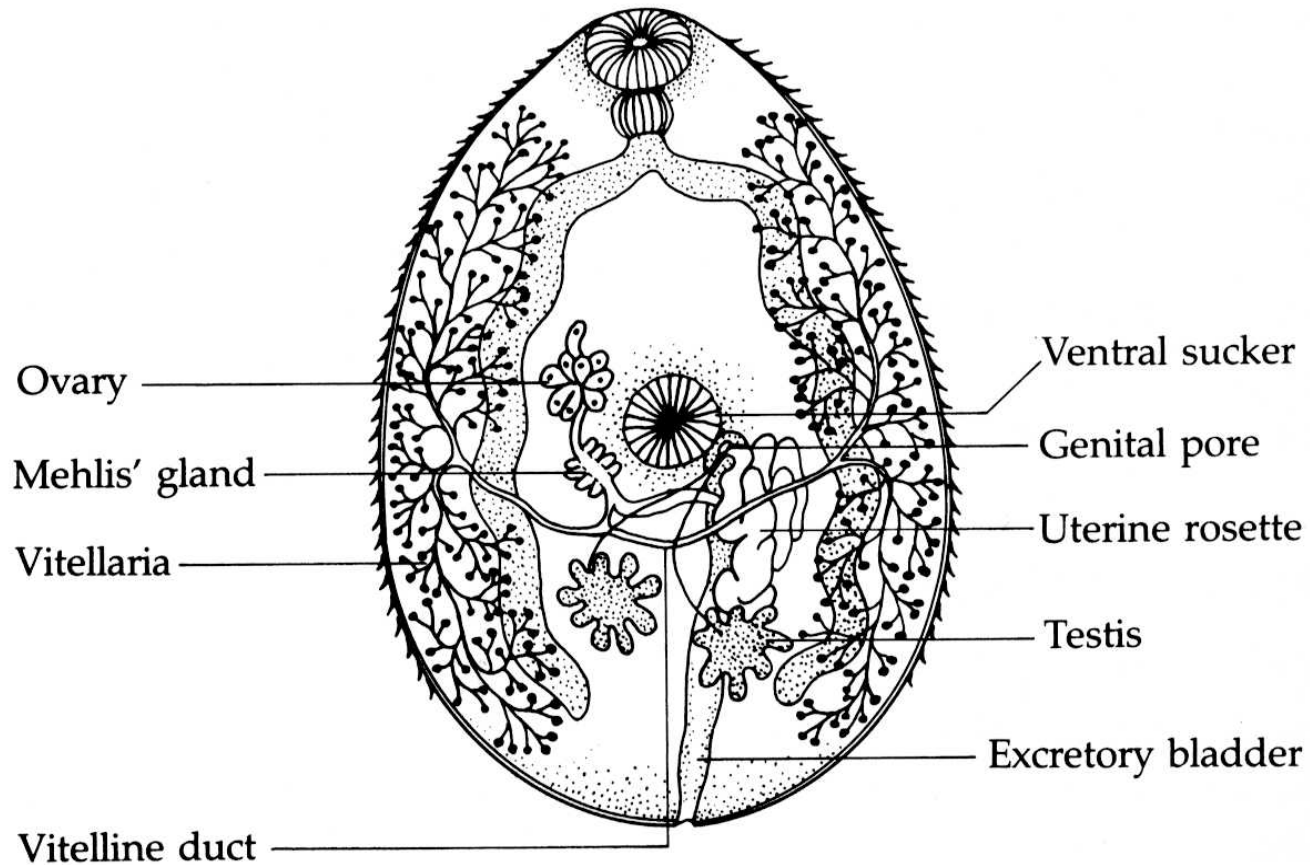
Vývoj:

- 1. Mz – okružáci (Planorbis, Melania) – mikrocerkárie
- 2. Mz – krabi a raci (Astacus sinensis, Eriocheir sinensis)

Zástupci:

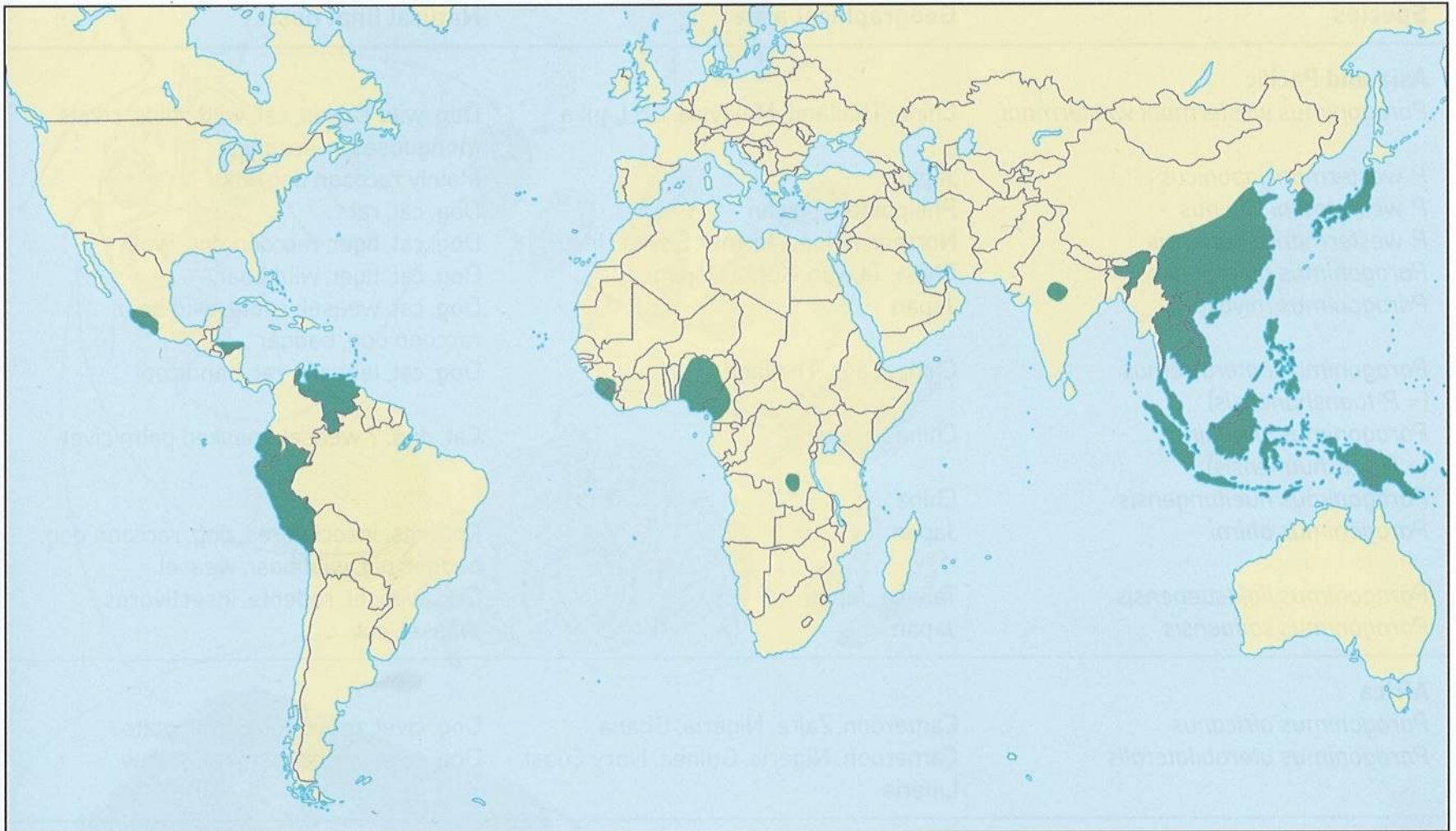
- **Paragonimus westermani** (východní Asie)
 - Šelmy, buvoli, člověk
 - Červi žijí 20 – 30 let
 - Častá záměna s TBC (krvavé sputum), kaverny v plicích až smrt
 - Léčba málo úspěšná

Paragonimus westermani (motolice plicní)

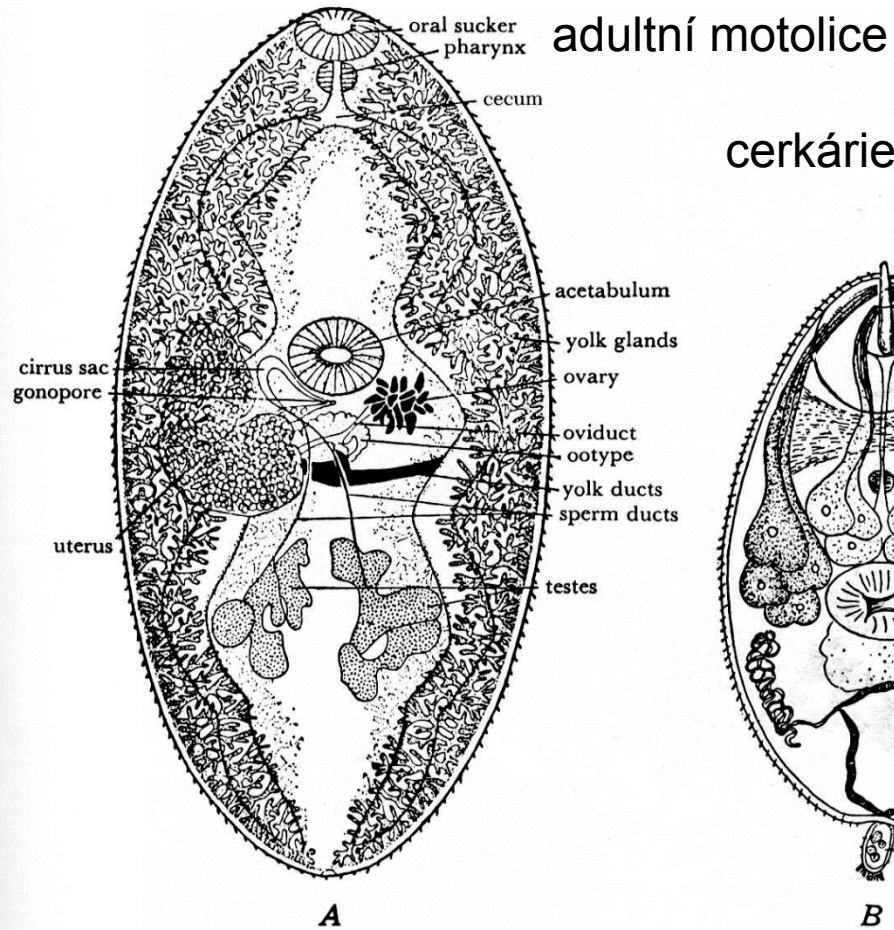
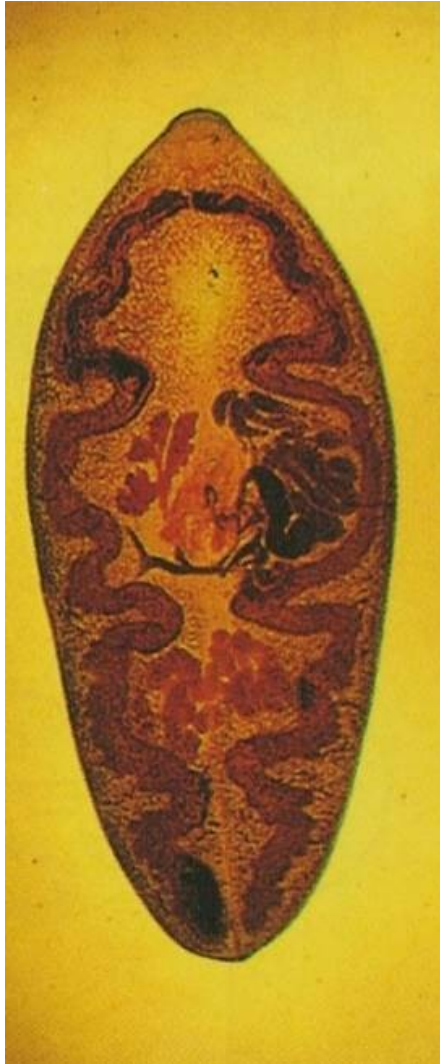


Paragonimus westermani

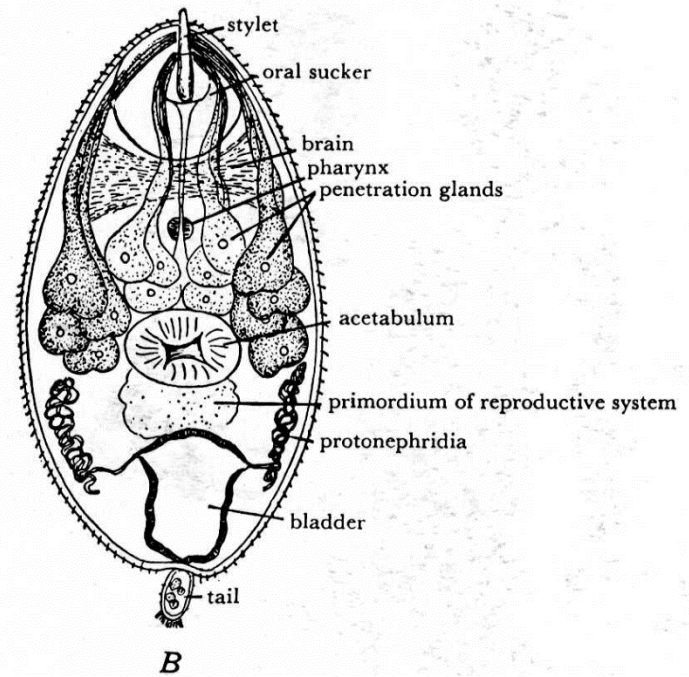
Paragonimiasa – rozšíření podle zemí, olivňuje cca 20 mil lidí, z toho 10 mil v Číně



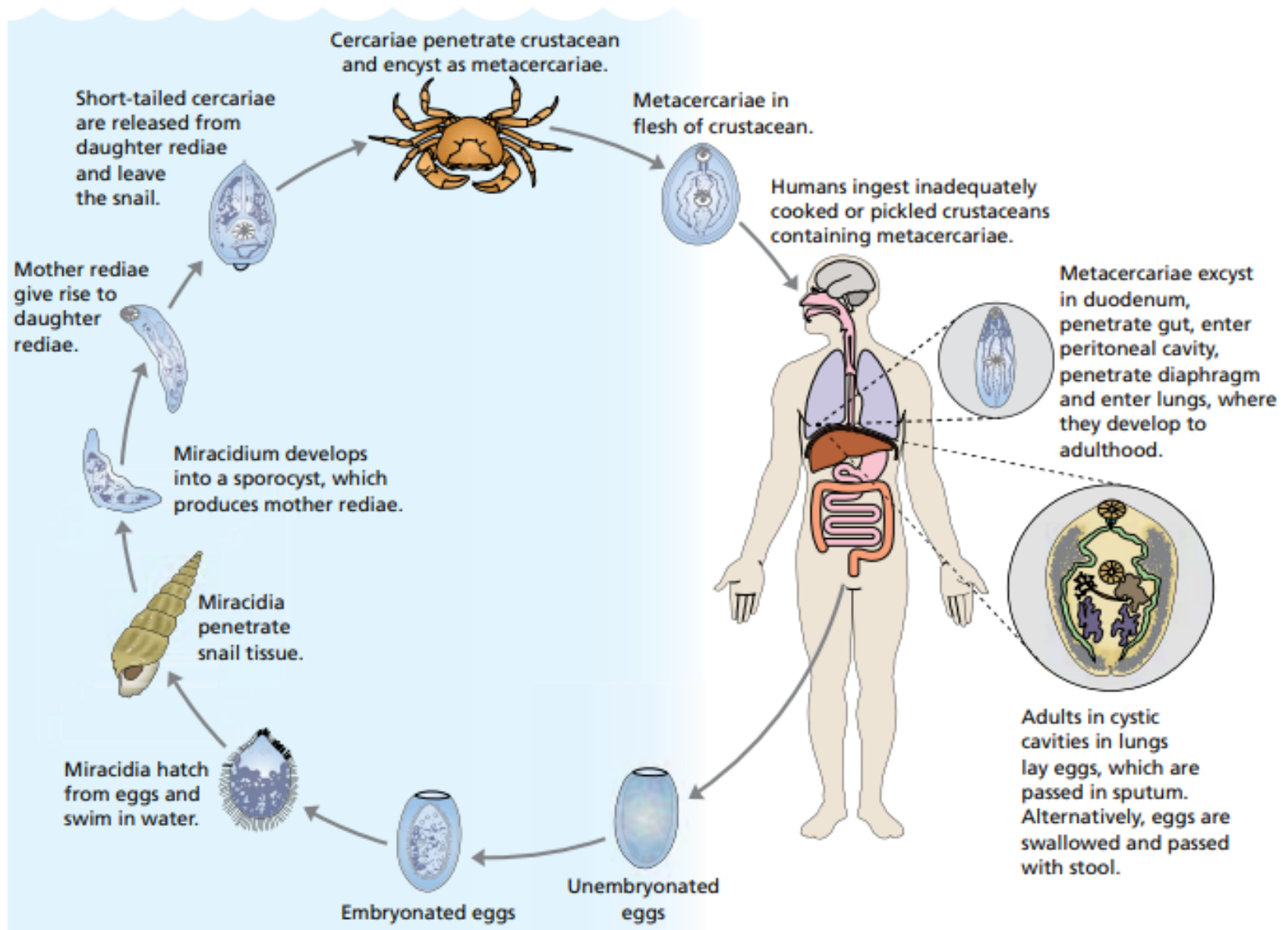
Paragonimus westermani



cerkárie

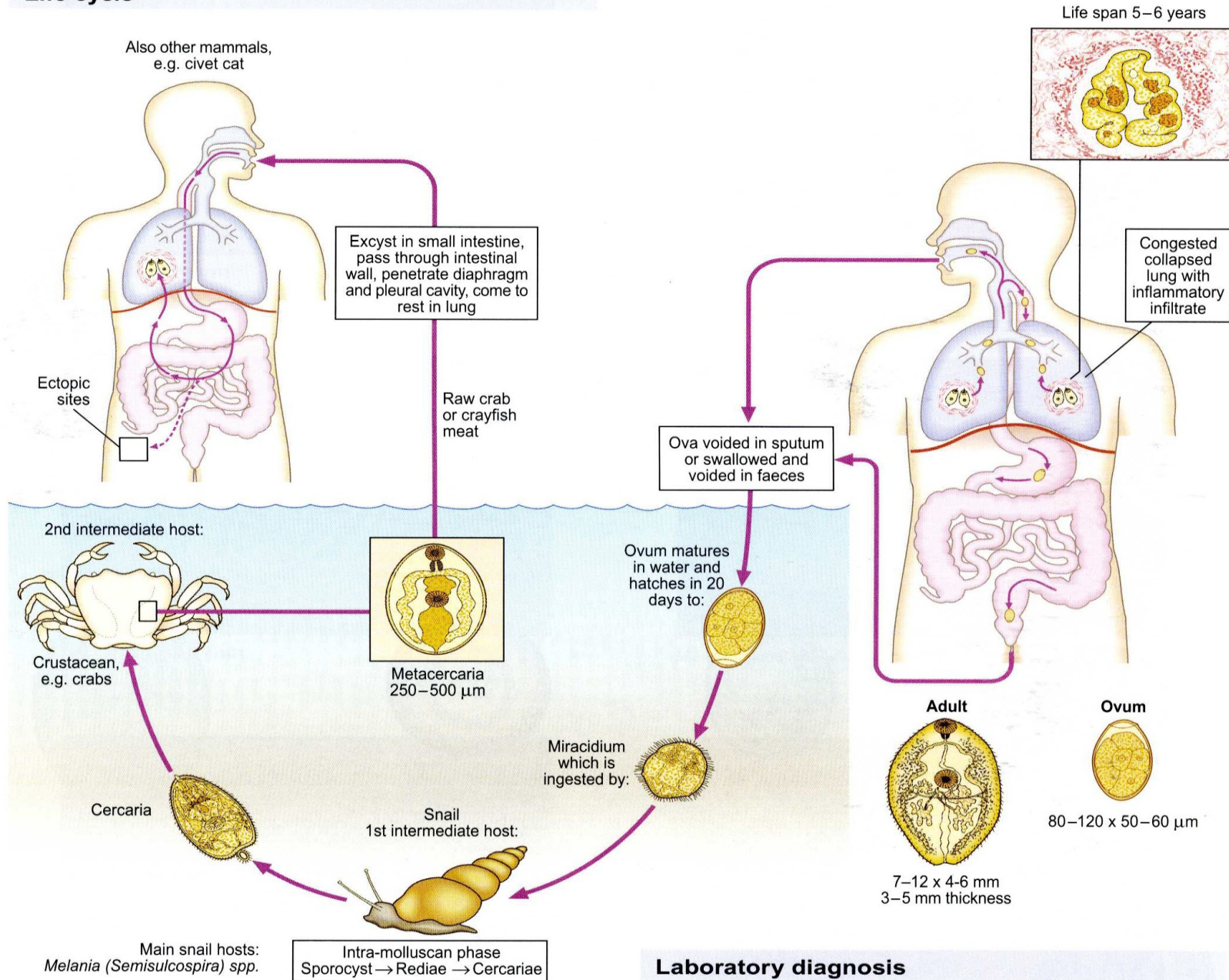


Paragonimus westermani



Paragonimus westermani (lung fluke)

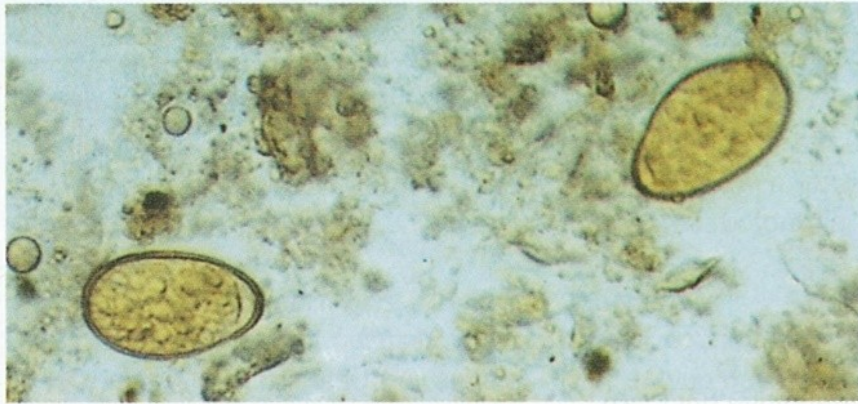
Life cycle



Laboratory diagnosis

Paragonimus sp.

Vajíčka ve sputu



594 Eggs in human sputum

Eggs are passed in the sputum or swallowed to be passed later in the faeces. The miracidia hatching from the eggs penetrate snails of various genera, including *Semisulcospira* and *Thiara* (see **Table 13**). After the usual cycle of development in the snail, microcercous cercariae emerge and encyst inside freshwater crayfish and crabs. Various crab-eating carnivores thus become the natural reservoirs of *Paragonimus* species. (See also **410**.) (× 150)

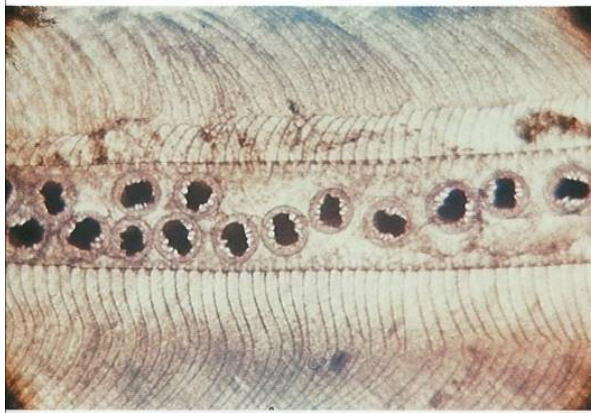
Mezihostitel rak druhu
Procambarus clarkii



596 *Procambarus clarkii*, an intermediate host of *Paragonimus pulmonalis*

This crayfish, which is a popular item of food in parts of Japan, is an intermediate host for the metacercarial stage of this trematode.

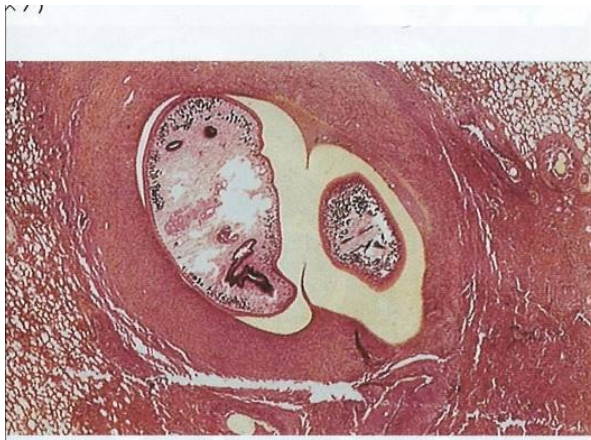
Paragonimus sp.



Metacerkarie v žaberním lupínku kraba *Eriocheir japonicus*



Krab *Ranguna smithiana* –
Mezihostel *P. westermani* v Thajsku



Řez plícemi



Adultní *Paragonimus westermani*

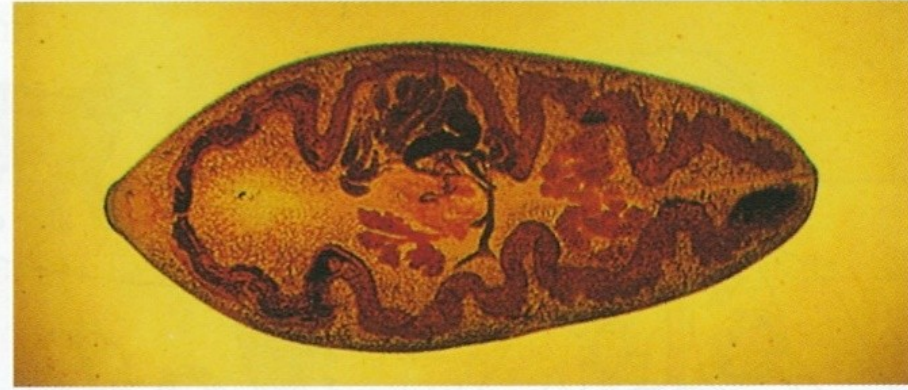
mužské tělo směřuje k hlavě, má dlouhý hřbetní řetězec a neobvyklé
číslo svalů. Má dva páry dlouhých křídel a tři páry
krátkých křídel. Má dva páry dlouhých křídel a tři páry
krátkých křídel. Má dva páry dlouhých křídel a tři páry
krátkých křídel.

Paragonimus westermani



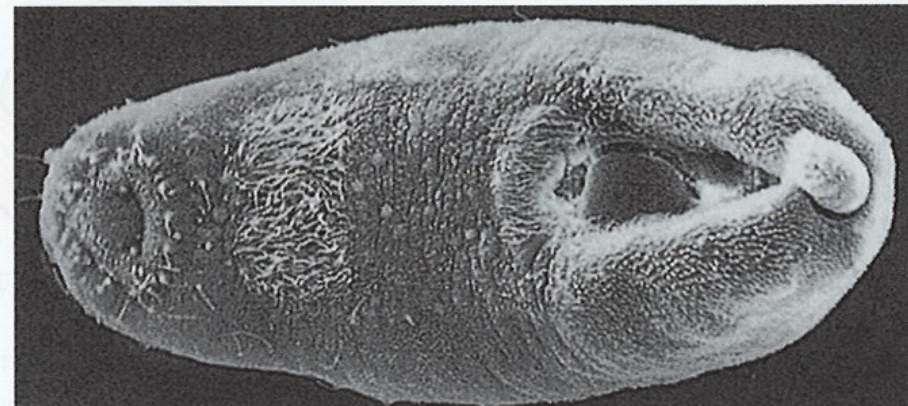592 African civet cat, *Viverra civetta* (Viverridae)

This carnivore is a primary reservoir host for both *P. africanus* and *P. uterobilateralis* in west Africa. The west African long-nosed mongoose, *Crossarchus obscurus*, is also an important host for *P. uterobilateralis* in Liberia as well as being infected by *P. africanus* in countries further east. The palm civet, *Paradoxurus hermaphroditus* (Viverridae) is one of the feral reservoir hosts of *Paragonimus* in Thailand and other Far East countries.

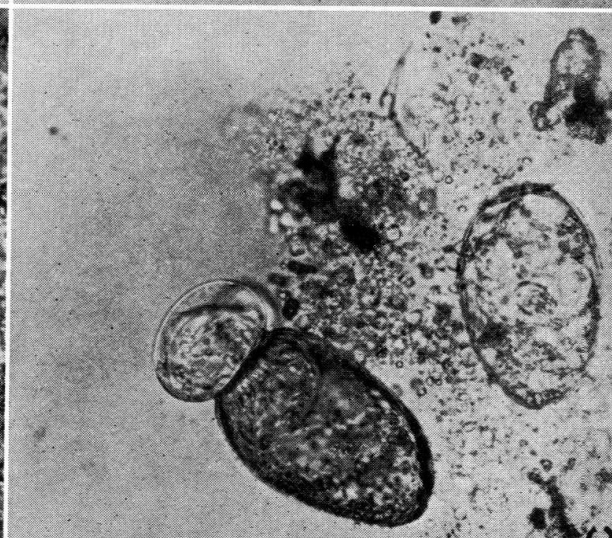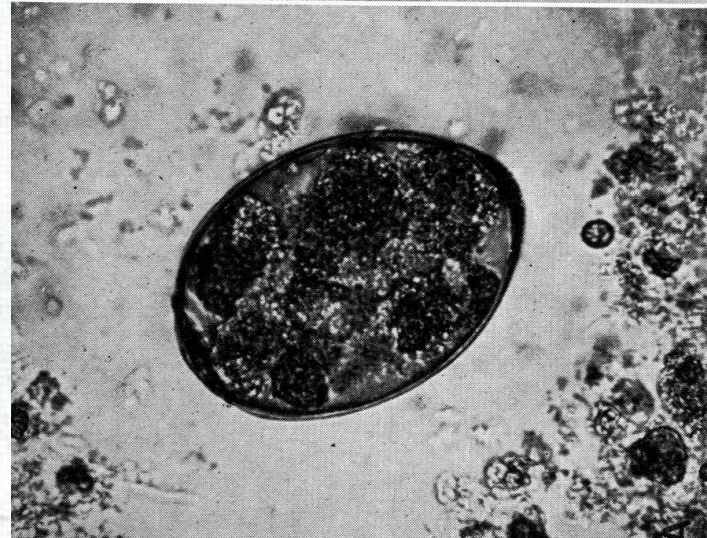
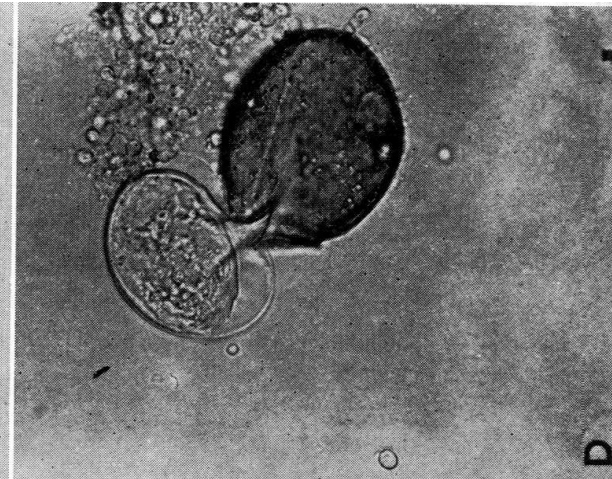
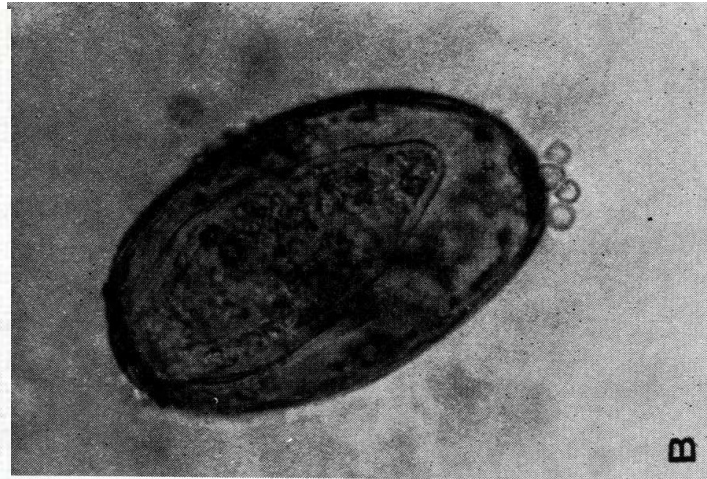

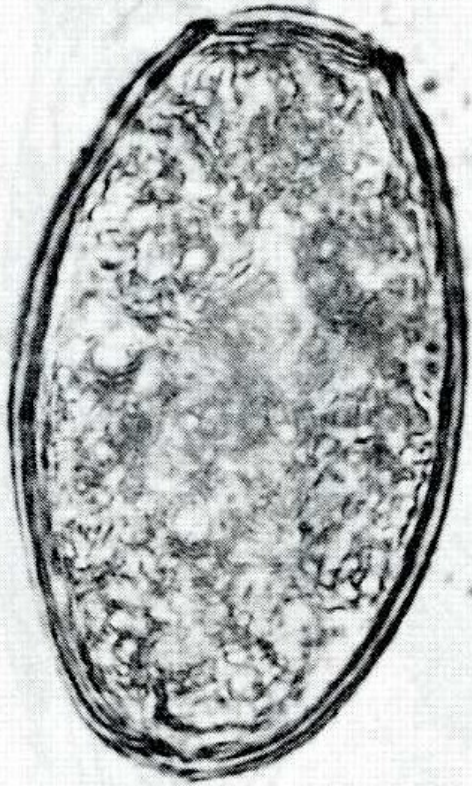
593 Adult *Paragonimus westermani*

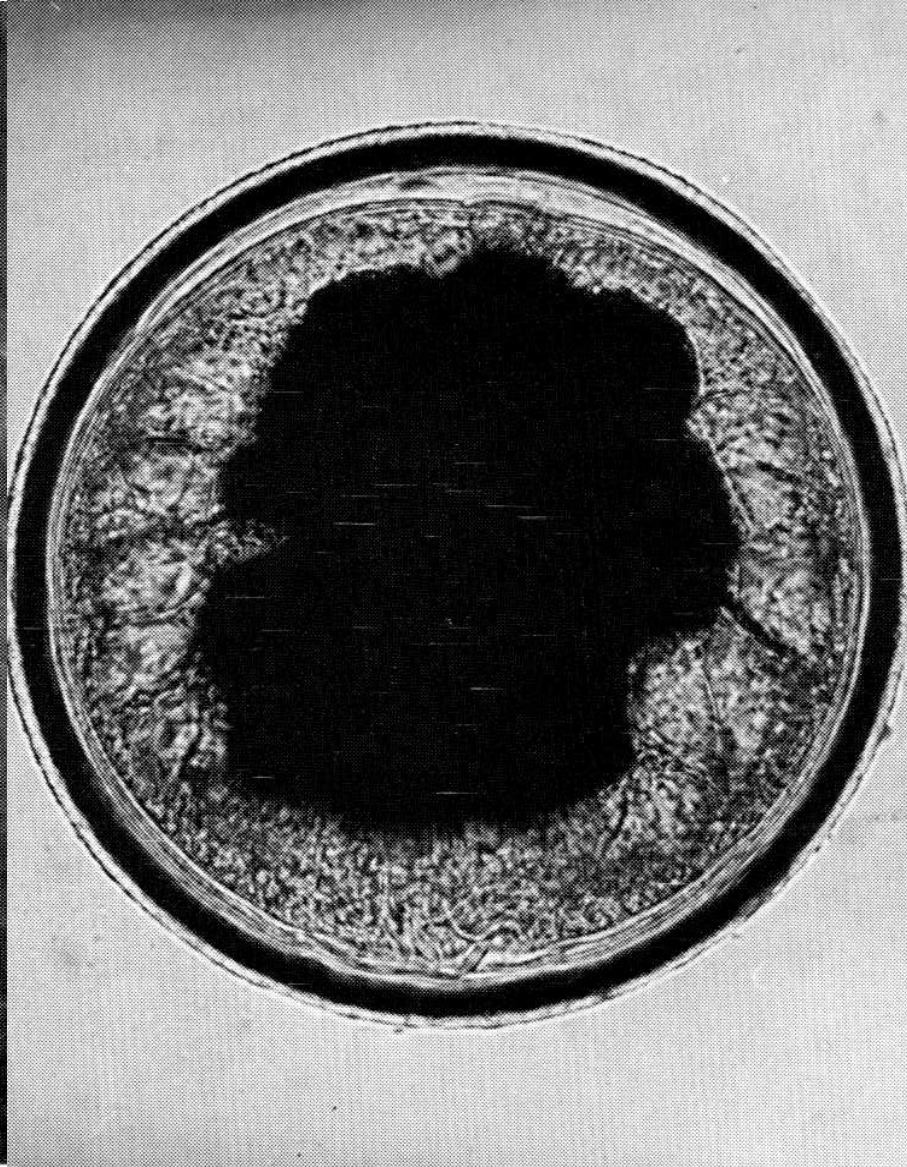
The adult fluke normally lives in the lungs. It is rather lemon-shaped and about 1 cm long when alive (see 600). Preserved specimens, as seen here, become flattened and distorted during preparation ($\times 5.2$).




Líhnutí miracidia z vajíček



Metacerkarie *Paragonimus westermani*



Eriocheir japonicus - mezihostitel



Paragonimus westermani v plicích a v mozku

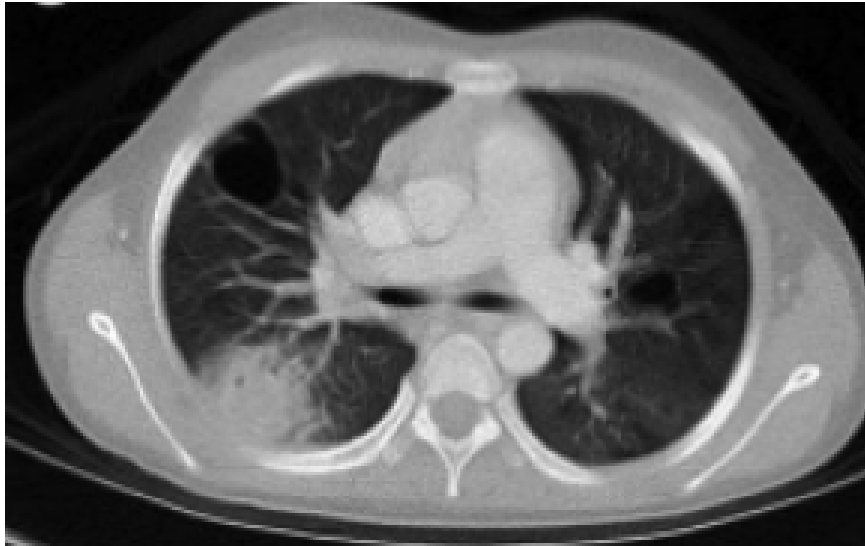

Fig. 3.243 Chronic pulmonary paragonimiasis.

Paragonimiasis is frequently misdiagnosed as tuberculosis (TB), although, in the former, lesions characteristically occur in the mid or lower zones and are peripherally located. This child had been diagnosed with pulmonary TB on the basis of multiple cavitary pulmonary lesions. She subsequently developed seizures and was initially thought to have developed TB meningitis (see Fig. 3.244). Lung biopsy revealed a pulmonary eosinophilia and stool sample was positive for ova of *P. westermani*. (From Kohli, S., Farooq, O., Jani, R. B. et al. Cerebral paragonimiasis: an unusual manifestation of a rare parasitic infection. *Pediatric Neurology*, 2015-03-01, Volume 52, Issue 3, Pages 366-369, Figure 1, panel B.)

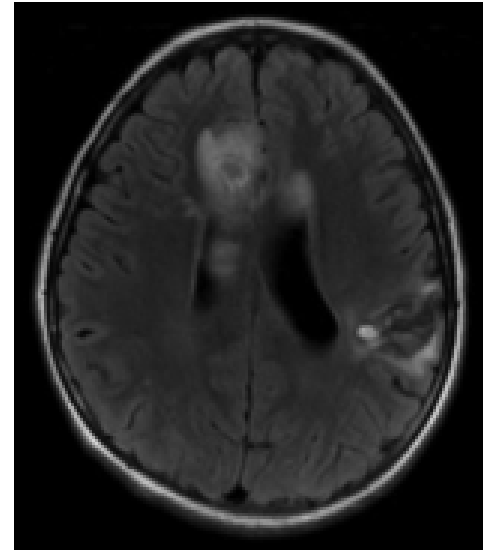
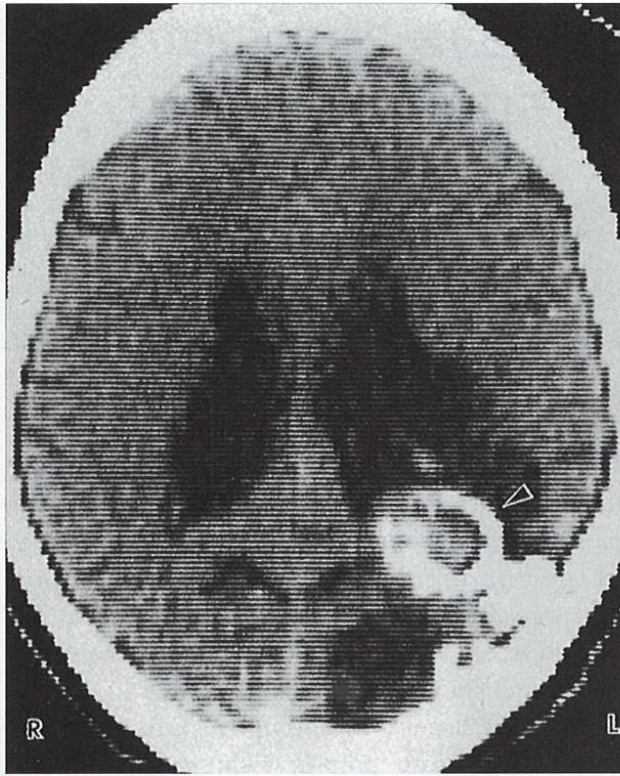


Fig. 3.244 Cerebral paragonimiasis.

Cerebral paragonimiasis, due to ectopic fluke migration, is rare but may have severe consequences. Note the ring-enhancing lesion in the frontal lobe with surrounding oedema and the second lesion in the parietal lobe. Cerebral lesions may mimic tuberculosis, cerebral abscess or neurocysticercosis on imaging. (From Kohli, S., Farooq, O., Jani, R.B, et al. Cerebral paragonimiasis: an unusual manifestation of a rare parasitic infection. *Pediatric Neurology*, 2015-03-01, Volume 52, Issue 3, Pages 366-369, Figure 2, panel A.)

Paragonimus – cysta v mozku



604 Cyst of *Paragonimus* in the brain

This patient, a 59-year-old woman who lived in China as a teenager, presented with a history of epileptic convulsions once or twice a year for over 40 years. They followed an initial pulmonary infection that was probably acquired when she was about 16 years of age. A computed tomography scan revealed a large, calcified mass caused by encystation of an adult fluke, probably *P. westermani*, in the left occipital region. The peripheral brain tissue was shrunken and the left lateral ventricle dilated.



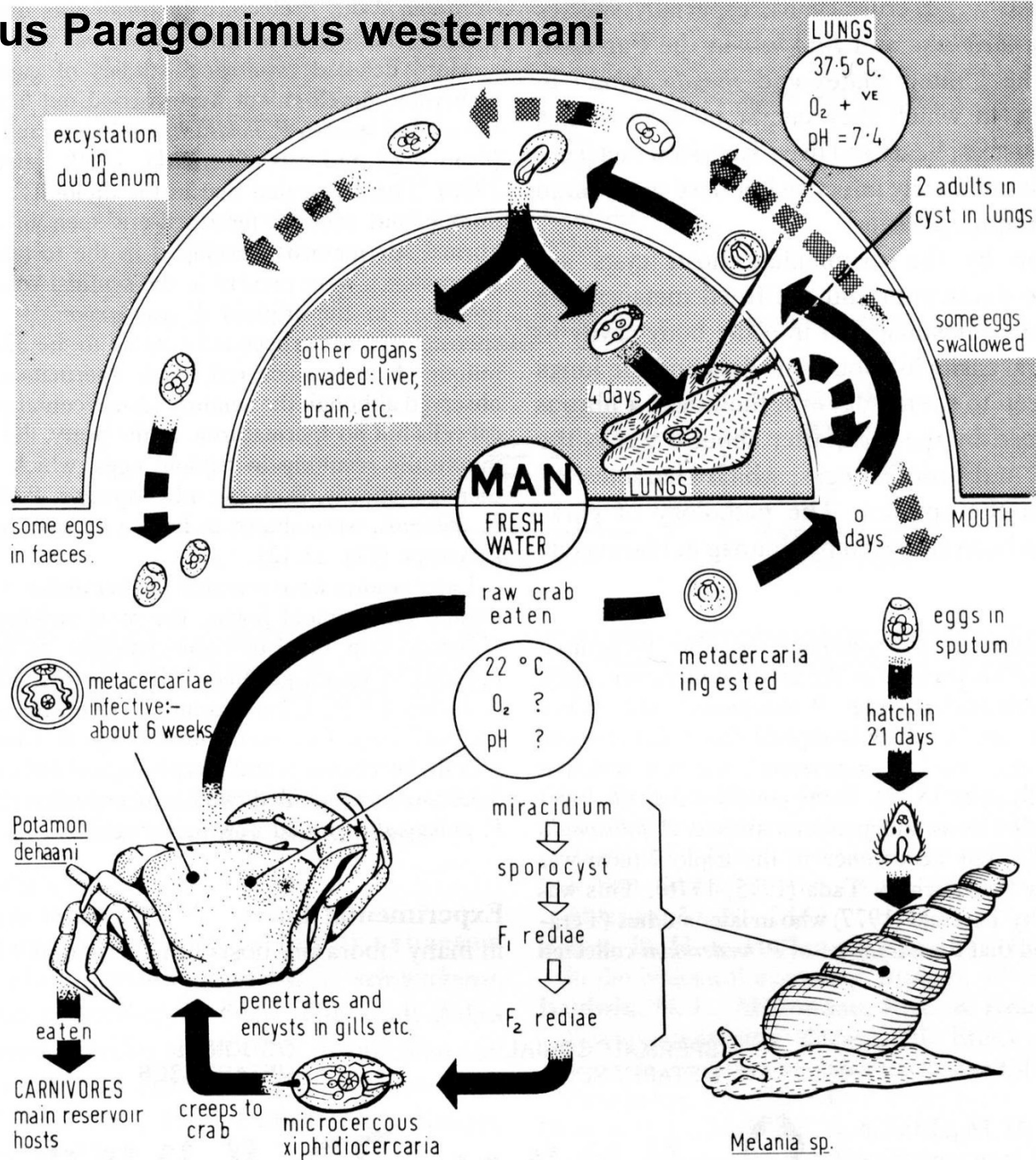
605 *Paragonimus* cyst extracted from brain

A cyst of *P. westermani* found at autopsy in the brain of a 21-year-old Japanese girl. Unlike the patient in 604, such individuals usually present with epilepsy occurring for the first time in adult life.

Paragonimiasis infection is by direct penetration of the skin by the larvae after a period of incubation of the cyst in the soil.

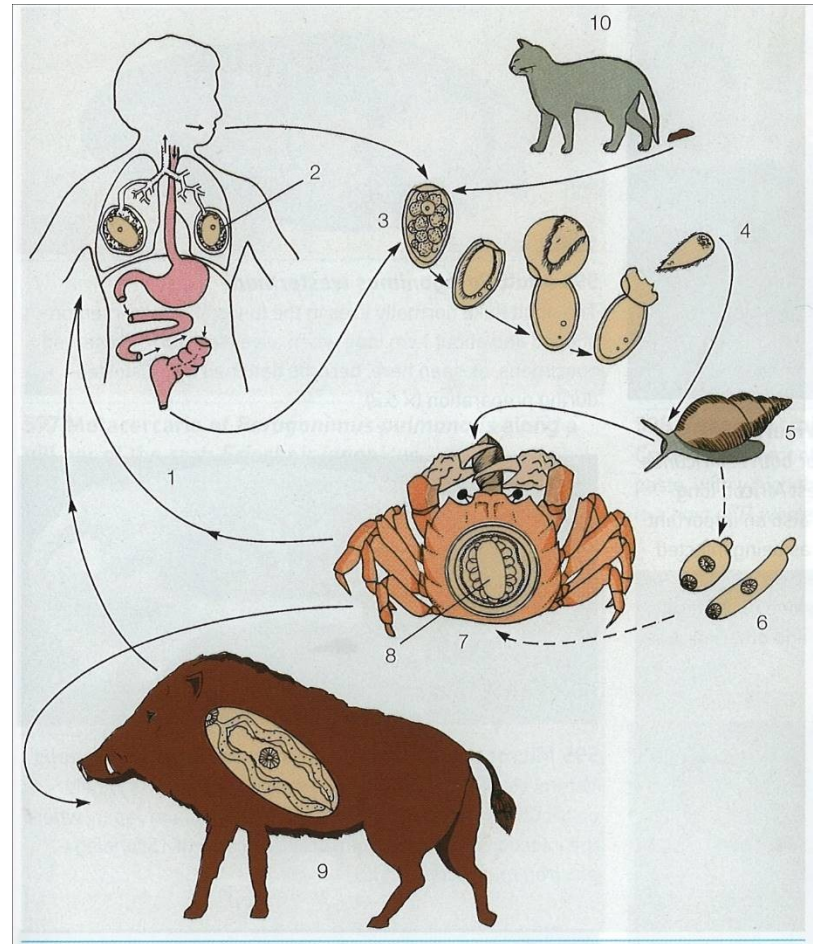
A number of the infections that are acquired through the gastrointestinal tract, such as cholera and typhoid, characteristically occur in epidemic form. The spread of cholera, for example, is facilitated by the potentiating combination of a widespread carrier state with widescale local and international travel. It was feared that the pandemic of the H₁N₁ flu biotype would soon be replaced by the more virulent O:139 serovar, which appeared in south-east Asia in the early 1990s, although so far this has not been realised. Typhoid continues to appear in epidemic form where poor sanitary

Životní cyklus *Paragonimus westermani*

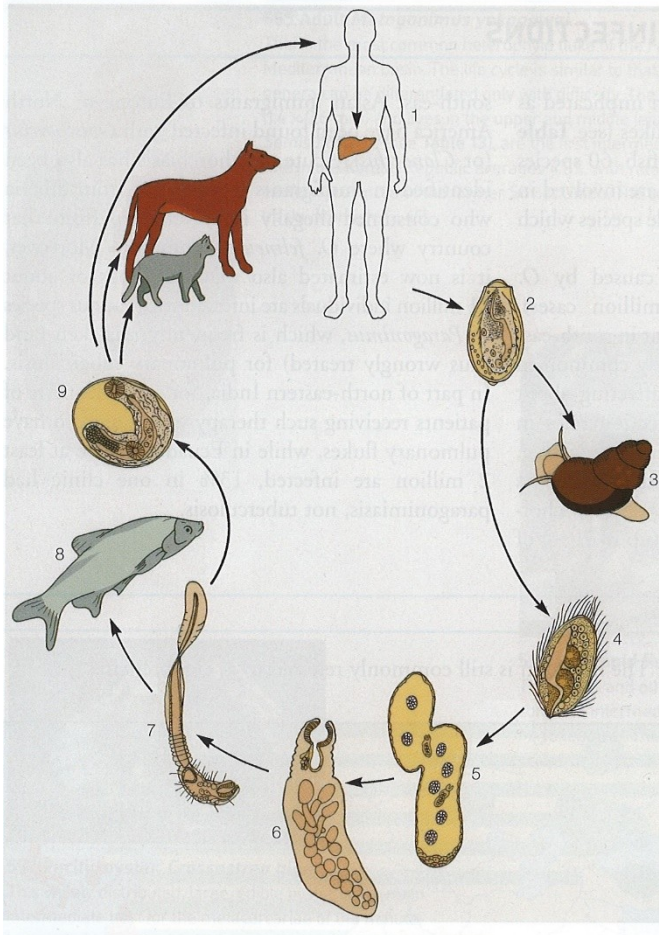


Děkuji za pozornost

Paragonimus westermani - diverzita



Opisthorchis - diverzita



Clonorchis x Opistorchis

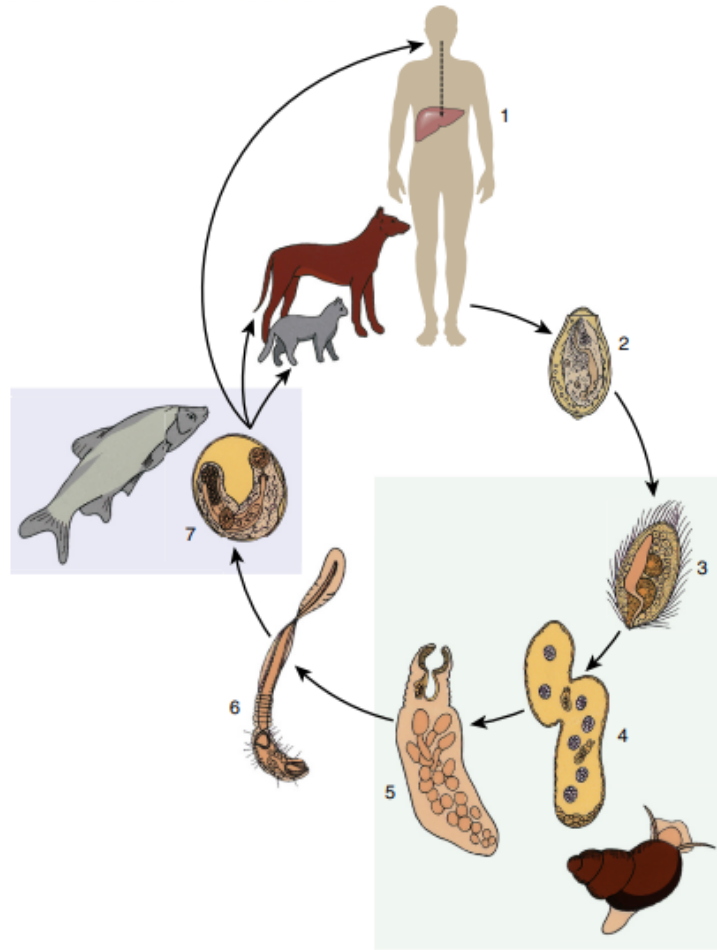
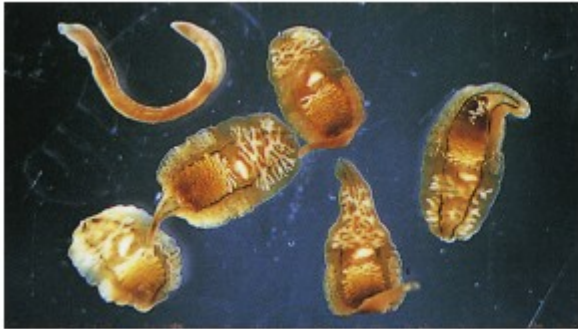

Fig. 3.204 Life cycle of the *Clonorchis sinensis*, *Opisthorchis viverrini* and *Opisthorchis felineus*.

The definitive hosts of *Clonorchis* and *Opisthorchis* species include humans, dogs, cats and other fish-eating mammals. All three flukes have a similar life cycle and pathogenesis. Adult flukes live in small peripheral intrahepatic bile ducts (1), producing embryonated eggs which are passed in faeces (2). When ingested by a snail host, the eggs hatch releasing miracidia (3). Within the snail, these develop into sporocysts (4) then rediae (5) which multiply and become cercariae (6). These leave the snail and penetrate the skin of freshwater fish, encysting within the flesh to form metacercariae (7). When consumed raw by a carnivore, the immature flukes emerge, migrating through the ampulla of Vater, up the bile ducts and eventually settling to mature in the small peripheral branches of the biliary tree (1).

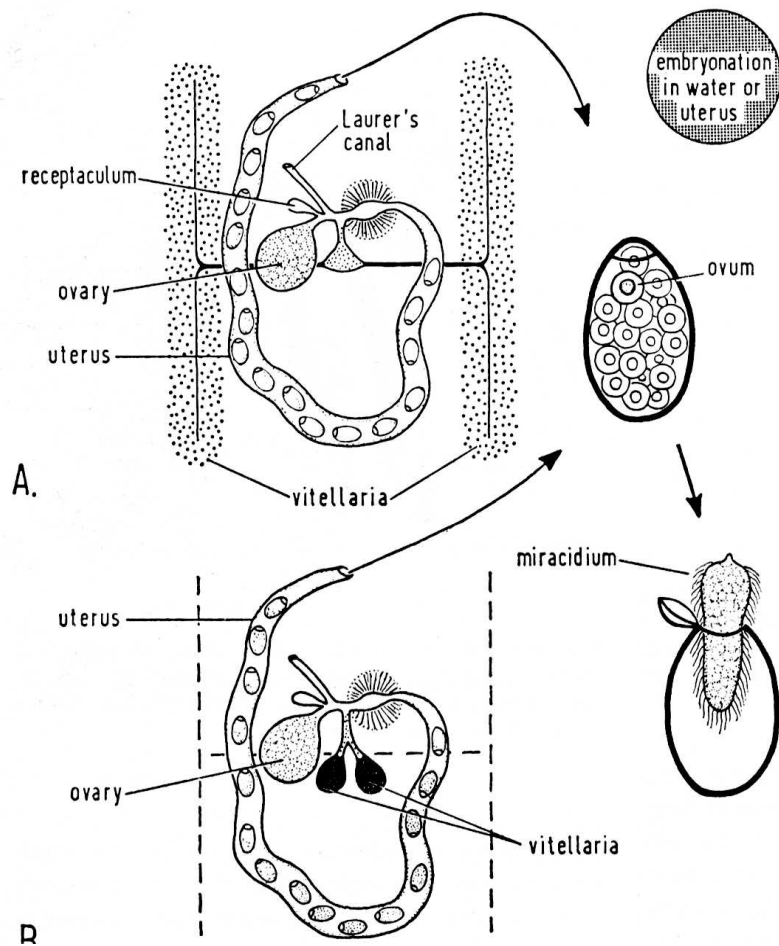


Fig. 9-7. Diagrammatic representation of female genitalia of digenetic trematodes. *A*, with extensive vitellaria; *B*, with condensed vitellaria. (From Smyth and Clegg, courtesy of Exp. Parasitol.)

Paragonimus westermani



Fig. 3.234 The African civet, *Civettictis civetta*.

This carnivore is a primary reservoir host for both *Paragonimus africanus* and *P. uterobilateralis* in West Africa. (Courtesy, Dr N. Cumberlandidge.)



Fig. 3.235 *Ranguna smithiana*: a host of lung fluke.

This species is a host of *Paragonimus heterotremus* in Thailand. Crabs are commonly eaten raw or in the form of an uncooked paste, with which the metacercariae are ingested. (Courtesy, Professor I. Miyazaki.)

Paragonimus westermani

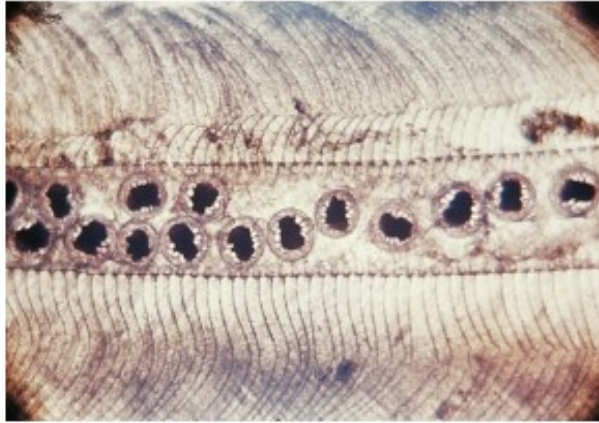


Fig. 3.236 Metacercariae of *Paragonimus pulmonalis*. Here they are located along a gill bar of the crab *Eriocheir japonicus*. (Courtesy, Professor I. Miyazaki.)

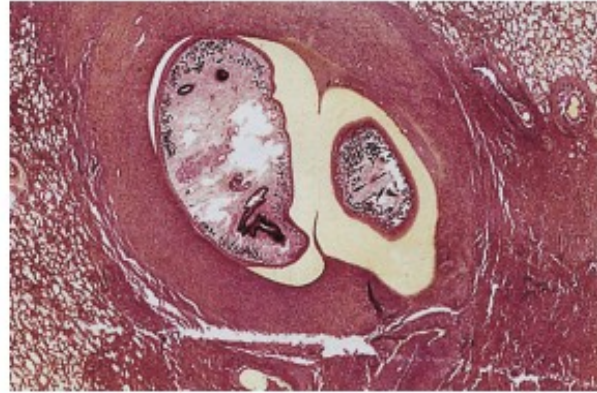


Fig. 3.239 Lung histology in paragonimiasis. Encapsulated within an inflammatory and fibrotic host tissue reaction, two adult *Paragonimus westermani* flukes are seen in this lung section. (H&E x20)

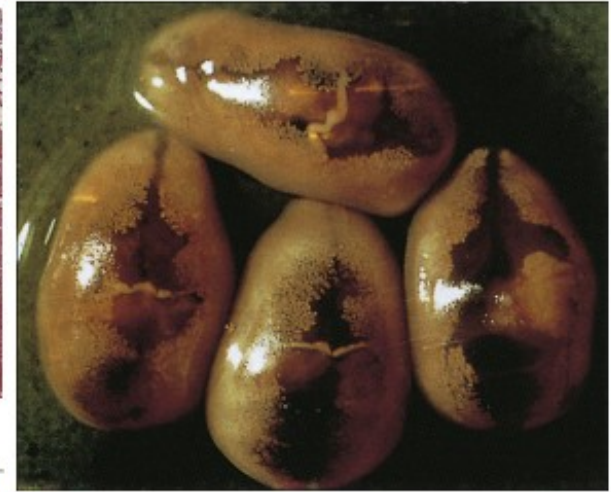

Fig. 3.238 Living adult *Paragonimus westermani*. Living adult *P. westermani* are lemon shaped. Compare this with the specimen above which has been flattened and distorted during preparation. (x 4.3.) (Courtesy, Professor Y. Yoshida.)

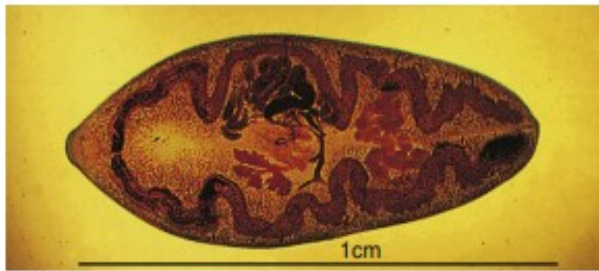


Fig. 3.237 Adult *Paragonimus westermani*. Adult flukes measure 1 cm x 0.5 cm and are ovoid in shape. The lobed ovary is located anterior to two branching testes. (Courtesy, Dr S. Vajasthira.)

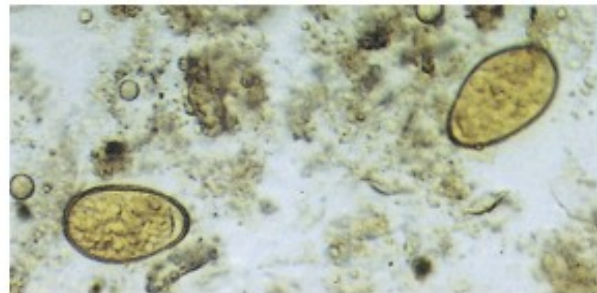


Fig. 3.240 Eggs in human sputum. Eggs measure 85 μm x 50 μm and are ovoid in shape. They are often asymmetrical: the opercular end is flatter whilst the abopercular end has a slightly thickened shell. (x 150.) (Courtesy, Professor D. A

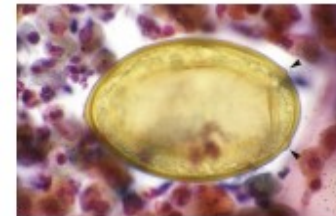


Fig. 3.241 *Paragonimus kellicotti*. *P. kellicotti* occasionally causes infection following consumption of raw crayfish in the USA. The eggs differ slightly to *P. westermani*: note the opercular shoulders (arrowheads) and the absence of abopercular thickening. (From Procop, G. W., Neafie, R. C. Human parasitic pulmonary infections. Pulmonary Pathology, Chapter 14, Pages 287-314, Figure 14-16)

Echinostoma revolutum

