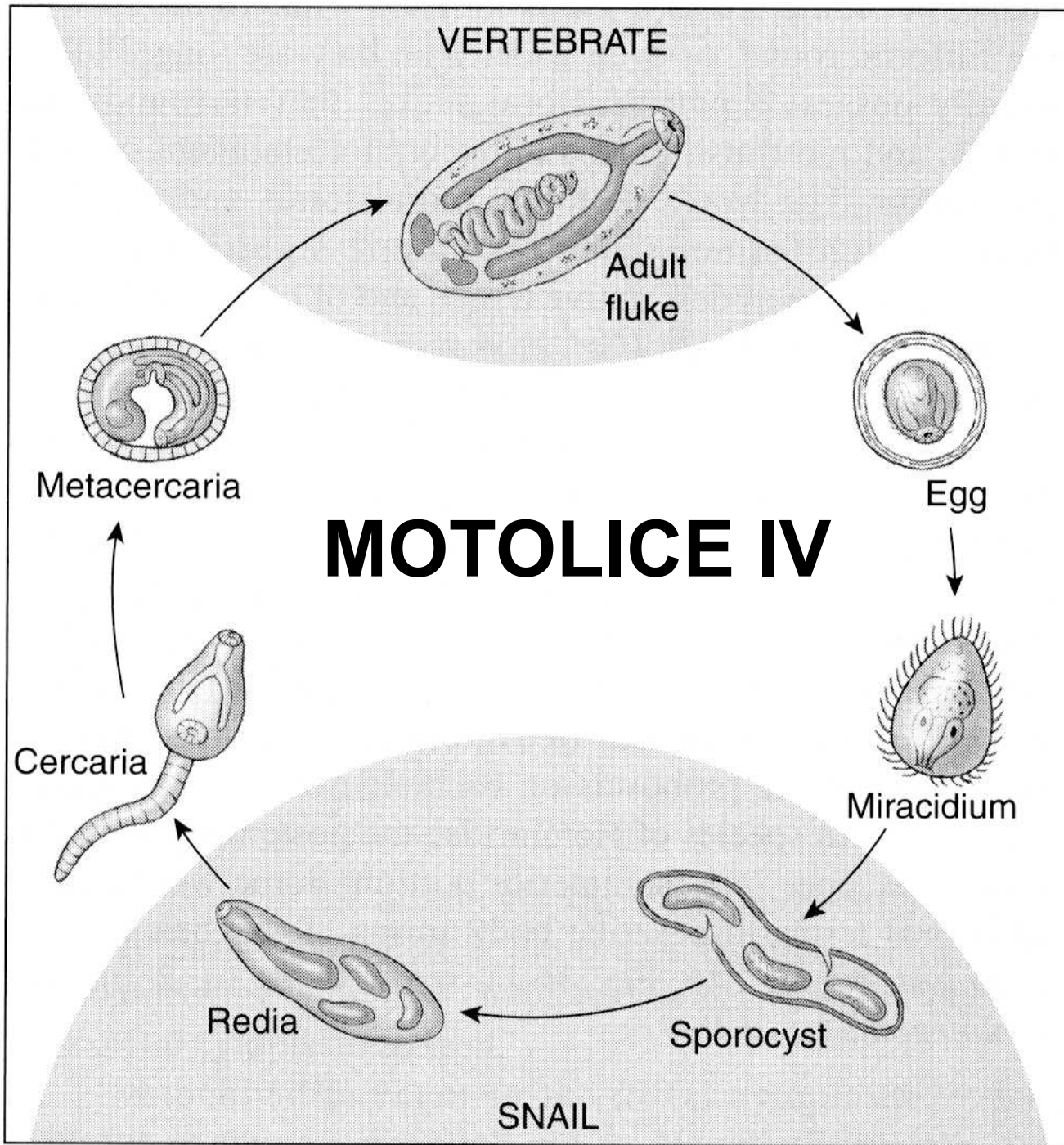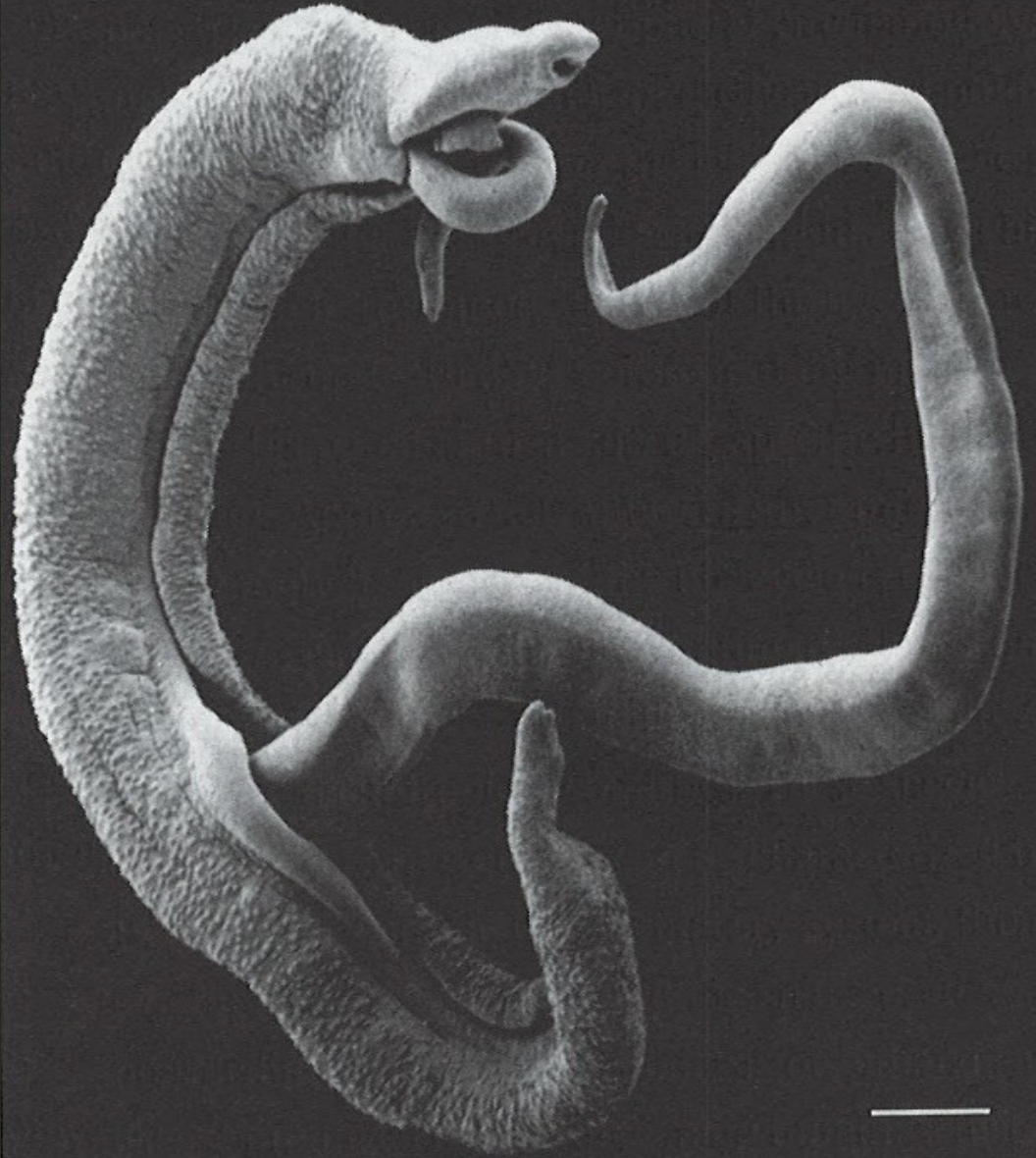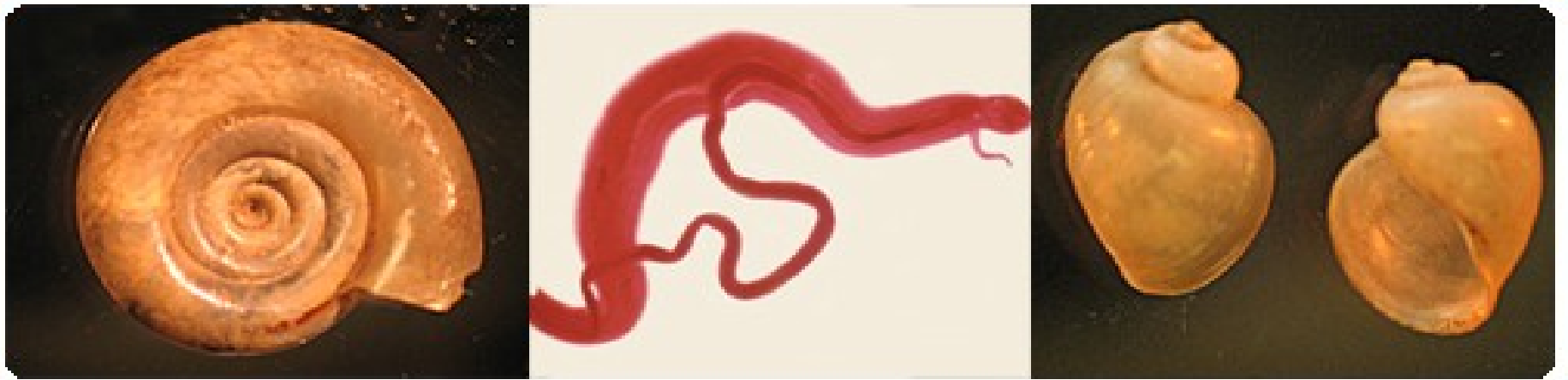


# Schistosomatidae







- **Schistosomiáza je známa také jako bilharzióza. Napadá asi 200 mil lidí a je po malárii druhou nejvýznamnější parazitósou.**
- **Cizopasníci působící schistosomiázu se vyvíjejí v různých druzích sladkovodních plžů. Infekčním, stádiem jsou cercárie, které aktivně penetrují lidskou pokožku. Nejčastěji jsou lidé napadeni těmito třemi druhy: *Schistosoma mansoni*, *S. haematobium*, or *S. japonicum*.**

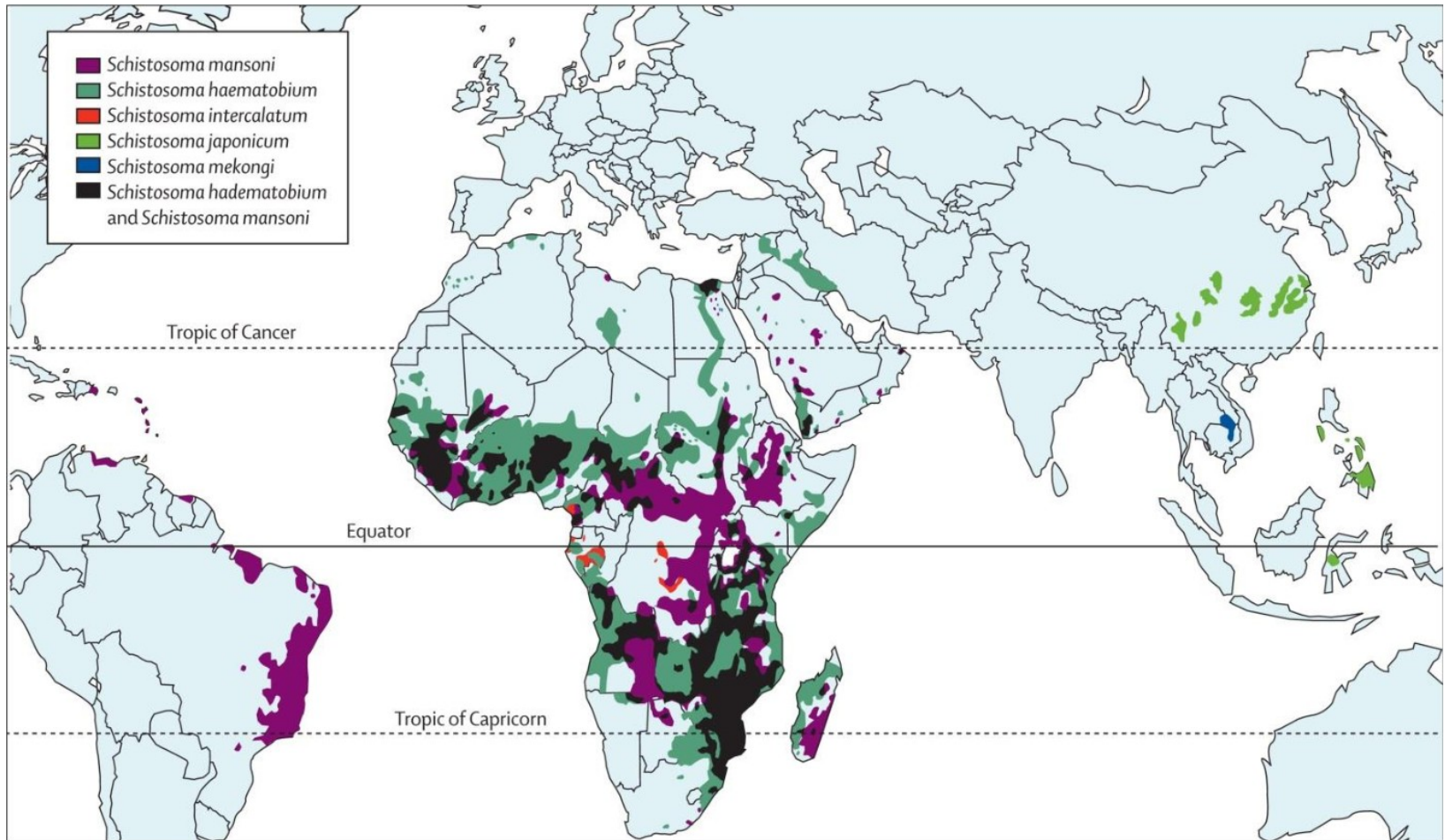
# Schistosomatidae

## Charakteristika:

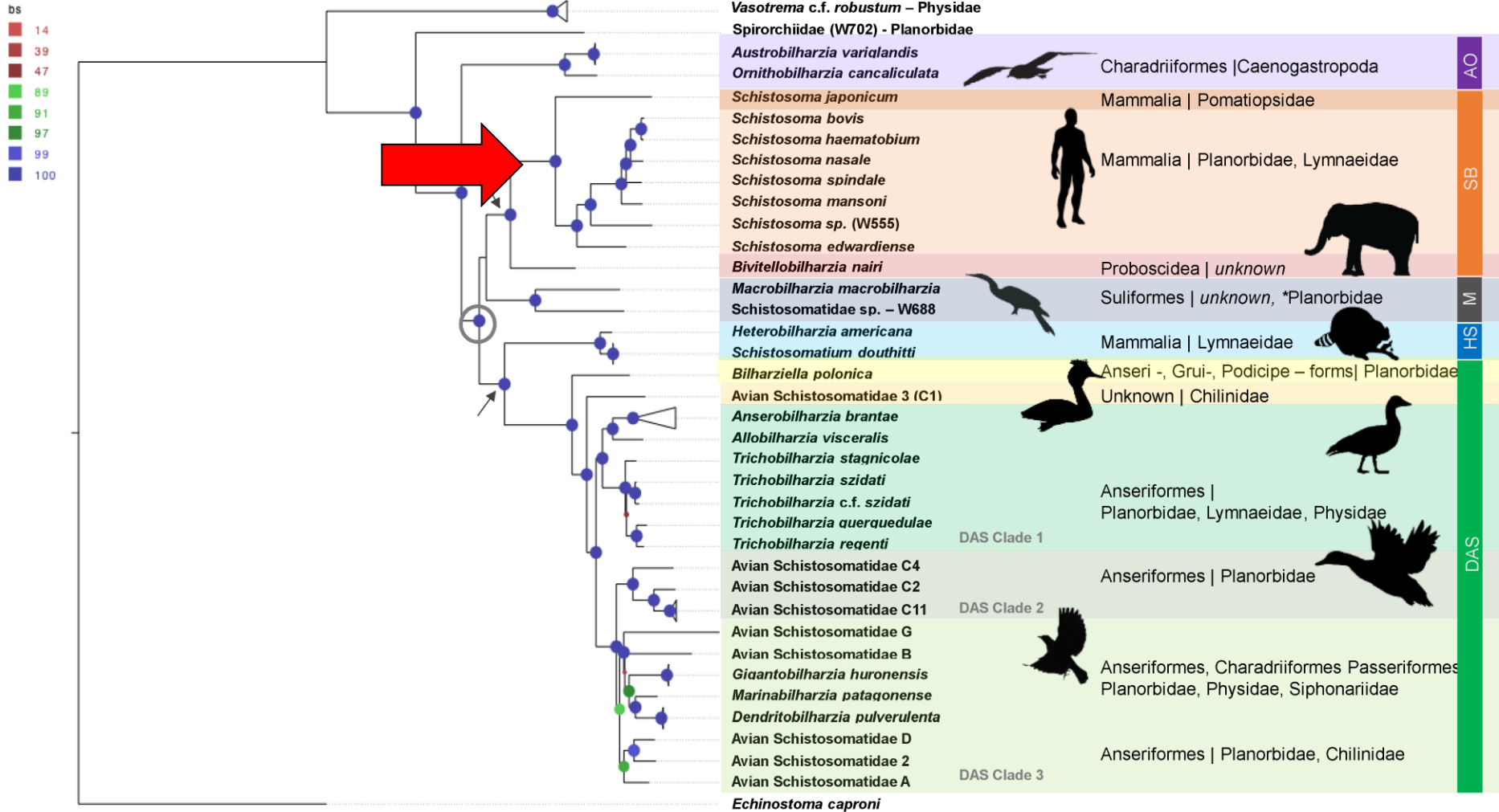
- Cizopasníci krevního systému
- Protáhlé tělo, až 20 mm dlouhé
- Gonochoristé
- Štíhlejší, delší samice v *canalis gynecophorus* kratšího, širšího samce



# Global distribution of schistosomiasis (Ferrari and Moreira, 2011)



# Fylogenomika a diverzifikace Schistosomatidae

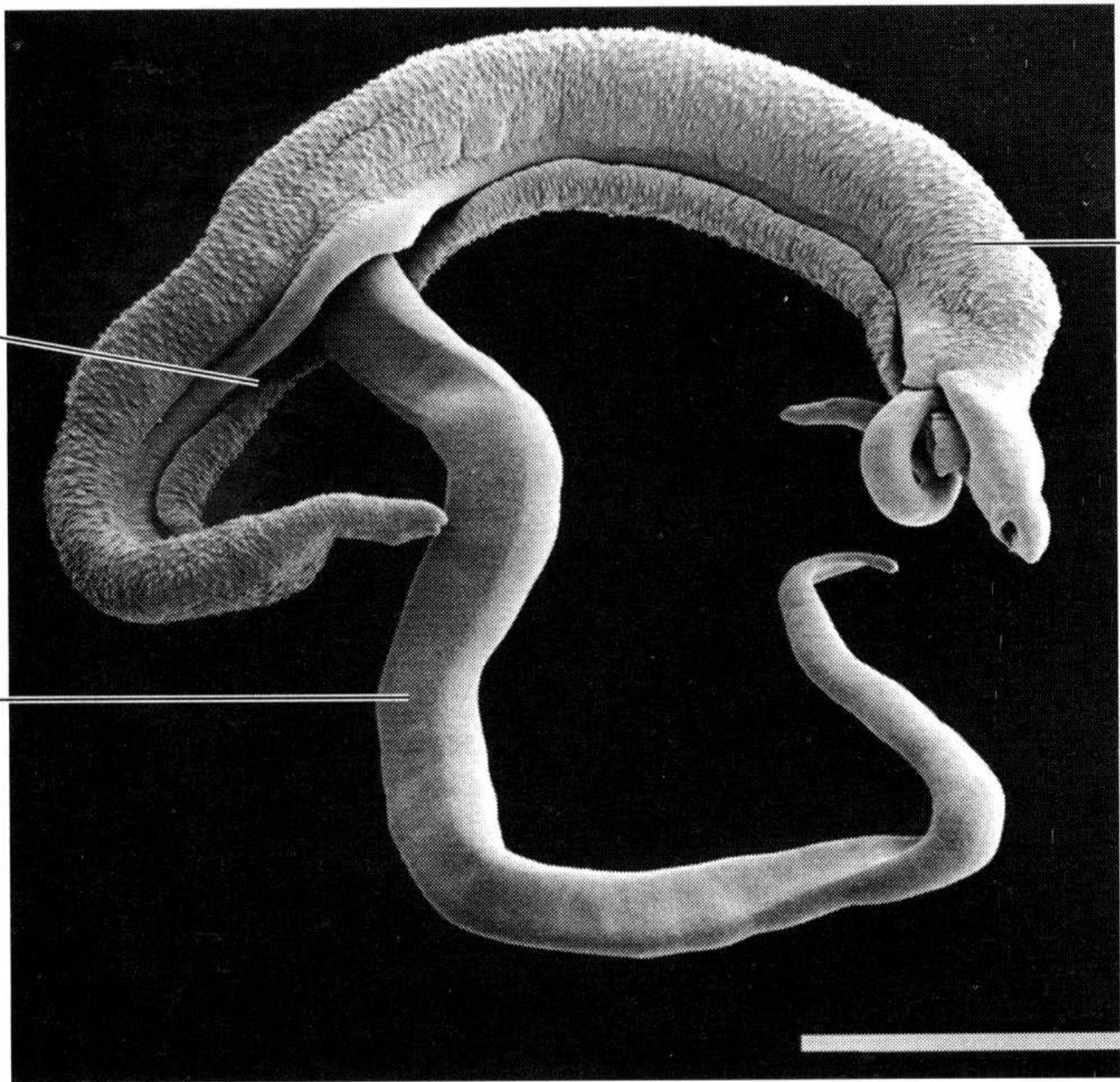




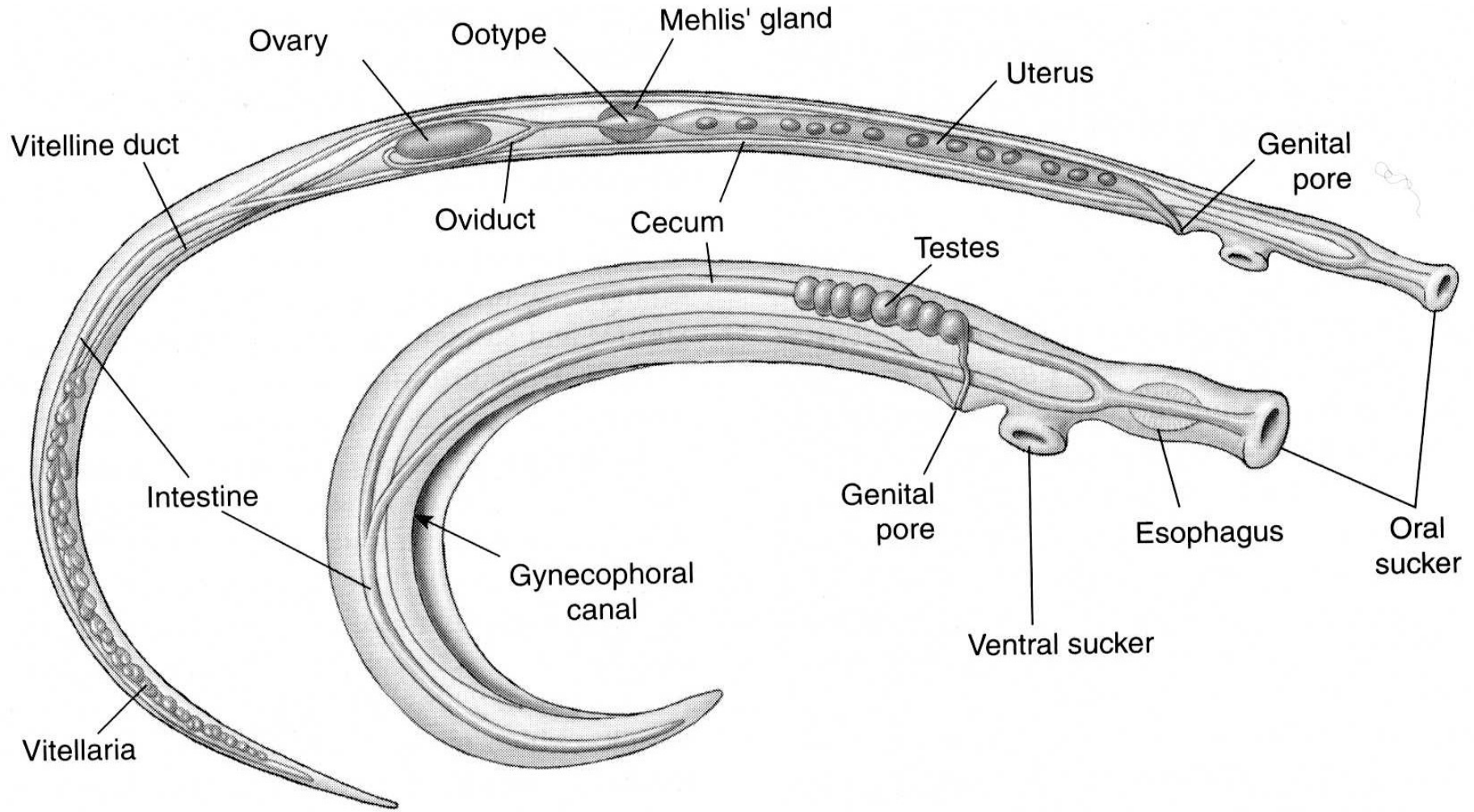
Gynecophoral canal

Male

Female

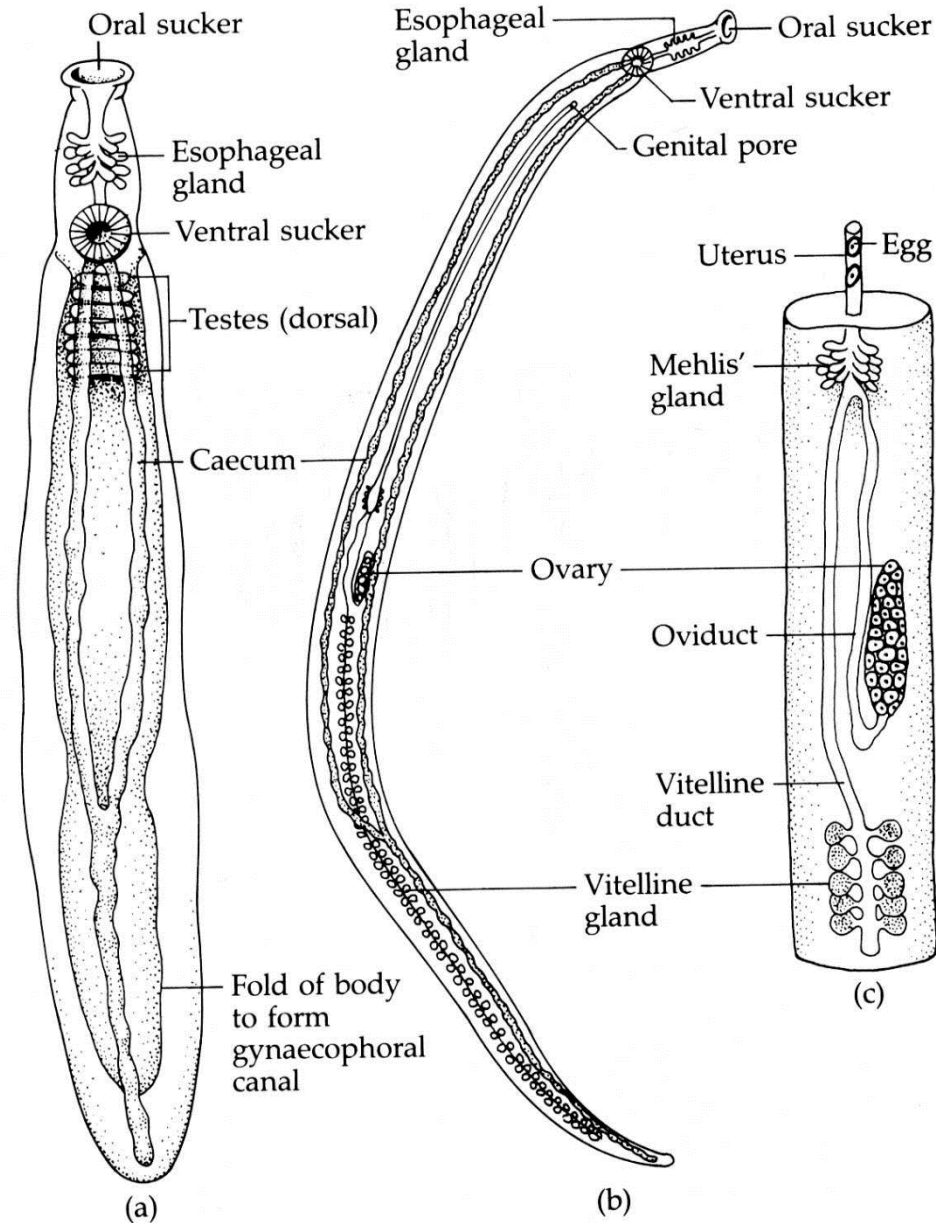


# Morfologie - gonochoristi

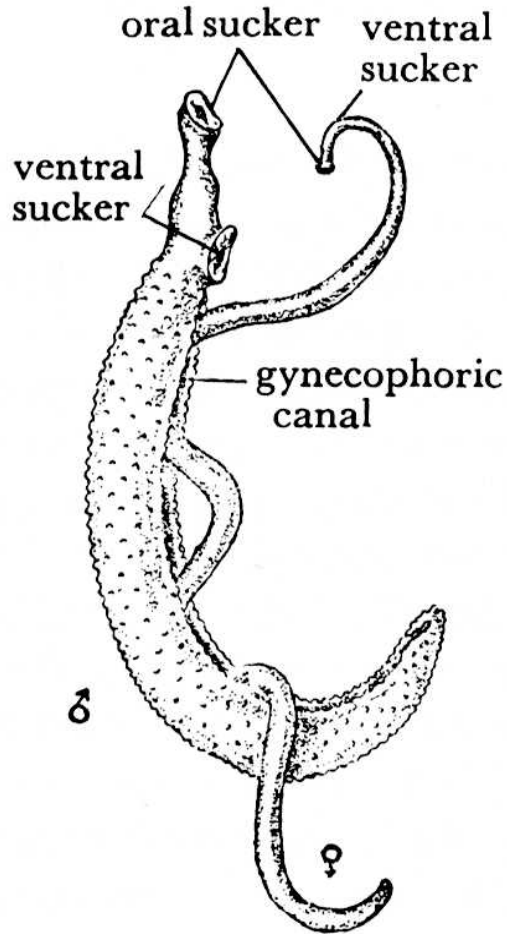




# Pohlavní dimorfismus



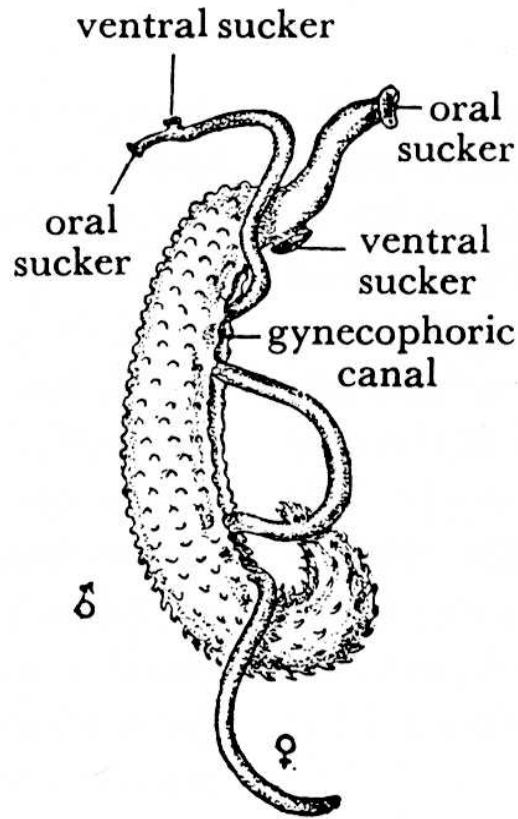
# Schistosoma haematobium (A) S. mansoni (B) a S.japonicum (C)



A

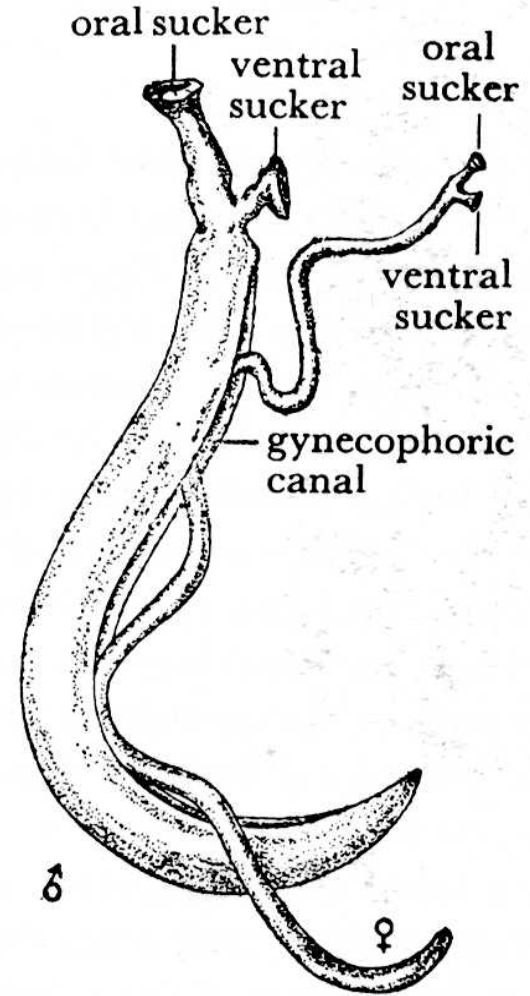
x5

B



x5

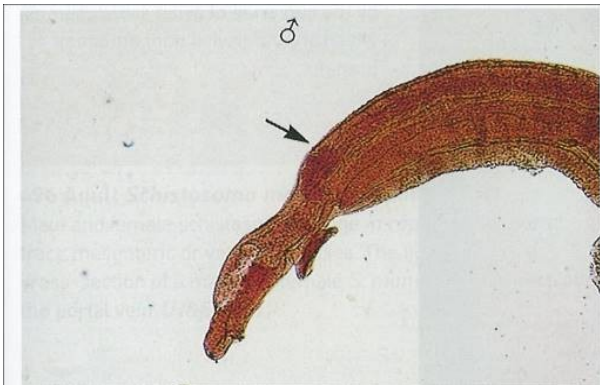
C



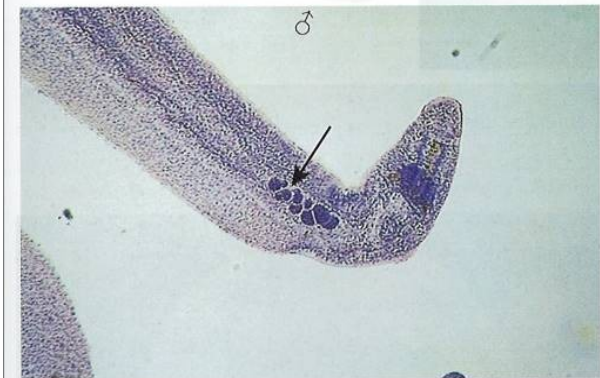
x5



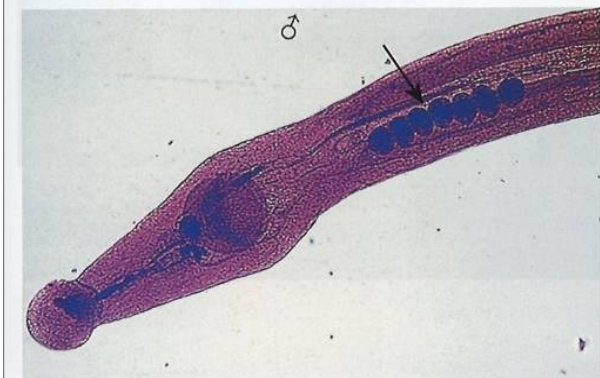
# Schistosoma - gonochoristi



487



488

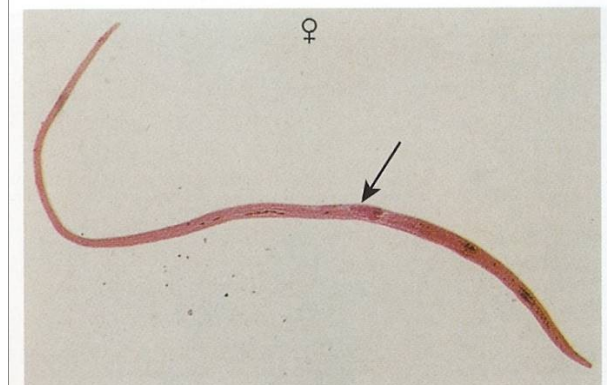


489

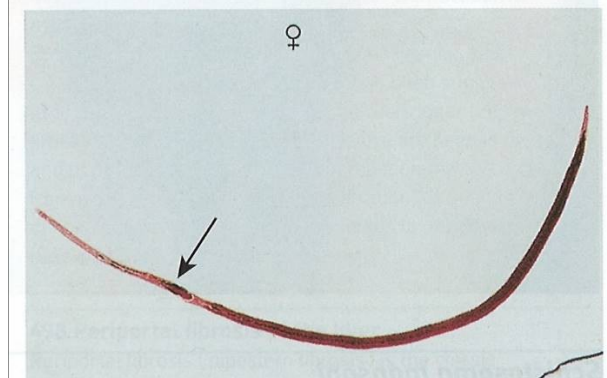
haematobium

mansoni

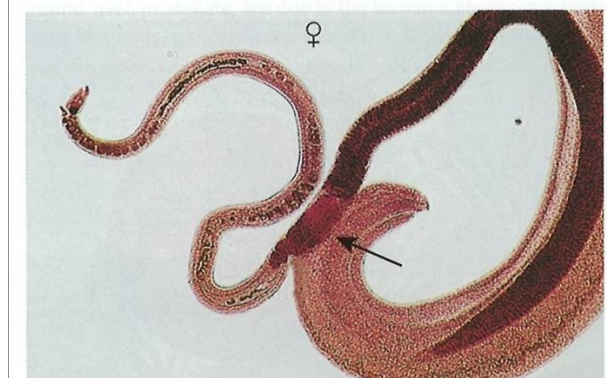
japonicum



490



491



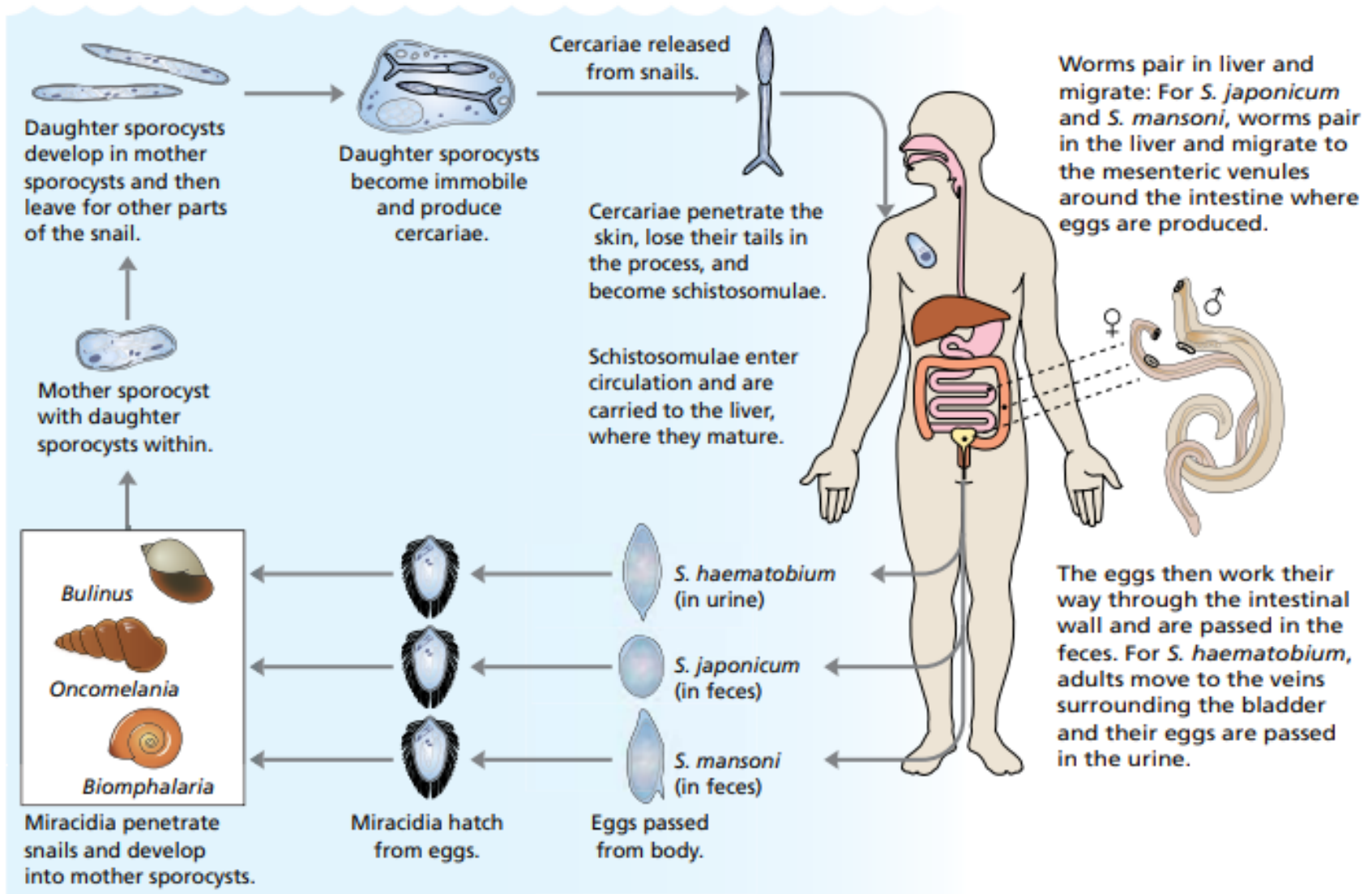
492

# Schistosomatidae

## Vývoj:

- 1.Mz: plži se sporocystami 1. a 2. generace
- Přímá penetrace furkocerkarií do definitivního hostitele – odvržení ocásku – (schistosomulum)
- Prepatentní perioda 5 – 8 týdnů
- Doba života až 30 let
- Po kopulaci migrace do kapilár specifických orgánů
- Denně kolem 300-3000 velkých vajíček, bez víčka, s vyvinutým miracidie
- Vajíčka hlavní patogenní agens( granulomy, protřetí kapilár – hematurie, hepatosplenomegalie

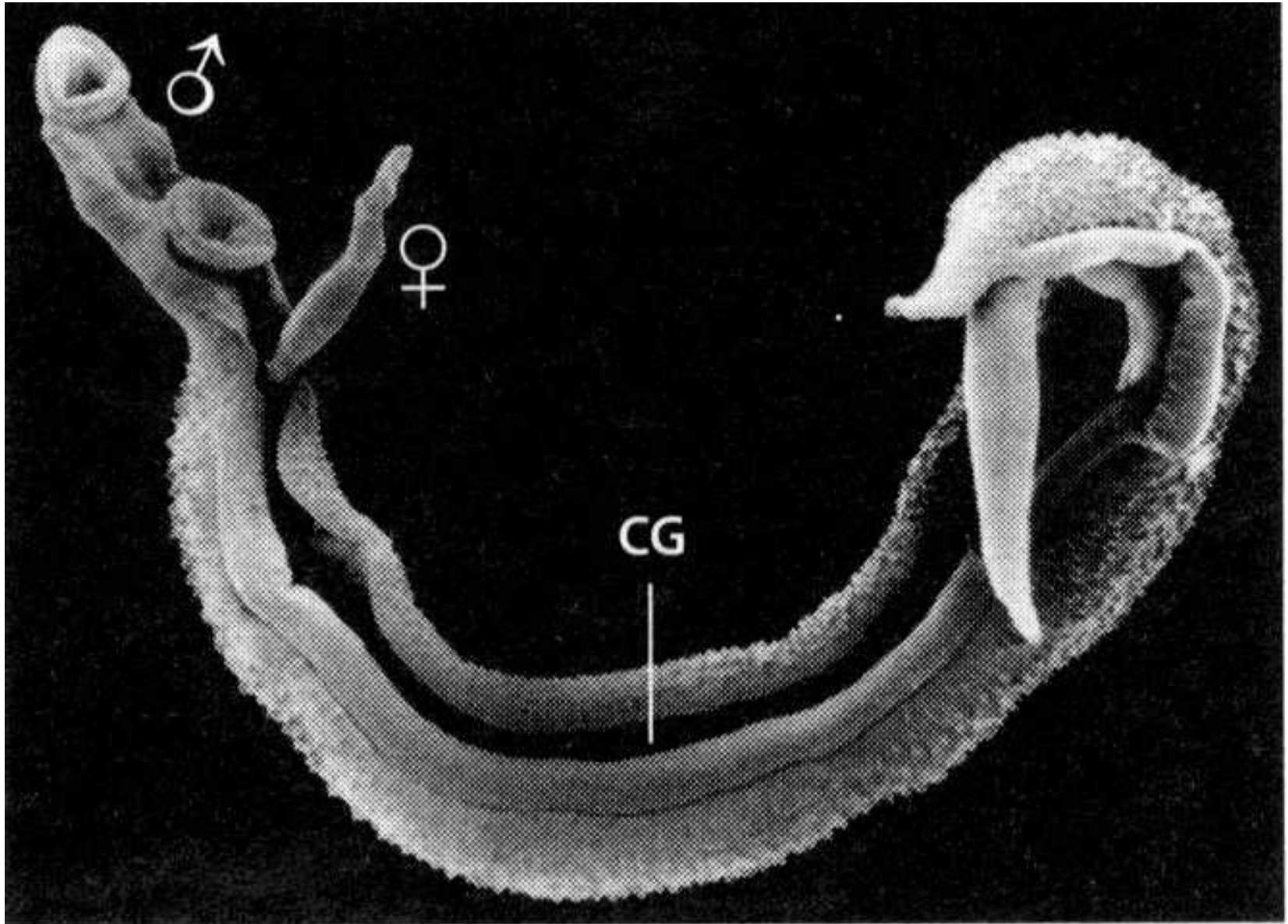
# Schistosoma – životní cyklus



# Schistosomiasa – vývojová stádia

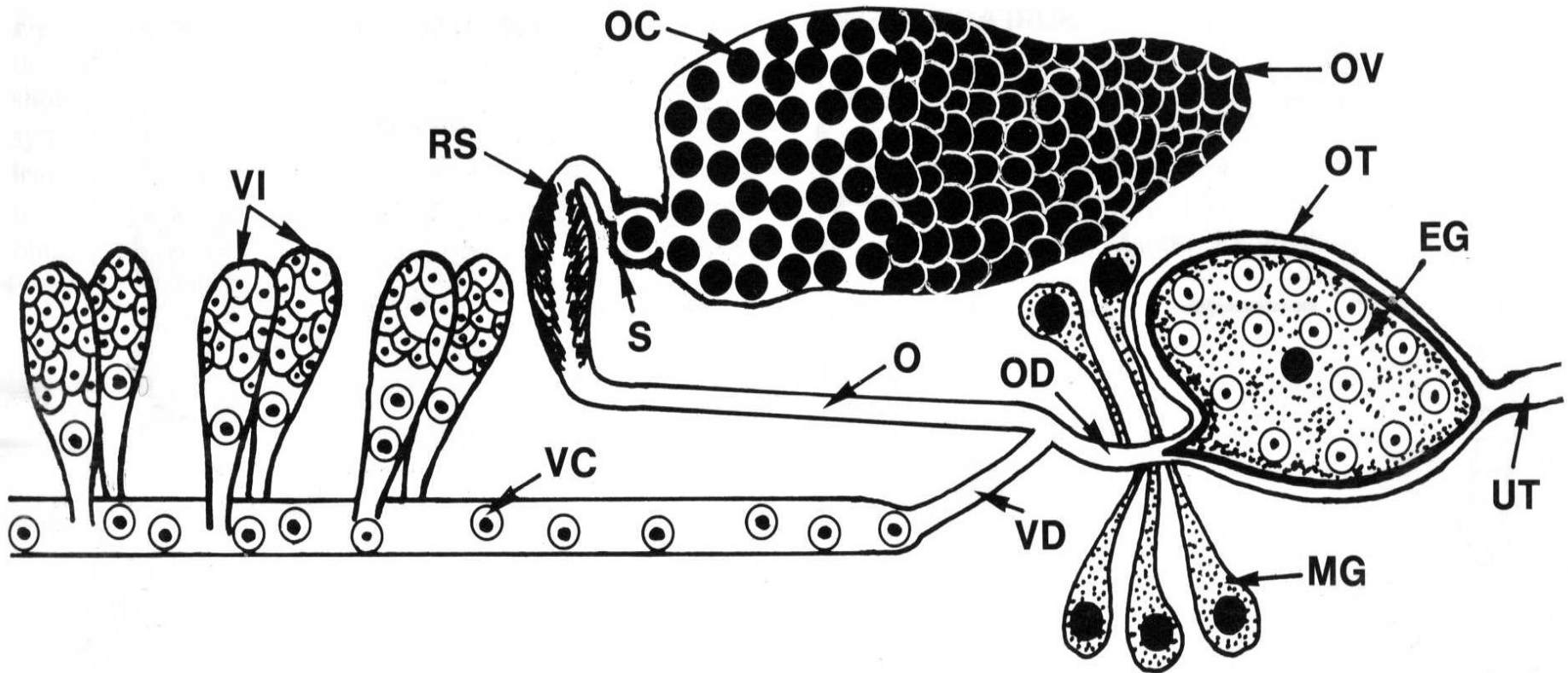


# Schistosoma - kopulace





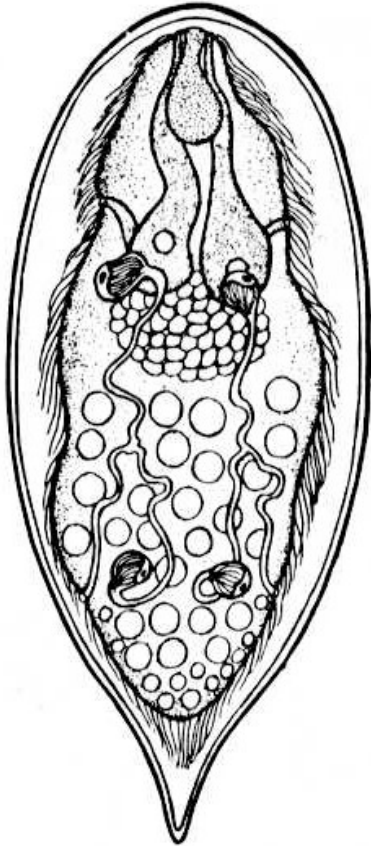
# Samičí reprodukční soustava



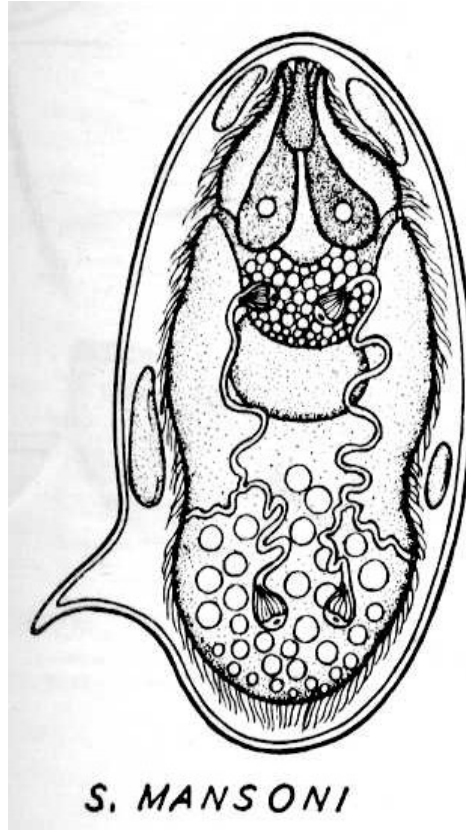
**Fig.3.97.** Diagrammatic representation of the reproductive organs of a female of *Schistosoma mansoni* (after Gönnert 1955 and Mehlhorn and Piekarski 1981). *EG*, Egg (containing the zygote and vitellary cells); *MG*, Mehlis's glands;

*O*, oviduct; *OC*, oocyte; *OD*, ovovitellary duct; *OT*, ootype; *OV*, ovary; *RS*, receptaculum seminis; *S*, sphincter; *UT*, uterus; *VC*, vitellary cell; *VD*, vitellary duct; *VI*, vitellarium

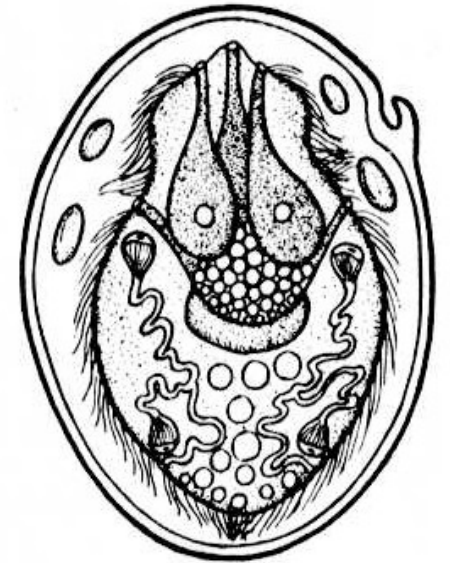
# Schistosoma - vajíčka



*S. HAEMATOBIIUM*

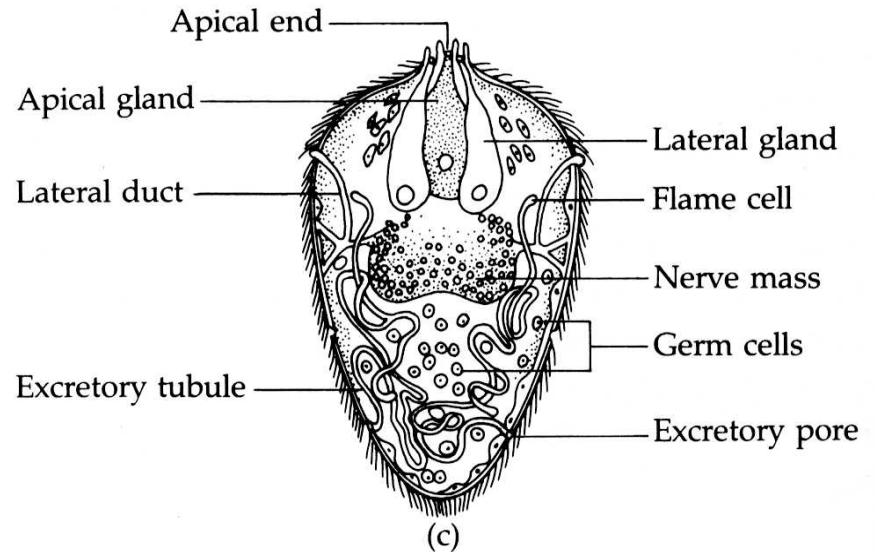
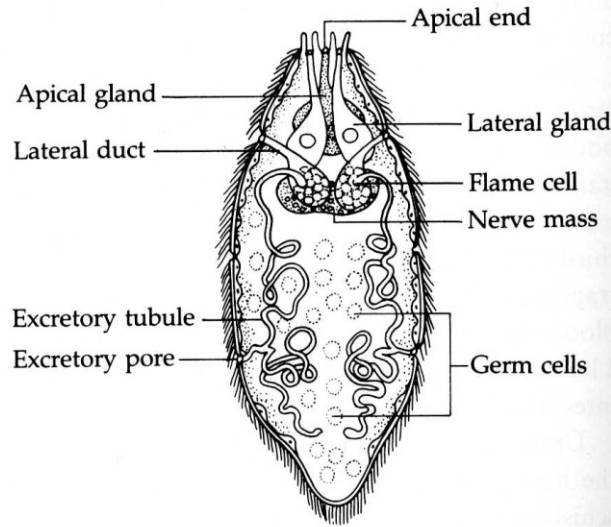
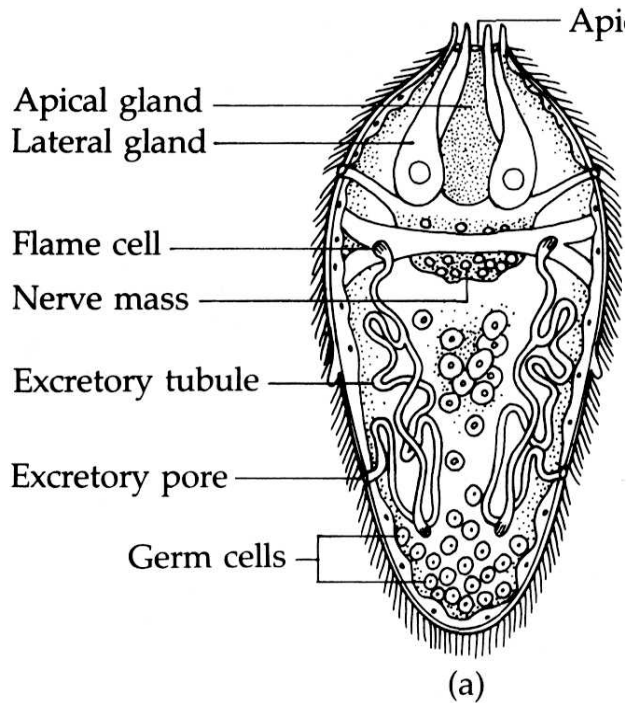


*S. MANSONI*

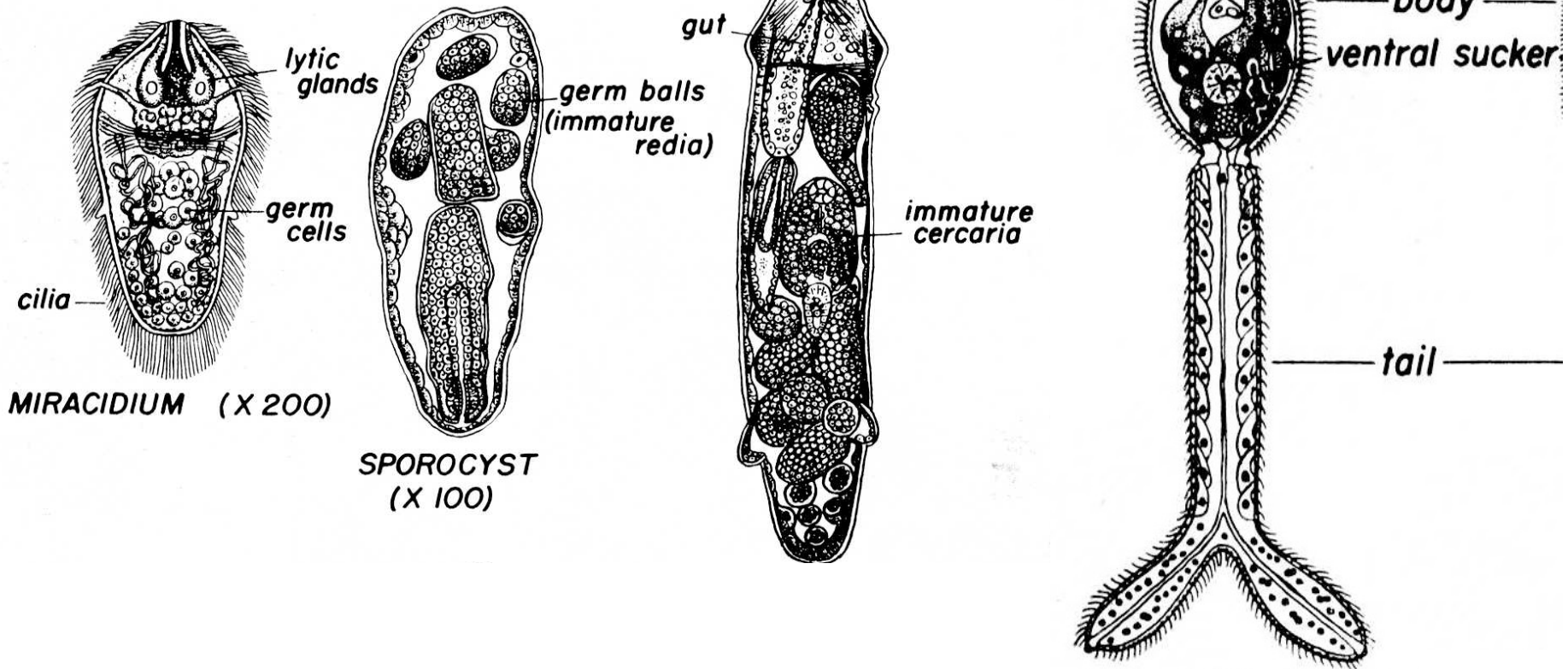


*S. JAPONICUM*

# Schistosoma - miracidium

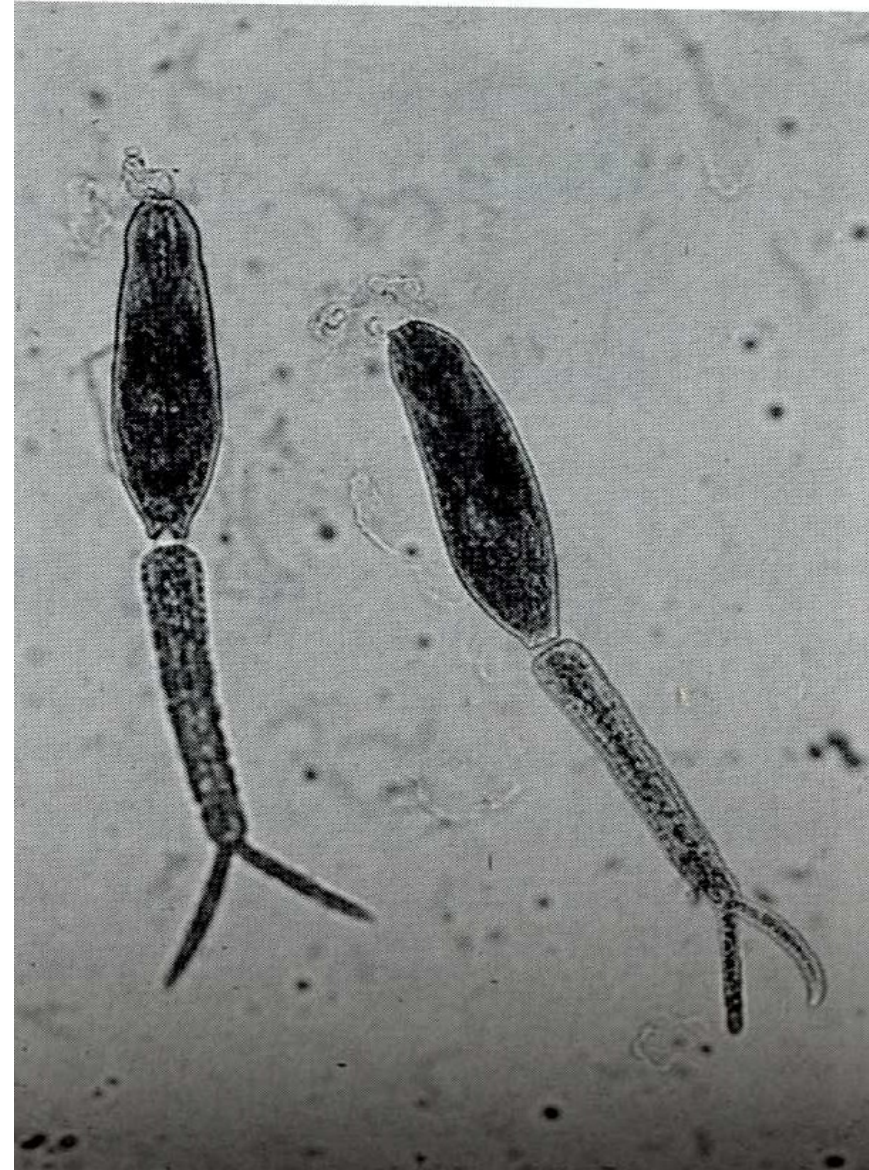
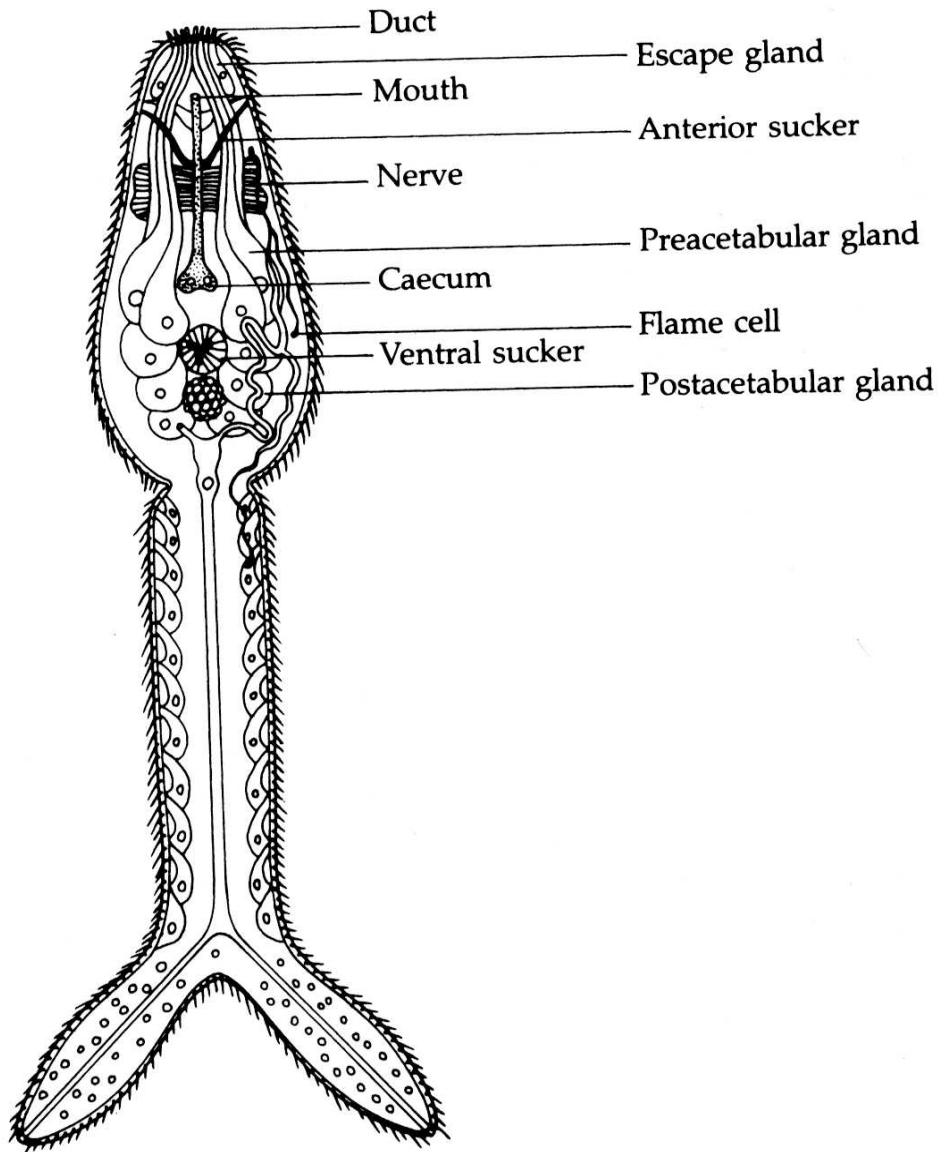


# Vývojová stádia

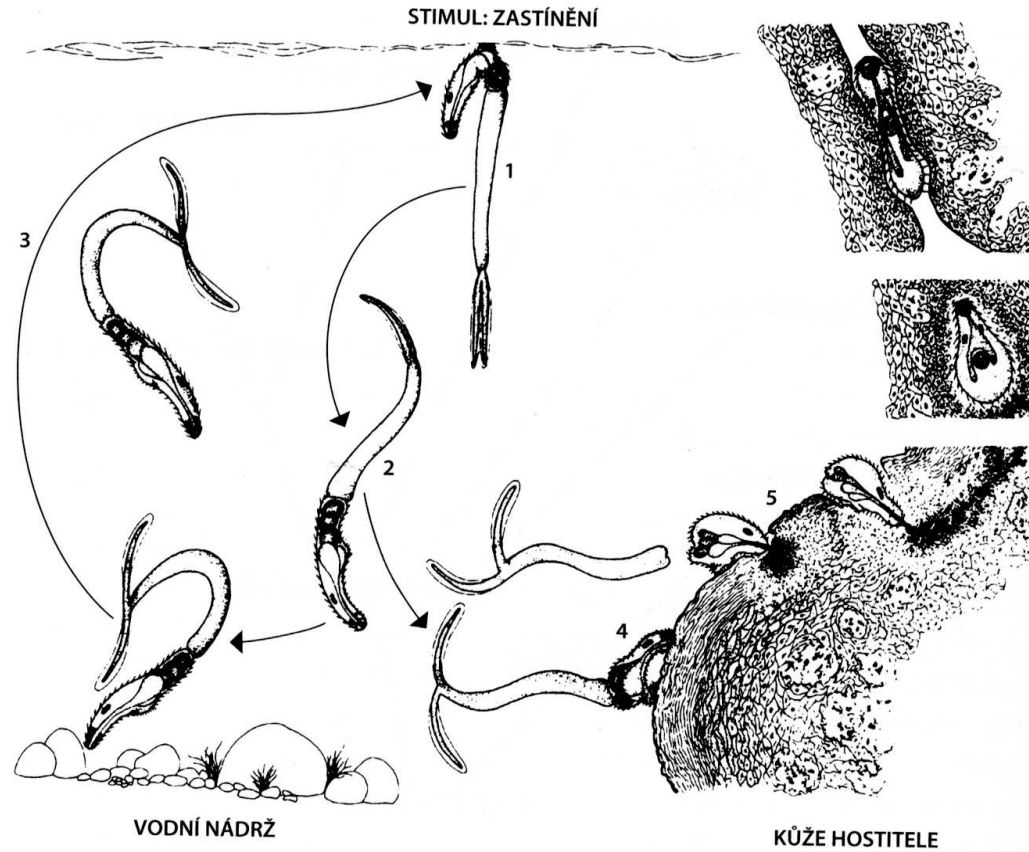




# Furkocerkárie penetruje pokožku



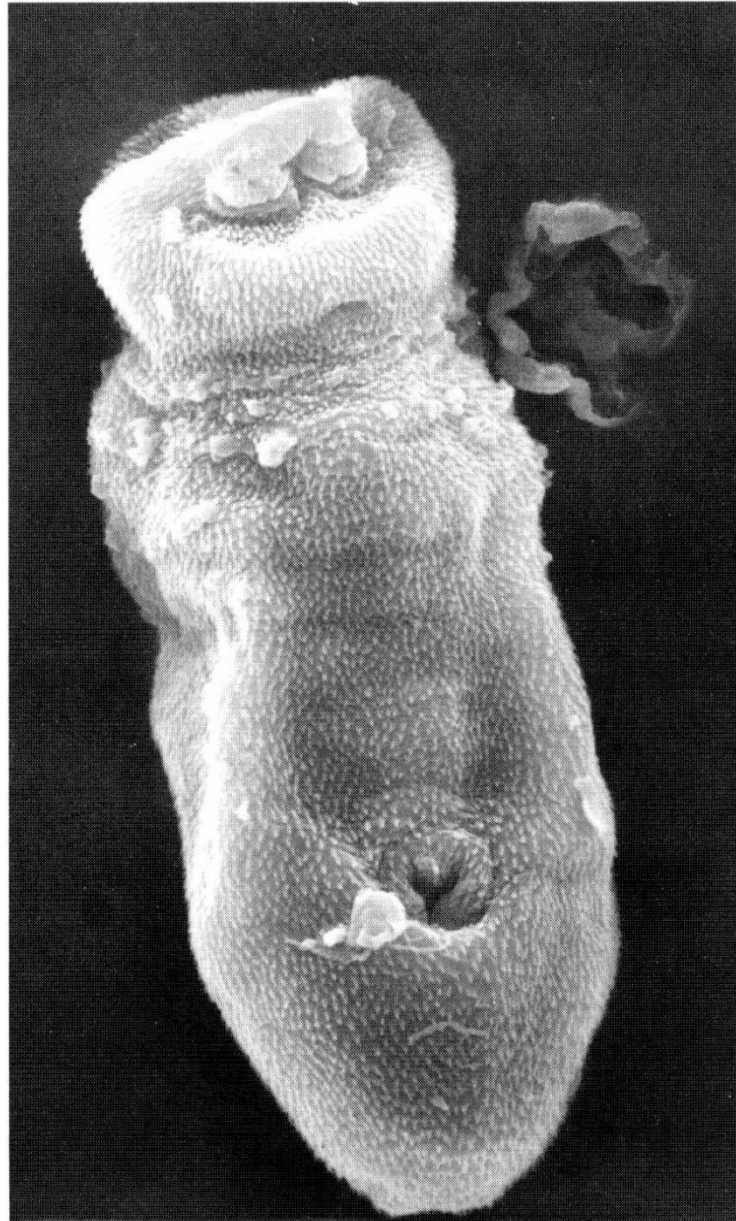
# Penetrace pokožky



Obr. 3-2 Platyhelminthes, Trematoda, *Trichobilharzia szidati*. Chování cercárií před

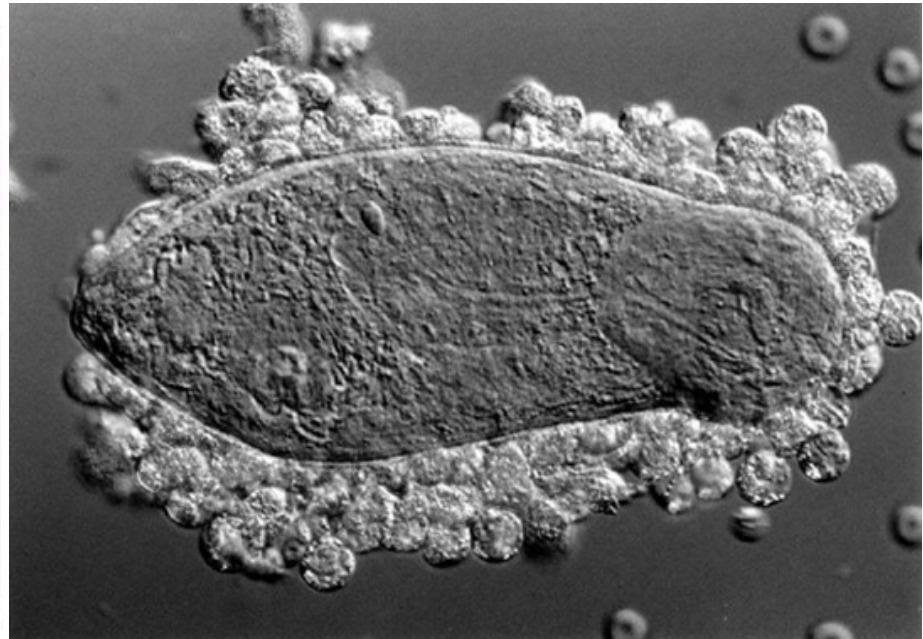
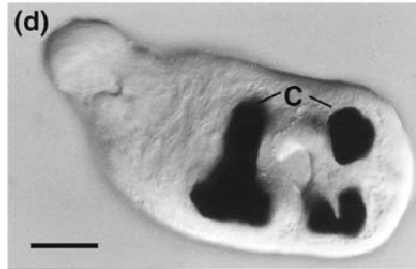
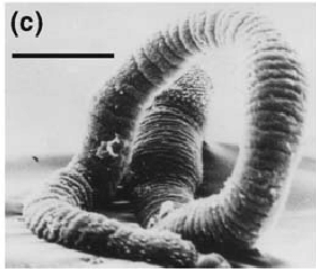
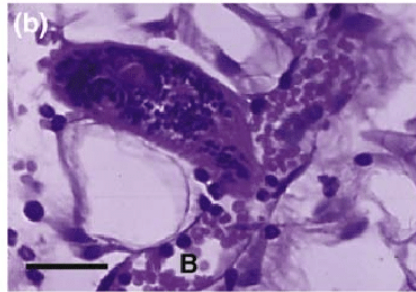
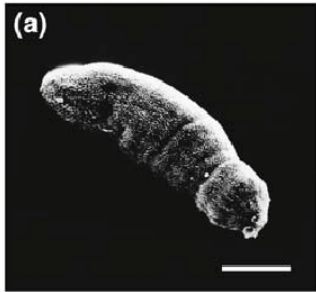


# Shistosomulum

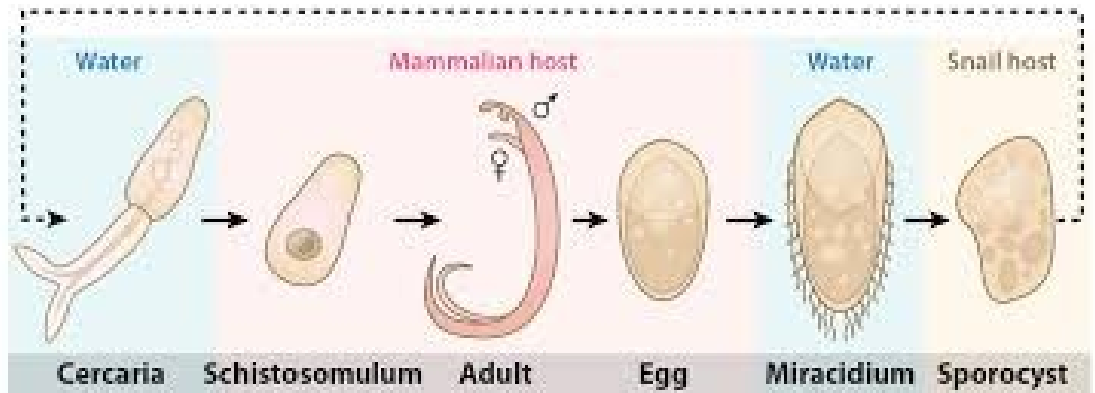
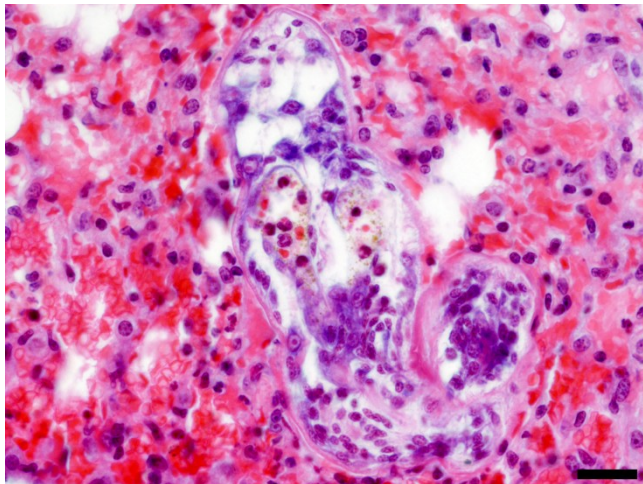


**FIGURE 11-10**  
Scanning electron  
micrograph of  
*Schistosoma mansoni*  
schistosomule.

# Schistosomulum

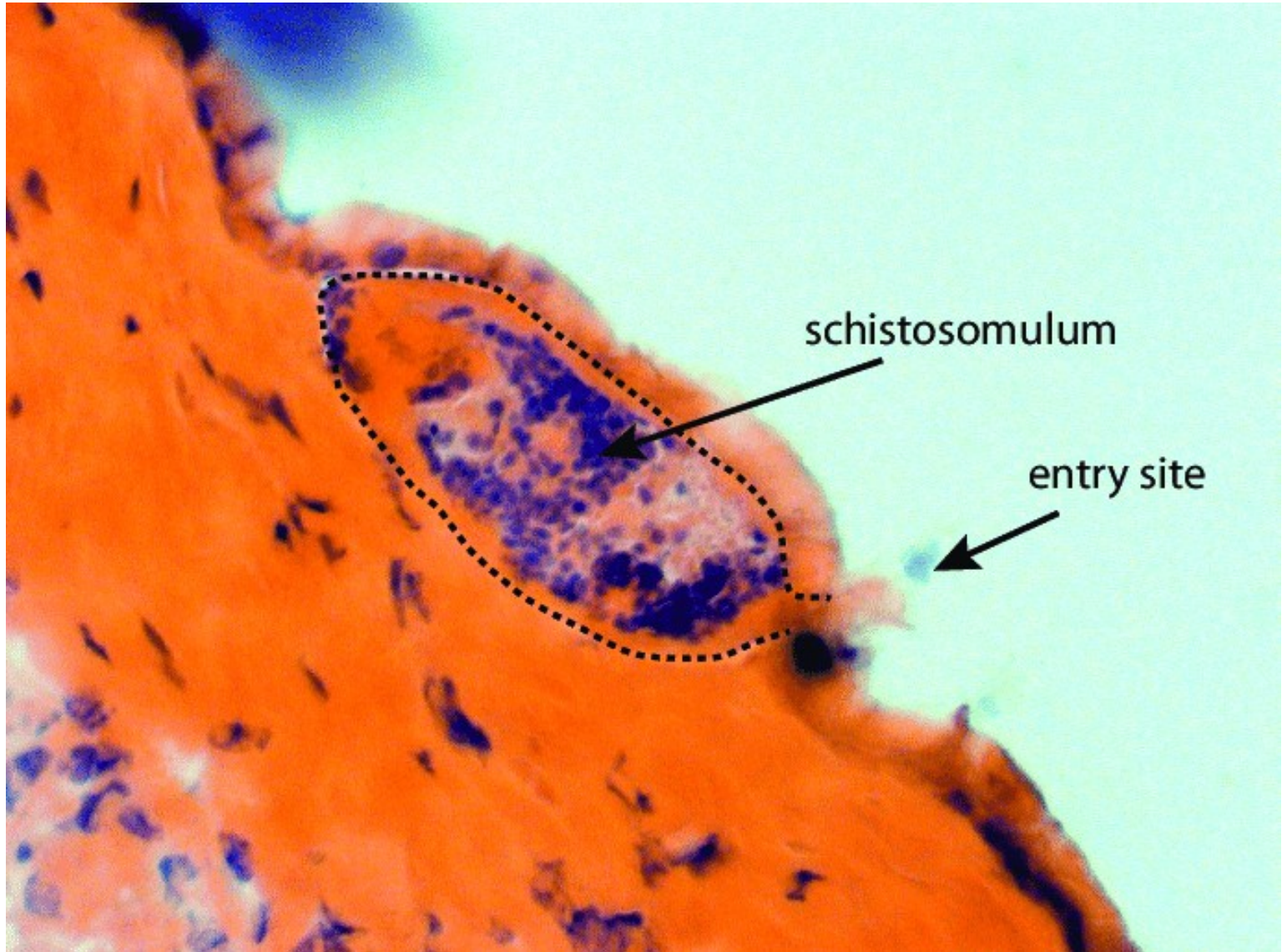


TRENDS in Parasitology





# Penetrance - schistosomulum



# Pohyb schistosomula v cévě

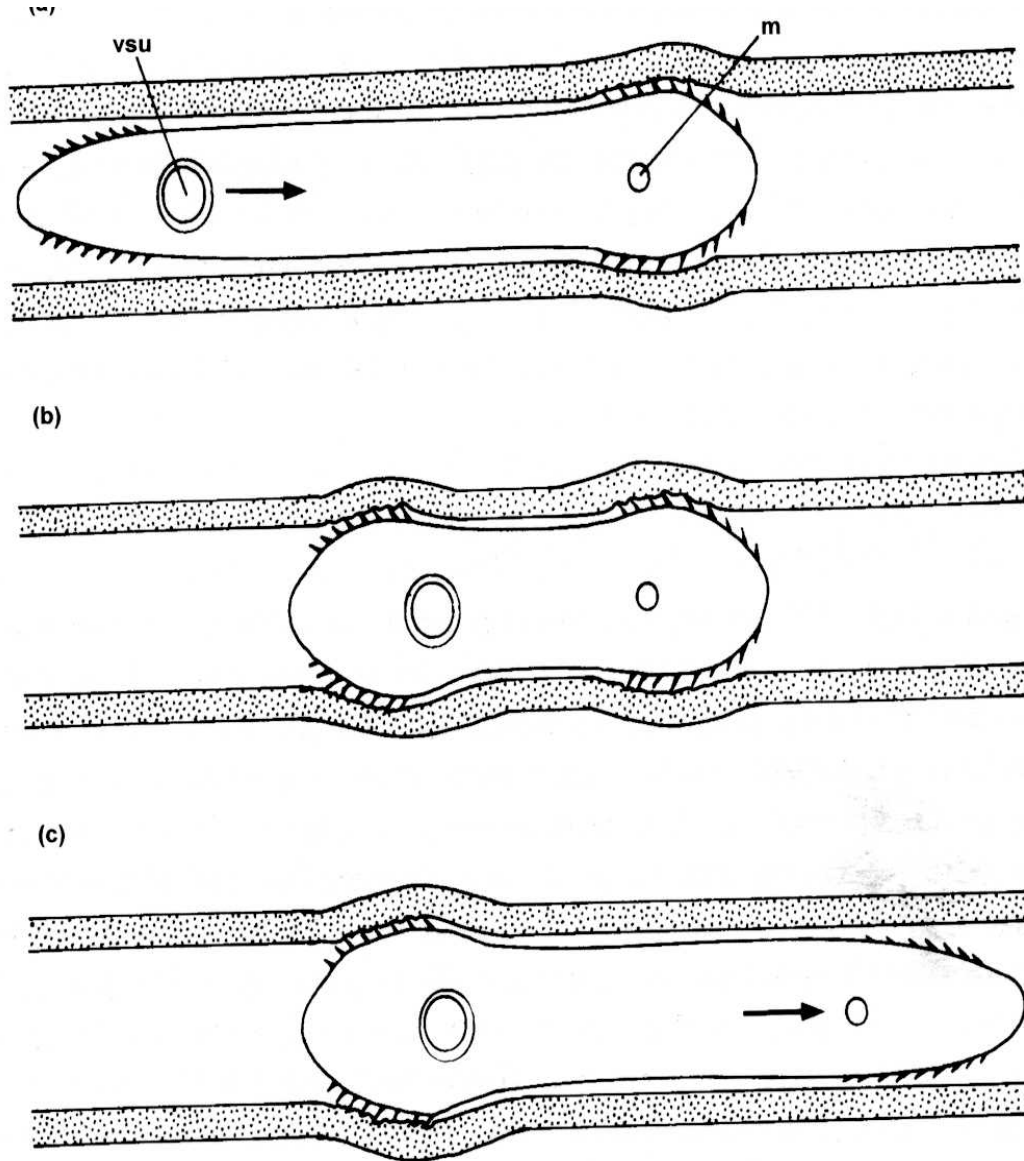
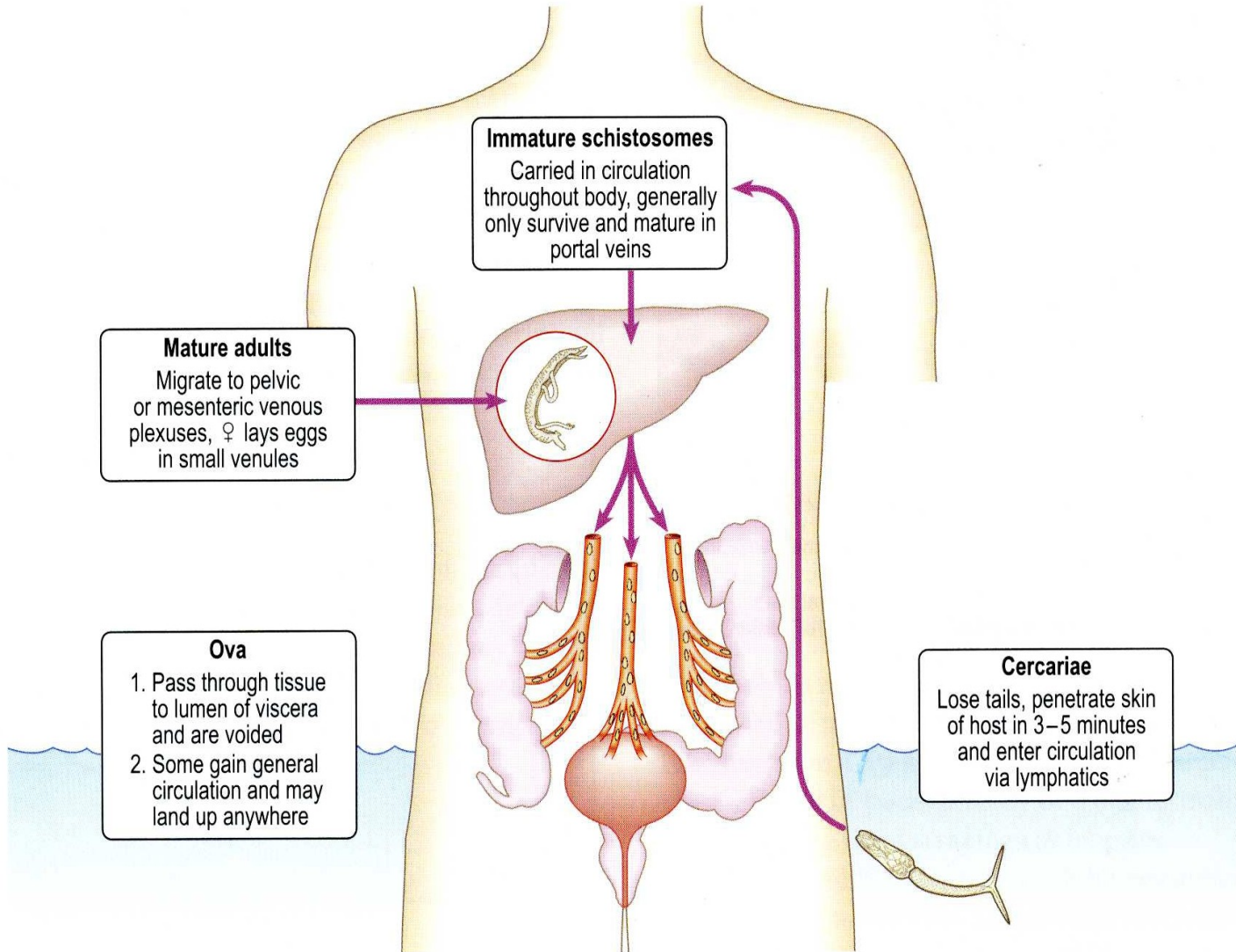


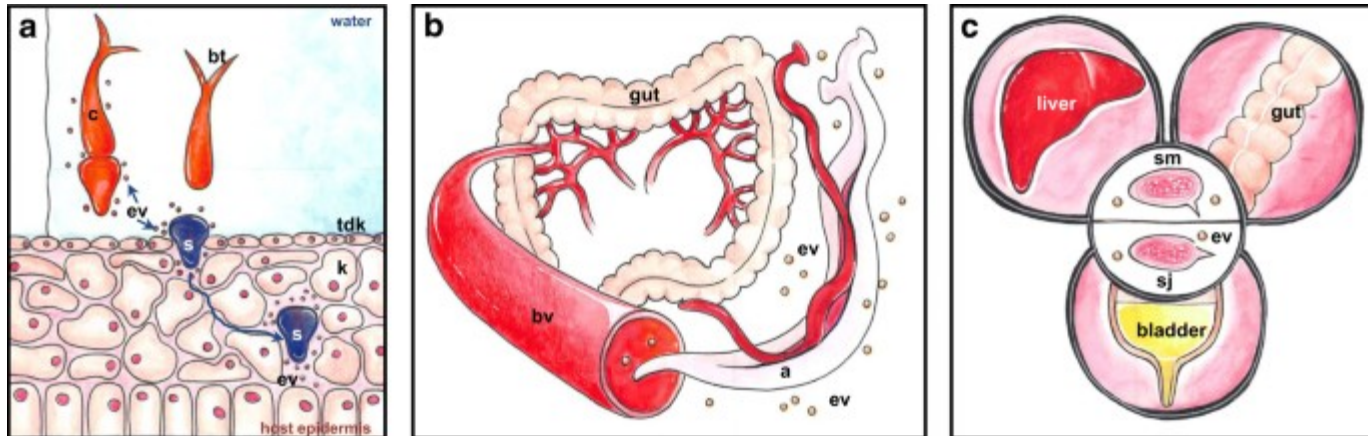
Fig. 18.14 Diagrammatic representation of the movement of a schistosomulum along the lumen of

# Vývoj v člověku



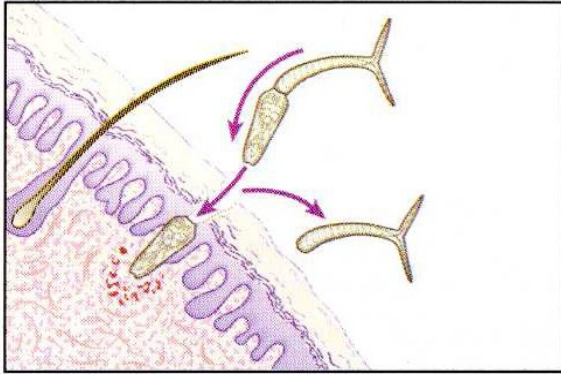


# Patogen host interakce

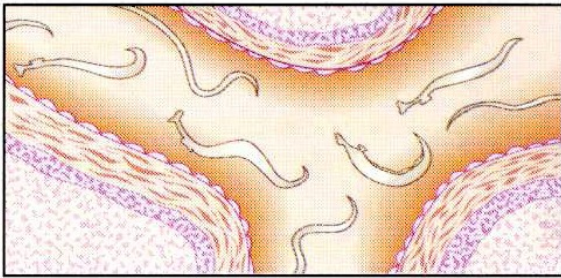


# Patogenita - schistosomy

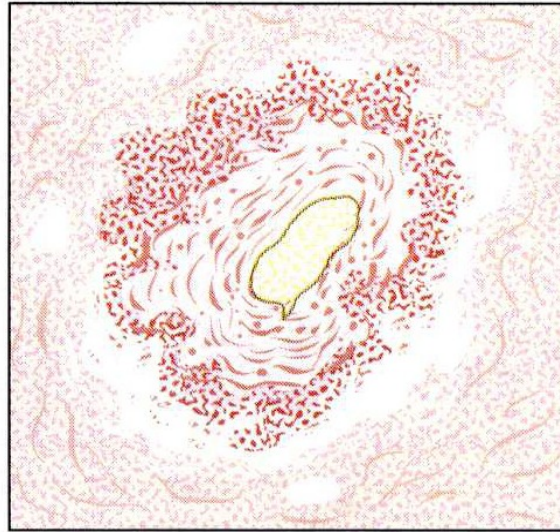
1



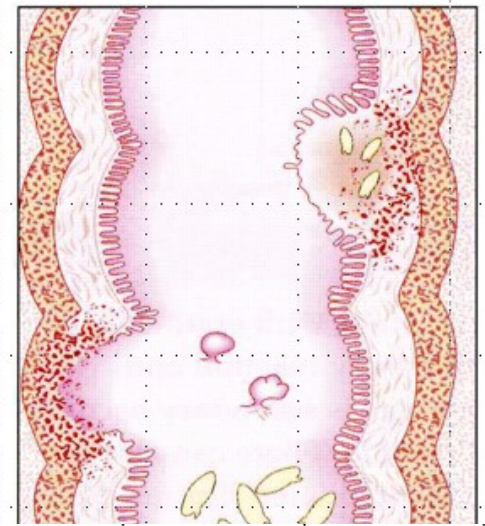
2



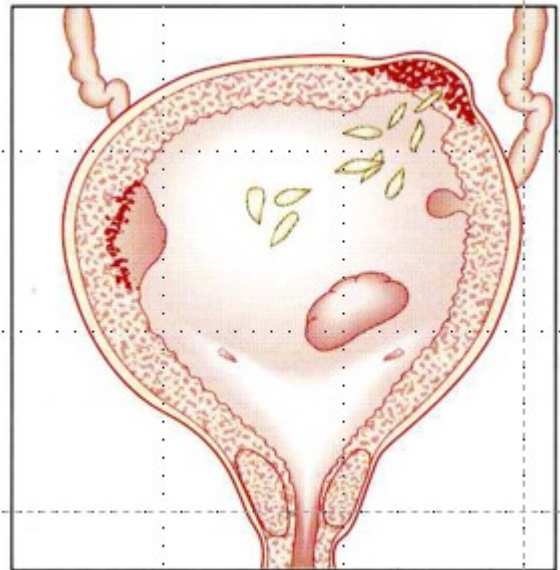
3



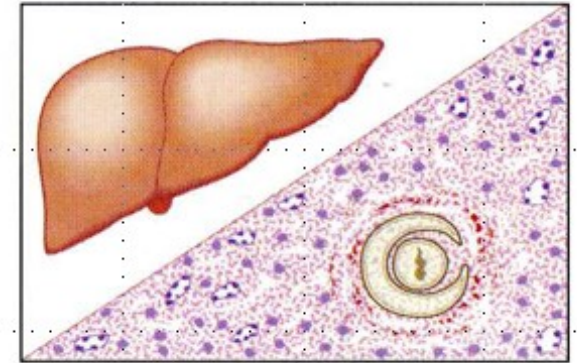
5



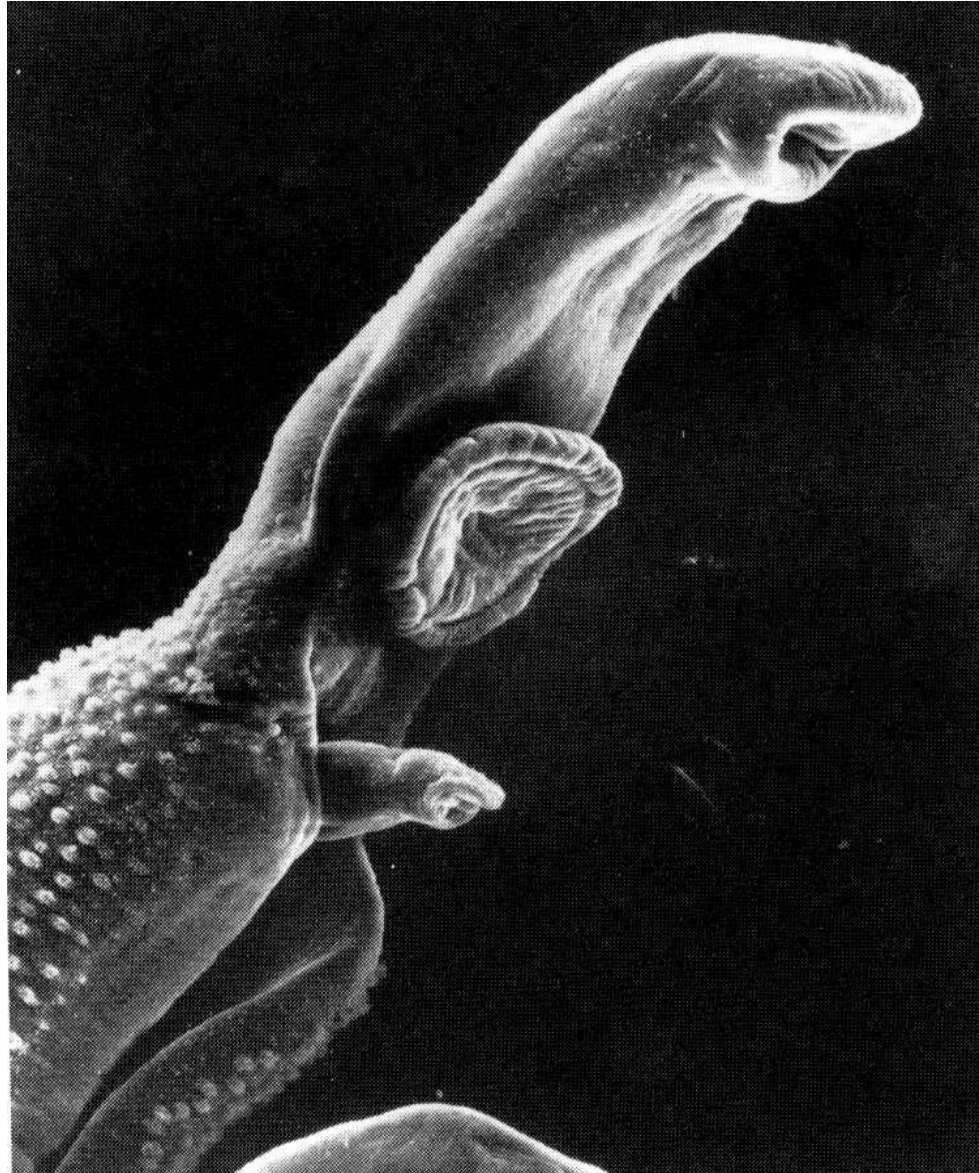
4



6

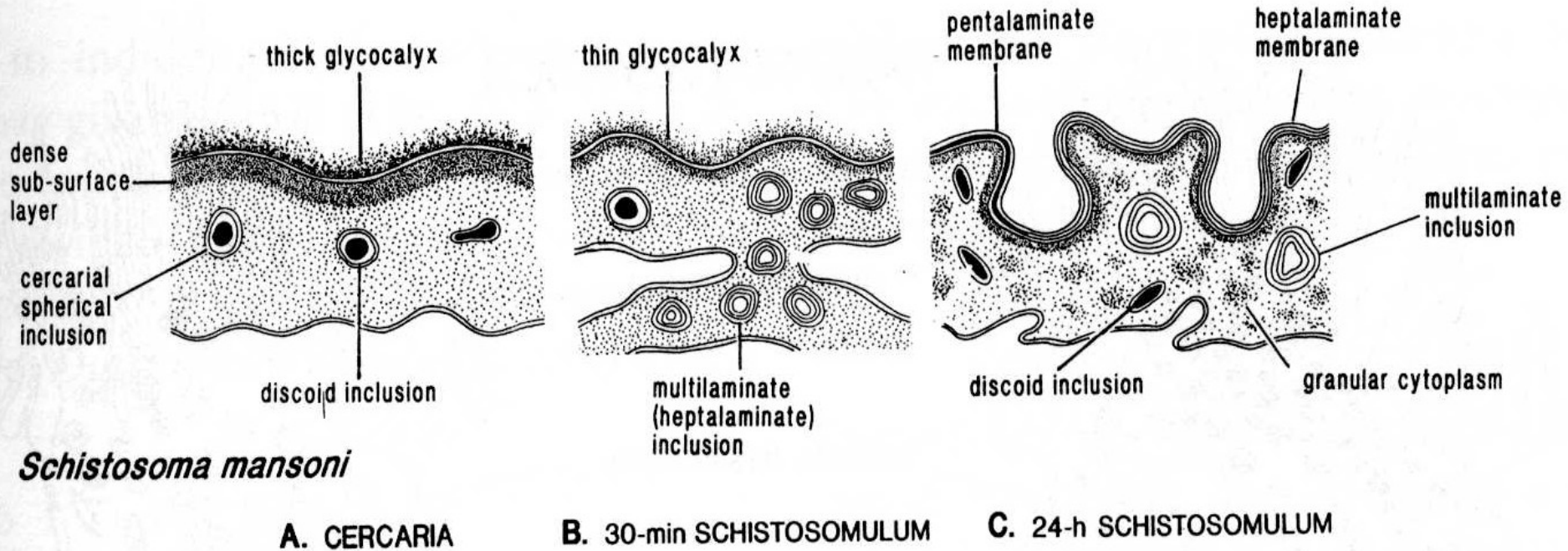


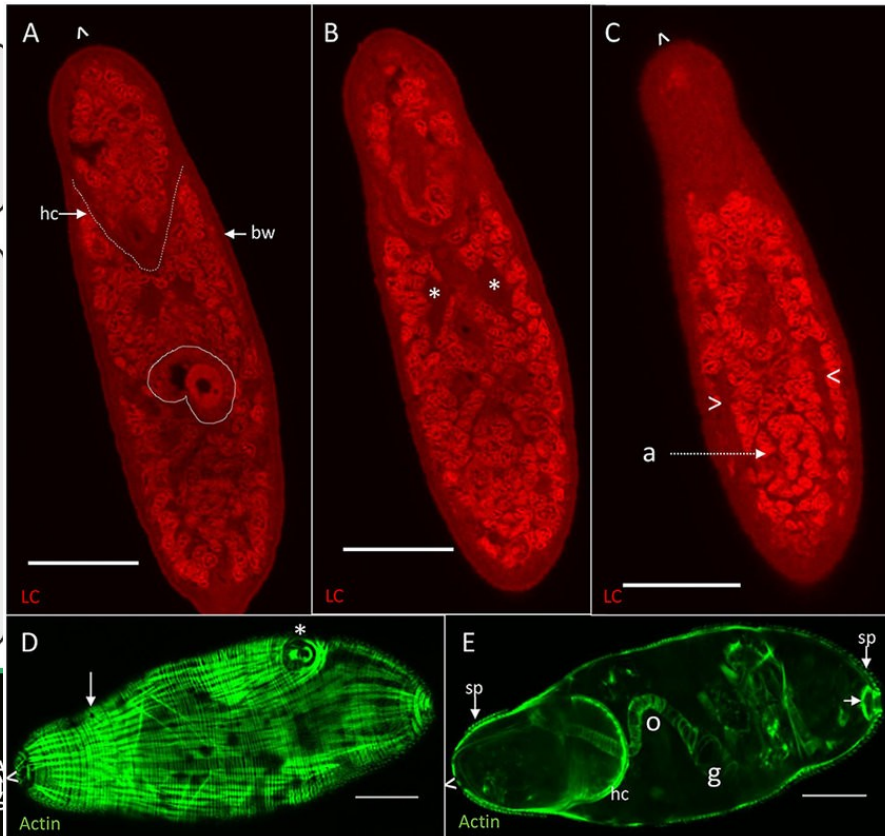
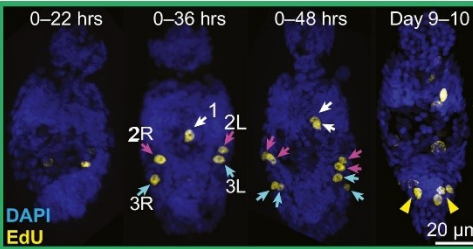
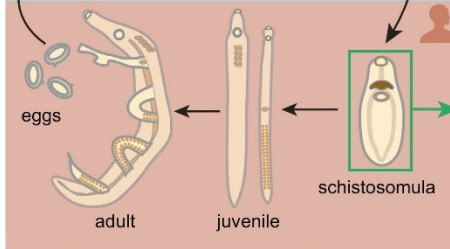
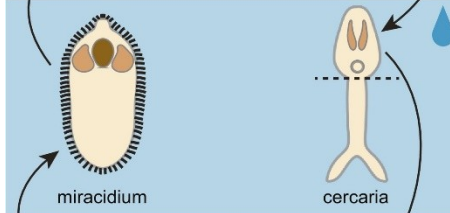
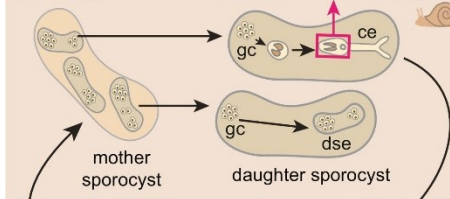
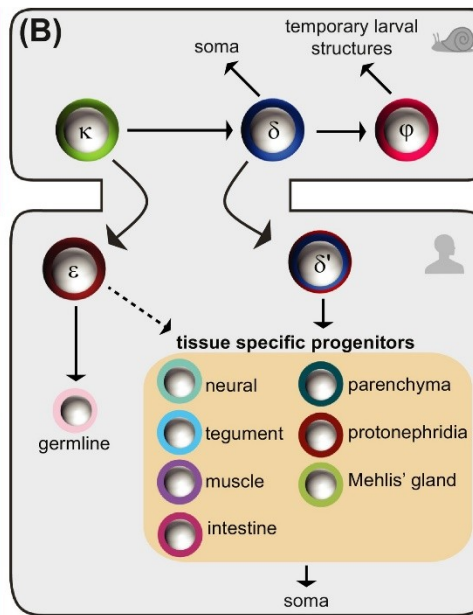
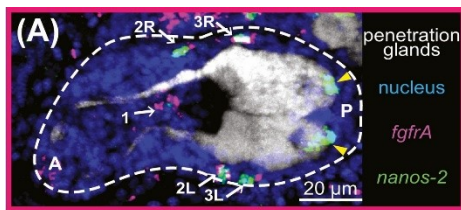
# Schistosomy - haematofagie





# Transformace tegumentu



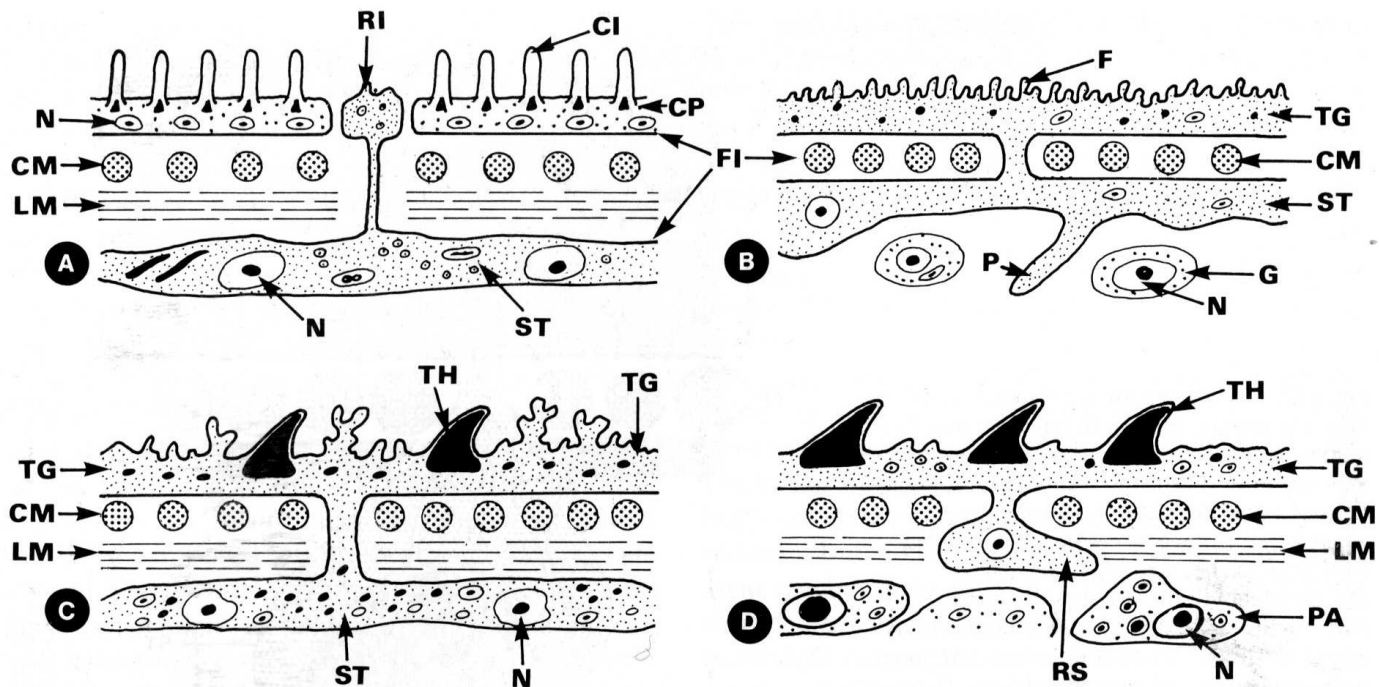


Trends in Parasitology

# 3 denní schistosomulum



# Vývoj tegumentu schistosom



**Fig.3.58 A-D.** Diagrammatic representation of the development of the syncytial tegument in digeneans (*Schistosoma mansoni*). **A** Miracidium which is covered by ciliary plates and ridges formed by the subtegumental layer. **B** Mother sporocyst after detachment of ciliary plates. **C** Daughter sporocysts are covered by a syncytial tegument, which is connected by bridges with the subtegumental layer. **D** Cercariae: the subtegumental layer becomes reduced, and later paren-

chymal cells will contact the syncytial tegument. *CI*, Cilia; *CM*, circular muscles; *CP*, ciliary plate; *F*, foldings; *FI*, fibrous layer; *G*, germinal cells; *LM*, longitudinal muscles; *N*, nucleus; *P*, protruding subtegument; *PA*, parenchymal cell; *RI*, ridge; *RS*, remnants of the subtegument; *ST*, subtegumental layer; *TG*, tegument; *TH*, tegumental thorn (hook)

# Schistosoma - ekologie





# Schistosoma - ekologie



**Fig. 2.63** Ecology of *Schistosoma japonicum*.

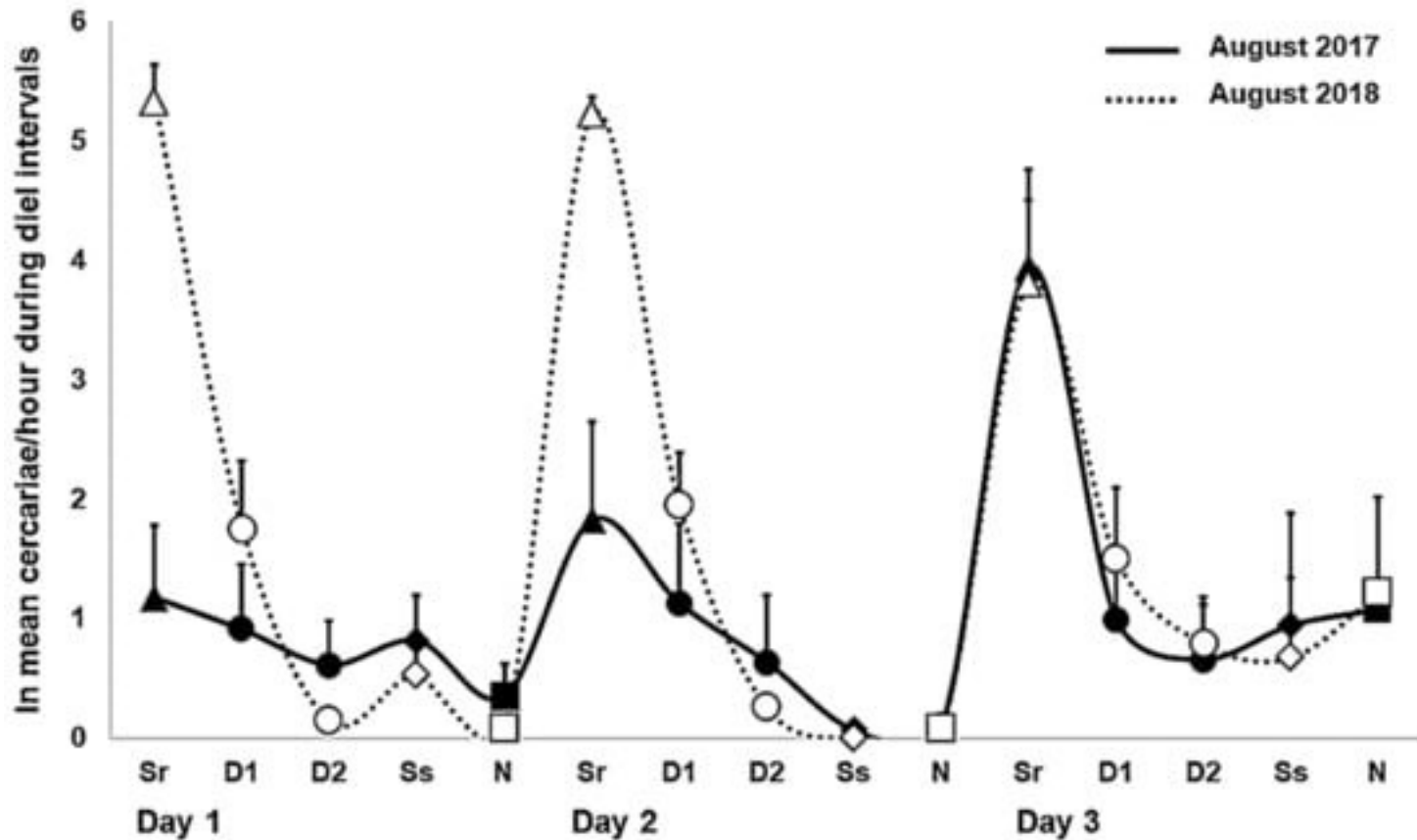
This zoonotic infection can be detected in cattle and domestic animals. Human infection occurs during exposure to contaminated water; for example when planting rice in paddy fields. (Courtesy, Dr. K. Woods.)



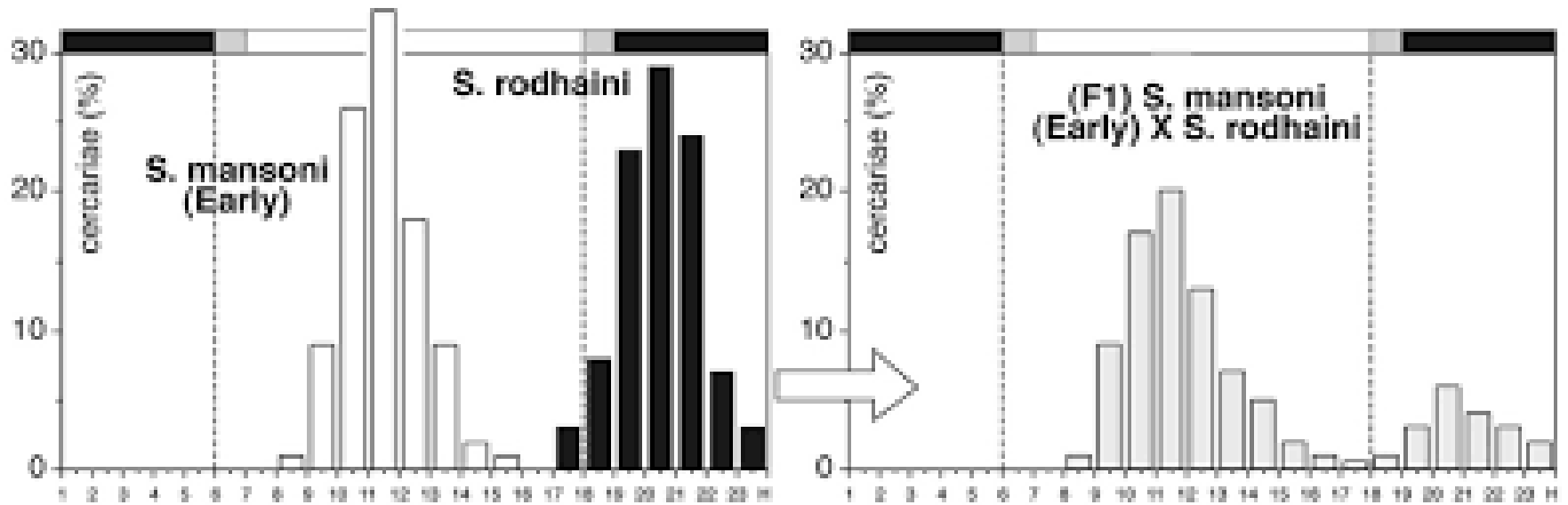
**Fig. 2.64** Ecology of *Schistosoma mekongi*.

Removal of the intermediate snail host, *Neotricula aperta*, of this most recently identified human schistosome is challenging, so mass drug administration of affected populations has been the mainstay of human disease control. The tiny snails are found on the submerged underside of rocks just like those upon which these children are sitting (see also Fig. 2.50). (Courtesy, Dr A Stich.)

# Cerকারী emergence



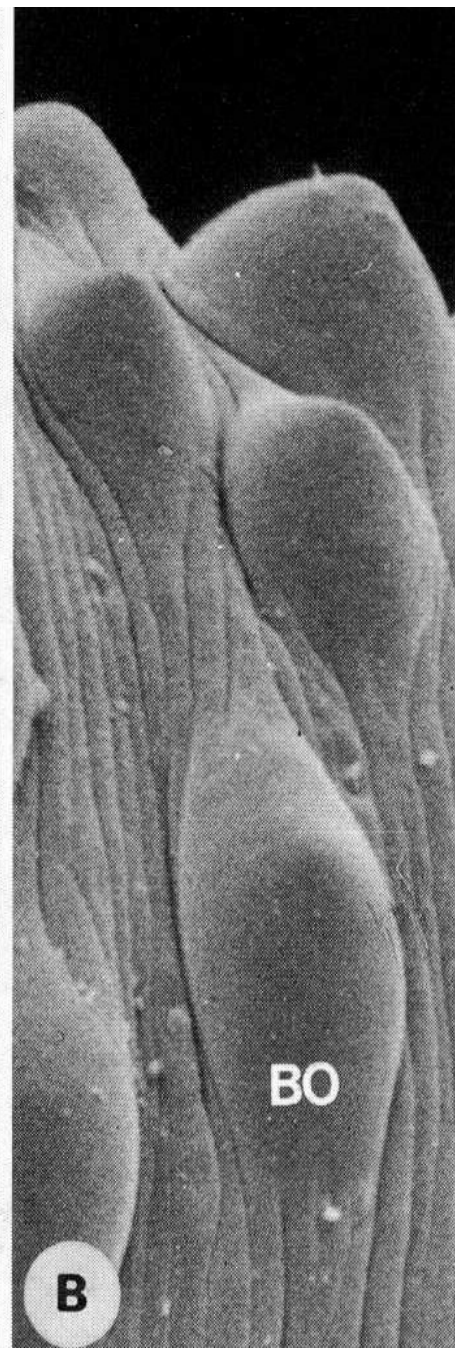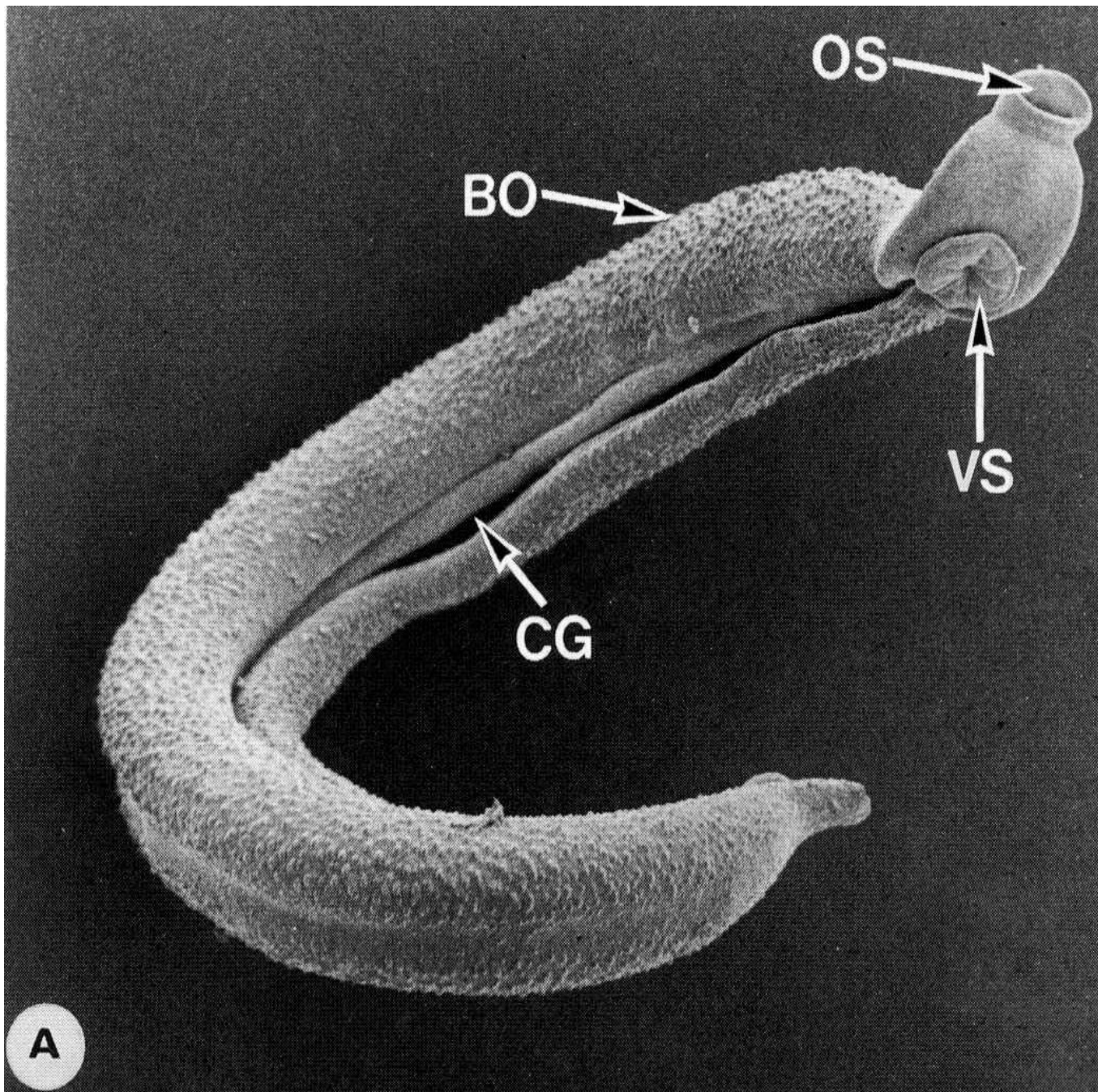
# Schistosoma mansoni versus S. rodhaini



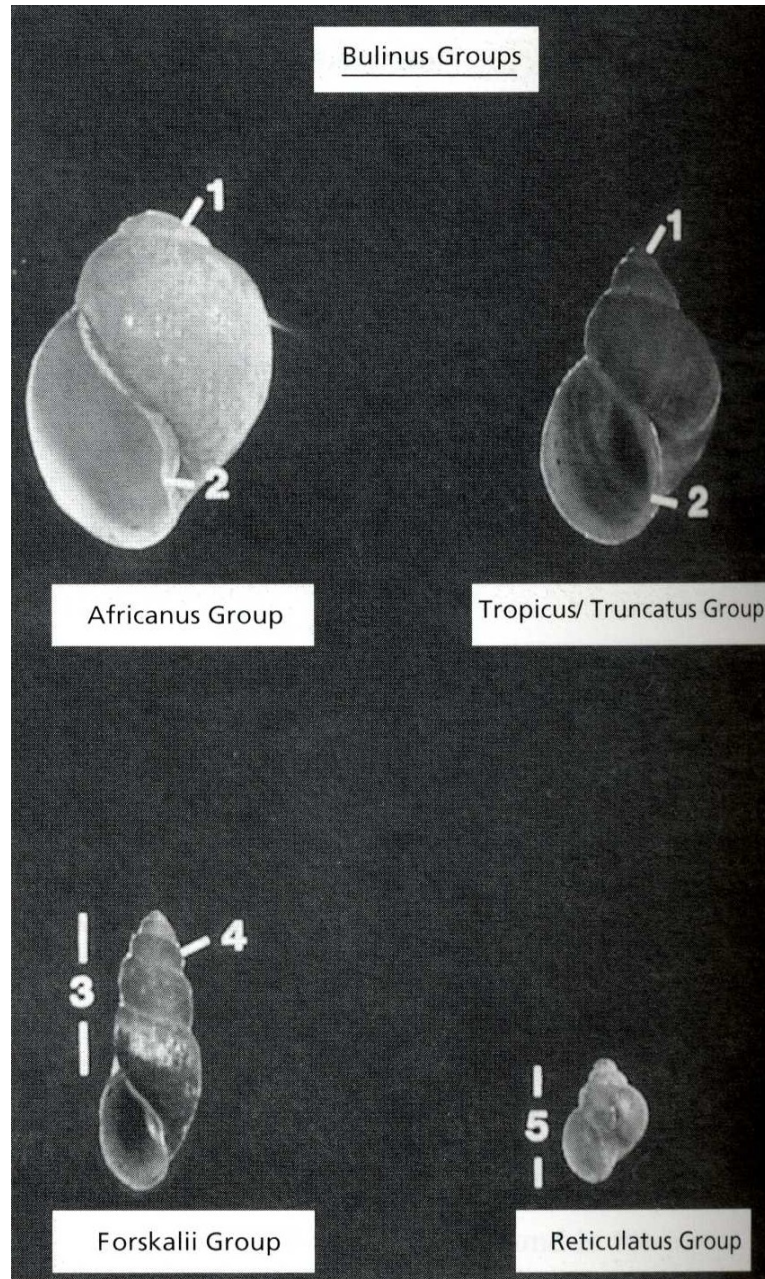


# Schistosoma haematobium

- Urogenitální schistosomóza
- Afrika, střední východ
- Kapiláry kolem močového měchýře (hematurie)
- Mezihostiteli plicnatí plži rodu *Bulinus*, *Physopsis*, *Ferrisia*
- Vajíčka uvolňována především močí
- Plicní forma po embolizaci vajíček
- Rezervoárem hlavně lidé

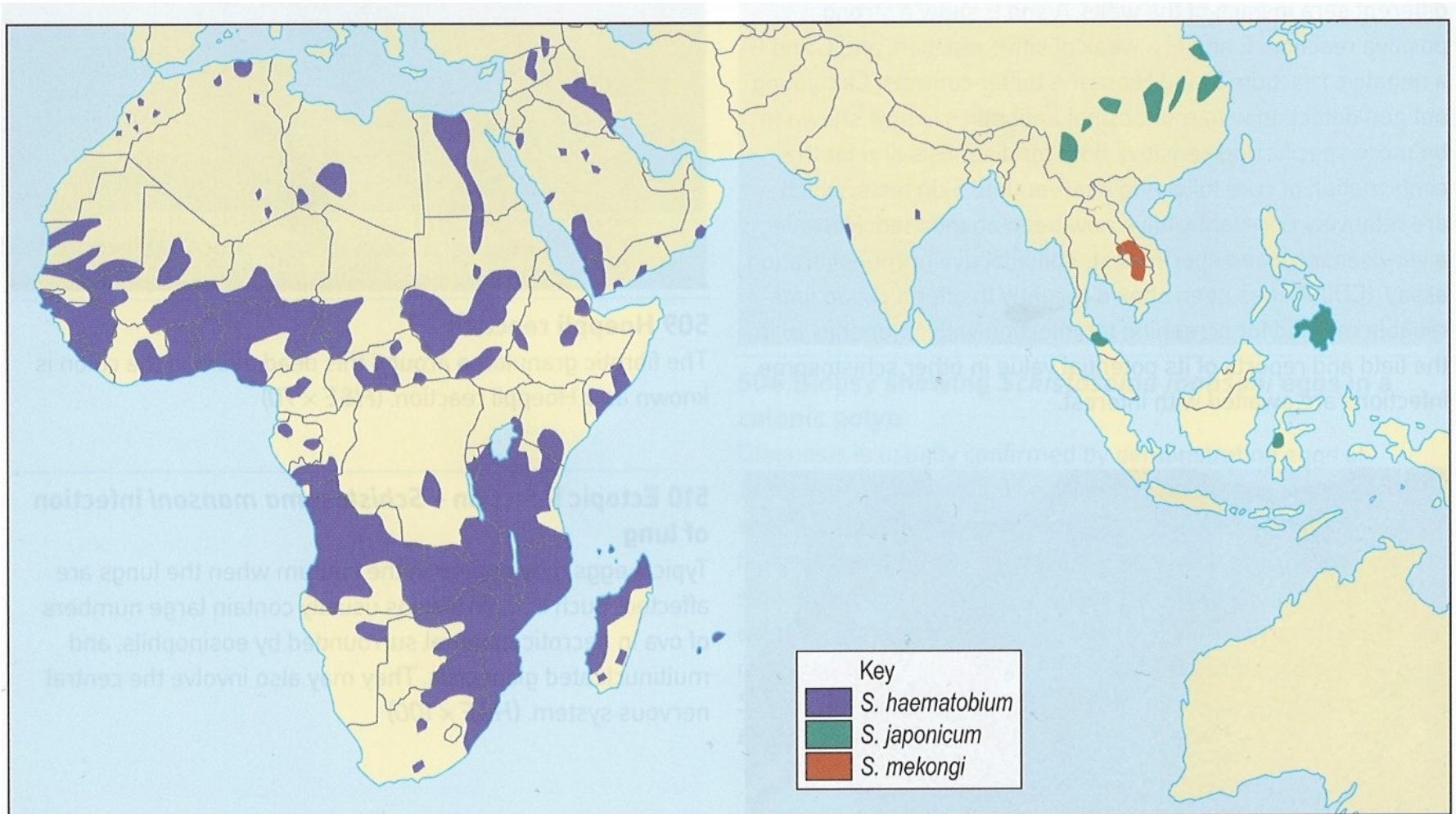


# Schistosoma haematobium





# Schistosoma haematobium, S. japonicum a S mekongi

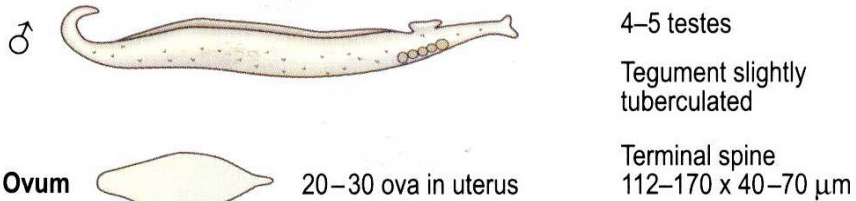



# Schistosoma haematobium

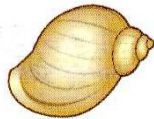
## *Schistosoma* species (blood flukes) (Continued)

### Morphology

*S. haematobium*

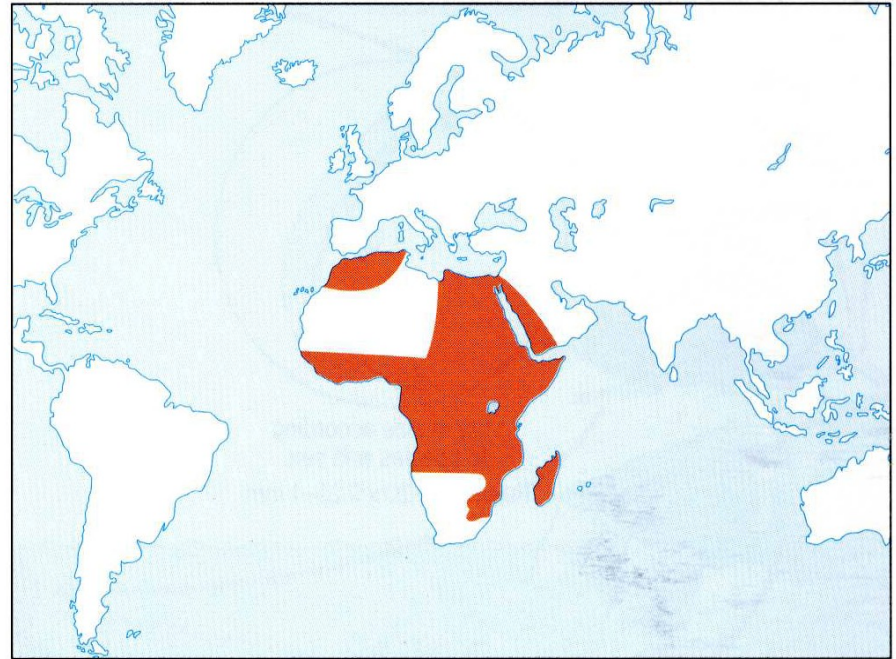


Host: *Bulinus*



### Distribution

*S. haematobium*: 78 million

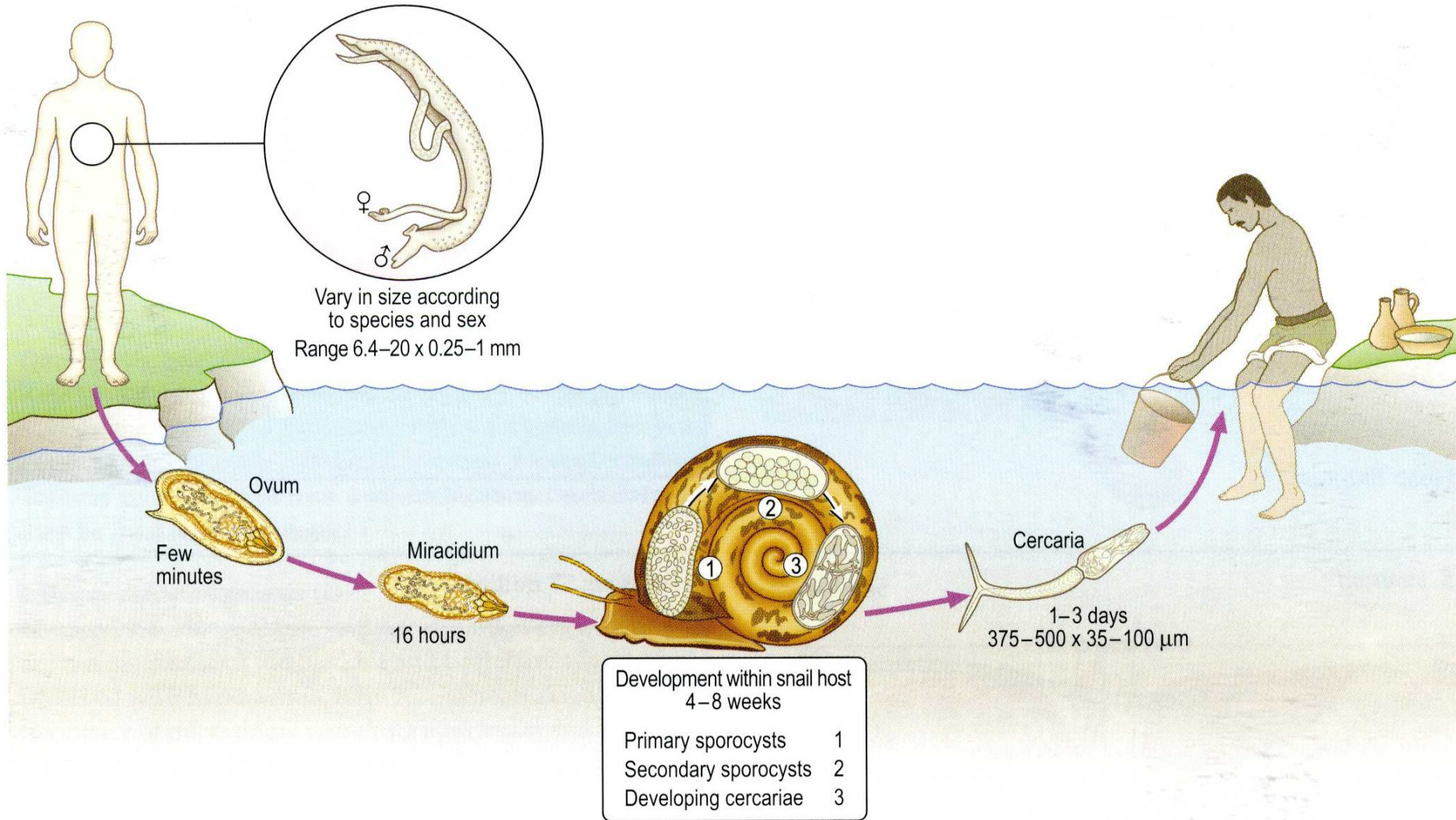




# Trematode (flat) worms

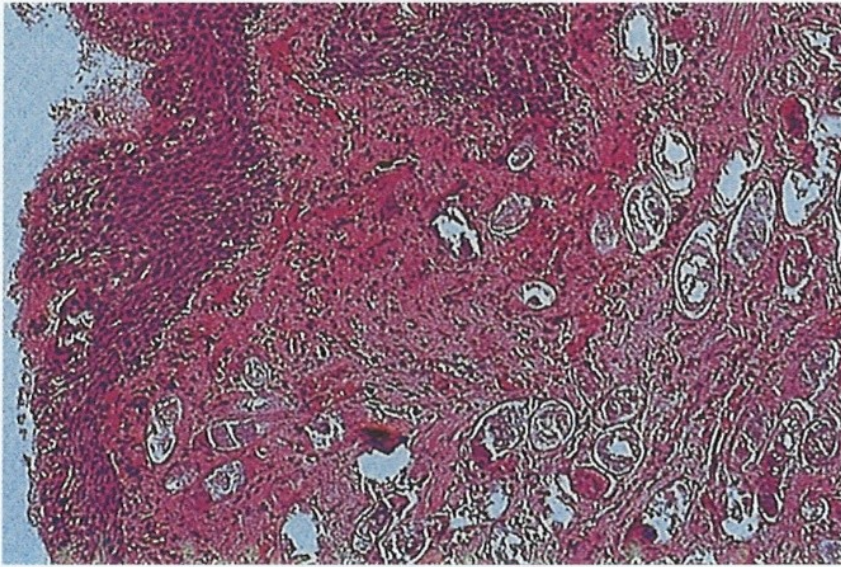
## *Schistosoma* species (blood flukes)

### Life cycle for all species



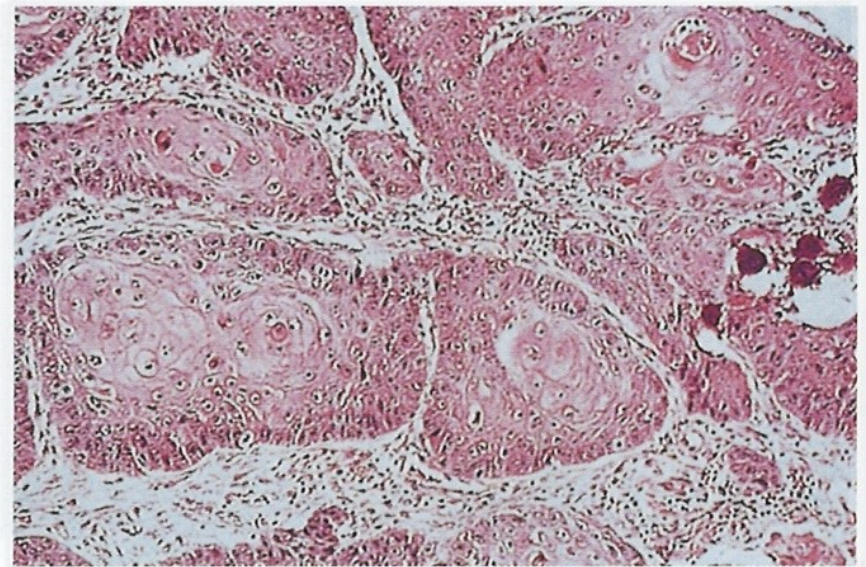


# Schistosoma haematobium – vajíčka ve stěně měchýře a karcinom stěny měchýře



## 526 Eggs in section of bladder

Schistosome ova laid by female worms in the vesical plexus are retained in the vesical tissues and later become calcified. (H&E  $\times 50$ )




## 527 Squamous-cell carcinoma of the bladder

In areas where *S. haematobium* infection is intense, the incidence of bladder cancer is high. Squamous-cell carcinoma is the type most commonly found, and ova of *S. haematobium* are often present in such tumours. Adenocarcinoma also occurs. (H&E  $\times 90$ )




# Schistosoma - haematurie



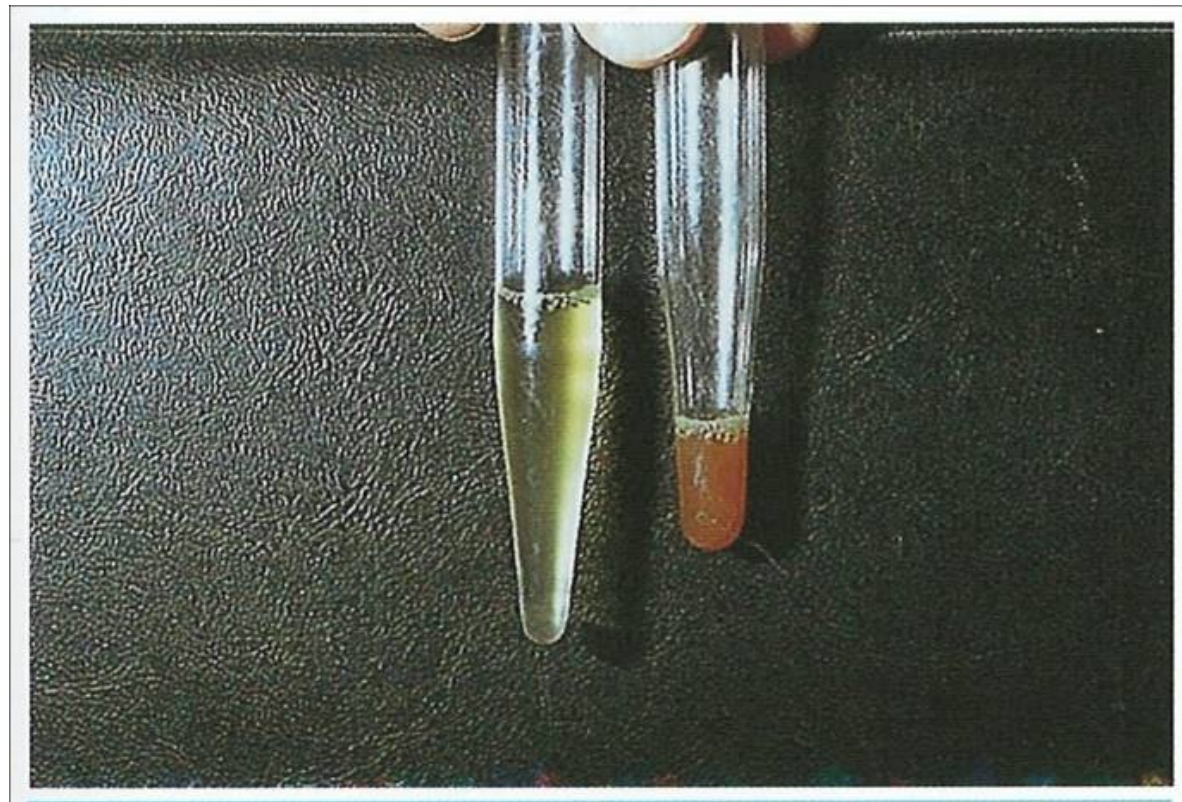
**515 Children in a village in Niger with urine samples**

Haematuria is often best seen at the end of urination and is a characteristic early clinical feature of infection with *S. haematobium*. (Photo by Dr Jurg Utzinger, Swiss Tropical Institute, courtesy of Professor Alan Fenwick.)




**517 Village survey for urinary schistosomiasis**

A simple and effective technique to detect eggs in urine is to pass samples through a nylon-mesh filter attached to a 10 ml syringe. The filter is removed and examined under the microscope using a  $\times 10$  objective, and the eggs collected on it are counted. A simple dipstick test for protein and blood is a useful supplementary method of assessing the prevalence of those passing eggs, and may even replace microscopy. This procedure, which saves labour, time and money, facilitates the delivery of treatment programmes in communities for which such intervention might otherwise be delayed (or not provided at all) and is valuable for assessing the effectiveness of such programmes.





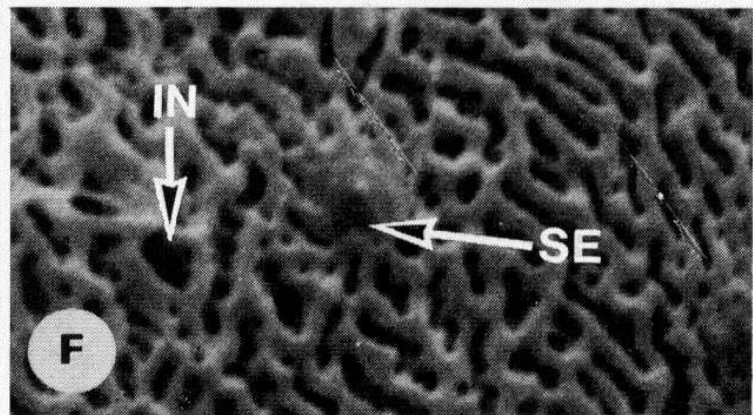
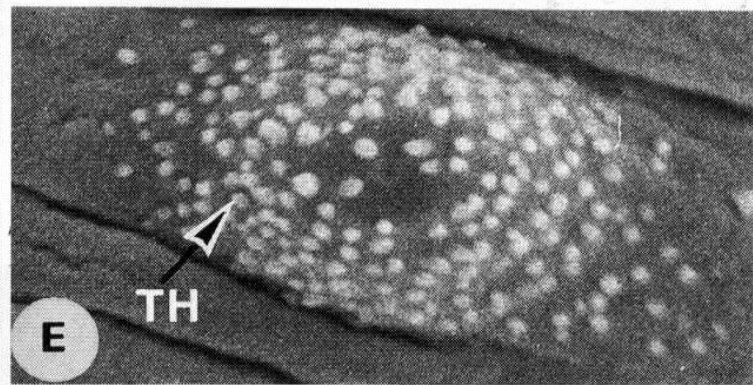
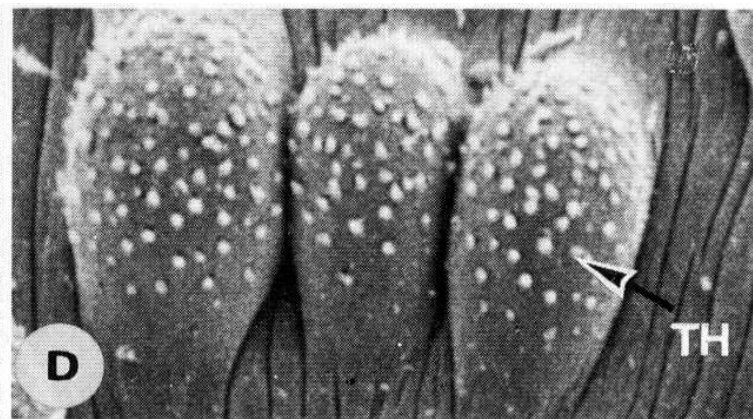
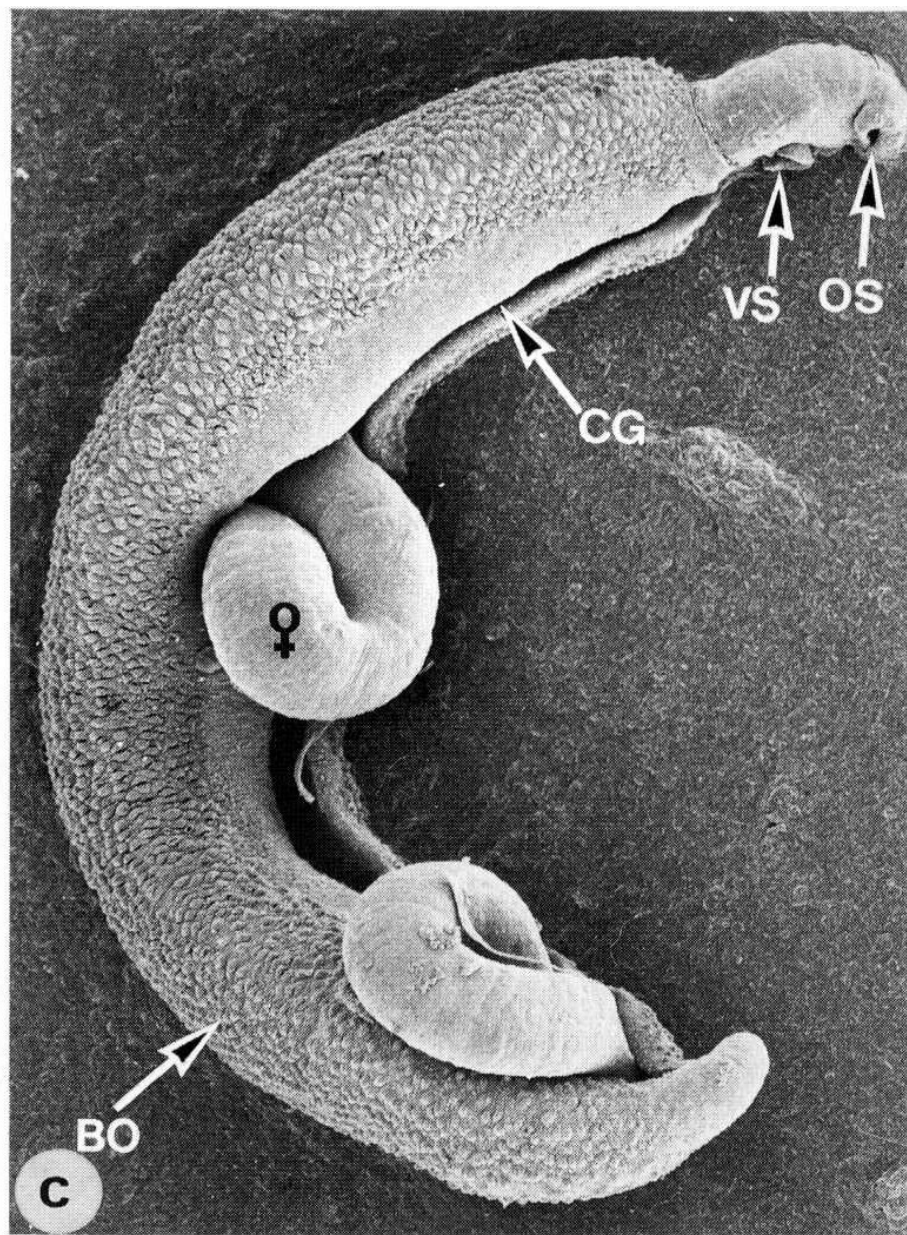
# Mezihostitelé *Schistosoma haematobium* - ekologie



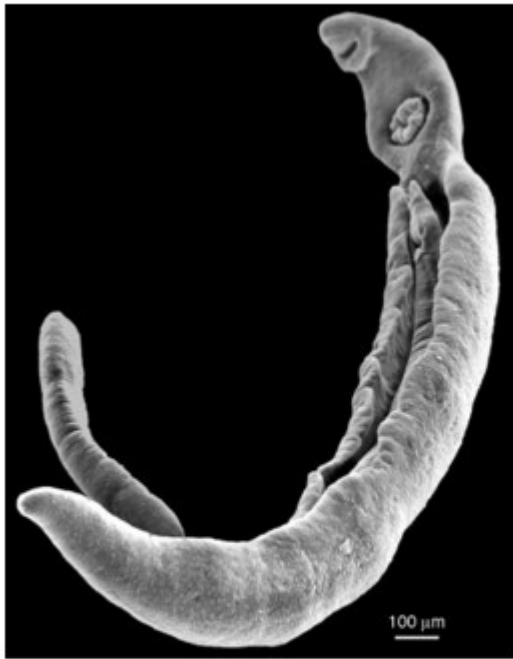

# Schistosoma mansoni

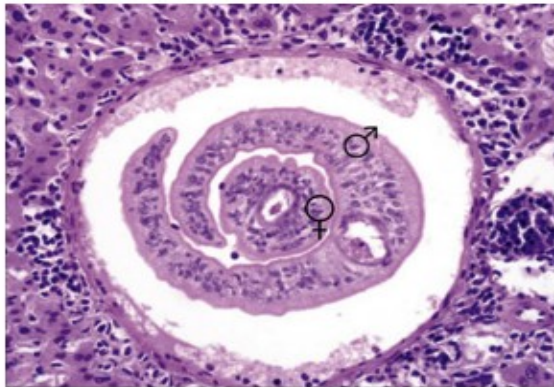
- Střevní schistosomóza
- Afrika, Střední Východ, Latinská Amerika, (Brazílie, Venezuela), karibská oblast
- Mezenterické cévy kolem střeva, především tlustého
- Hepatosplenomegalie
- Mezihostitelé vodní plicnatí plži Biomphalaria, Australorbis, Tropicorbis
- Vajíčka uvolňována stolicí
- Plicní forma po embolizaci
- Rezervoárem lidé, opice, hlodavci



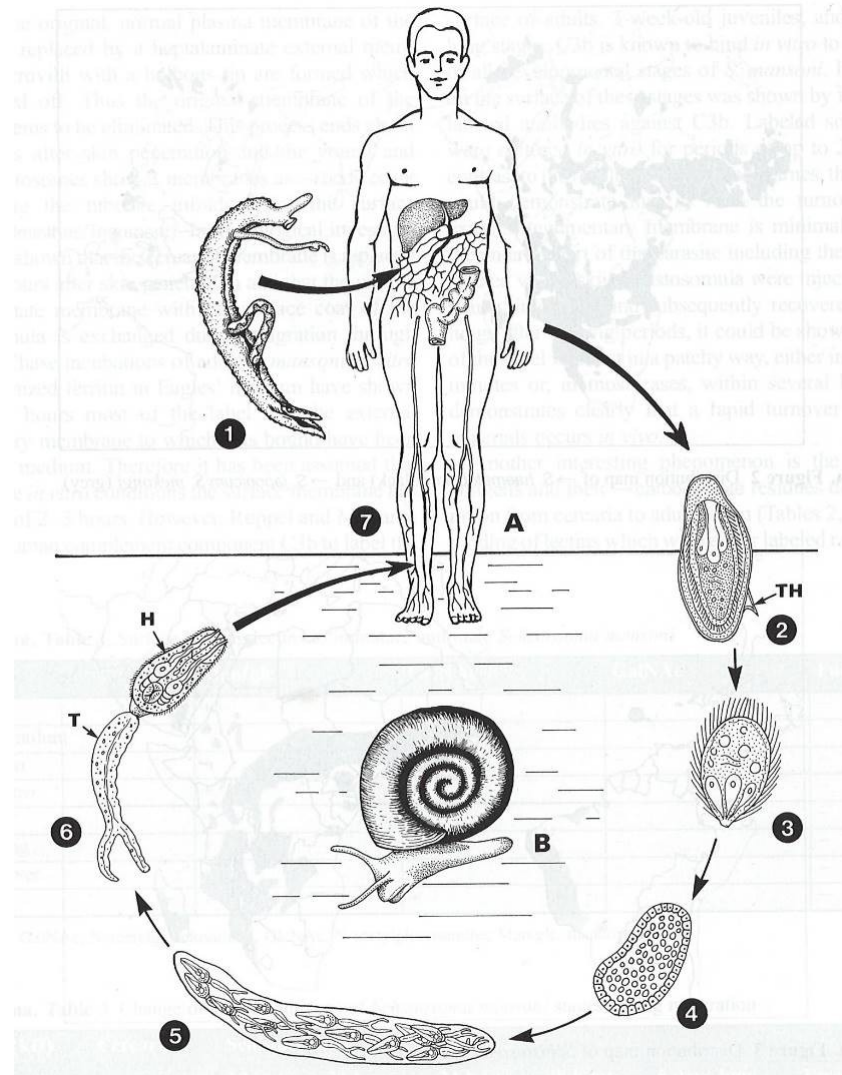
# Schistosoma mansoni



**Fig. 2.45** Male and female *Schistosoma mansoni* adult worms. The slender female lies enveloped within the gynaecophoral groove of the larger male. (Courtesy, D. Estabriet, Beltran S., Boissier, J. Schistosome monogamy: who, how and why? In Trends in Parasitology.

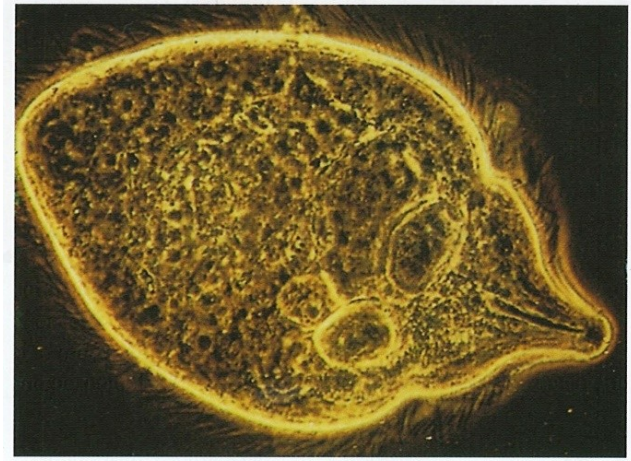
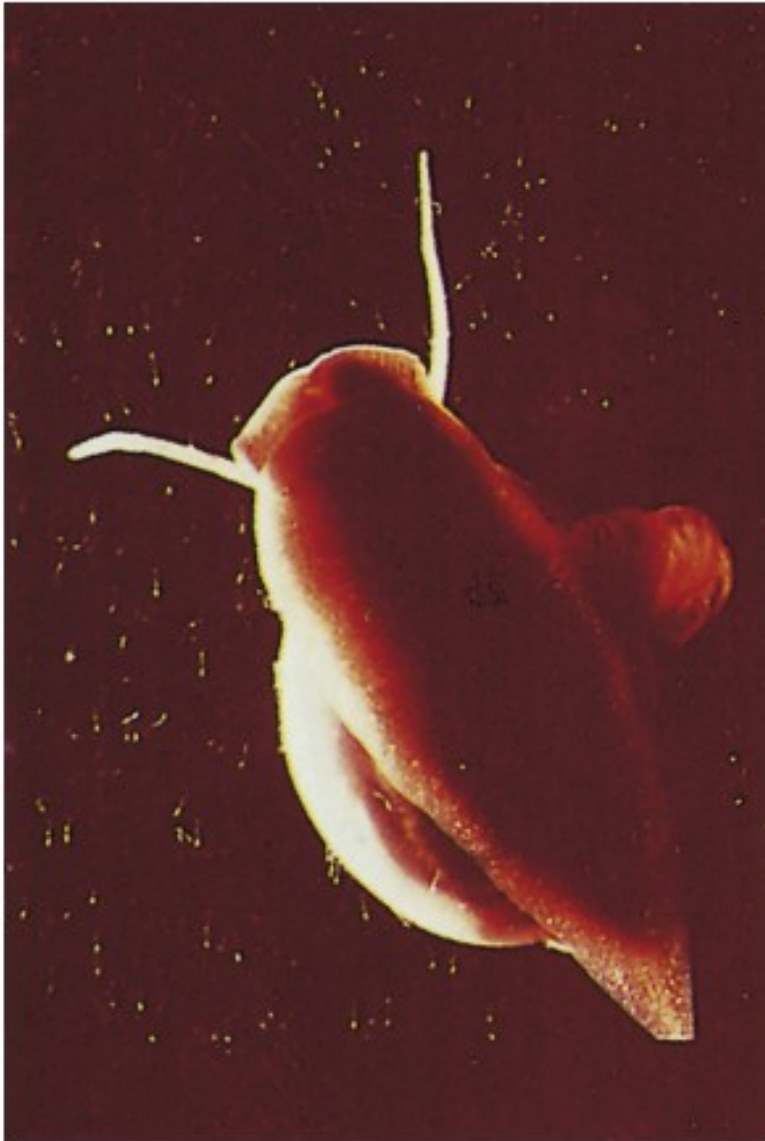
**Fig. 2.46** Adult *Schistosoma mansoni* worm pair in portal tract. Cross-sectional view of adult worm pair in a state of permanent copulation in a branch of the portal vein. (Courtesy B.A.Mathison, from Zaki S.R., Alves V.A.F., Hale G.L. Non-hepatotropic viral, bacterial and parasitic infections of the liver. In: MacSween's Pathology of the Liver, Ch 7, 416-490, Figure 7.73B, e7, 2018, Elsevier.)





# Schistosoma mansoni



**480 Hatched miracidium of *Schistosoma mansoni***

The three common species of schistosomes infecting humans have easily recognisable eggs, although those of *S. haematobium* may be confused with those of *S. intercalatum*

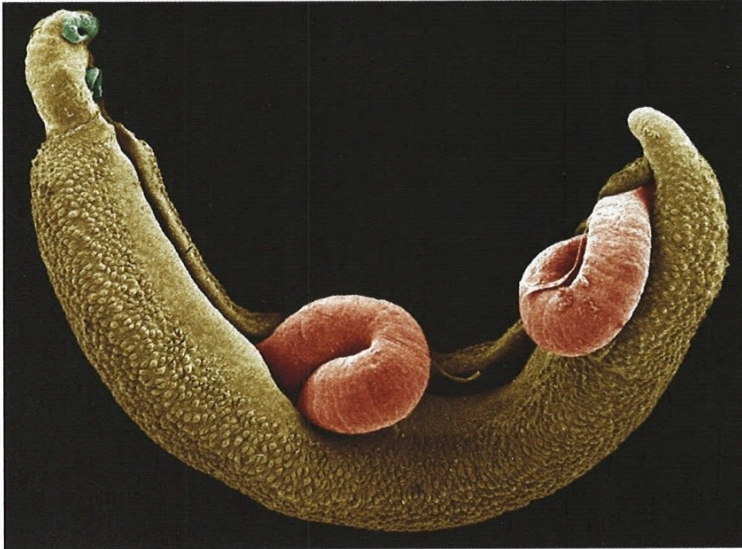

**Fig. 2.47** *Biomphalaria* sp.

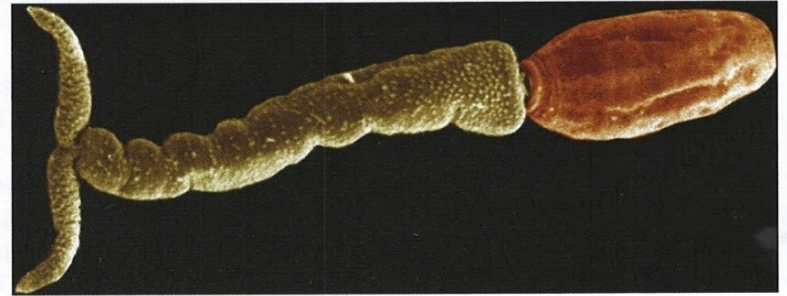The snail intermediate host of *Schistosoma mansoni*. (Courtesy, C. Whitehorn)



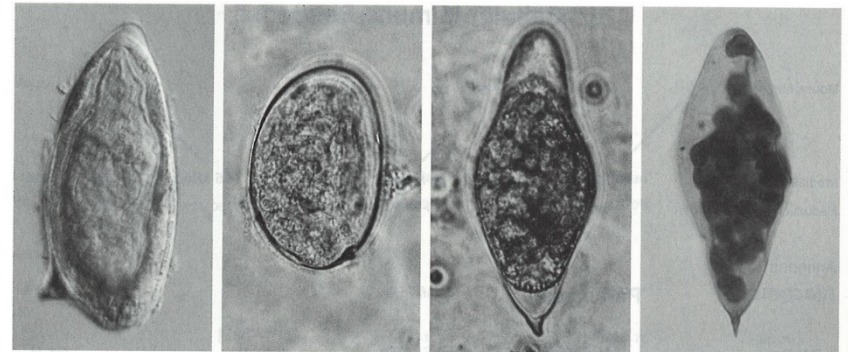
# Schistosoma mansoni



**Fig. 4.1** Scanning electron micrograph of a couple of the species *Schistosoma mansoni*. The male transports the female inside the so-called canalis gynaeophorous, which is produced by upfolding of the lateral sides of the male

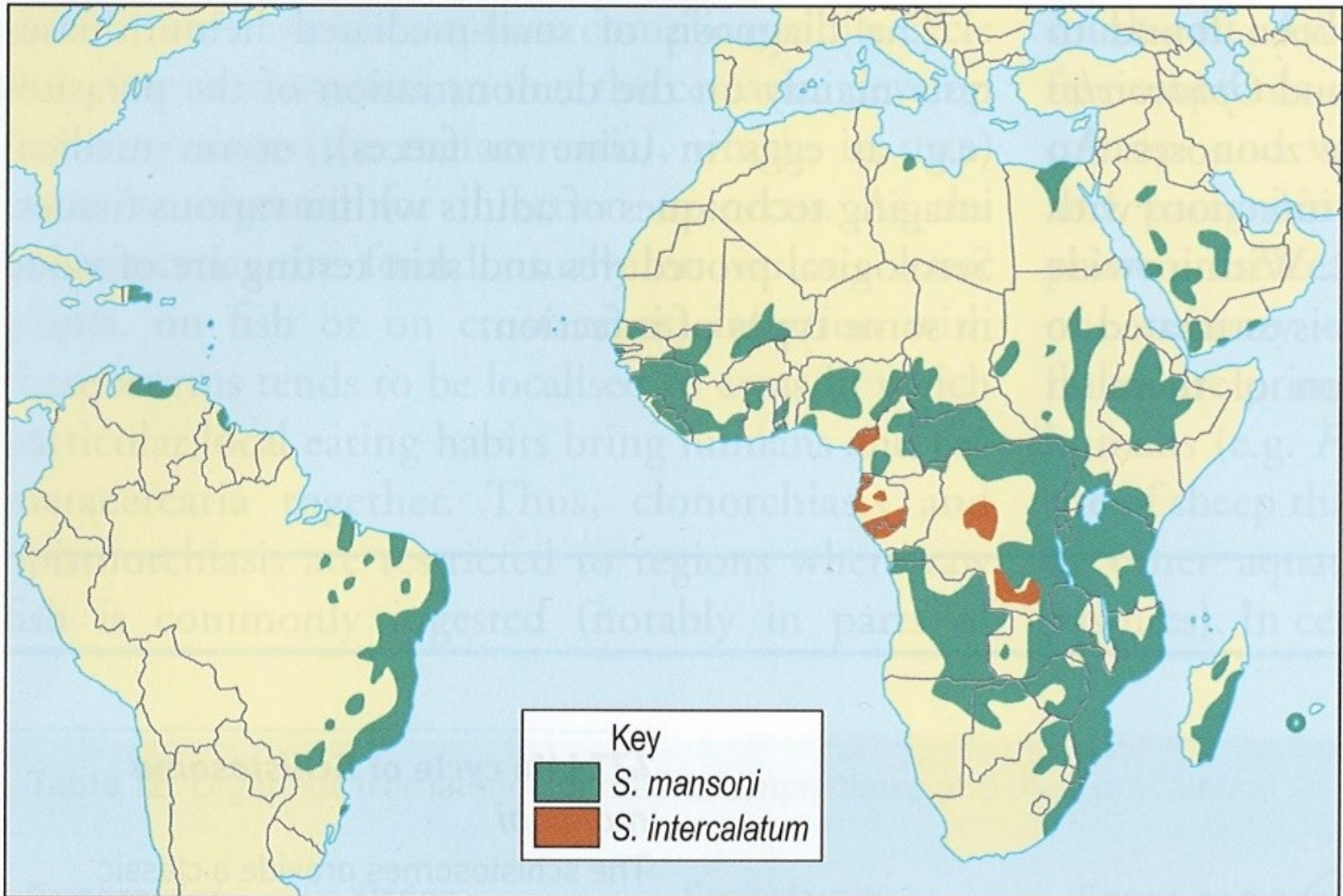


**Fig. 4.2** Scanning electron micrograph of a cercaria of *S. mansoni*



**Schistosomiasis, Man. Figure 5** The eggs of the 4 important *Schistosoma* spp. (from left: *S. mansoni*, *S. japonicum*, *S. intercalatum*, *S. haematobium*).

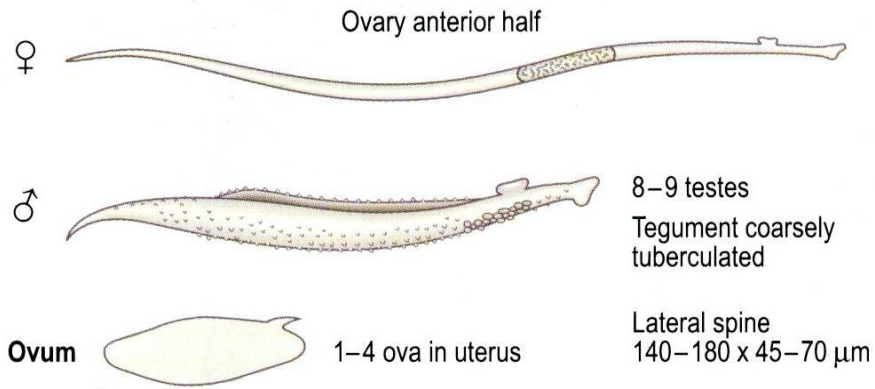
# Schistosoma mansoni a S.intercalatum





# Schistosoma mansoni

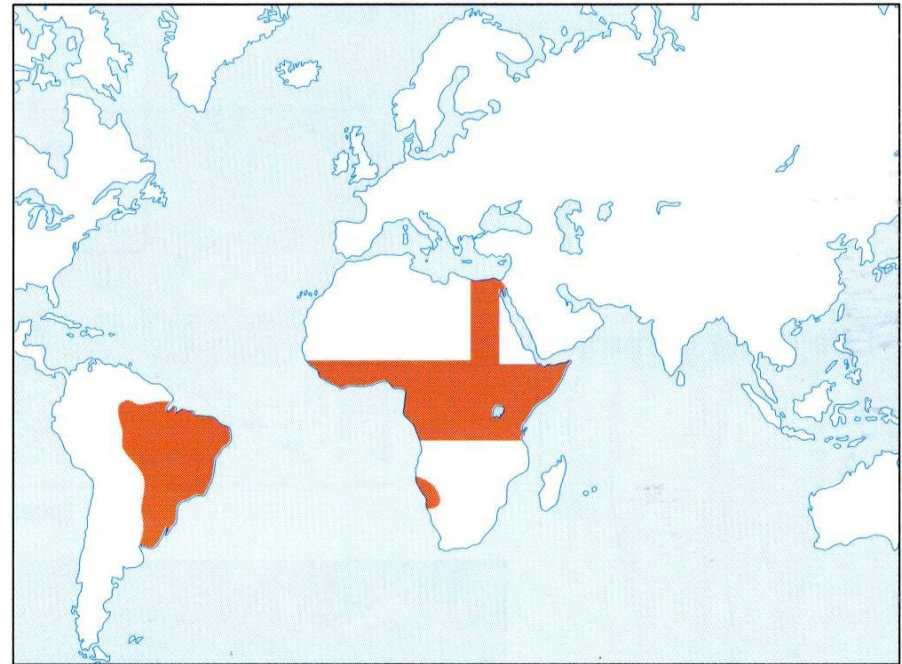
*S. mansoni*



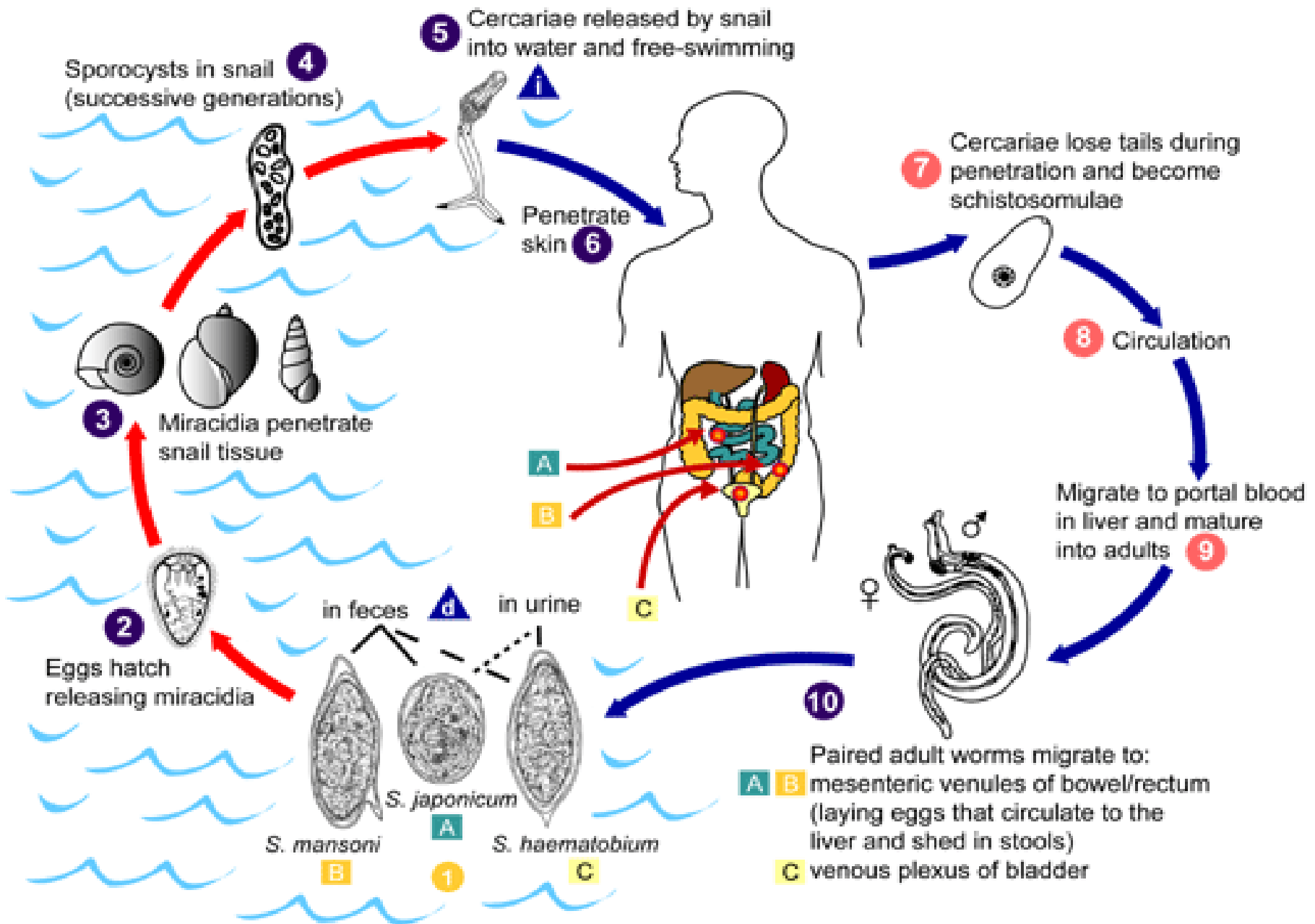
Host: *Biomphalaria*



*S. mansoni*: 57 million

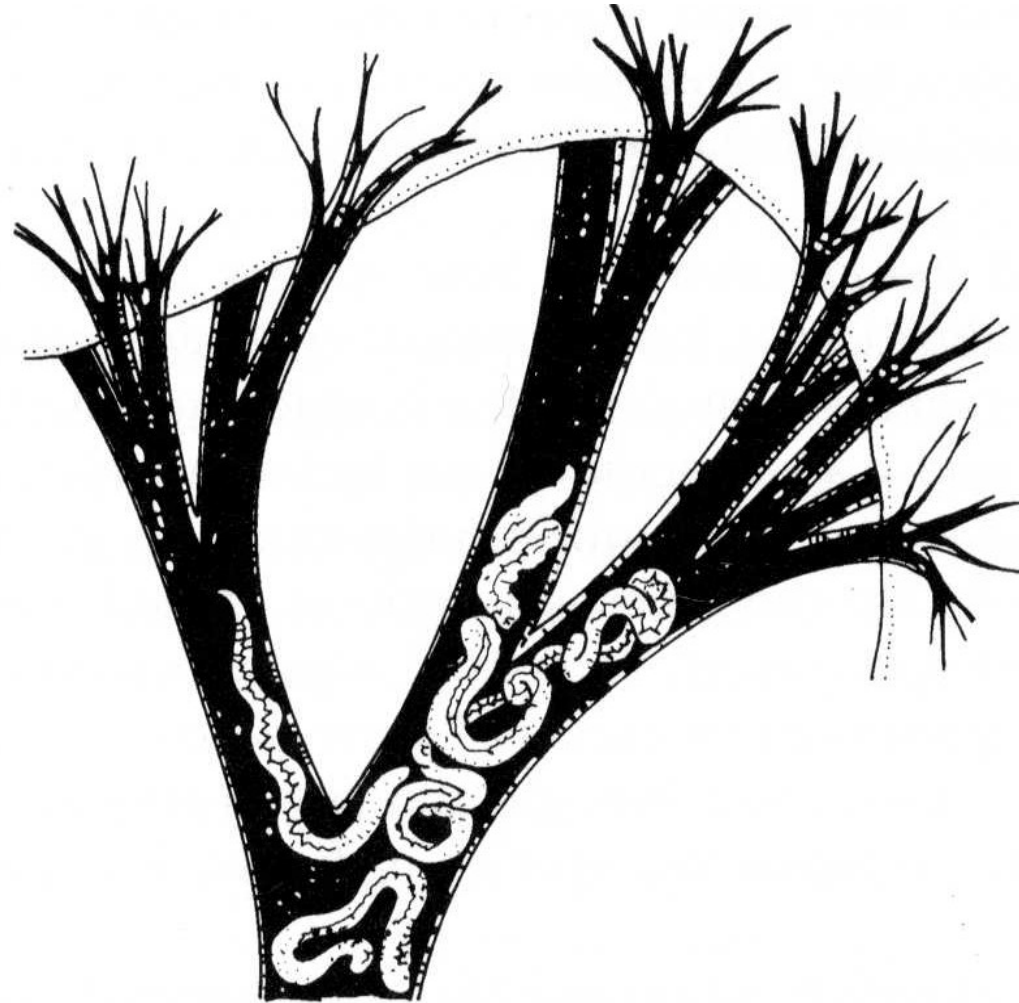

**i** = Infective Stage  
**d** = Diagnostic Stage






# Schistosoma mansoni v cévách hostitele



**Figure 18.1** *Schistosoma mansoni* in a mesenteric vein of a hamster. Source: reproduced from Bae

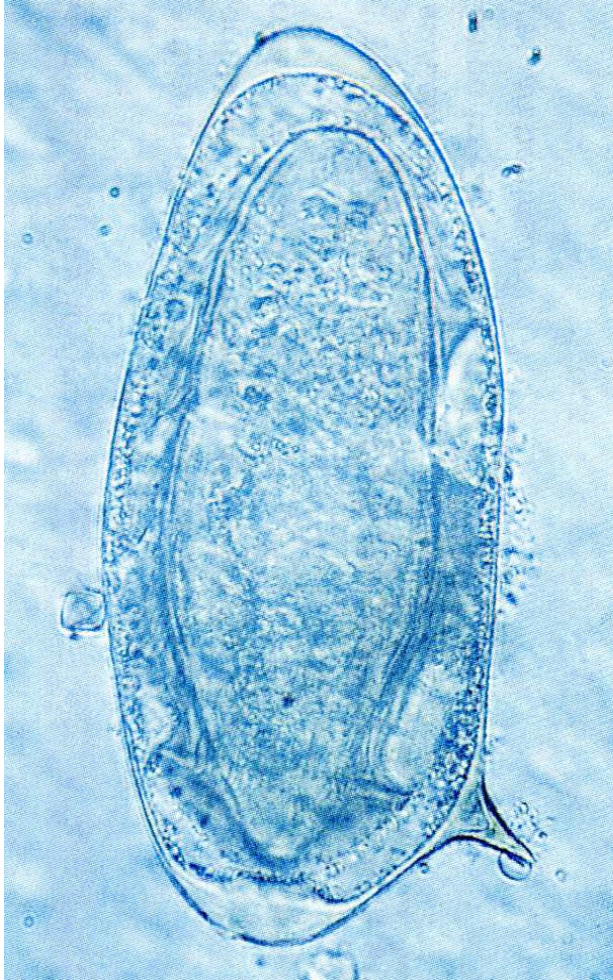
# Schistosoma mansoni



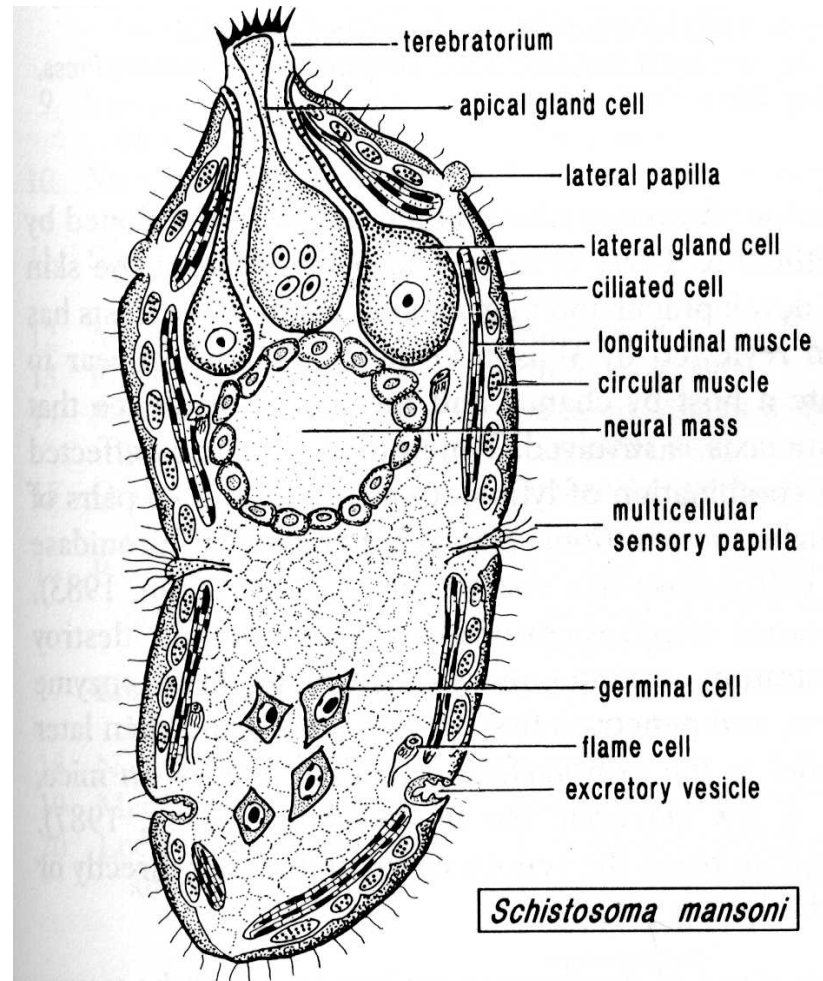
**Figure 29.4** *Biomphalaria glabrata*, an important intermediate



# Schistosoma mansoni

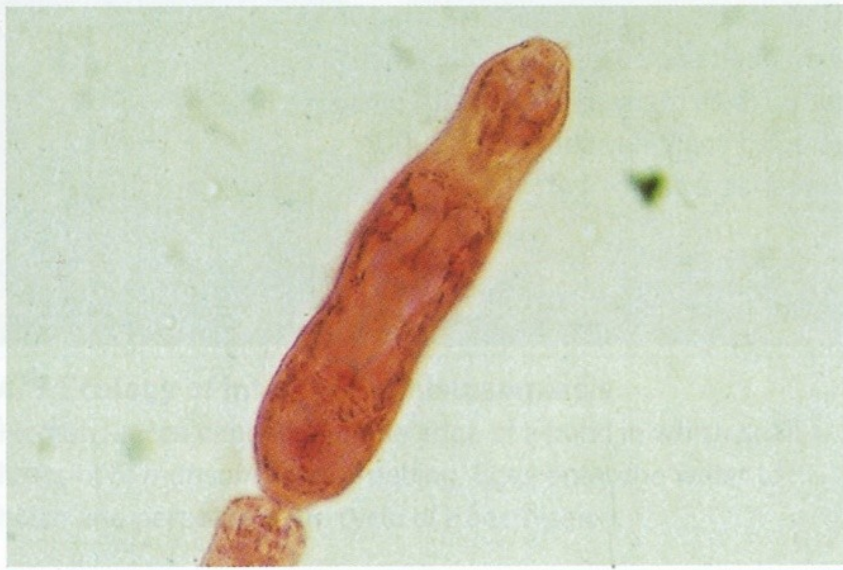

**Figure 29.1** *Schistosoma mansoni* ovum.



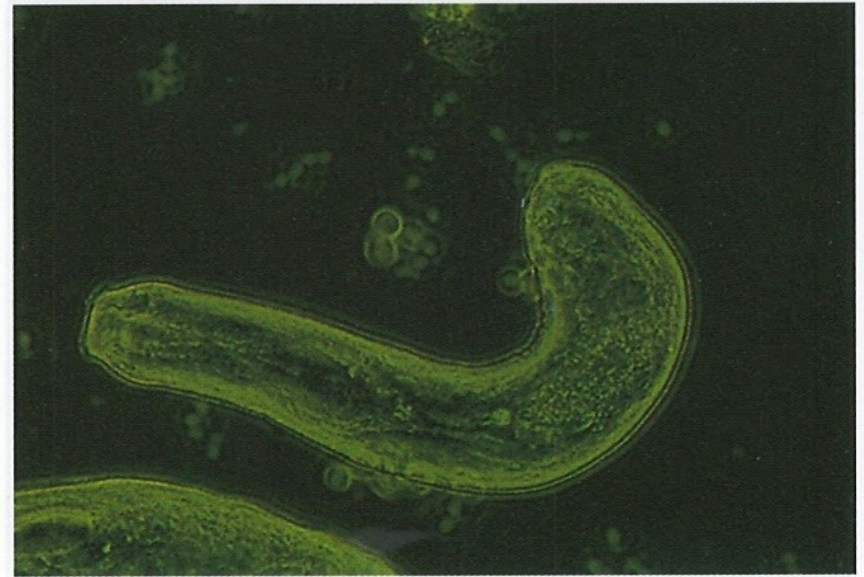

# Schistosoma mansoni – přední konec cercarie a schistosomulum



**484 Head of cercaria**

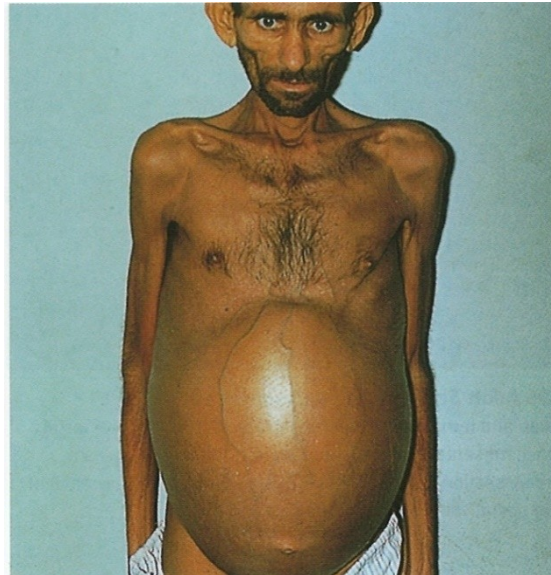
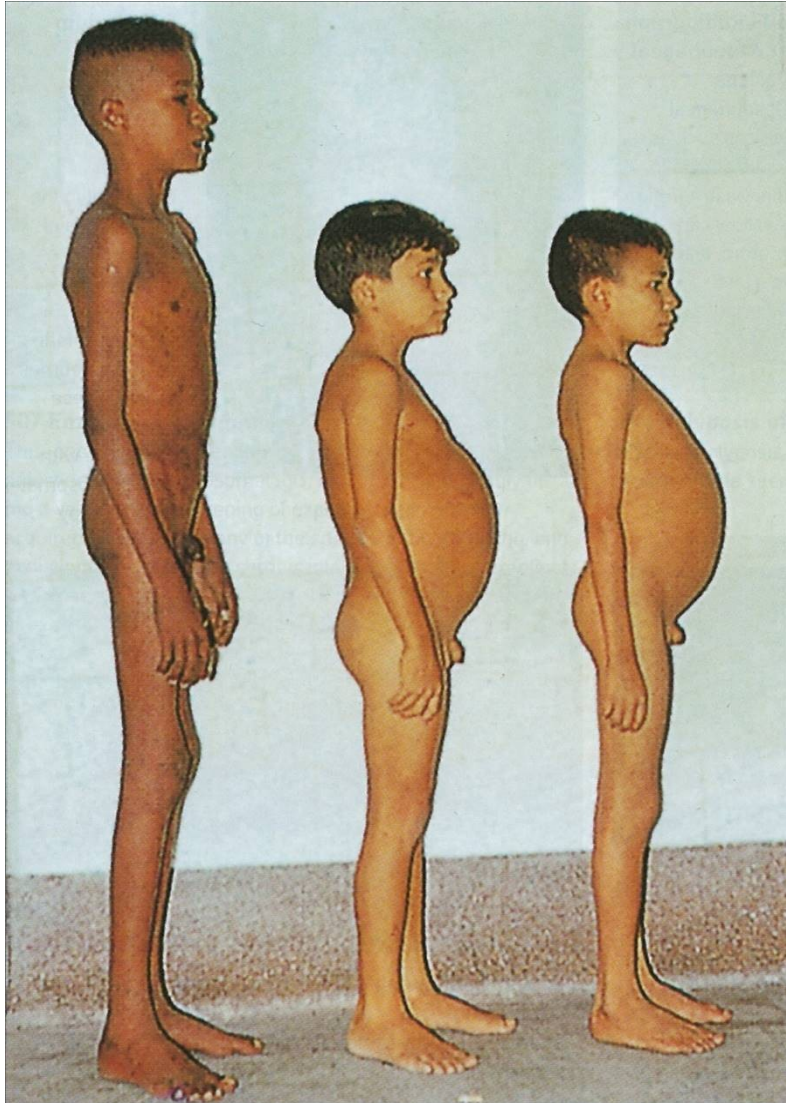
The apical and ventral suckers of the future schistosomule are clearly seen in this preparation. (*Mayer's haemalum* × 310)



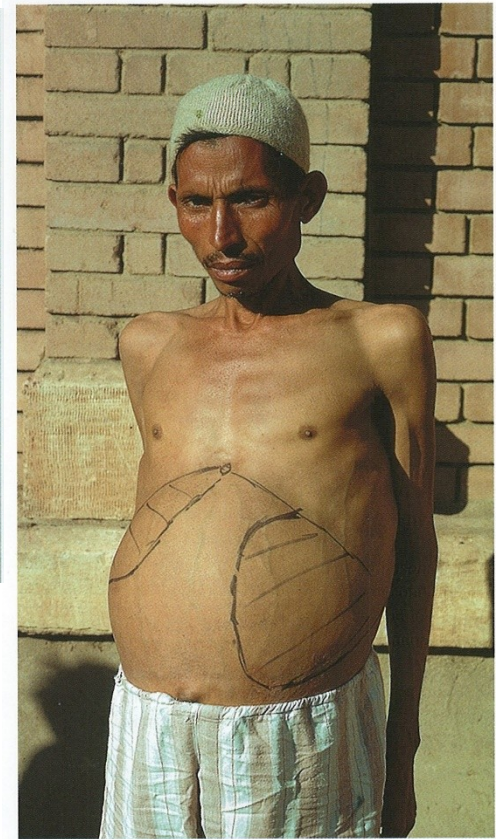
**485 Schistosomule of *Schistosoma mansoni***

(*Phase-contrast* × 350)

# Schistosoma mansoni – retardovaný růst a splenomegalie



Chlapci mají 14, 13 a 12 let; dva vpravo pak chronickou infekci *Schistosoma mansoni*

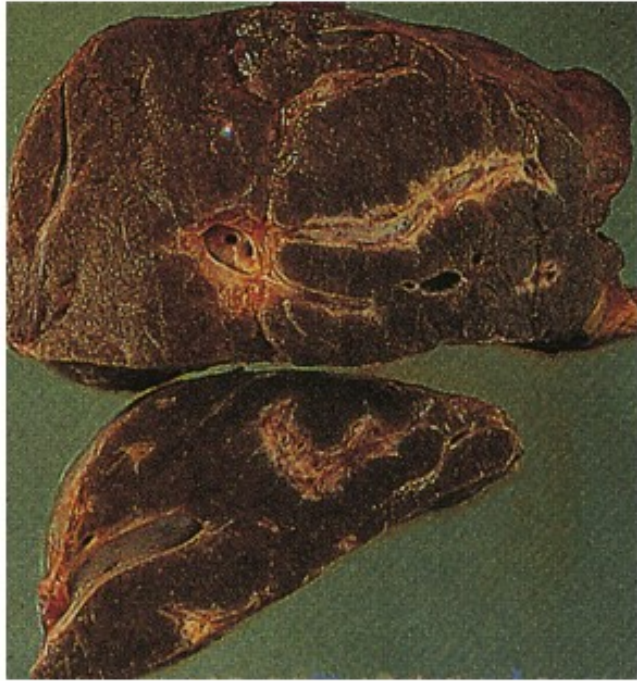

#### 499 Egyptian splenomegaly

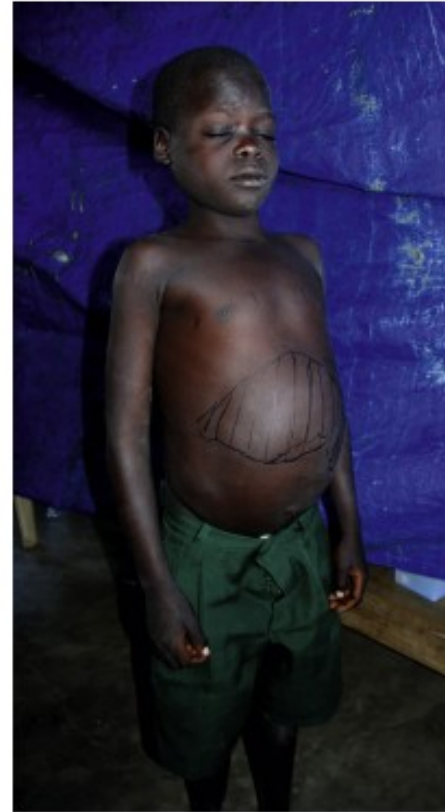The combination of enlarged, irregularly fibrosed liver and greatly enlarged spleen is commonly called 'Egyptian hepatosplenomegaly'.



# Schistosoma mansoni – hepatosplenomegalie/fibróza jater



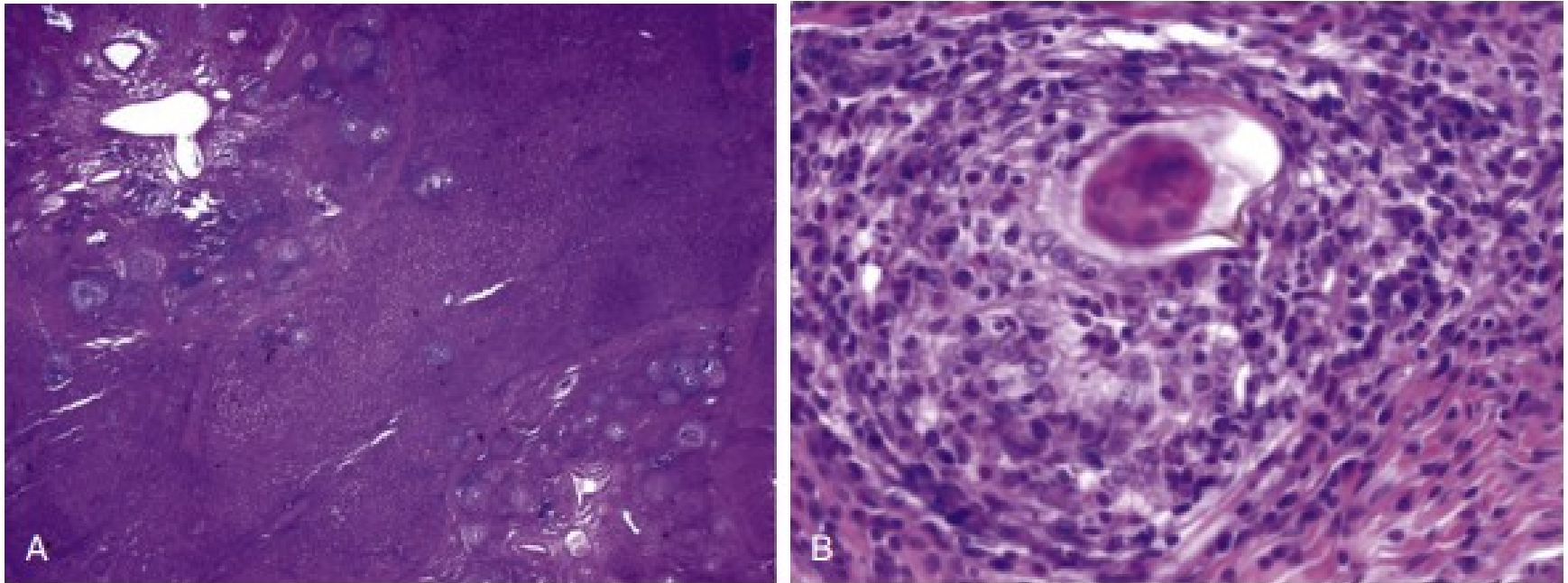
**Fig. 2.55** Periportal 'pipestem' fibrosis.  
This is the characteristic pathological lesion of hepatic schistosomiasis. Pipestem refers to the similarity of the appearance to old clay-to-bacco pipes. (Courtesy, Professor S Lucas)



**Fig. 2.56** Hepatosplenomegaly due to *Schistosoma mansoni*.  
An enlarged liver with splenomegaly in this young Ugandan boy would progress, if untreated, to development of ascites and collateral venous circulation reflecting portal hypertension in late-stage schistosomiasis. Gastrointestinal haemorrhage from oesophageal varices carries a slightly better prognosis than if the underlying cause is alcoholic liver disease, because the latter is further complicated by poor synthetic function and coagulopathy, which is not a feature of schistosomiasis. (Courtesy, Dr A Bustinduy)



# Schistosoma mansoni – granuloma v jatrech

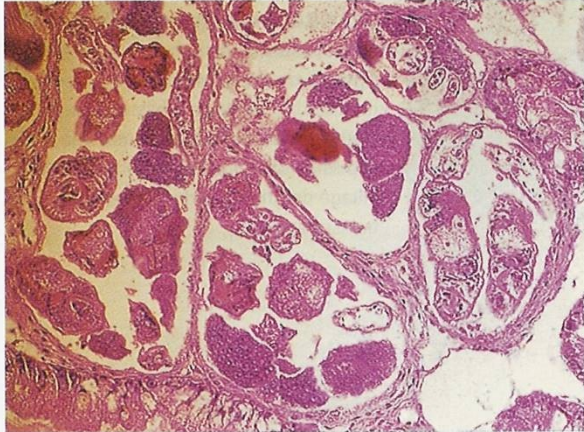


**Fig. 2.54** Egg granuloma of *Schistosoma mansoni* in the liver.

Chronic granulomatous inflammation precedes the development of liver fibrosis and portal hypertension. Here the liver shows marked expansion of two portal areas with fibrosis and numerous granulomas, consistent with Symmer's pipestem fibrosis (A). There is no evidence of cirrhosis in the remaining liver. Under high-power a granuloma surrounding a schistosome ovum with the characteristic lateral spine is clearly seen (B). (From Masia, R., Misdraji, J. Liver and bile duct infections. In: Diagnostic Pathology of Infectious Disease. 2nd edition. Pages 272-322, Fig. 11.35. Copyright © 2018 by Elsevier, Inc. All rights reserved.)

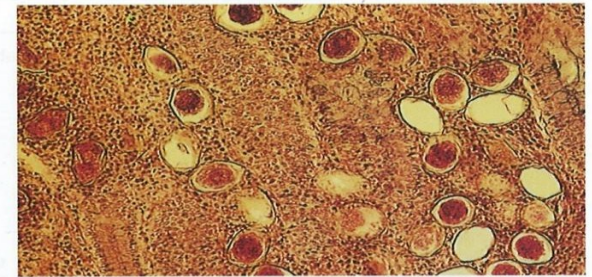


# Schistosoma – sporocysta, tlusté střevo, játra



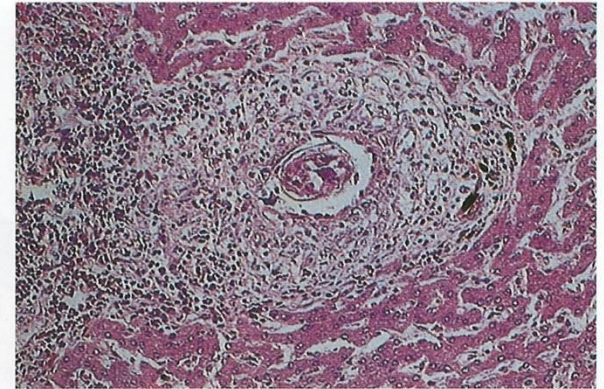
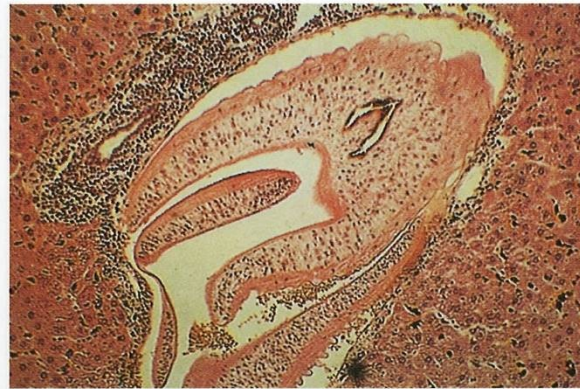**481** Section of 'mother' sporocyst in the hepatopancreas of a snail

The cycle in the snail is of variable duration, depending upon the species of parasite and host, and on the environmental conditions, but it is usually only 1 month. Cercariae develop in the second generation ('daughter') sporocysts. The figure shows several coils of the sporocyst in the hepatopancreas and sections of cercariae. (*Acetic carbol fuchsin*  $\times 130$ )



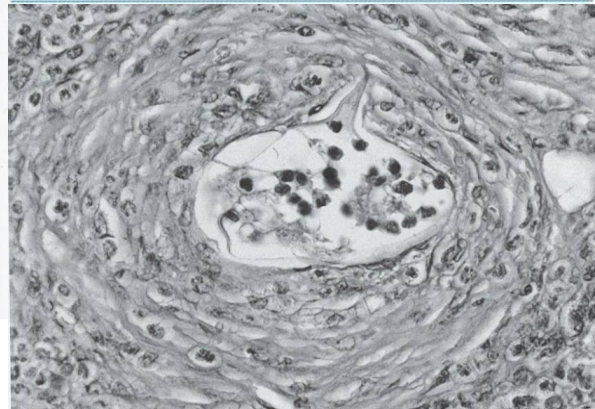
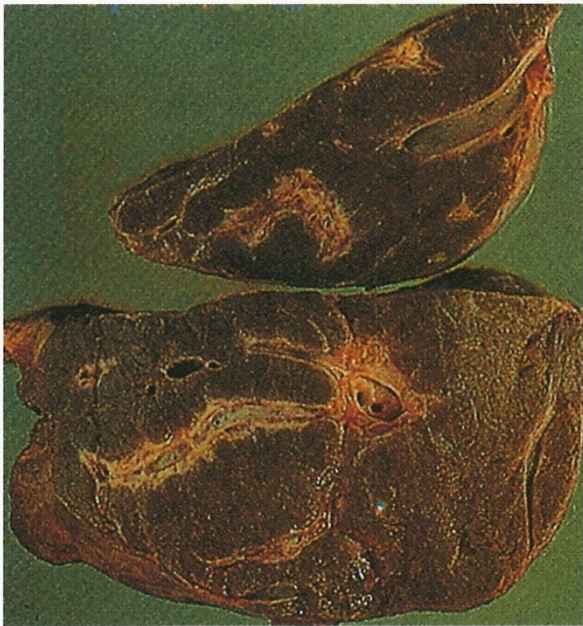**533** Eggs of *Schistosoma japonicum* in wall of colon

The adult worms do not invade the vesical plexus, but usually inhabit the mesenteric plexus. The diagnosis of *S. japonicum* can usually be made by finding typical eggs in the faeces. However, it is commoner for eggs of *S. japonicum* to be deposited in ectopic sites than those of other schistosome species. (*H&E*  $\times 150$ )



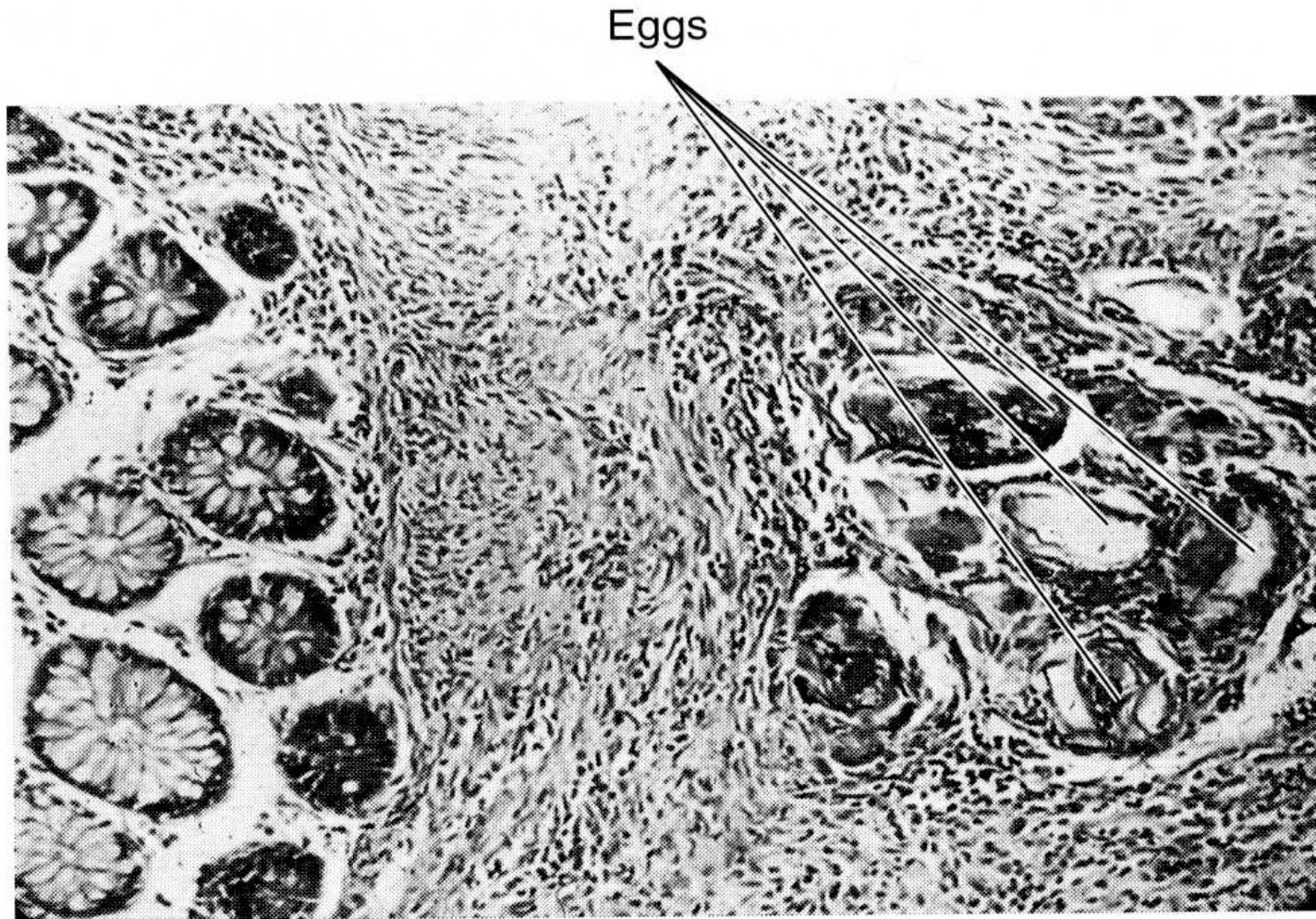
**497** Granuloma surrounding egg of *Schistosoma mansoni* in liver

Eggs (**405**) may lodge ectopically in any tissues, where they cause characteristic granulomas. It has been suggested that toxic substances associated with the ova trigger the fibrotic process. In histological sections, the ova are seen in the portal and periportal regions. All types of reaction may be present from acute eosinophilic cellular infiltration (as seen here) to the dense collagenous deposition that leads to periportal fibrosis. (See also **509**.) (*H&E*  $\times 90$ )





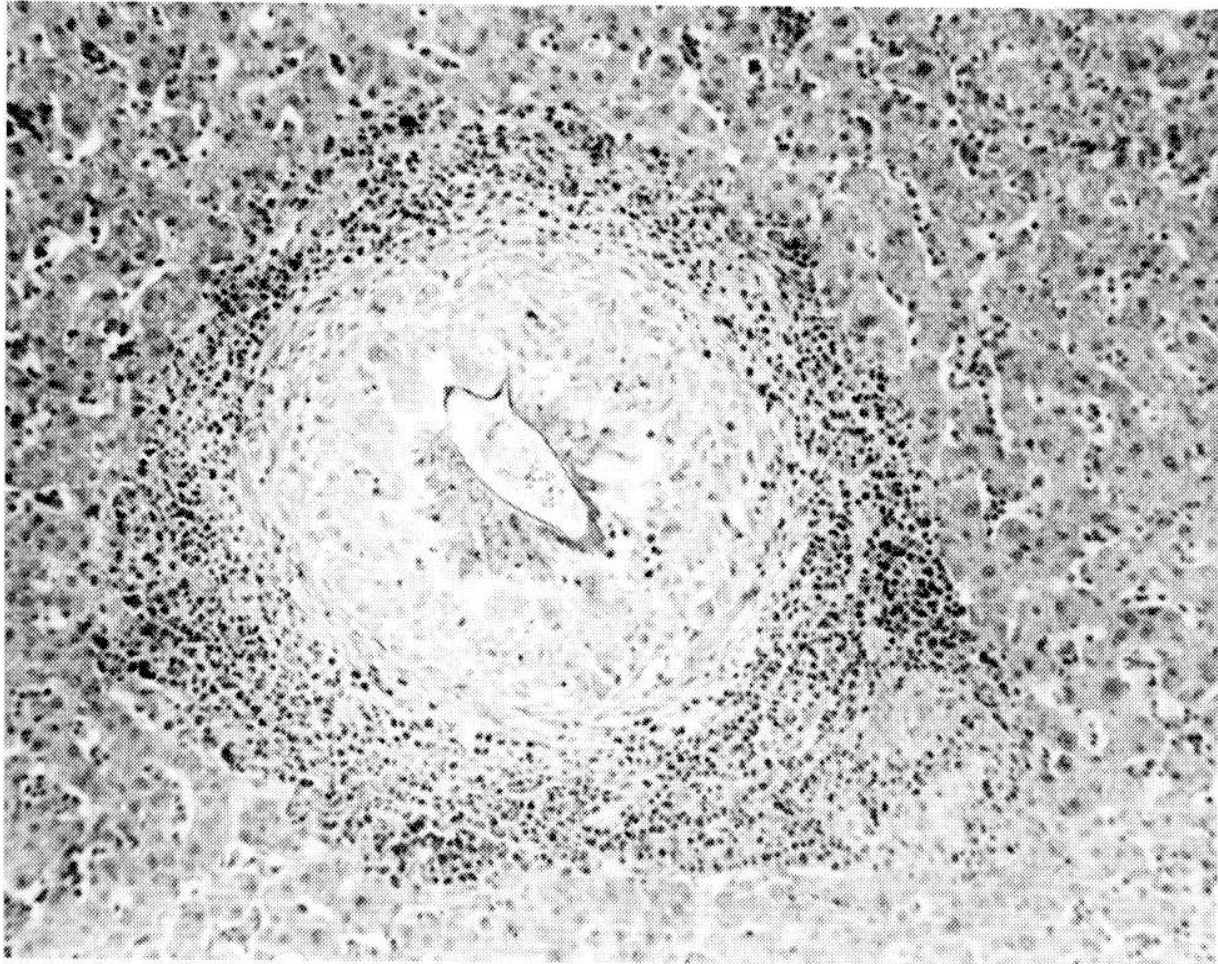
# Granulom – *S. mansoni*



**Figure 16.15** Eggs of *Schistosoma mansoni* in granuloma in intestinal wall.

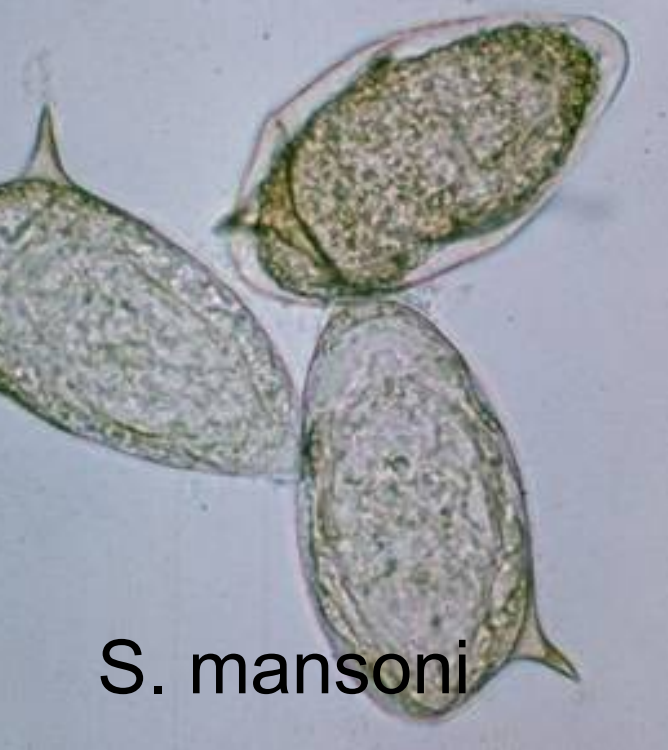

# Granulom S. mansoni

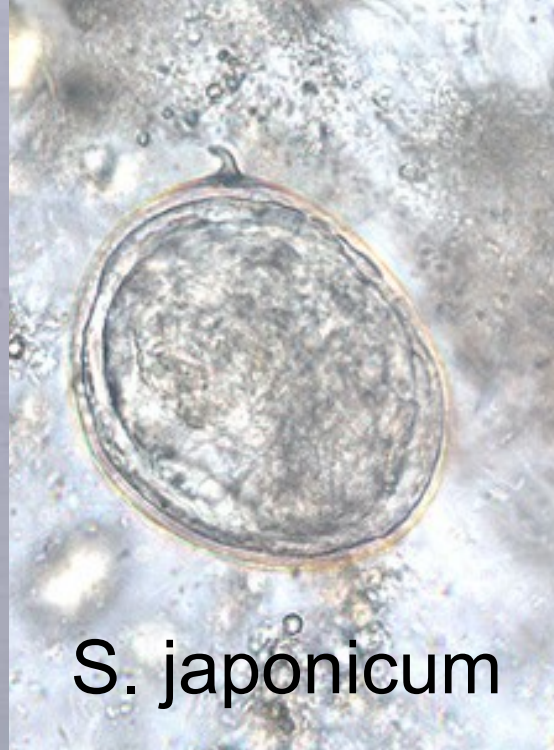

**Figure 16.16** Egg of *Schistosoma mansoni* in granuloma.

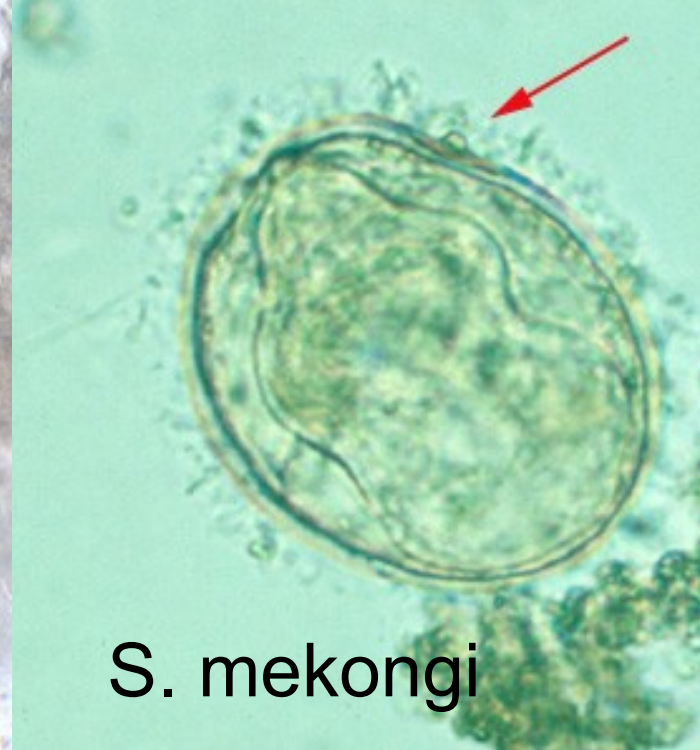Note leukocytic infiltration around the granuloma.



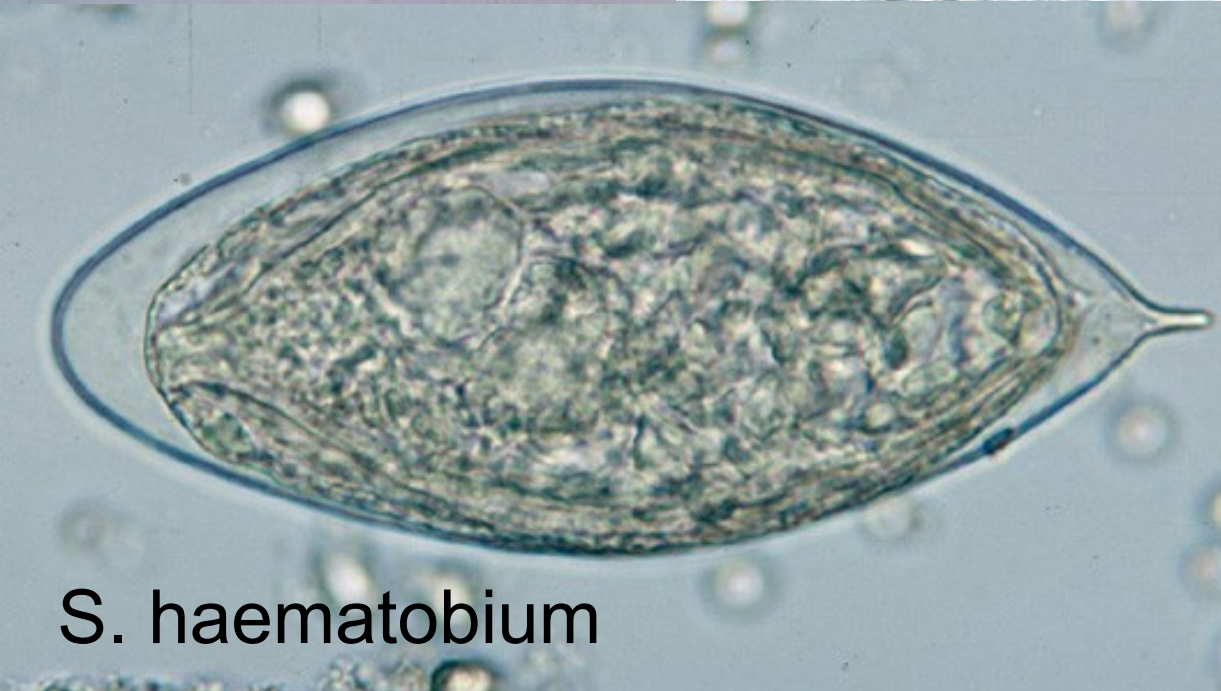*S. mansoni*



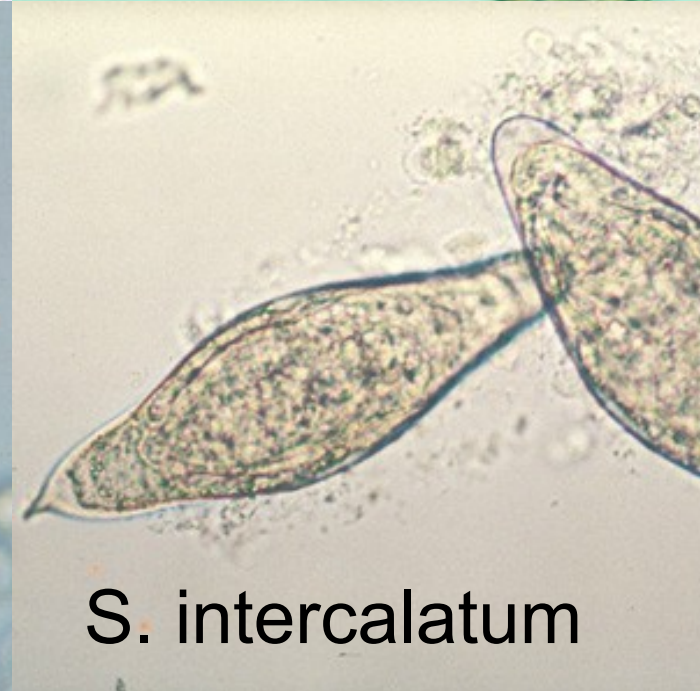
*S. japonicum*



*S. mekongi*



*S. haematobium*



*S. intercalatum*

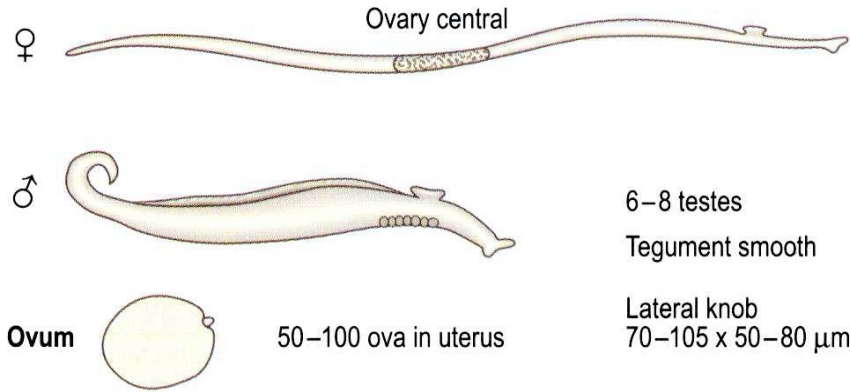
# Schistosoma japonicum

- Japonská schistosomósa
- Čína, Japonsko, Celebes
- Kapiláry mezenteria kolem střeva, především tlustého
- Hepatosplenomegalie
- Obojživelný předožádný plž Oncomelania
- Rezervoárem široké spektrum savců




# Schistosoma japonicum

*S. japonicum*

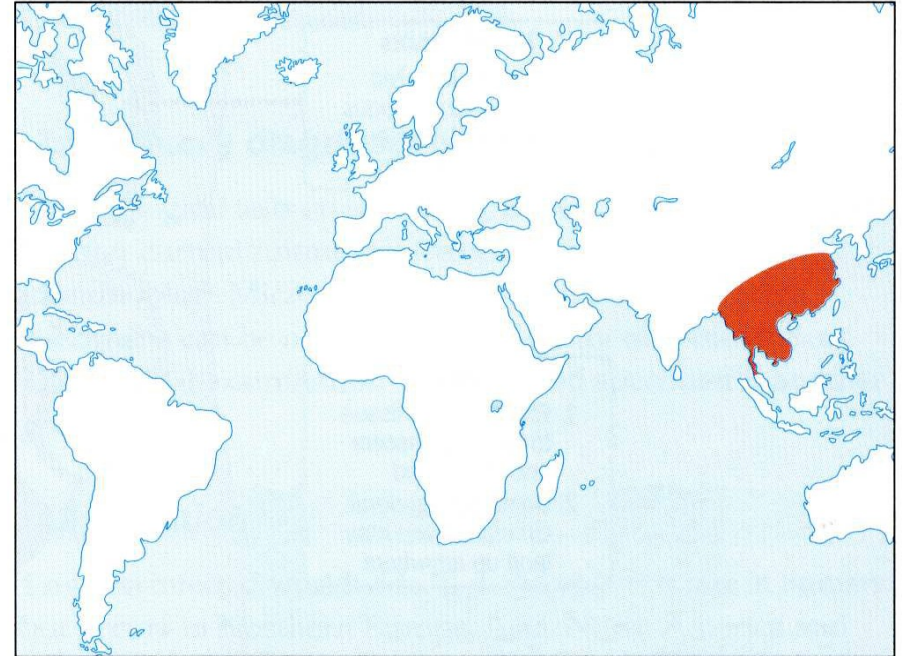


6–8 testes  
Tegument smooth  
Lateral knob  
70–105 x 50–80  $\mu$ m

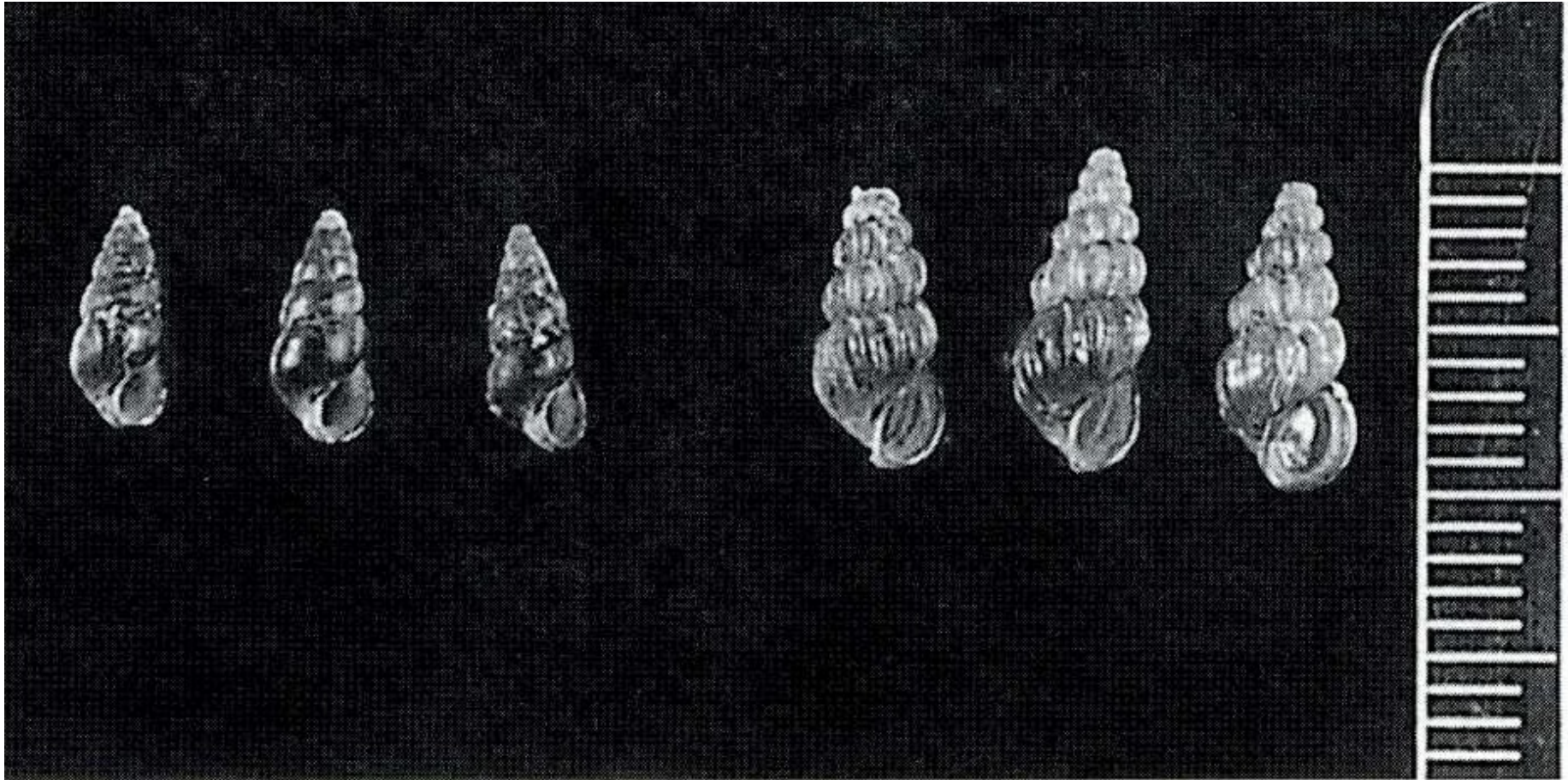Host: *Oncomelania*



*S. japonicum*: 69 million



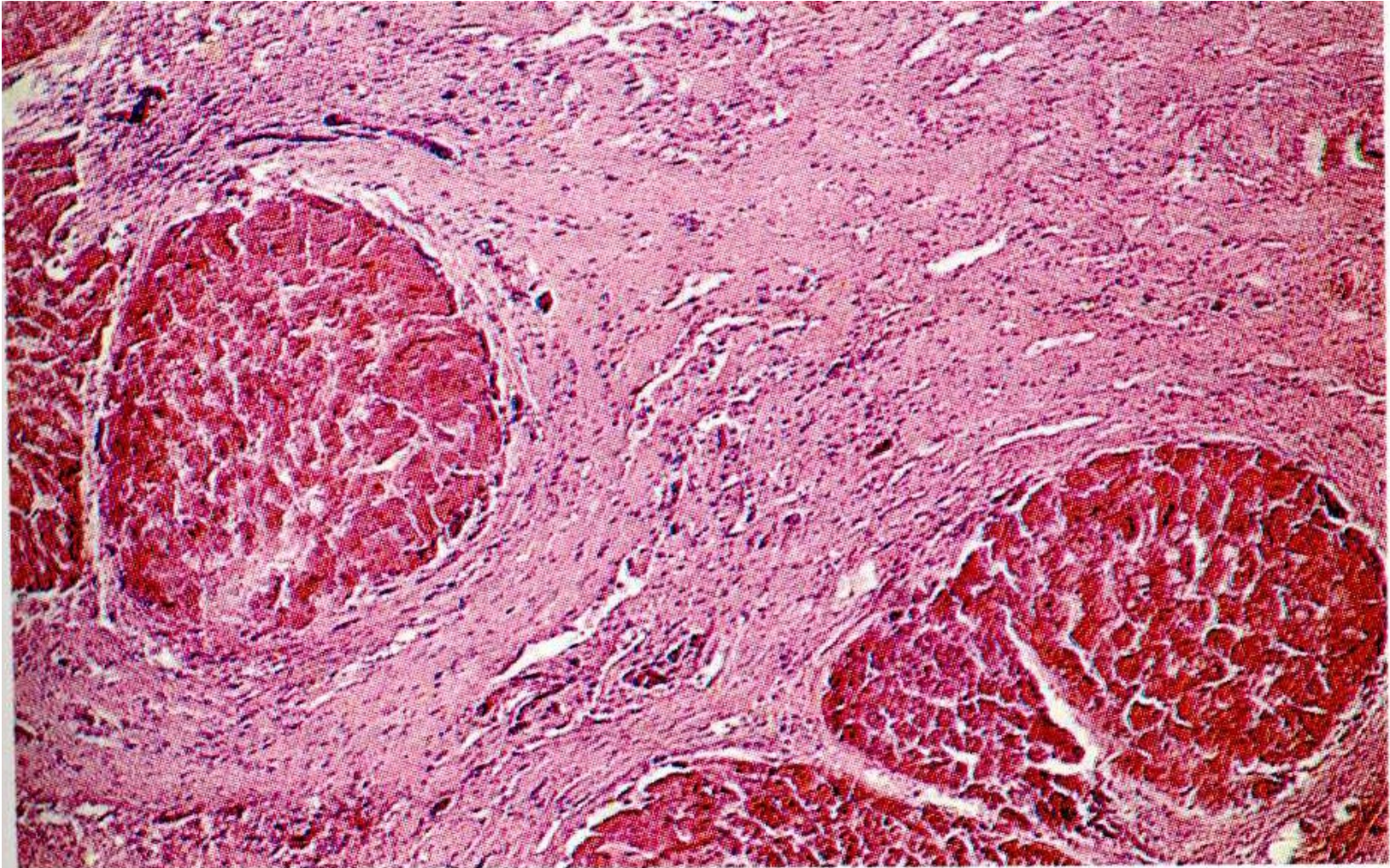
# Schistosoma japonicum



**Figure 30.2** Intermediate snail hosts of *Schistosoma japonicum*: left, *Oncomelania hupensis nosophora* collected from Yamanashi,



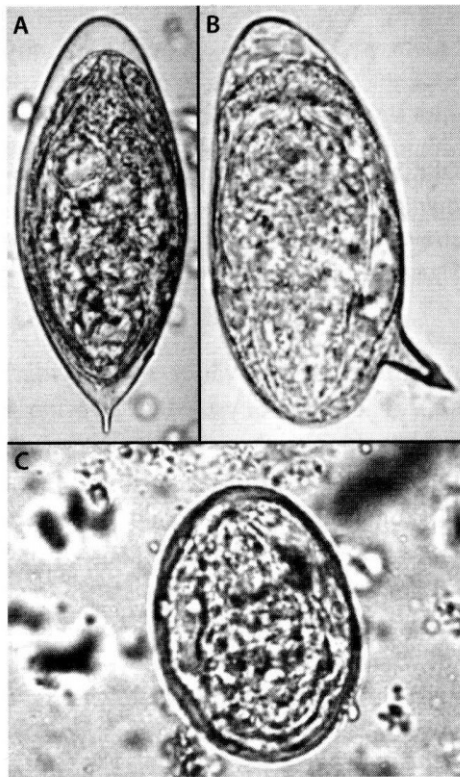
# Jaterní cirrhosa po *S. japonicum*



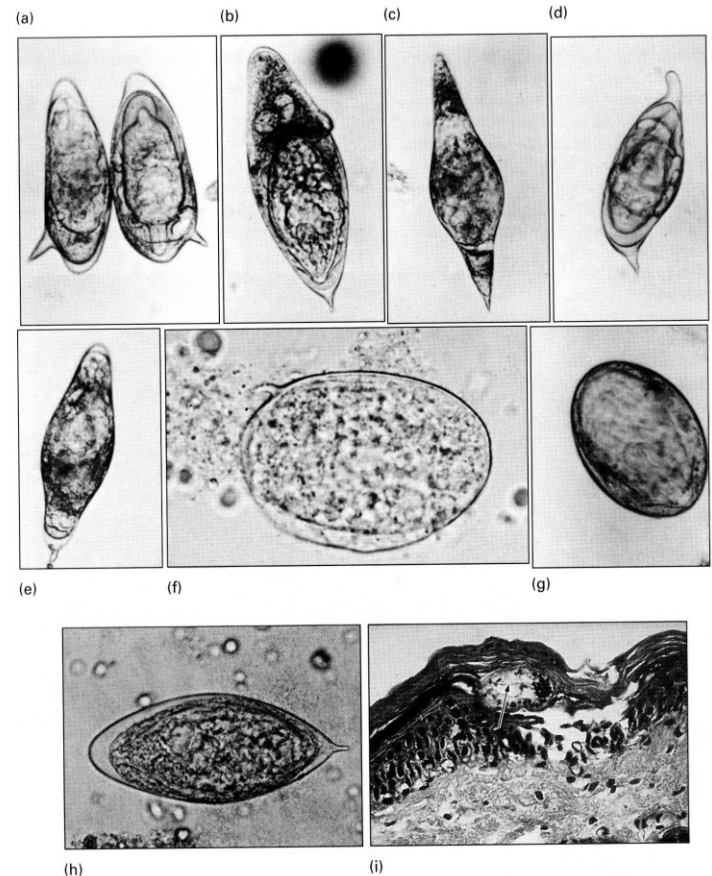
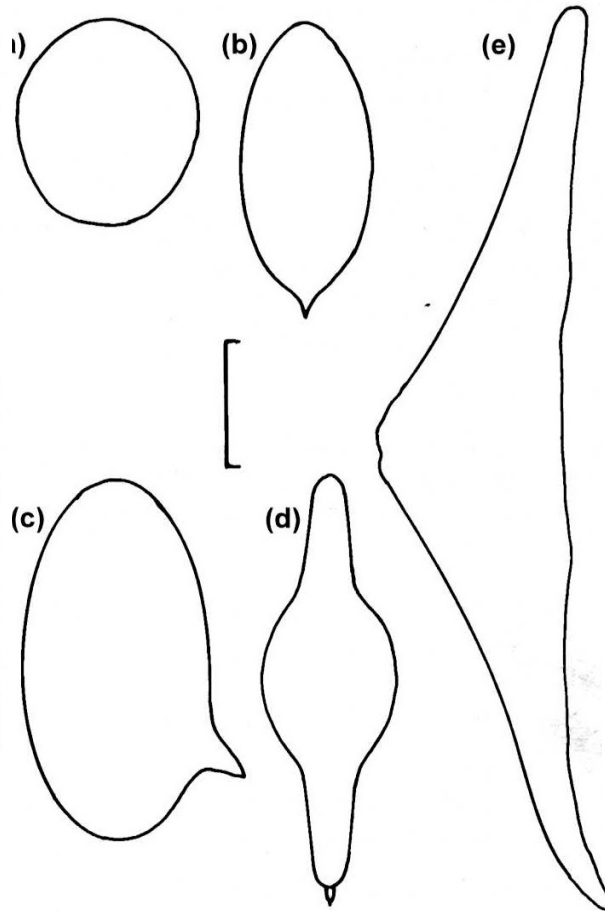
**Figure 30.5** *Liver cirrhosis due to Schistosoma japonicum*



# Srovnání vajíček schistosom



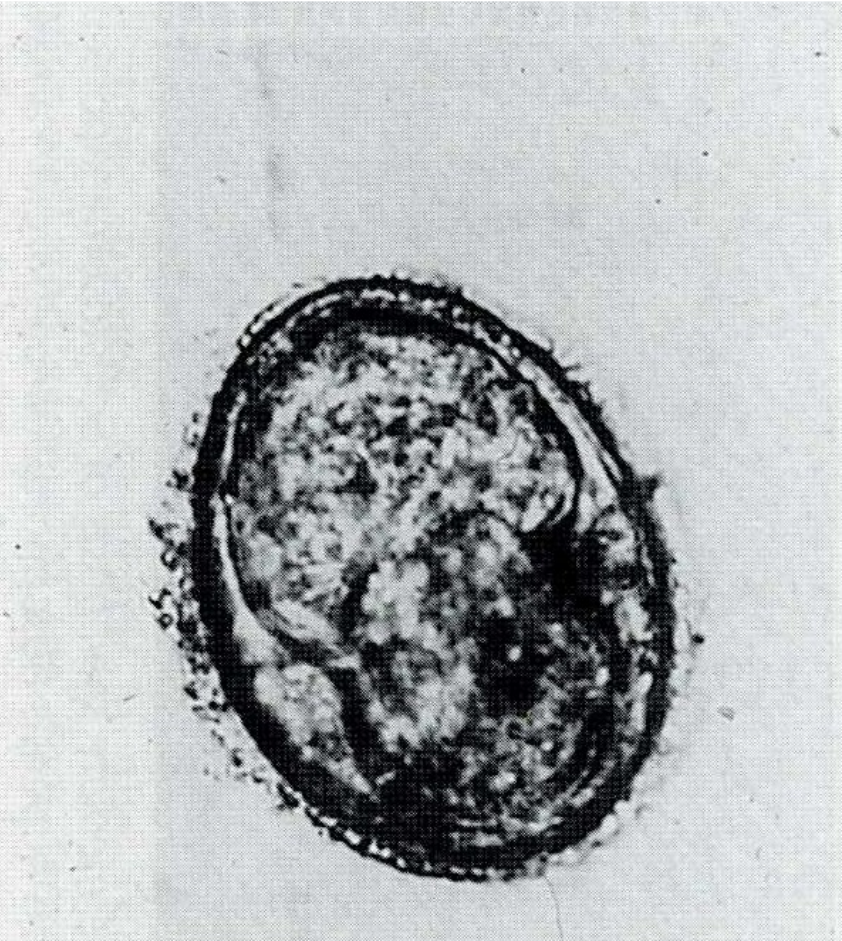
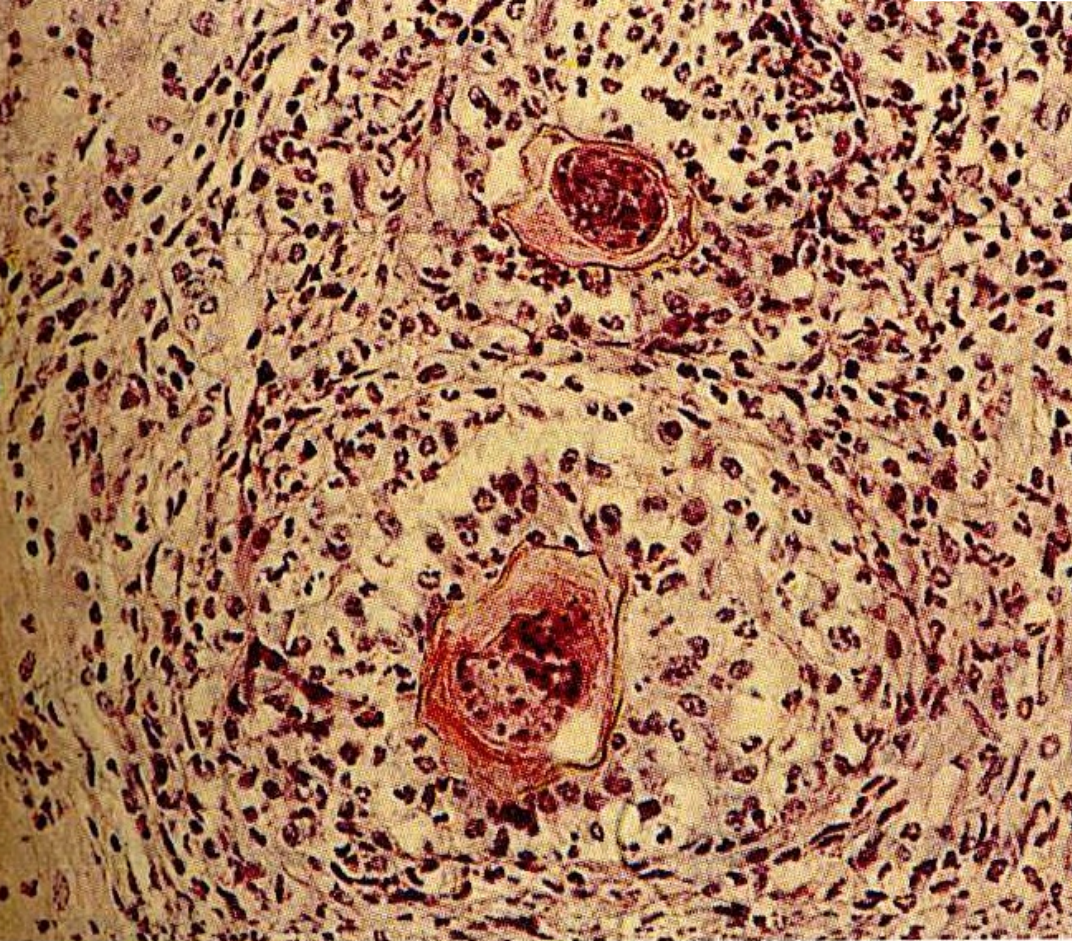
Obr. 3-15 Digenea, Schistosomatidae. Vajíčka nejběžnějších lidských schistosom. A – *S. haematobium*, B – *S. mansoni*, C – *S. japonicum* (dle různých autorů, upra-



**Figure 18.3** The eggs of *Schistosoma* spp. (a) *S. japonicum*. (b) *S. haematobium*. (c) *S. mansoni*. (d) *S. bovi* (e) *S. spindale*. Scale bar: 50  $\mu$ m. Source: reproduced from Sambon, 1909.


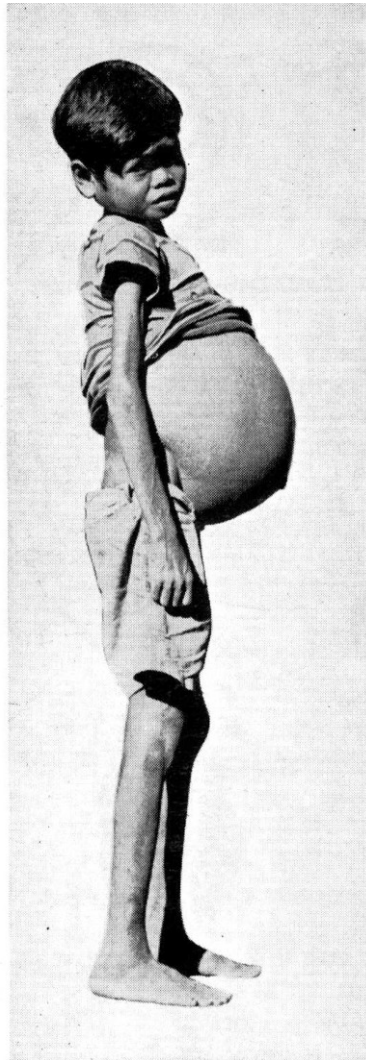


# Granulom kolem nakladených vajíček





# Pokročilá schistosomiasa japonica



**Figure 16.17** Ascites in advanced schistosomiasis japonica, Leyte, Philippines (*right*).



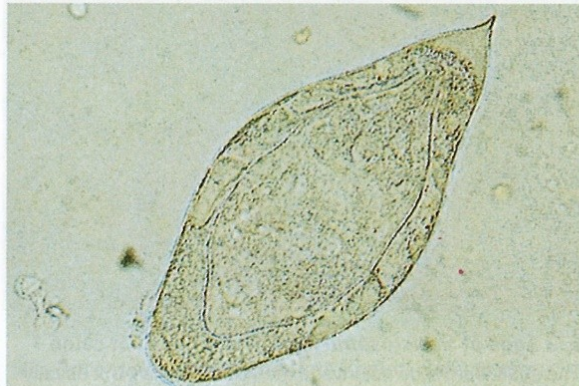# Schistosoma - zástupci

- **Schistosoma intercalatum** – člověk, západní a střední Afrika
- **Schistosoma mekongi** – člověk, jihovýchodní Asie
- **Schistosoma bovis** – dobytek, ovce, Afrika, Střední Východ, jižní Evropa
- **Schistosoma matthei** – ovce, jižní Afrika
- **Schistosoma margrebowiei** – antilopy, buvoli, střední Afrika

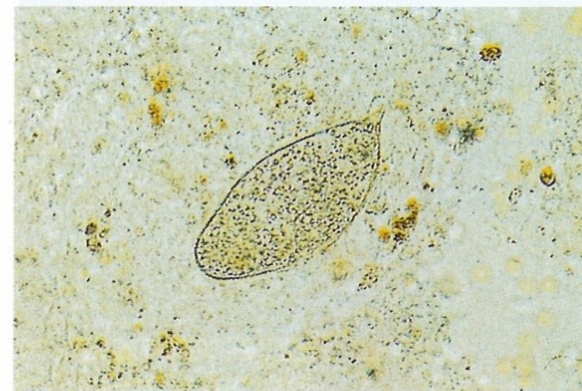
# Schistosoma intercalatum a S. mattheei

## 535-538 Eggs of unusual schistosomes seen in humans

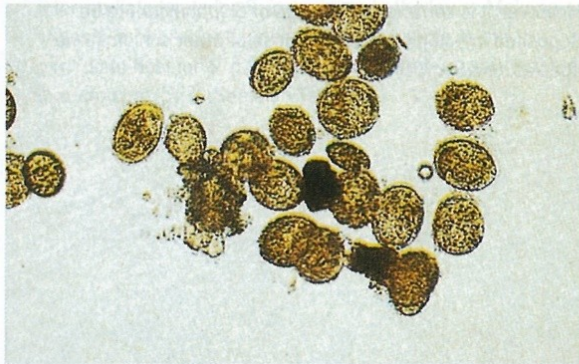The eggs of *S. intercalatum* (535) are similar to those of *S. haematobium*, but are found only in the faeces. *S. mattheei* (536), which occurs in sheep and cattle, has been found in humans on rare occasions ( $\times 290$ ). *S. mekongi* (537) is easily mistaken for *S. japonicum*, which is shown here for comparison (538). ( $\times 140$ ) (*S. intercalatum* is decreasing in prevalence; the incidence of human infection with *S. mekongi* has been considerably reduced by mass chemotherapy but its main intermediate snail host, *Neotricula aperta* is difficult to control.)



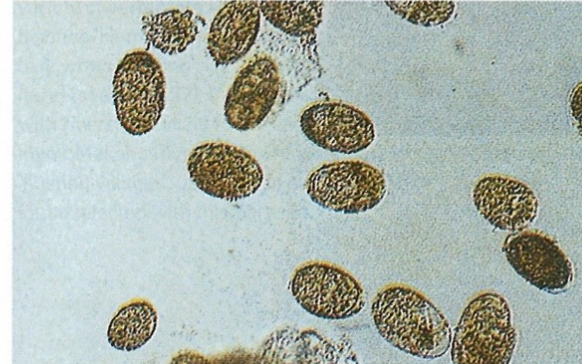
535



536

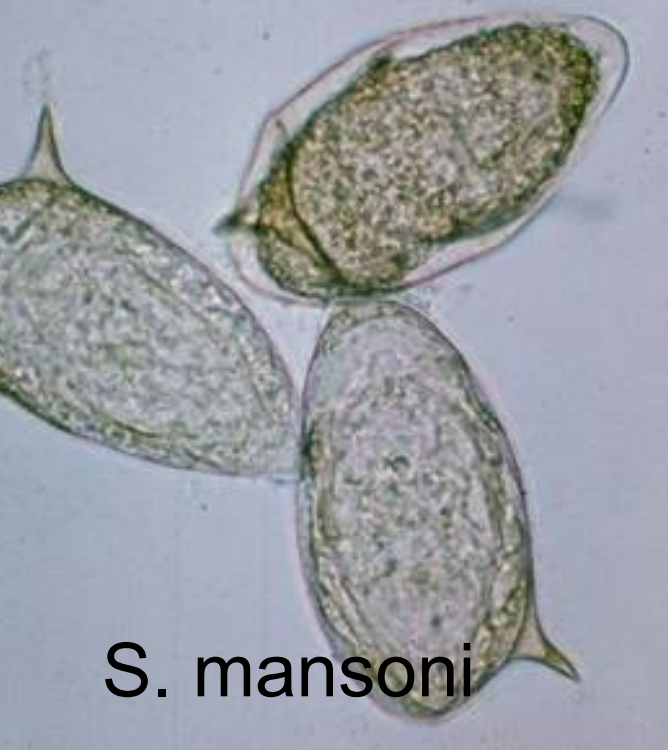

537



538

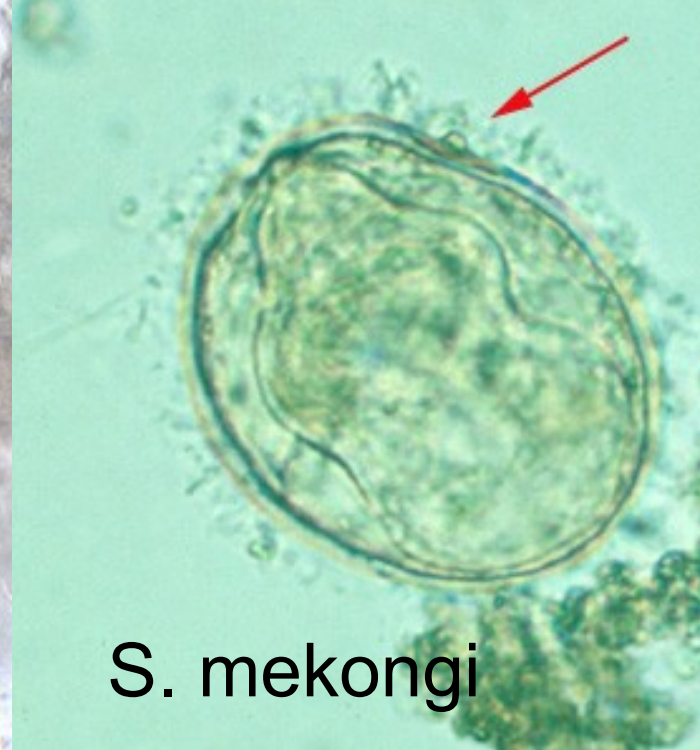




*S. mansoni*



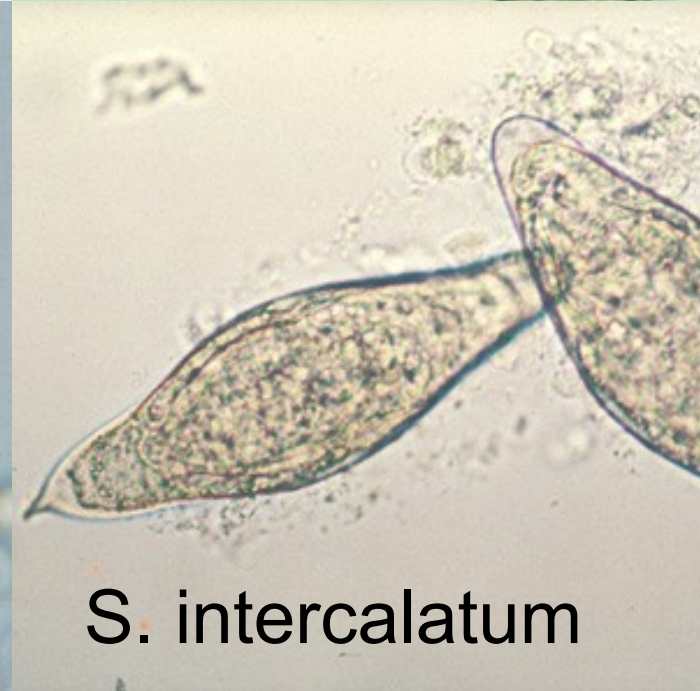
*S. japonicum*



*S. mekongi*



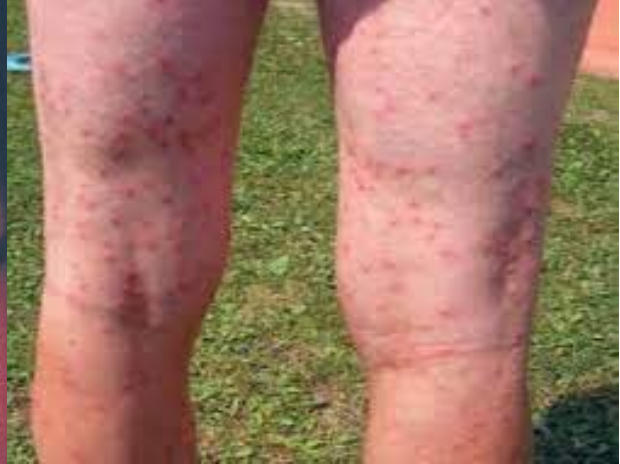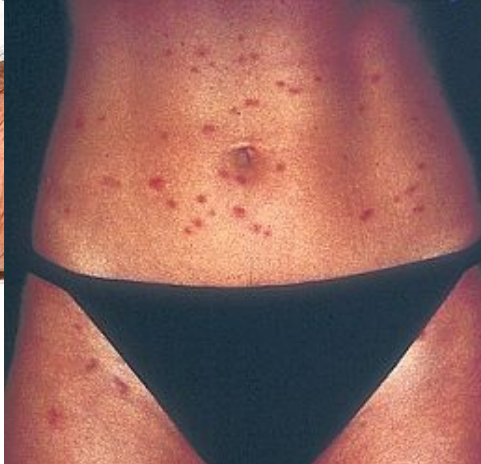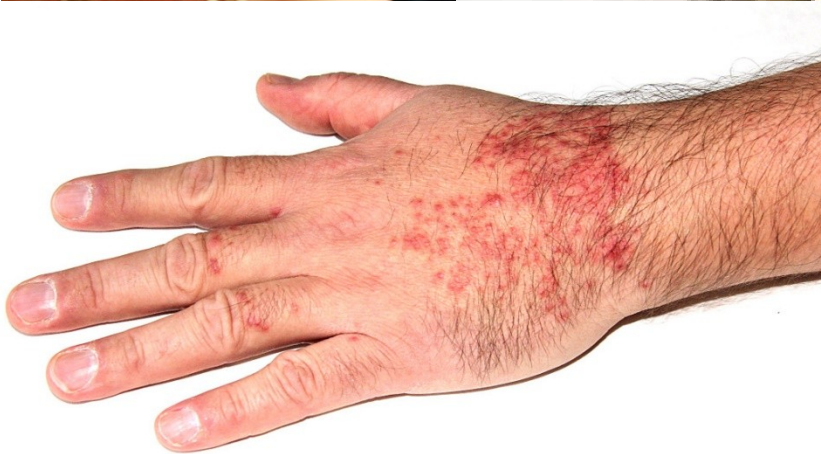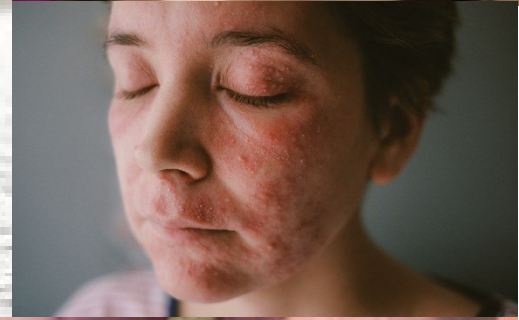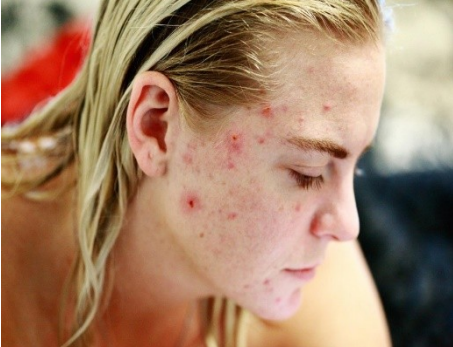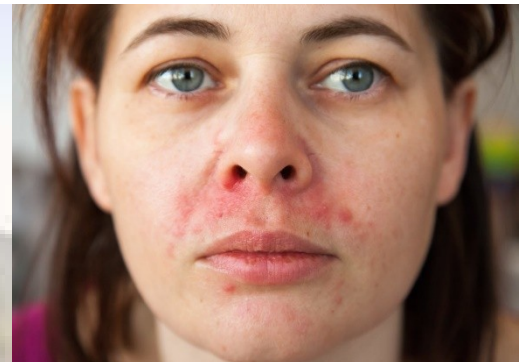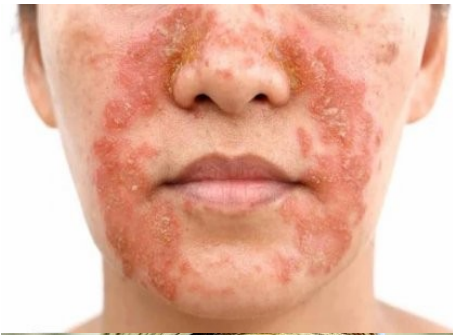*S. haematobium*




*S. intercalatum*



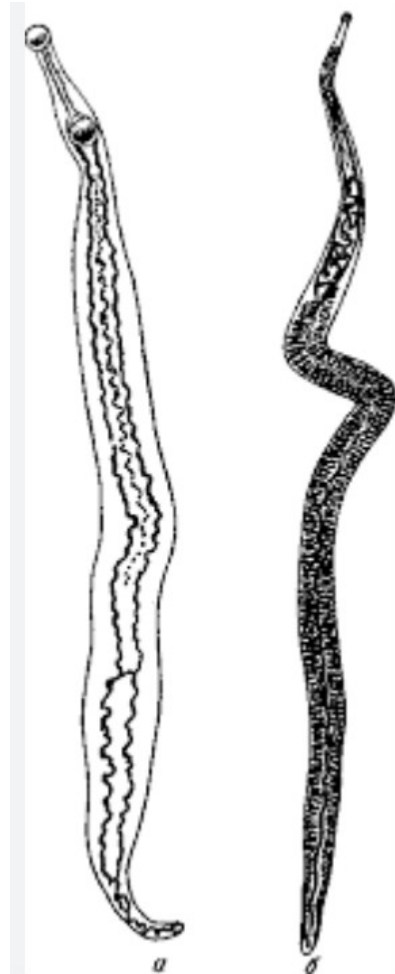
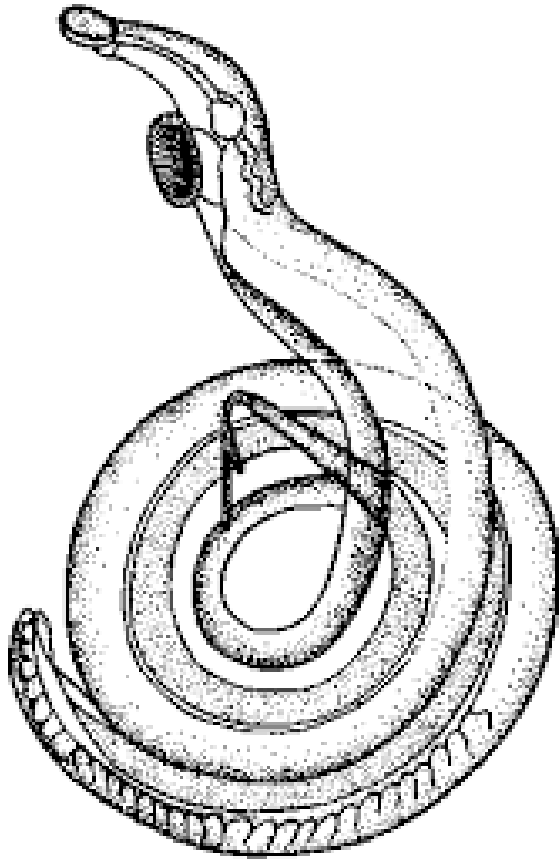
# Cerkáriová dermatidida





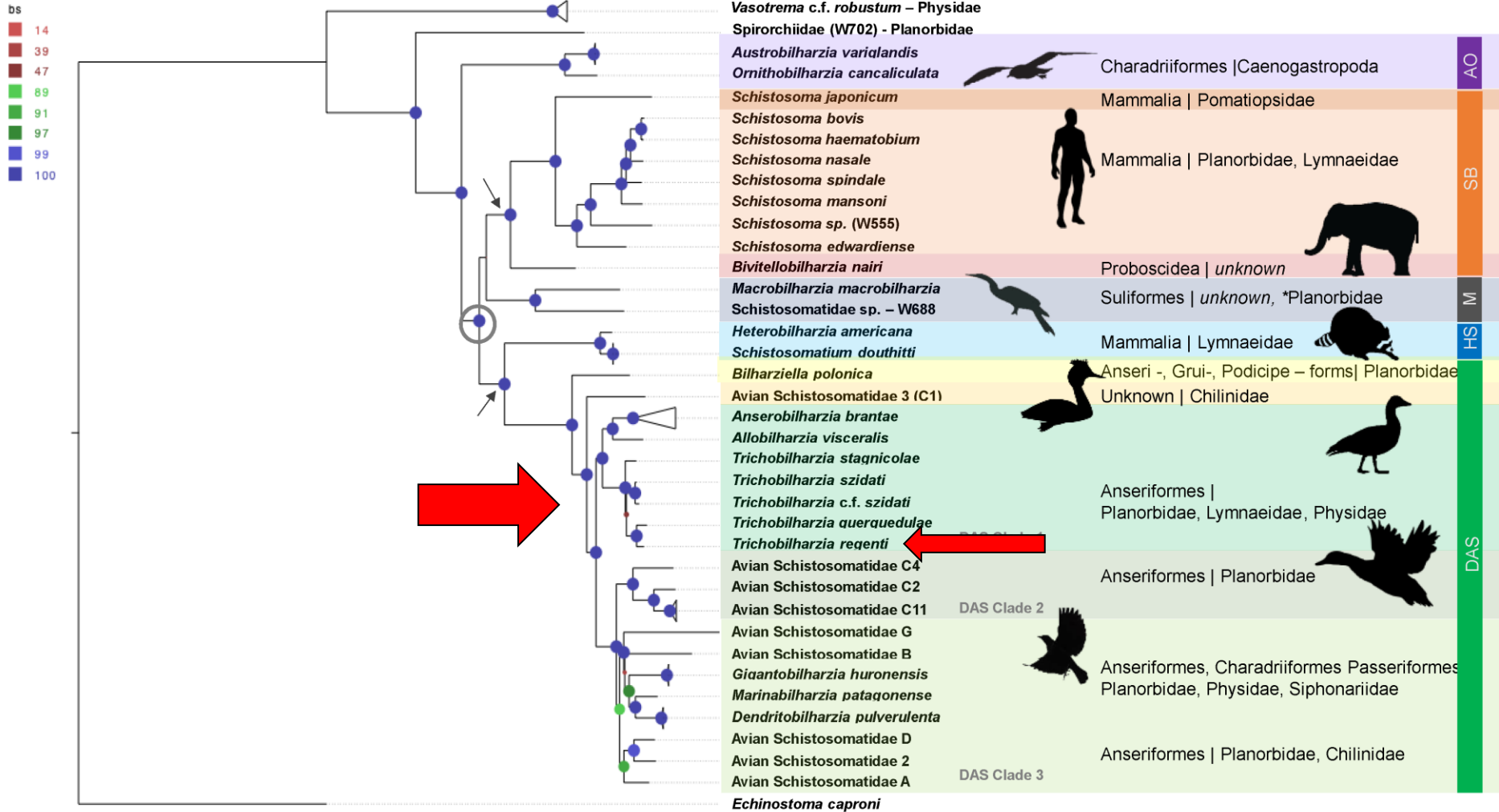
- **Cerkáriová dermatitida** vzniká jako důsledek alergické reakce pokožky na průnik cercárií schistosom vyvíjejících se běžně u ptáků a některých savců.
- Tito cizopasníci se vyvíjejí ve různých druzích sladkovodních a mořských plžů a kontaminují tak prostředí jezer, rybníků a moří.
- Cercárie se při dostávají při koupání do kontaktů s lidskou pokožkou, do které se zavrtávají a vyvolávají tak alergickou reakci.
- U většiny případů cercáriové dermatitidy není nutnou vyhledat lékaře.

# Ornithobilharzia spp.

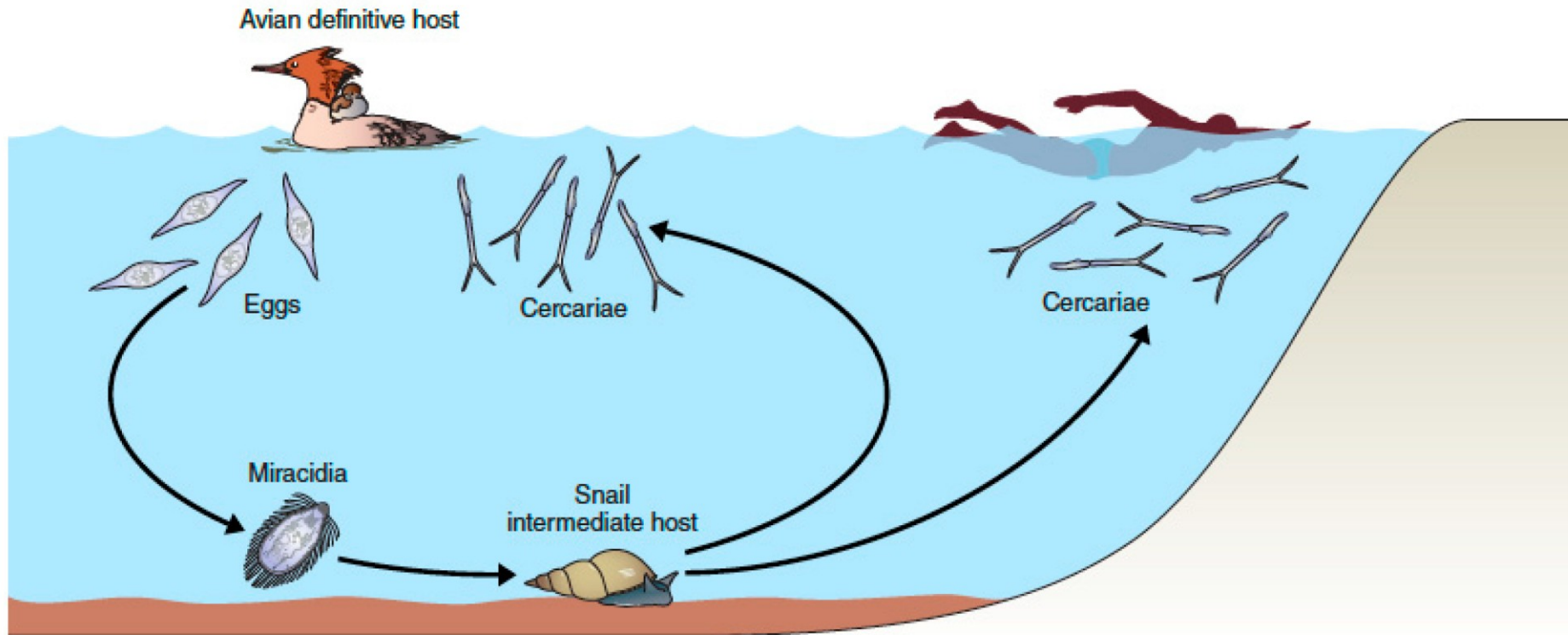




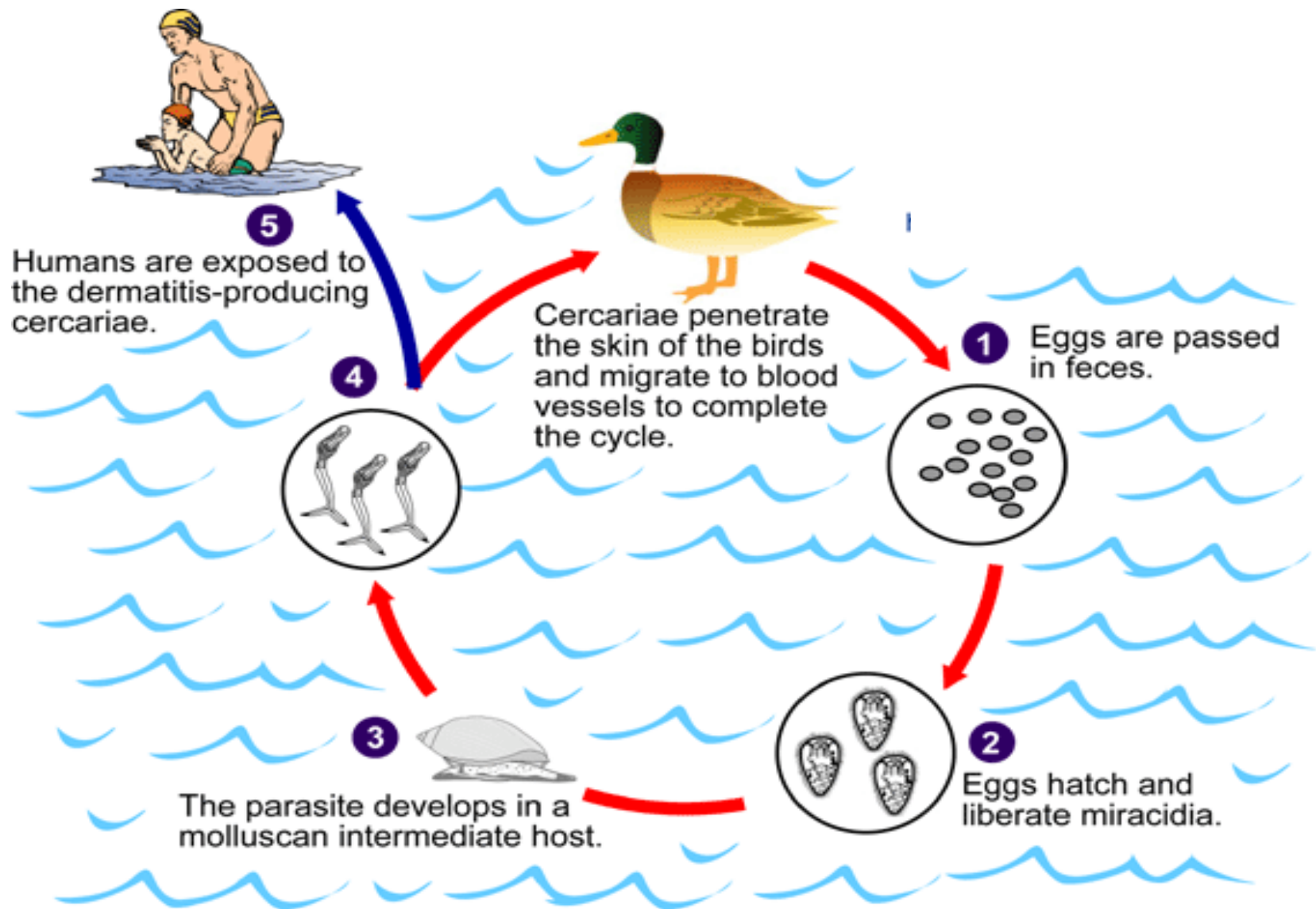
# Fylogenomika a diverzifikace Schistosomatidae



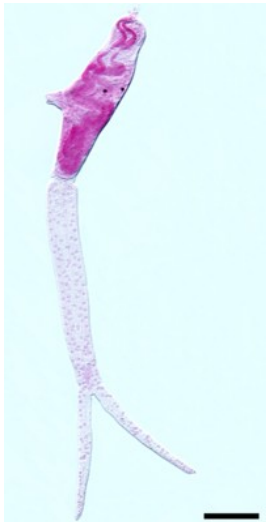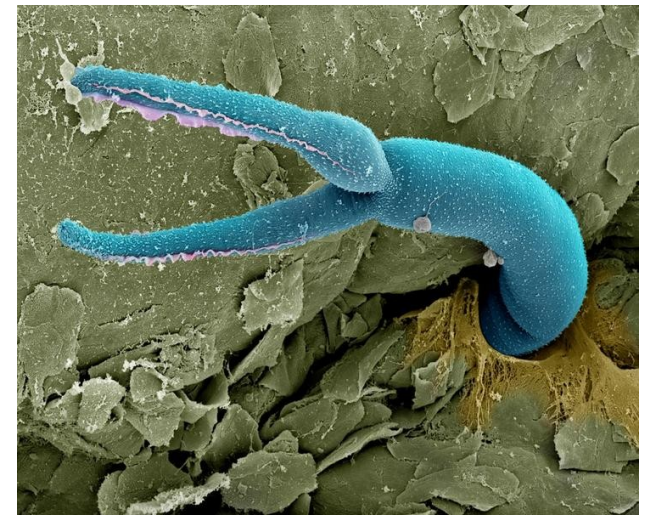
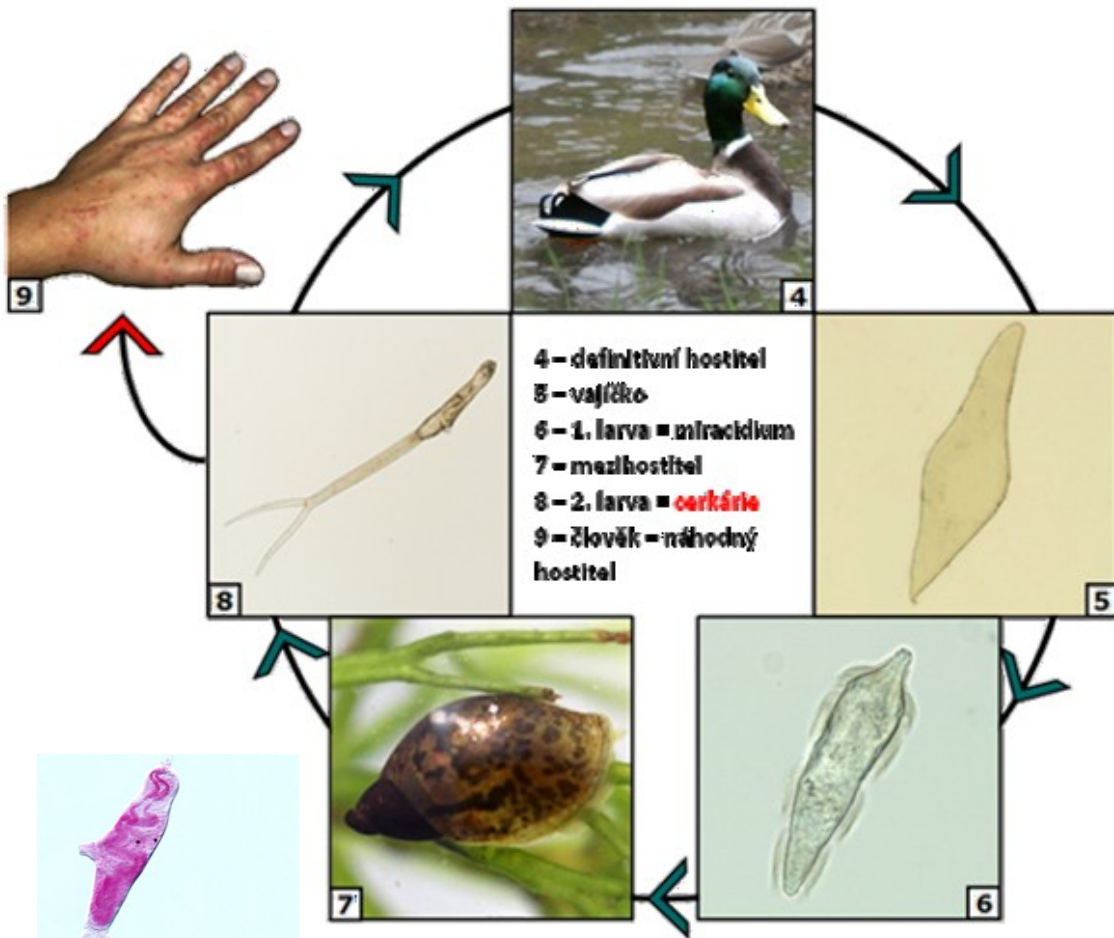
# Životní cyklus ptačích schistosom



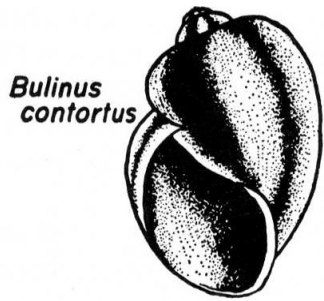
# Cerkáriová dermatitida – penetrace cerkáriemi



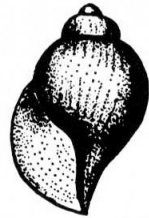



# Cerkáriová dermatitida



*Bulinus contortus*



*Physopsis africana*



*Planorbis boissyi*



*Oncomelania hupensis*



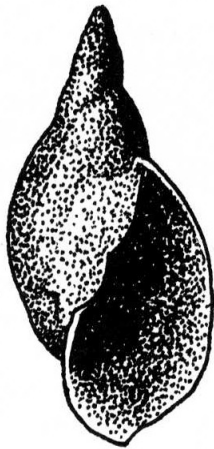
*Oncomelania nosophora*



*Parafossarulus striatulus*



*Bithynia fuchsiana*



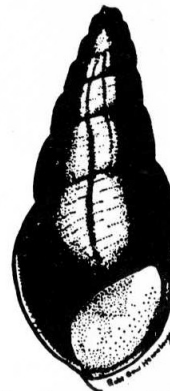*Lymnaea stagnalis*



*Segmentina schmackeri*



*Gyraulus prashadi*



*Brotia libertina*



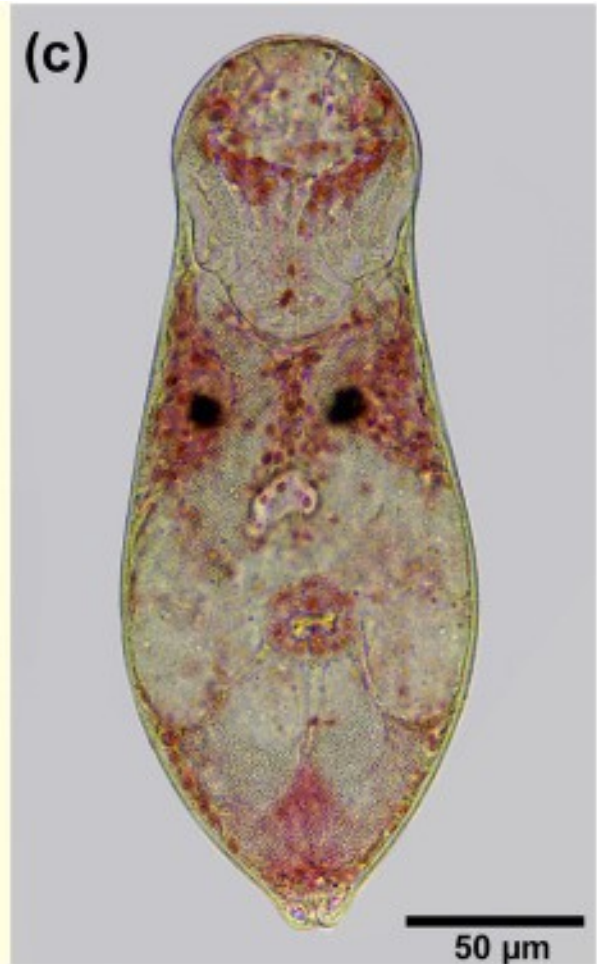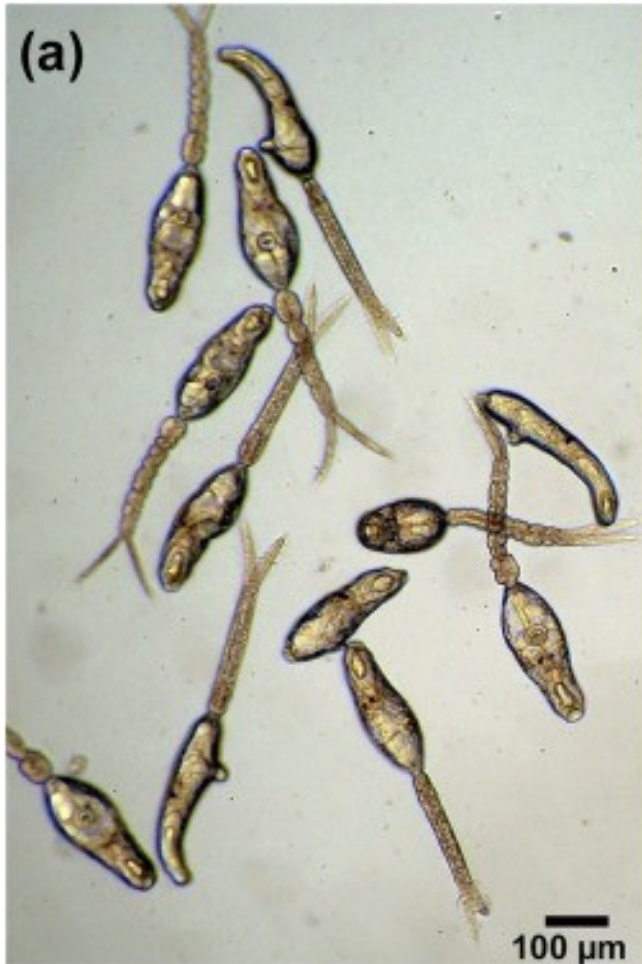Fig. 2.48 *Bulinus* sp.  
The snail intermediate host of *Schistosoma haematobium*. (Courtesy, C. Whitehorn.)




Fig. 2.49 *Oncomelania* sp.  
The snail intermediate host of *Schistosoma japonicum*. (Courtesy, C. Whitehorn.)

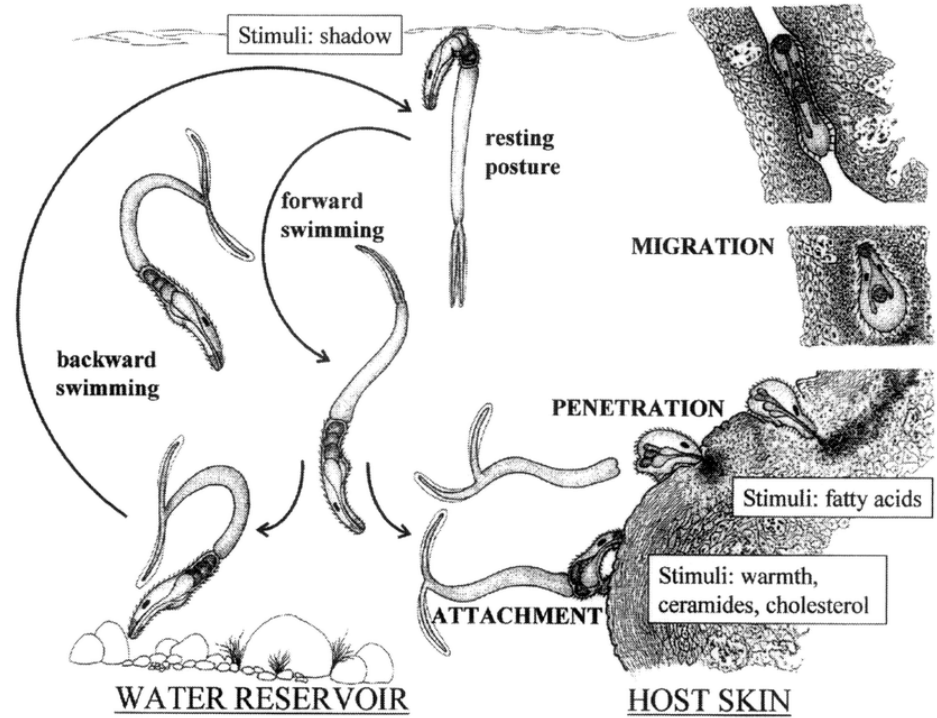
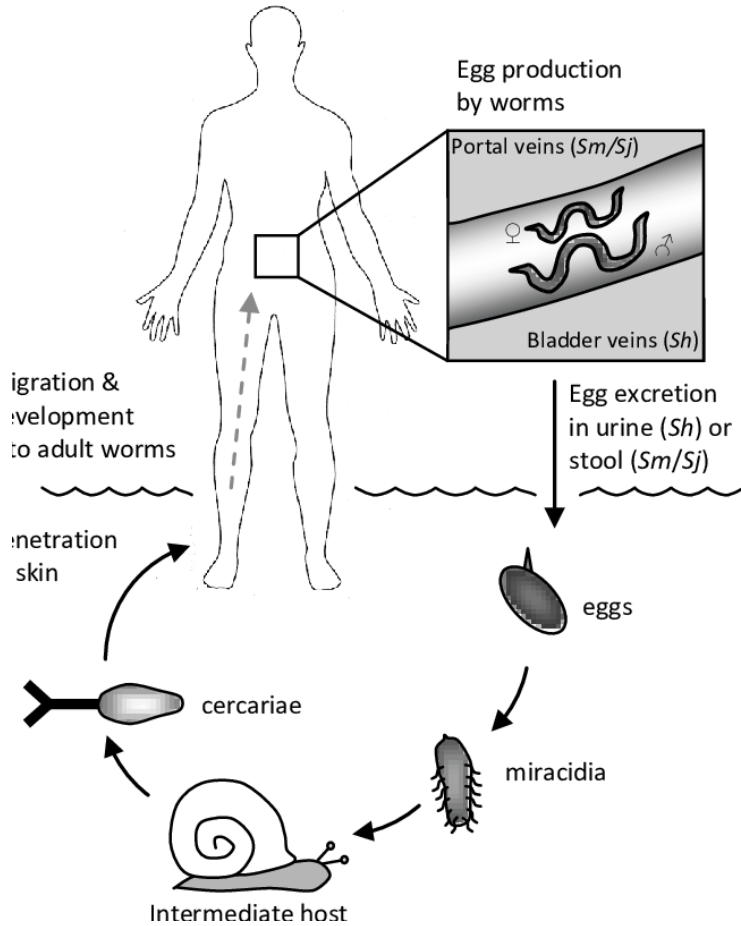


# Cerkariová dermatitida





# Skin penetrance



# Co je třeba dělat pro omezení cerkáriové dermatitidy ?

- Neplavat a nekoupat se v místech, kde je vysoká pravděpodobnost vzniku CD.
- Neplavat v blízkosti zarostlých vodních ploch, kde se obvykle vyskytuje velké množství plžů
- Okamžitě po vystoupení z vody je nutno se utřít ručníkem.
- Nelákejte a nekrmte ptáky v blízkosti vodních nádrží, kde se lidé koupou.
- Oznamte na patřičných místech, kde je CD problém, aby tyto oblasti mohly být patřičně označeny.

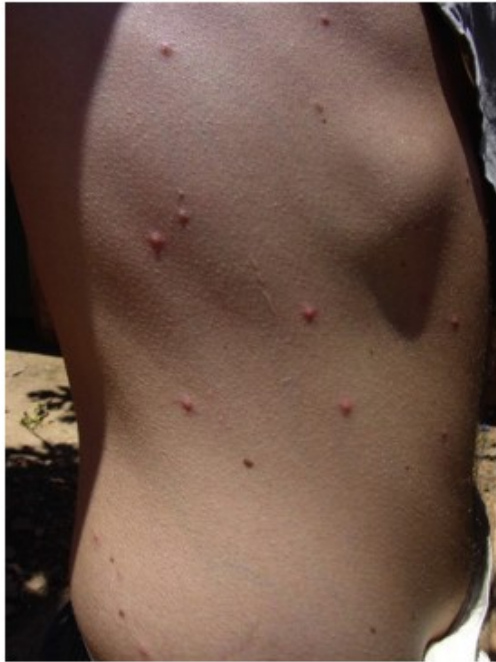# Jaké jsou příznaky cerkariové dermatitidy ?

Symptomy:

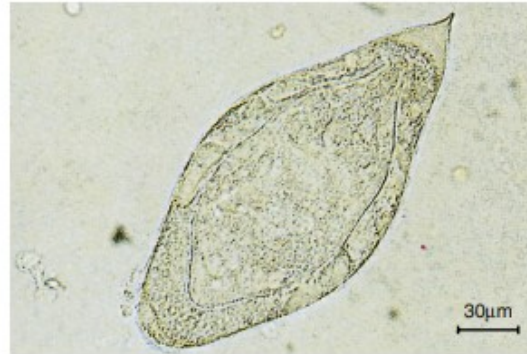- Zarudnutí, pálení a svědění pokožky
- Malé zarudlé pupínky
- Drobné puchýřky



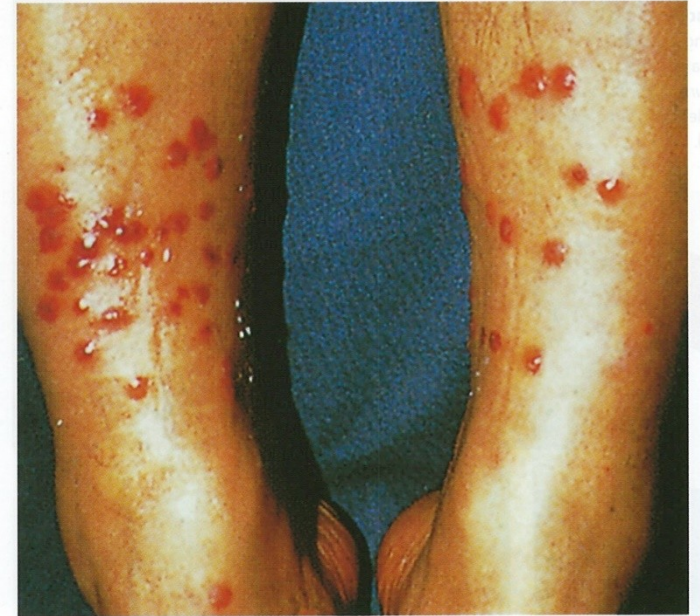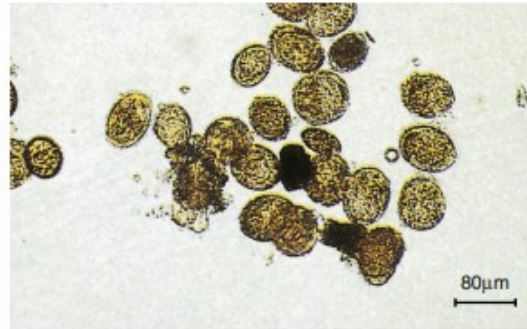
# Schistosoma – cercáriová dermatitida



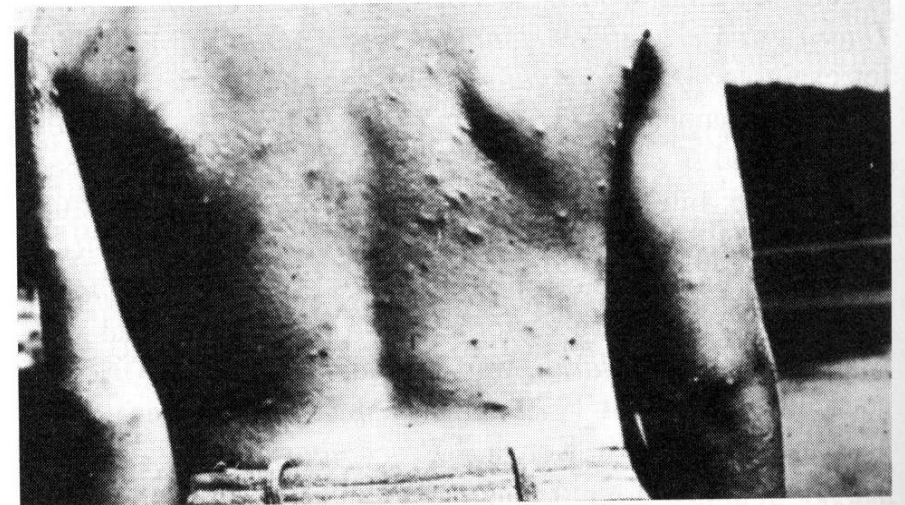
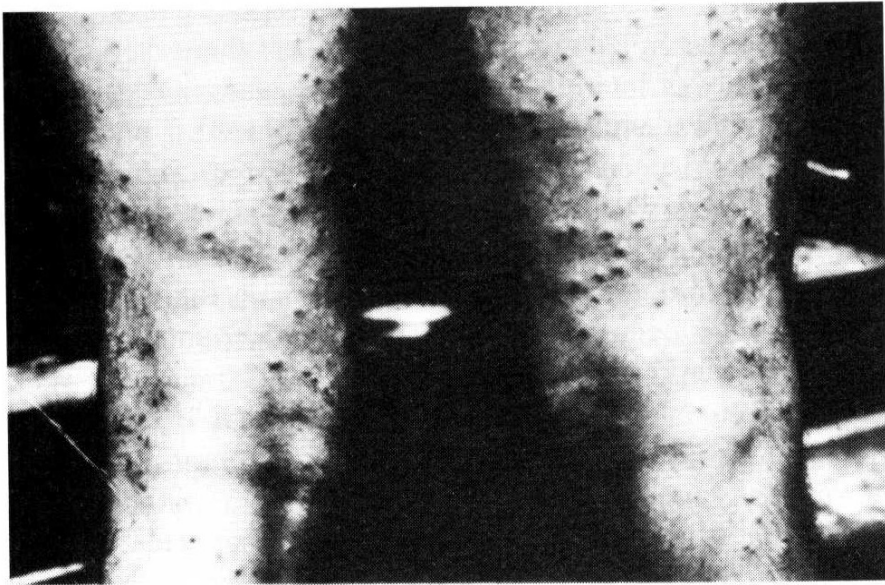
**Fig. 2.67** Cercarial dermatitis 3 days after exposure. Though 'swimmer's itch' usually describes the cercarial dermatitis caused by human pathogenic schistosomes, as here, cercarial dermatitis can occur in countries non-endemic for human schistosomiasis, following exposure to avian schistosomes. (From Pavlin,



**Fig. 2.68**



# Trichobilharzia, Ornithobilharzia



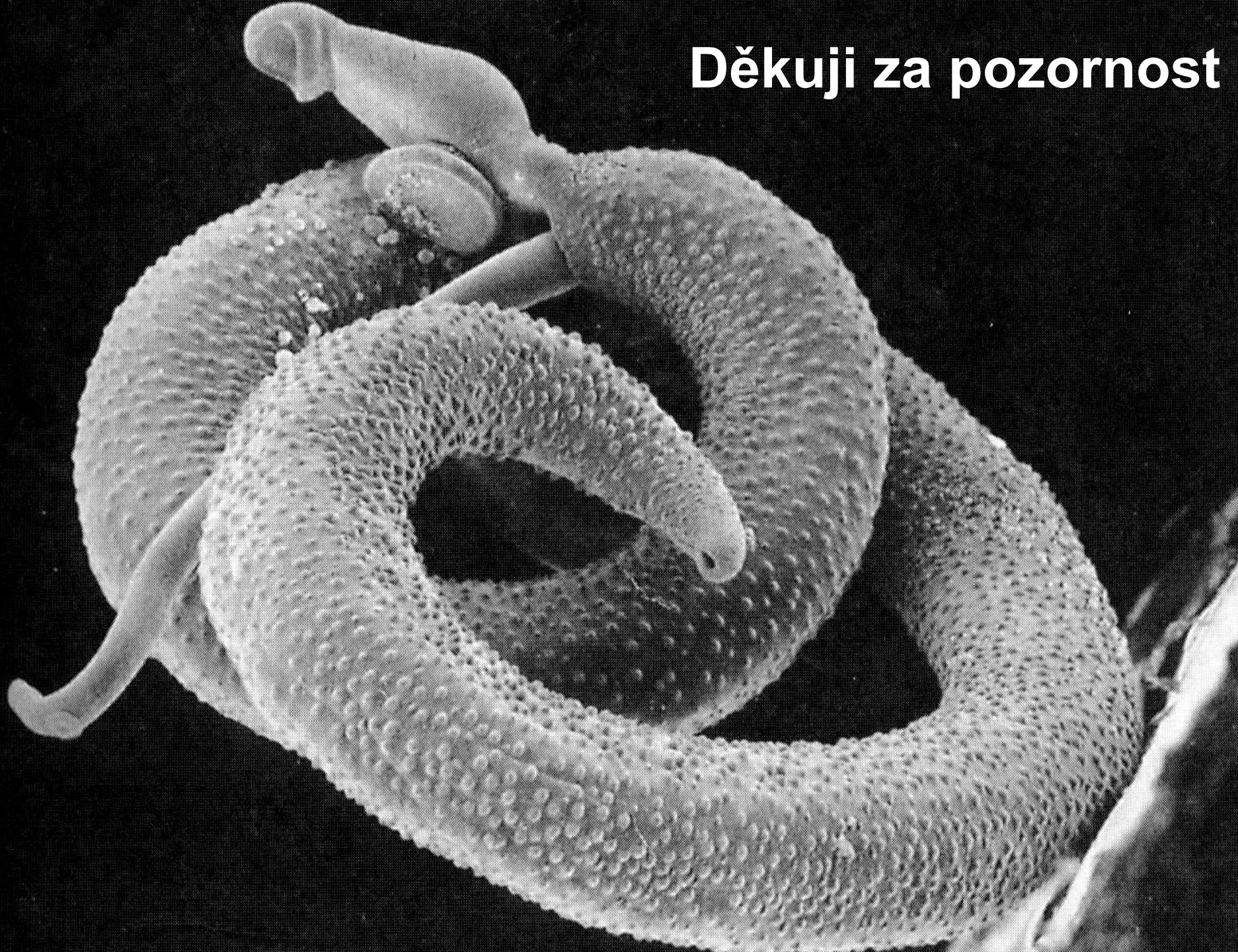**Figure 16.19** Cercarial dermatitis, or “swimmer’s itch,” caused by cercariae of avian blood flukes.

# Cerkariová dermatitida

- Cerkariová dermatitida je působena cercáriemi běžných druhů motolic parazitujících obvykle u ptáků a některých savců.
- Cercárie těchto motolic mají chemotrofickou reakci na lidskou pokožku a aktivně se do ní zavrtávají. Tato penetrace působí lokální podráždění pokožky.
- Běžně ji působí schistosomy rodů, *Trichobilharzia* a *Ornithobilharzia* parazitující obvykle u kachen.
- Případy CD jsou známy jak se sladkovodního, tak brakického prostředí.
- Plž druhu *Nassarius obsoletus*, je mezihostitelem druhu *Austrobilharzia* které se vyvíjejí v mořském prostředí a vyskytuje se na mořských plážích mírného pásma,
- CD by neměla být zaměňována se sežehnutím mořskými medúzami.



**Děkuji za pozornost**

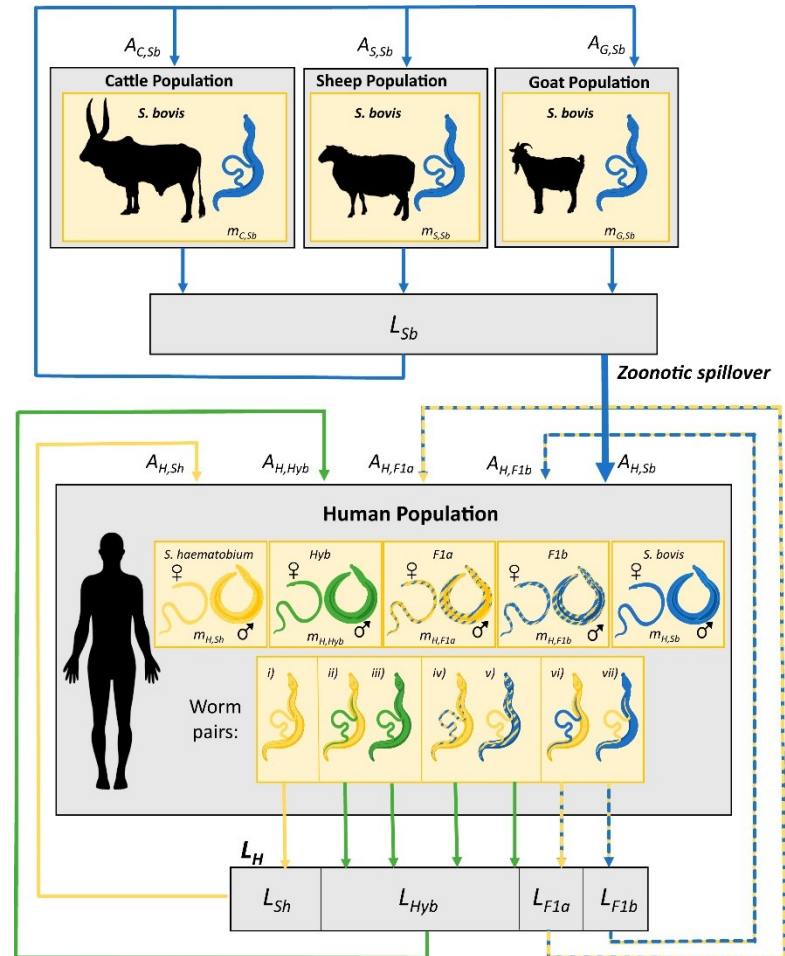
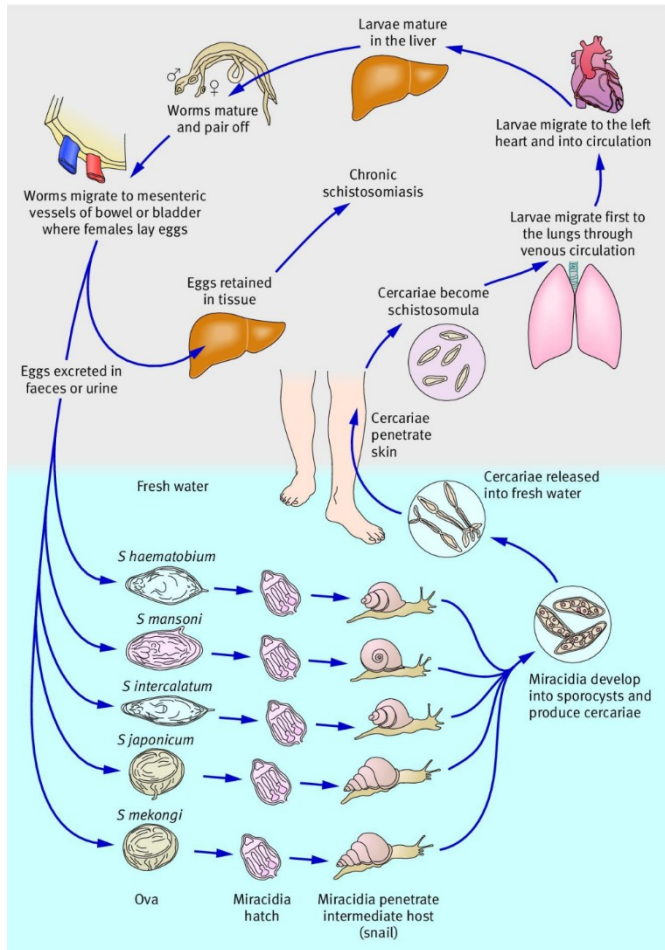








# Migrace motolic rodu Schistosoma



**Fig. 1.** Schematic of the multihost, multiparasite transmission model: *S. haematobium*, *S. bovis*, and Haematobium group hybrids in human and livestock populations. Parameter description and categorization of worm genotypes in definitive hosts are detailed in [SI Appendix, Tables S1 and S2](#).

# Cerkarie penetrují pokožku

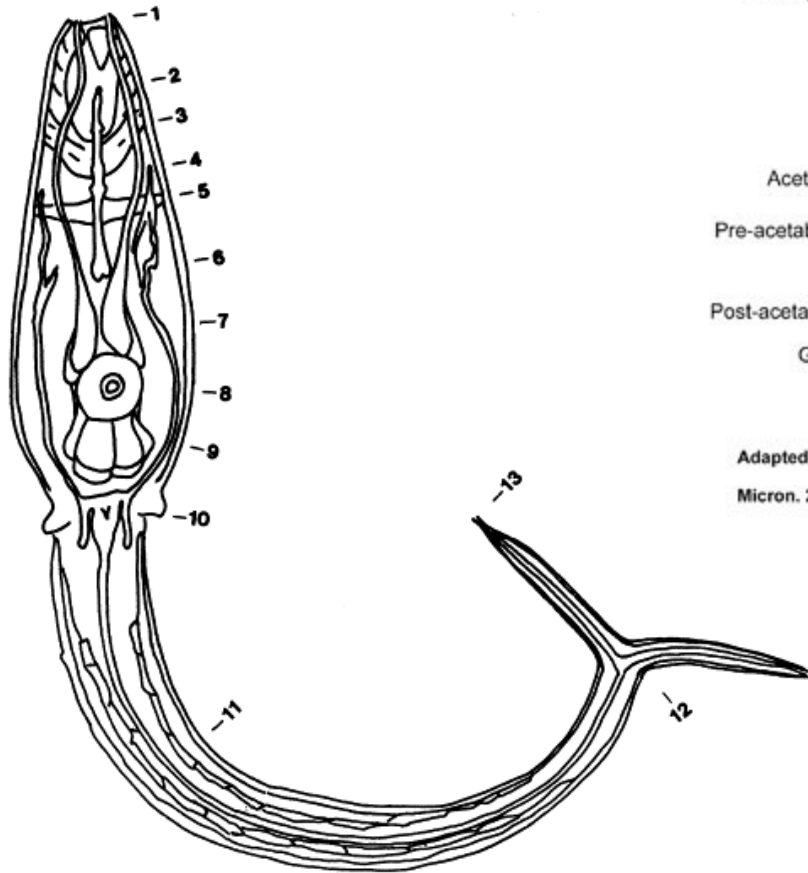
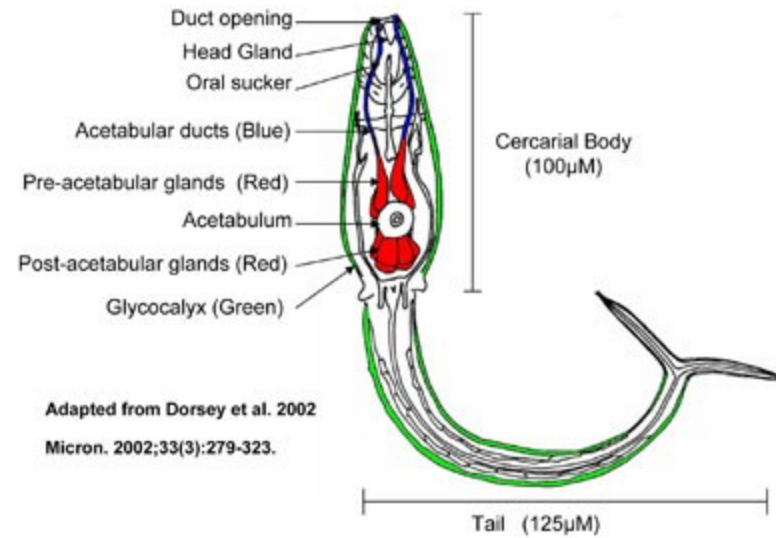
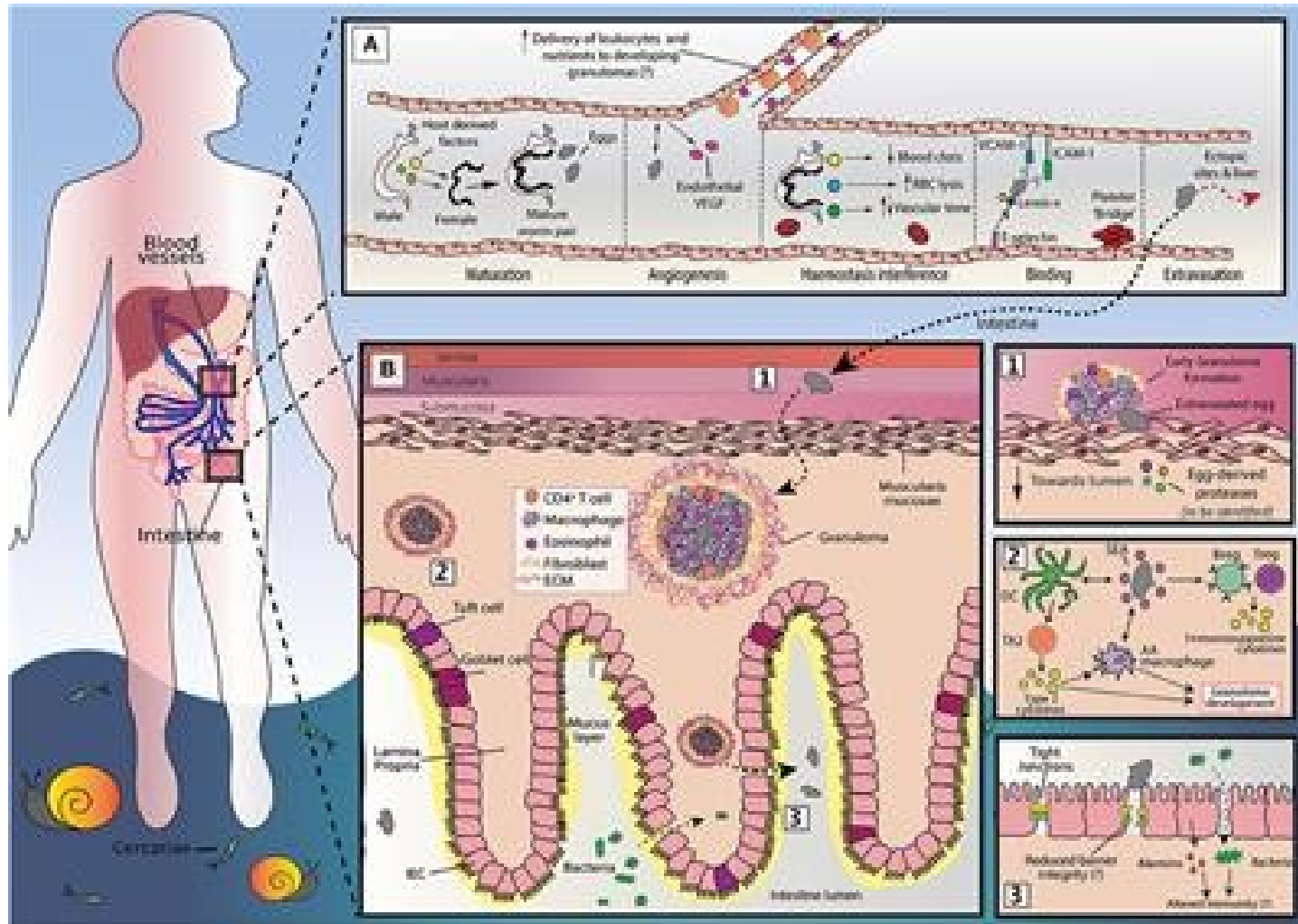


Diagram of *Schistosoma mansoni* cercaria



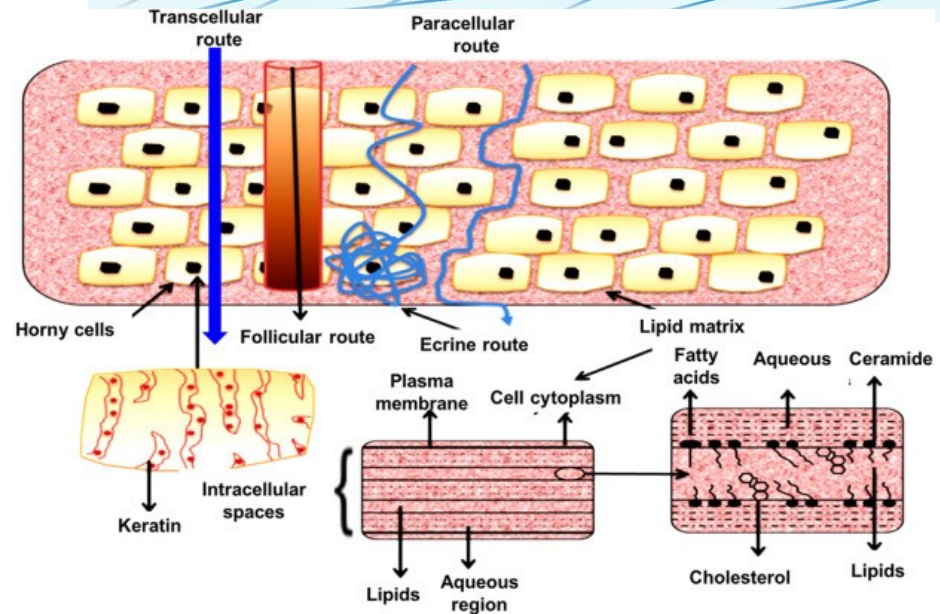
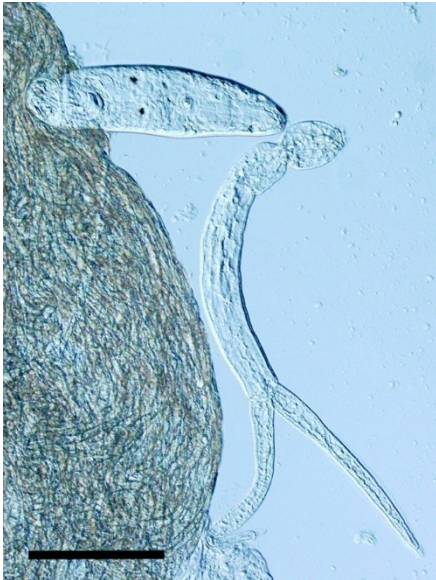# Schistosoma egg migrace



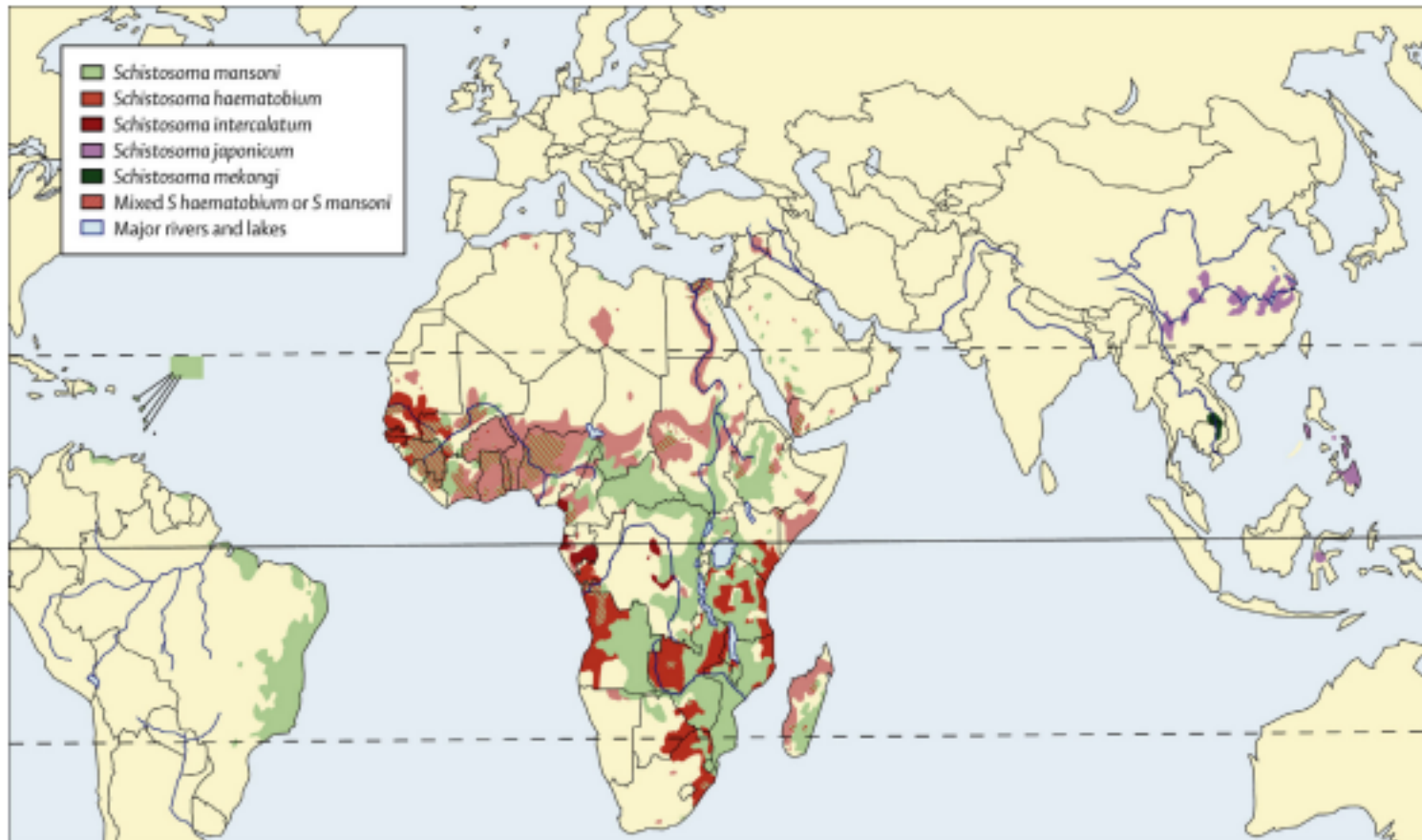


## Mode of infection

- Skin penetration by cercaria from contaminated water of canals aided by:-
- 1- Surface tension of drying droplets of water.
- Proteolytic enzymes secreted by penetration glands.
- Strong lashing movement of the tail pressing the body of cercaria into human skin

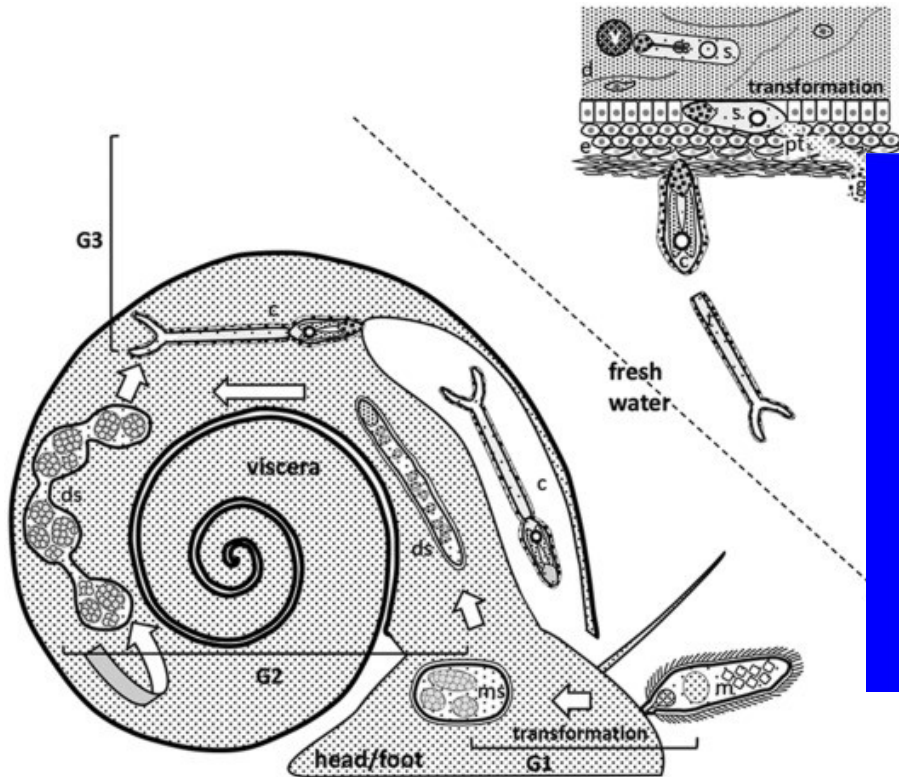


# Shistosoma - rozšíření



**Fig. 2.52** Global distribution of countries where human schistosomiasis is transmitted.

Schistosome species have specific snail hosts whose habitat range defines the distribution of human disease. Thus only *Schistosoma mansoni* is found in the Americas and *Schistosoma japonicum* is only found in Asia, predominantly China and the Philippines. *Schistosoma haematobium* and *Schistosoma mansoni* are found throughout Africa and the Middle East. *Schistosoma mekongi* (Mekong River basin) and *Schistosoma intercalatum* (Central and West Africa) account for a minor portion of disease and have geographically more restricted distributions. (From Colley D.G., Bustinduy A.L., Secor W.E., King C.H. Human schistosomiasis. Lancet 2014, Volume 383, Number 9936, 2253-2264, Fig. 2. (adapted from Gryseels and colleagues). [www.thelancet.com](http://www.thelancet.com))



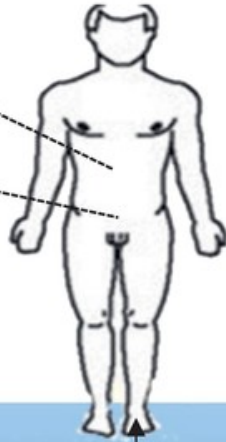
## Host Penetration

- Cercariae attach to the skin surface of an unsuspecting bather.
- Creep over the surface in search of an entry site.
- Penetration through the epidermis.
- Skin penetration takes variable period of time.
- Cercaria loses its tail and becomes a schistosomulum.

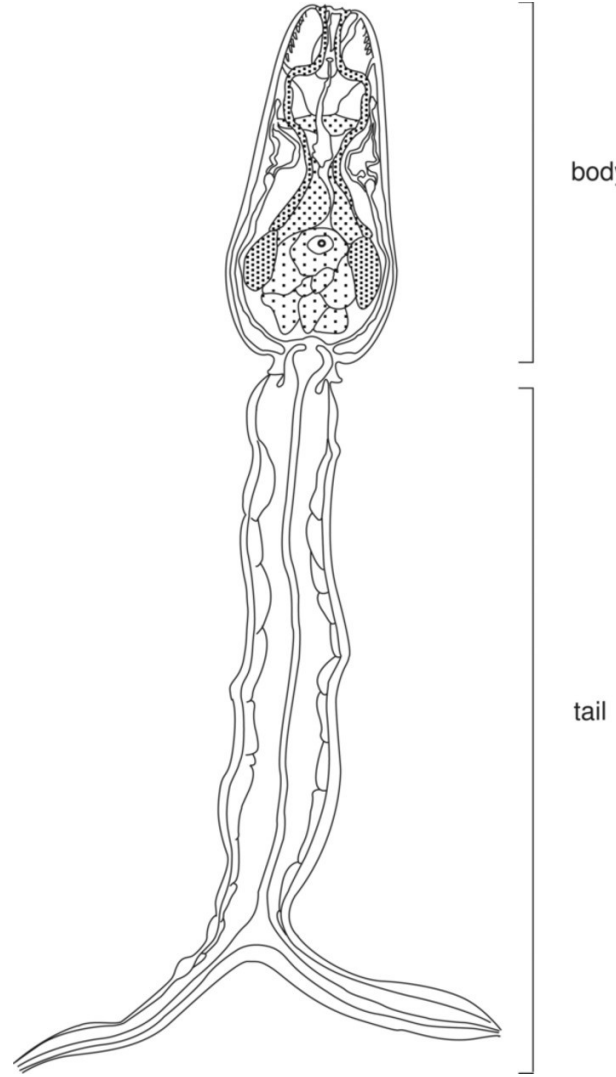
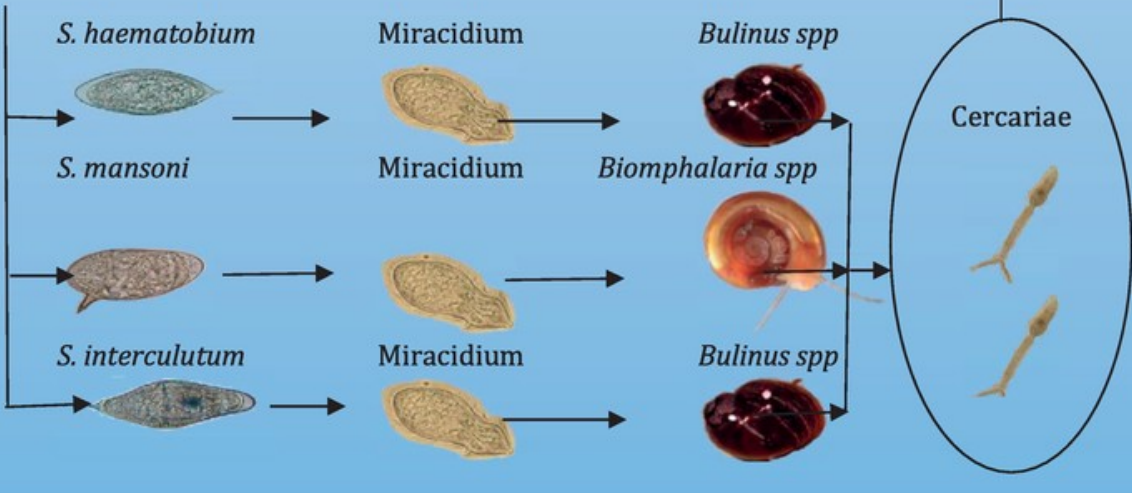


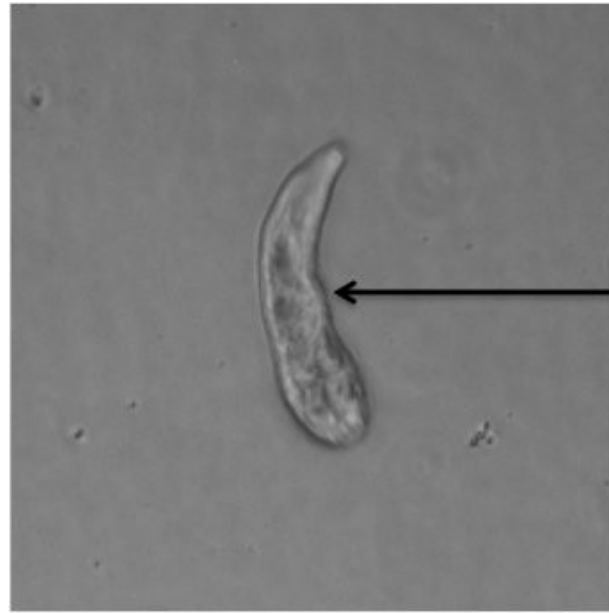
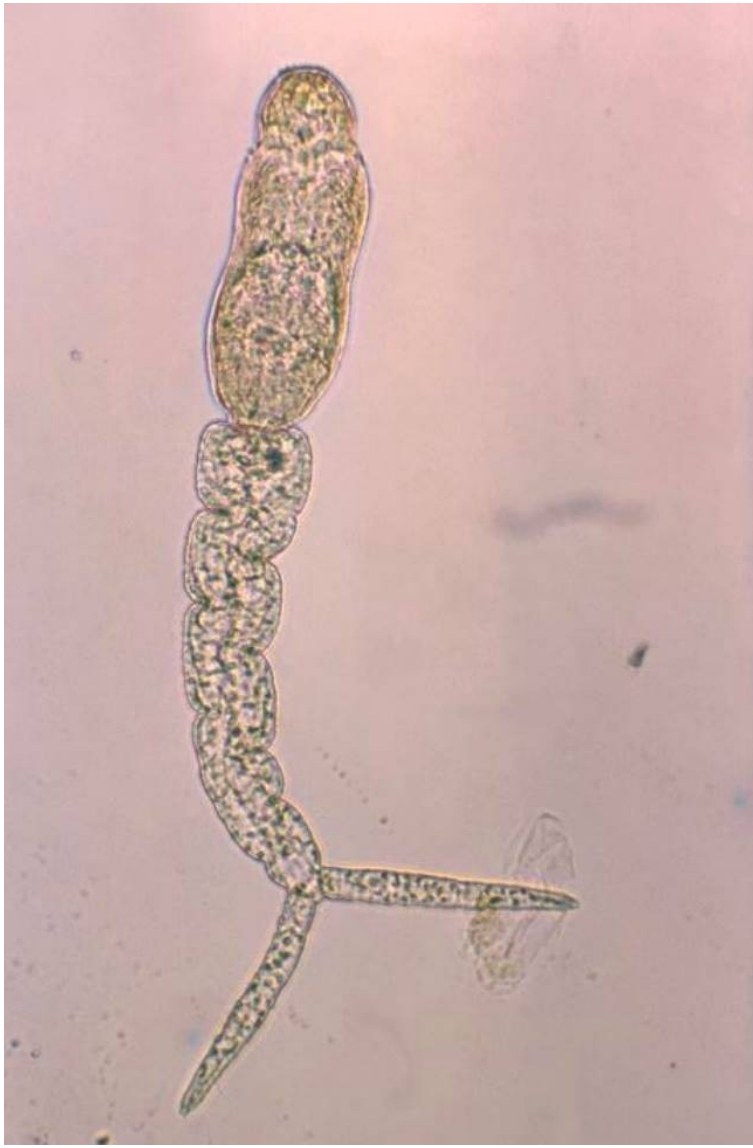
Adult male and female in copula

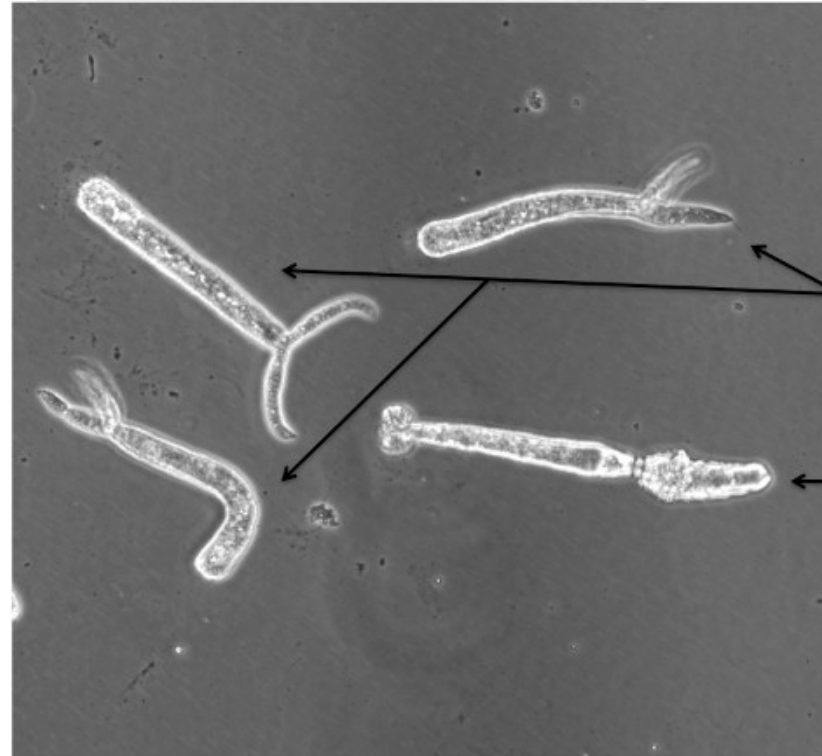


Eggs excreted in urine or feces





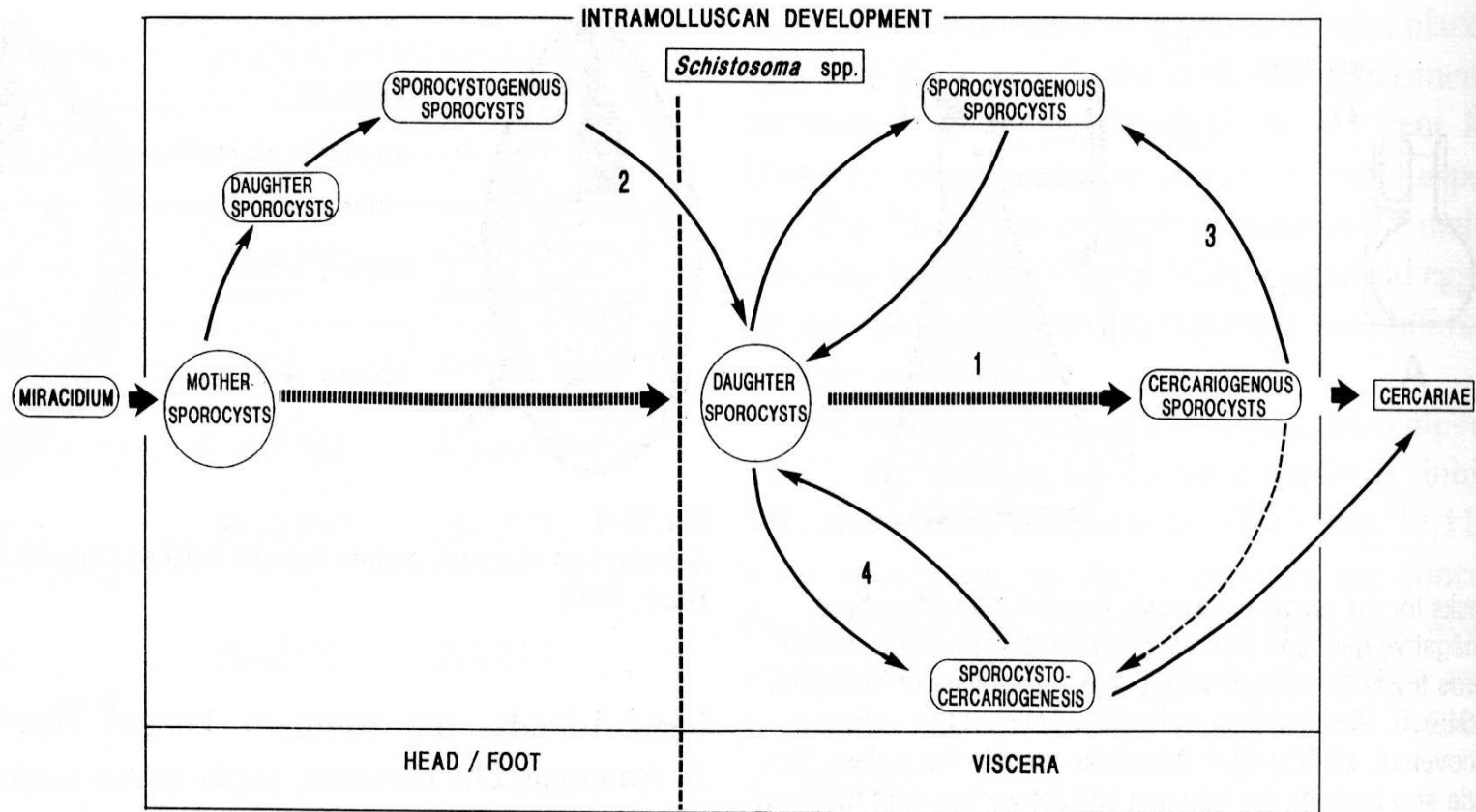
Schistosomulum



Cercarial tails

Cercaria

# Vývoj cizopasníka v mezihostiteli



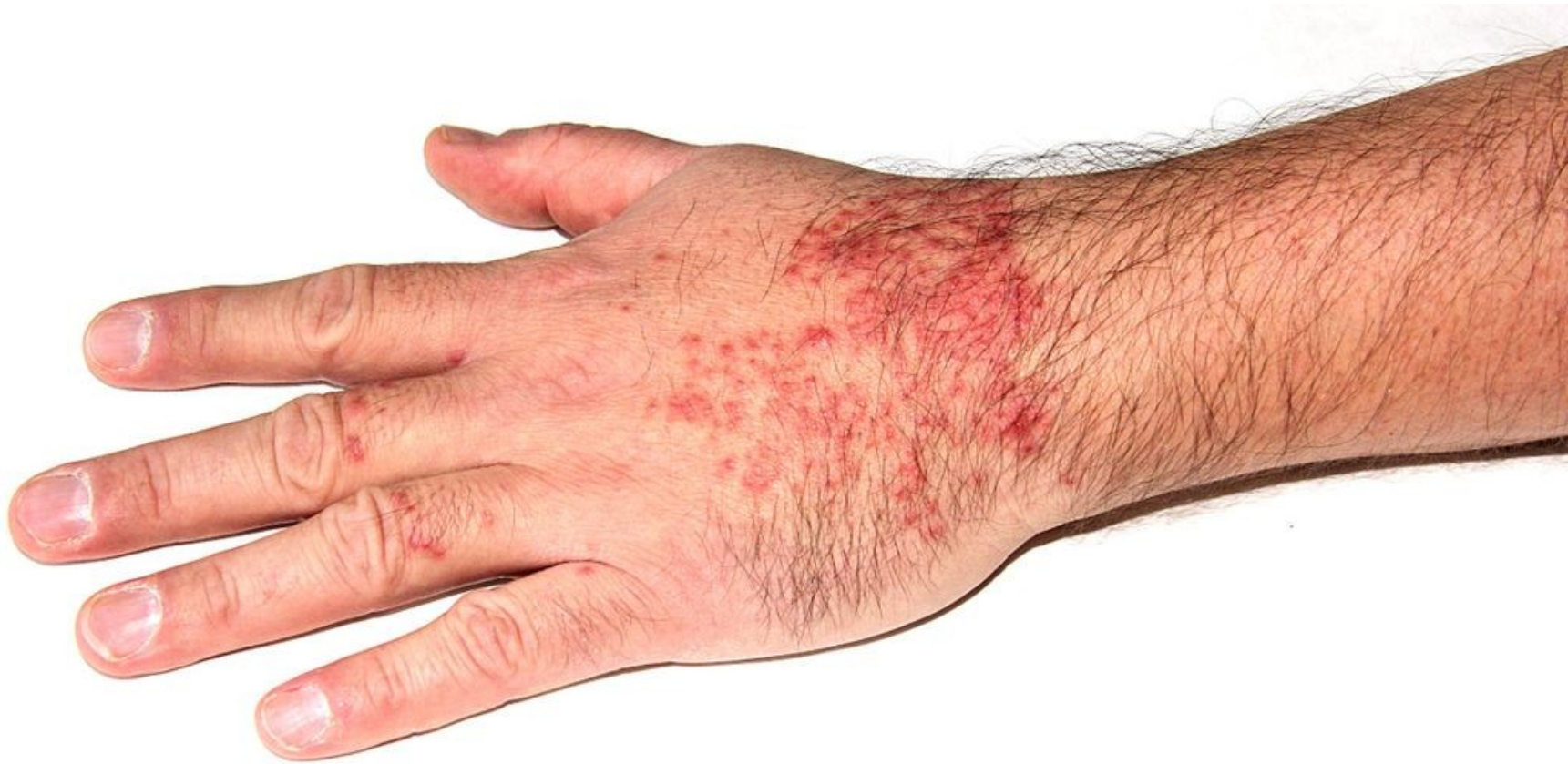**Fig. 16.7**

A proposed new interpretation of the intracellular larval development of schistosomes for which several pathways are possible:

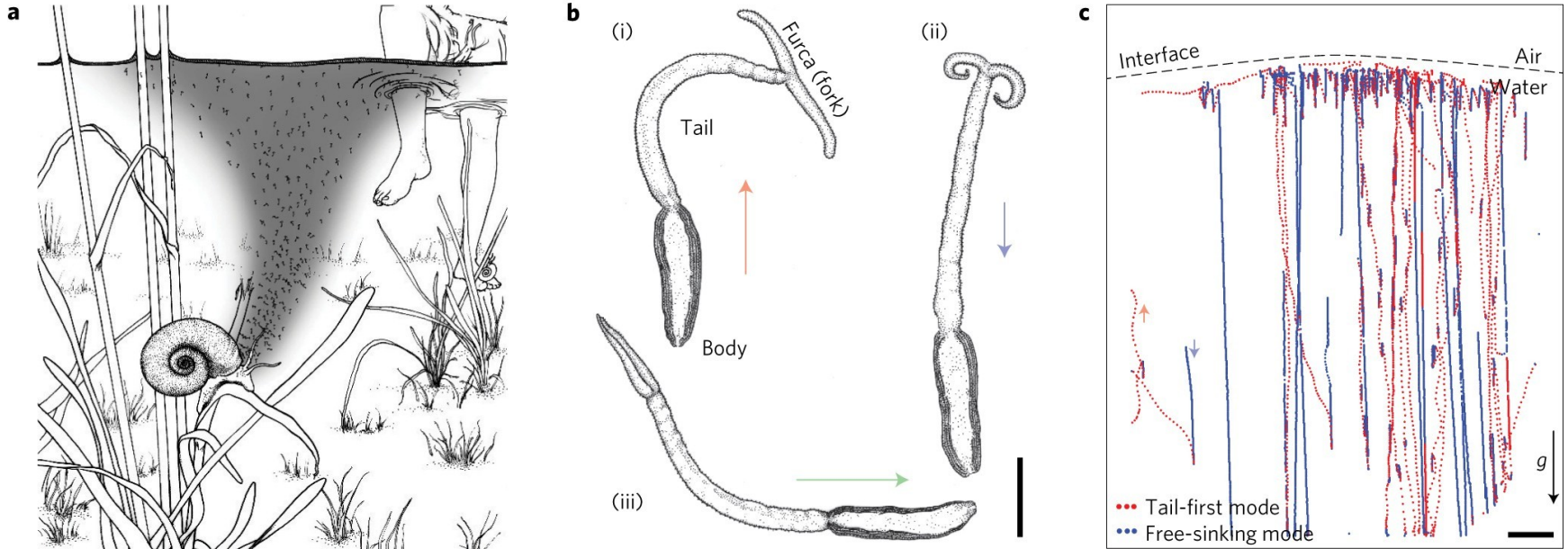
1. Cercariogenous sporocysts producing only cercariae;
2. Sporocystogenous sporocysts producing a new generation of daughter sporocysts by direct sporocystogenesis, or by

3. Sporocystogenesis taking place after cercariogenesis; or by
4. Simultaneous sporocysto-cercariogenesis. (Adapted from Jourdan & Therón, 1987; reprinted with permission from *Biology of Schistosomes* (ed. R. Rollinson & J. C. Simpson), p. 87. Academic Press, London, 1987.)



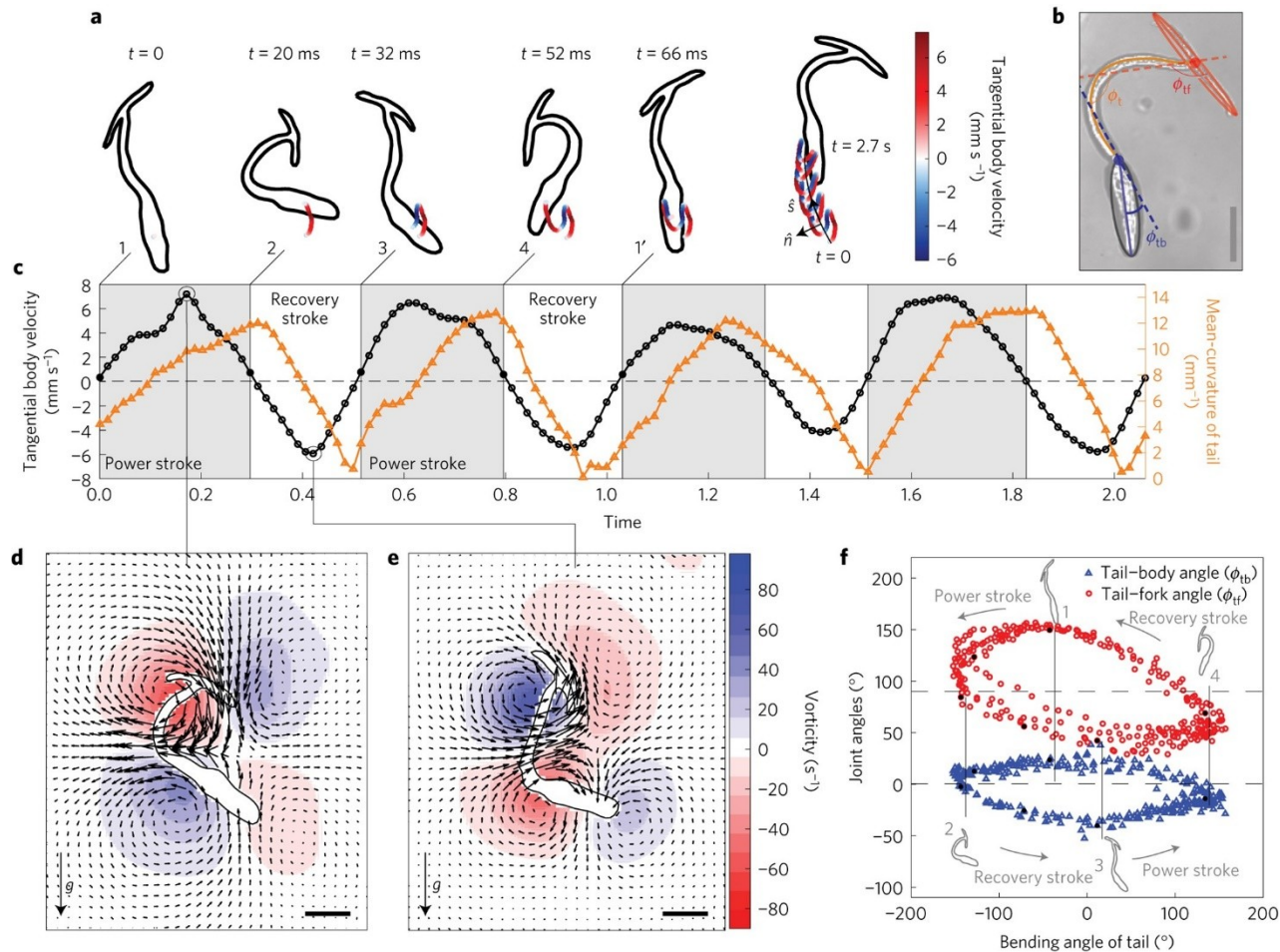






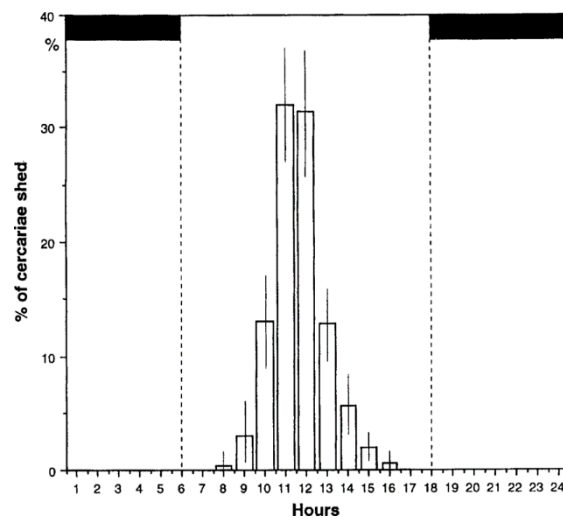
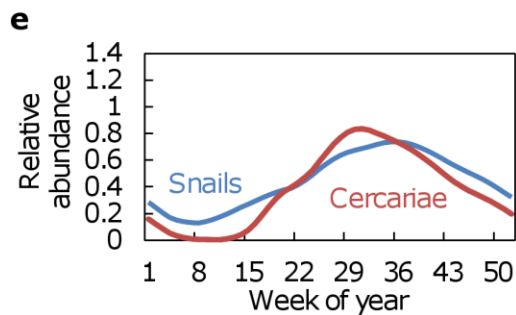
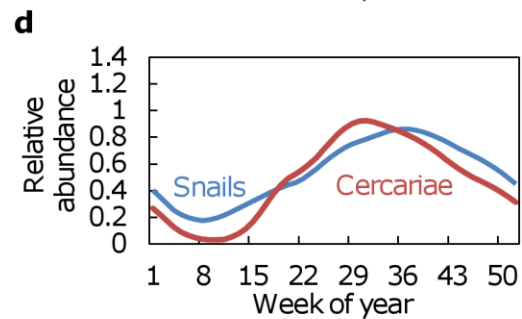
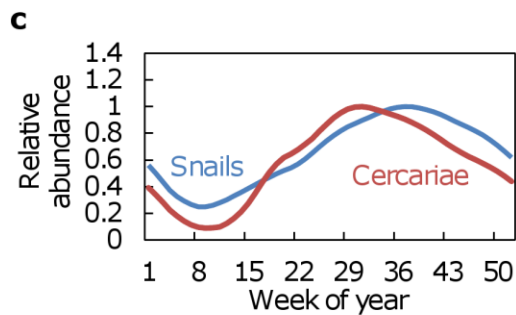
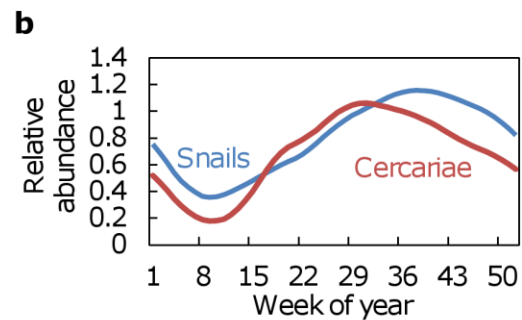
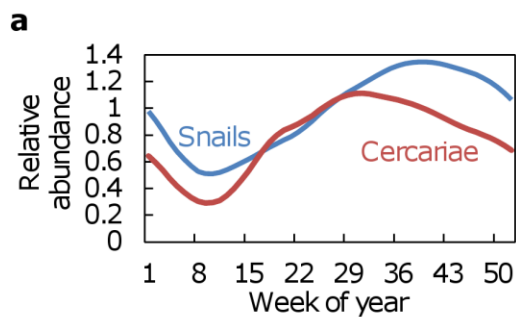
**a**, Artistic rendering (not to scale) of a typical transmission site where cercariae (immature, human infectious stage of the parasites) emerge into freshwater from snails and aggregate near the water surface<sup>8</sup>. **b**, Artistic rendering of the three distinct modes displayed by cercariae in their intermittent swimming behaviour ([Supplementary Video 1](#)) termed (i) tail-first mode, (ii) free-sinking mode and (iii) body-first mode. Arrows indicate the direction of motion. Scale bar, 100  $\mu\text{m}$ . **c**, Computationally tracked snapshot of cercariae swimming in a vertical chamber ([Supplementary Methods](#)) showing tail-first swimming (red) and sinking (blue) trajectories for 10 min ([Supplementary Movie 2](#)). The resulting tracks of organisms have a strikingly columnar nature ([Supplementary Movie 2](#)) with very little drift in the horizontal direction. This is due to the fact that cercariae are bottom-heavy swimmers ([Supplementary Fig. 2](#)) and undergo a gravitational realignment such that their longitudinal axis is aligned with the vertical with the body pointing down. Scale bar, 1 mm.

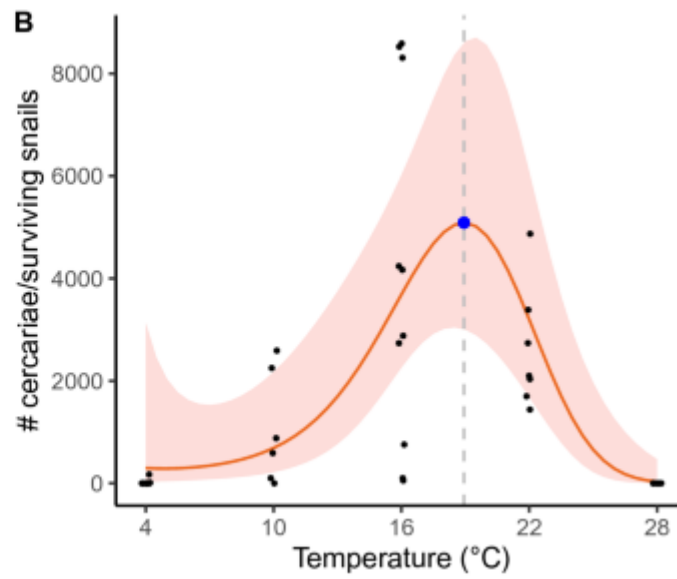
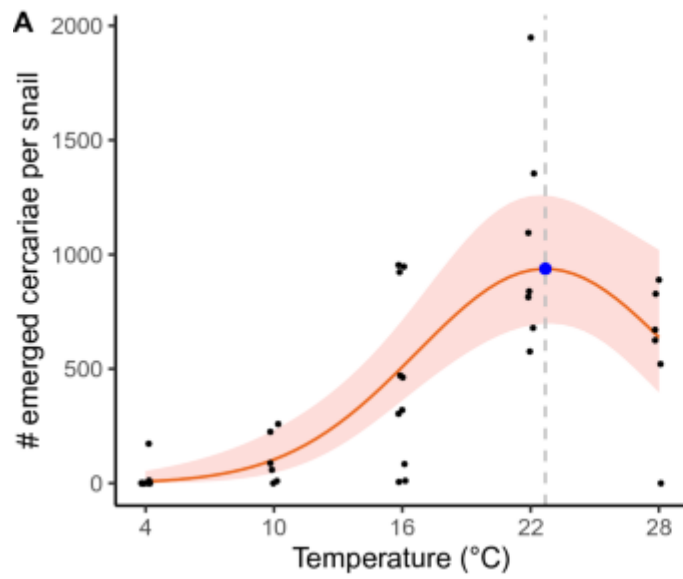




**a**, Extracted dynamic shapes from high-speed videos of cercomorphs at different time points during a swimming cycle (Supplementary Methods). The trajectory of the body is colour-coded based on the instantaneous velocity magnitude along the local tangent ( $\hat{s}$ ) to the mean swimming trajectory, shown as a solid black line in the last panel. **b**, Illustration of kinematic parameters: the angle at the tail-body joint  $\phi_{tb}$  shown in blue, the angle at the tail-fork joint  $\phi_{tf}$  shown in red and an effective bending angle of the tail  $\phi_t$  shown in orange. **c**, Time series plot of the tangential body velocity along  $\hat{s}$  (left axis) demonstrates forward motion although the mean-curvature of the tail (right axis) is symmetric, seemingly appearing to be a reciprocal stroke. Grey regions (1  $\rightarrow$  2, 3  $\rightarrow$  4 and so on) correspond to power strokes where the body of the organism has a tangential velocity in the mean swimming direction, while white regions (2  $\rightarrow$  3, 4  $\rightarrow$  1' and so on) are recovery strokes where the body moves in the opposite direction. Time is normalized by  $1/f$ , where  $f = 15.6$  Hz is the beat frequency. **d, e**, Snapshots of the transient flow velocity exhibiting reversing stagnation points. Vorticity fields obtained using particle image velocimetry (PIV) during the power stroke and recovery stroke, respectively. The regions of vorticity remain attached to the organism and are not shed (Supplementary Movie 4). **f**, Phase plot of  $\phi_{tb}$  and  $\phi_{tf}$  as a function of  $\phi_t$  clearly shows a finite area, hence revealing the role of tail-fork and tail-body joints in producing a non-reciprocal swimming stroke, required for low-Reynolds-number swimming. Scale bars,  $100 \mu\text{m}$ .

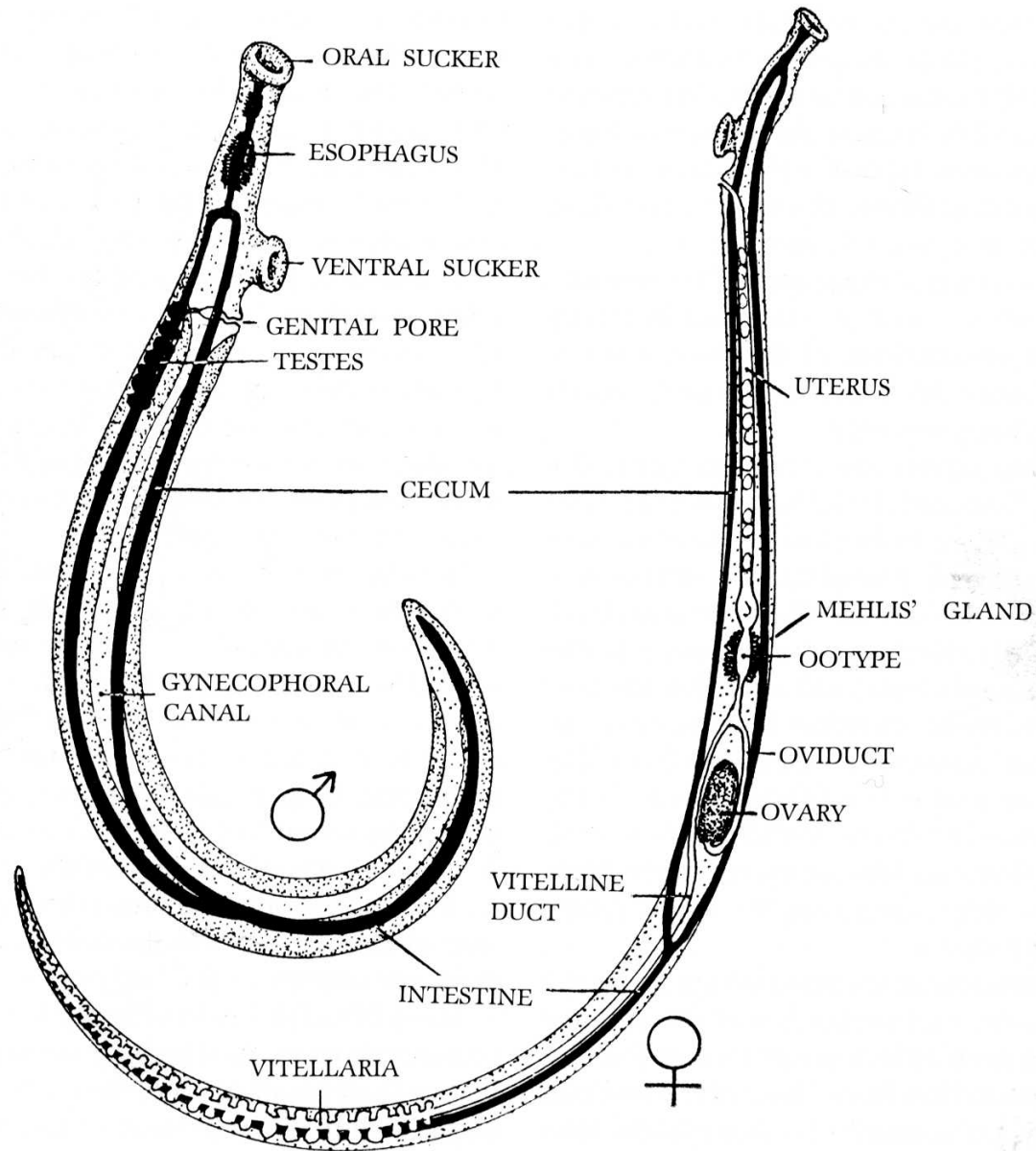
# Vztah plži versus cercárie



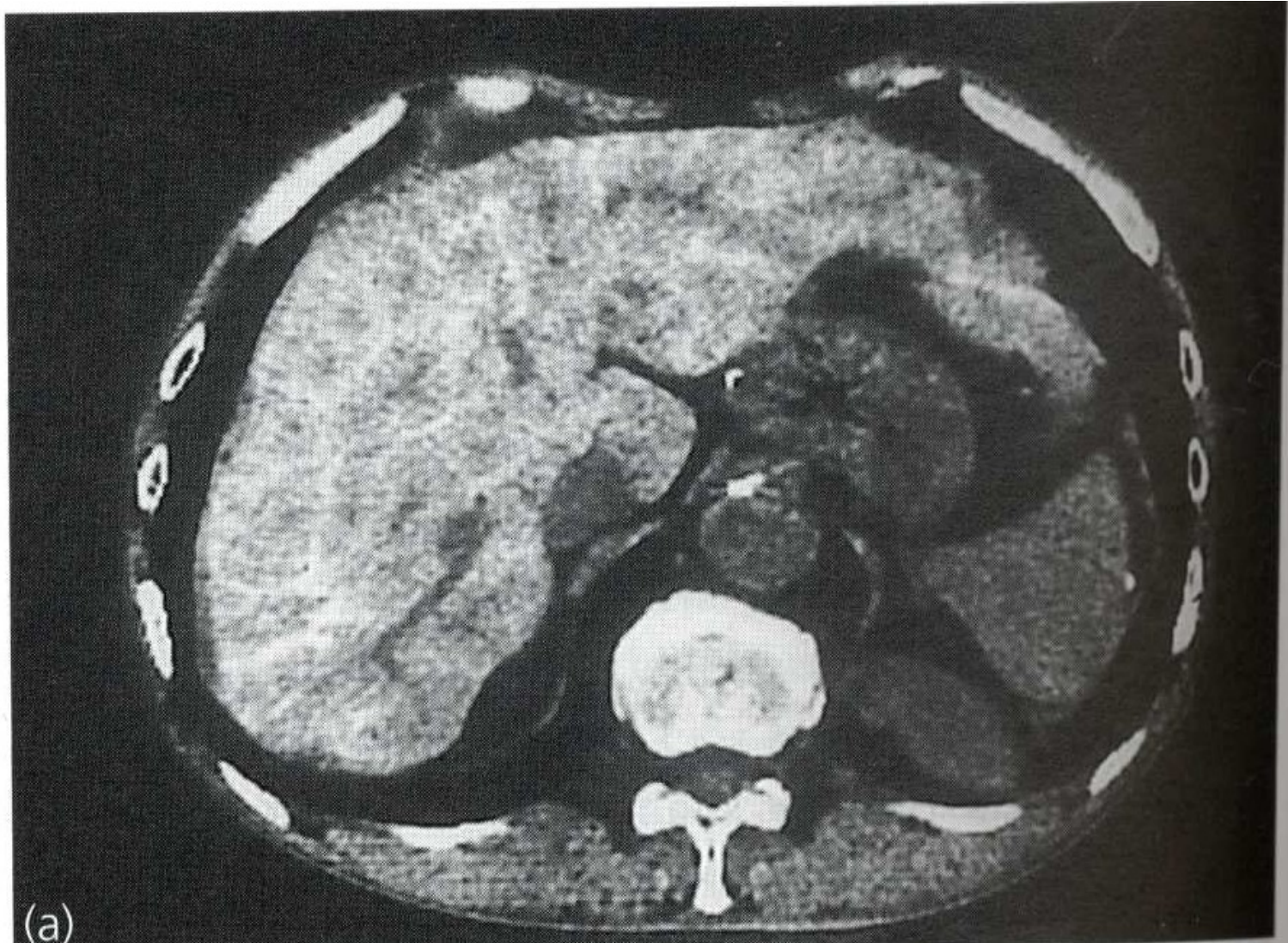




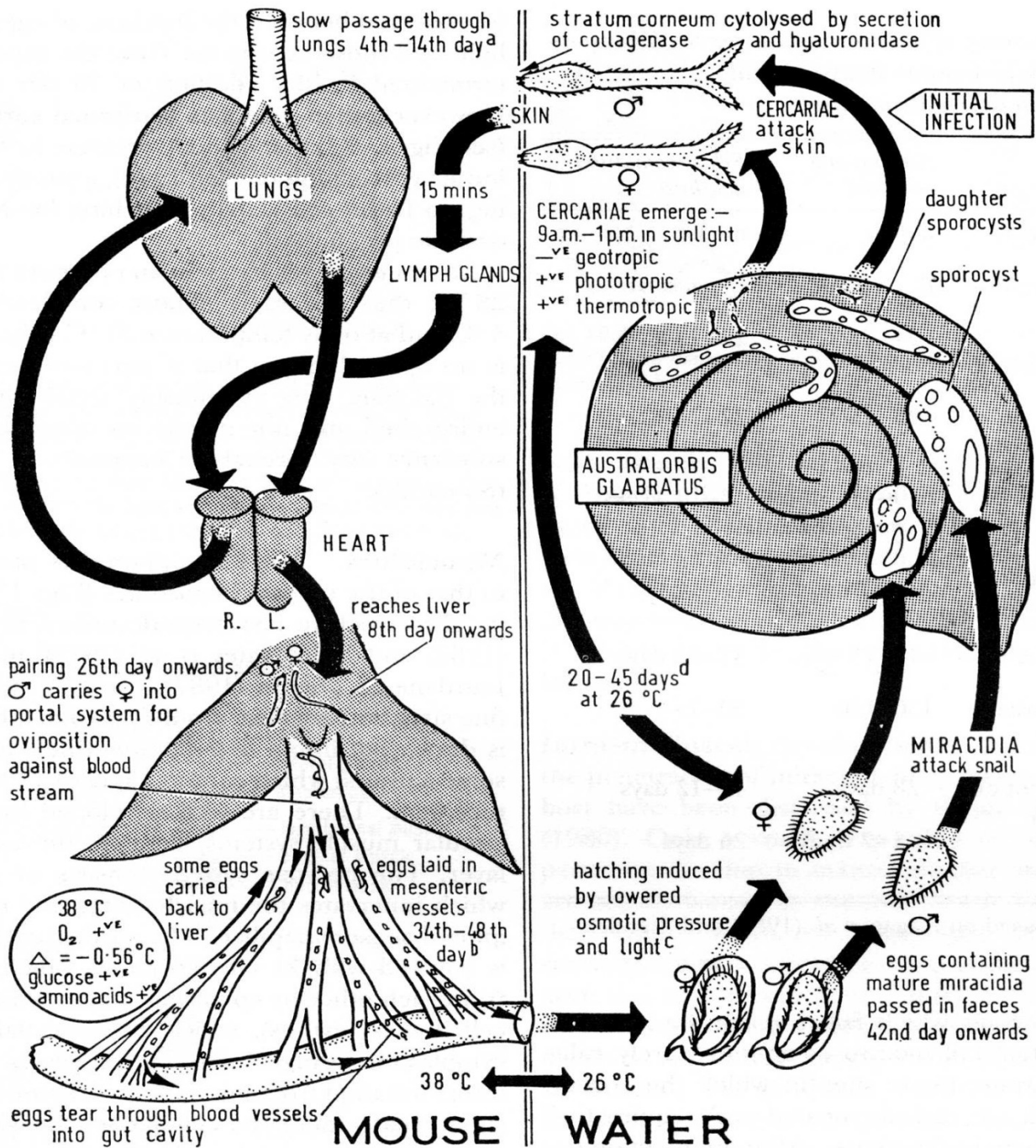




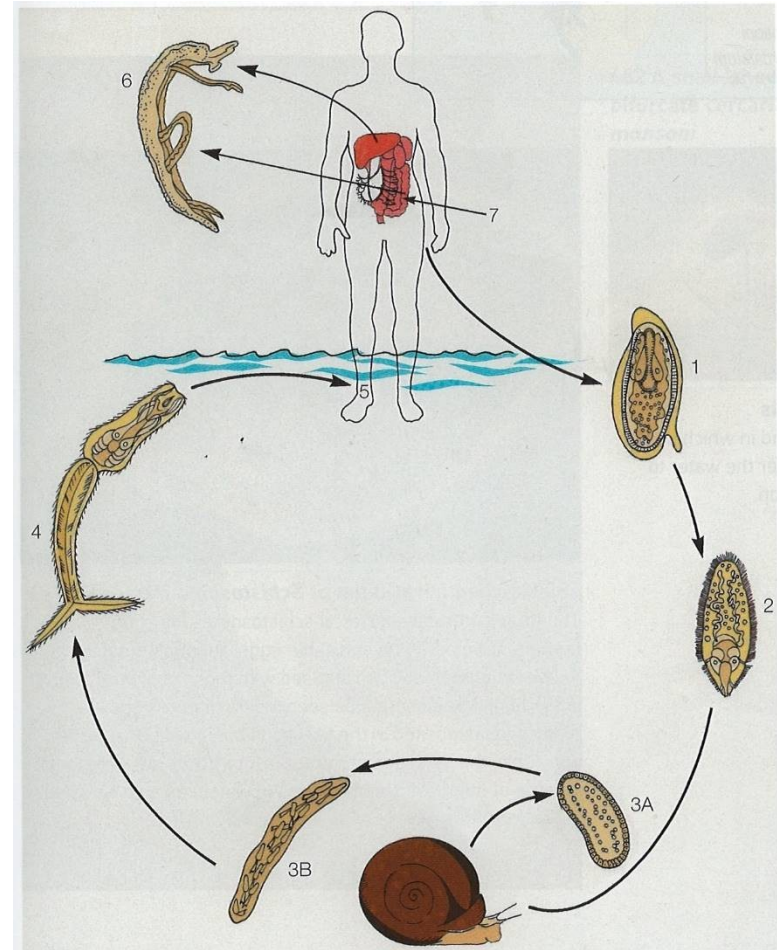
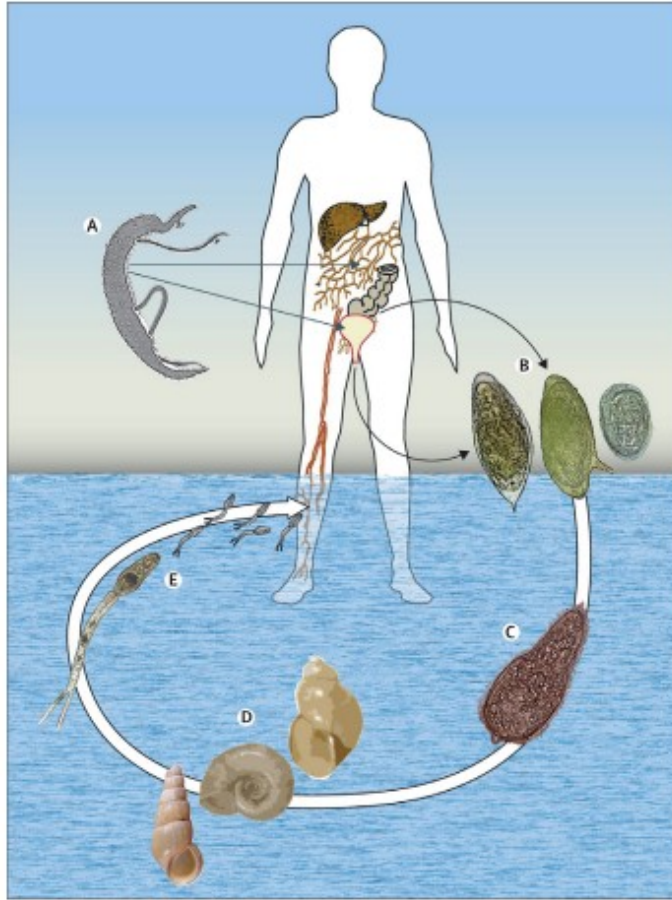
# Japonica ?



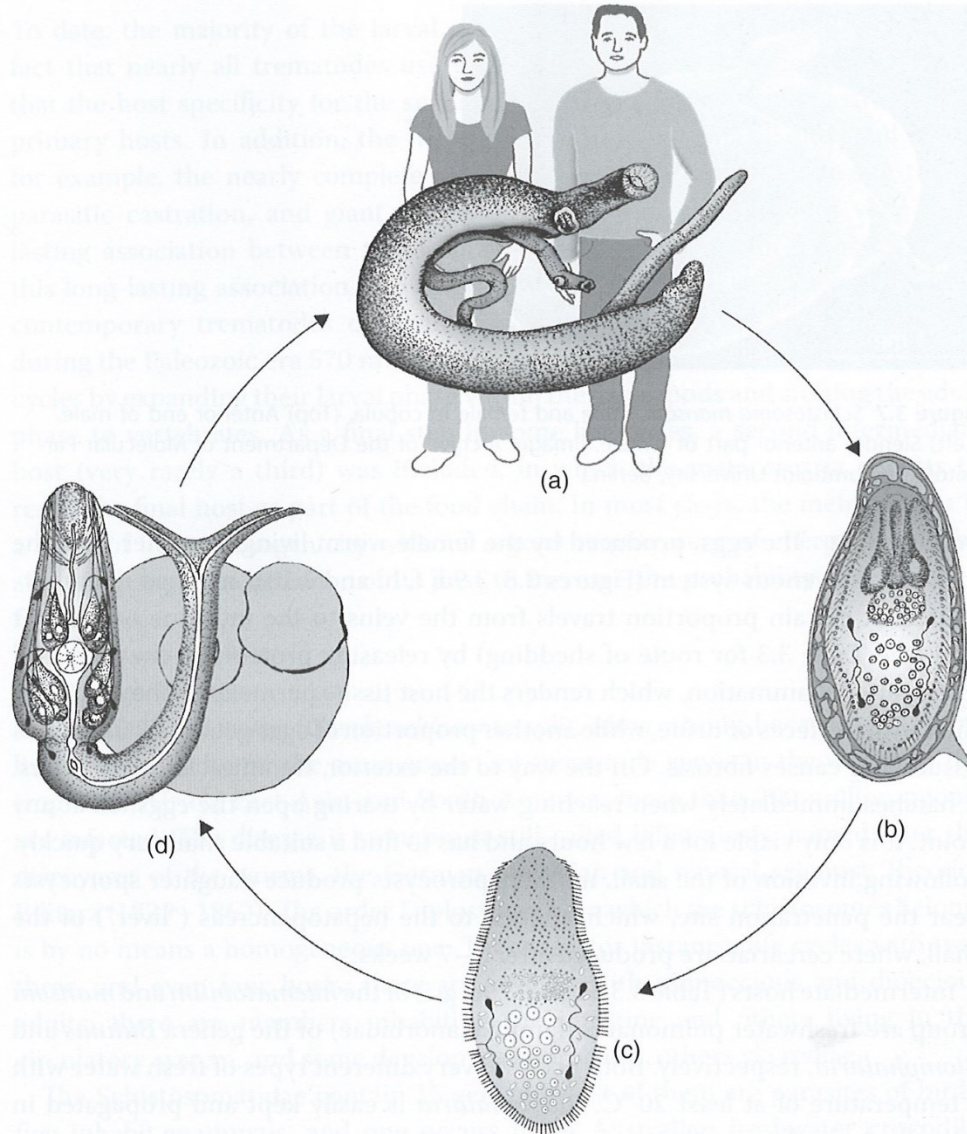




# Schistosoma - diverzita



# Schistosoma mansoni





# Schistosoma mansoni

