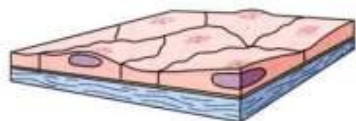


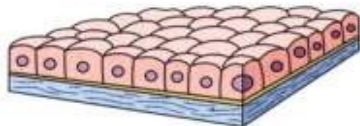
Klasifikace epitelů

jednovrstevný

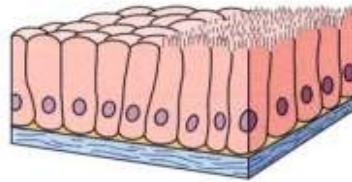
víceřadý



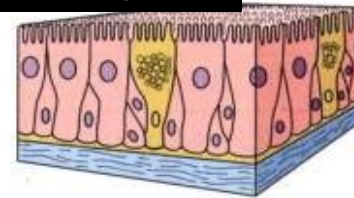
Squamous



Cuboidal



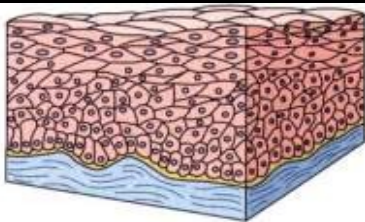
Columnar



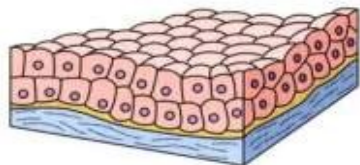
Pseudostratified columnar

mnohovrstevný

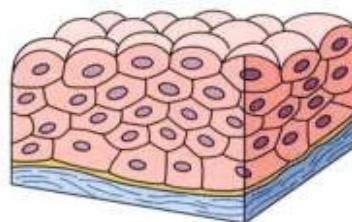
Přechodný



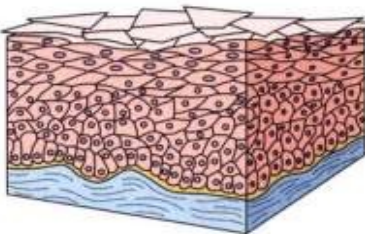
Squamous nonkeratinized



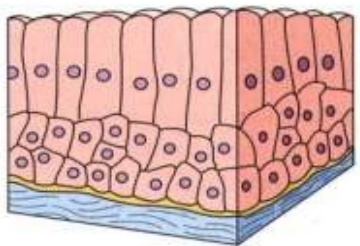
Cuboidal



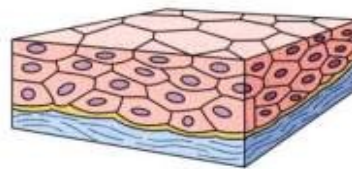
Transitional (relaxed)



Keratinized



Columnar



Transitional (distended)

See: Junqueira & Carneiro (Fig. 4-12)