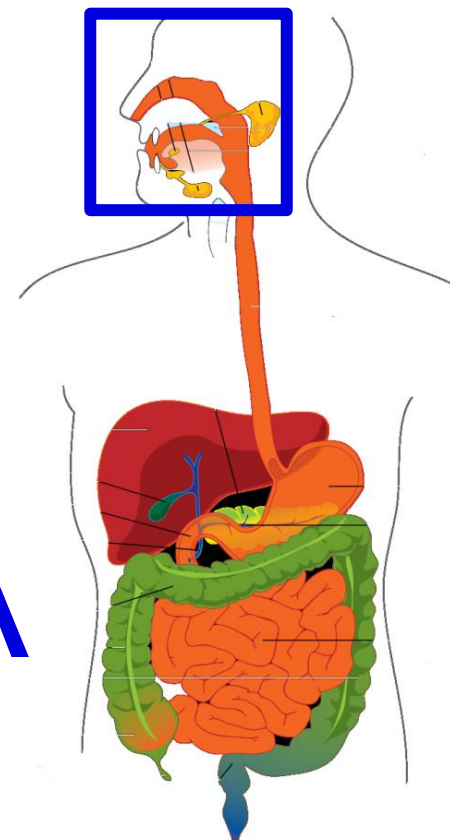


# VÝVOJ A MIKROSKOPICKÁ ANATOMIE GIT I



# ÚSTNÍ DUTINA



- Horní a dolní ret
- Vestibulum oris
- Tvrdé a měkké patro
- Zub
- Jazyk

# ORÁLNÍ SLIZNICE

- ***lamina epithelialis mucosae***  
vrstevnatý dlaždicový epitel
- ***lamina propria mucosae***  
řídke kolagenní vazivo

- **krycí sliznice**

- slizniční a podslizniční vazivo

- **mastikační sliznice**

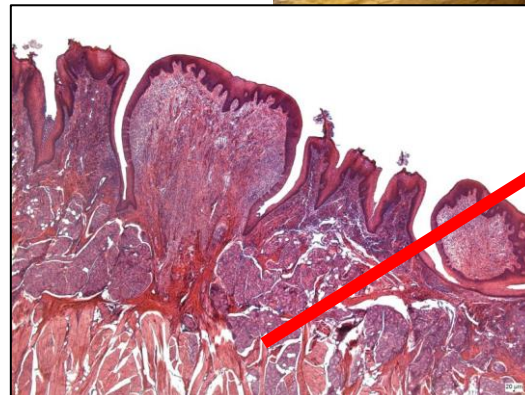
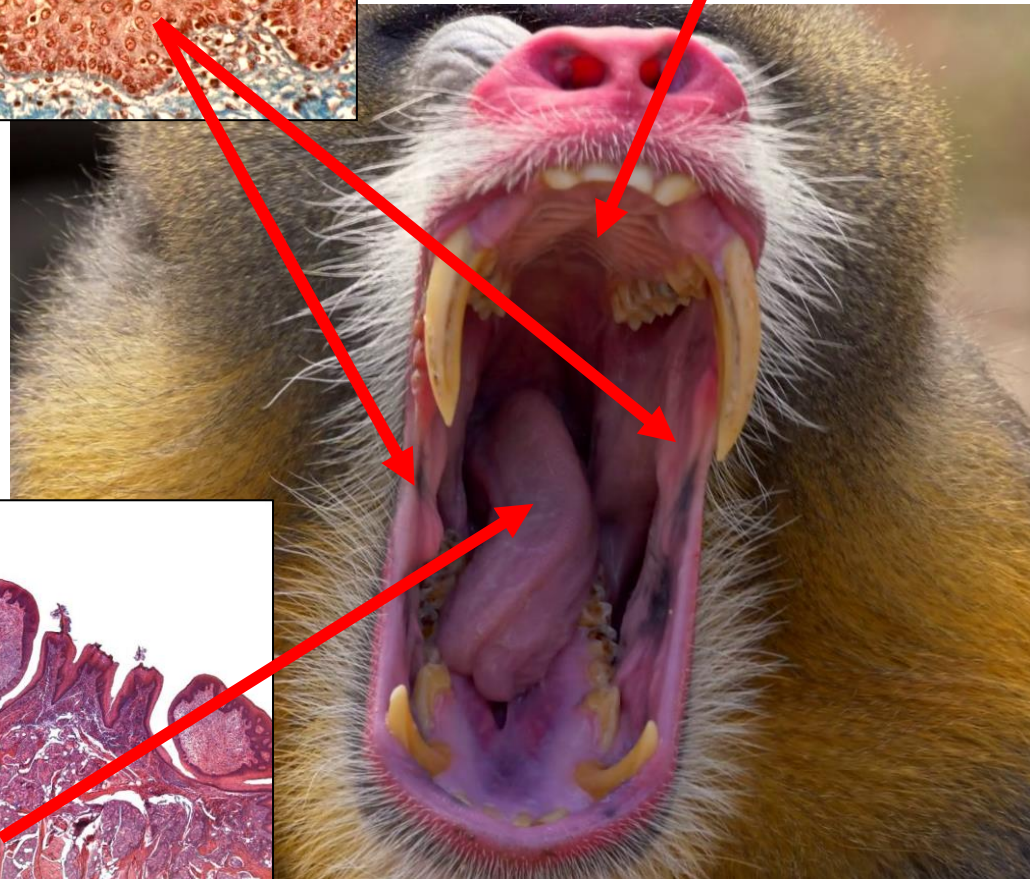
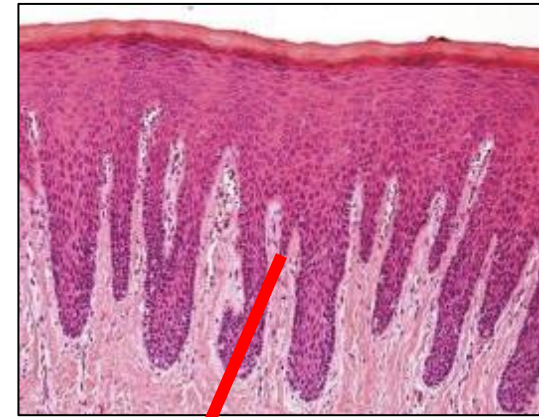
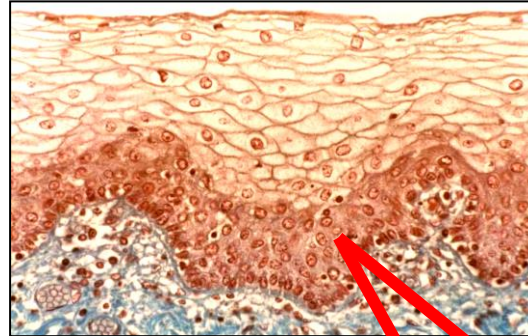
- zrohovatělý epitel, lamina propria  
přechází v periost (mukoperiost)

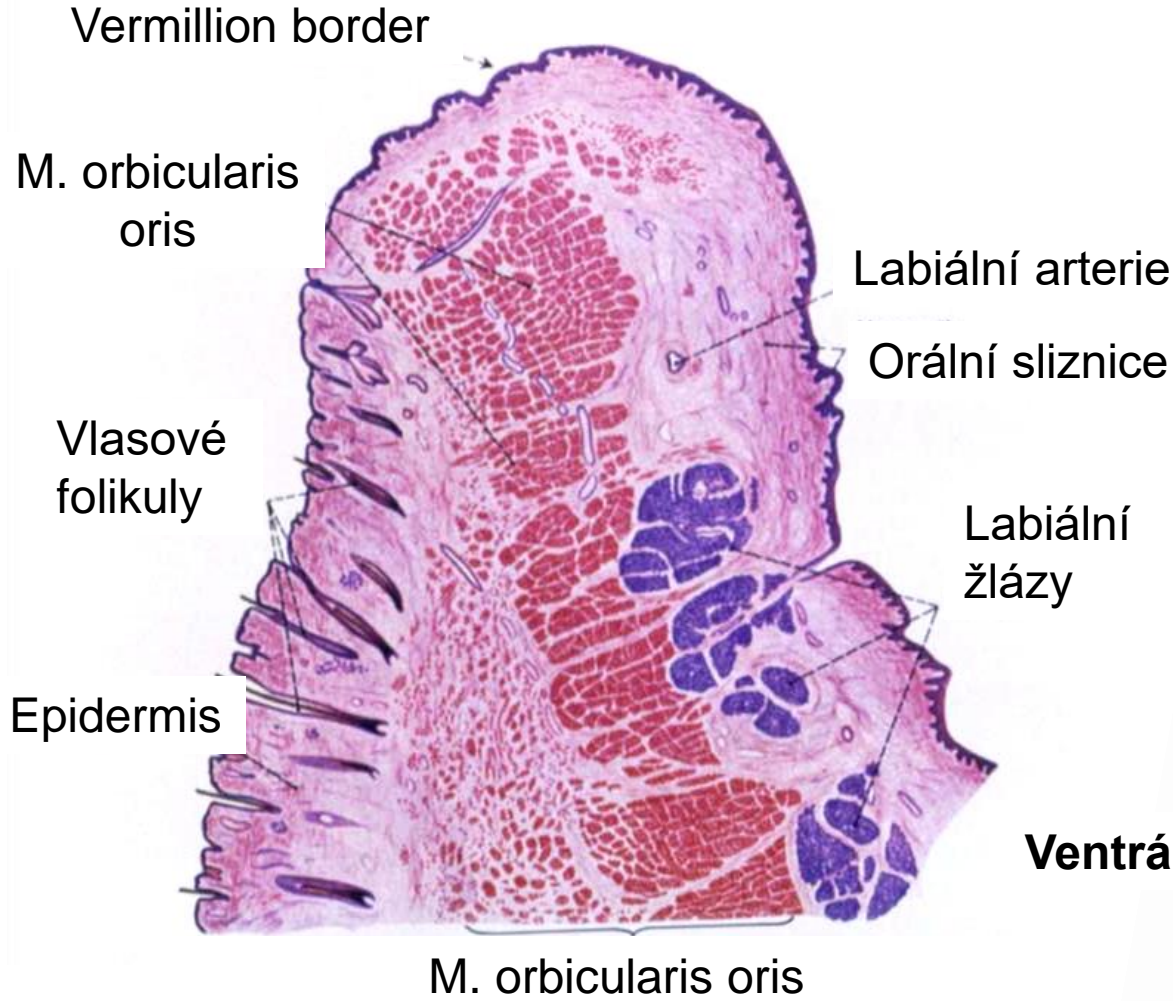
- submukóza chybí

- dásně, tvrdé patro

- **specializovaná sliznice**

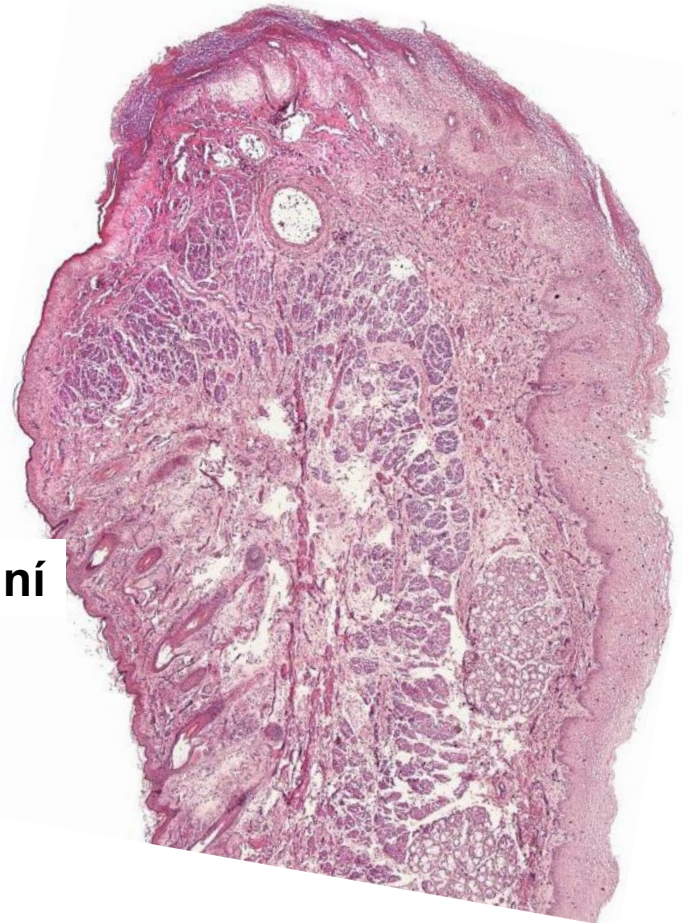
- dorsum linguae

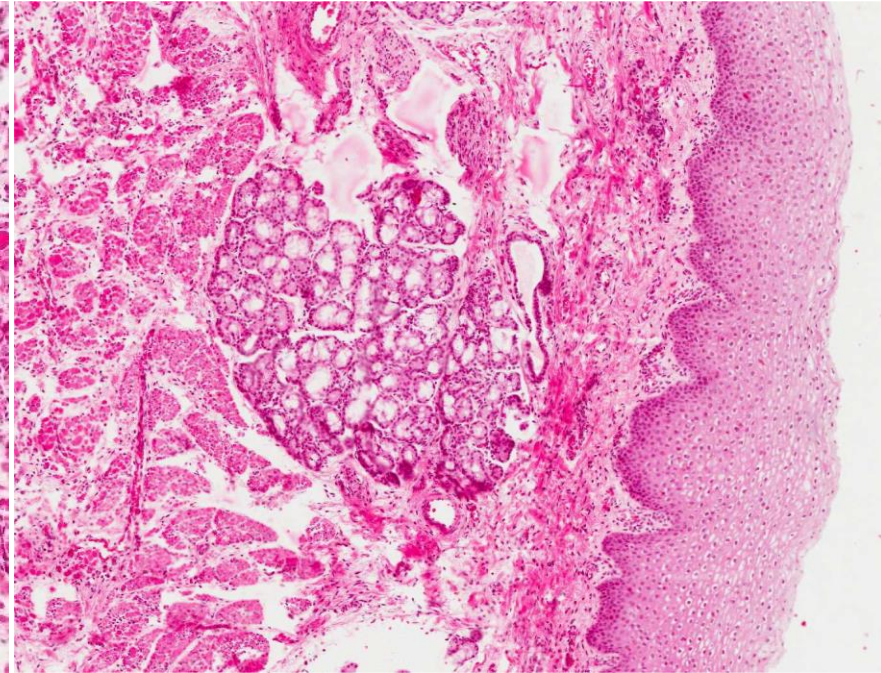
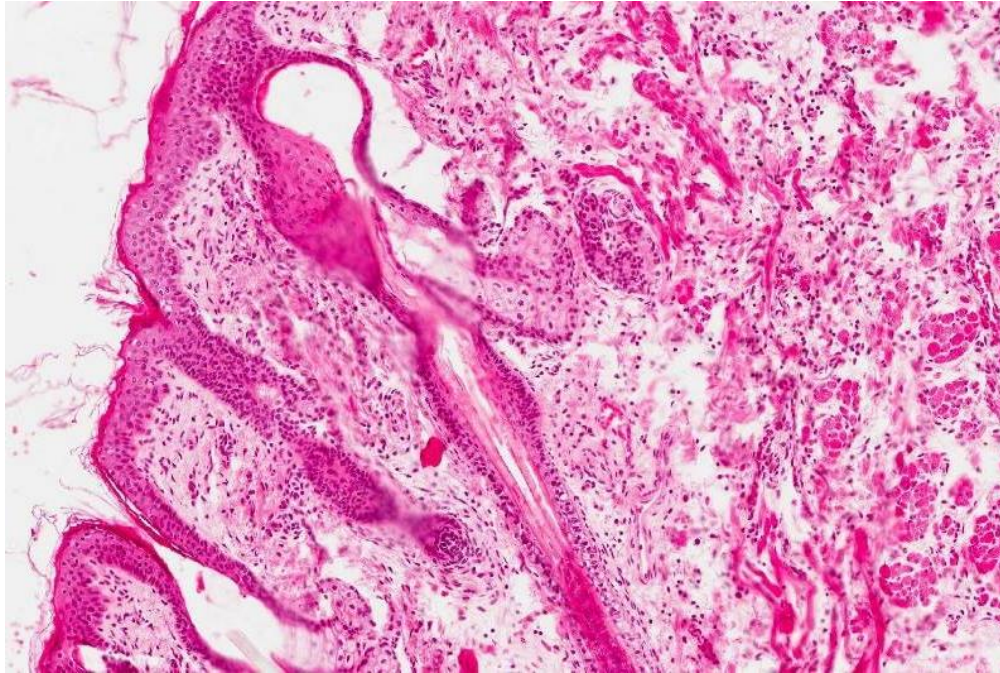




**Dorsální**

**Ventrální**



**Kožní aspekt (ventrálně)****Orální aspekt (dorsálně)****Epidermis**

Vrstevnatý dlaždicový epitel rohovějící

**Dermis**

Řídké kolagenní vazivo

Vlasové folikuly

Mazové žlázy

Potní žlázy

**Orální sliznice**

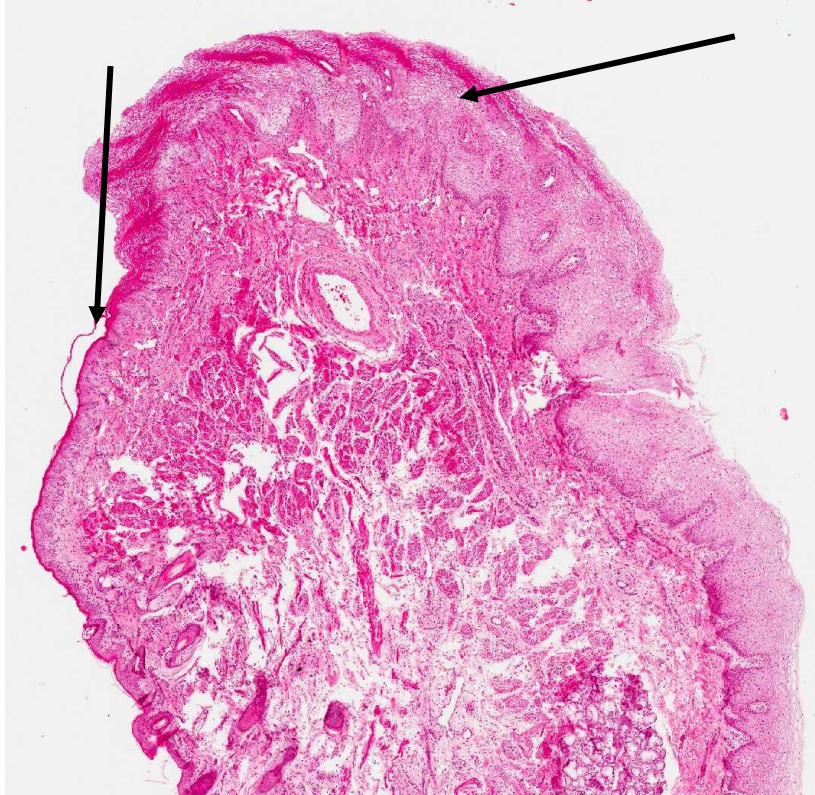Vrstevnatý dlaždicový epitel

Řídké kolagenní vazivo

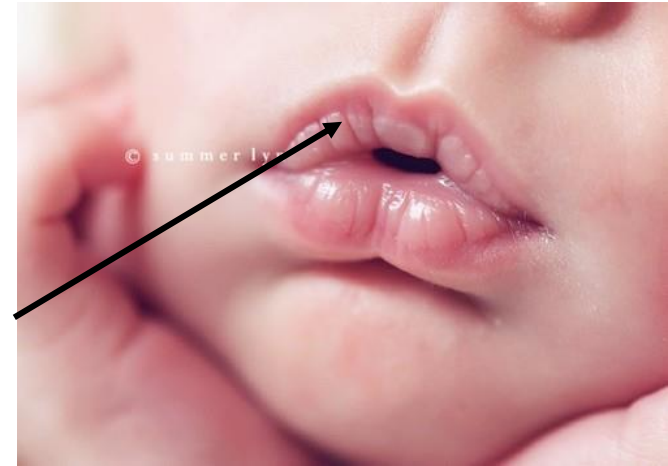Malé labiální smíšené slinné žlázy

pars glabra

pars villosa

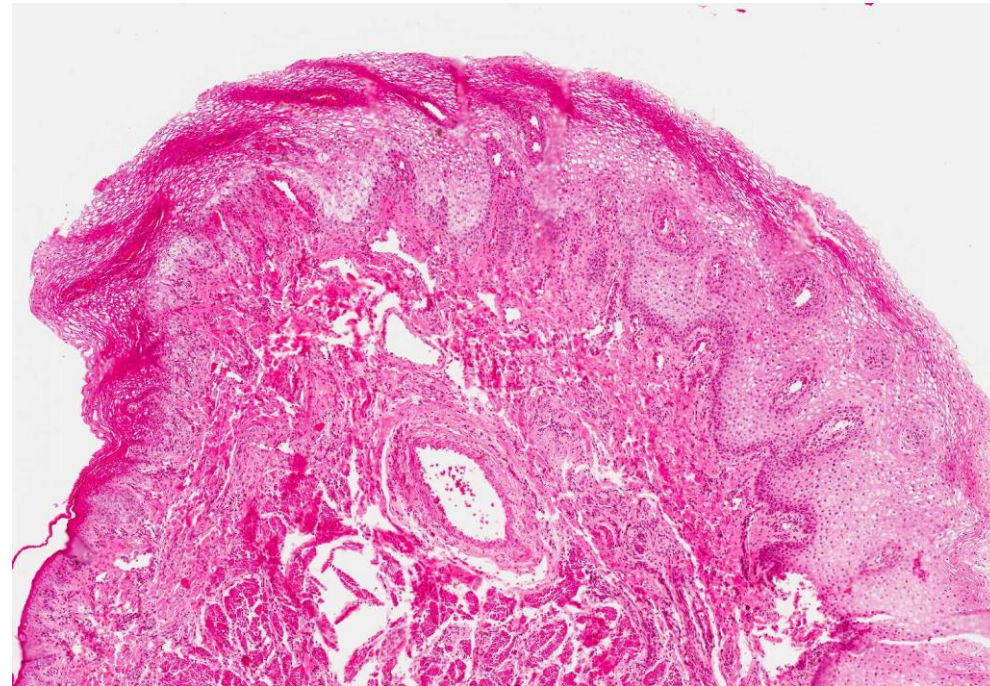


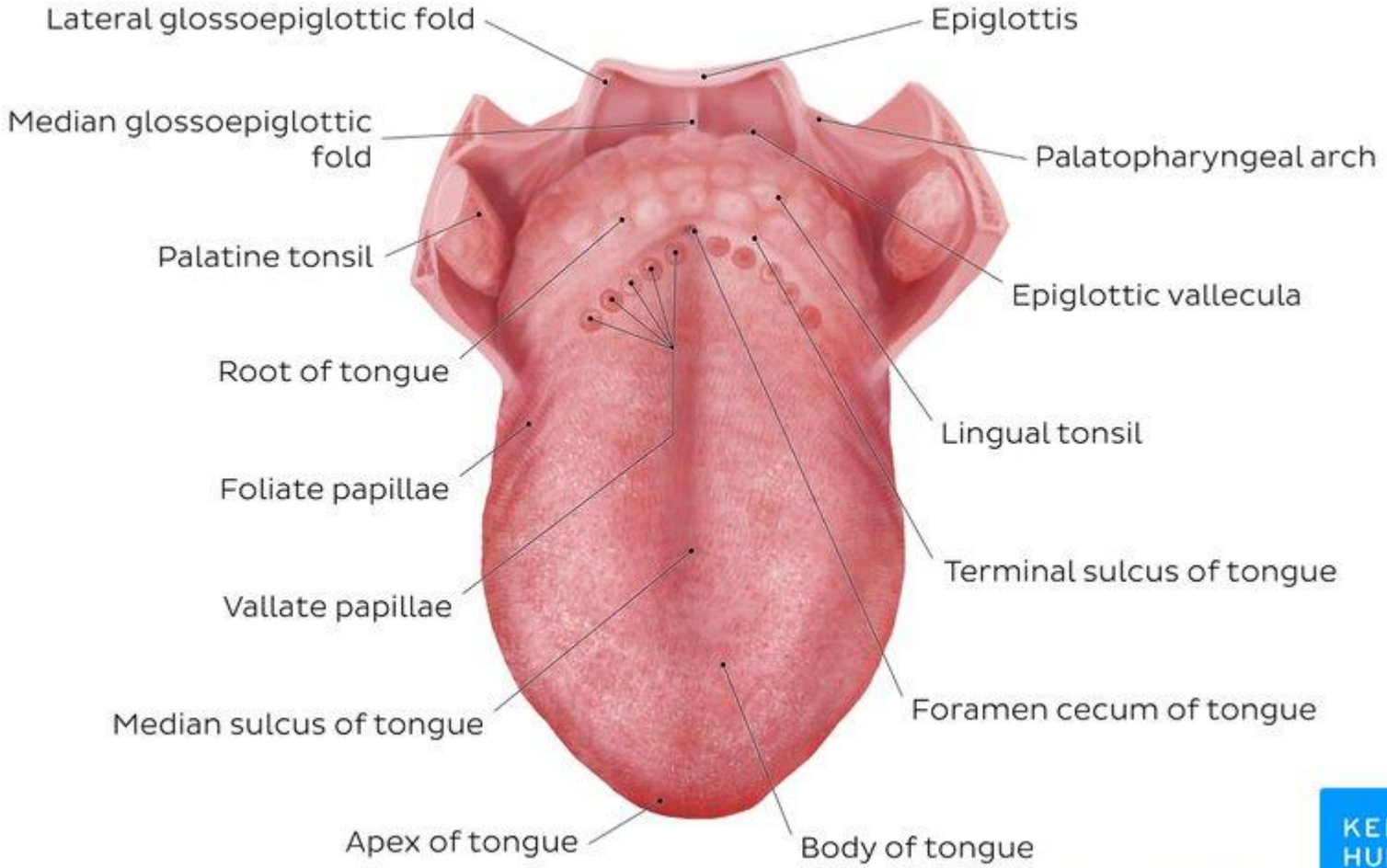
novorozenci  
torus labialis

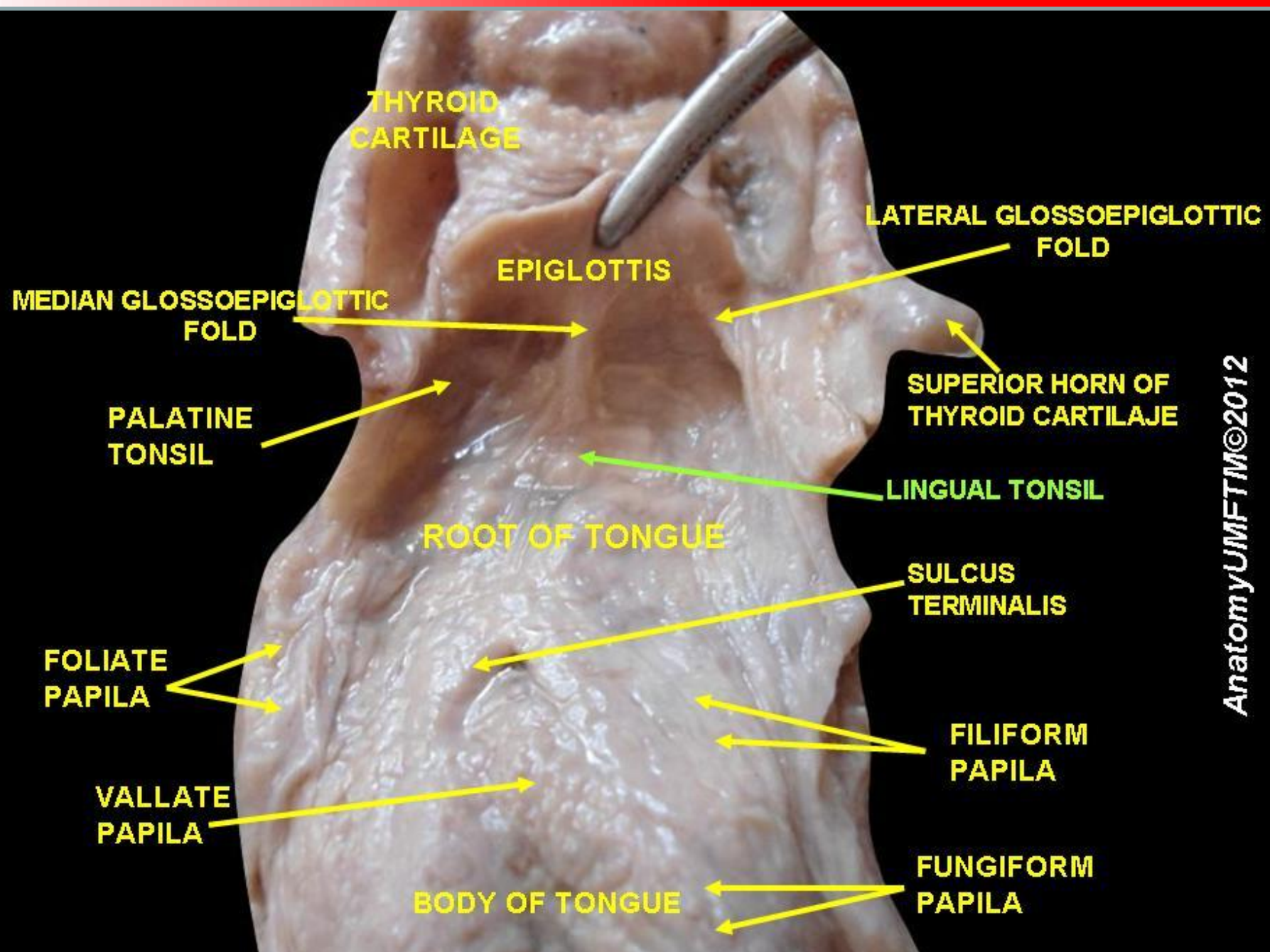


## Vermillion border (červeň rtu)

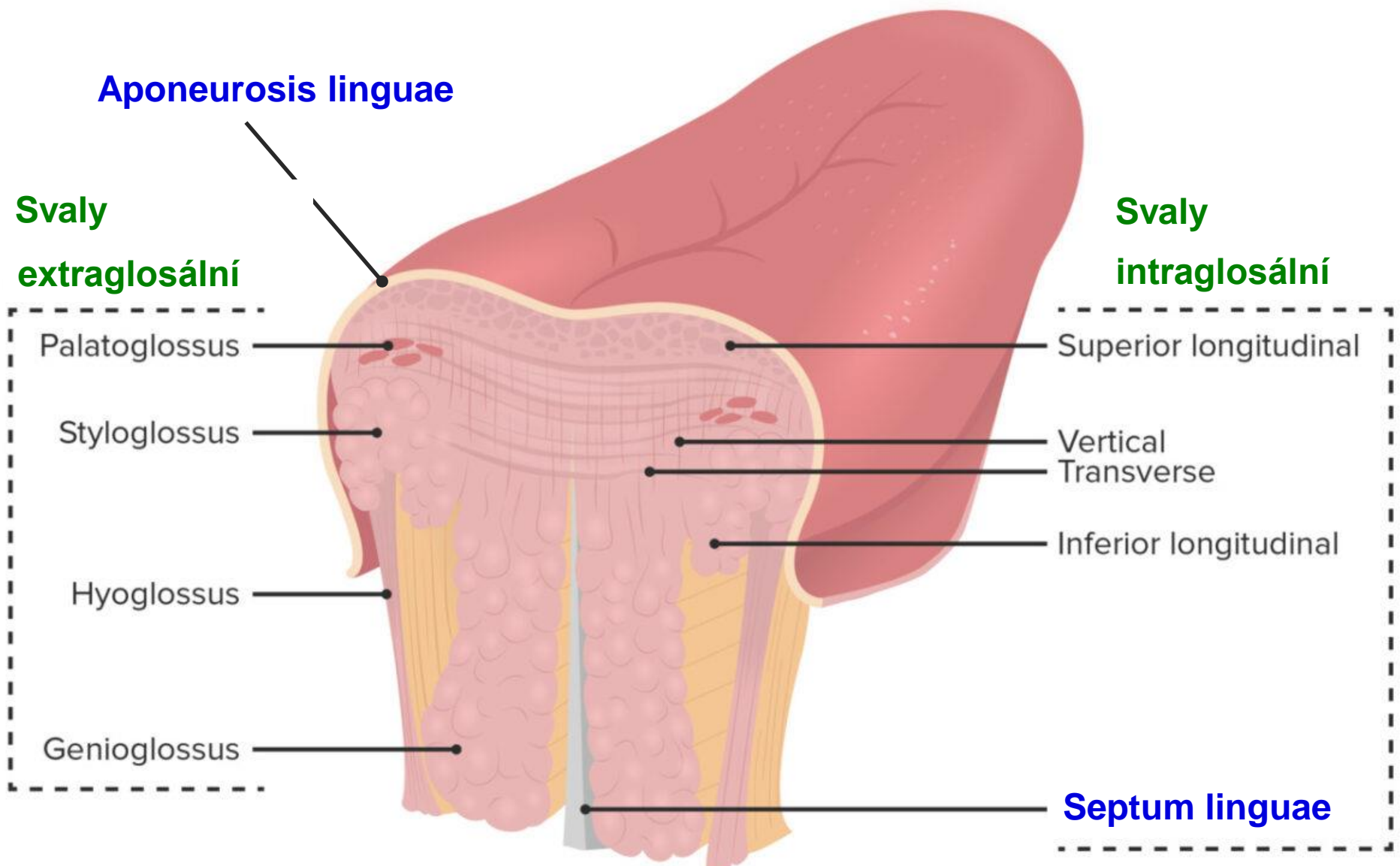
- Eleidin
- Absence slinných žláz, vlasových folikulů, potních žláz
- Vysoké vazivové papily, kapiláry
- Nervová zakončení, Meissnerova tělíska











**Aponeurosis linguae**

**Svaly extraglosální**

**Svaly intraglosální**

Palatoglossus

Superior longitudinal

Styloglossus

Vertical Transverse

Hyoglossus

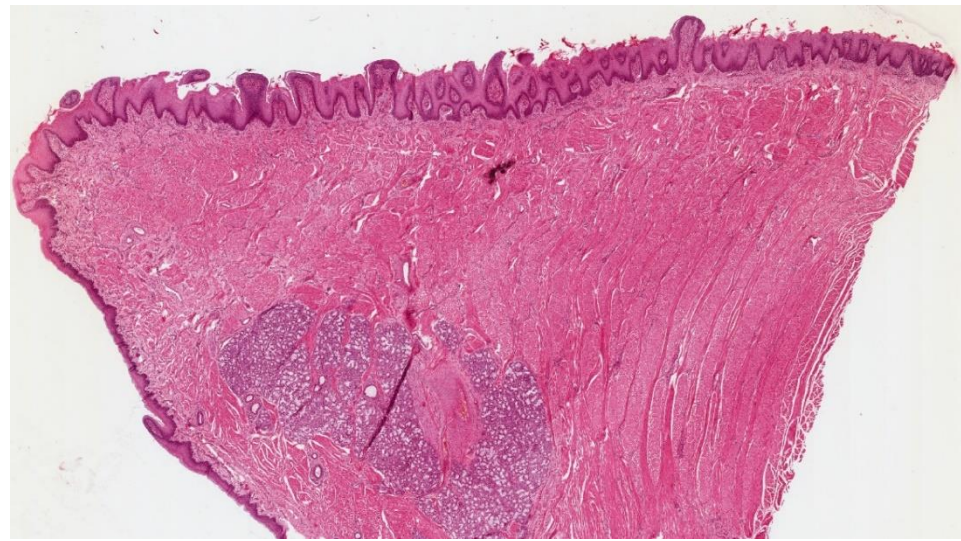
Inferior longitudinal

Genioglossus

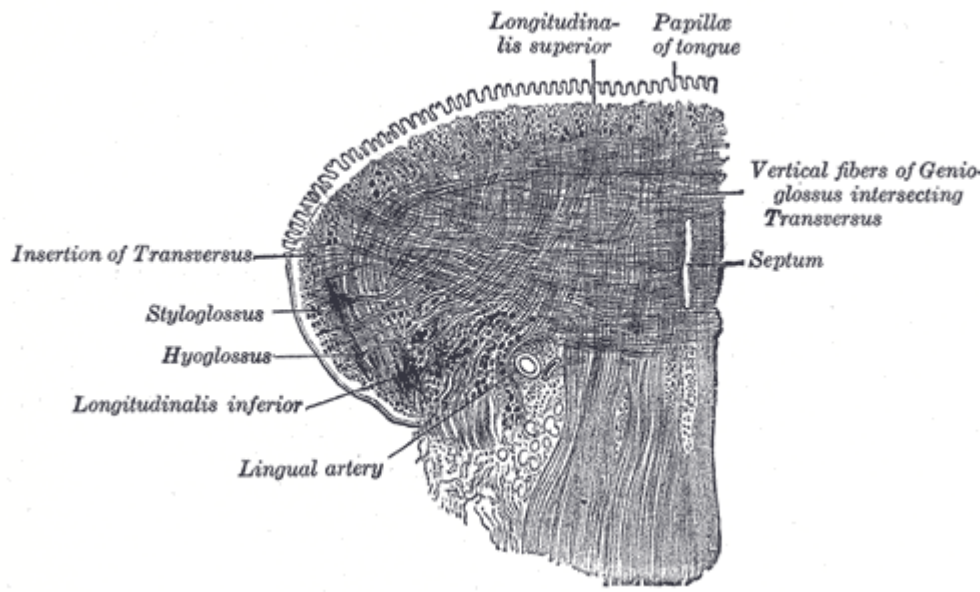

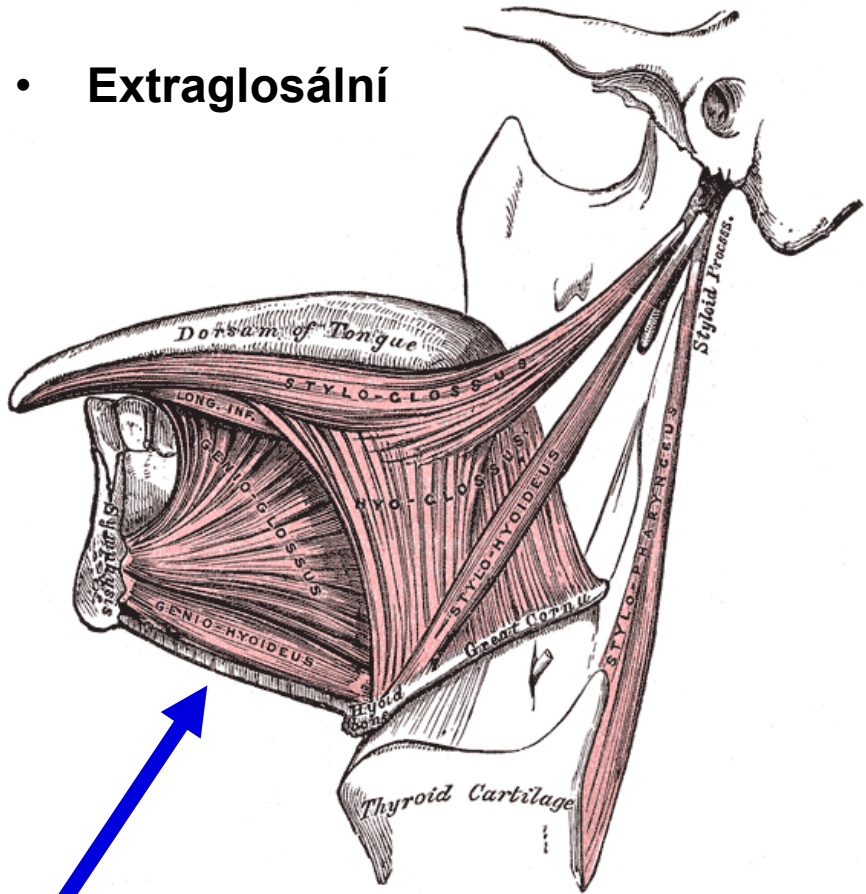
**Septum linguae**

# JAZYK – SVALY A ÚPONY

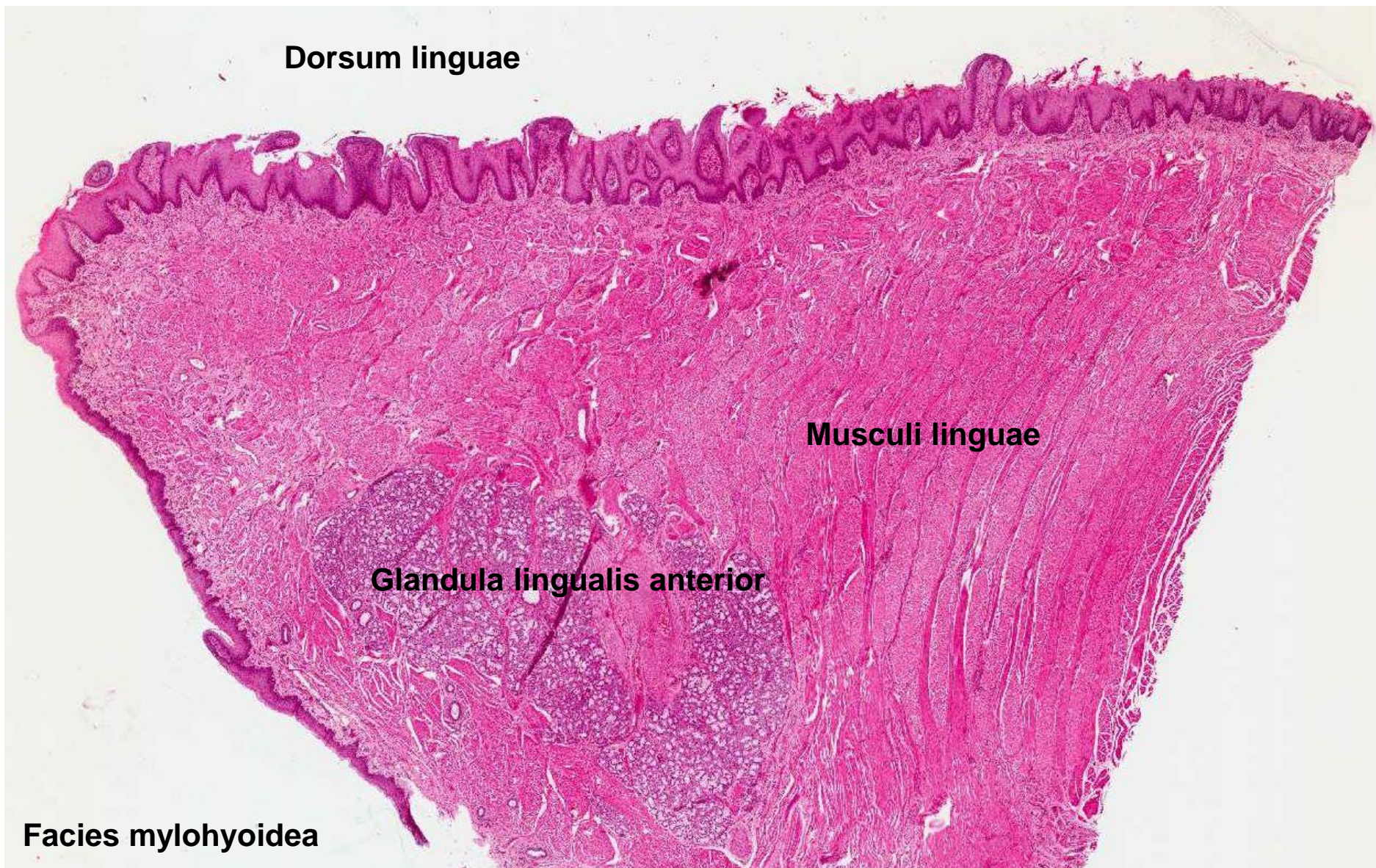
- Intraglosální



- Extraglosální



# JAZYK – APEX LINGUAE



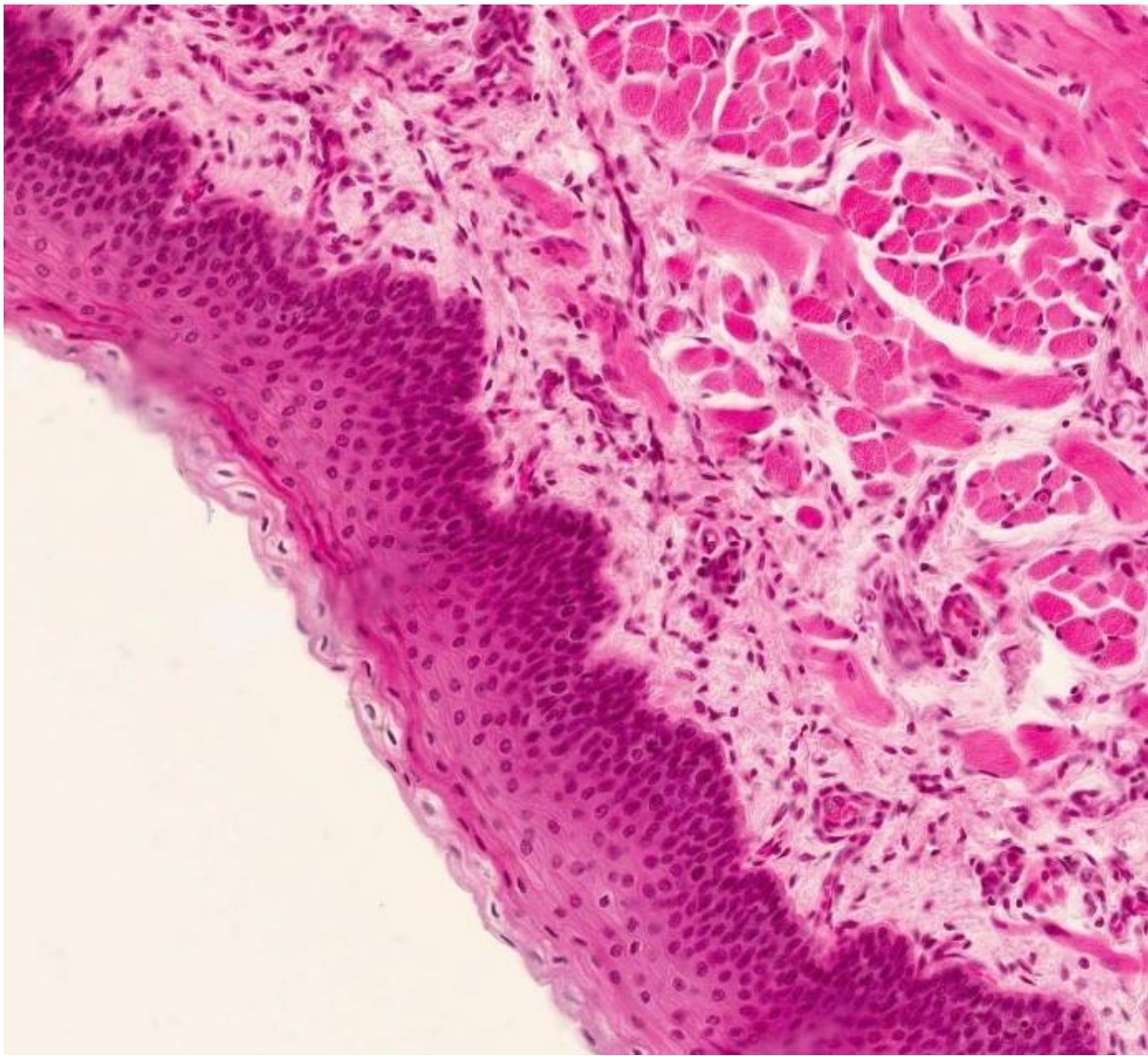
**Dorsum linguae**

**Musculi linguae**

**Glandula lingualis anterior**

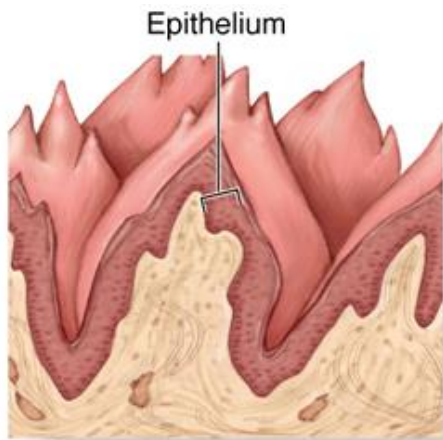
**Facies mylohyoidea**

# JAZYK - FACIES MYLOHYOIDEA

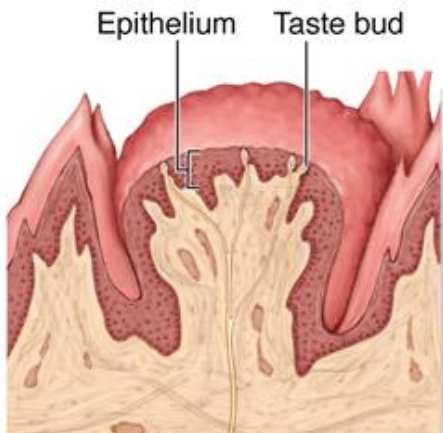


# JAZYK – DORSUM LINGUAE

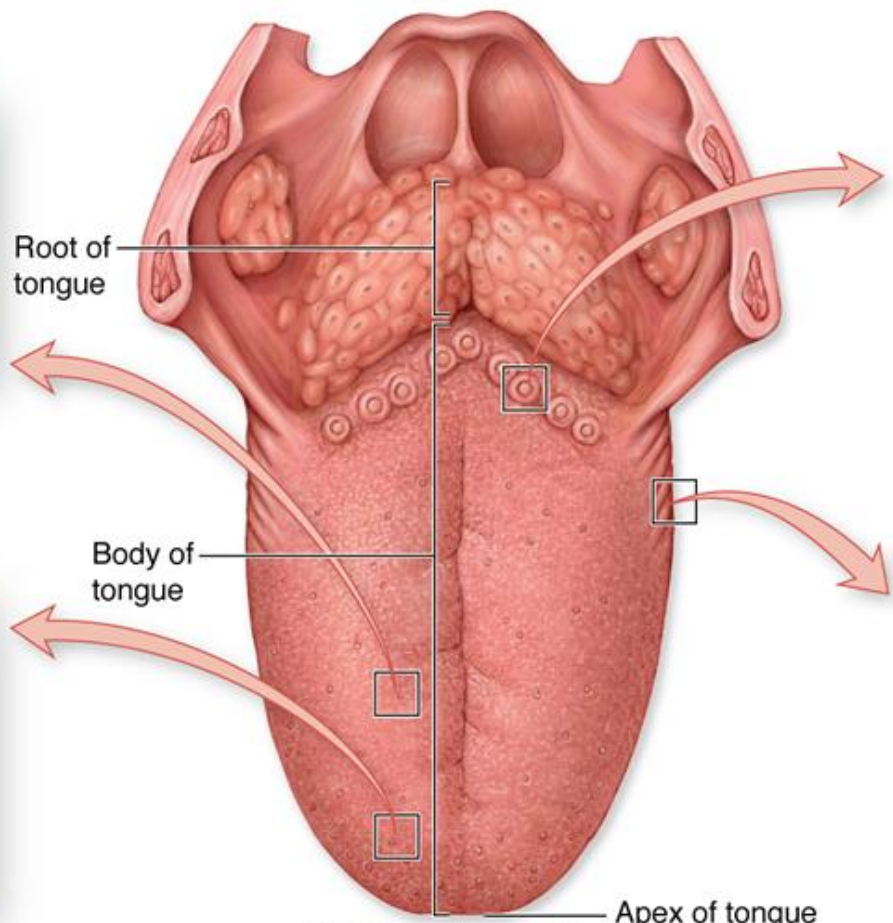
- specializované slizniční struktury - **papily**
- výběžky slizničního vaziva kryté epitelem



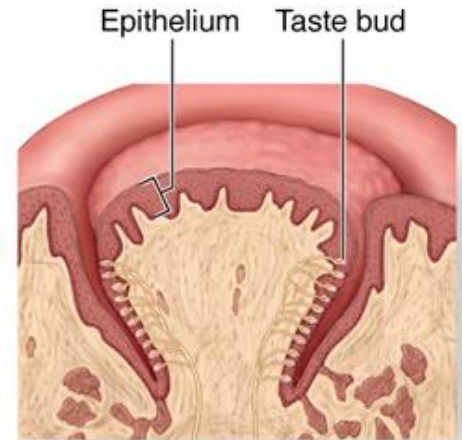
Filiform papilla



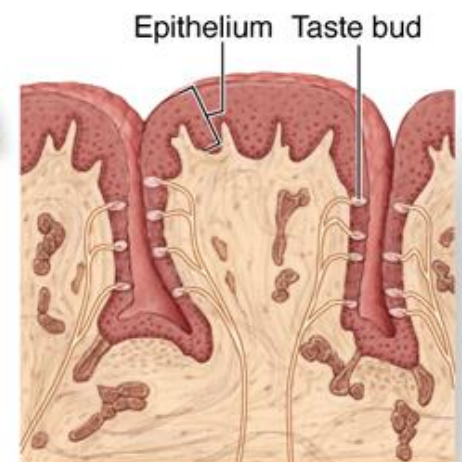
Fungiform papilla



Dorsal surface of tongue



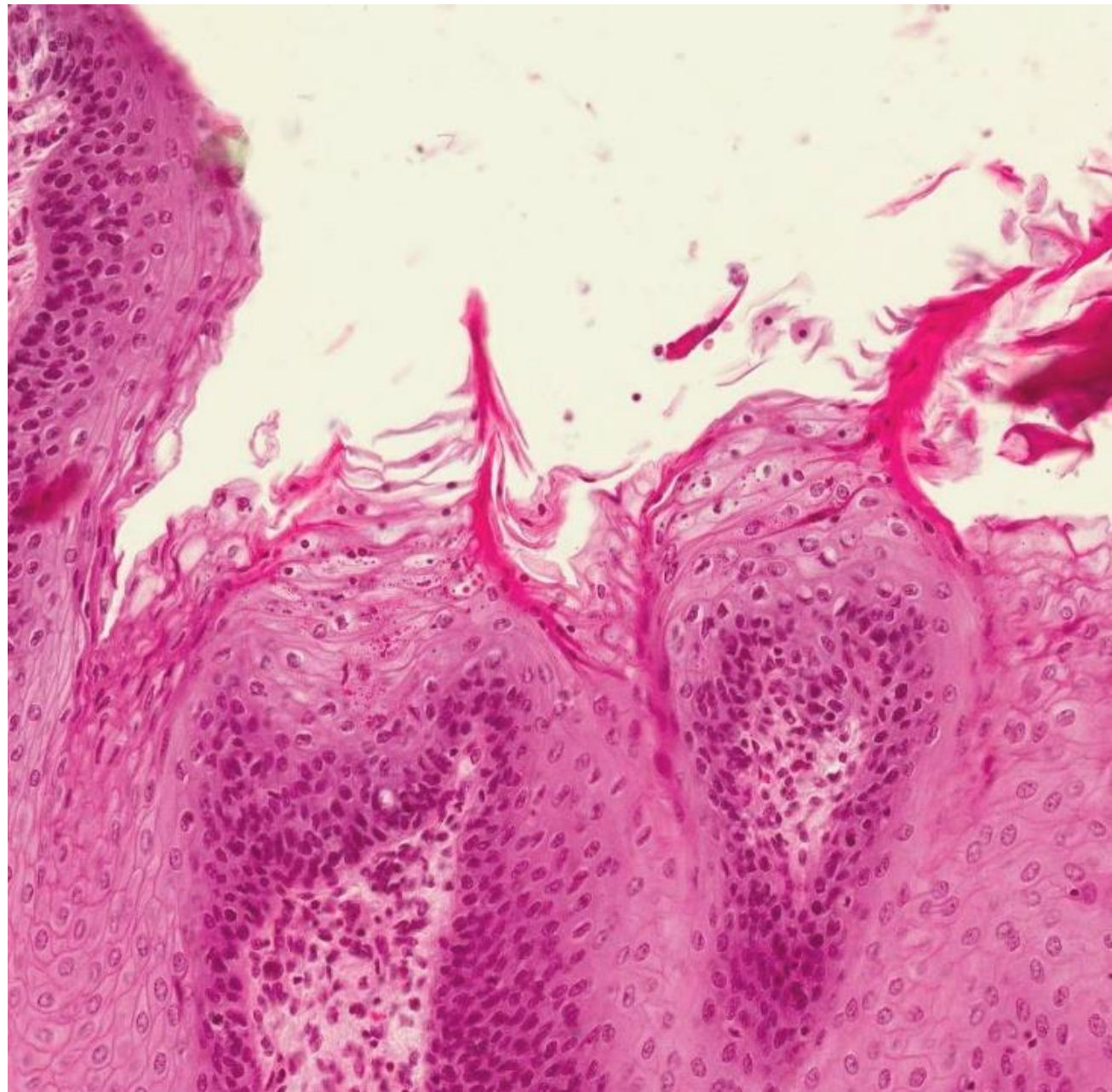
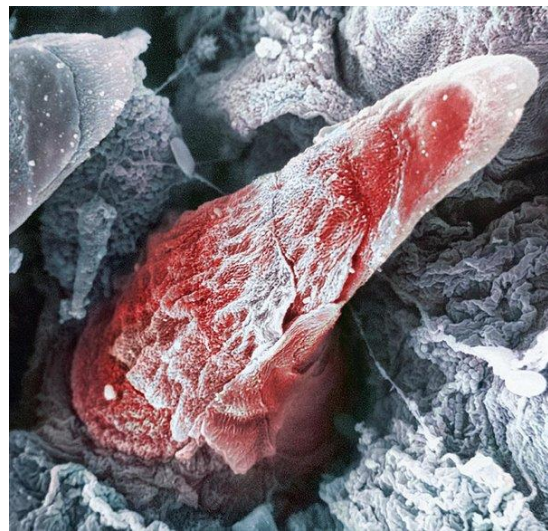
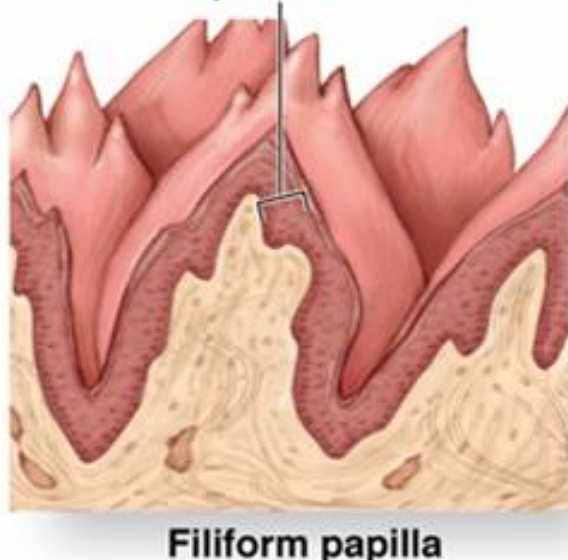
Vallate papilla



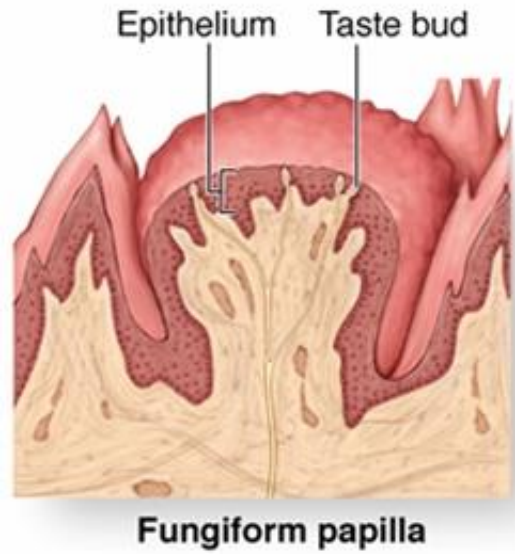
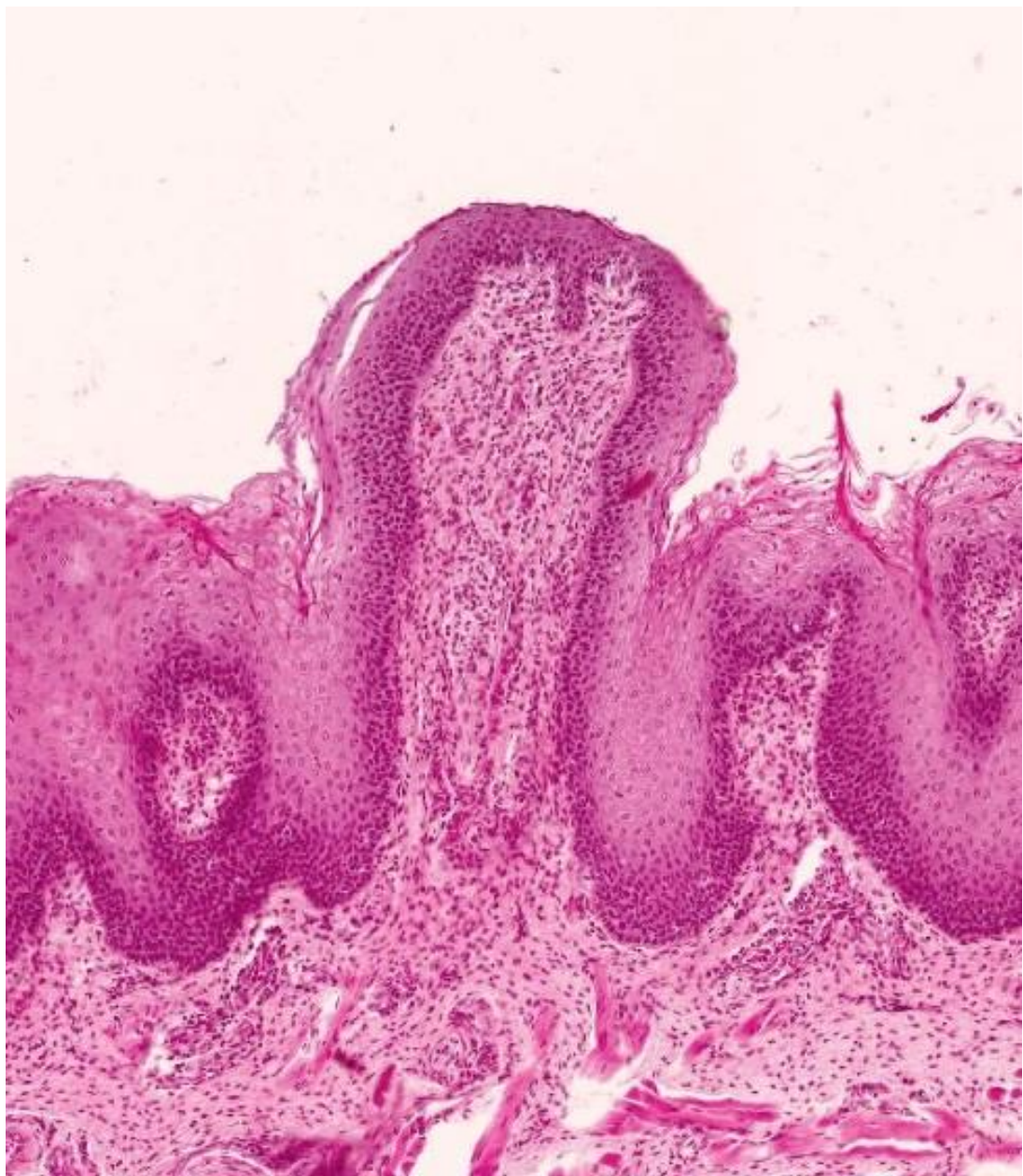Foliate papilla

# JAZYK – FILIFORMNÍ (NITKOVITÉ) PAPILY

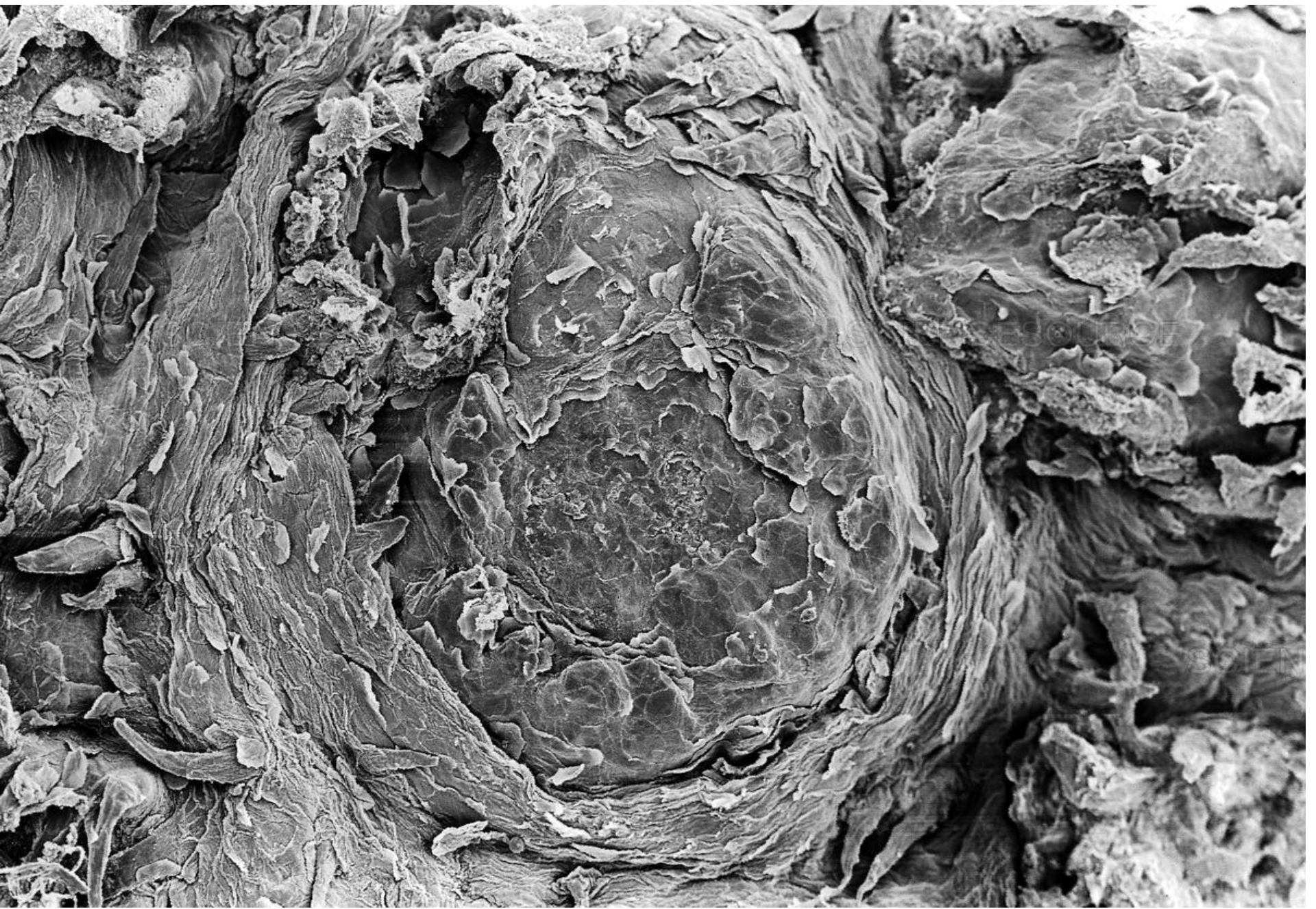
Epithelium



# JAZYK – FUNGIFORMNÍ (HOUBOVITÉ) PAPILY

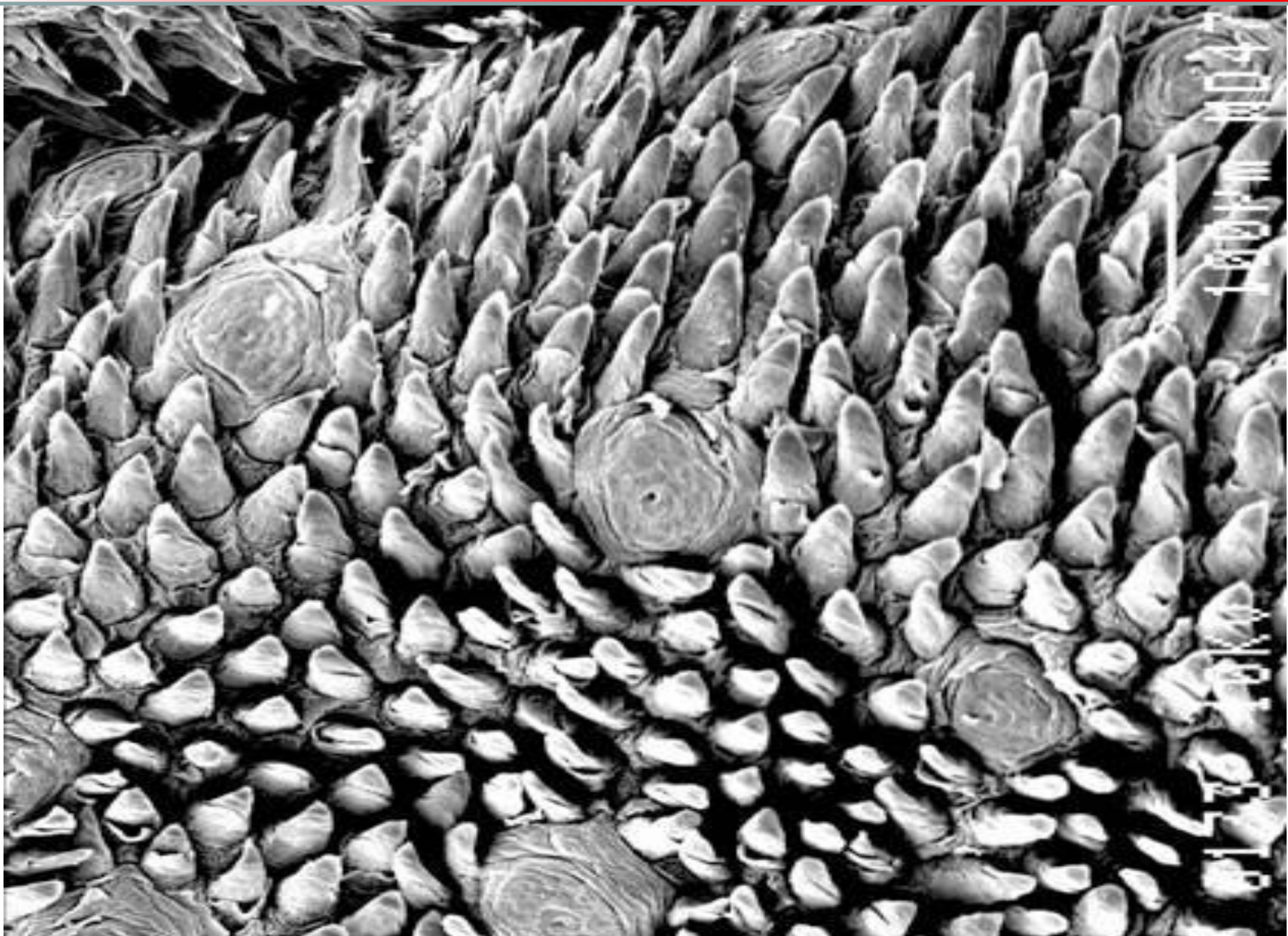


# JAZYK – FUNGIFORMNÍ PAPILY

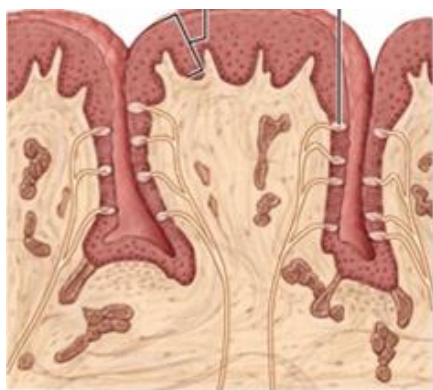




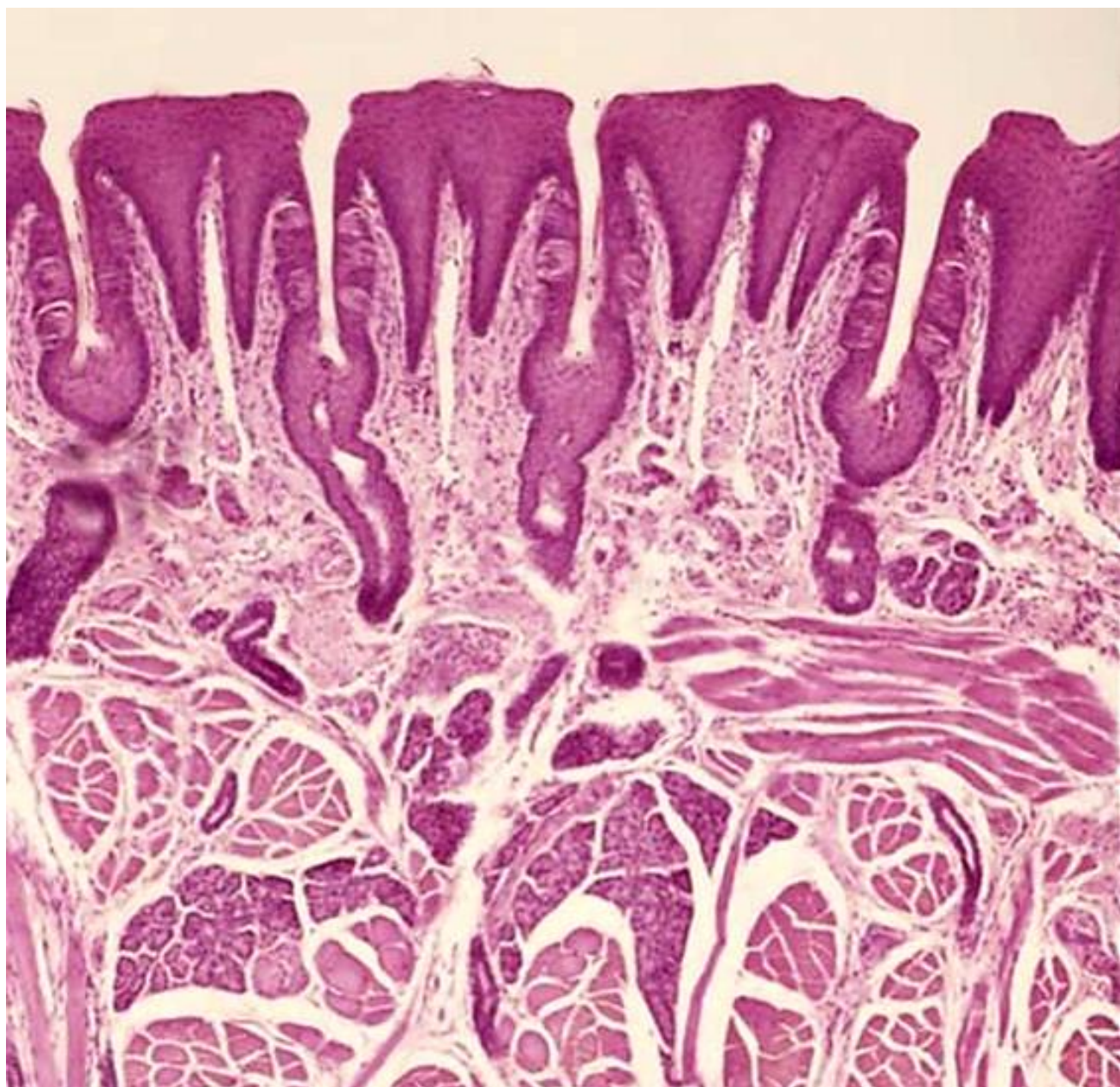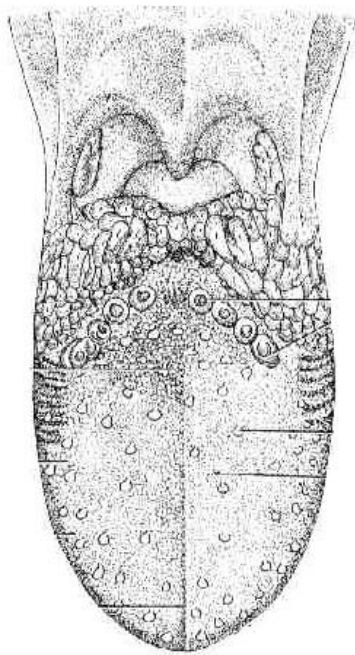
# JAZYK – FILIFORMNÍ A FUNGIFORMNÍ PAPILY



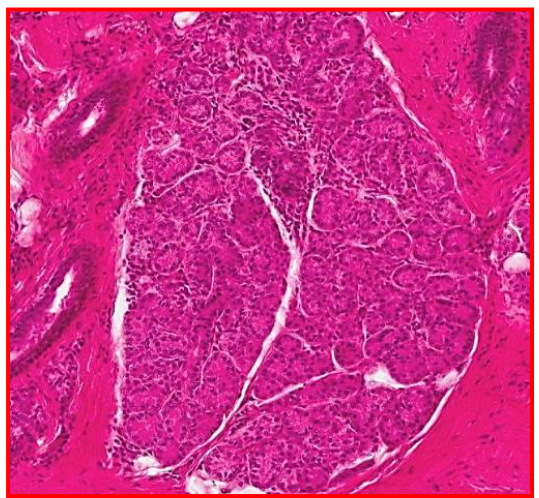
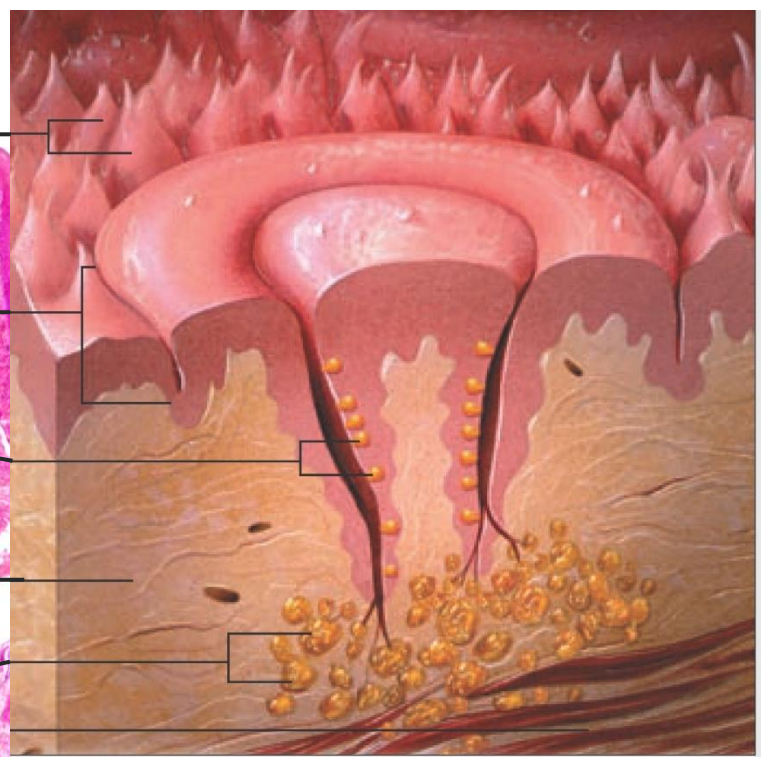
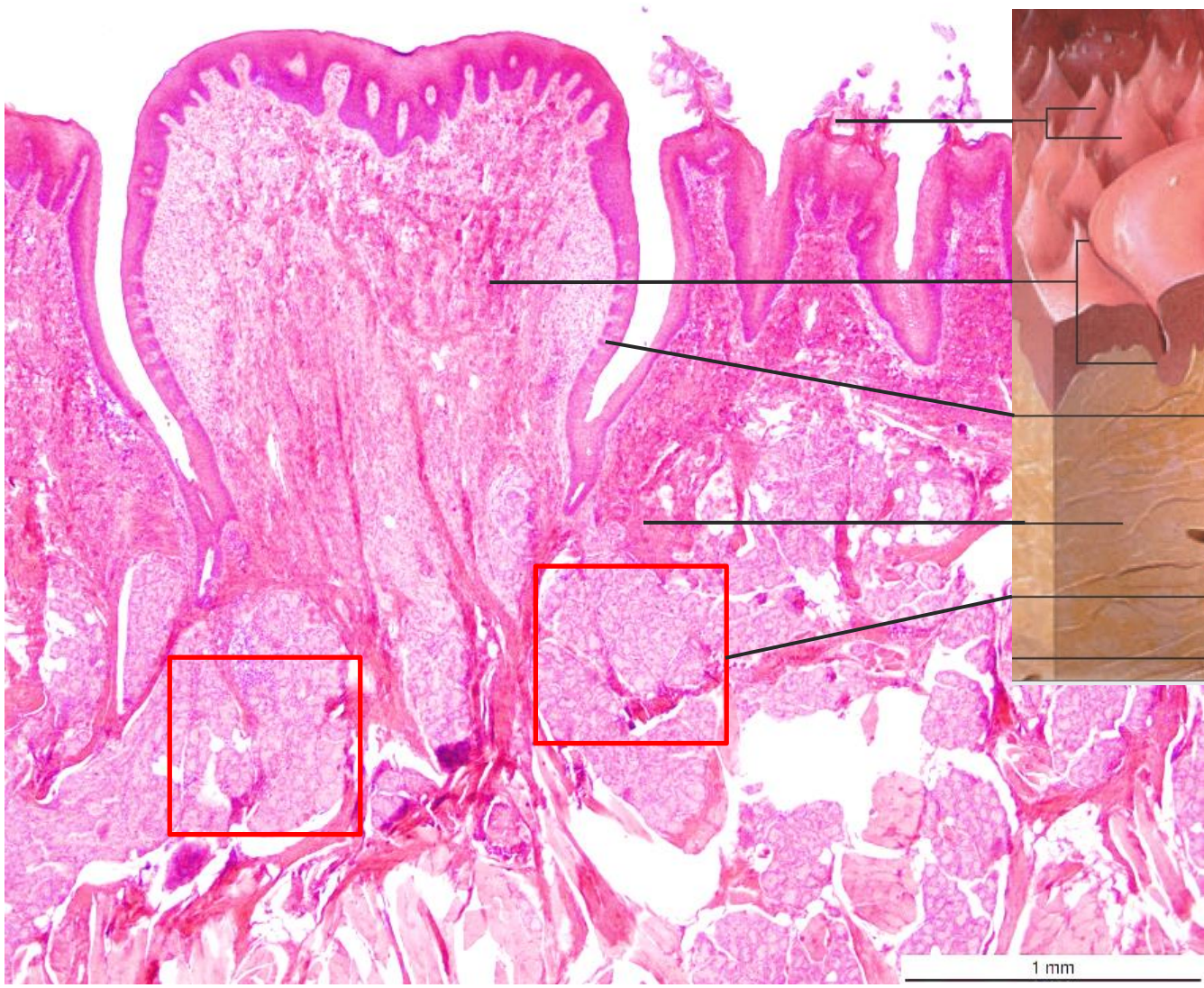
# JAZYK – FOLIÁTNÍ (LISTOVITÉ) PAPILY



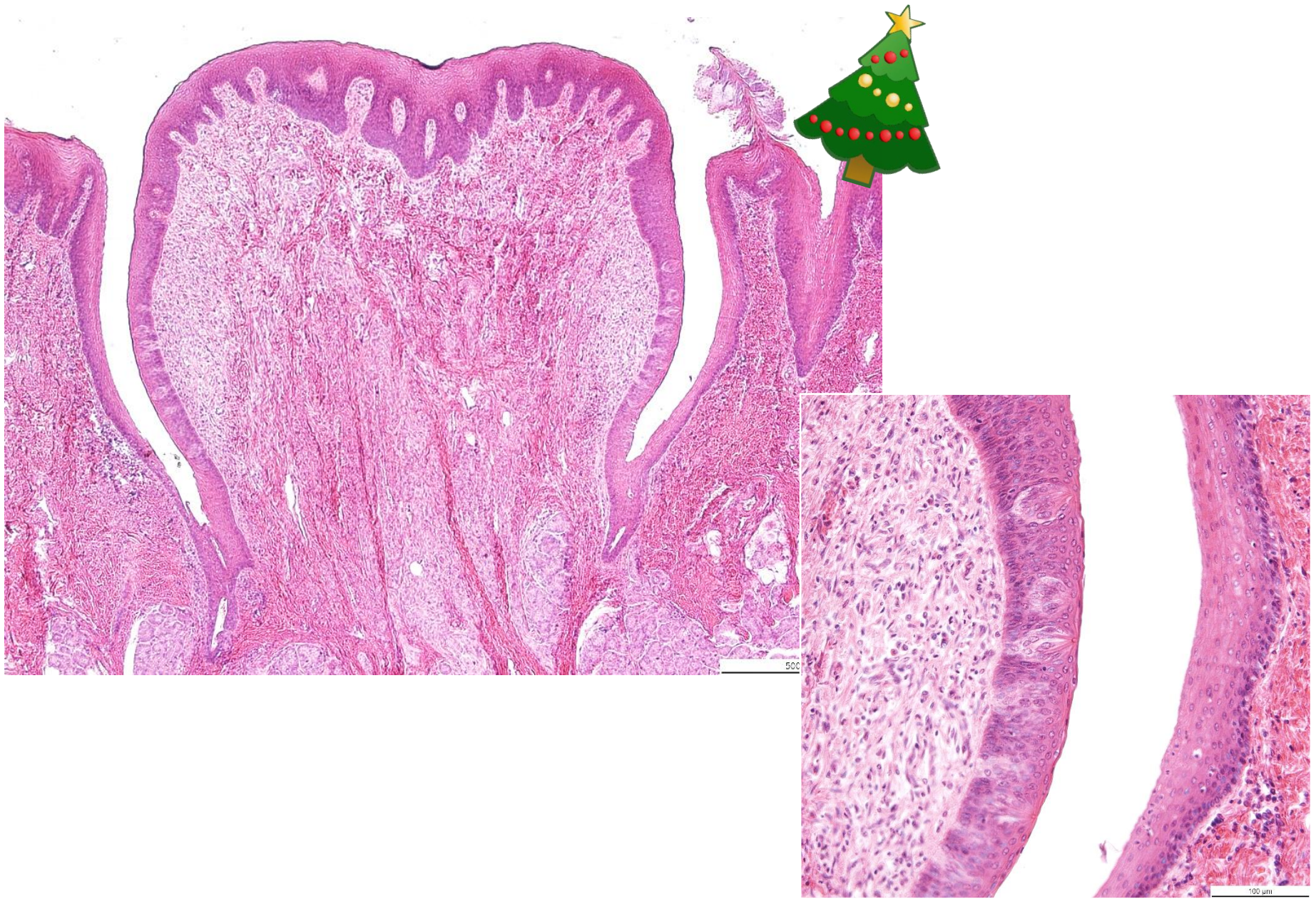
Foliate papilla



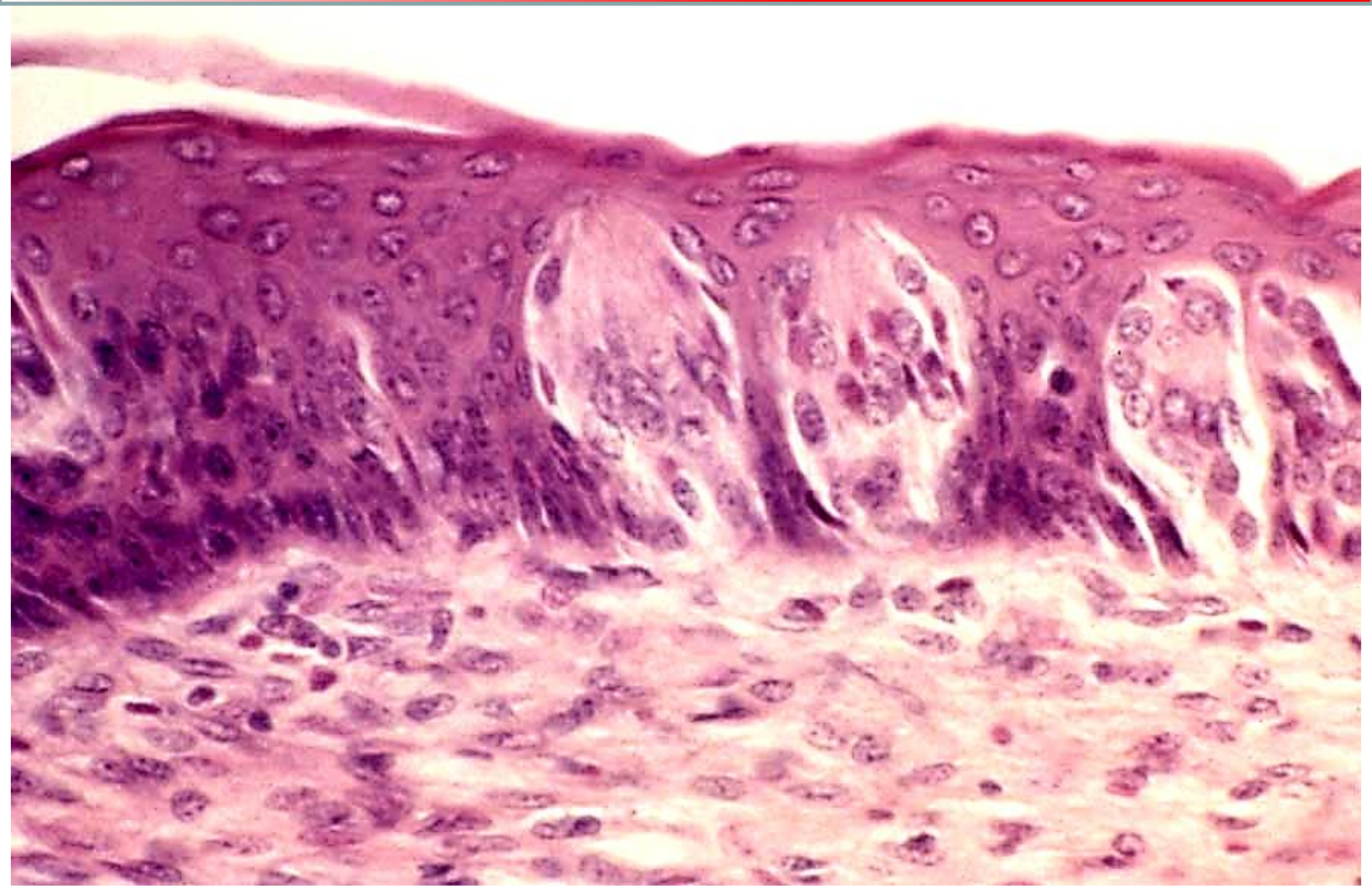
# JAZYK – VALÁTNÍ (HRAZENÉ) PAPILY



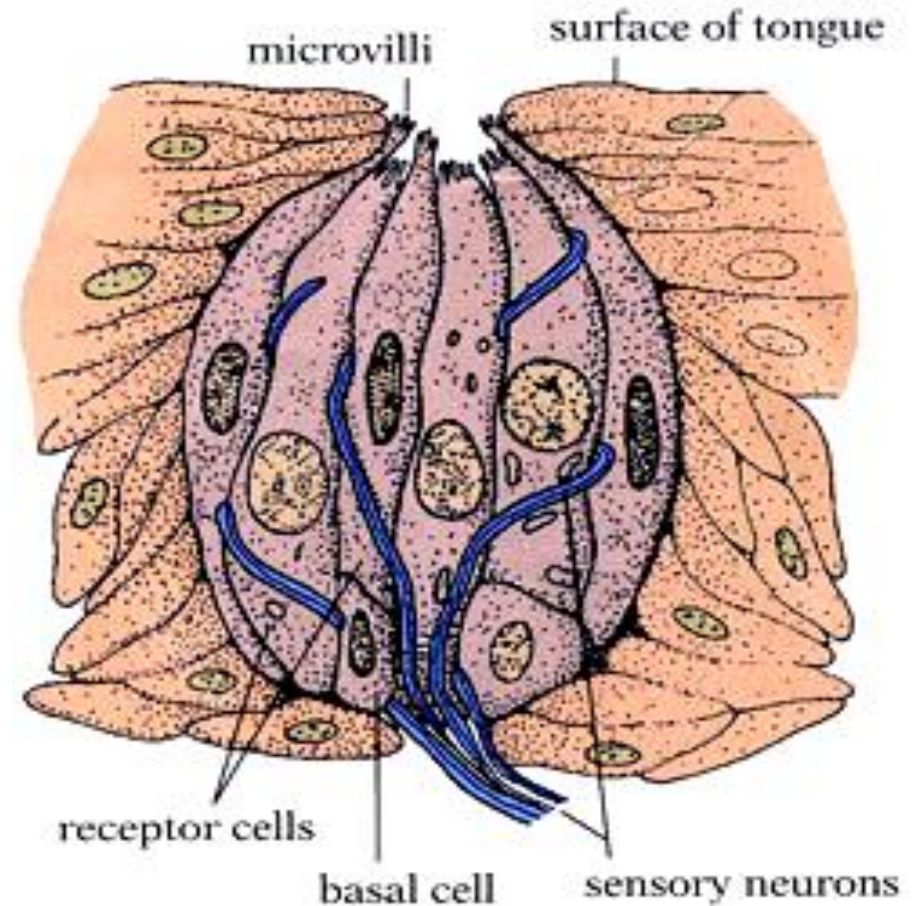
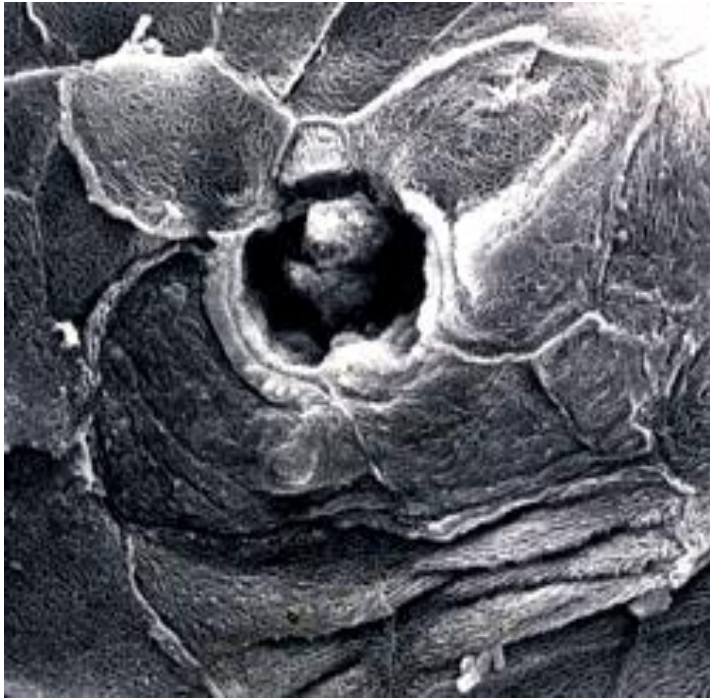# JAZYK – VALÁTNÍ (HRAZENÉ) PAPILY



# JAZYK – CHUŤOVÉ POHÁRKY

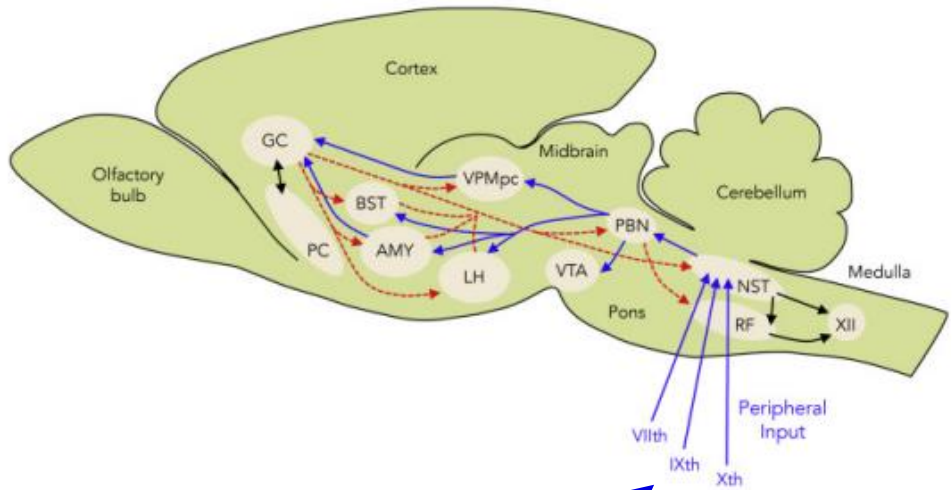
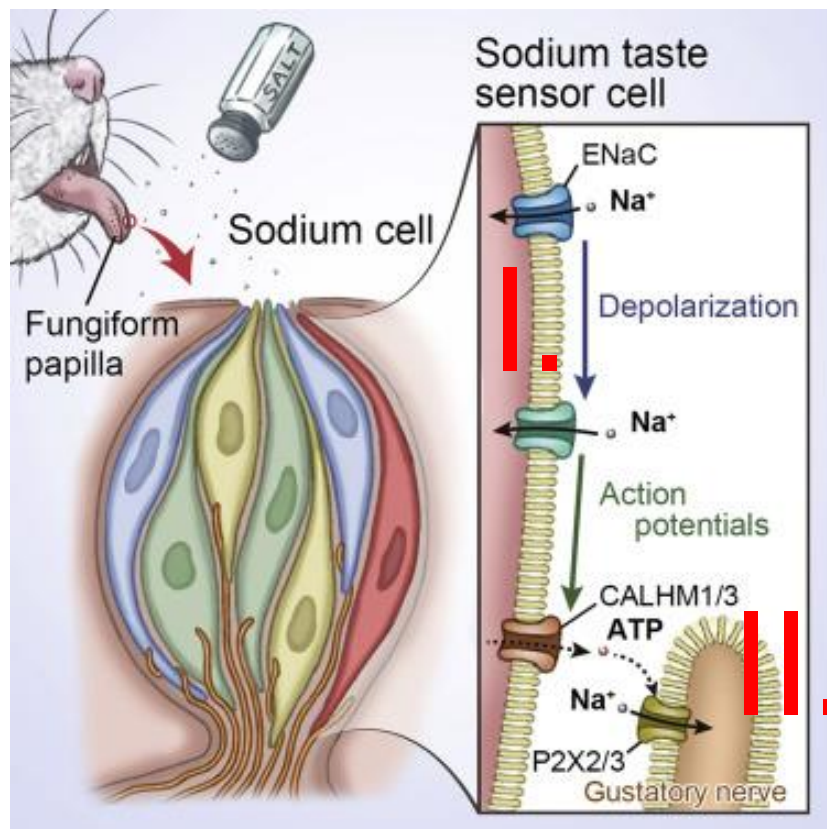


# JAZYK – CHUŤOVÝ POHÁREK



- intraepiteliální struktury
- porus gustatorius
- 2000-8000 v ústní dutině
- 60-80 buněk
- 70-80  $\mu\text{m} \times 30-40 \mu\text{m}$
- mikrokly na smyslových buňkách
- nervová vlákna

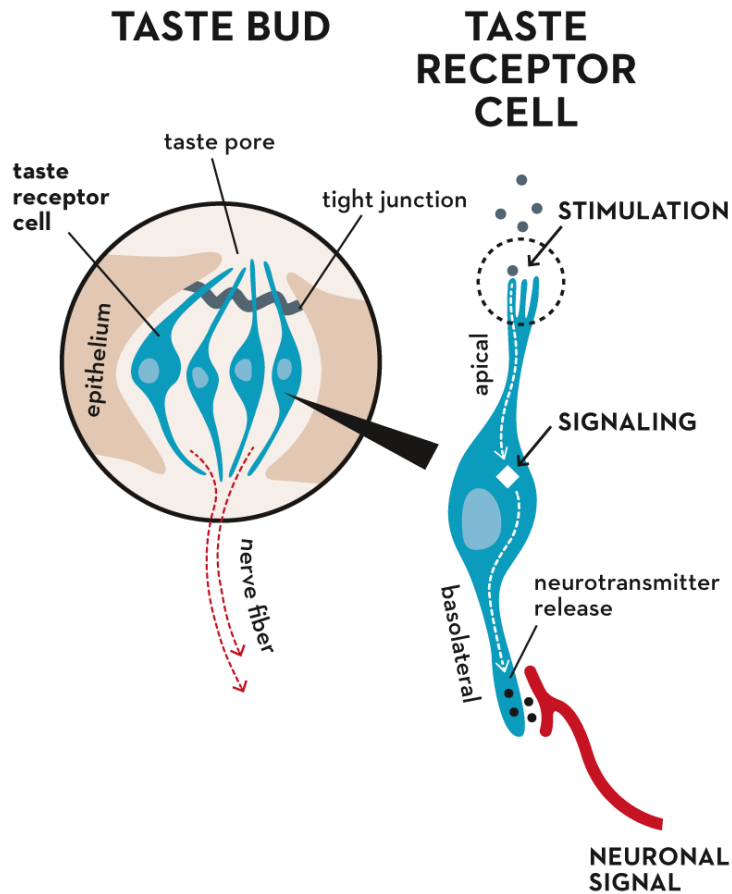
# JAZYK – CHUŤOVÝ POHÁREK



- sekundární smyslový epitel

- n. vagus
- n. facialis
- n. glossopharyngeus

# JAZYK – CHUŤOVÝ POHÁREK

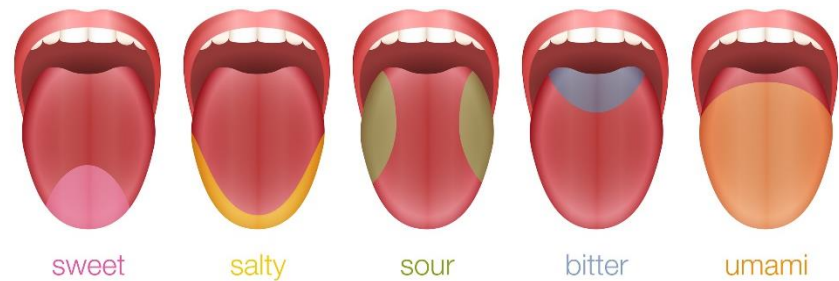


- hořké
- sladké
- umami (glutamát)
- G-proteiny asociované s receptory

- slané
- kyselé
- iontové kanály

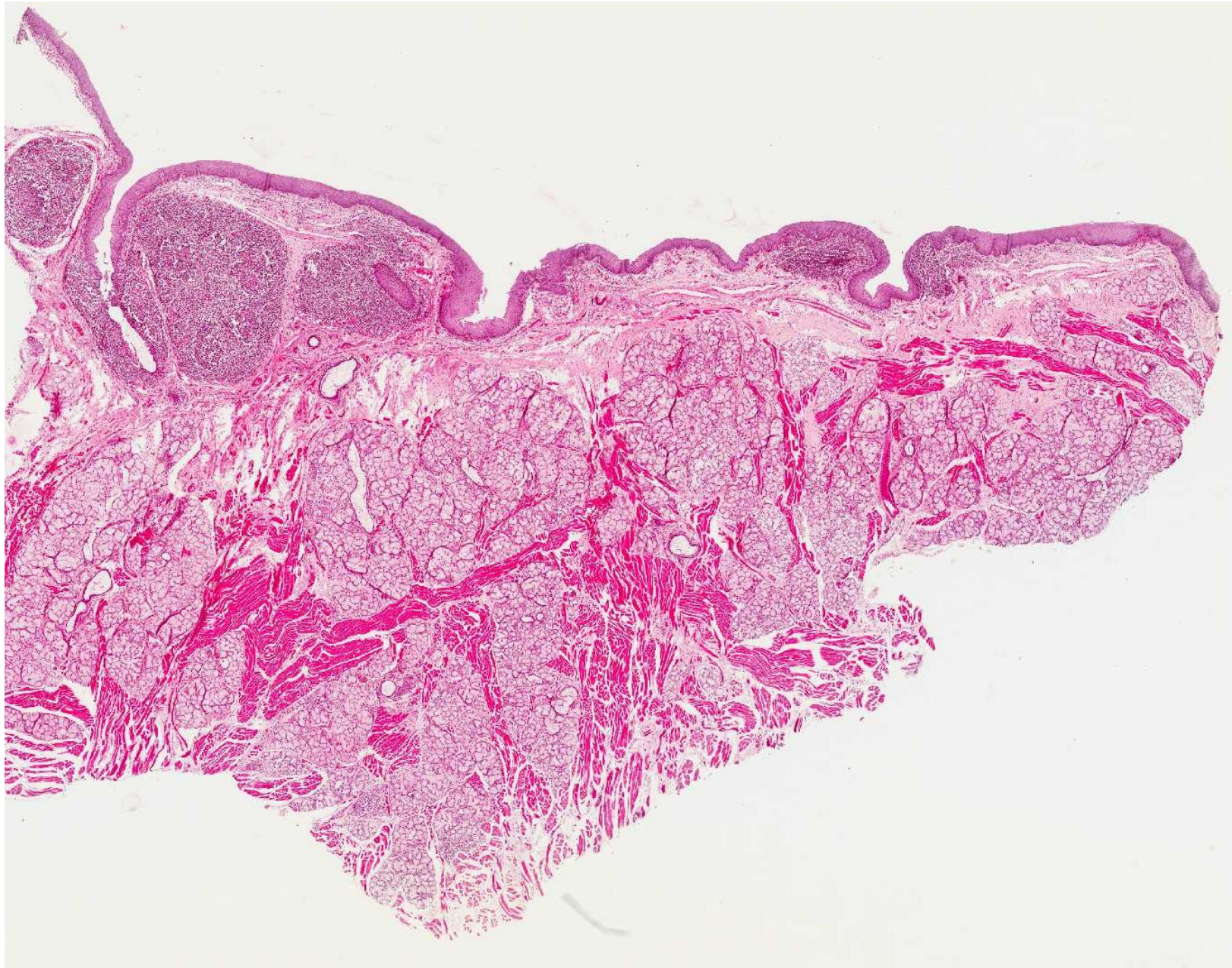
- CD36
- fatty acid transporter

- na vnímání chuti se podílí i čichový epitel

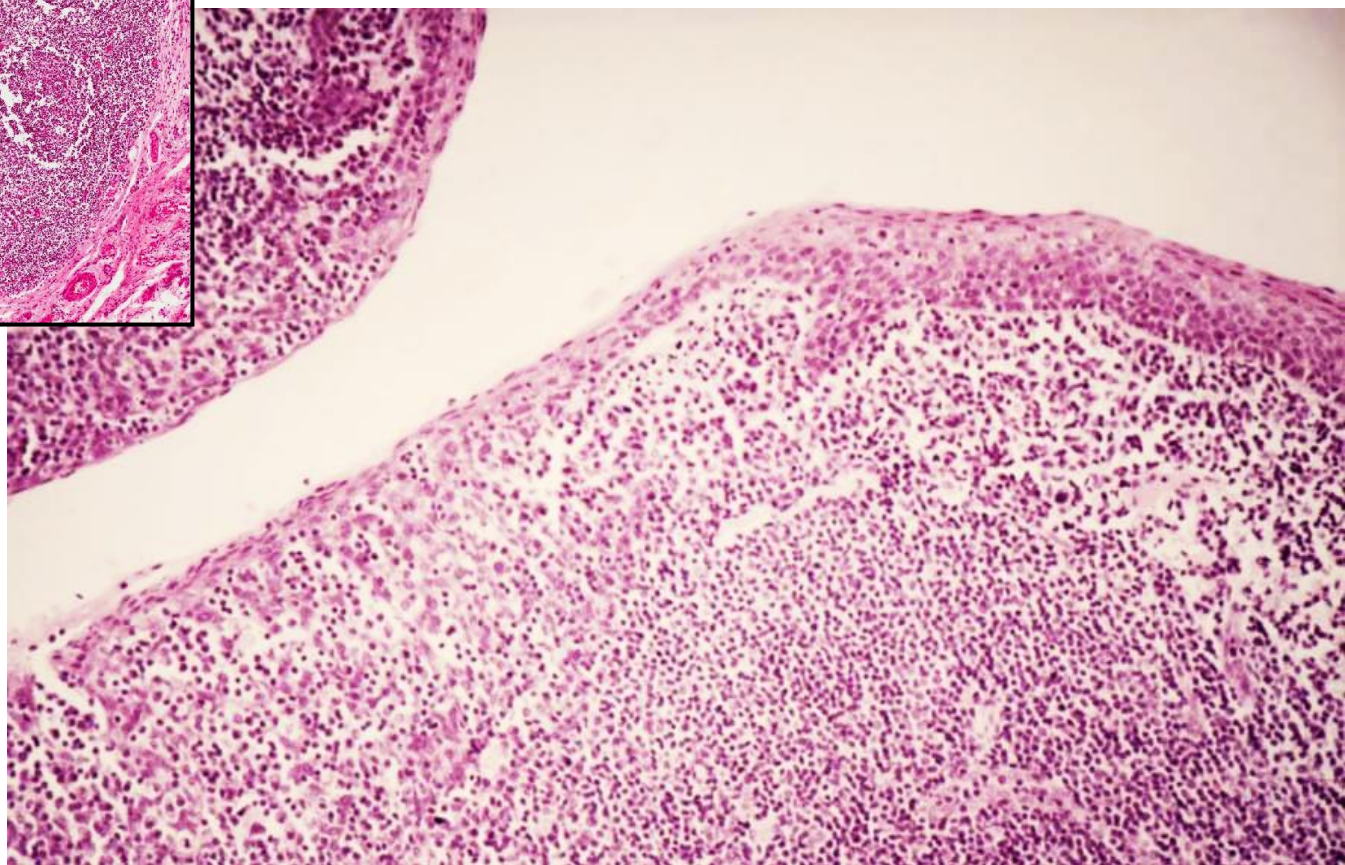
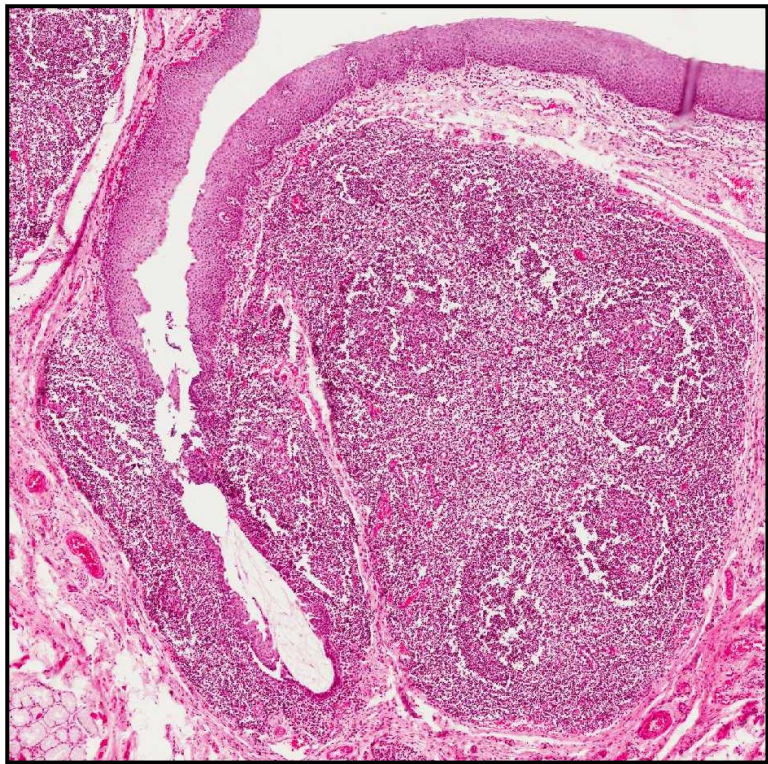




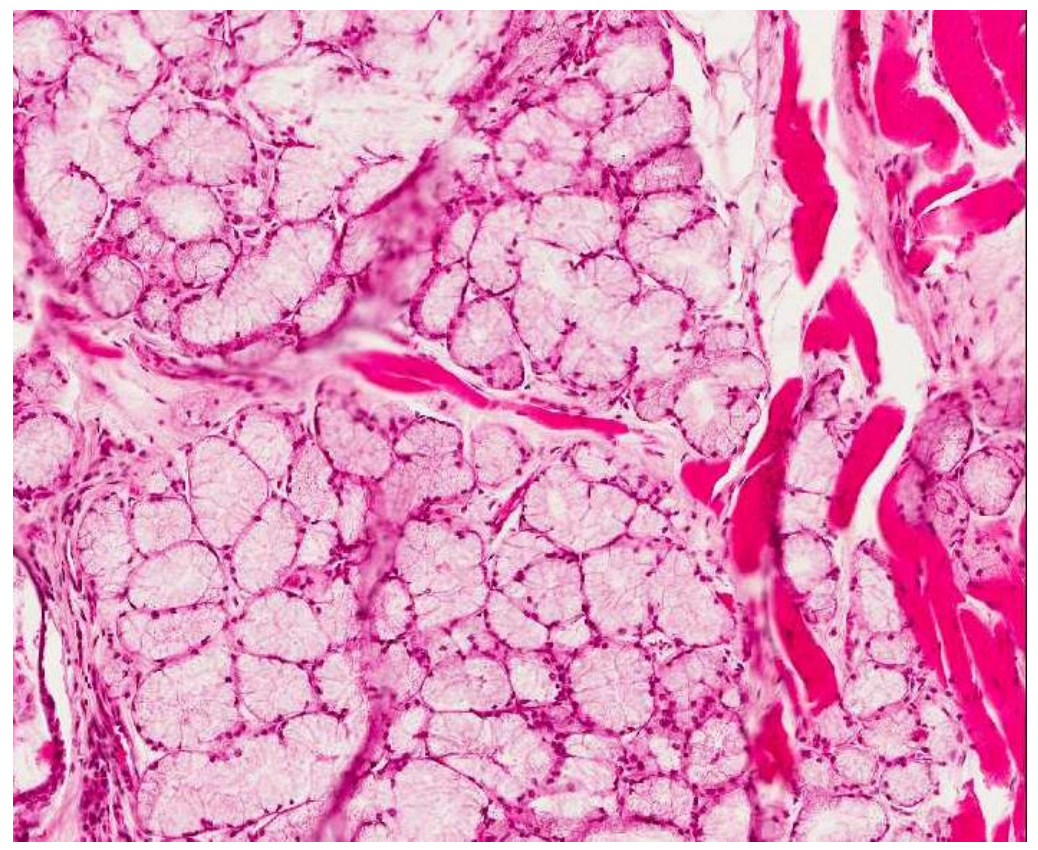
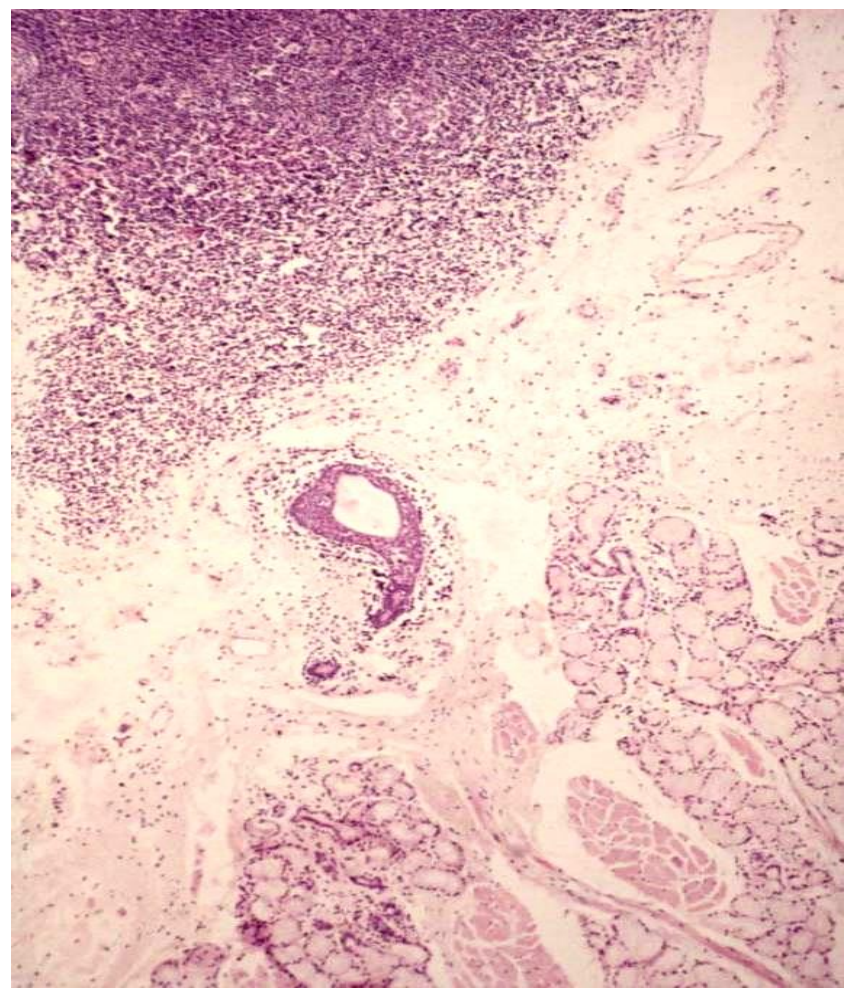
JAZYK – RADIX, TONSILLA LINGUALIS



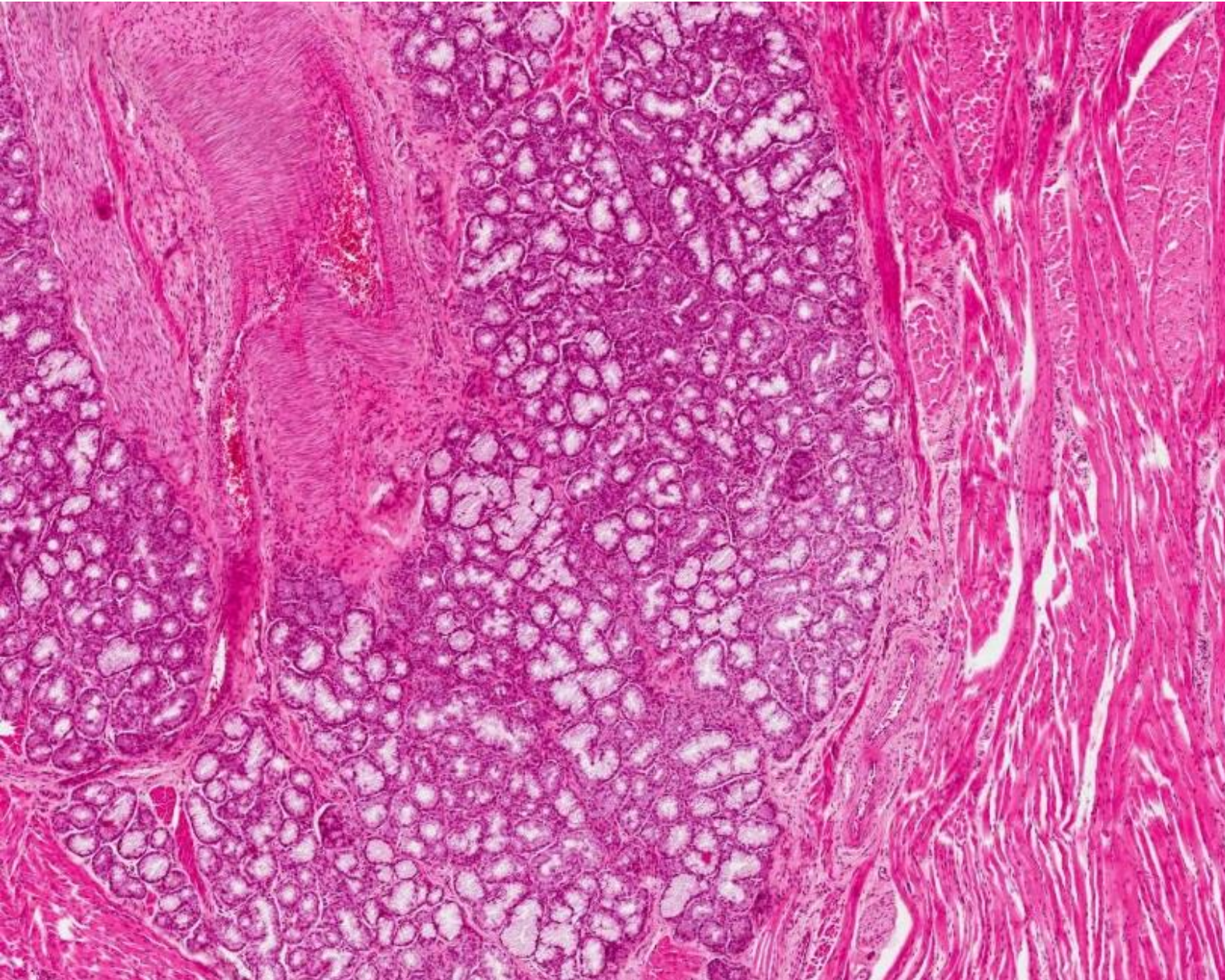
JAZYK – RADIX, TONSILLA LINGUALIS - KRYPTY



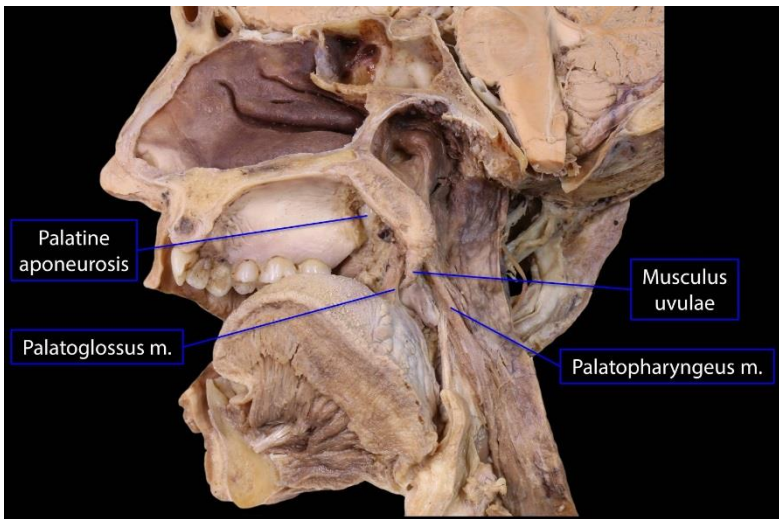
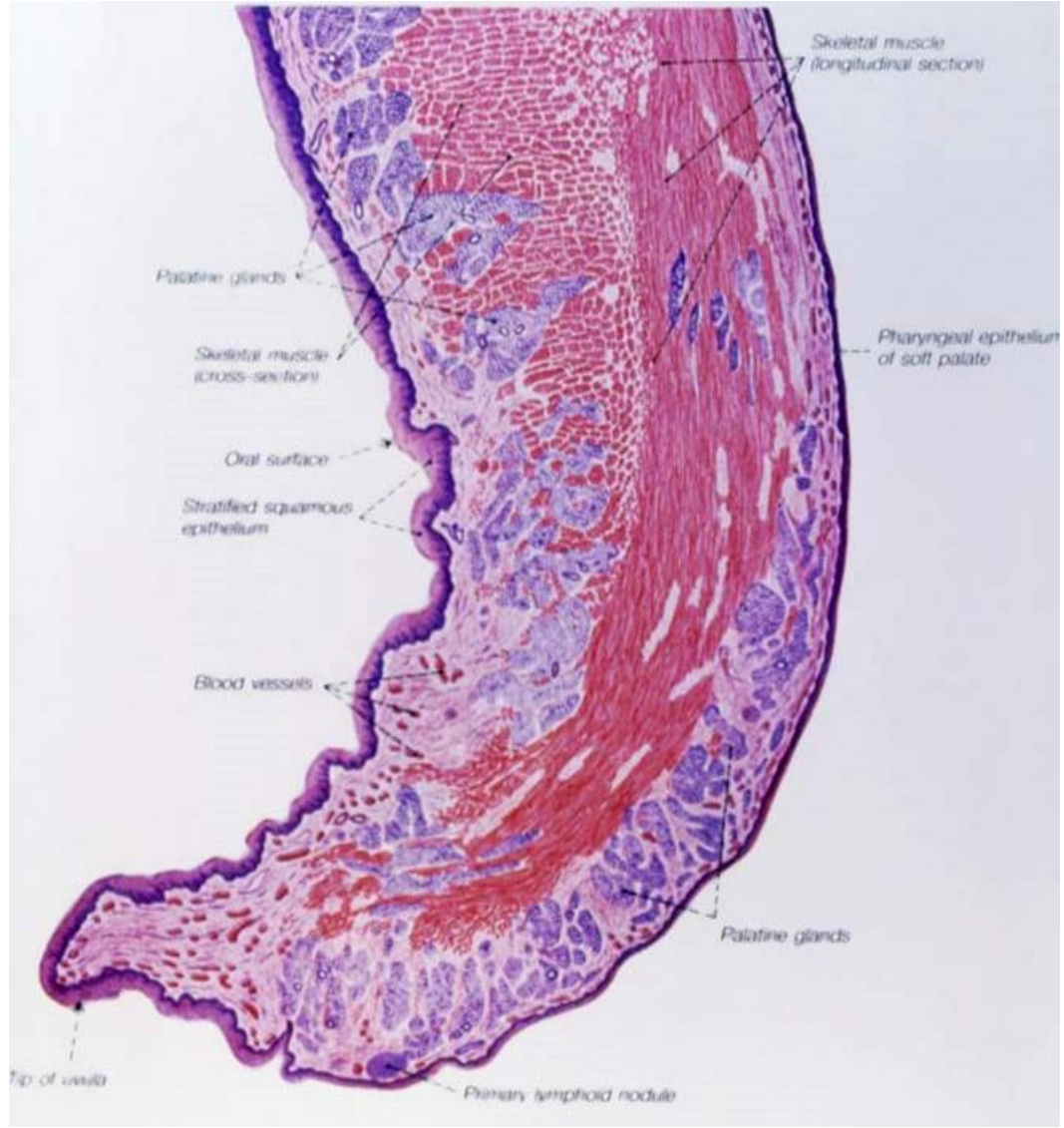
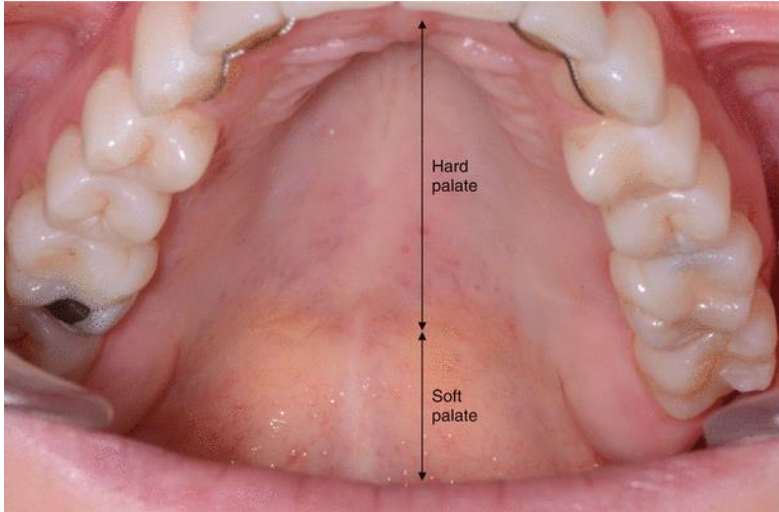
# JAZYK – RADIX, TONSILLA LINGUALIS A WEBEROVY ŽLÁZY



JAZYK - GLL. LINGUALES ANTERIORES (BLANDINI)

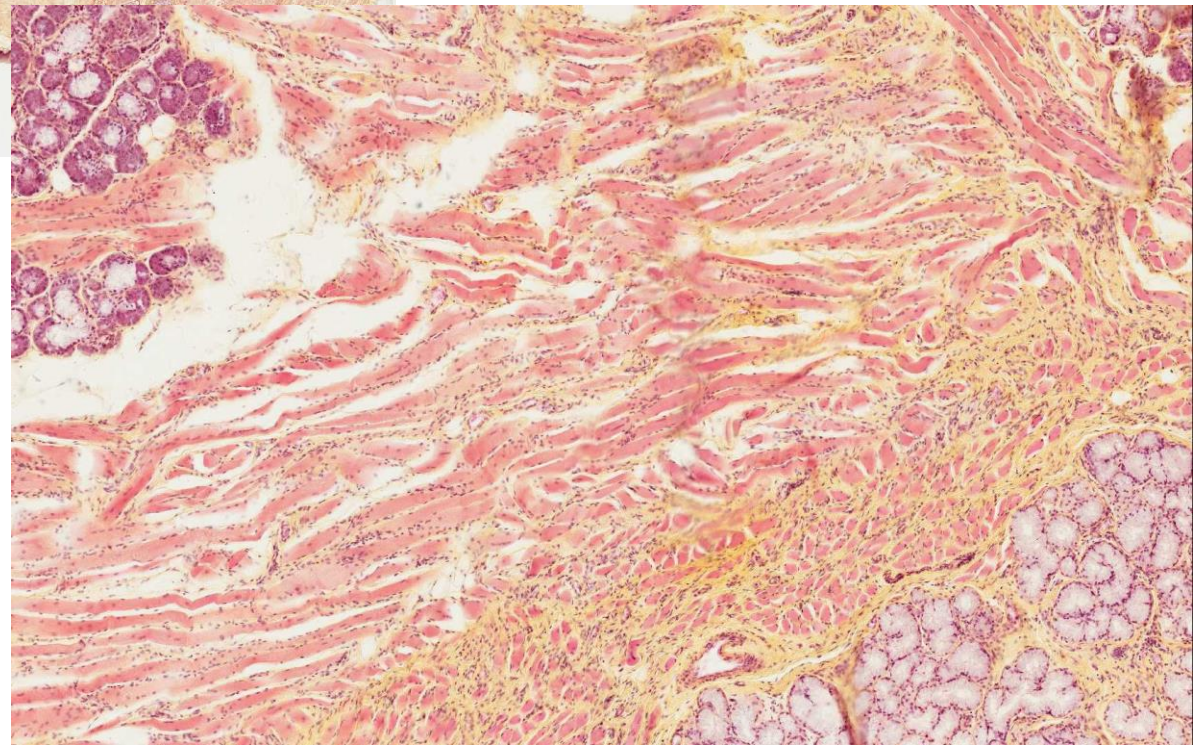
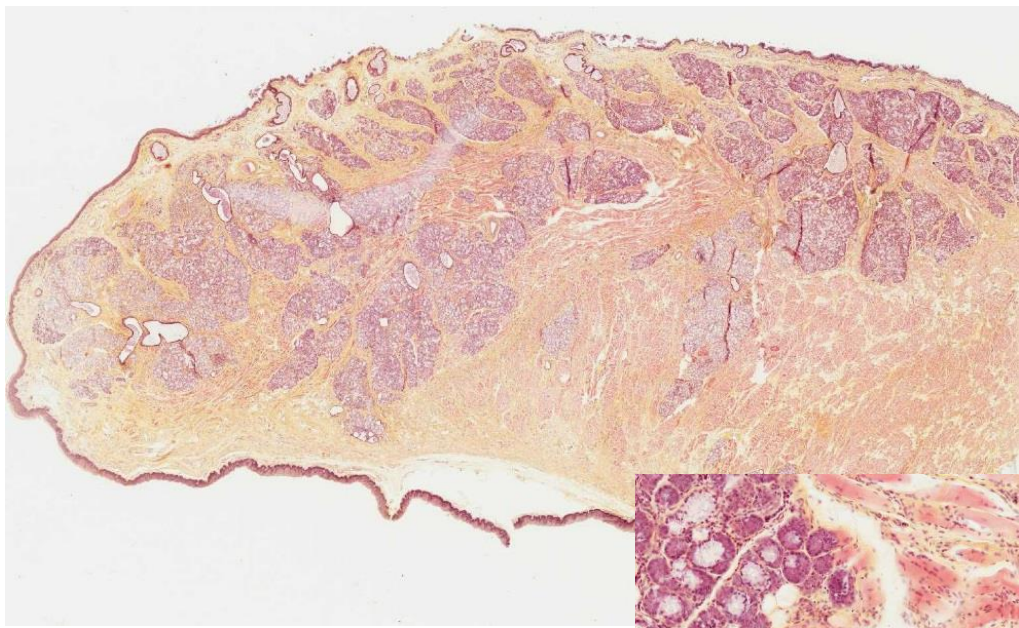


# PATRO

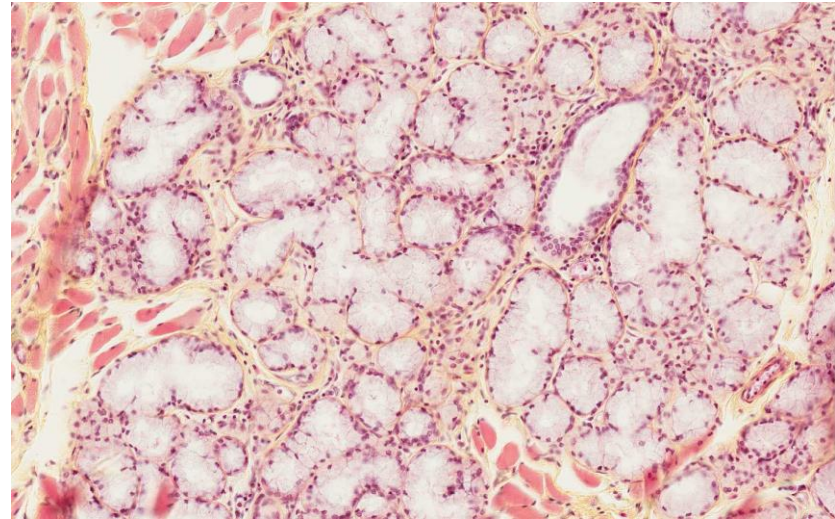
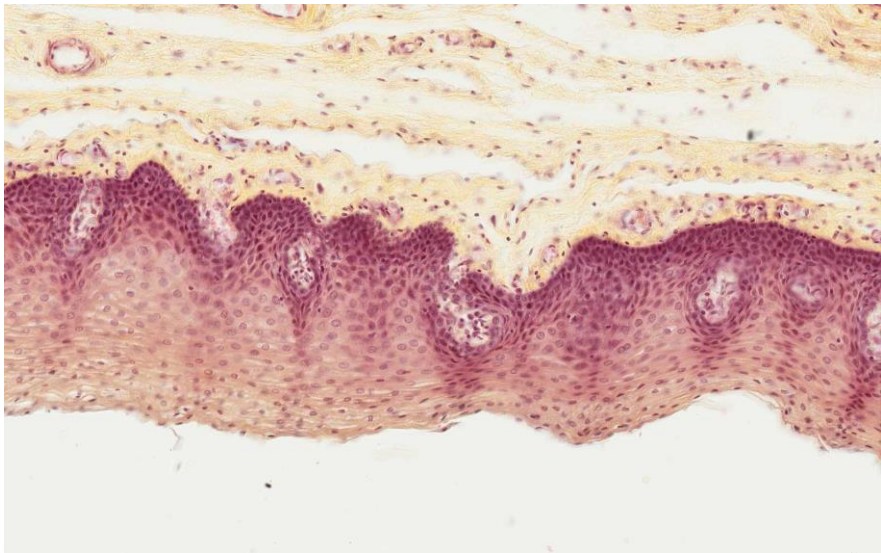
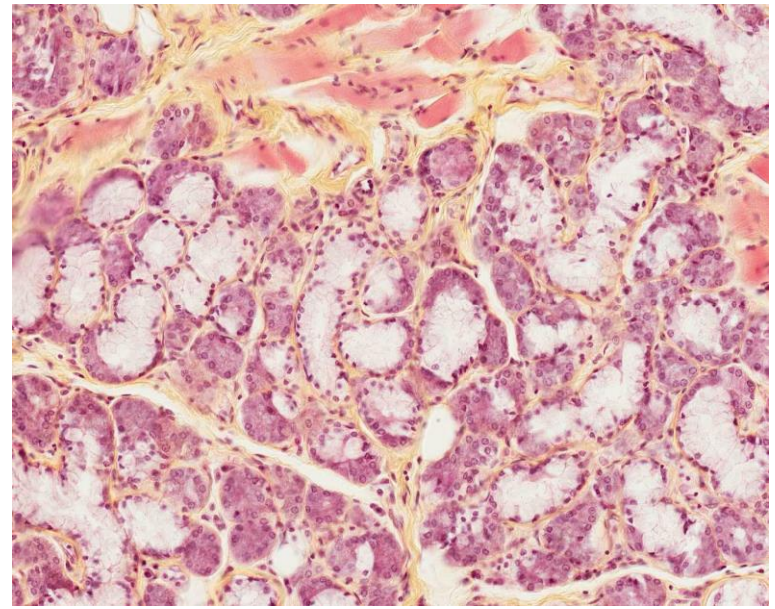
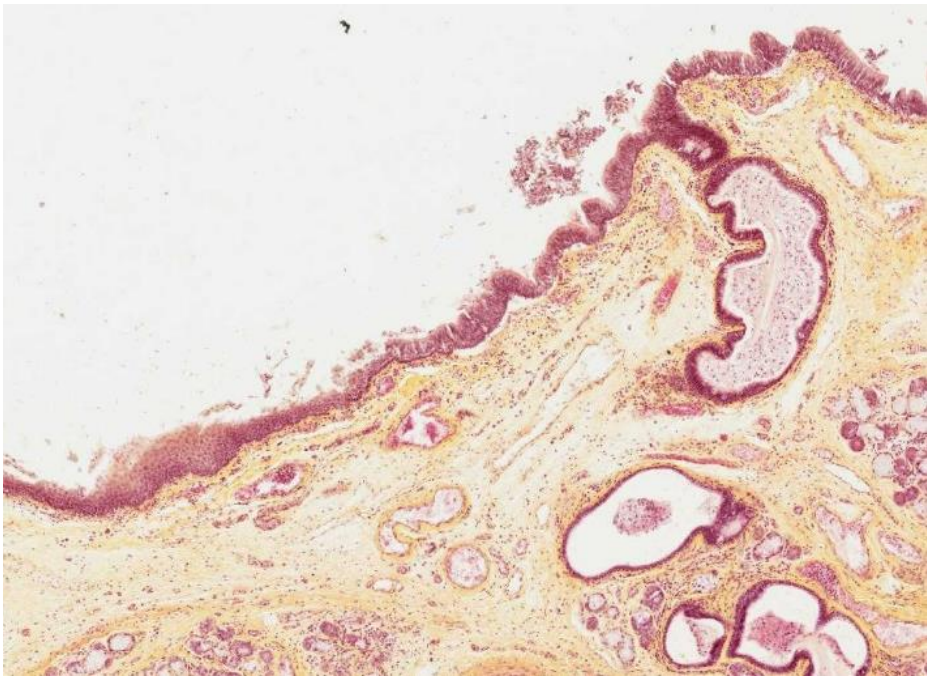


Hemisected head, medial

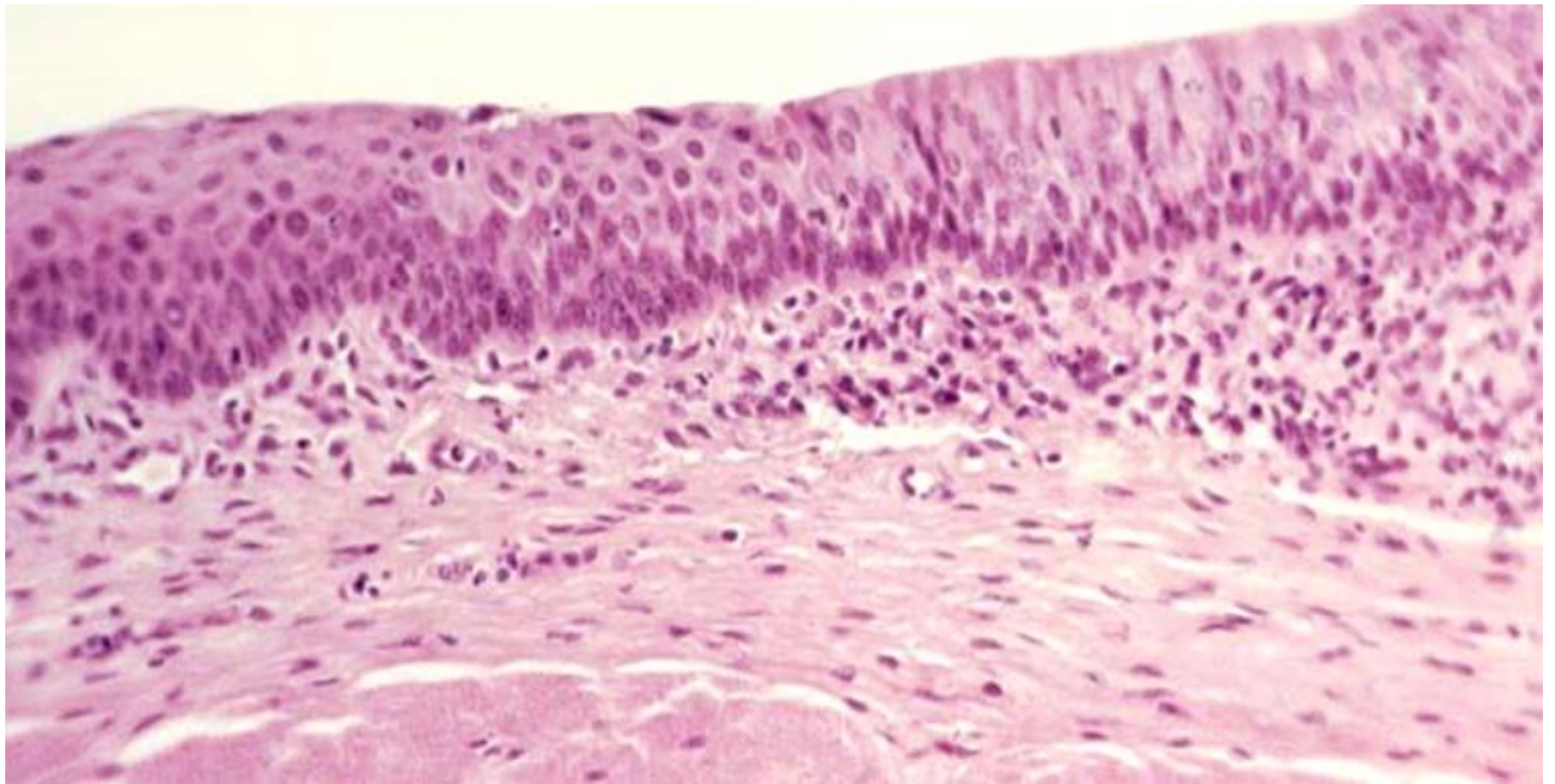
# MĚKKÉ PATRO



# MĚKKÉ PATRO

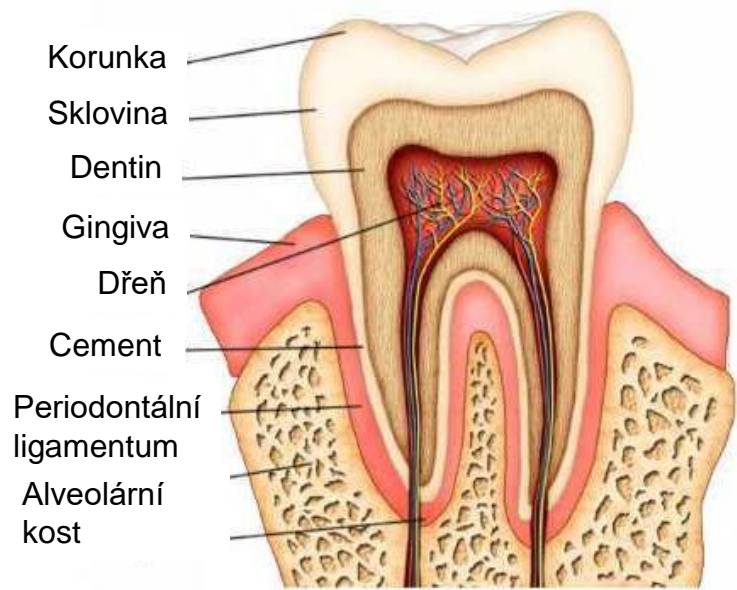


# MĚKKÉ PATRO - PŘECHOD EPITELŮ

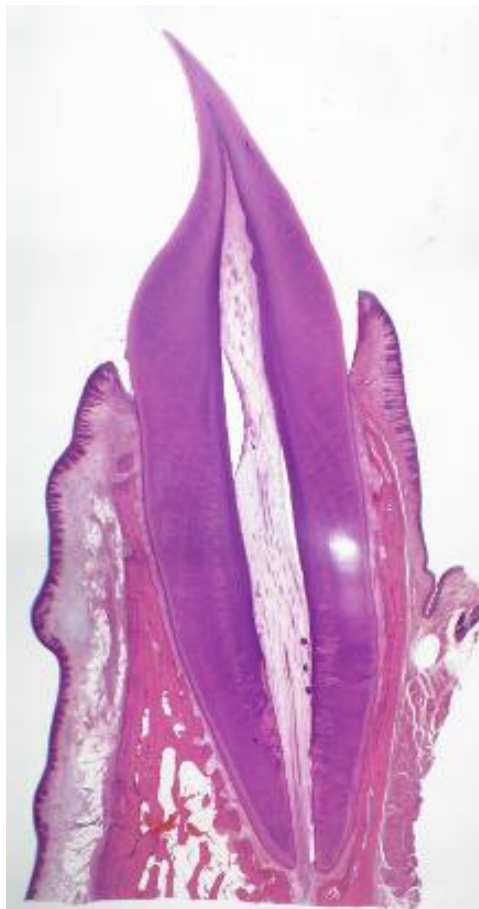



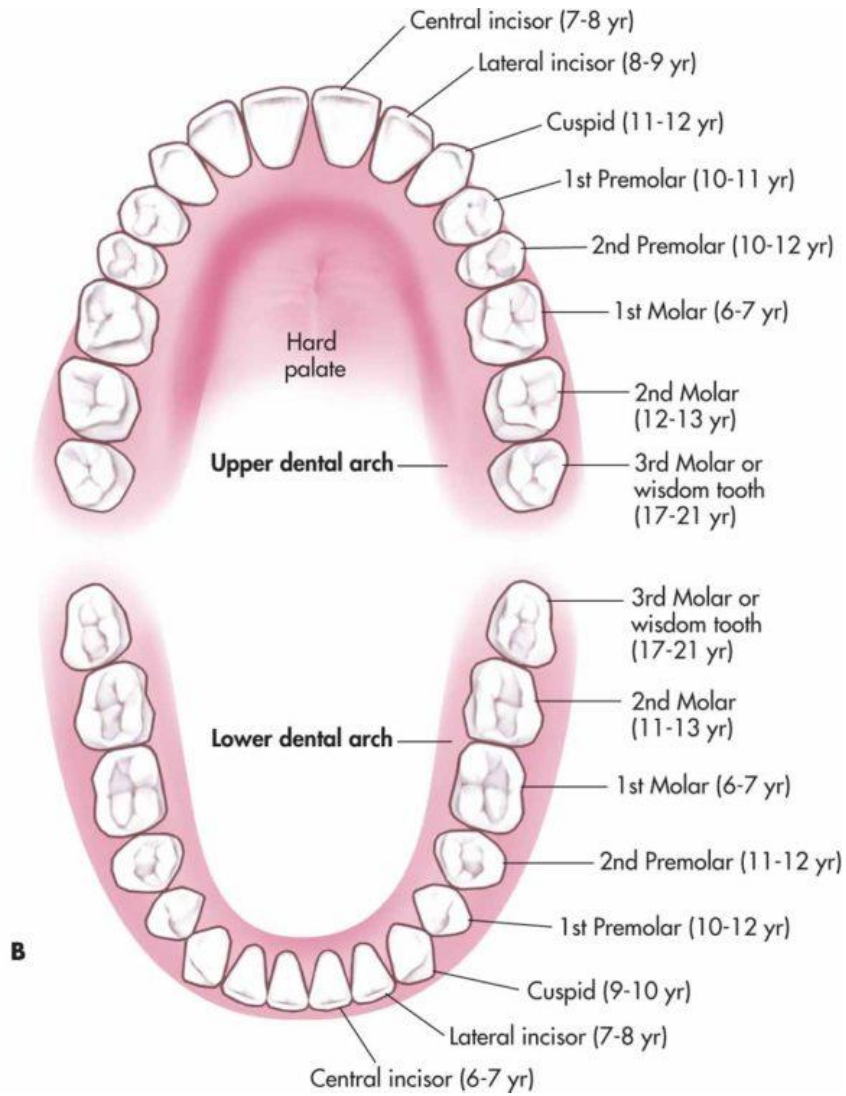
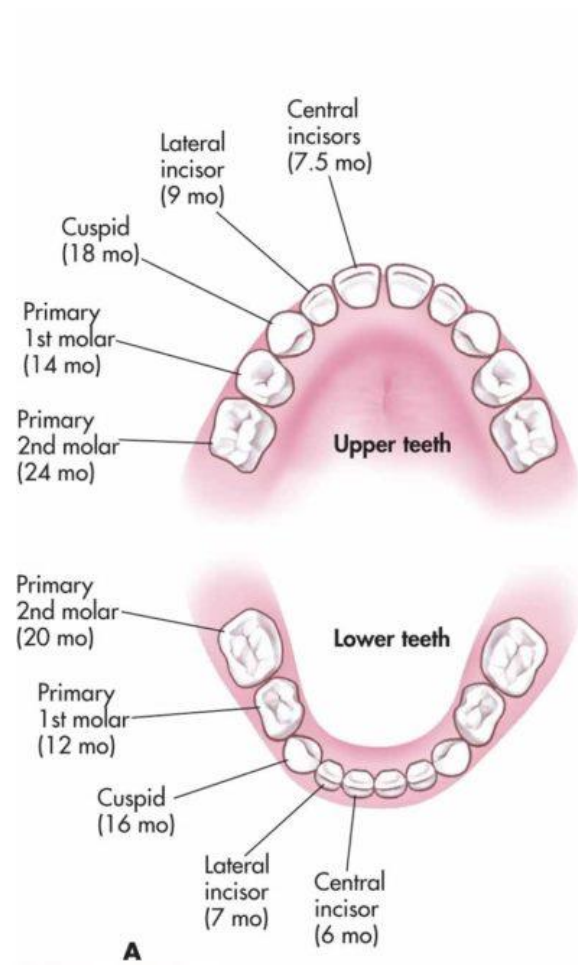
# ZUB



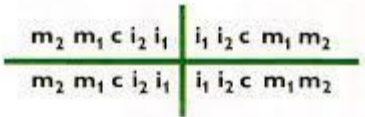
- Anatomická × klinická korunka
- Krček
- Kořen



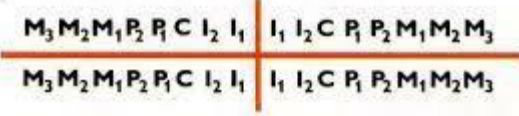
# ZUB



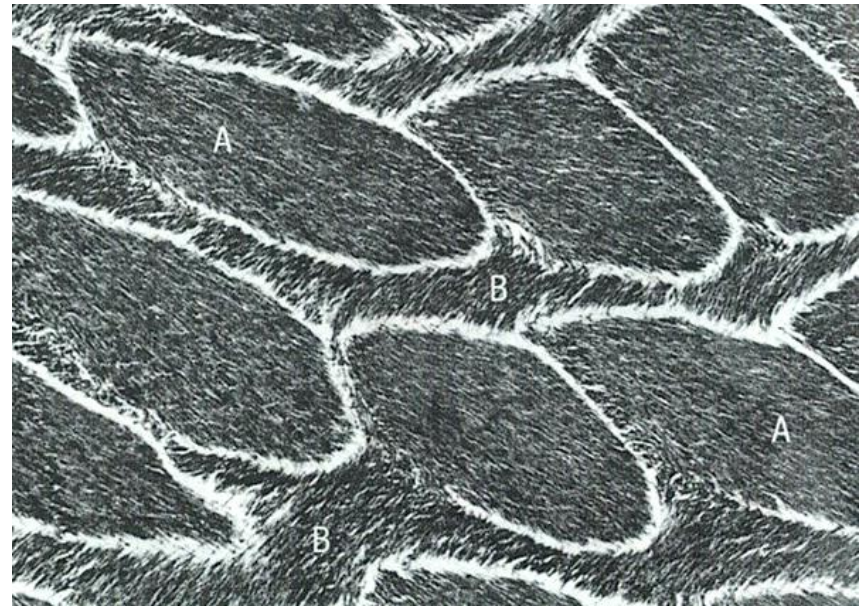
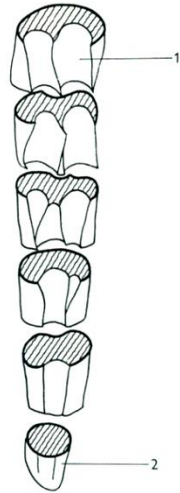
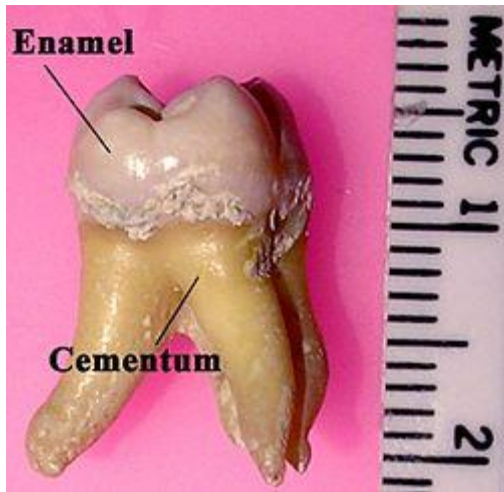Vzorec mléčného chrupu:



Vzorec definitivního chrupu:

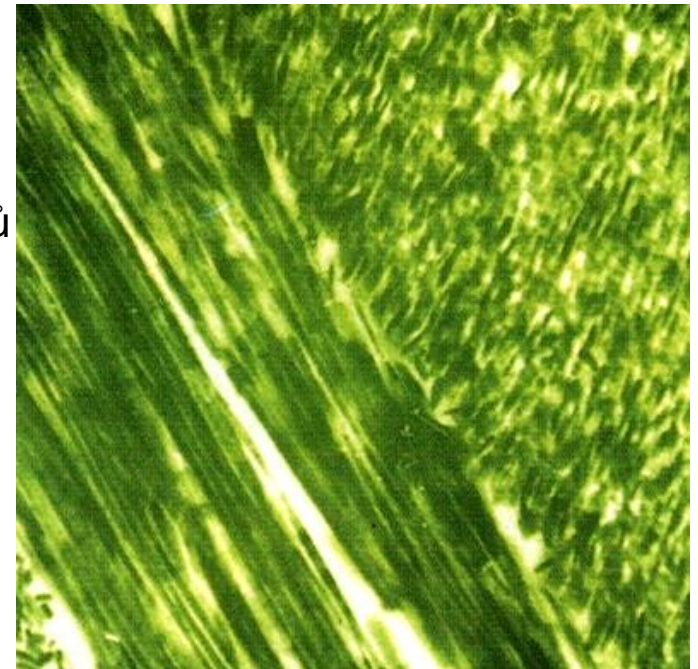


# ZUB - ZUBNÍ SKLOVINA A CEMENT

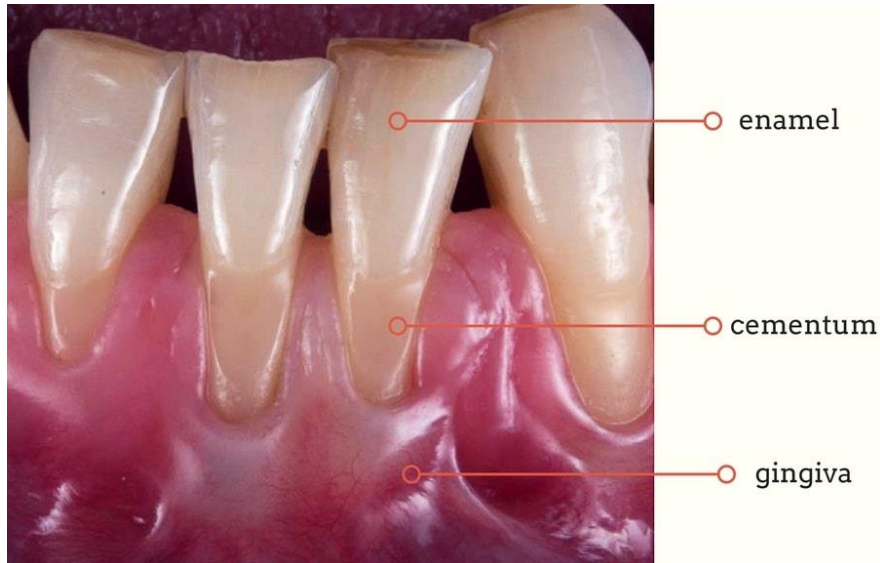


## Sklovina, 1-2 mm

- Kryje korunku
- Vytvářena **ameloblasty**, které vymizí při prořezání zubů
- Neobsahuje buňky, neregeneruje
- 96% Ca-hydroxyapatit, prizmata
- Enameliny, amelogeniny, ameloblastiny

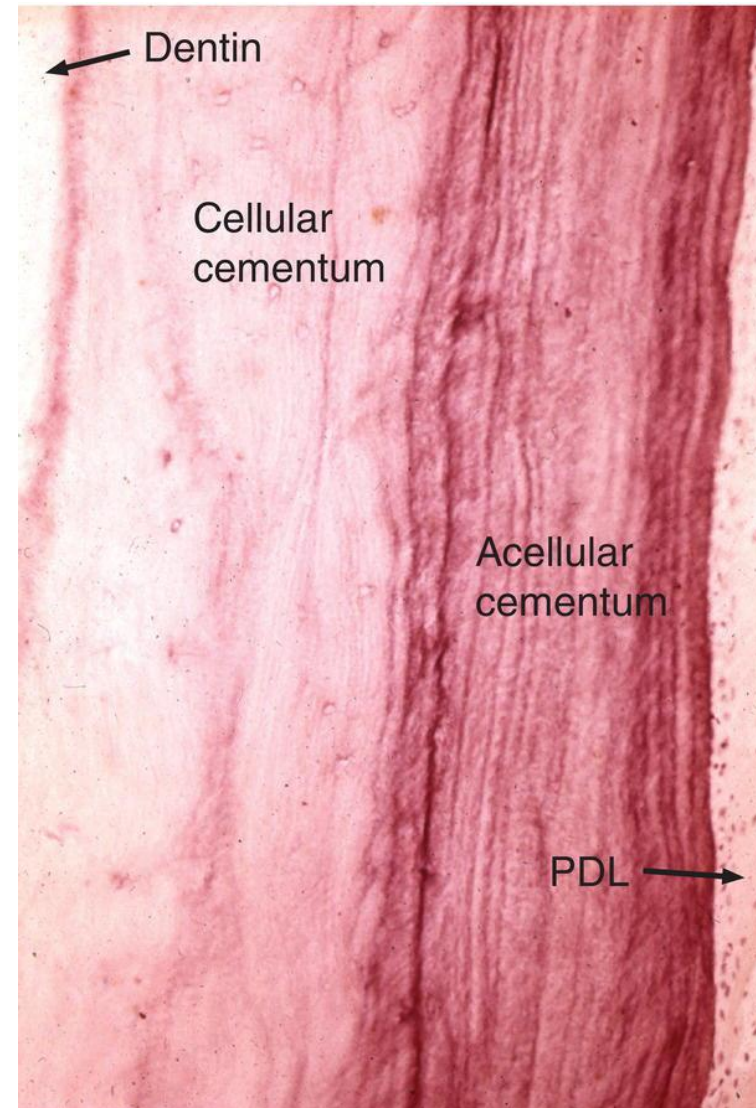


# ZUB - ZUBNÍ SKLOVINA A CEMENT

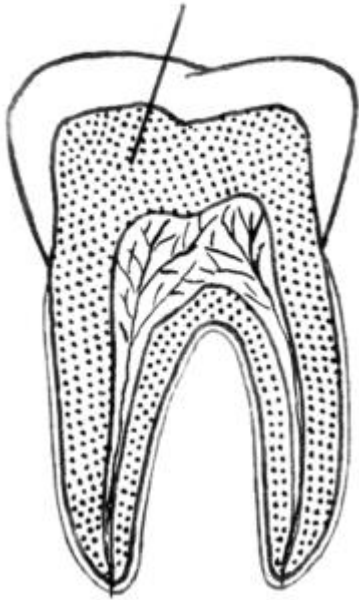


## Cement, 100-500 $\mu\text{m}$

- Kryje kořen a krček zubu, dorůstá
- 50% Ca-hydroxyapatit
- Acelulární fibrilární cement
- Apikální část kořene – **cementocyty**
- Kolagen I, III, XII, GAG, proteoglykany
- Periodontální ligamenta – zubní alveolus

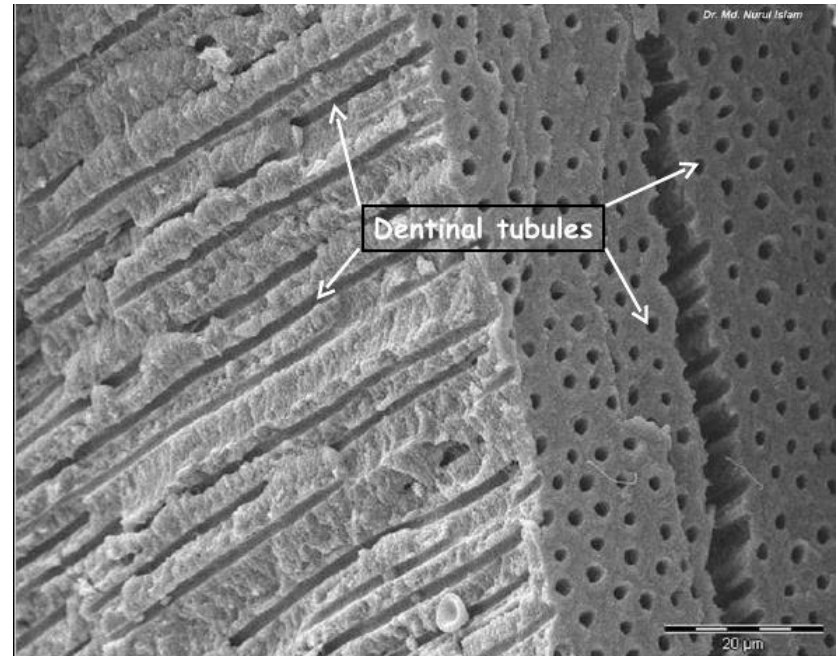
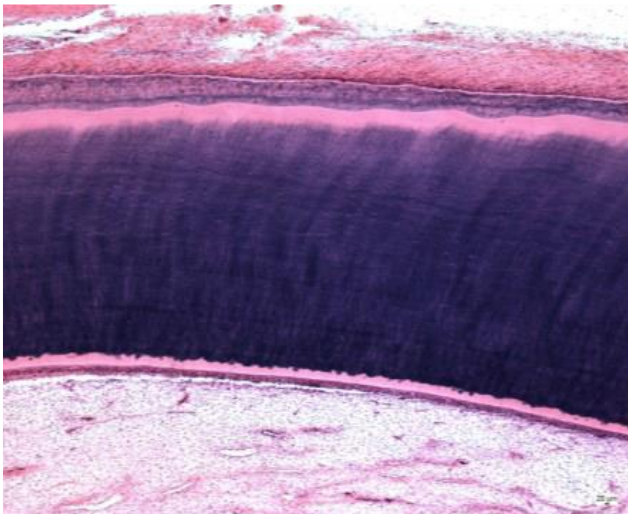


## DENTIN

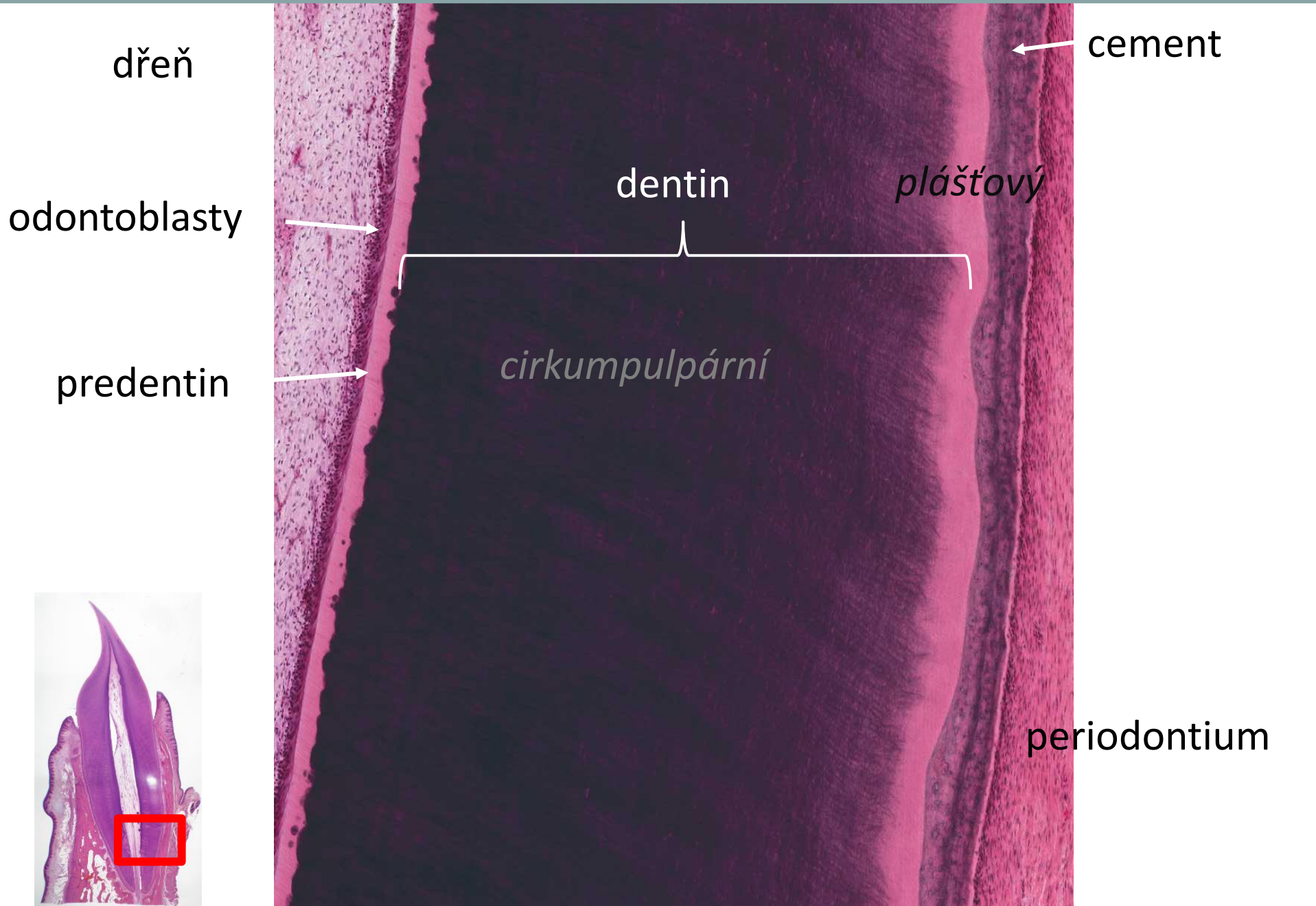


### Dentin

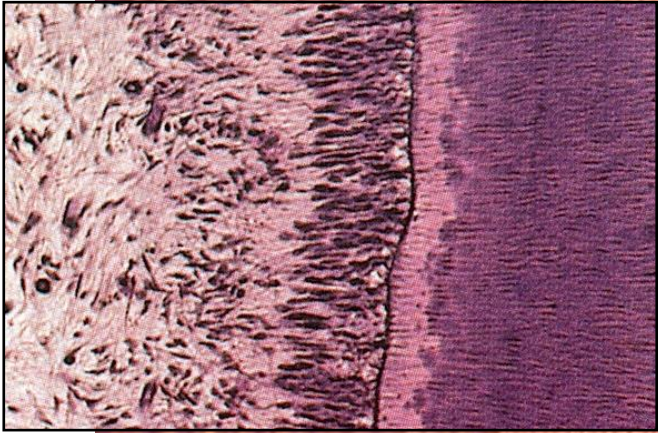

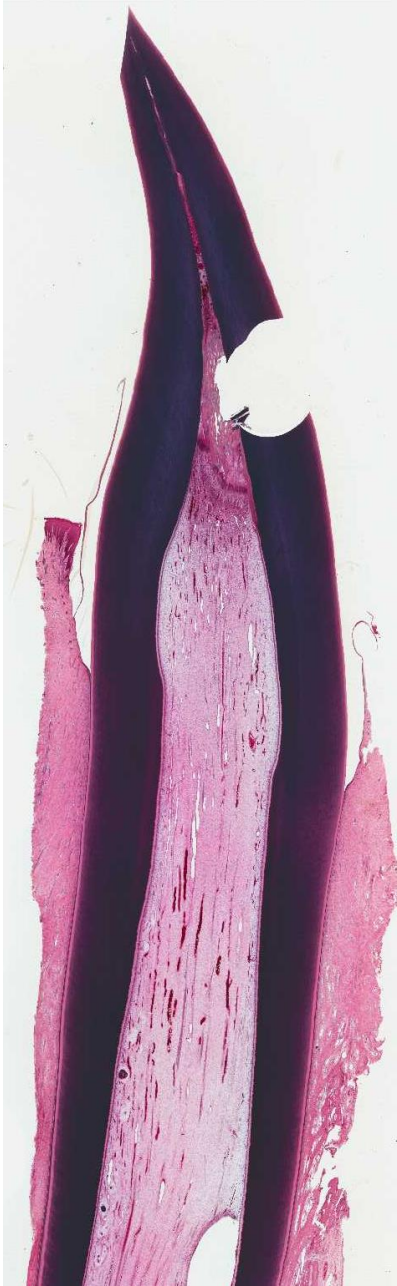
- Pravidelně uspořádané **odontoblasty**
- Přirůstá
- 70% Ca-hydroxyapatit
- Kolagen I, glykoproteiny, proteoglykany
- Výběžky odontoblastů – Tomesova vlákna
- Owenovy linie
- Nervová vlákna



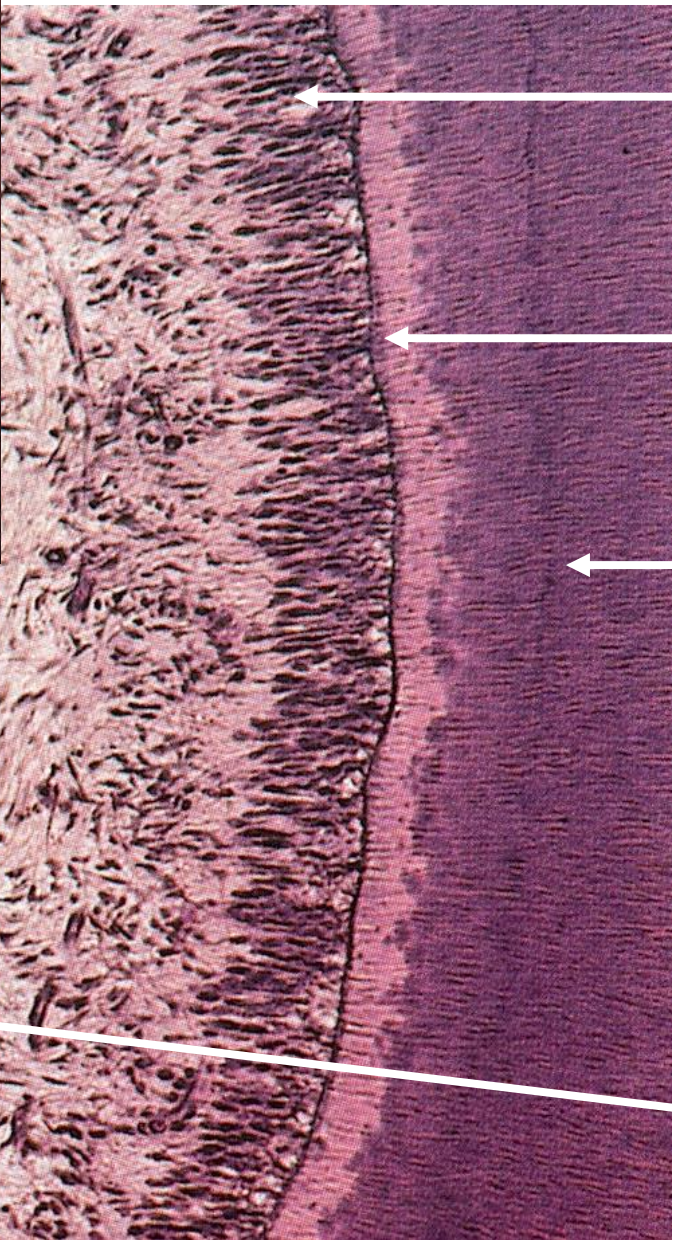

# ZUB - DENTIN



# ZUB - ODONTOBLASTY



# ZUB - ODONTOBLASTY



odontoblasty

predentin

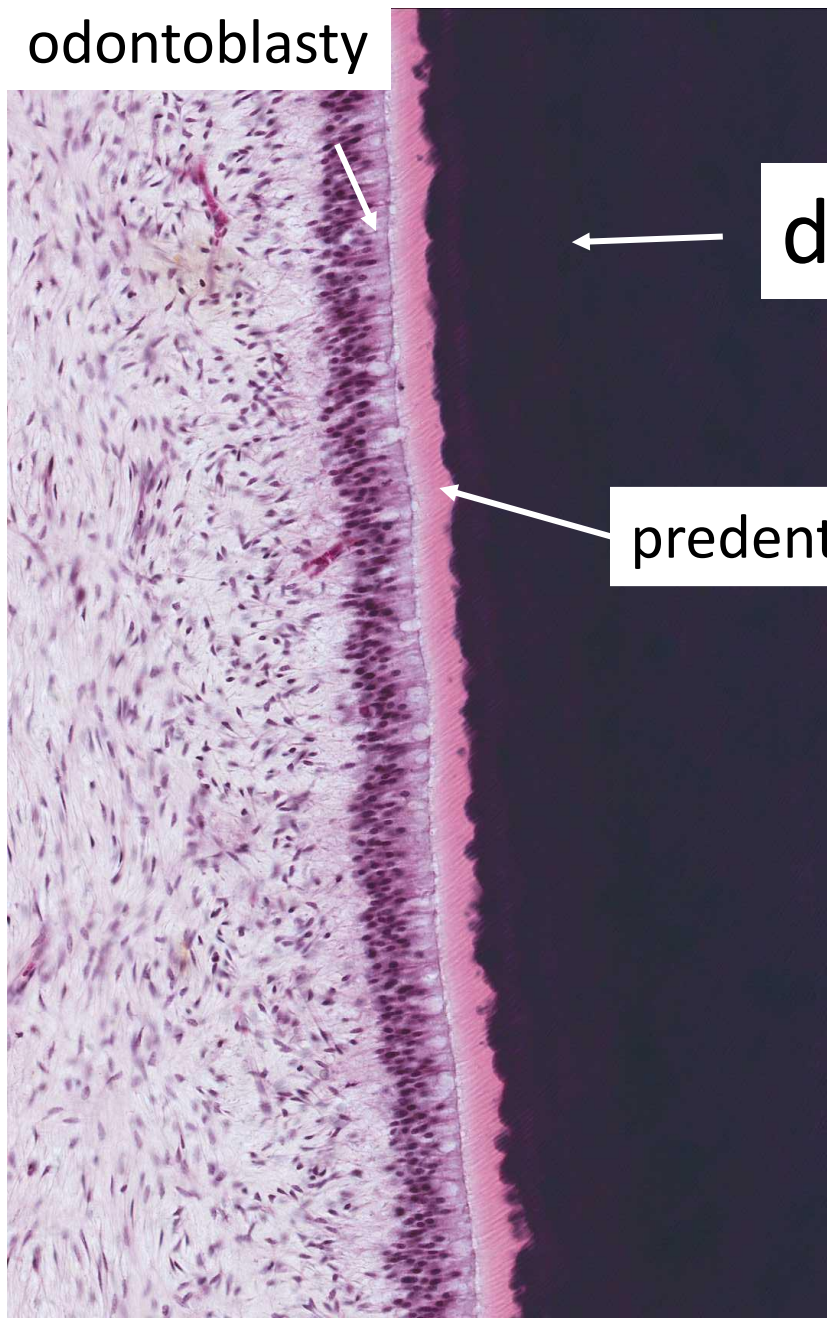
dentin

pulpa

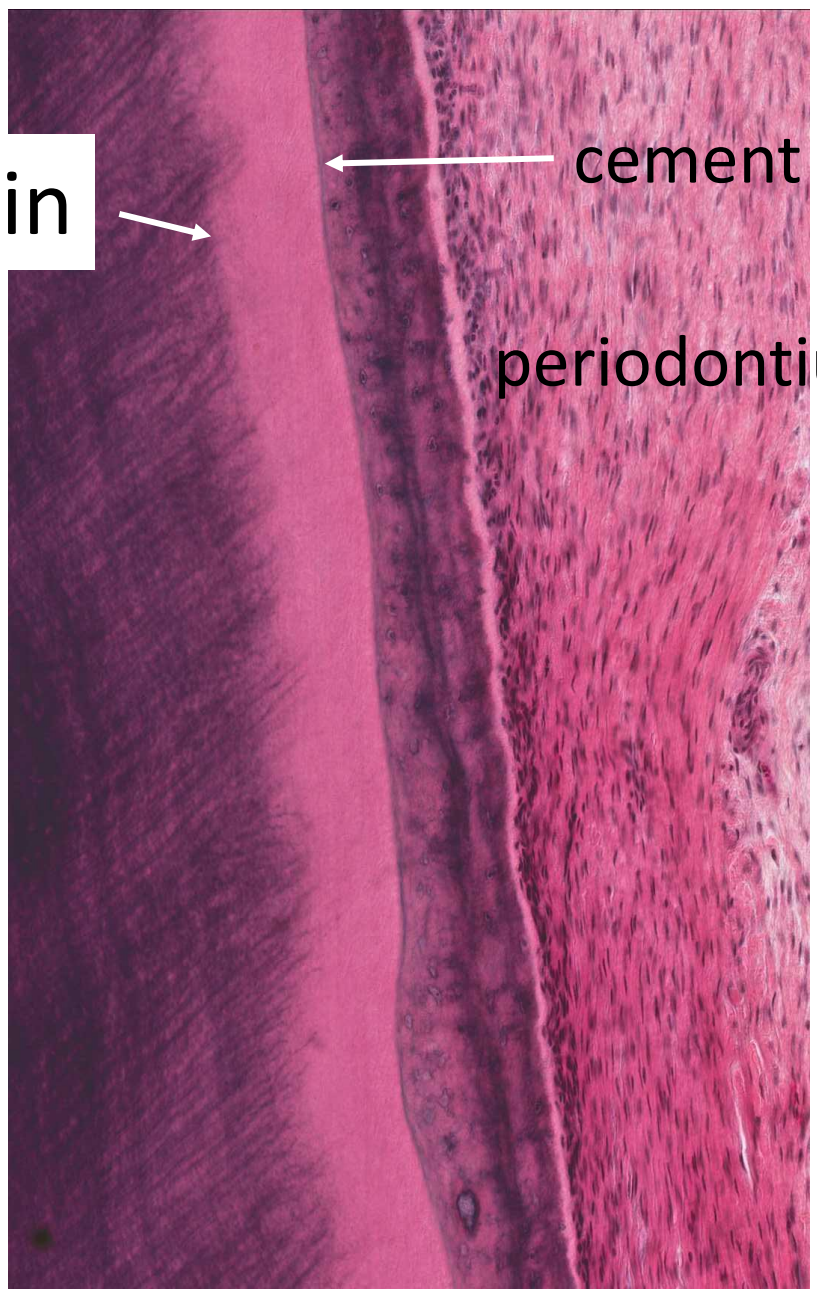


ZUB

odontoblasty



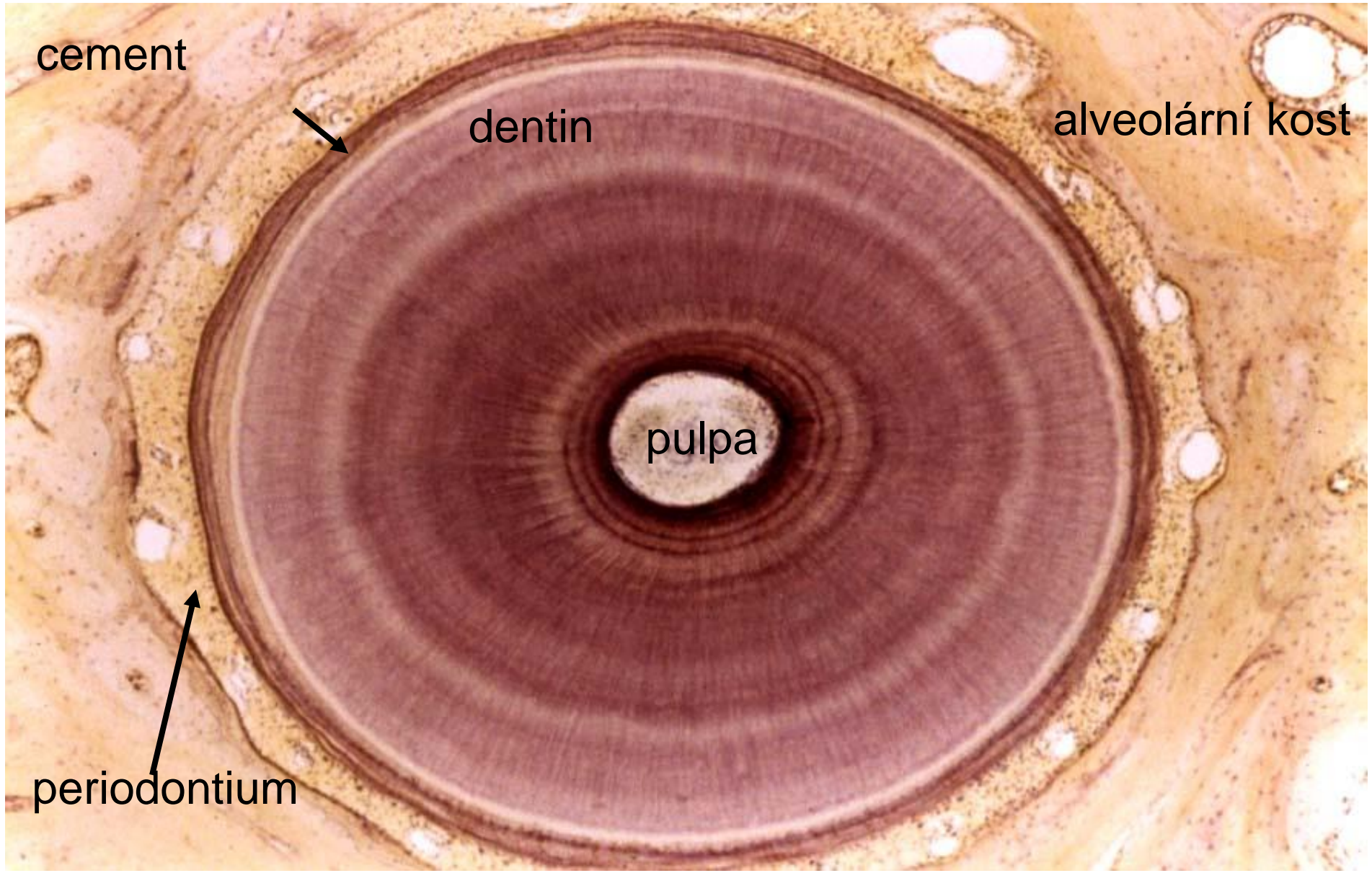
dentin



cement

periodontium

ZUB



cement

dentin

alveolární kost

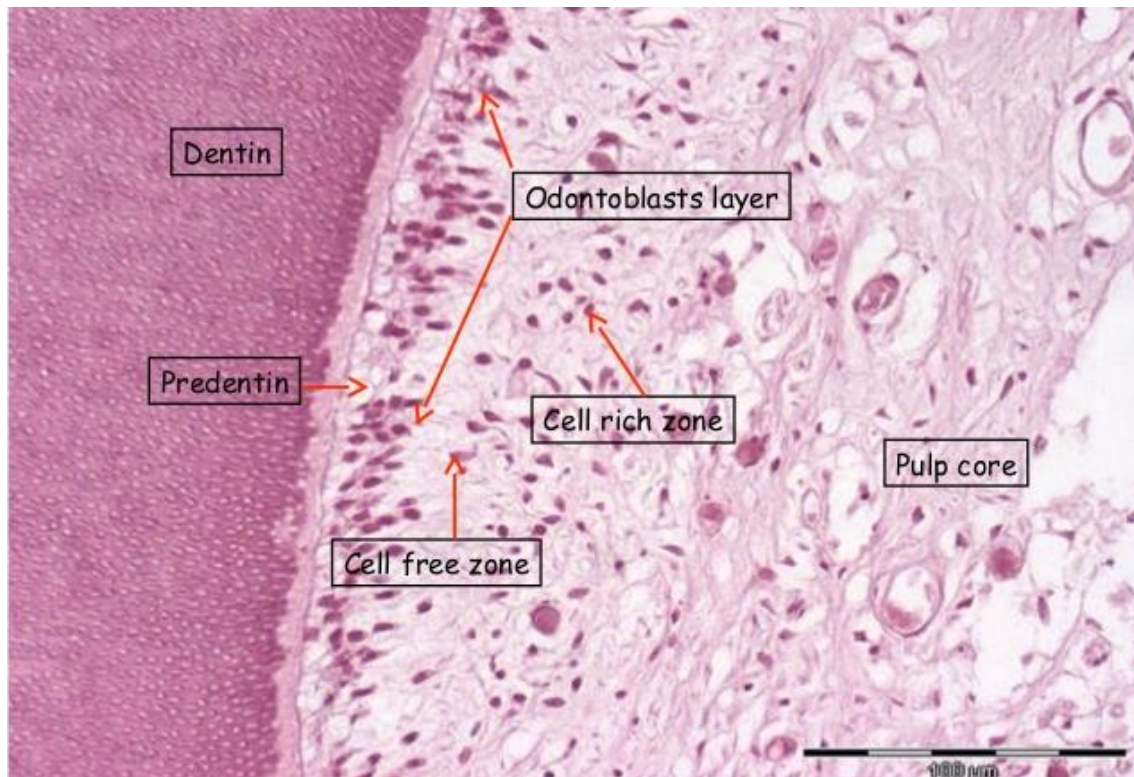
pulpa

periodontium

# ZUB - DŘEŇ (PULPA)

## Pulpa

- rosolovité vazivo podobné embryonálnímu mesenchymu, fibroblasty
- bohatá vaskularizace a inervace
- korunková dřeň a kořenový kanálek
- foramen apicale – periodontium
- odontoblasty
- nociceptivní nervová vlákna (plexus Raschkowi) – zasahují do dentinových kanálek

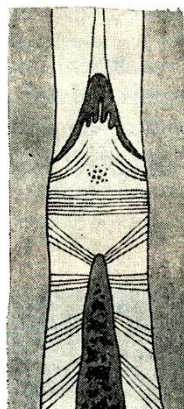
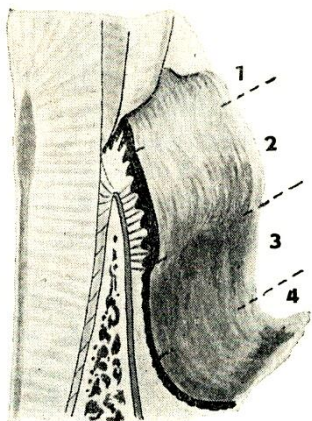
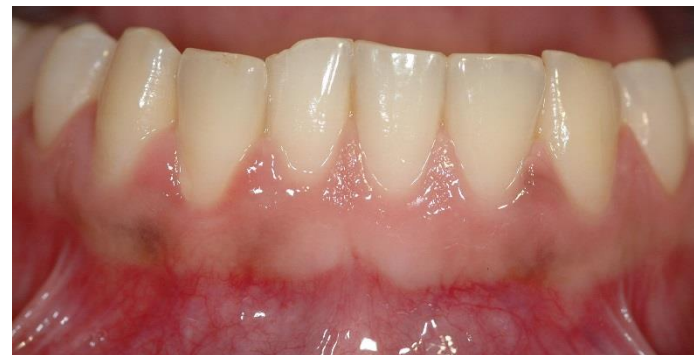

<https://www.slideshare.net/hesham63/pulp-15597098>

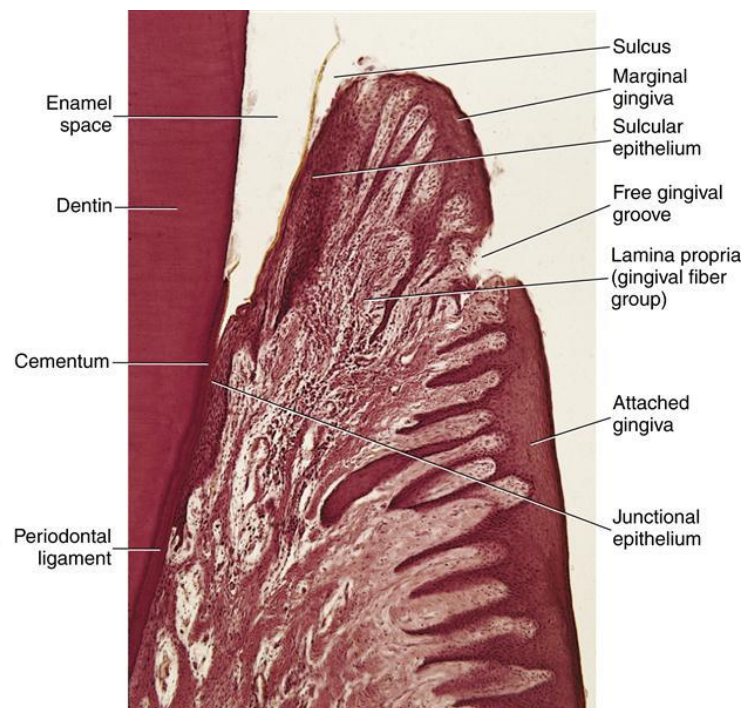
# ZUB – PERIODONTIUM A GINGIVA

## Dáseň

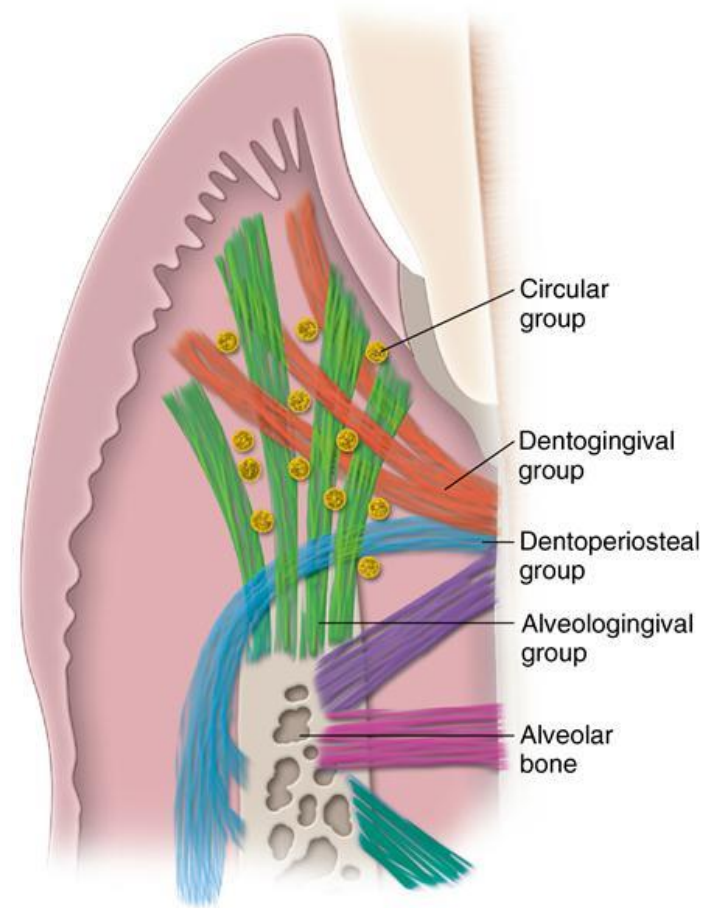
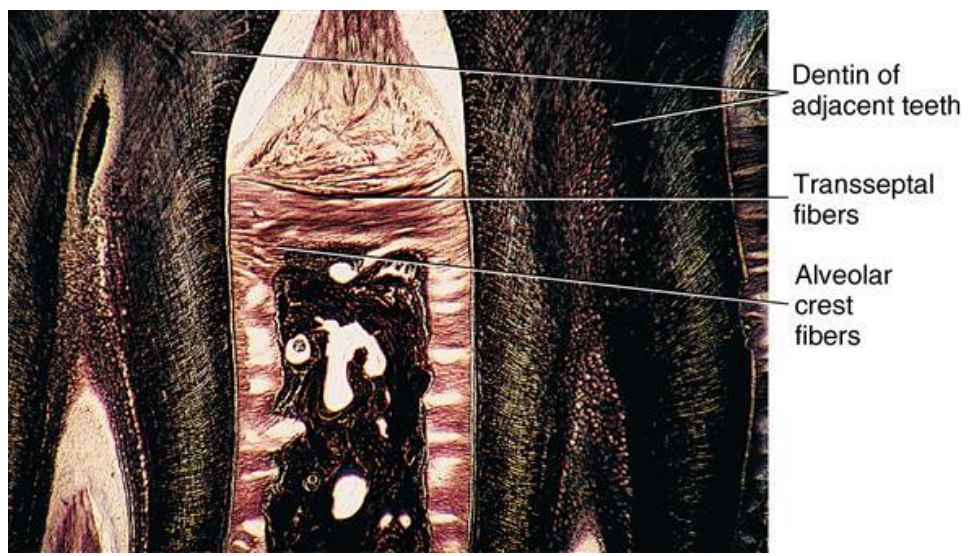
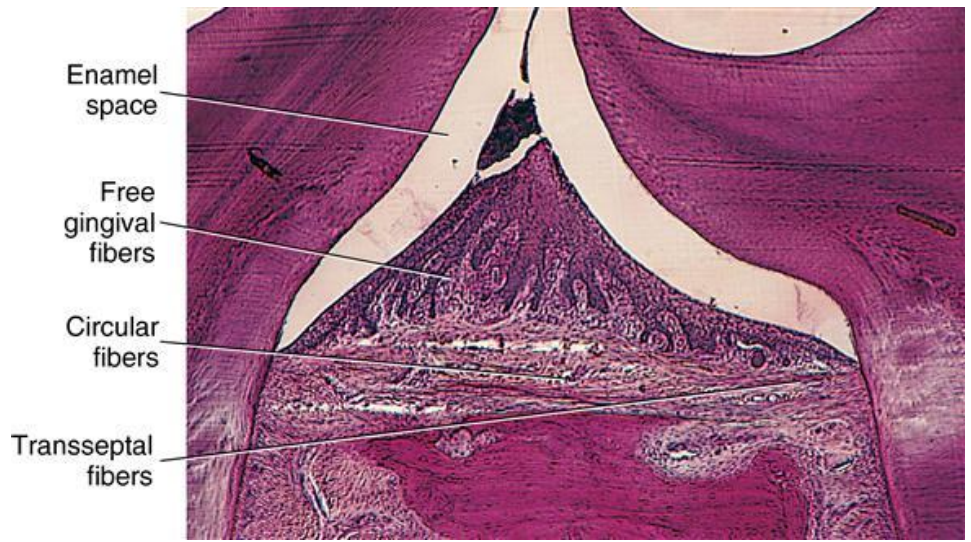
- volná (marginální, g. libera)
  - připojená (g. affixa)
  - paramarginální rýha (zevní gingivální žlábek)
  - sulcus gingivalis
  - gingivodentální uzávěr
- 
- vrstevnatý dlaždicový epitel
  - lamina propria mucosae – husté kolagenní vazivo



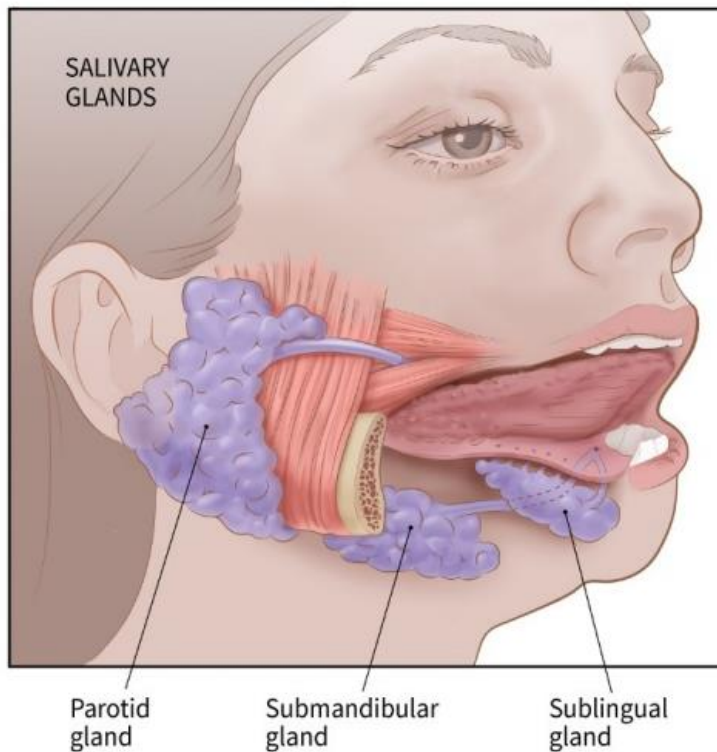
Obr. 8. Schéma gingivy. 1 — volná gingiva, 2 — připojená gingiva, 3 — alveolární sliznice, 4 — vestibulární sliznice



# ZUB – PERIODONTIUM A GINGIVA

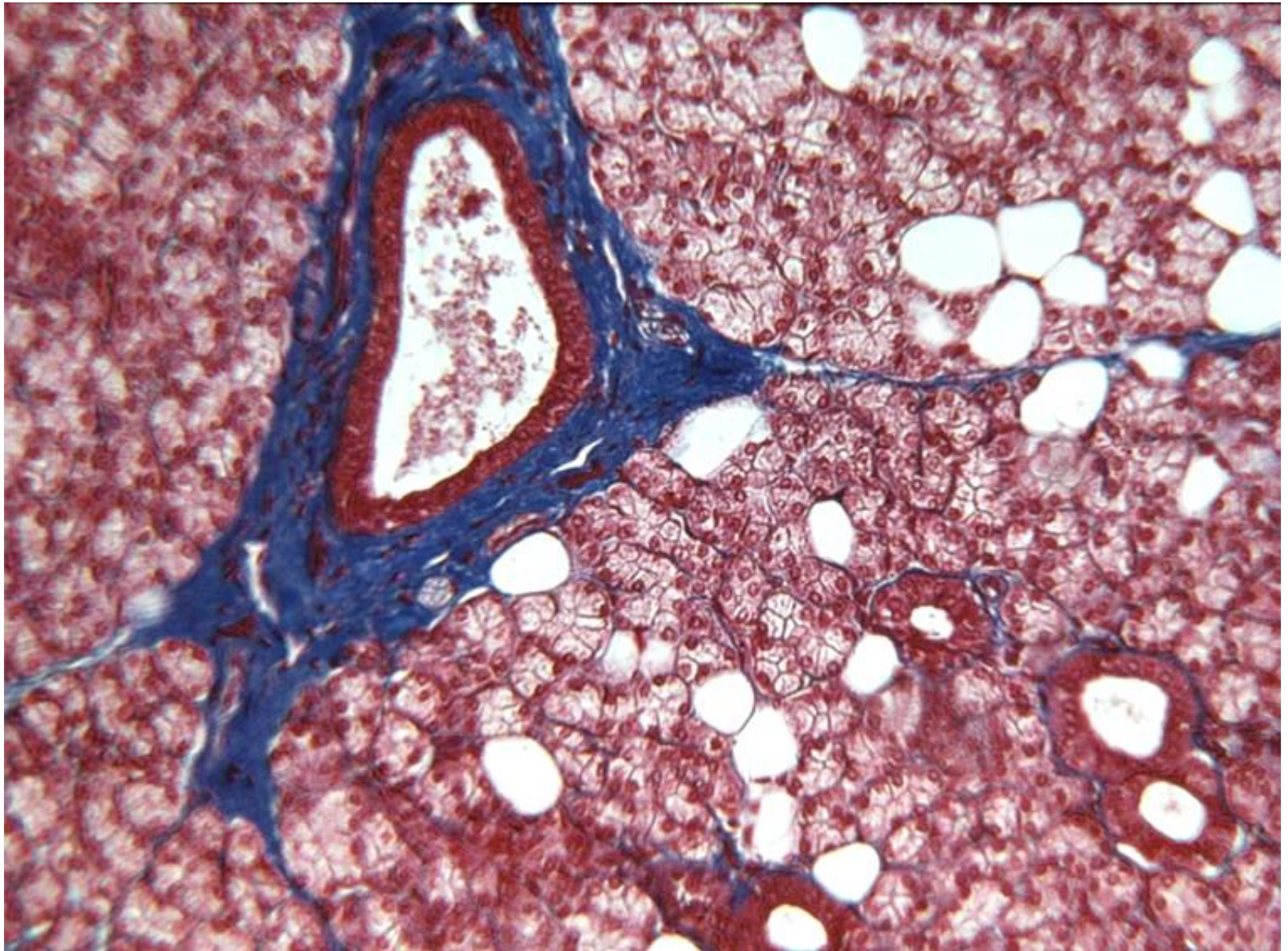


- malé (gl. labiales, buccales, retromolares, palatinae, gl. lingualis anterior - Blandini, gl. Ebneri, gl. Weberi)
- velké (gl. parotis, gl. submandibularis, gl. sublingualis)

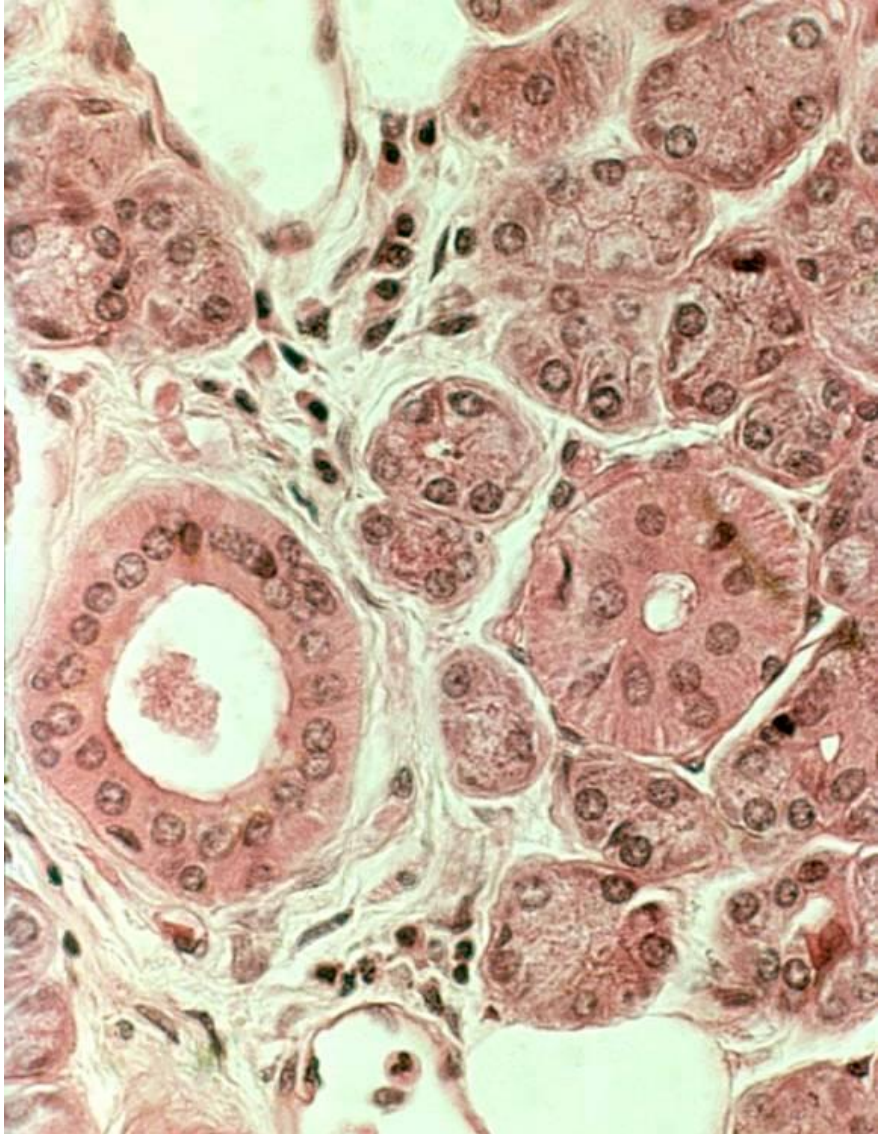
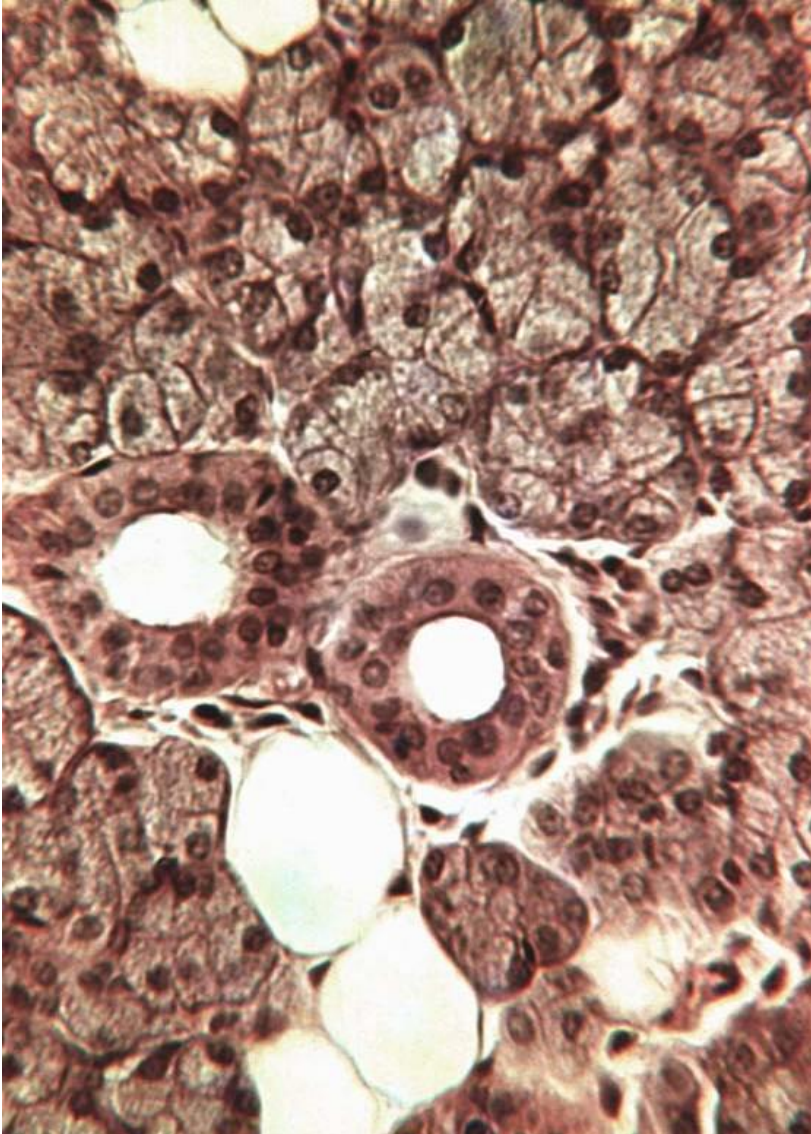


Podrobněji  
viz GIT 3

# SLINNÉ ŽLÁZY – GL. PAROTIS

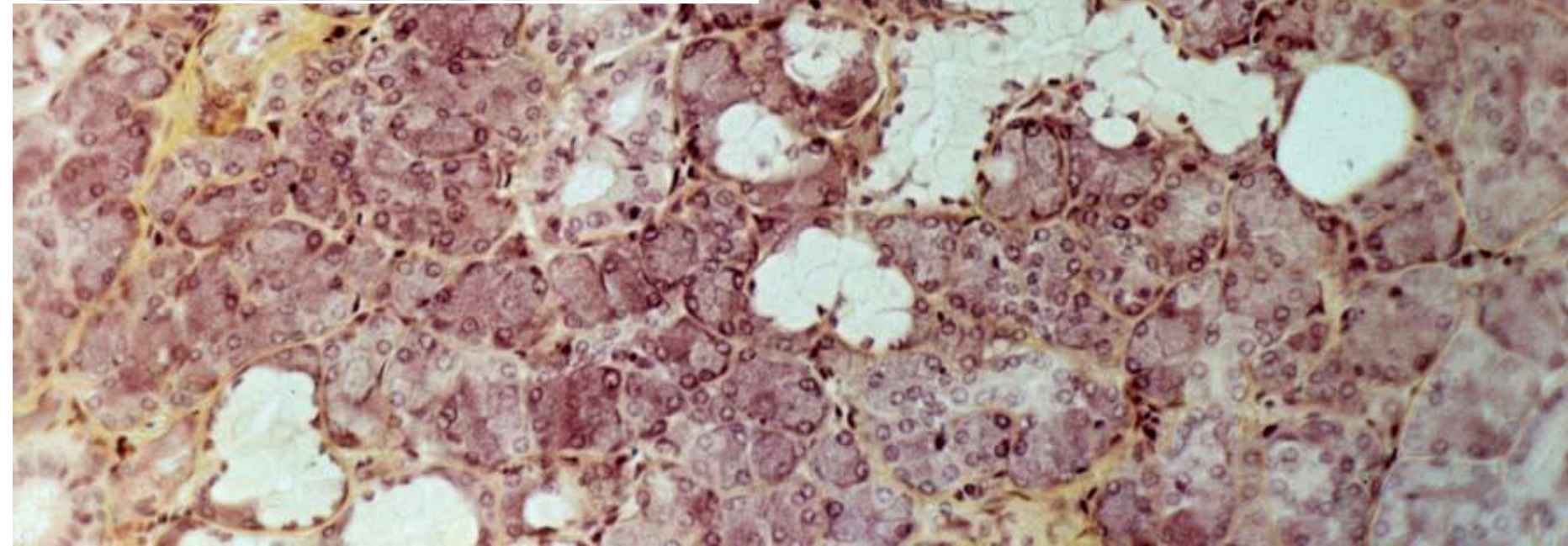
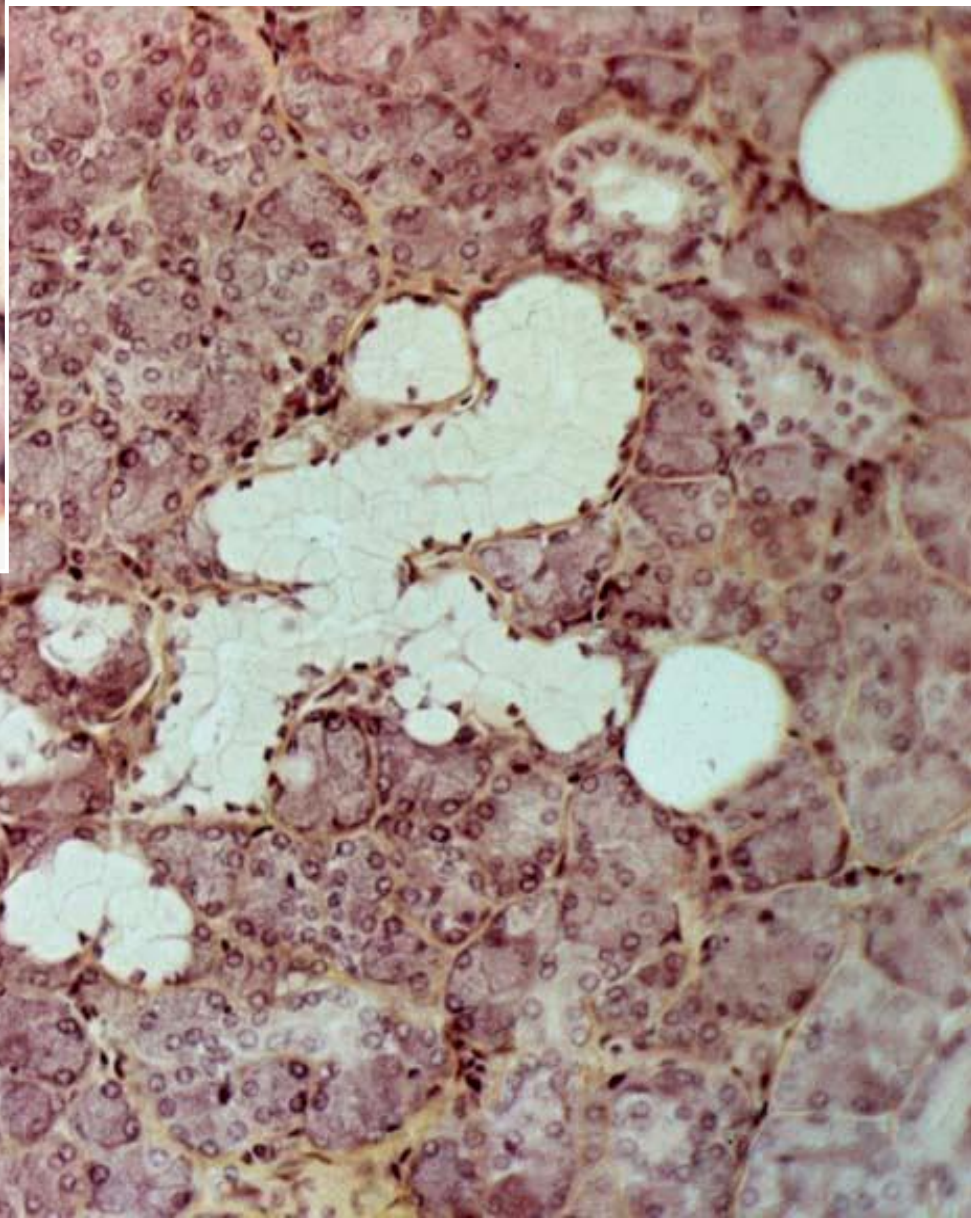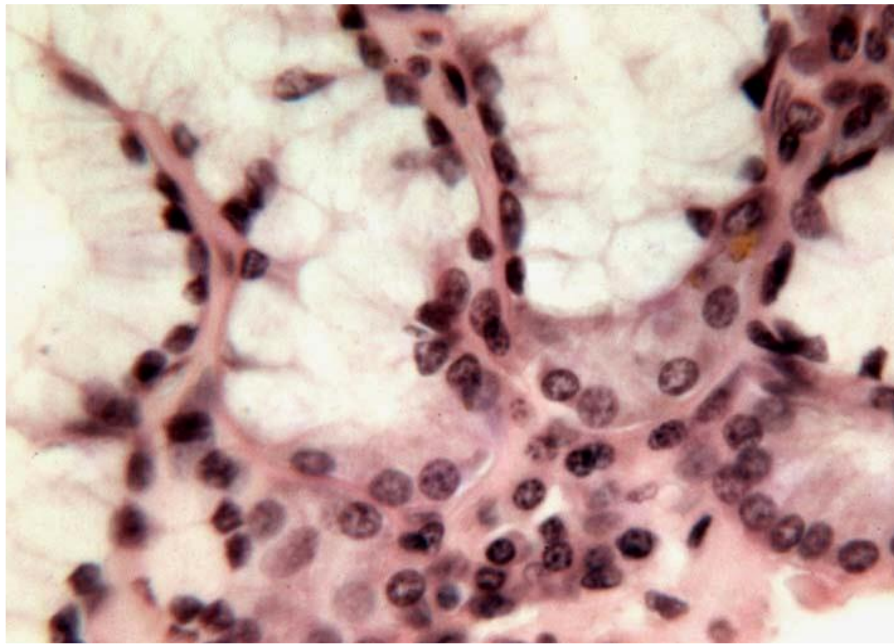


# SLINNÉ ŽLÁZY – GL. PAROTIS

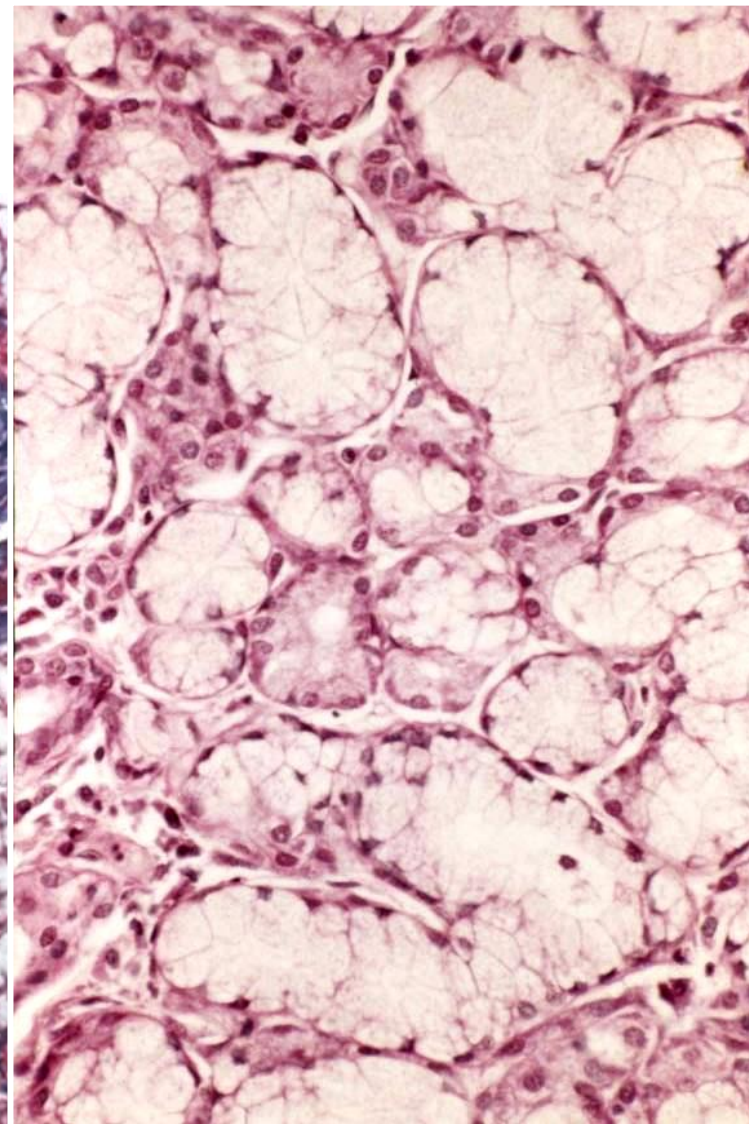
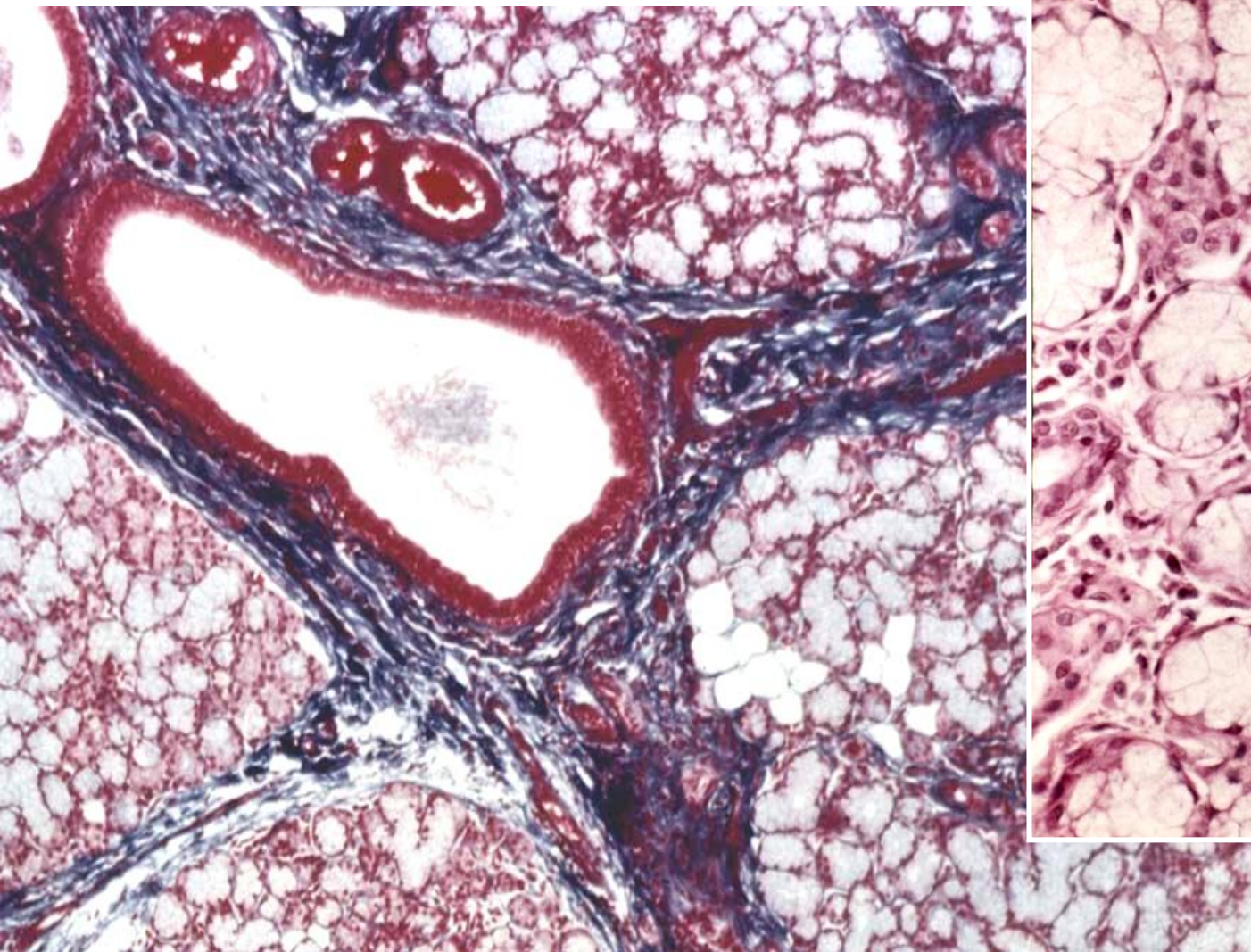





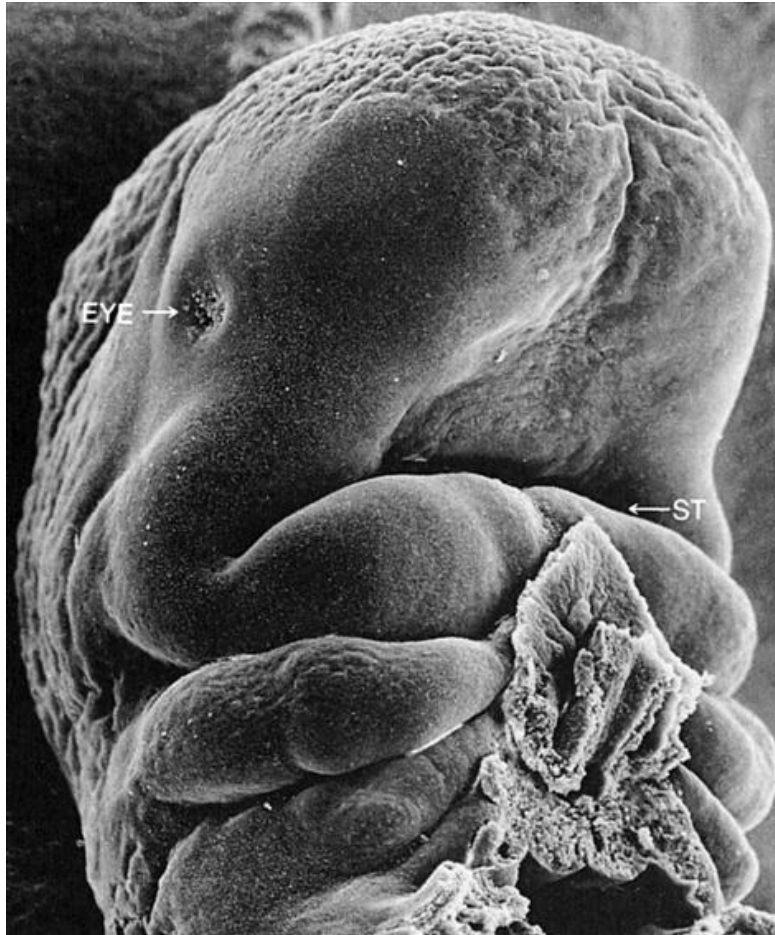
# SLINNÉ ŽLÁZY – GL. SUBMANDIBULARIS



# SLINNÉ ŽLÁZY – GL. SUBLINGUALIS

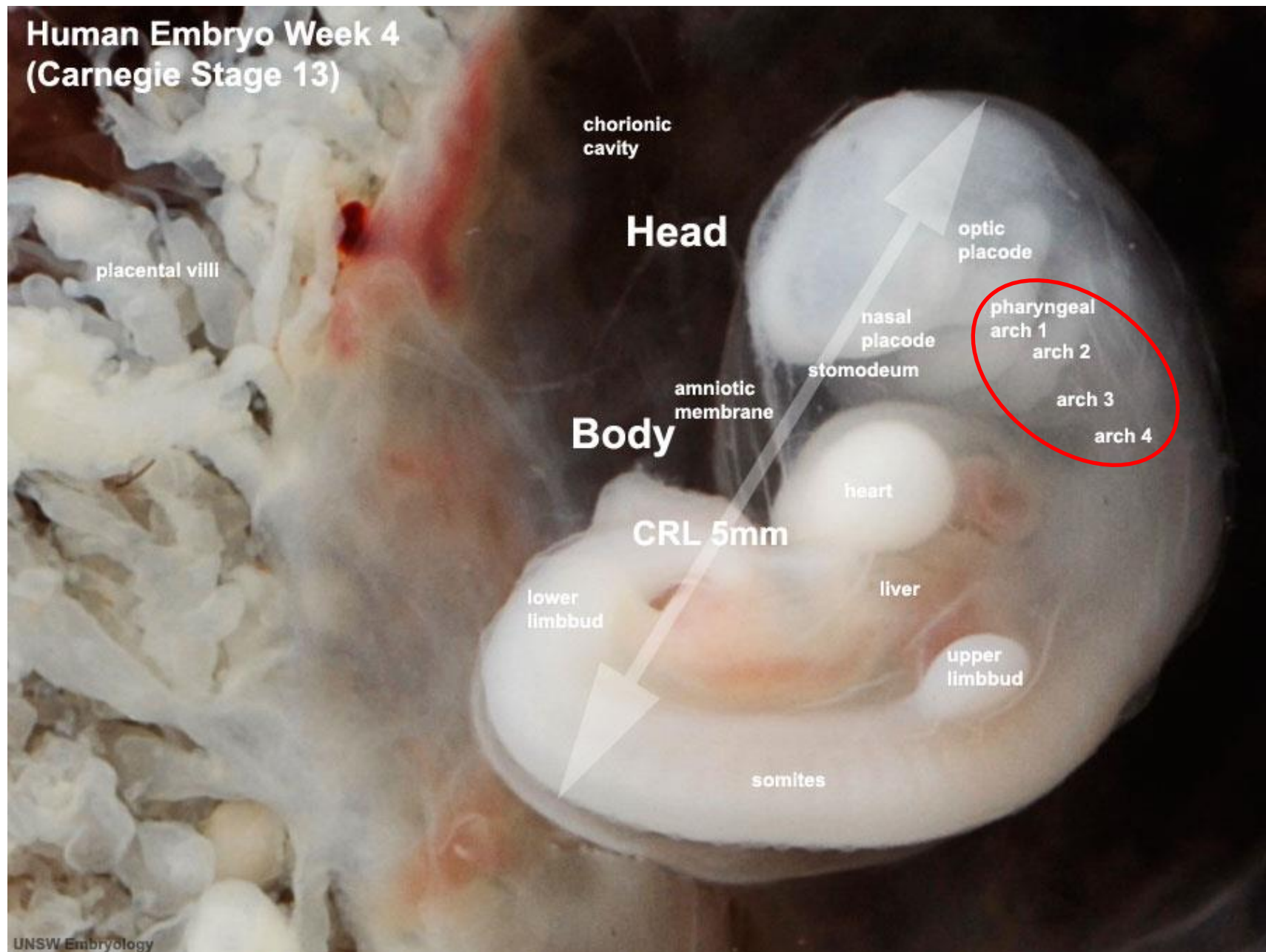


# VÝVOJ OBLIČEJE A SOUVISEJÍCÍCH ANATOMICKÝCH STRUKTUR



**Klíčová vývojová struktura:  
FARYNGOVÝ (ŽABERNÍ) APARÁT**

# FARYNGOVÝ APARÁT



# FARYNGOVÝ APARÁT

## Faryngový oblouk

- Sval
- Chrupavka
- Arterie
- Nerv
- Mezenchym/Ektomezenchym

## Ektodermální vklesliny

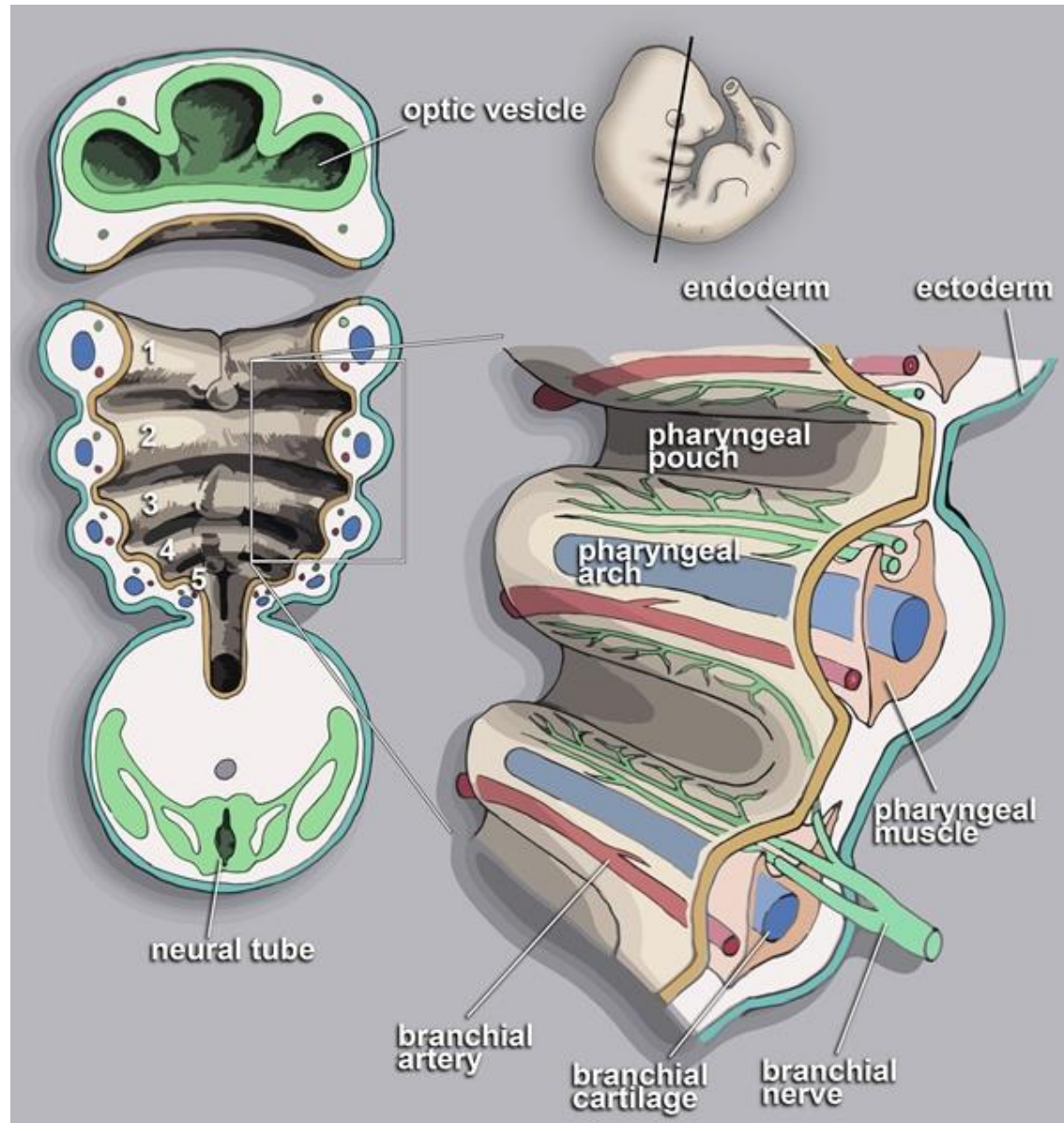
- z povrchu
- ektoderm

## Faryngové výchlípky

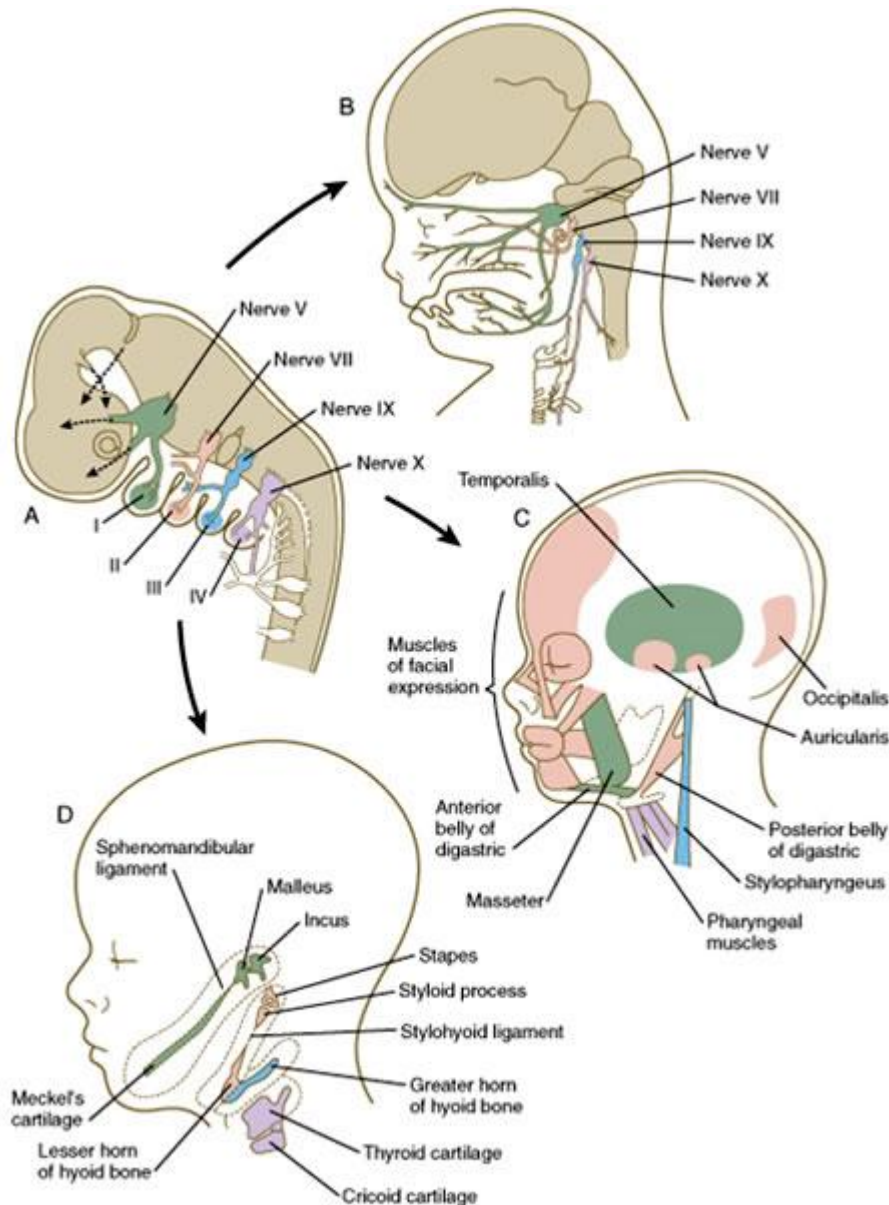
- z primitivního faryngu
- entoderm

## Faryngové membrány

- Kontakt štěrbin a výchlípky
- Ektoderm a entoderm
- *Membrana obturans/branchialis*



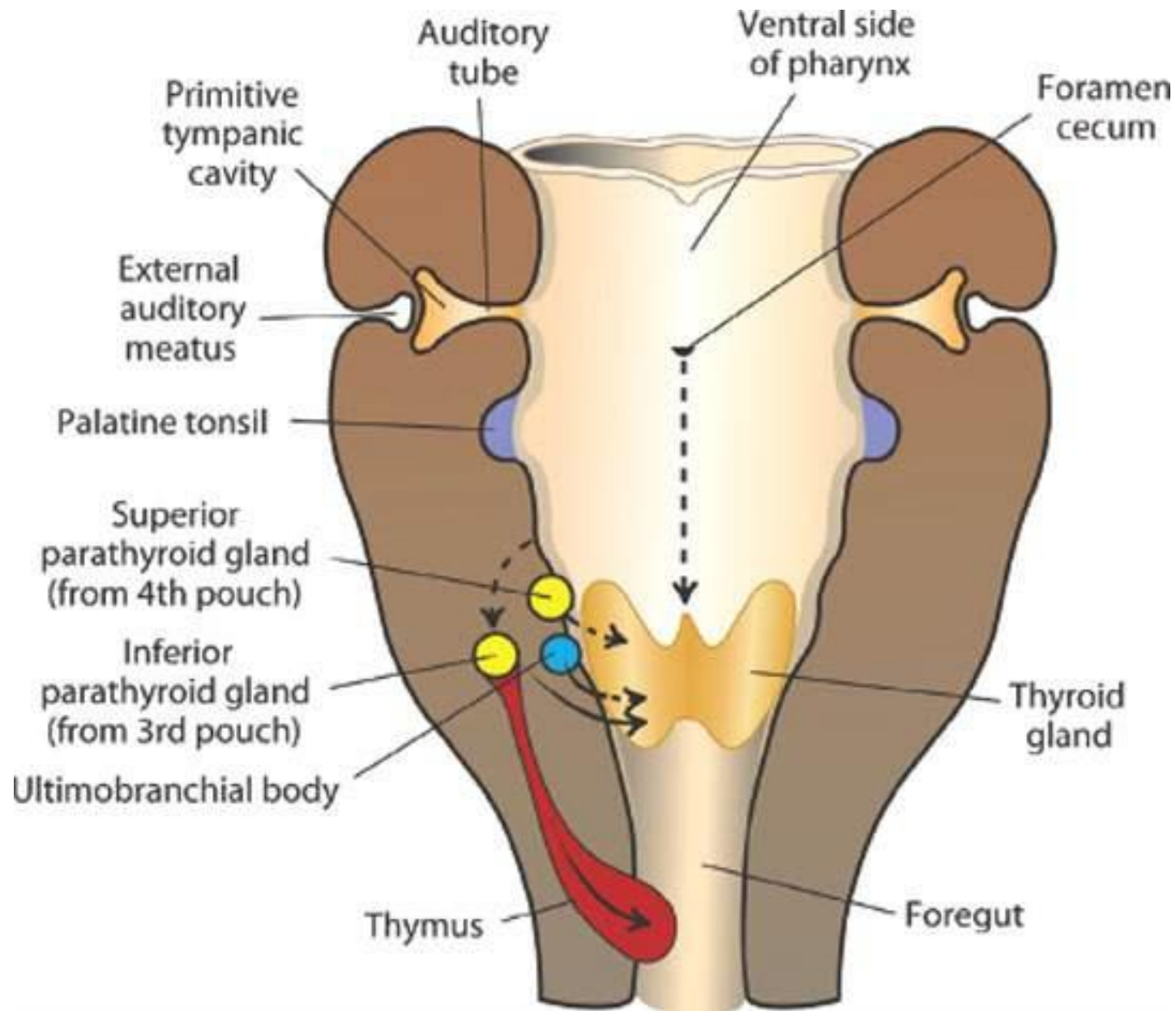
# FARYNGOVÝ APARÁT



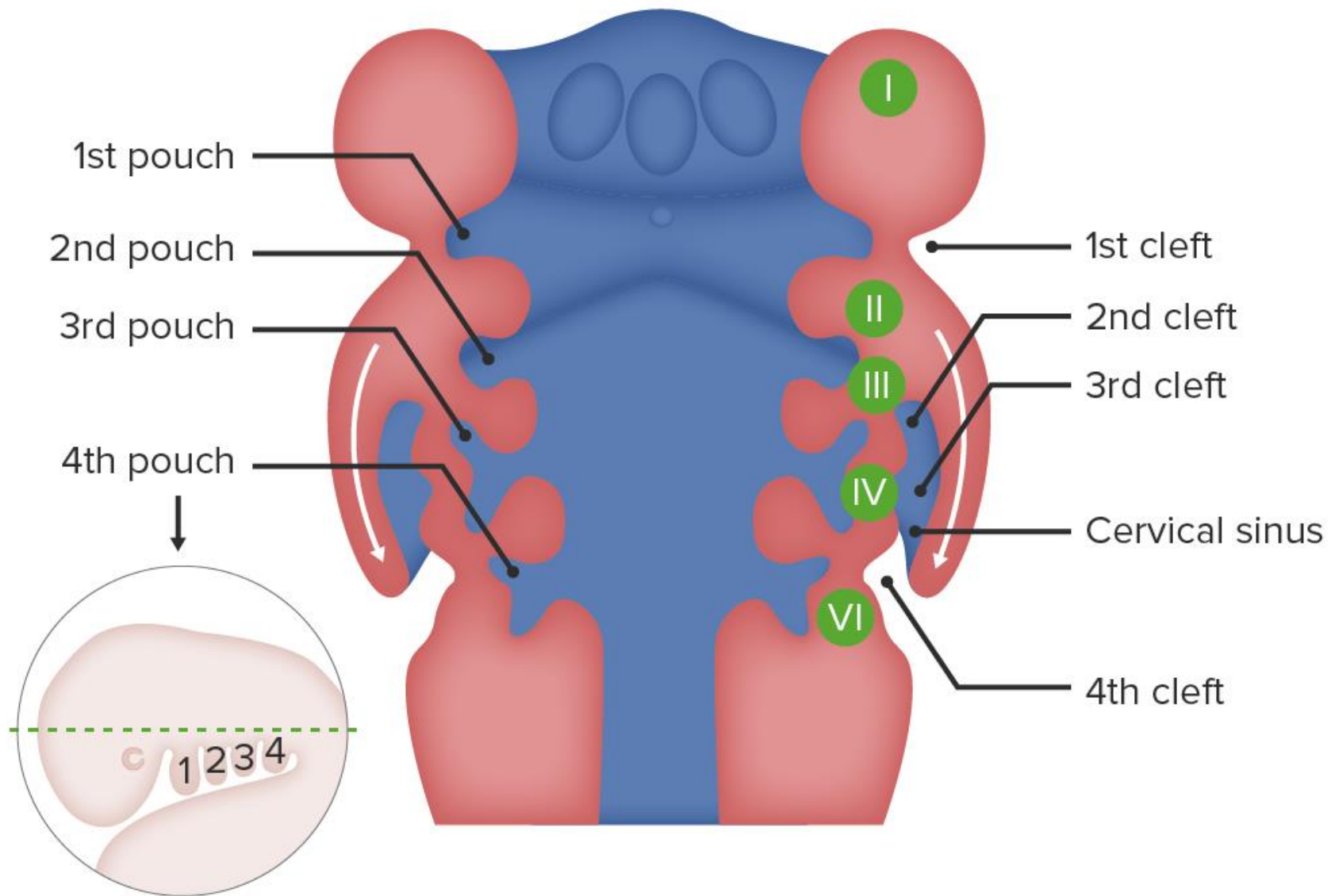
## Deriváty faryngového aparátu

- Obličej včetně měkkých tkání
- Mimické a žvýkací svaly
- Jazyk
- Zevní a vnitřní ucho
- Jazyka
- Chrupavky laryngu
- Thymus
- Příštítná tělíska
- Fossa tonsillaris (pro t. palatina)
- Velké arterie

# FARYNGOVÝ APARÁT



# FARYNGOVÝ APARÁT- SINUS CERVICALIS

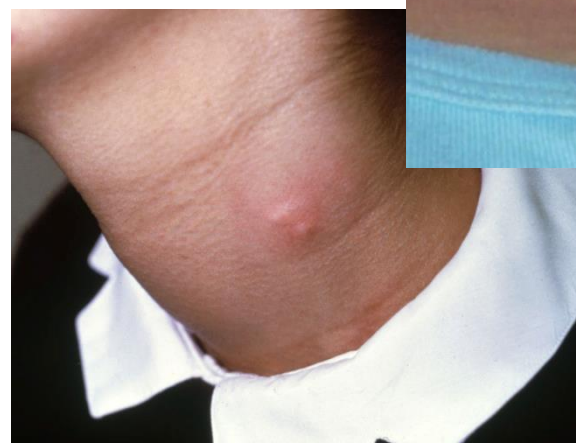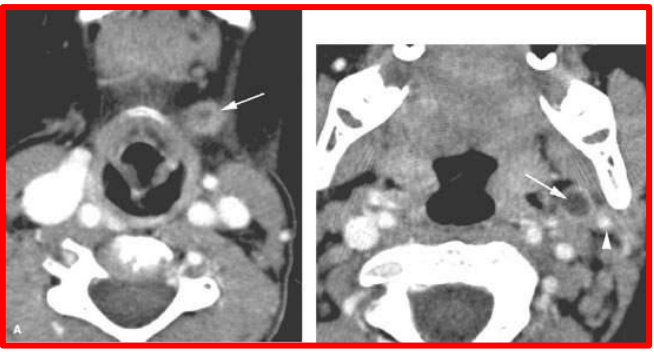
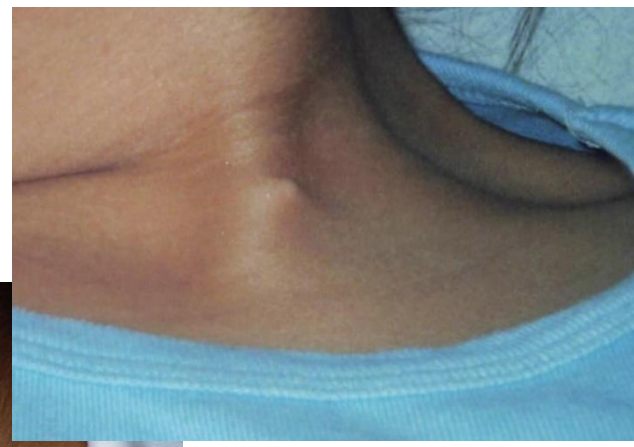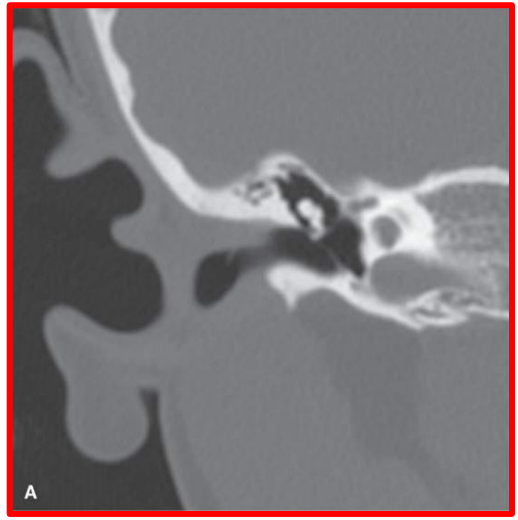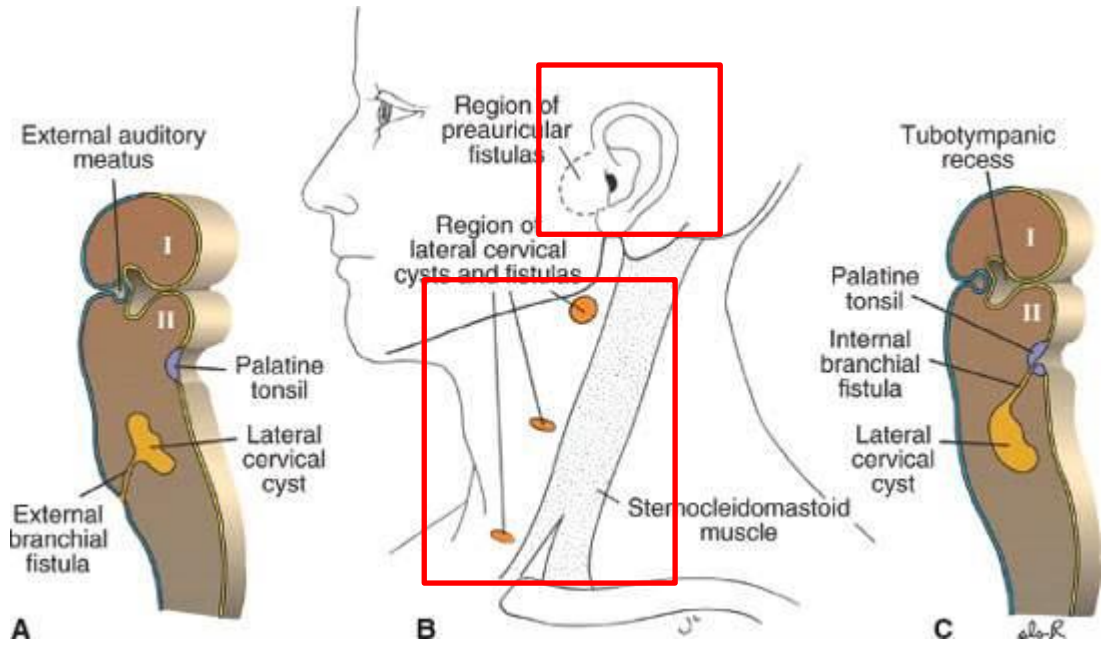




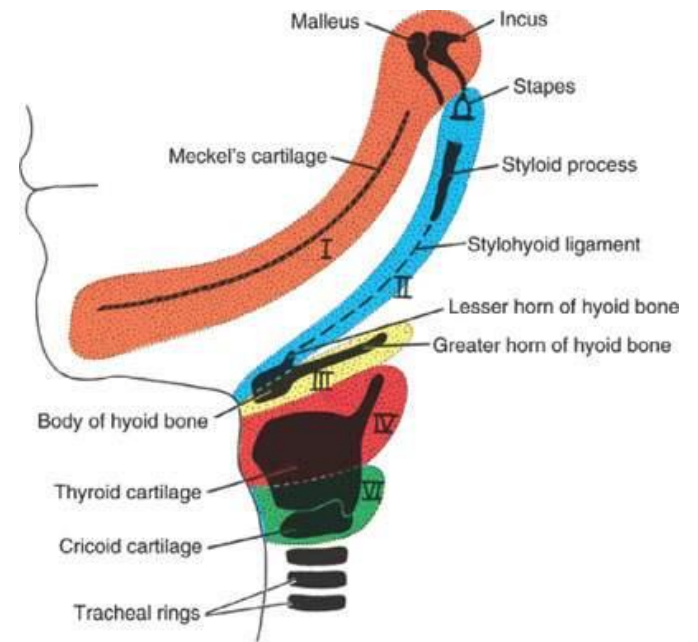
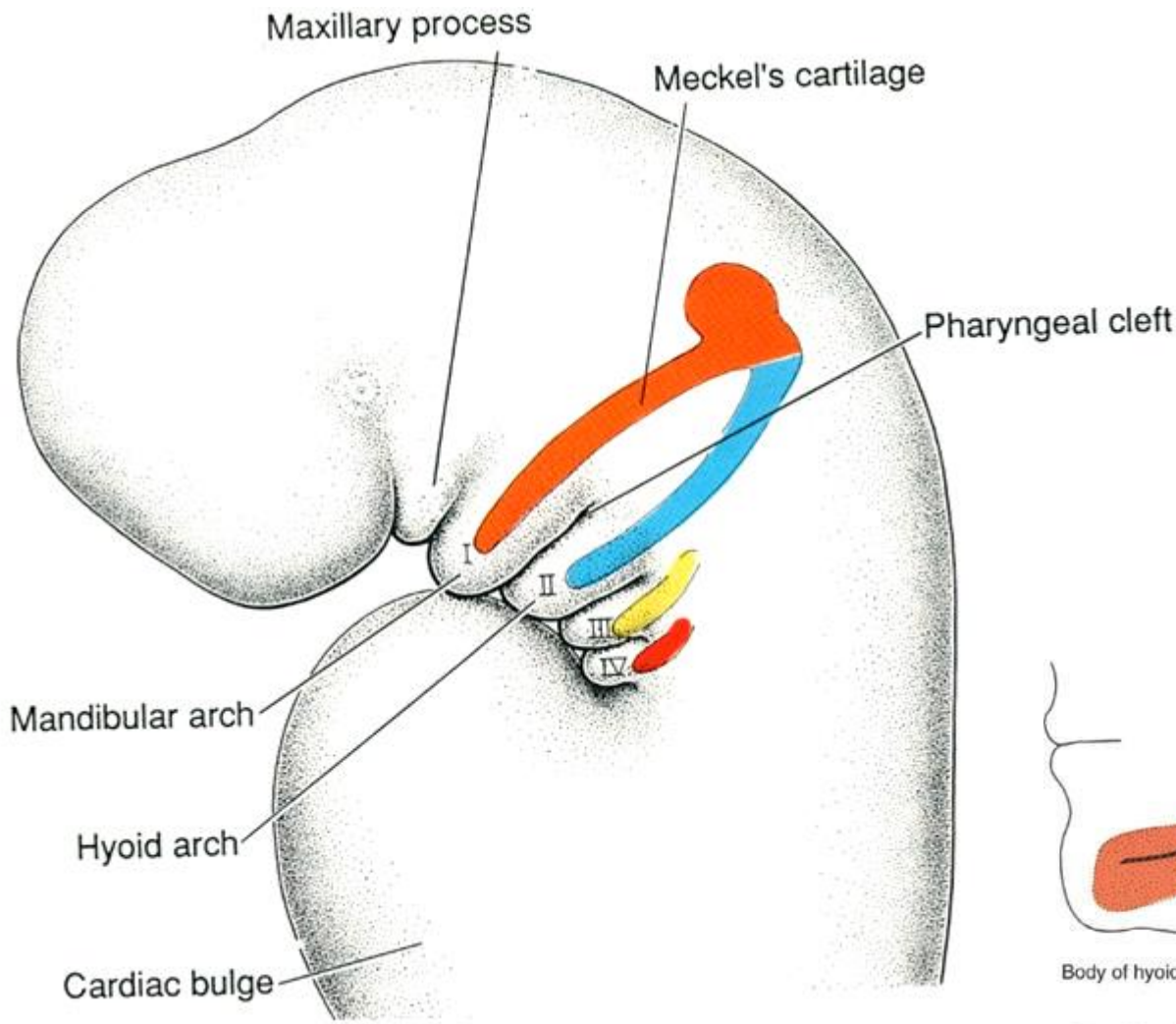
# FARYNGOVÝ APARÁT A JEHO DERIVÁTY

Derivát ektodermové brázdy	Faryngový oblouk	Aortální oblouk	Kraniální nerv	Příklad branchiomerních svalů	Deriváty skeletu	Deriváty entodermové výchlípký
vnější zvukovod	1 mandibulární	a. maxillaris	V trigeminus	žvýkácí	kladívko, kovadlinka lig. sphenomandib. Meckelova chrupavka	středoušní dutina, tuba auditiva
zanikají	2 hyoidní	a. stapedia a. hyoidea	VII facialis	mimické	třmínek proc. styloideus, hyoidní chrupavka	fossa tonsillaris
	3	a. carotis interna	IX glossopharyn geus	m. stylopharyn geus	hyoidní chrupavka	thymus, příštítná tělíska (inf)
	4	a. subclavia dx. a. arcus aortae	X vagus	svaly faryngu a laryngu	laryngeální chrupavky	příštítná tělíska (sup)

# ABNORMALITY FARYNGOVÉHO APARÁTU



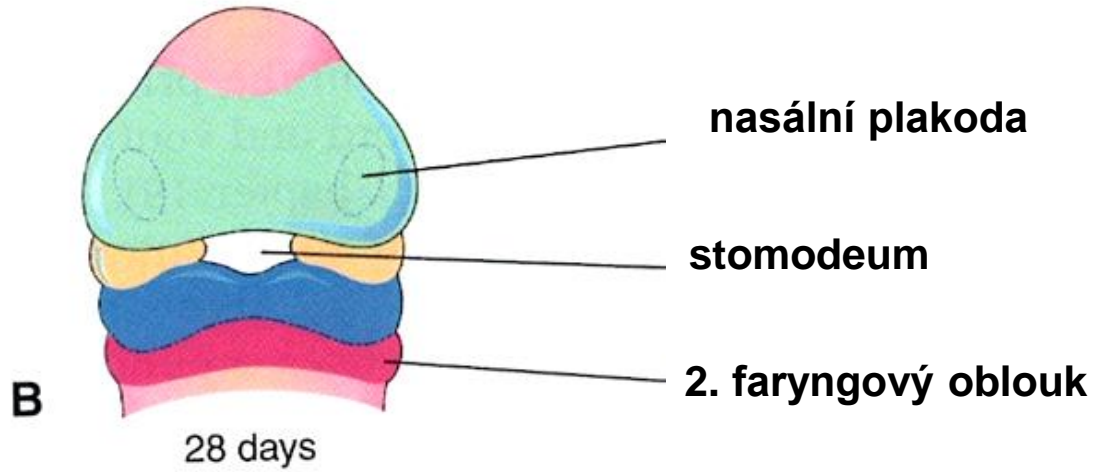
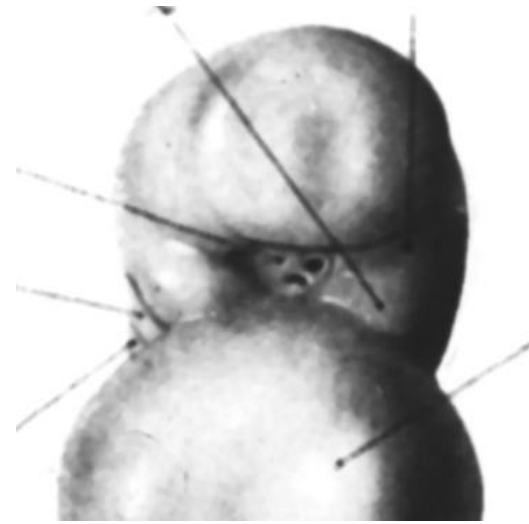
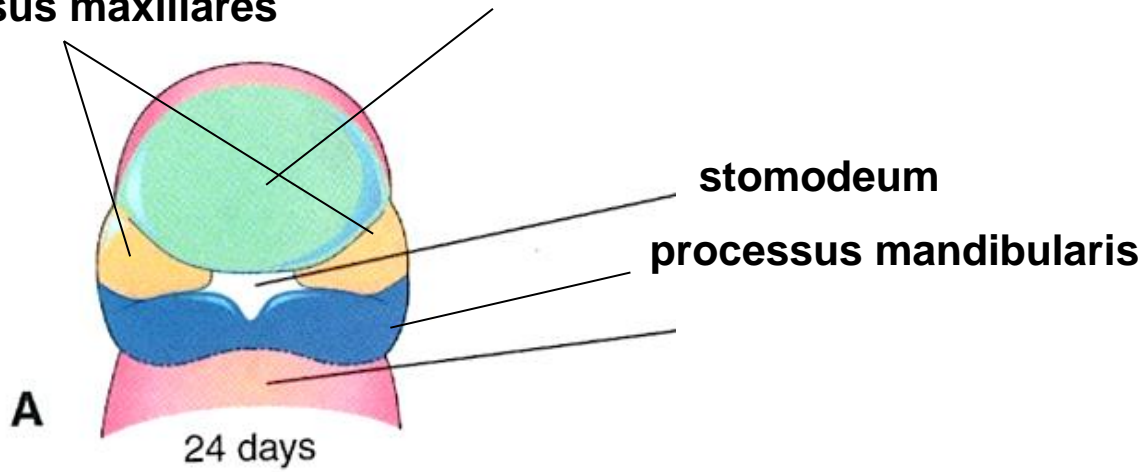
# VÝVOJ OBLIČEJE



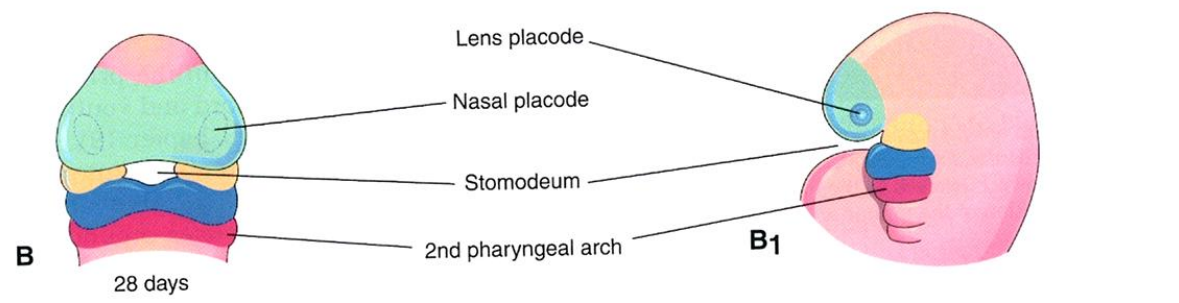
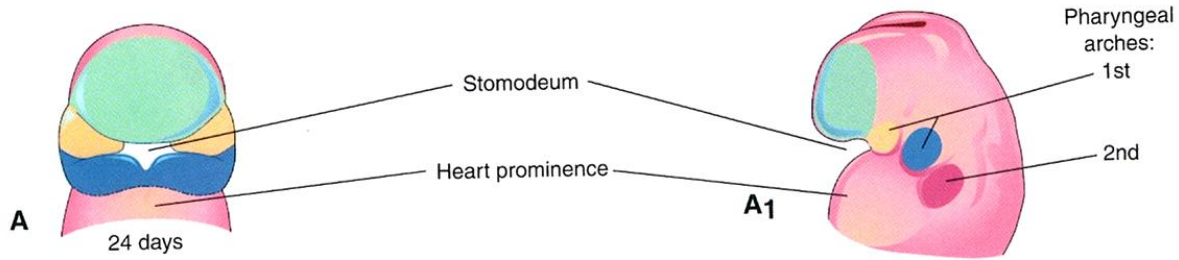
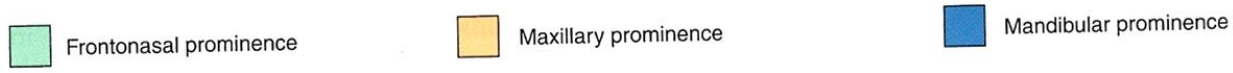
# VÝVOJ OBLIČEJE

processus frontonasalis

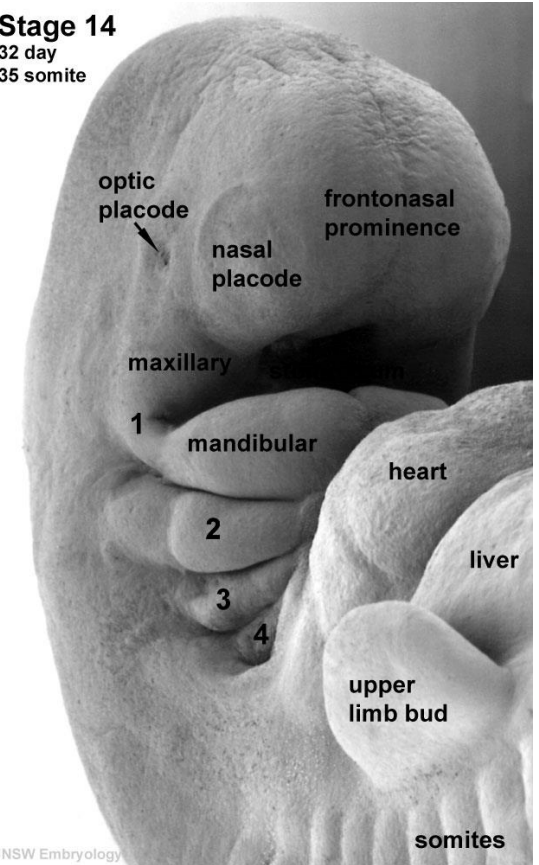
processus maxillares



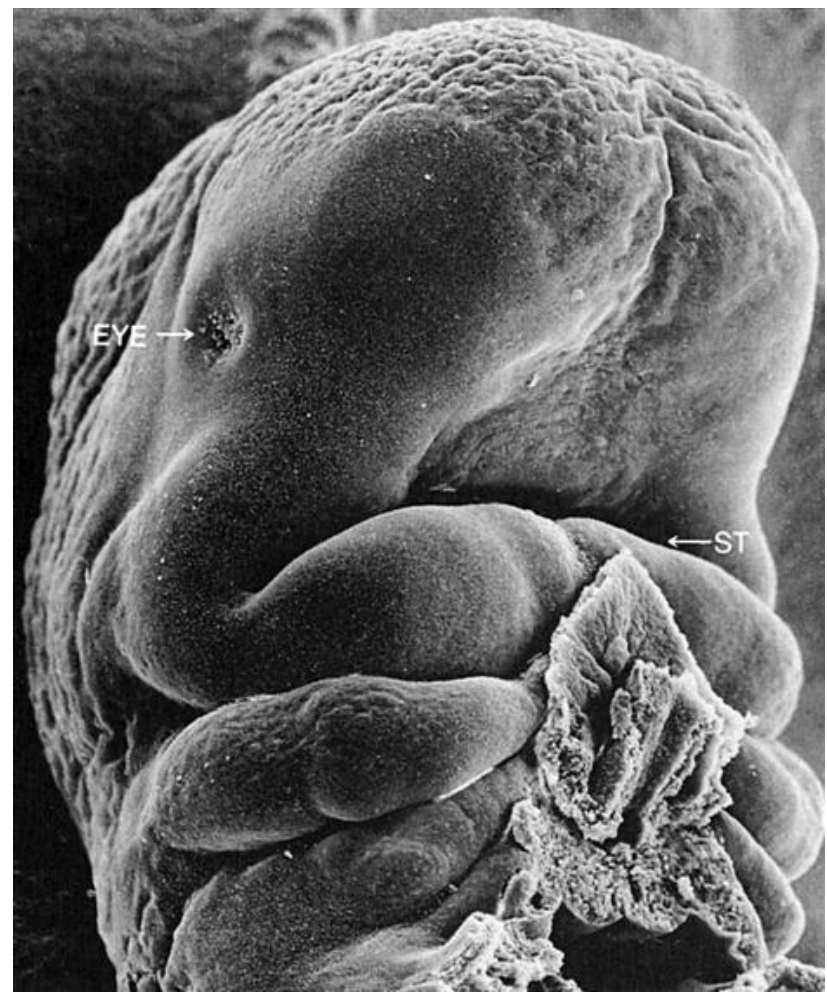
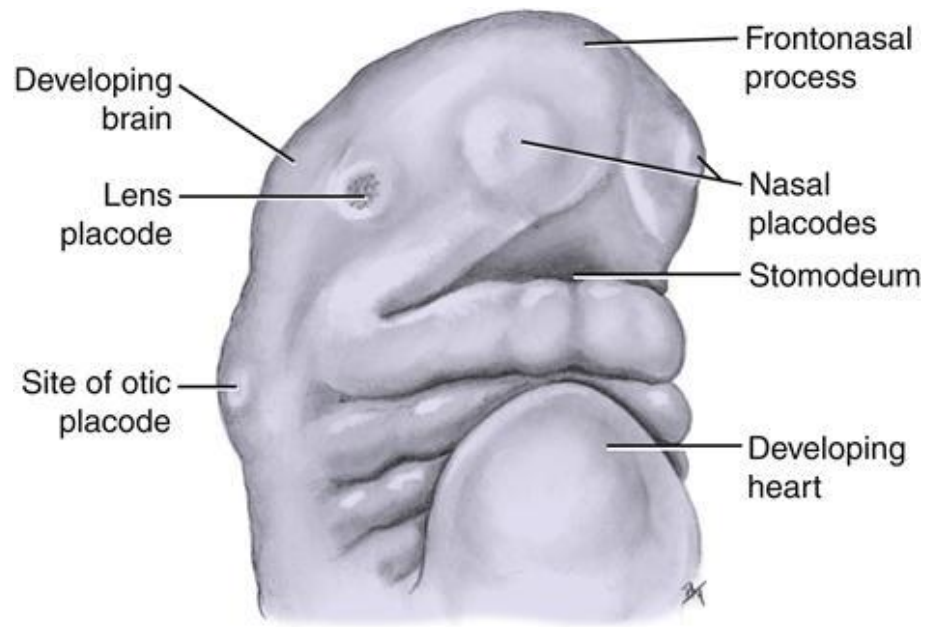
# VÝVOJ OBLIČEJE



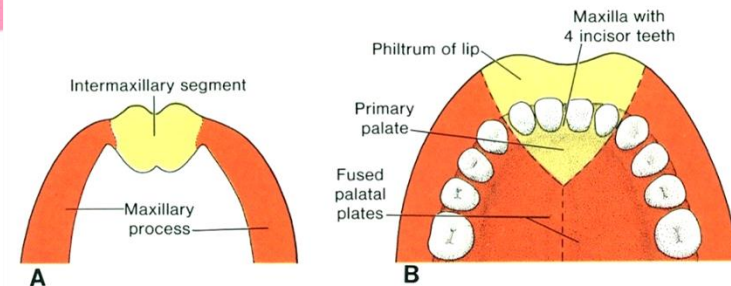
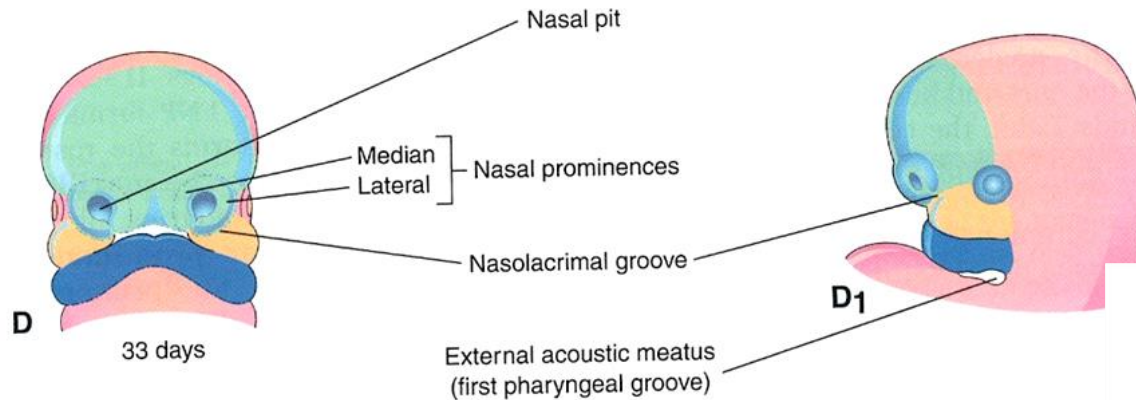
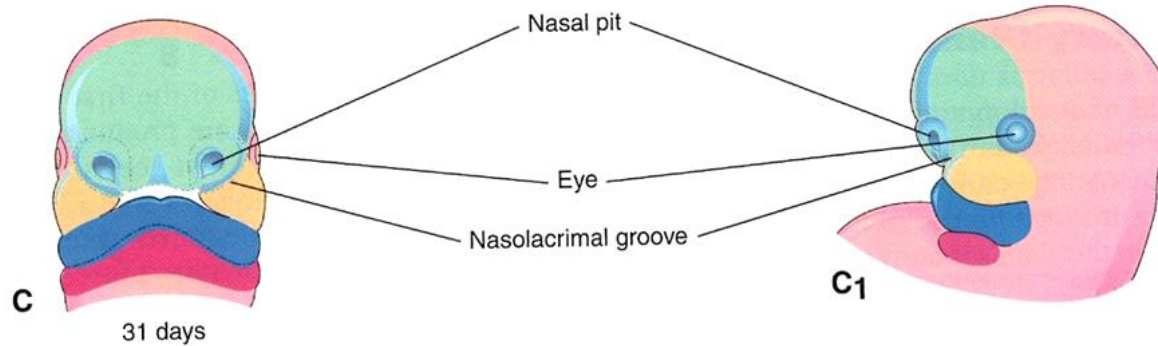
**Stage 14**  
 32 day  
 35 somite



4. týden

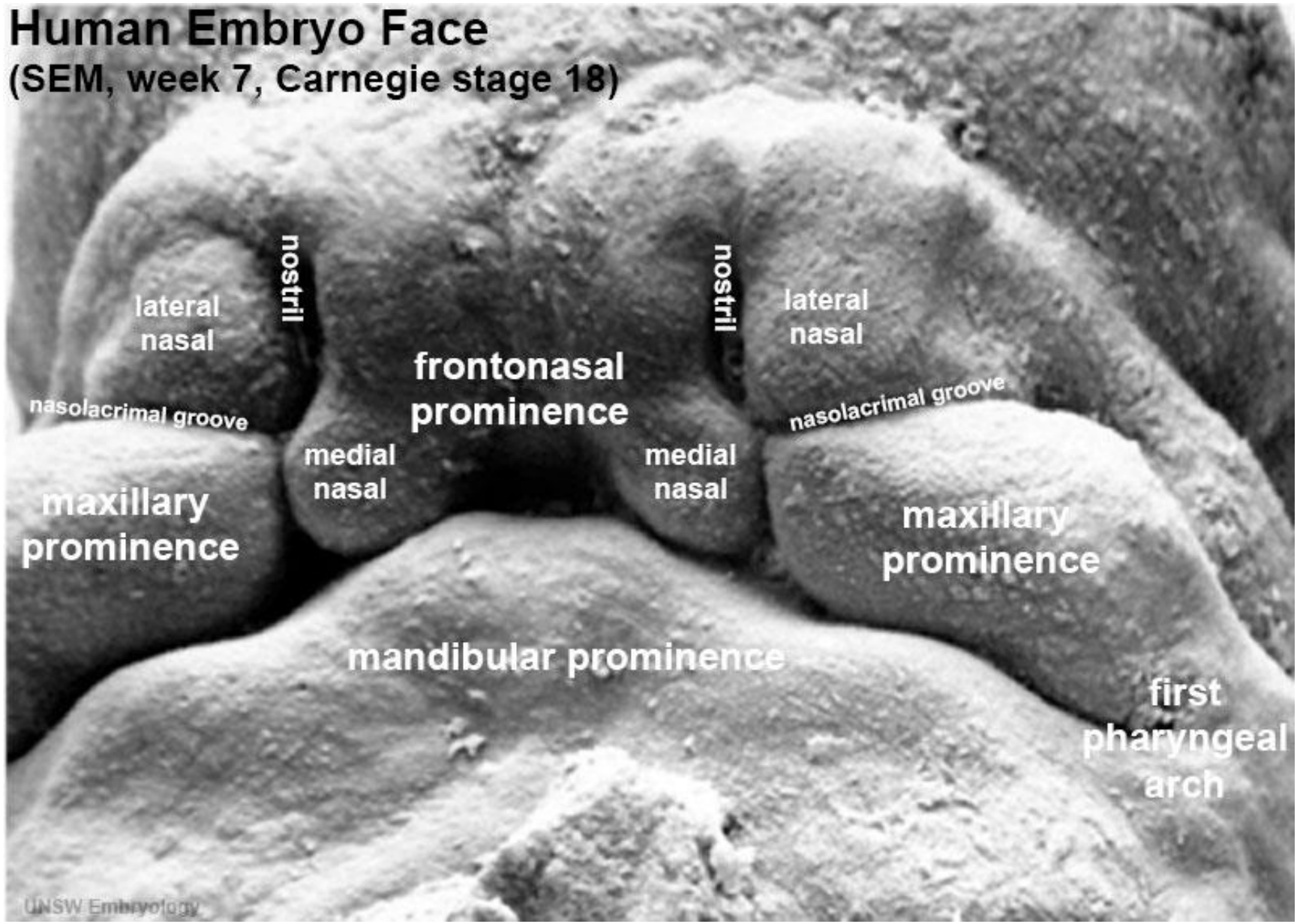


# VÝVOJ OBLIČEJE



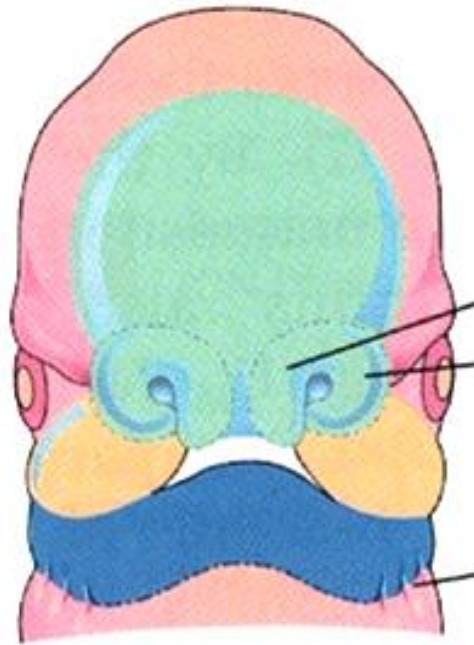
- čichové jamky jsou ohraničeny vally – **mediální a laterální nosní vally**
- zbytek čelního valu - **area triangularis** (základ pro hřbet a hrot nosu)
- mediální nosní vally spolu srostou a vsouvají se mezi maxilární výběžky jako **intermaxilární segment** (střední část horního rtu, část horní čelisti v oblasti řezáků a části patra – **primární patro**)

# Human Embryo Face (SEM, week 7, Carnegie stage 18)

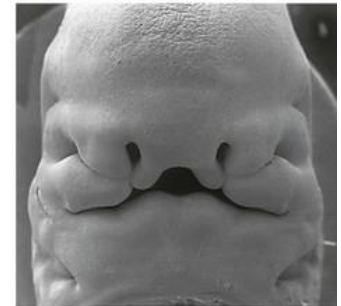
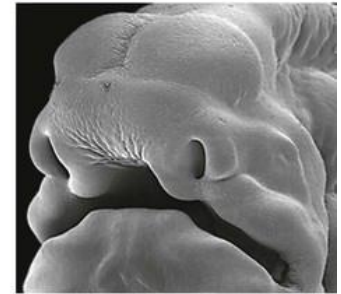
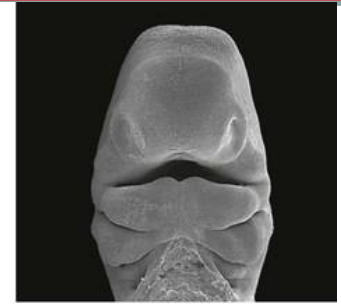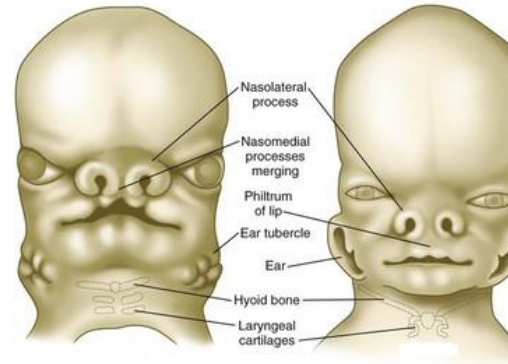
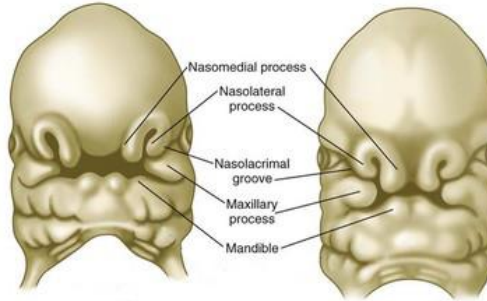
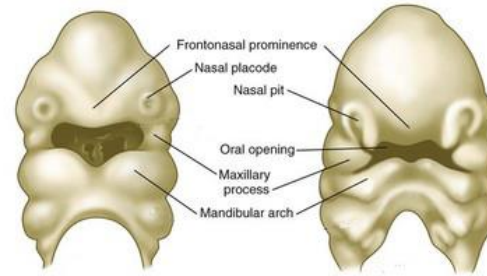




# VÝVOJ OBLIČEJE

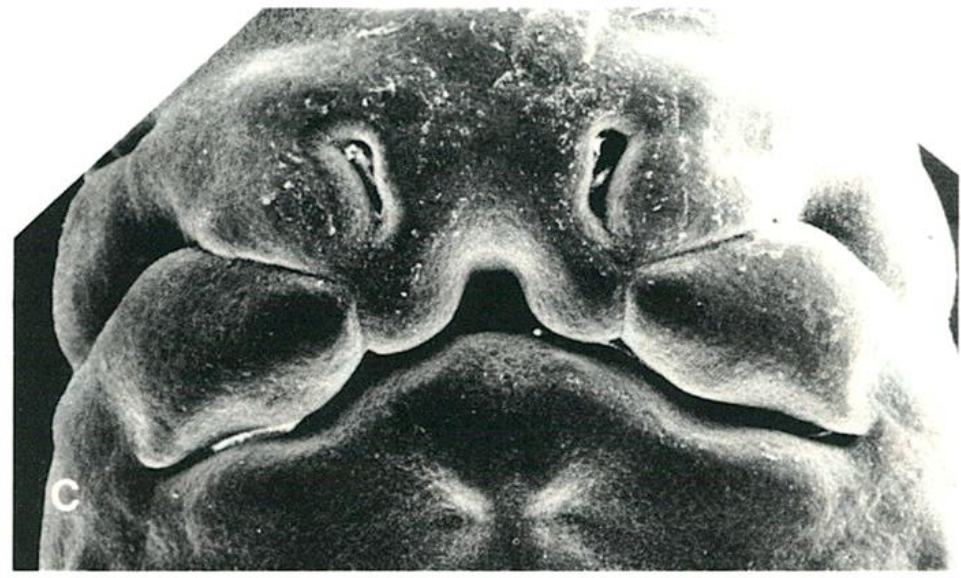
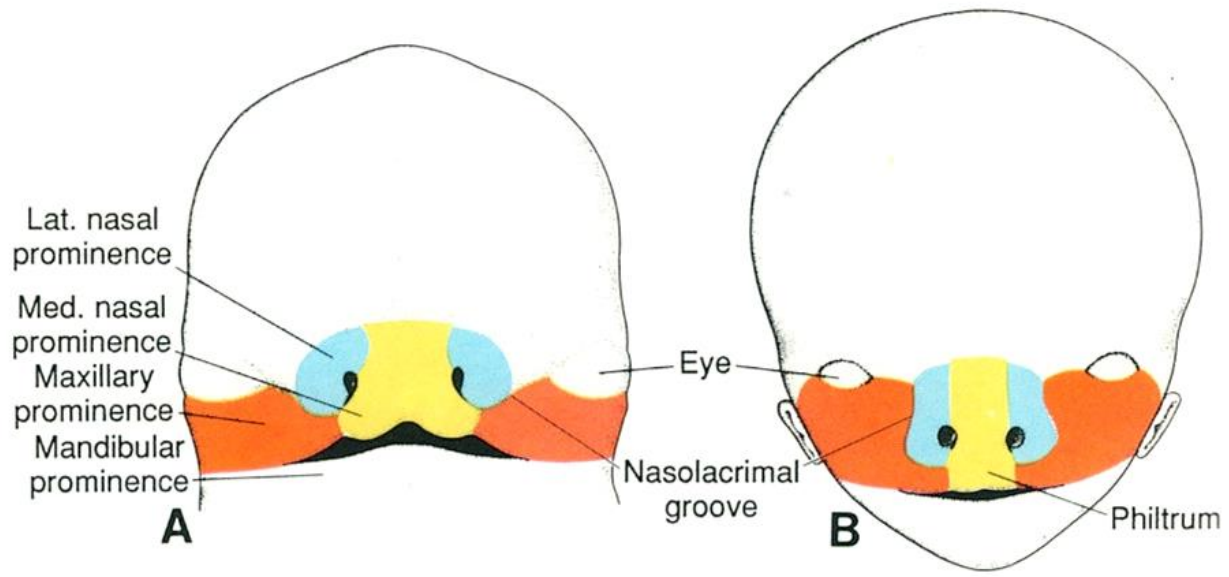


35 days



- **maxilární výběžky srostou**
  1. s **intermaxilárním segmentem** (vytvoření horní čelisti a rtu)
  2. s **laterálními nosními valy** – (zbytek horní čelisti a křídla nosu)
- laterální nosní valy jsou od maxilárních výběžků zpočátku odděleny rýhou – **sulcus nasolacrimalis**, která se uzavře a vytvoří **slzný kanálek**

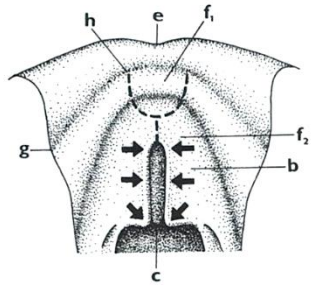
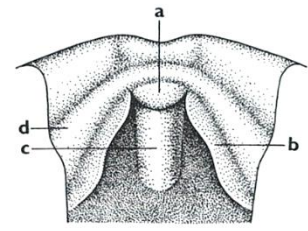
# VÝVOJ OBLIČEJE



7. týden

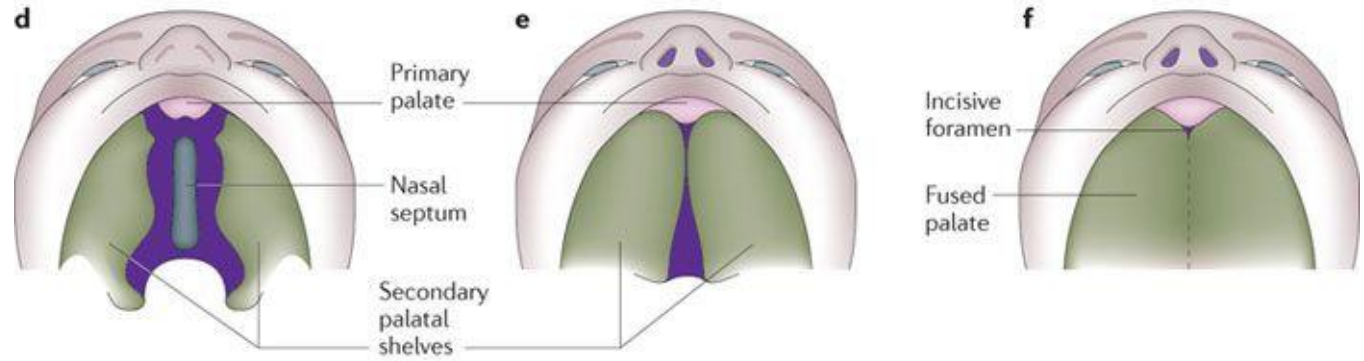
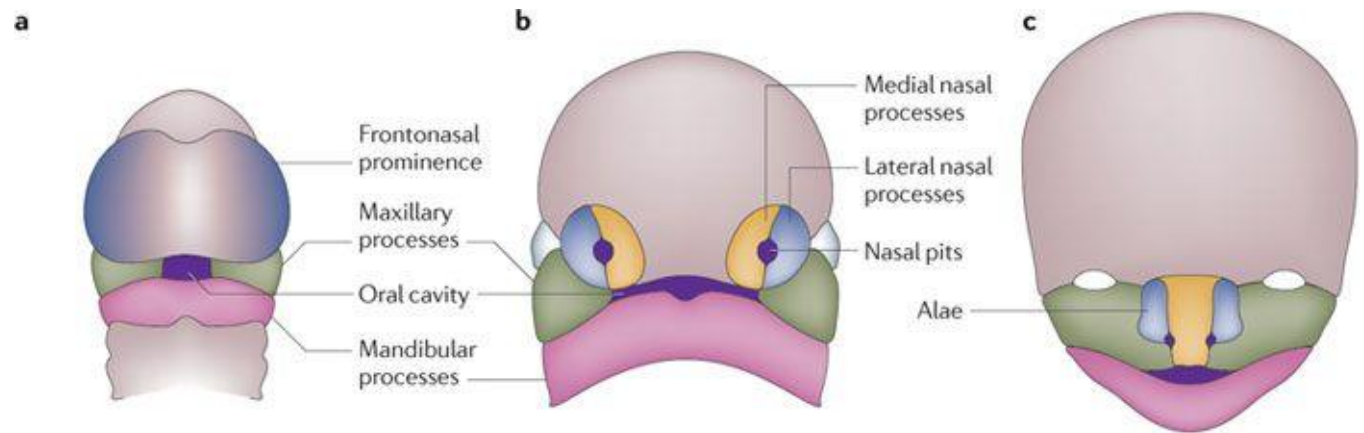
# VÝVOJ OBLIČEJE - PATRO

- **primární patro** (intermaxilární segment)
- **sekundární patro** (laterální patrové ploténky)

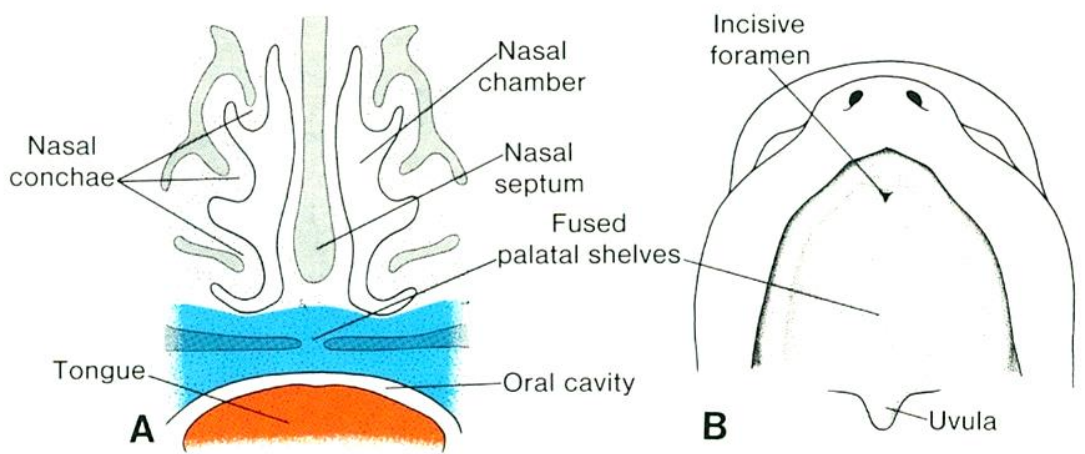
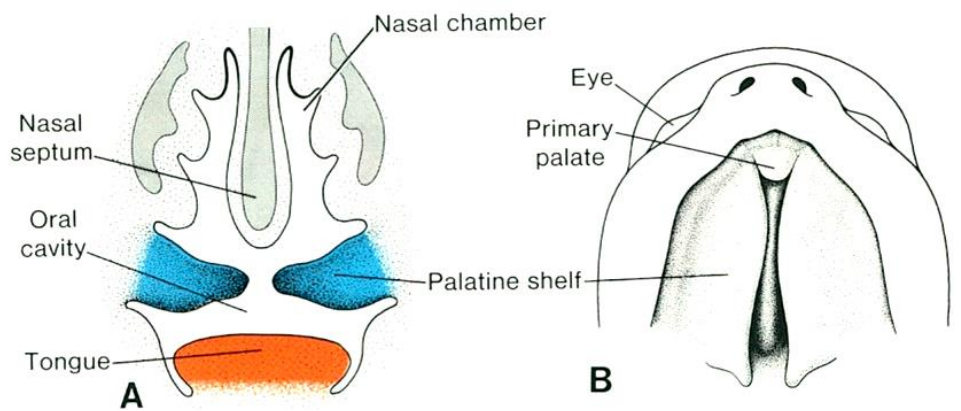
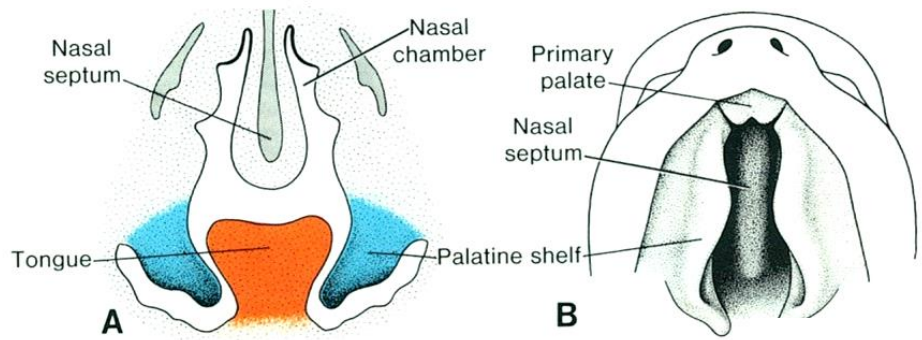


A

B



# VÝVOJ OBLIČEJE - PATRO





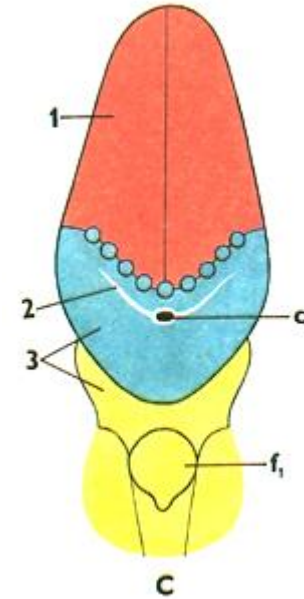
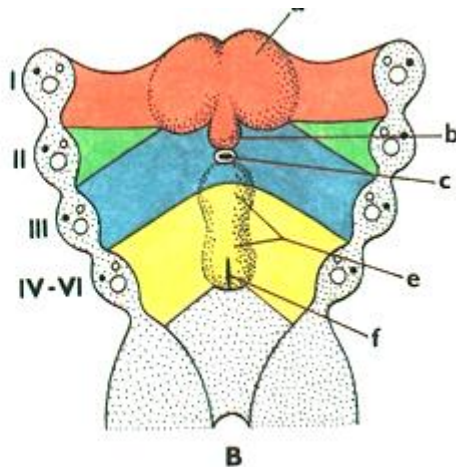
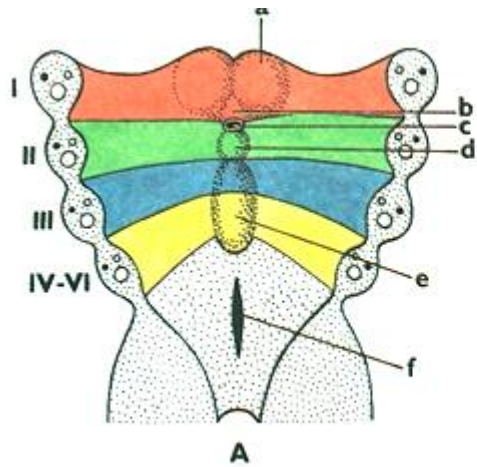
# VÝVOJ JAZYKA

## Základem jazyka je mezenchym faryngových oblouků I, III, IV

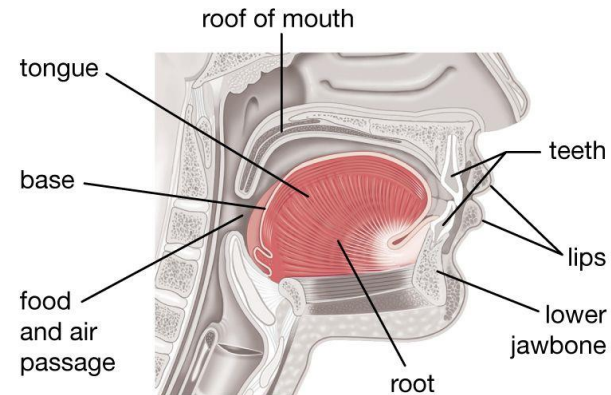
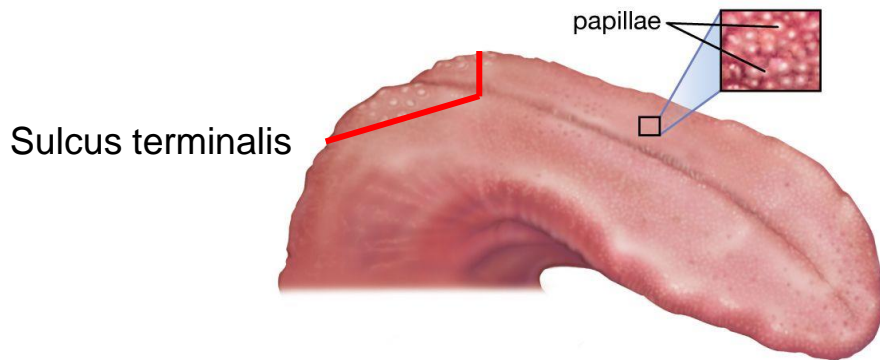
I. tuberculum linguale laterale (dx. et sin.) + tuberculum impar (linguale mediale) → **apex a corpus**

III-IV. copula + eminentia hypobranchialis → **radix**

Svalové buňky z okcipitálních myoblastů



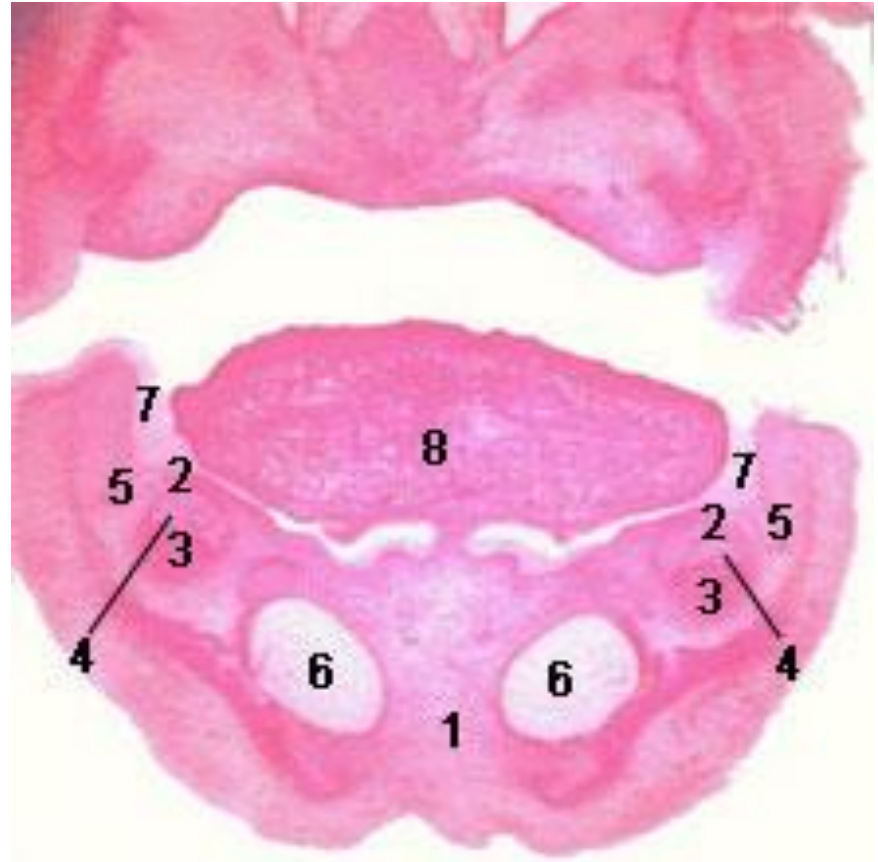
The human tongue



## Vestibulární lišta

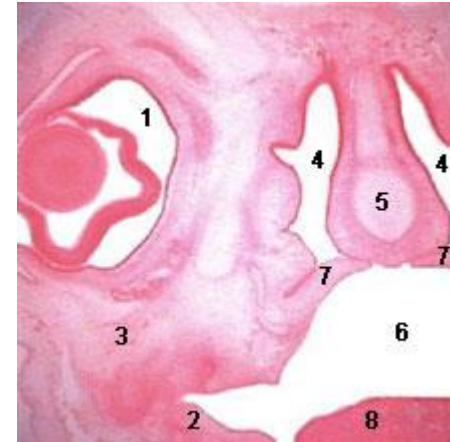
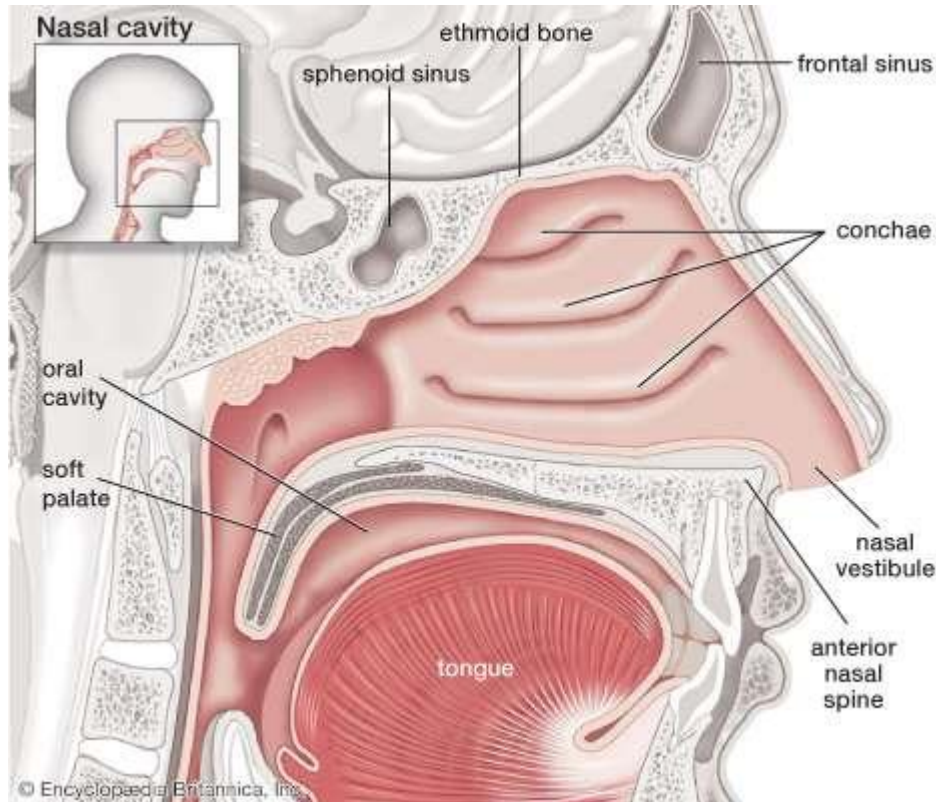
- definitivní ret
- gingivální val

1. Mandibula
2. Dentální lamina
3. Dentální papilla
4. Orgán skloviny
5. Labiogingivální lamina
6. Meckelova chrupavka
7. Orální epitel
8. Jazyk



# VÝVOJ VESTIBULUM NASI

- **Nazální kanálky** – primitivní choany
- **Nazální septum** z area triangularis – splývá se sekundárním patrem

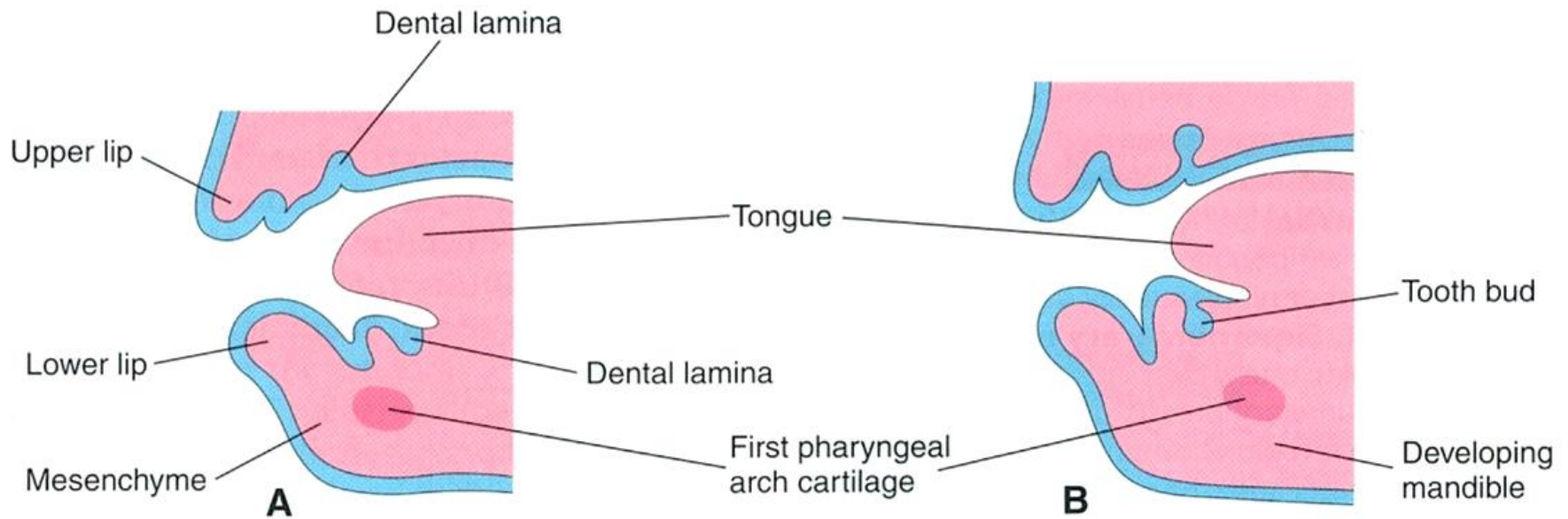


1. Oko
2. Mandibula
3. Maxila
4. Dutina nosní
5. Nosní septum
6. Dutina ústní
7. Patrové výběžky
8. Jazyk



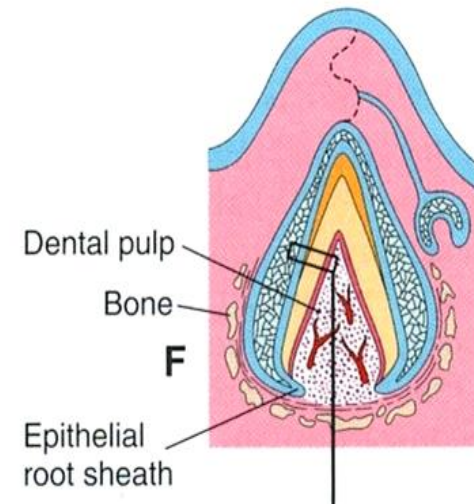
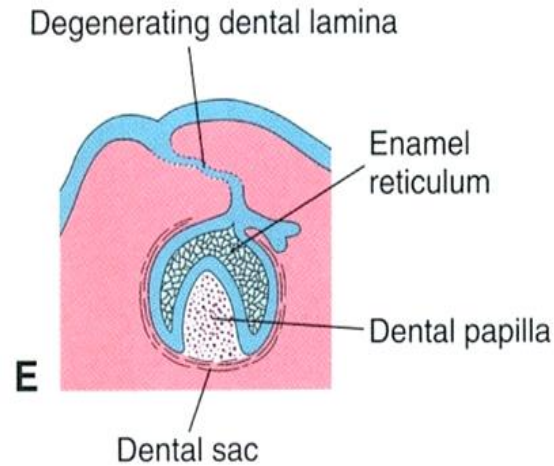
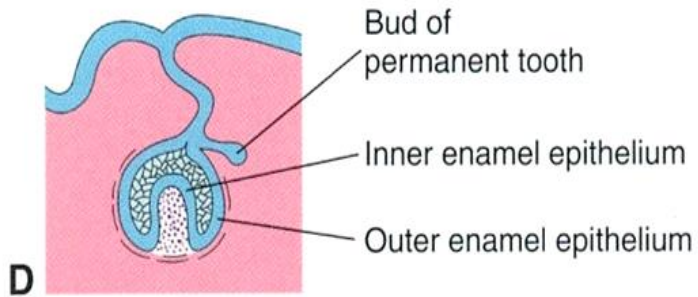
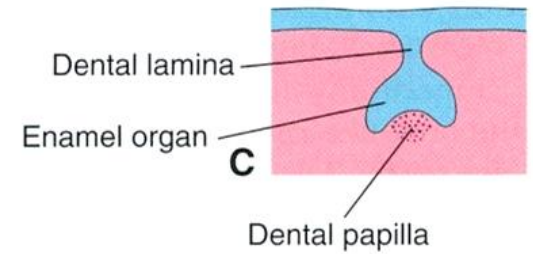
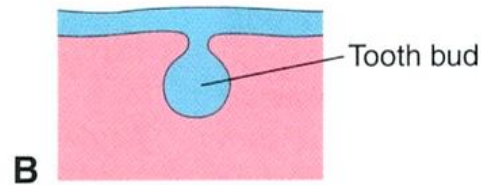
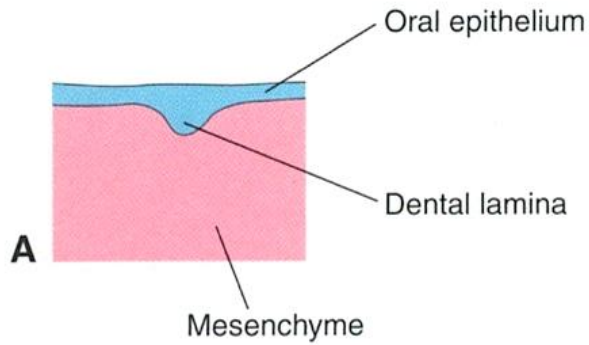
## Interakce ektodermu a mesenchymu

- primární dentální lamina – zubní primordia

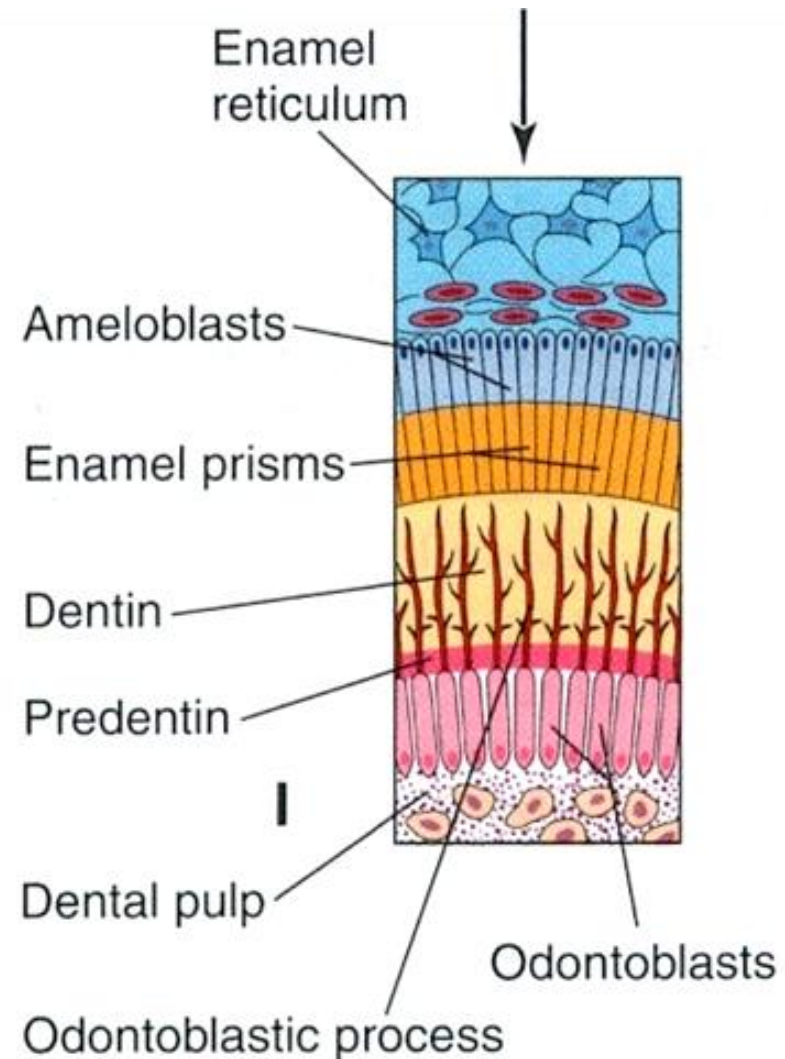
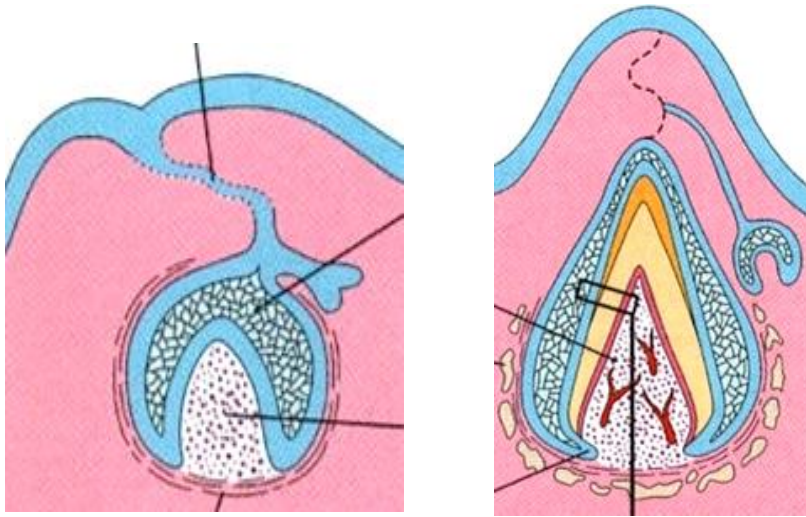


# VÝVOJ ZUBU

- Primordium
- Zubní váček (zubní papila)
- Zubní pohárek (orgán skloviny)



# VÝVOJ ZUBU

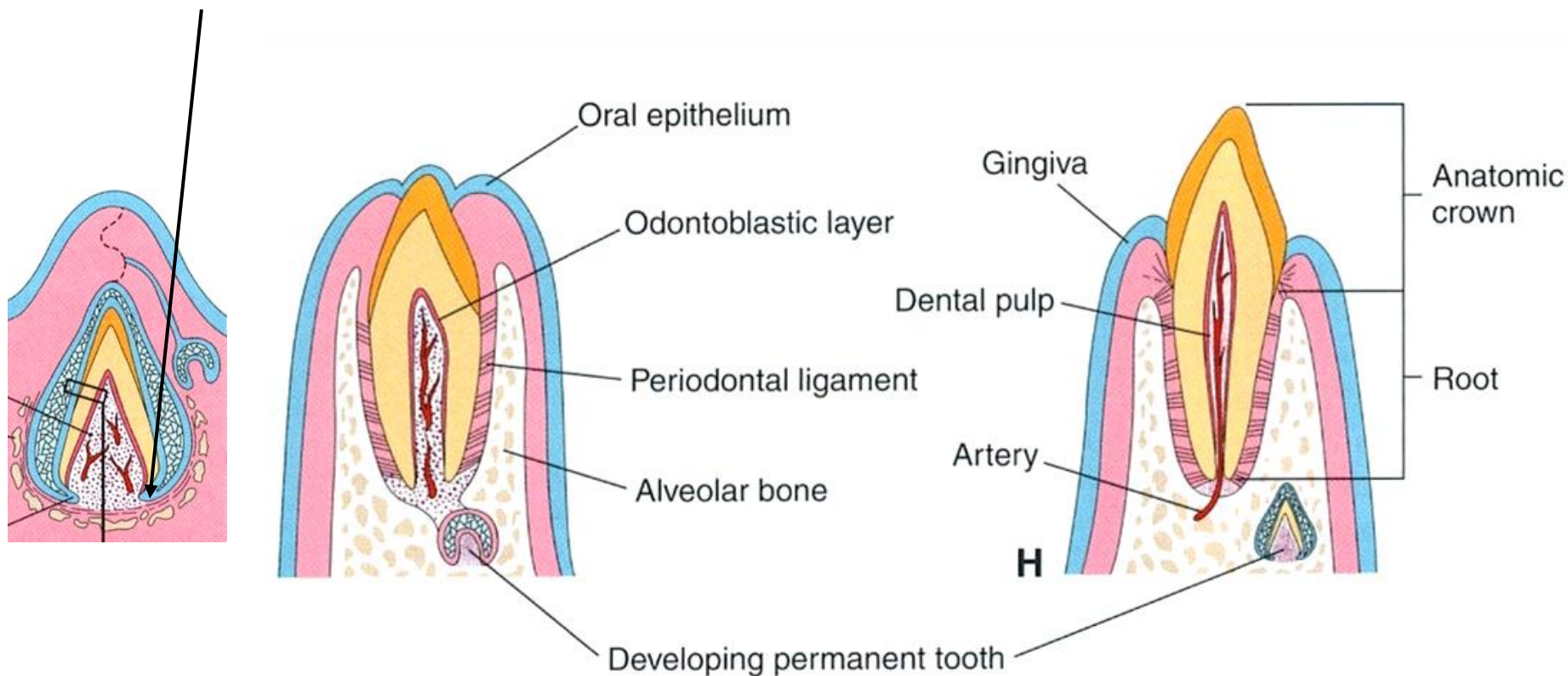


- orgán skloviny (zevní a vnitřní ameloblasty, pulpa skloviny – sklovinné retikulum) - produkce sklovinných prizmat
- diferenciace odontoblastů - ukládání dentinové matrix
- výběžky odontoblastů: Tomesova vlákna

# VÝVOJ ZUBU

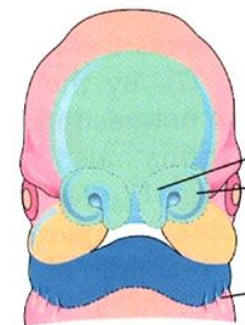
vývoj kořene – prořezání zubu

cervikální klička → Hertwigova kořenová pochva

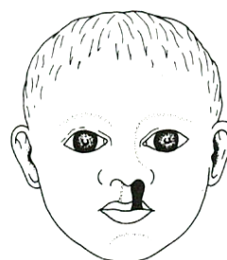

## Rozštěp měkké tkáně

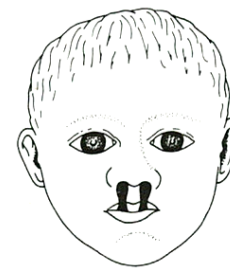
- rozštěp horního rtu (*cheiloschisis*) – laterální (uni, bi), mediální
- rozštěp dolního rtu – mediálně, kombinovaný s dalšími vadami (čelist, jazyk) – *gnathoschisis et cheiloschisis inf.*
- šikmý rozštěp (*fissura orbitofacialis*)
- příčný rozštěp (*fissura transversa*)



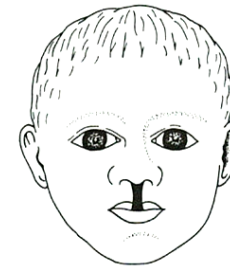
35 days



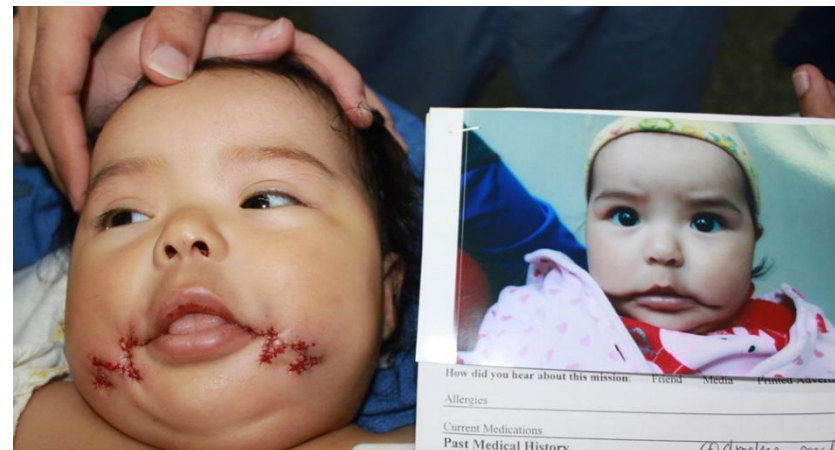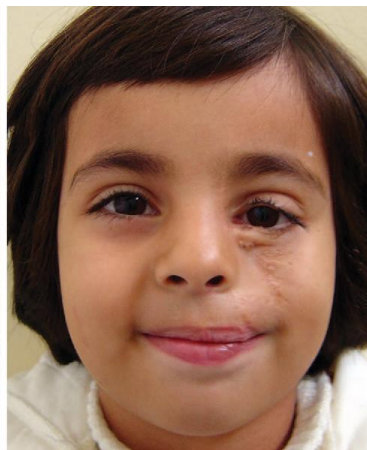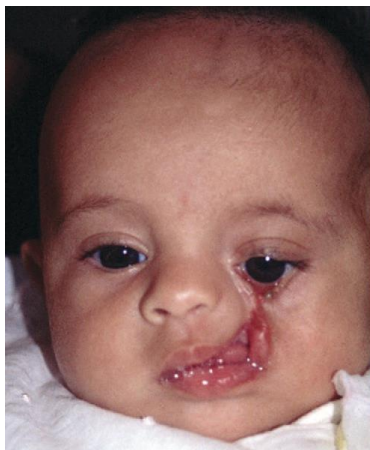A



B



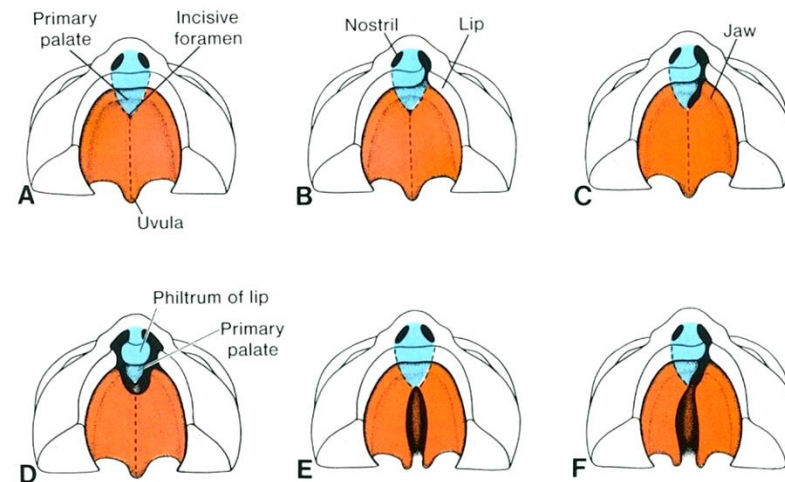
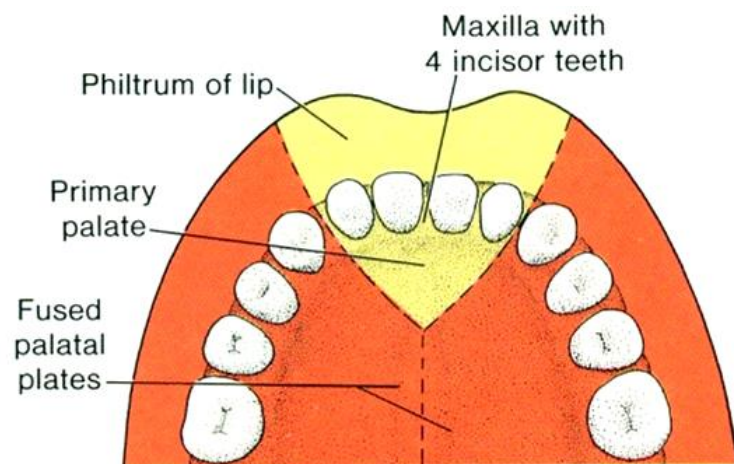
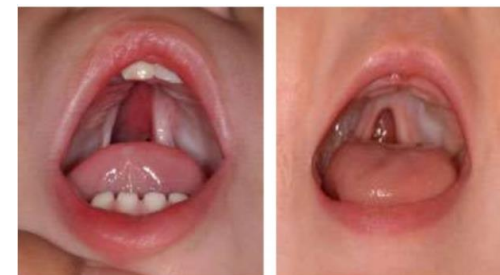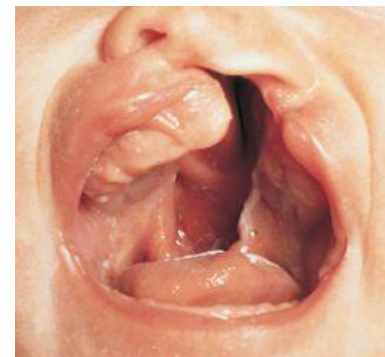C



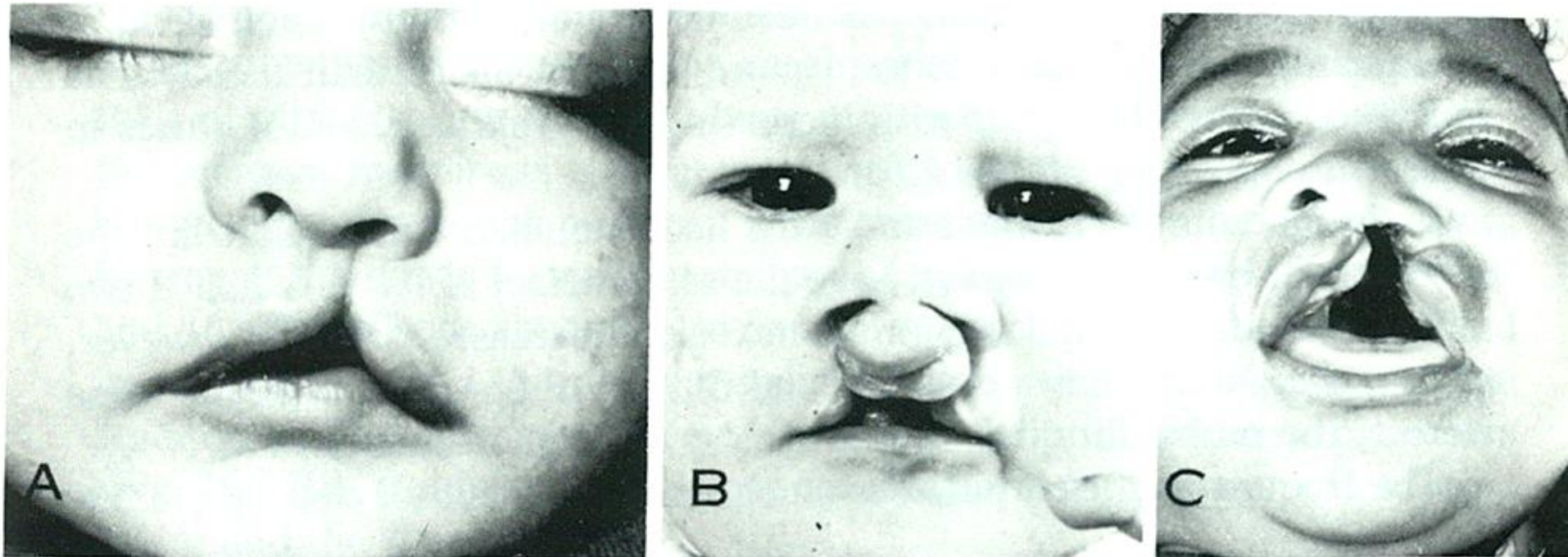
# ABNORMALITY VÝVOJE OBLIČEJE - ROZŠTĚPOVÉ VADY

## Rozštěp tvrdé tkáně

- horní čelist
- mezi špičkem a 2. řezákem
- unilaterálně nebo bilaterálně
- kombinována s rozštěpem patra (*cheilognathoschisis*)
- patro (*palatoschisis*)
- primární (před foramen incisivum)
- sekundární (za foramen incisivum)
- sdružené vady: *cheilognathopalatoschisis*



**Figure 16-25.** Ventral view of the palate, gum, lip, and nose. **A**, Normal. **B**, Unilateral cleft lip extending into the nose. **C**, Unilateral cleft involving lip and jaw, and extending to incisive foramen. **D**, Bilateral cleft involving lip and jaw. **E**, Isolated cleft palate. **F**, Cleft palate combined with unilateral anterior cleft.



**Figure 16-26.** Photographs of incomplete cleft lip (A), bilateral cleft lip (B), and cleft lip, cleft jaw, and cleft palate (C). (Courtesy Dr. M. Edgerton, Department of Plastic Surgery, University of Virginia.)

# Děkuji za pozornost

pvanhara@med.muni.cz

<http://www.histology.med.muni.cz>