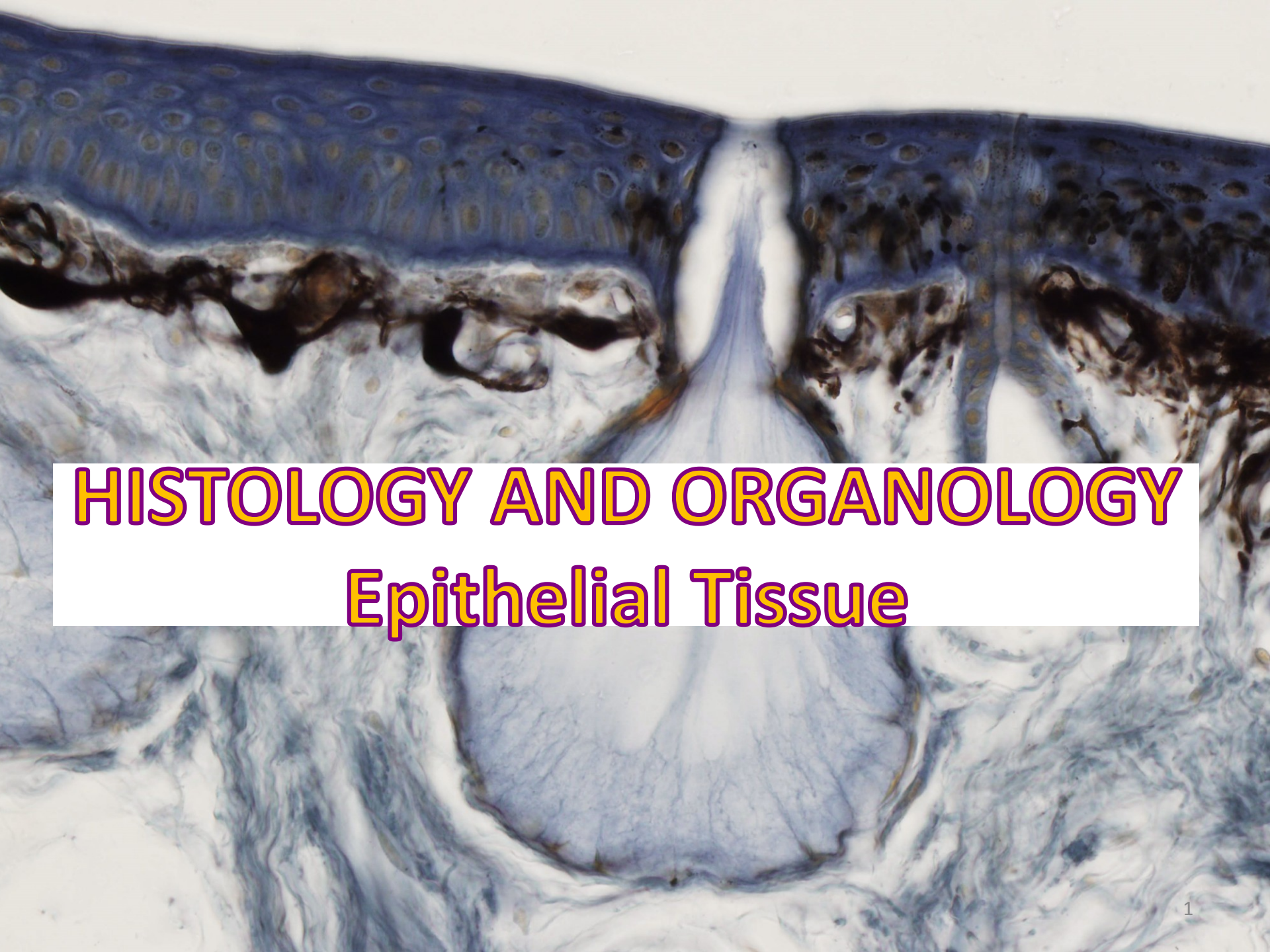



HISTOLOGY AND ORGANOLOGY

Epithelial Tissue

EPITHELIAL TISSUE

GENERAL FEATURES OF ALL EPITHELIAL TISSUES

- Highly **cellular**, epithelial cells **vary** in shape and size
- Numerous **intercellular junctions** for attachment and anchorage
- **Avascular**
- High **proliferative capacity** (especially in epithelial membranes, to replace continual sloughing of cells from free surface)
- Most rest on a **basement membrane**: extracellular structure that separates epithelial cells from underlying connective tissue. It provides structural support to epithelial tissues and helps anchor the cells in place. is composed of proteins, glycoproteins, and collagen fibers, contributing to the overall stability and integrity of epithelial layers. It also plays a crucial role in regulating the exchange of molecules between the epithelium and the underlying tissue.
- **The embryological origin**: epithelial tissues are derived from all of the embryological germ layers (from ectoderm e.g., the epidermis; from endoderm e.g., the lining of the gastrointestinal tract; from mesoderm e.g., the inner linings of body cavities).
- **Free and basal surfaces of epithelia**
 - Basal surface contacts the basal lamina of the basement membrane.
 - Free surface interfaces with the external environment or spaces within the body.

EPITHELIAL TISSUE

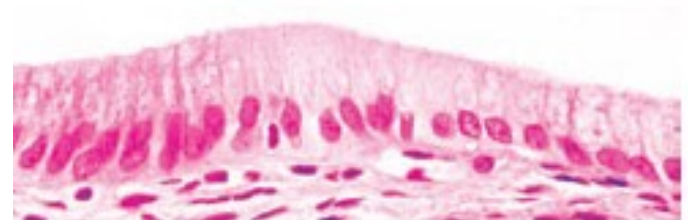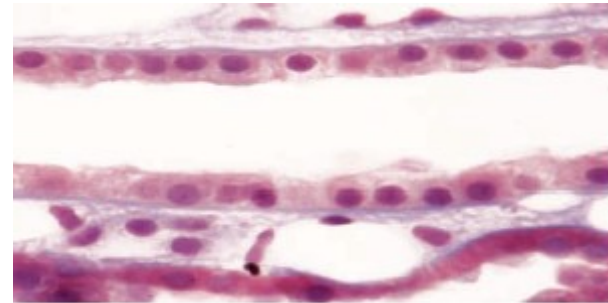
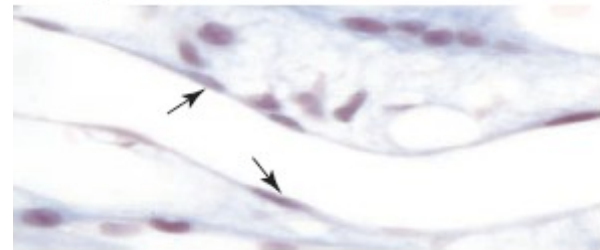
- **Polarity** – epithelia exhibit functional and morphologic polarity. A polarized cell is one that exhibits contrasting properties or structures on opposite sides of the cell. Because epithelial tissues face a free surface, the function of the apical surface is often very different from that at the base of the cell. This diversification is reflected by the non-homogeneous distribution of organelles.
- **Function of epithelium:**
 - Covering of external surfaces
 - Lining of internal surfaces
 - Protection
 - Absorbtion
 - Secretion
 - Sensory function
 - Contraction
- **Types of epithelium:**
 - Covering and lining epithelium
 - Glandular epithelium

EPITHELIAL TISSUE

CLASSIFICATION OF LINING AND COVERING EPITHELIUM

- Shape of superficial cells
- Number of cell layers
- Presence of specialized structures (cilia, microvili, keratin)

- Shape of superficial cells
 - Squamous
 - Cells are much wider than tall.
 - Nucleus is highly flattened.
 - Cuboidal
 - Cells are of equal height and width.
 - Nucleus is spherical.
 - Columnar
 - Cells are much taller than they are wide.
 - Nucleus is oval shaped, generally located in the mid to lower portions of the cell.



EPITHELIAL TISSUE

CLASSIFICATION OF LINING AND COVERING EPITHELIUM

- **Number of cell layers**
 - **Simple epithelium**
 - One cell layer thick
 - All cells rest on the basement membrane (basal surface) and all cells face the free surface.
 - *Simple squamous*
 - Allows for rapid diffusion across the epithelium
 - Forms the lining of blood vessels, alveoli of the lungs, and internal body cavities
 - *Simple cuboidal*
 - Lines and absorbs
 - Forms the walls of ducts and tubules
 - *Simple columnar*
 - Lines and absorbs
 - Forms the lining of the intestines and gall bladder

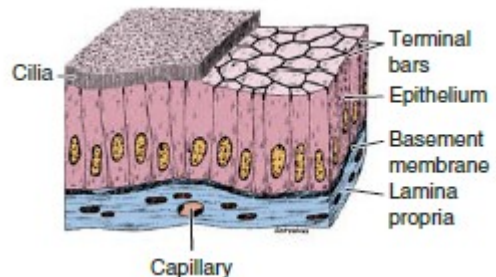
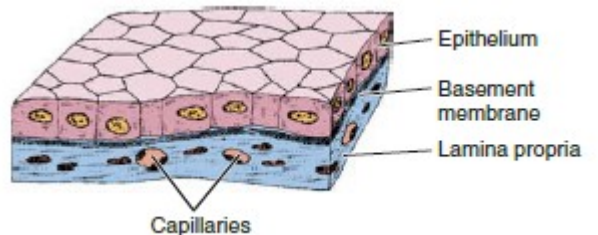
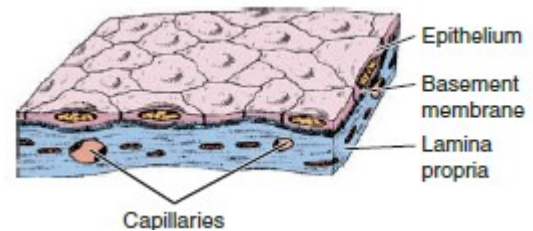


FIG. 5.1 Simple squamous epithelium

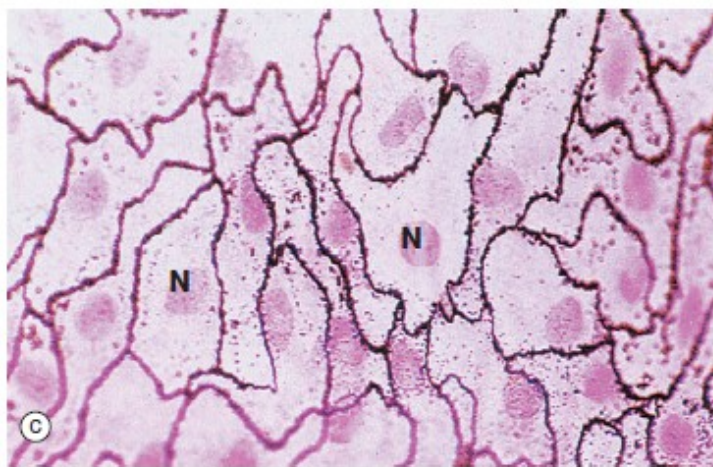
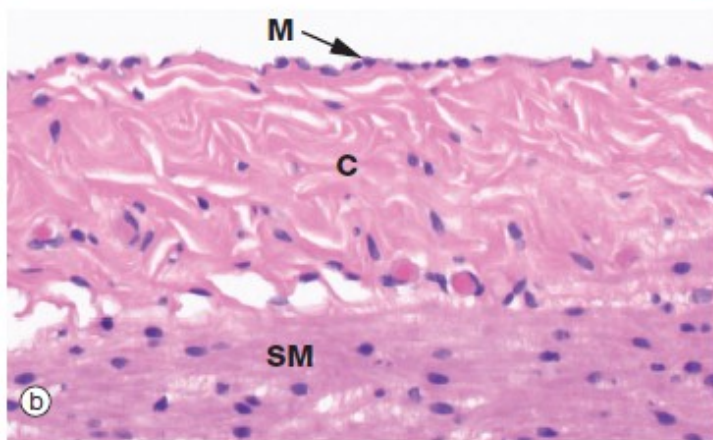
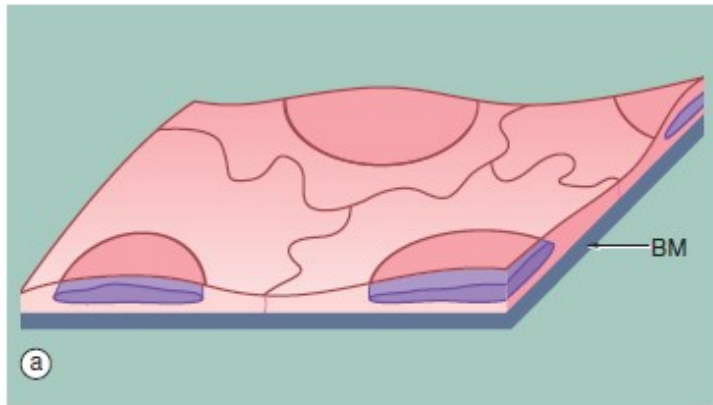
(a) Diagram (b) H&E (HP) (c) Spread preparation, silver method/neutral red (HP)

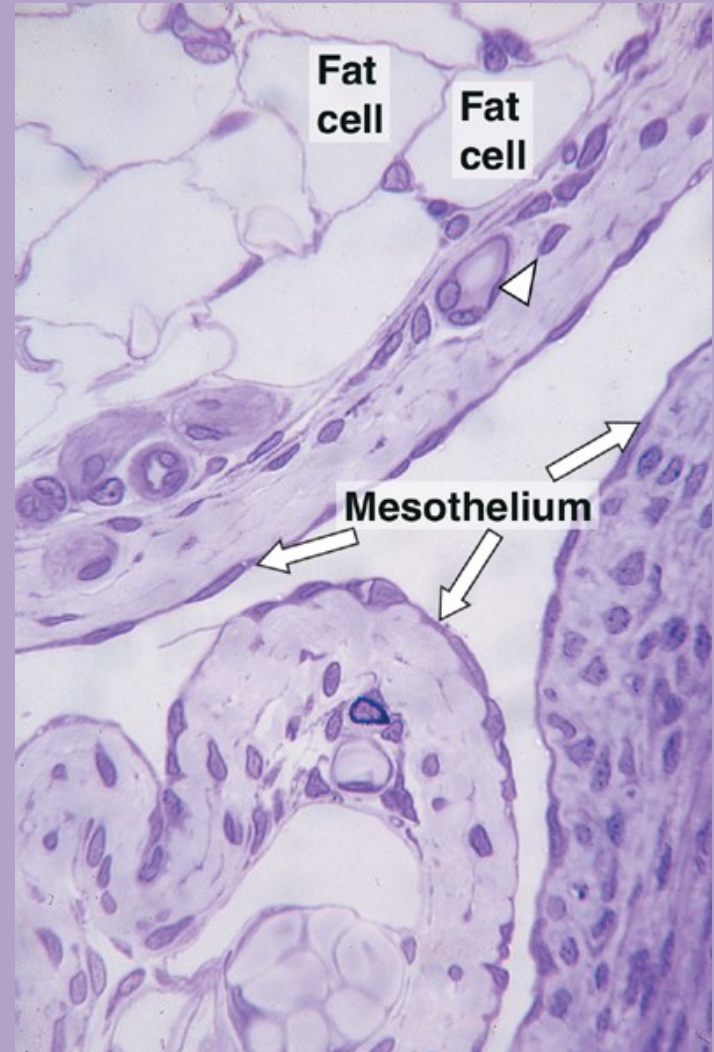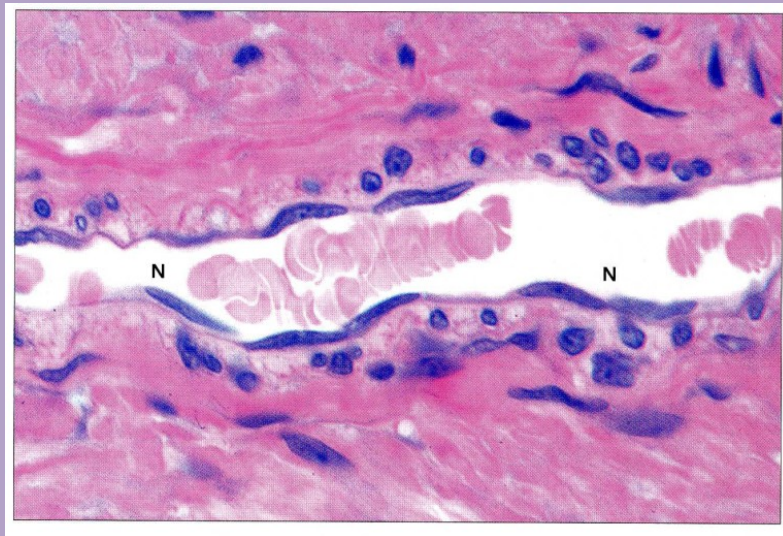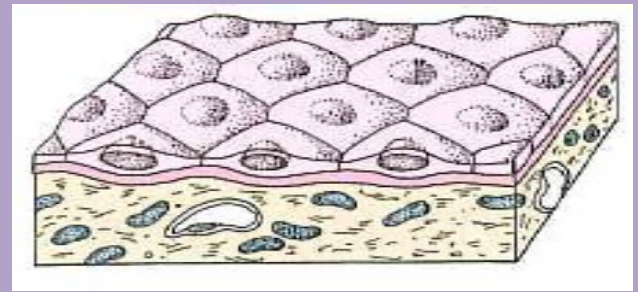
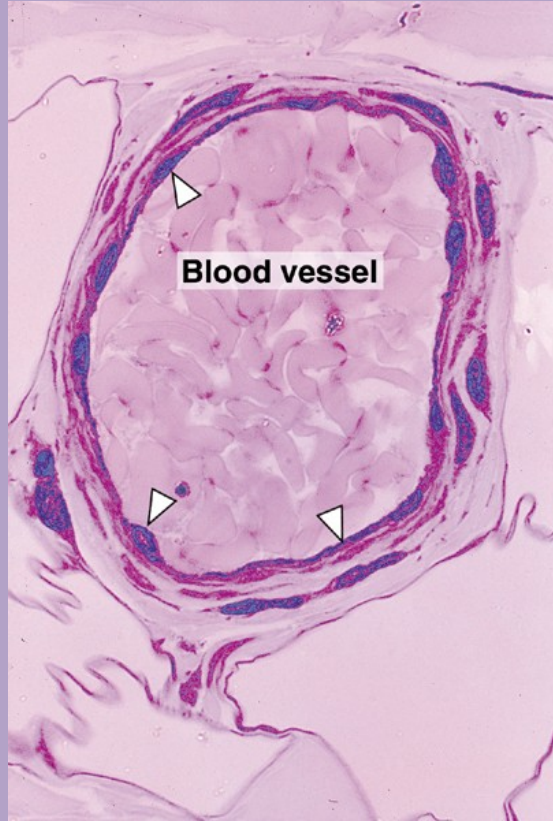
Simple squamous epithelium is composed of flattened, irregularly shaped cells forming a continuous surface that is sometimes called *pavemented epithelium*; the term *squamous* derives from the comparison of the cells to the scales of a fish. Like all epithelia, this delicate lining is supported by an underlying basement membrane **BM** as shown diagrammatically.

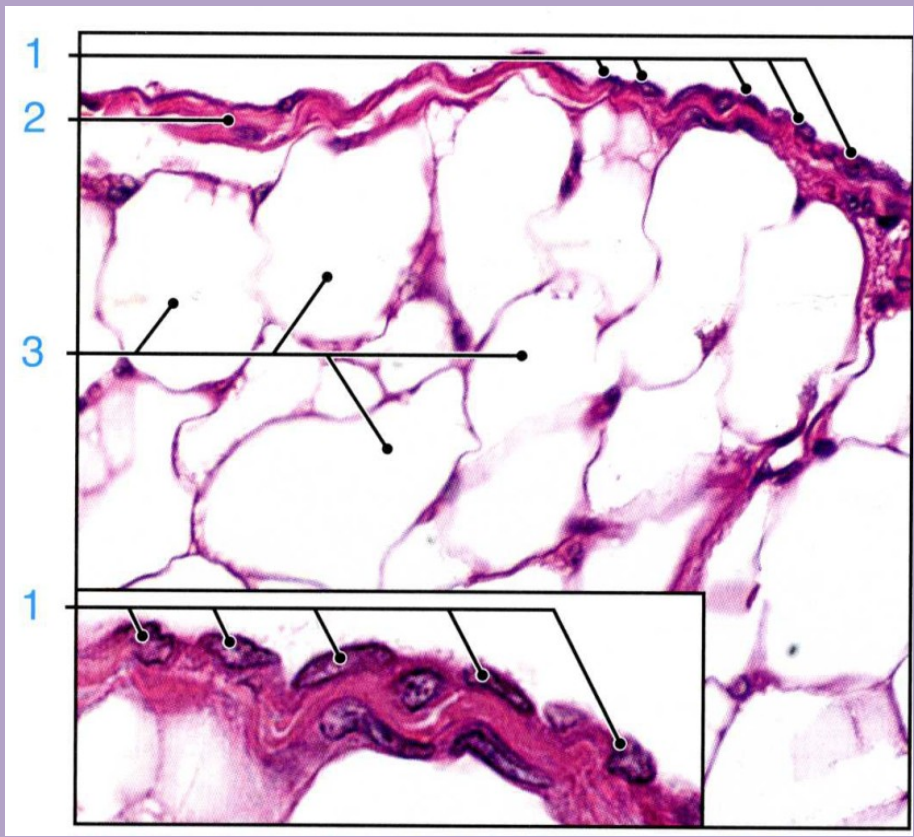
Simple squamous epithelium is found lining surfaces involved in passive transport (diffusion) of either gases (as in the lungs) or fluids (as in the walls of blood capillaries). Simple squamous epithelium also forms the delicate lining of the pleural, pericardial and peritoneal cavities where it allows passage of tissue fluid into and out of these cavities. Although these cells appear simple in form they have a wide variety of important roles.

Micrograph (b) shows a *mesothelium* (peritoneum) covering the surface of the appendix and illustrates the typical appearance of simple squamous epithelium in section. The mesothelial lining cells **M** are so flattened that they can only be recognised by their nuclei, which bulge on the surface. The supporting basement membrane is thin and, in H&E stained preparations, has similar staining properties to the underlying collagenous supporting tissue **C**; hence it cannot be seen in this micrograph. Deeper in the wall of the appendix, the smooth muscle **SM** of the muscularis propria can be identified.

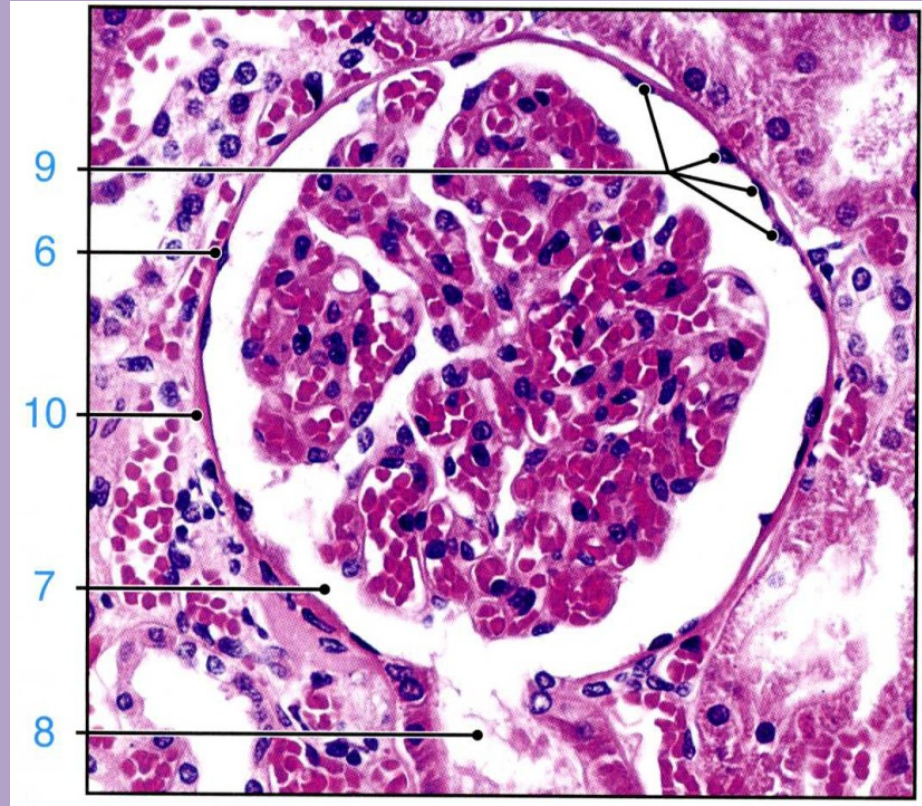
In the preparation used in micrograph (c), the mesothelial lining of the peritoneal cavity has been stripped from the underlying tissues and spread onto a slide, thus permitting a surface view of simple squamous epithelium. The intercellular substance has been stained with silver thereby outlining the closely interdigitating and highly irregular cell boundaries. The nuclei **N** are stained a slightly darker pink.





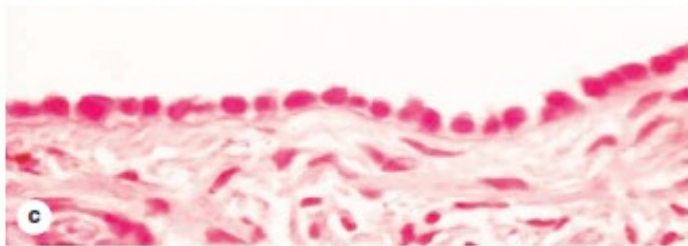
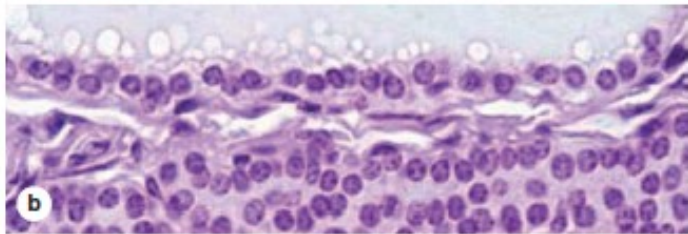
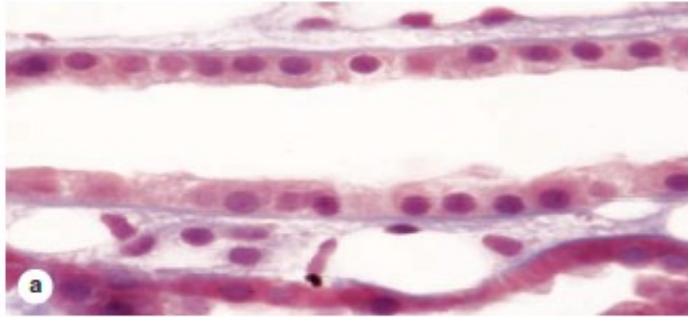
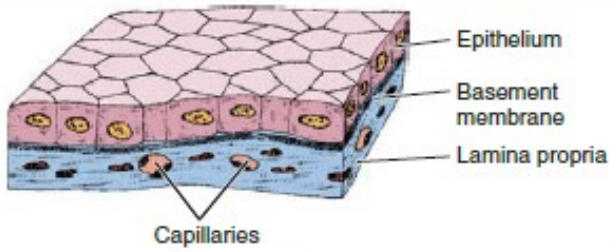


Mesovarium, mesothelium

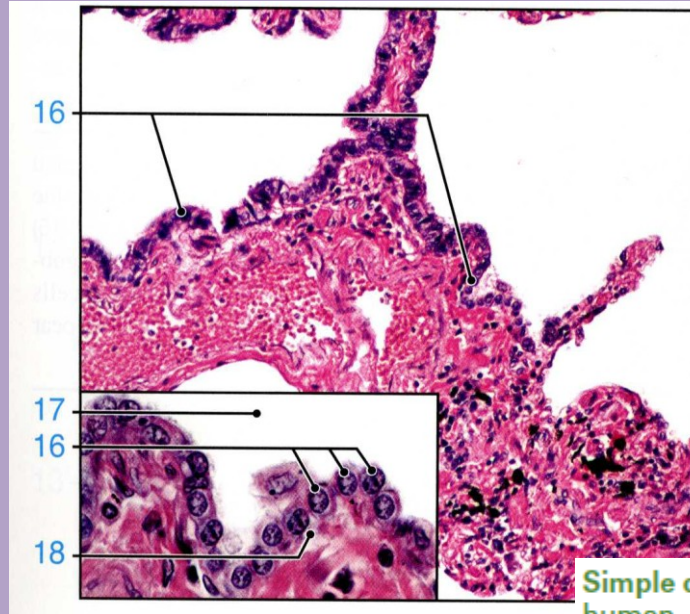


Kidney, Bowman s capsule

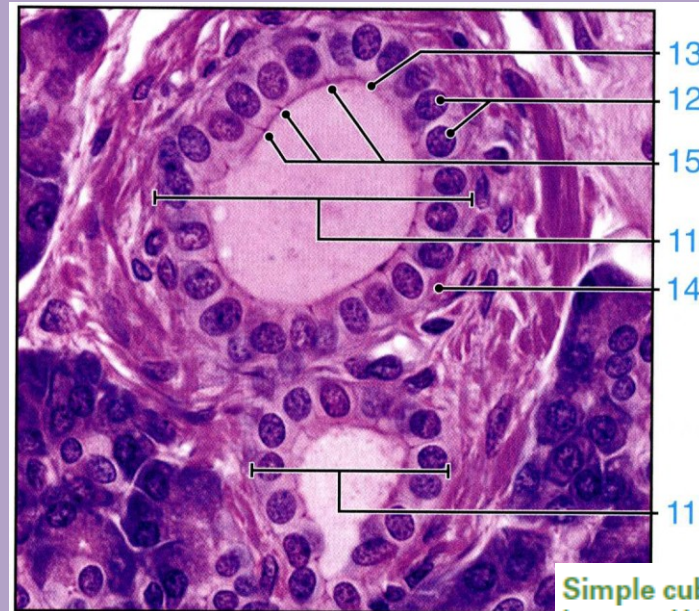
FIGURE 4-13 Simple cuboidal epithelium.



Cells here are roughly as tall as they are wide. Their greater thickness allows cytoplasm to be rich in mitochondria and other organelles for a high level of active transport across the epithelium and other functions. Examples shown here are from a renal collecting tubule **(a)**, a large thyroid follicle **(b)**, and the thick mesothelium covering an ovary **(c)**. (All X400; H&E)



Simple cuboidal epithelium, lung, human, H&E, ×175; inset ×525.



Simple cuboidal epithelium, pancreas, human, H&E, ×700.

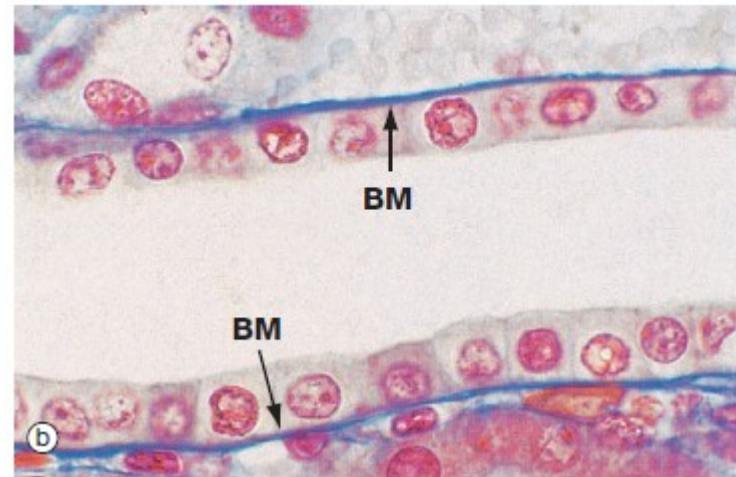
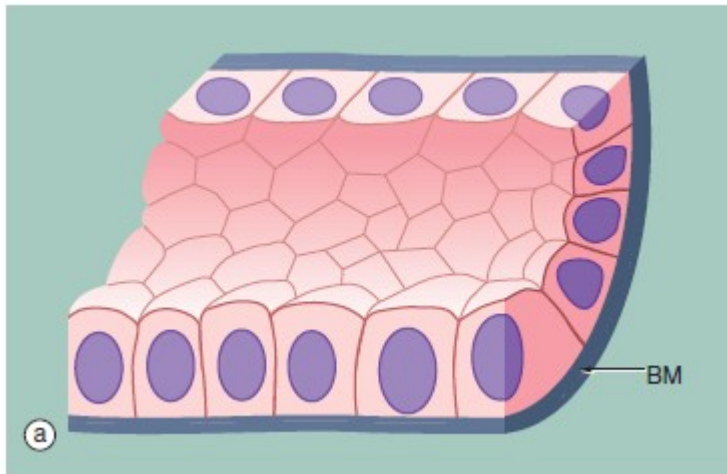


FIG. 5.2 Simple cuboidal epithelium
 (a) Diagram (b) Azan (HP)

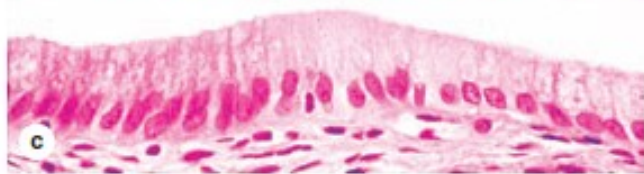
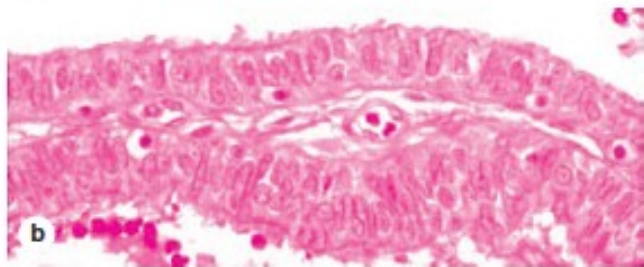
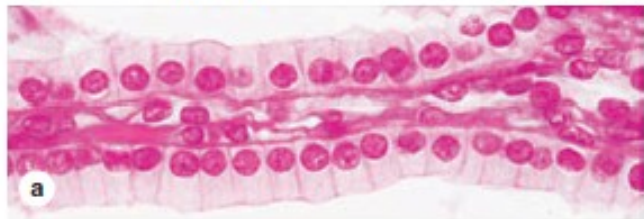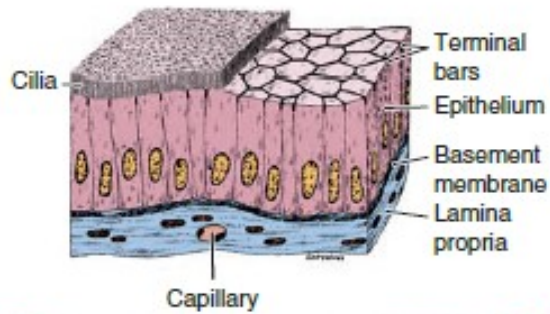
Simple cuboidal epithelium represents an intermediate form between simple squamous and simple columnar epithelium; the distinction between tall cuboidal and low columnar is often arbitrary and is of descriptive value only. In the section perpendicular to the basement membrane **BM**, the epithelial cells appear square, leading to its traditional description as cuboidal epithelium; on surface view, however, the cells are actually polygonal in shape. The nucleus is usually round and located in the centre of the cell.

Simple cuboidal epithelium usually lines small ducts and tubules that may have excretory, secretory or absorptive

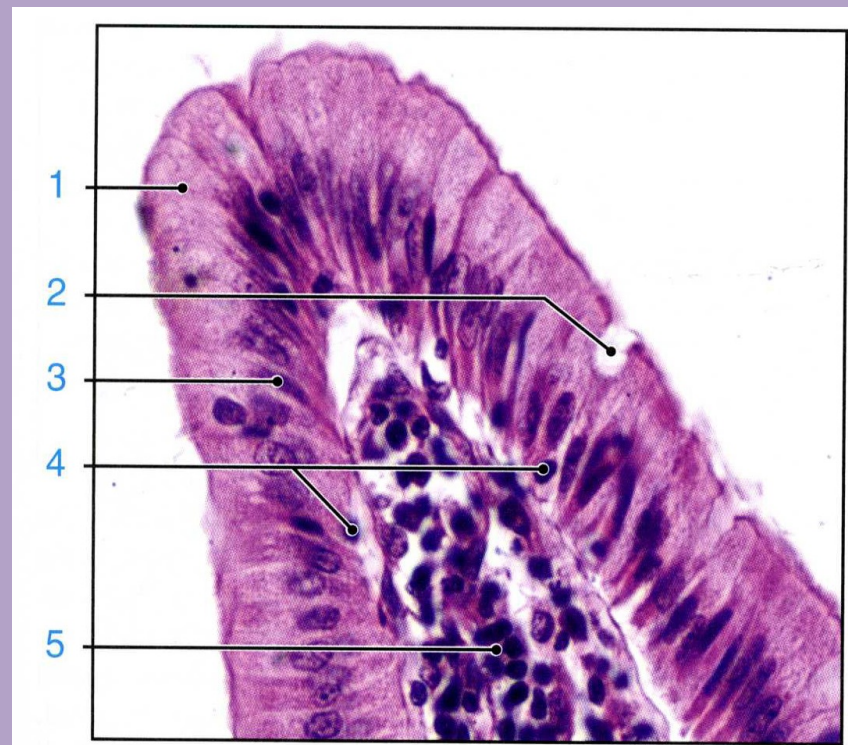
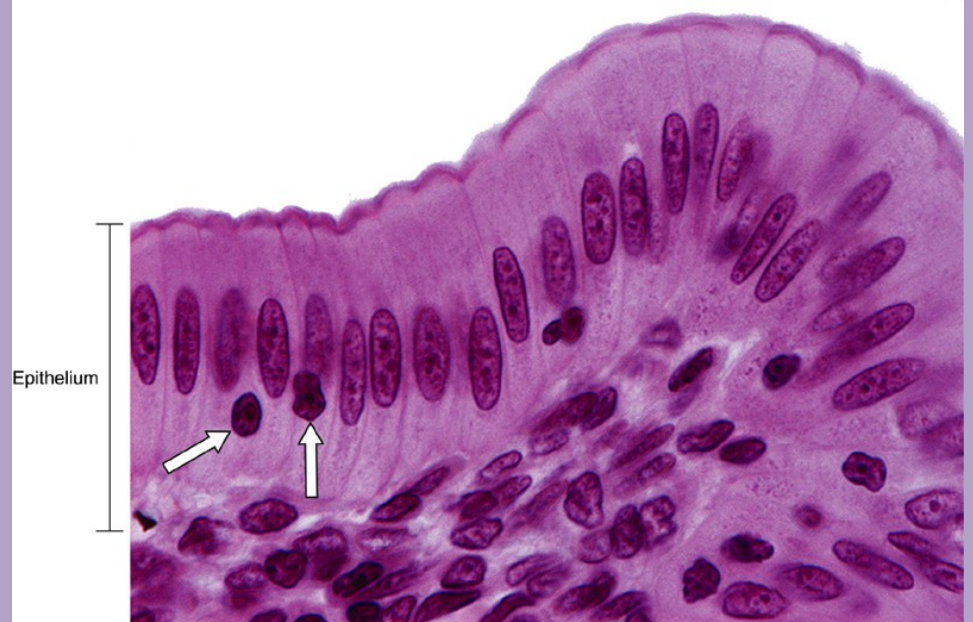functions; examples are the collecting tubules of the kidney and the small excretory ducts of the salivary glands and pancreas.

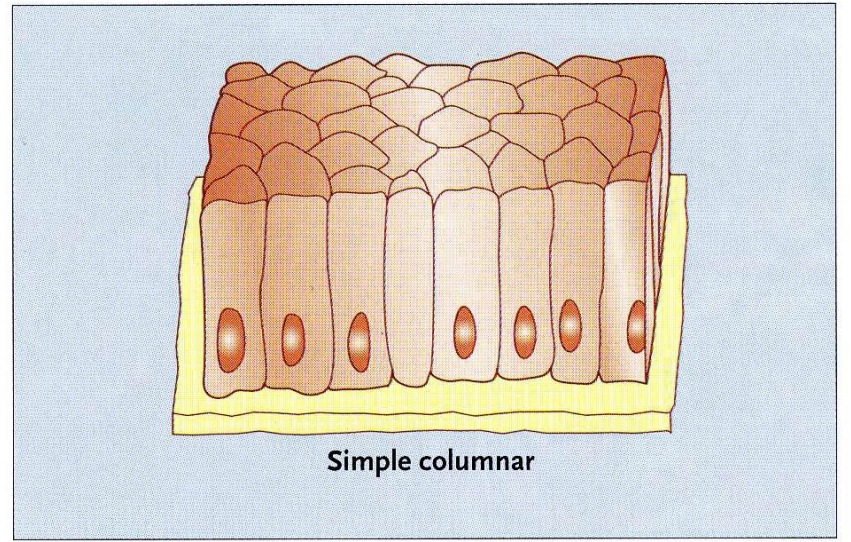
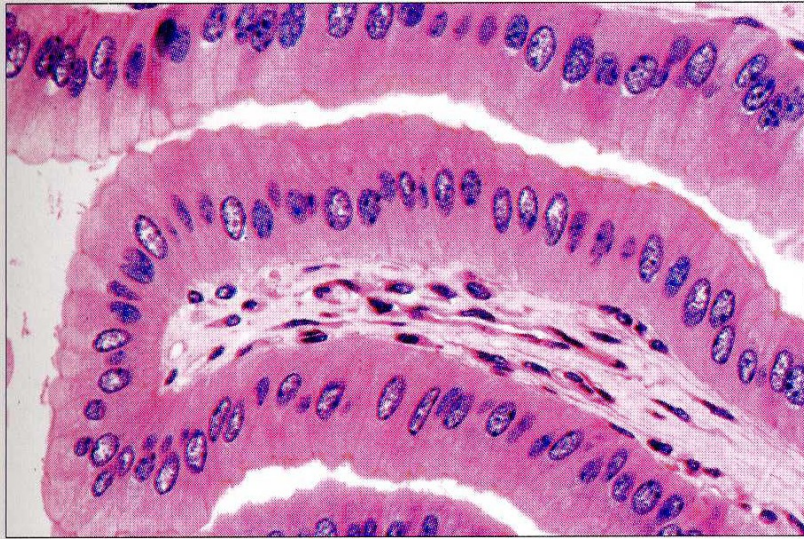
Micrograph (b) shows the cells lining a collecting tubule in the kidney. Although the boundaries between individual cells are indistinct, the nuclear shape provides an approximate indication of the cell size and shape. The underlying basement membrane **BM** appears as a prominent blue line with the Azan staining method, in contrast to basement membranes stained with the standard H&E stain (see Fig. 5.3b) that are generally indistinguishable.

FIGURE 4-14 Simple columnar epithelium.

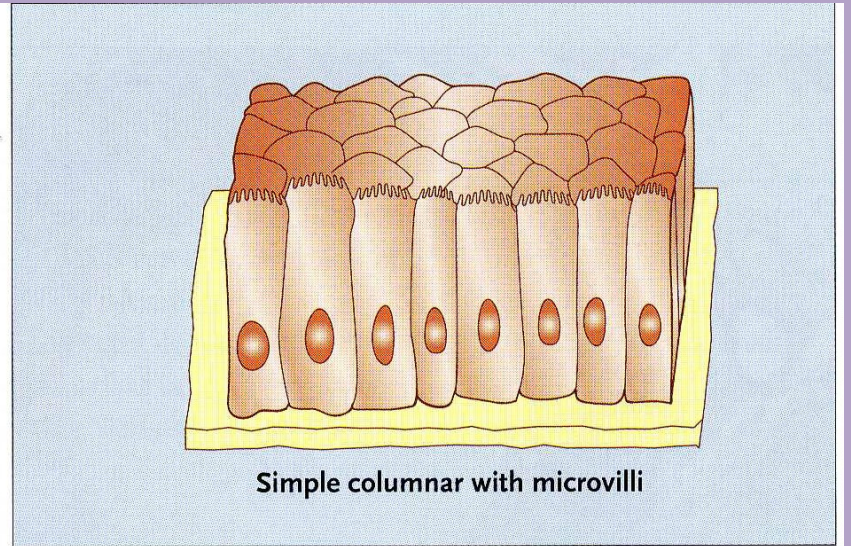
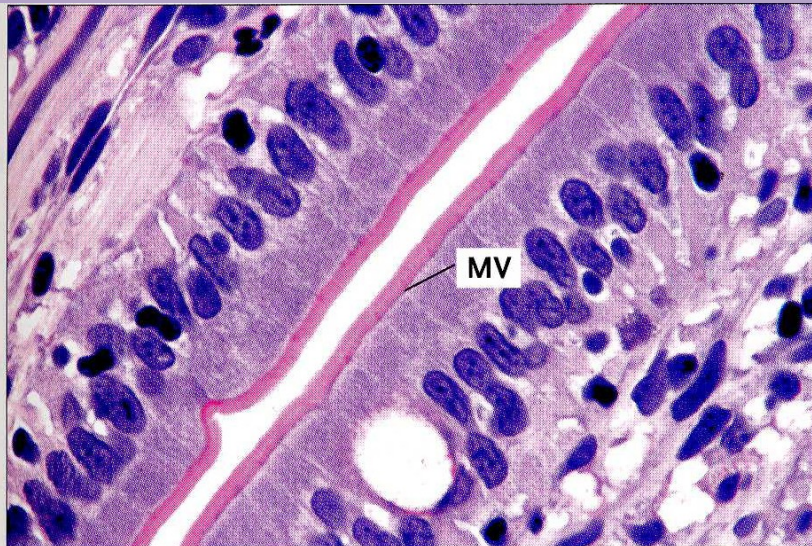

Cells here are always taller than they are wide, with apical cilia or microvilli, and are often specialized for absorption. Complexes of tight and adherent junctions, sometimes called "terminal bars" in light microscopic images, are present at the apical ends of cells. The examples shown here are from a renal collecting duct (a), the oviduct lining, with both secretory and ciliated cells (b), and the lining of the gallbladder (c). (All X400; H&E)





Simple columnar



Simple columnar with microvilli

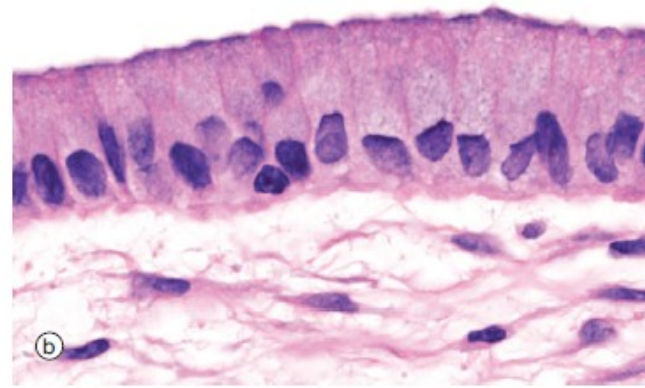
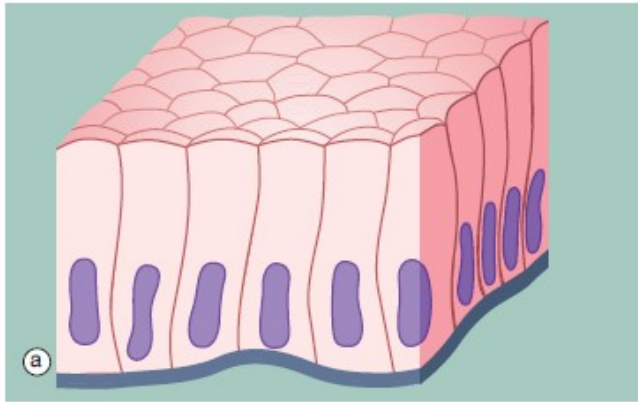
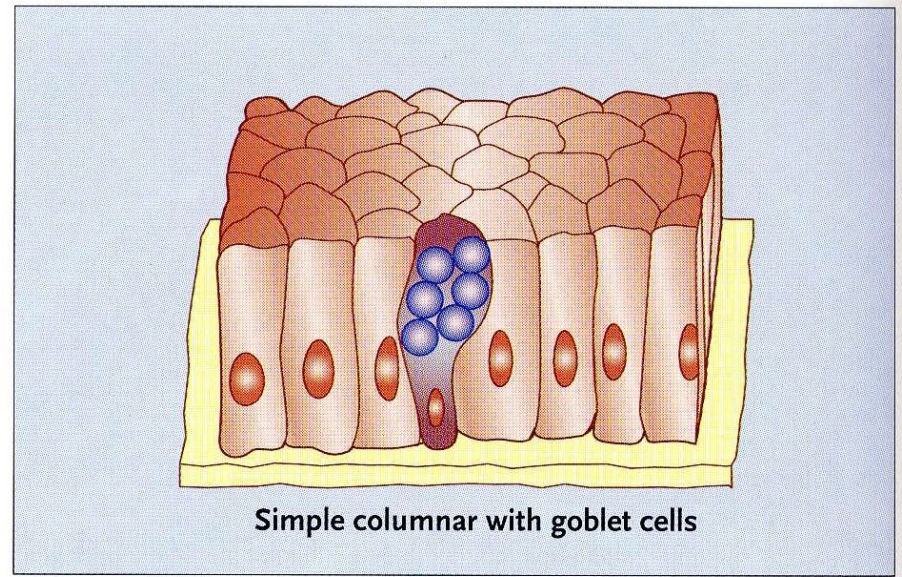
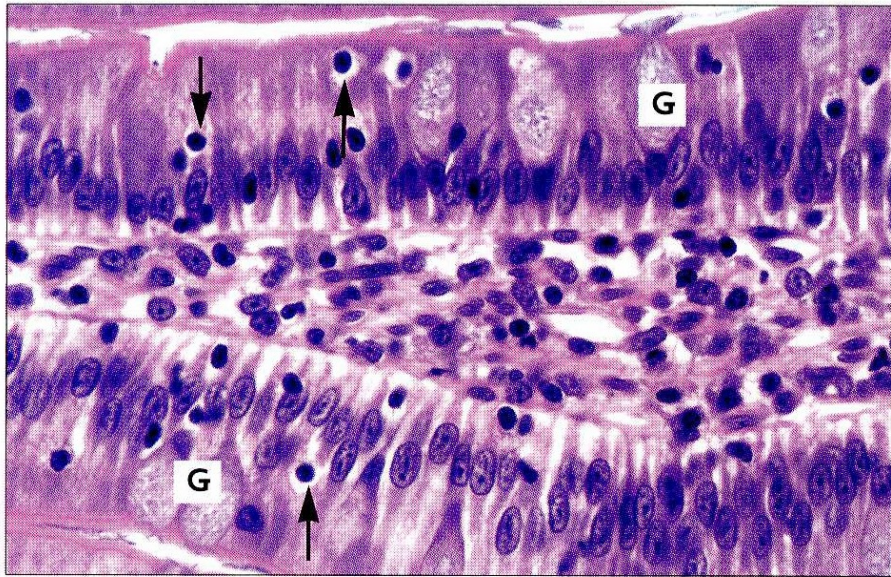


FIG. 5.3 Simple columnar epithelium
 (a) Diagram (b) H&E (HP)

Simple columnar epithelium is similar to simple cuboidal epithelium except that the cells are taller and appear columnar in sections perpendicular to the basement membrane. The height of the cells may vary from low to tall columnar, depending on the site and/or degree of functional activity. The nuclei are elongated and may be located towards the base, the centre or occasionally the apex of the cytoplasm; this is known

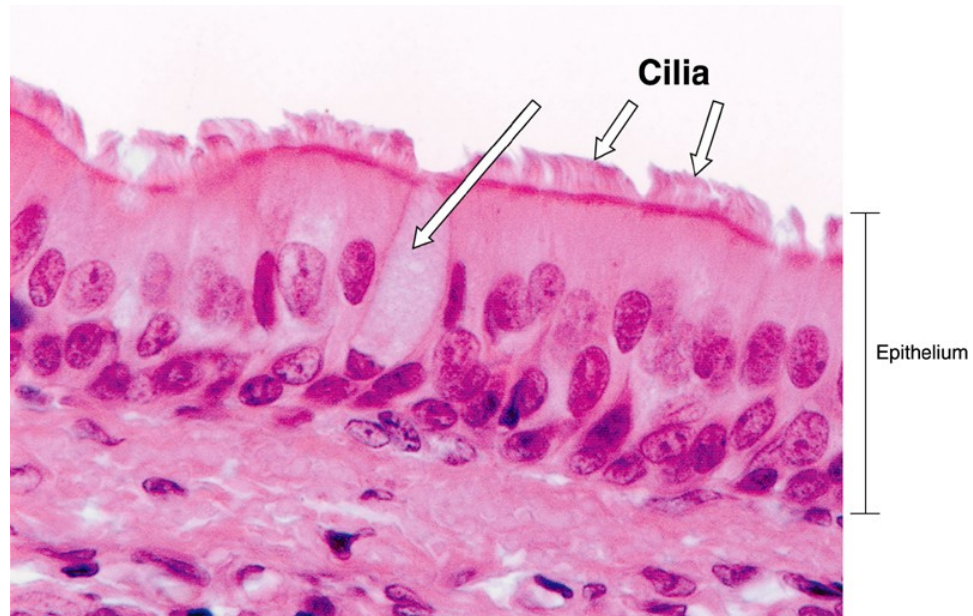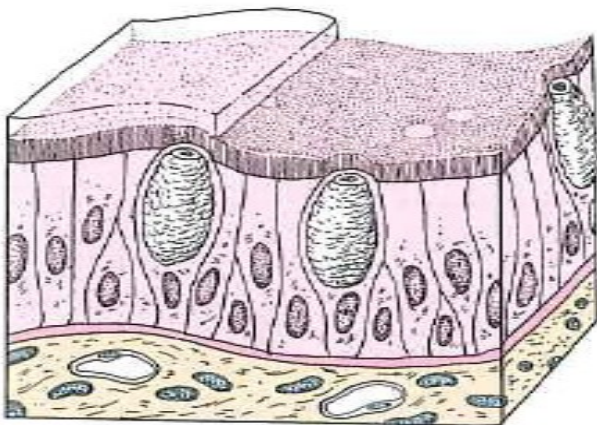
as the *polarity* of the nucleus. Simple columnar epithelium is found on absorptive surfaces such as in the small intestine, as well as at secretory surfaces such as that of the stomach.

Micrograph (b) shows simple columnar epithelium taken from the endocervix where it has the function of secreting mucus. Note the typically basally located nuclei.

EPITHELIAL TISSUE

CLASSIFICATION OF LINING AND COVERING EPITHELIUM

- *Pseudostratified*
 - Cells are of various heights. It appears stratified. All cells rest on the basement membrane, but only the tallest cells reach the free surface. Variation in height of the cells and the location of nuclei give the appearance of a stratified epithelium. Frequently ciliated.
 - Provides protection and surface transport when ciliated.
 - Forms the lining of much of the respiratory tract and much of the male reproductive system.



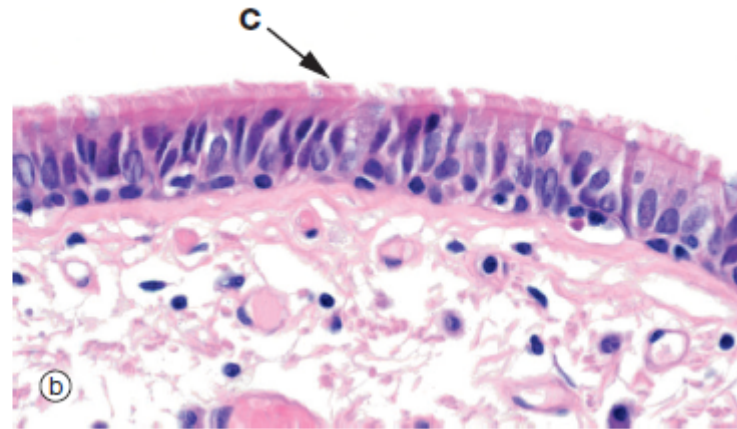
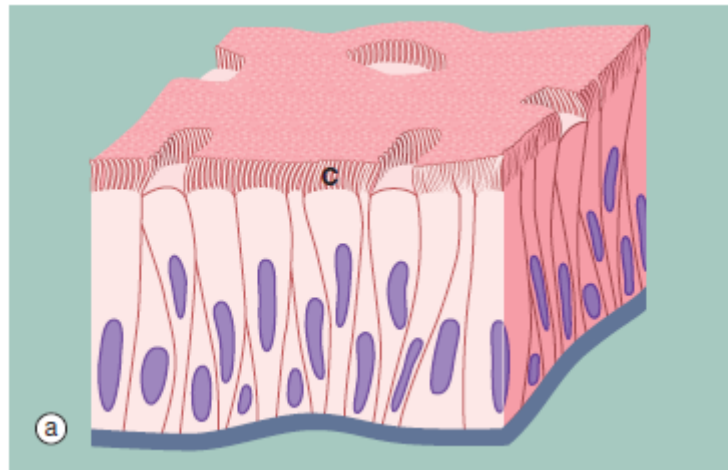


FIG. 5.5 Pseudostratified columnar ciliated epithelium
(a) Diagram (b) H&E (MP)

Another variant of simple columnar epithelium is described in which the majority of cells are also usually ciliated. The term *pseudostratified* is derived from the appearance of this epithelium in section, which conveys the erroneous impression that there is more than one layer of cells. In fact, this is a true simple epithelium, since all the cells rest on the basement membrane. The nuclei of these cells, however, are disposed at different levels, thus creating the illusion of cellular stratification. Scattered stem cells (see Ch. 2) are found throughout the epithelium; these generally are devoid of cilia (i.e. less differentiated) and do not extend to the luminal surface.

Pseudostratified columnar ciliated epithelium may be distinguished from true stratified epithelia by two

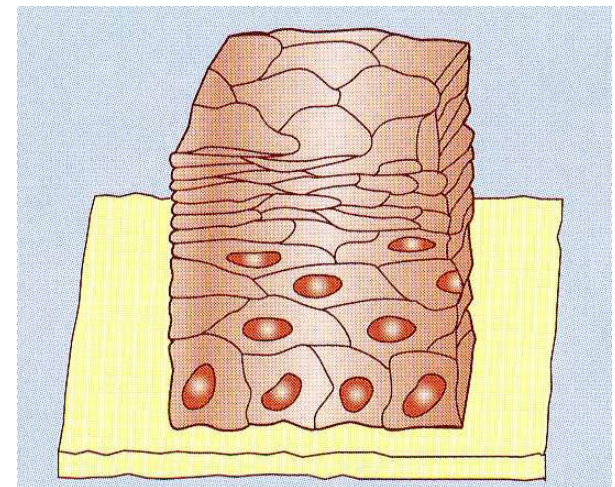
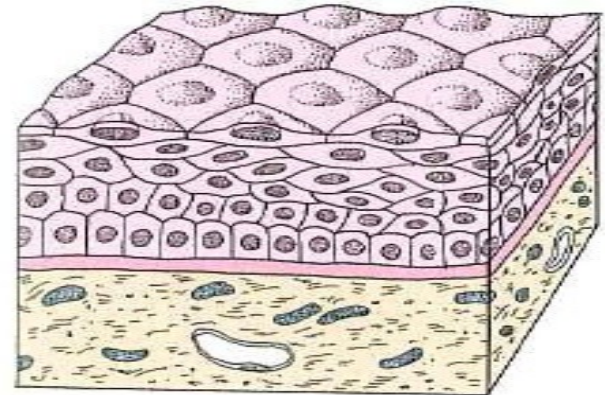
characteristics. Firstly, the individual cells of the pseudostratified epithelium exhibit polarity, with nuclei being mainly confined to the basal two-thirds of the epithelium. Secondly, cilia are never present on true stratified epithelia.

Pseudostratified epithelium is almost exclusively confined to the airways of the respiratory system in mammals and is therefore often referred to as *respiratory epithelium*. Micrograph (b) illustrates the lining of a bronchus. In the respiratory tract, the cilia propel a surface layer of mucus containing entrapped particles towards the pharynx in what is often described as the *mucociliary escalator*. The mucus is secreted by nonciliated goblet cells found amongst the ciliated cells (not seen in this micrograph, see Figs 5.16 and 5.17).

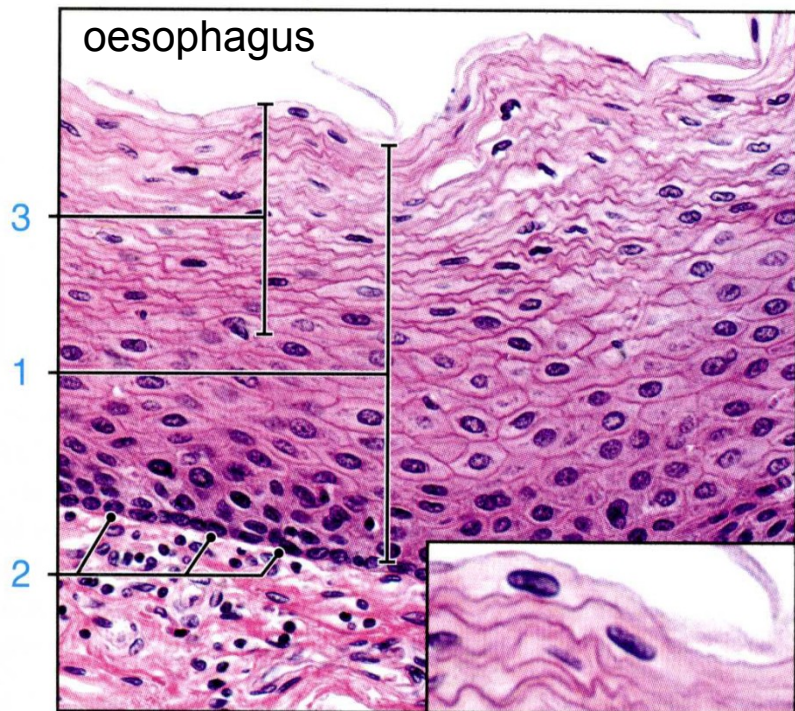
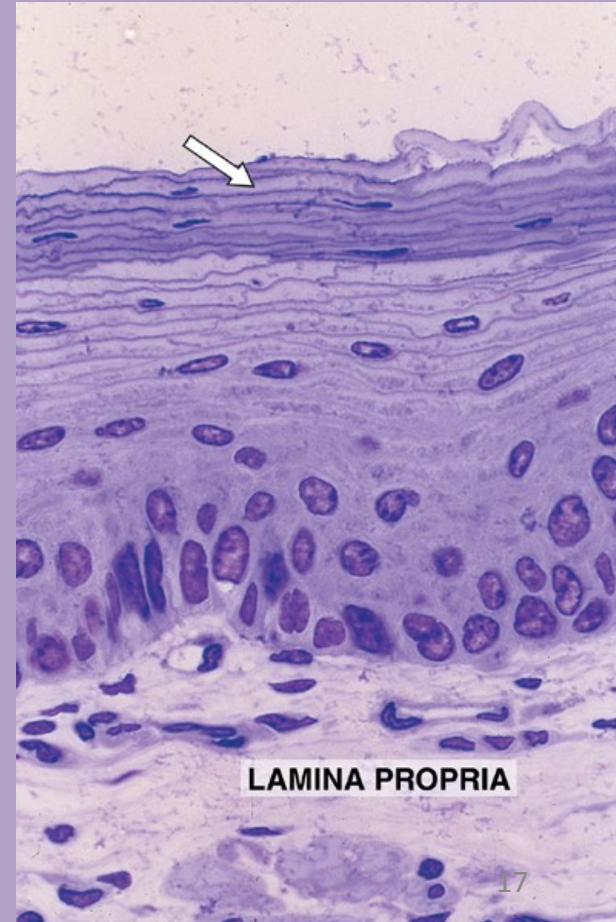
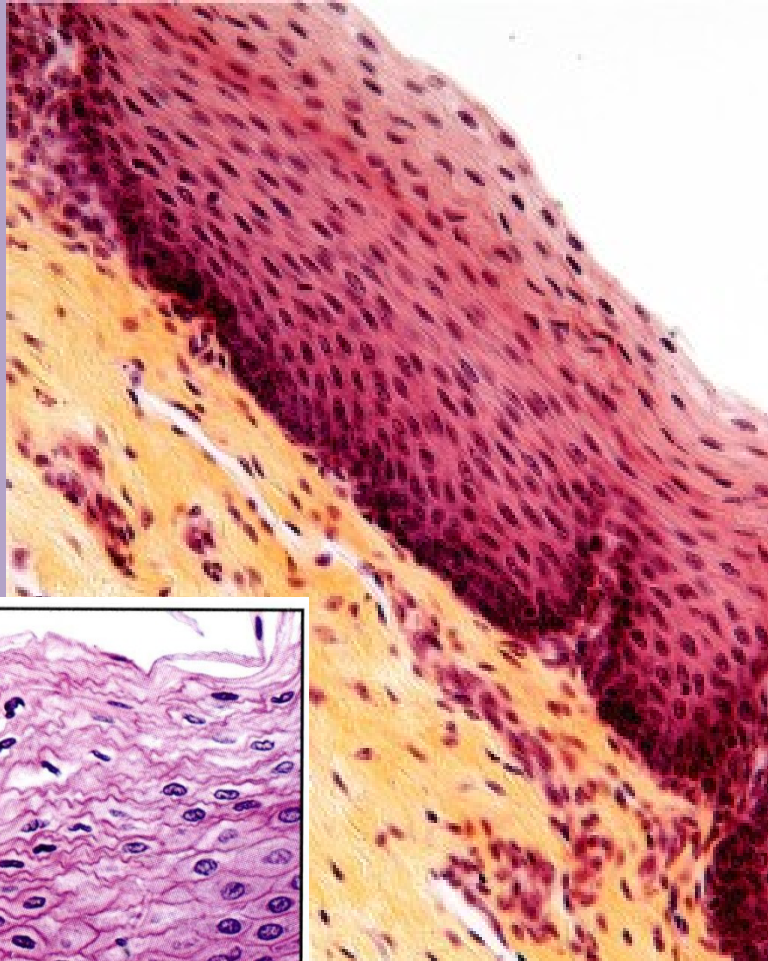
EPITHELIAL TISSUE

CLASSIFICATION OF LINING AND COVERING EPITHELIUM

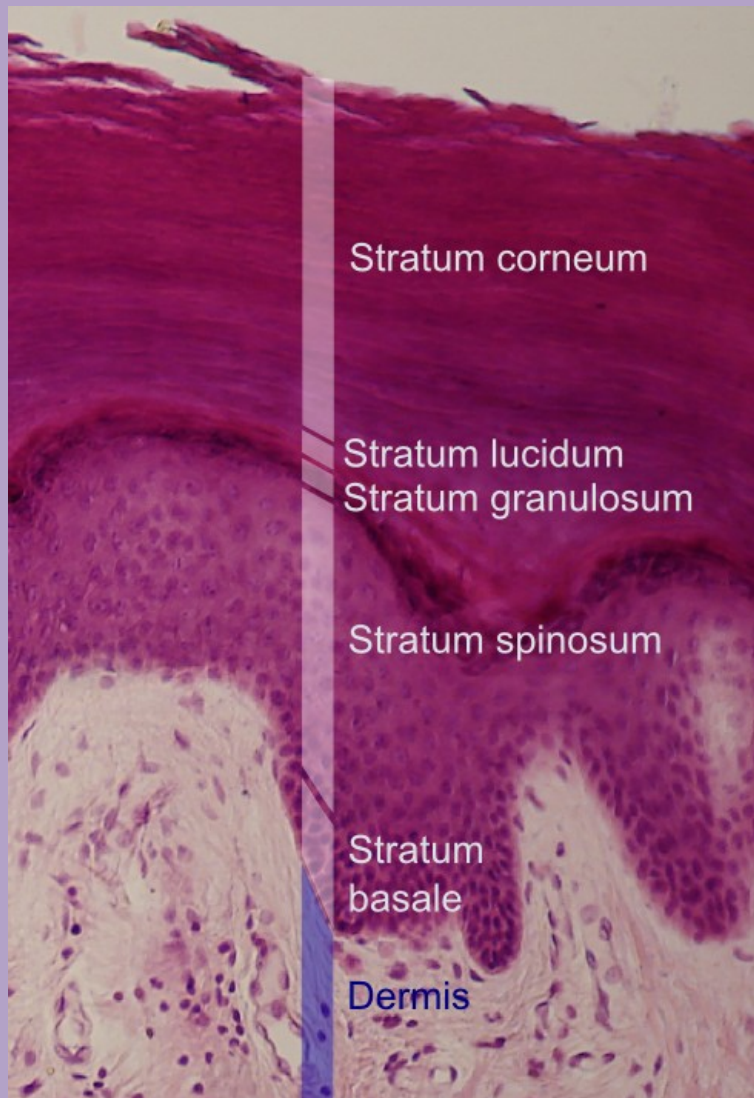
- **Stratified epithelium**
 - More than one cell layer thick
 - Only the deepest layer of cells contact the basement membrane and only the superficial-most cells have a free surface.
 - Named according to the shape of the cells at the free surface.
- *Stratified squamous*
 - Protects from physical abrasion and prevents desiccation
 - Two types:
 - *Nonkeratinized* (moist). Lining of wet cavities, including the mouth, esophagus, rectum, and anal canal; surface cells are nucleated and living.
 - *Keratinized* (dry). Epidermis of the skin; surface cells are nonliving.



Stratified squamous nonkeratinized epithelium



Stratified squamous keratinized epithelium



S. corneum: the keratinised layers of dead cells, filled with densely packed keratin.

S. lucidum: only in thick skin. It is a thin transparent layer, difficult to recognise in routine sections.

S. granulosum: the cells lose their nuclei and organelles and become keratinised. The granules contain a lipid rich secretion, which acts as a water sealant.

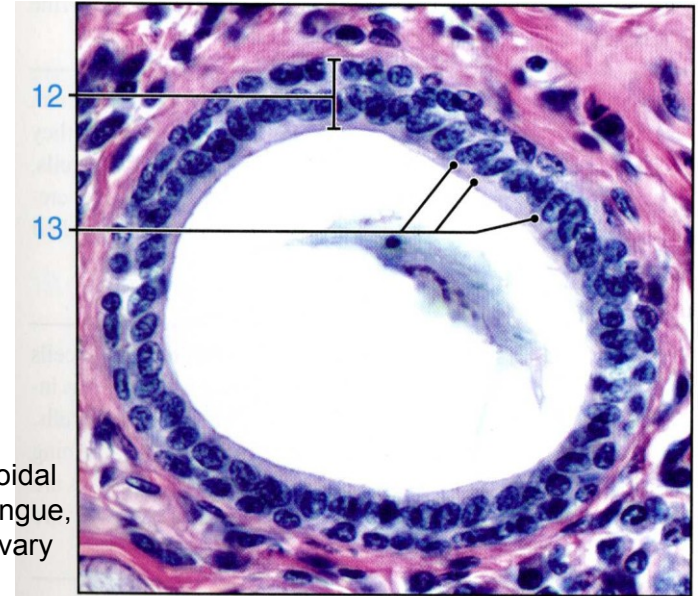
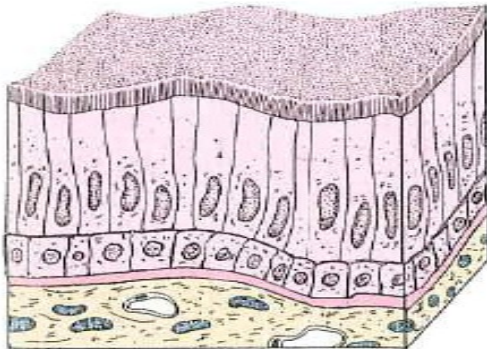
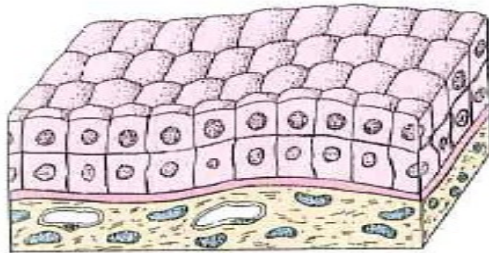
S. spinosum: „prickle cells“ with a lot of desmosomes, which anchor the cells to each other, with some amounts of keratin. When the cells shrink during fixation, the desmosomes from neighbouring cells remain bound to each other and look like 'prickles' or 'spines' → „prickle cells“.

Stratum basale = s. germinosum: a single layer of cells, closest to the dermis. The cells can divide and some move up to the next layer.

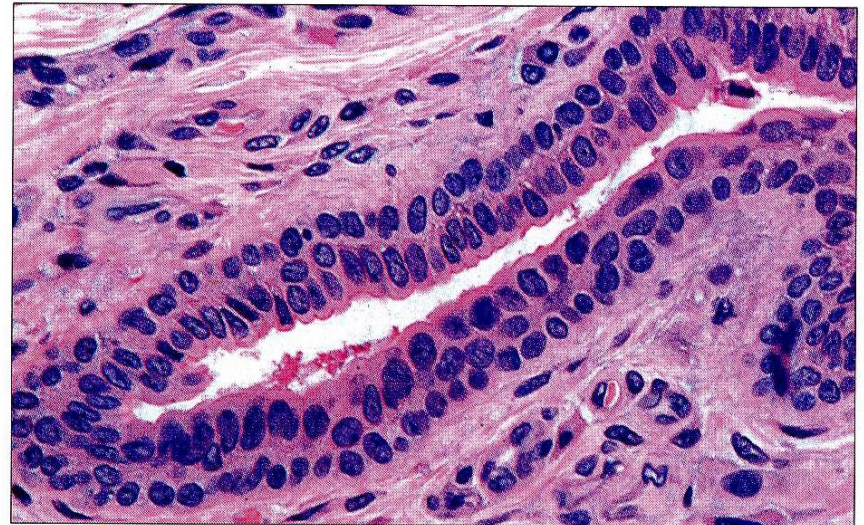
EPITHELIAL TISSUE

CLASSIFICATION OF LINING AND COVERING EPITHELIUM

- *Stratified cuboidal/columnar*
 - Lines the larger ducts of exocrine glands.



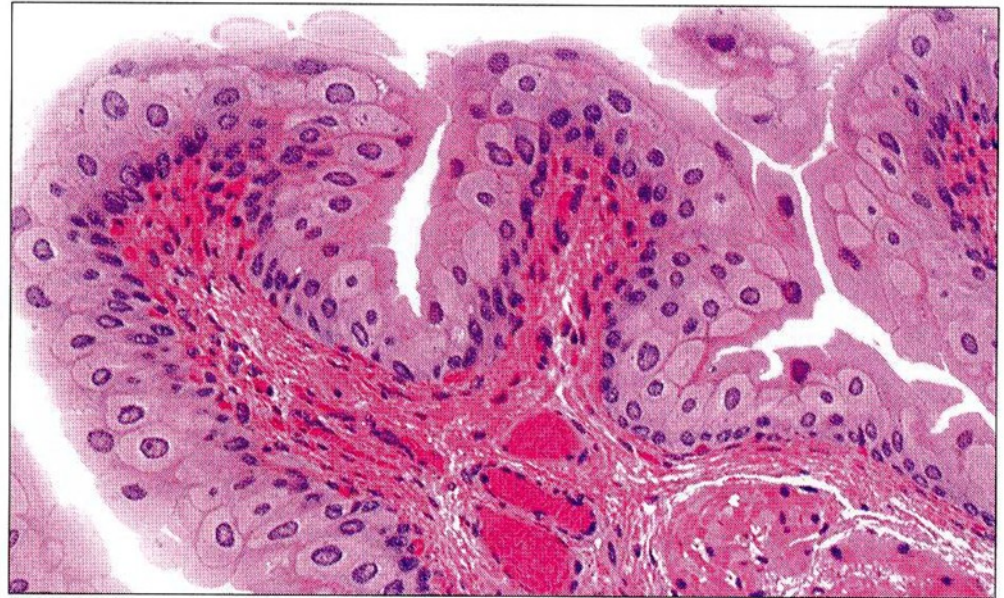
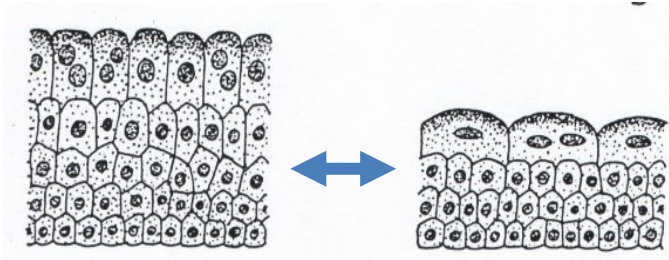
Stratified cuboidal epithelium, tongue, duct from salivary gland

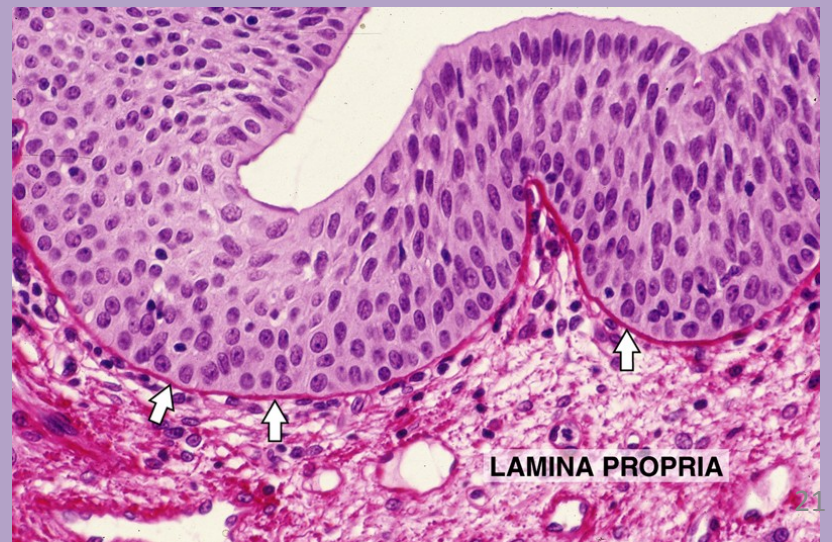
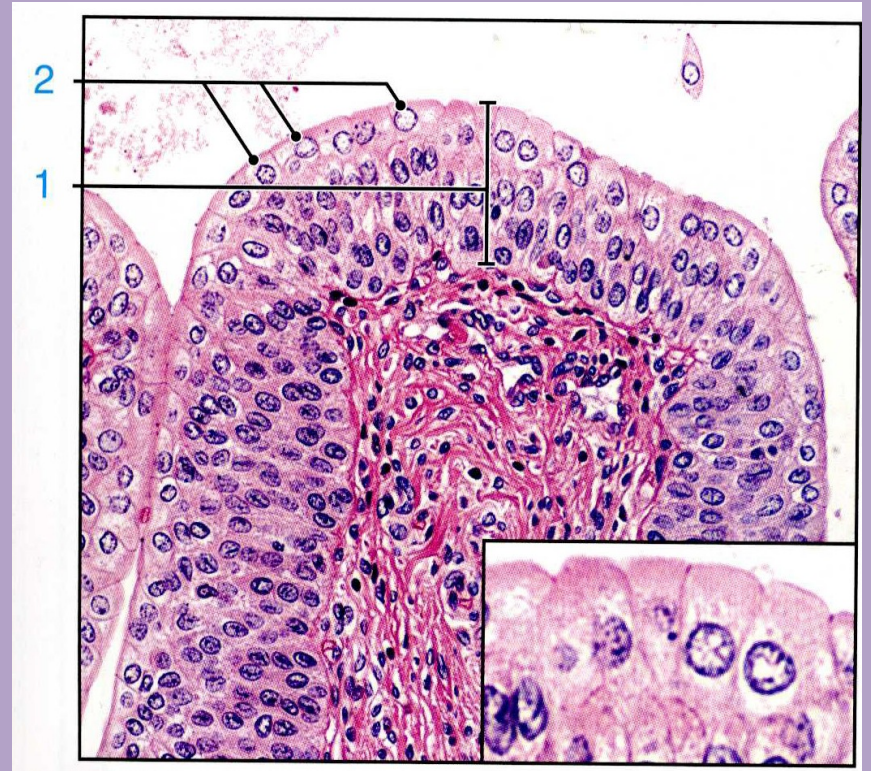
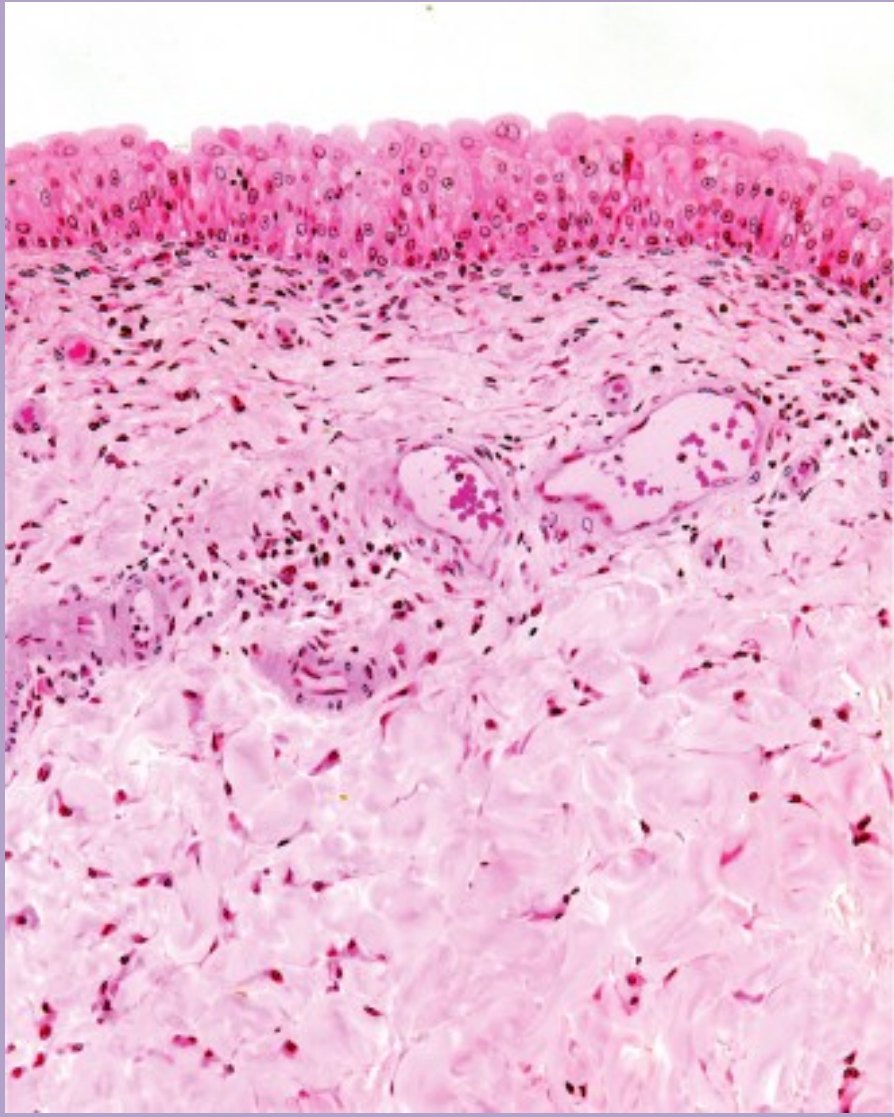


EPITHELIAL TISSUE

CLASSIFICATION OF LINING AND COVERING EPITHELIUM

- *Transitional*
 - Protective function; constructed to expand with distension of the hollow organs it lines
 - Unique to the urinary system; lines the urinary bladder and ureter





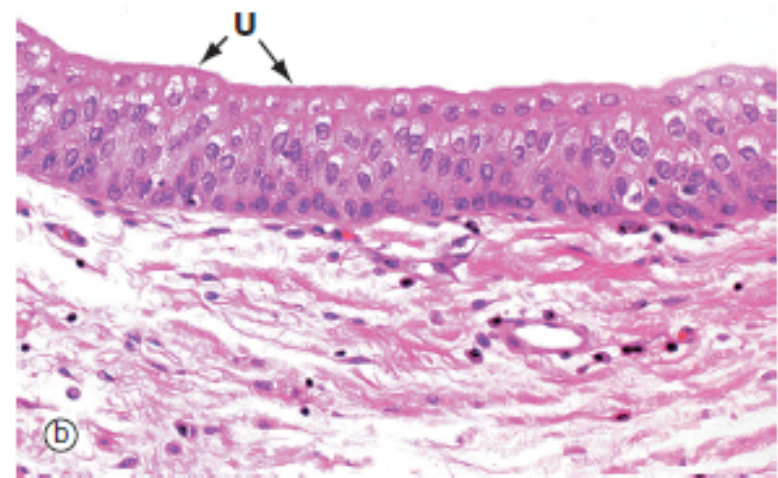
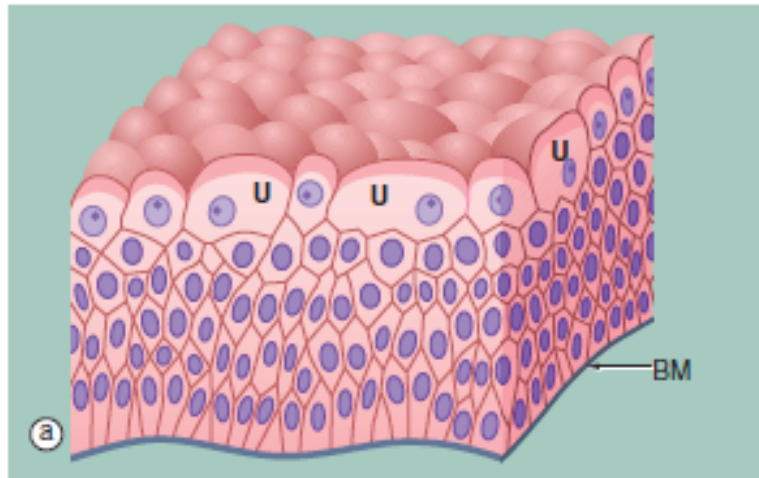


FIG. 5.8 Transitional epithelium
(a) Diagram (b) H&E (HP)

Transitional epithelium (or *urothelium*) is a form of stratified epithelium found only in the urinary tract in mammals, where it is highly specialised to accommodate a great degree of stretch and to withstand the toxicity of urine. This epithelial type is so named because it has some features intermediate (transitional) between stratified cuboidal and stratified squamous epithelia. In the non-distended state, transitional epithelium appears to be about four to five cell layers thick. The basal cells are roughly cuboidal, the intermediate cells are polygonal and the surface cells (*umbrella* or *dome cells* U) are large and rounded and may contain two nuclei. In the stretched state, transitional epithelium often appears only two or three cells thick (although

the actual number of layers remains constant) and the intermediate and surface layers are extremely flattened.

Micrograph (b) shows the appearance of transitional epithelium from the lining of a non-distended bladder. The shape and apparent size of the basal and intermediate cells vary considerably depending on the degree of distension, but the cells of the surface layer usually retain characteristic features. Firstly, the surface umbrella cells are large and pale stained with a scalloped surface outline often overlapping two or more of the underlying cells. Secondly, the luminal surface of the cells appears thickened and more densely stained.

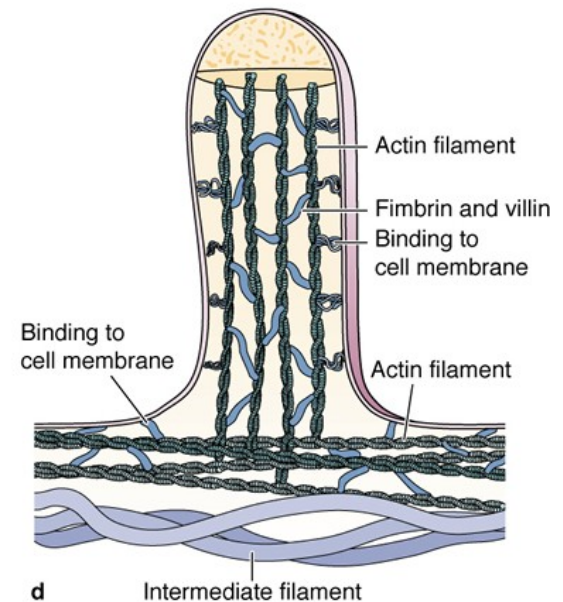
EPITHELIAL TISSUE

SURFACE SPECIALIZATIONS

- Apical domain with special structural surface modification to carry our specific function

Microvilli

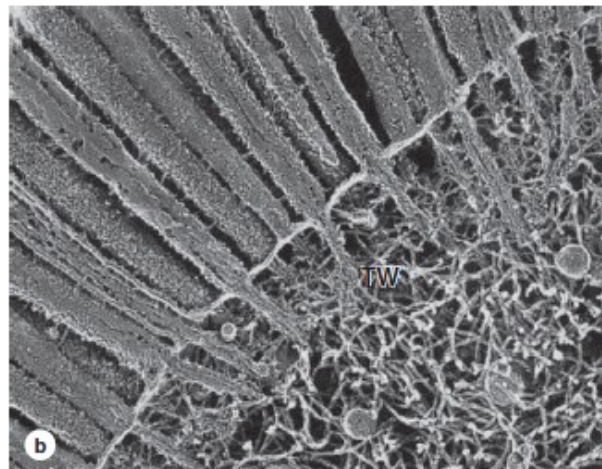
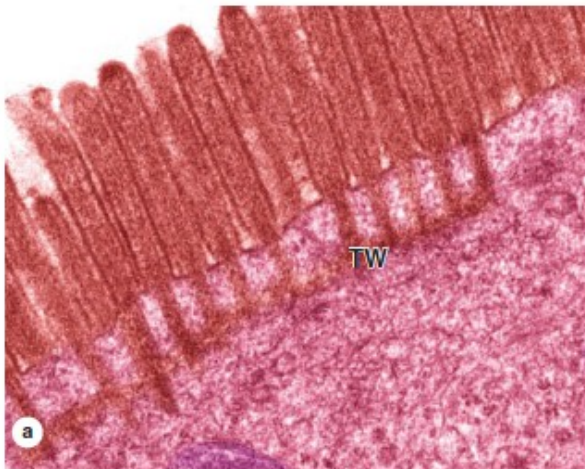
- Finger-like extensions from the free surface of the cell, about 1 micron in height
- Are usually present in large numbers on each cell and, collectively, are called a brush or striated border
- Contain a core of actin microfilaments
- Are relatively non-motile
- Increase surface area for absorption
- Prominent on cells lining the digestive tract and proximal tubules in the kidney


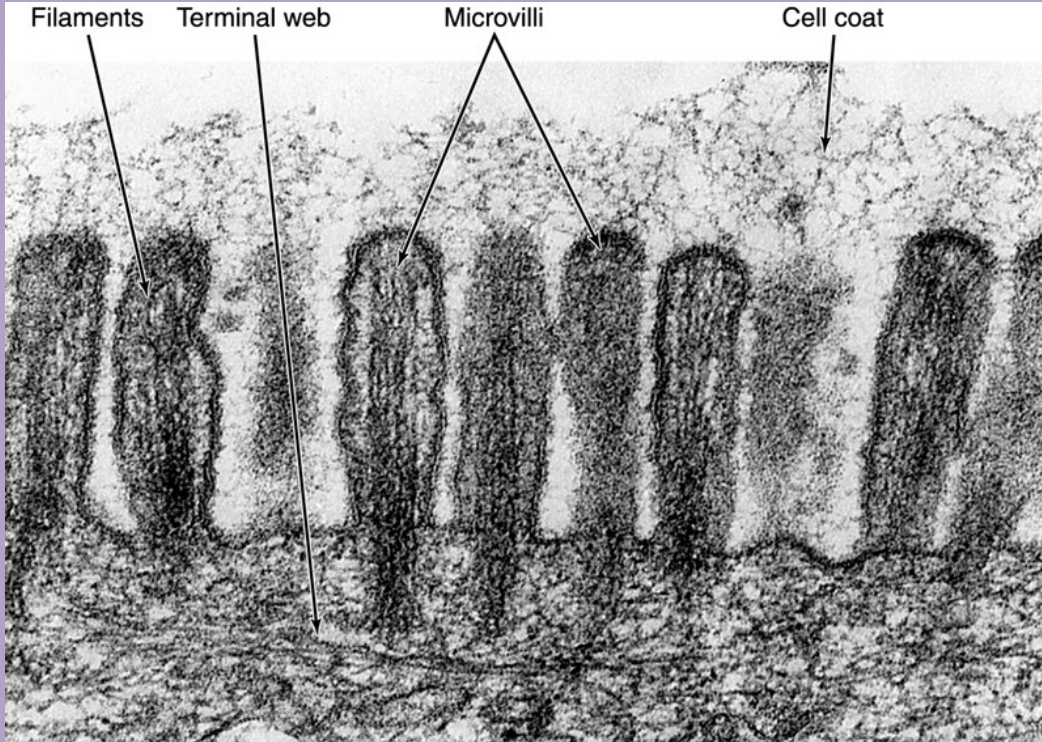


d Absorptive cells lining the small intestine demonstrate the highly uniform microvilli of a striated or brush border particularly well.

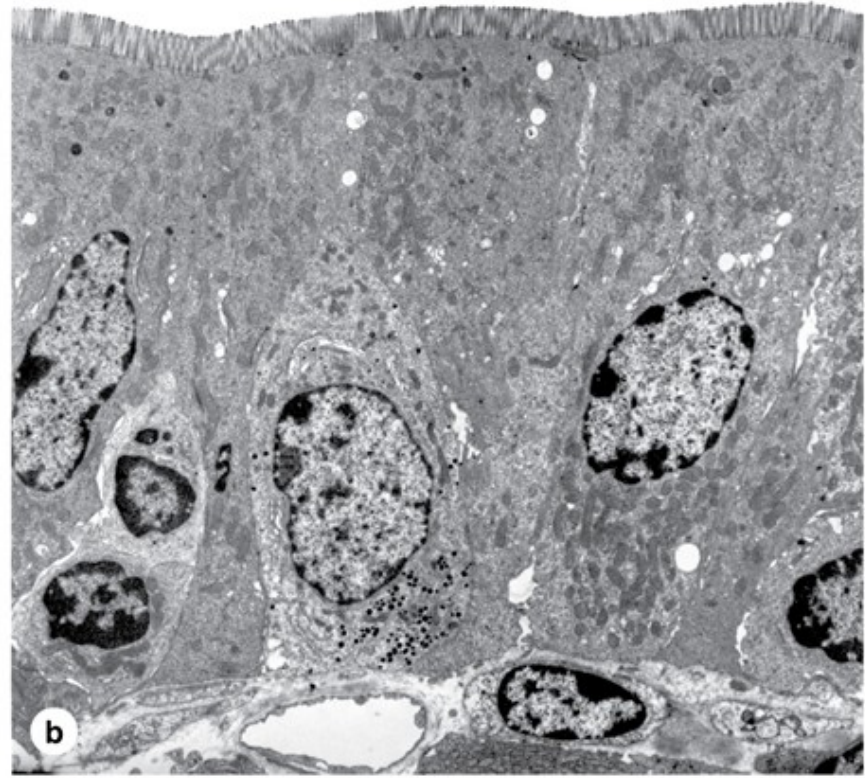
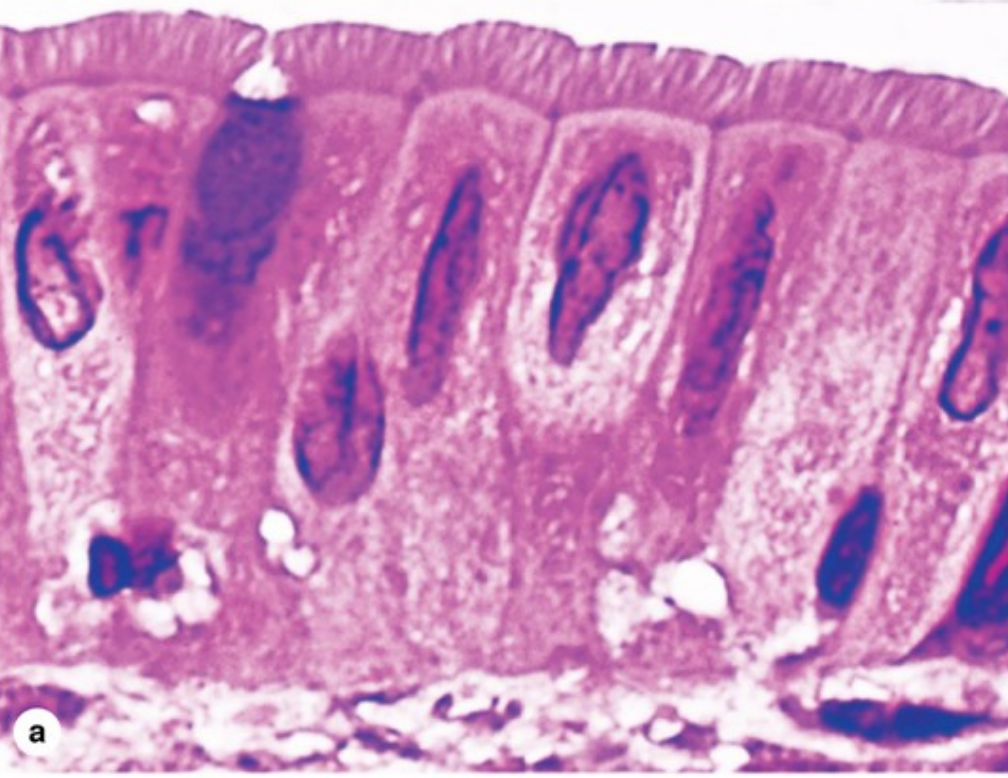
(a) A high-magnification light microscope shows many parallel microvilli and their connections to the terminal web (TW) in the underlying cytoplasm. (X6500)

(b) SEM of a sectioned epithelial cell shows both the internal and surface structure of individual microvilli and the association with actin filaments and intermediate filaments of the terminal web. (X7000; TW)





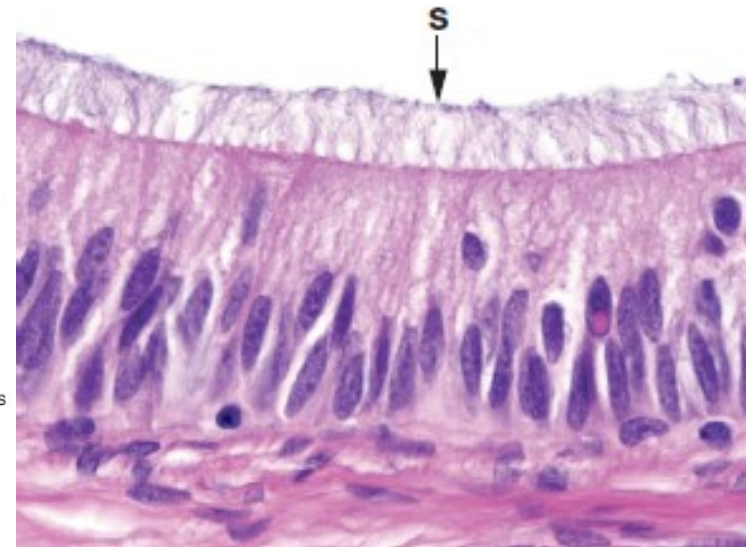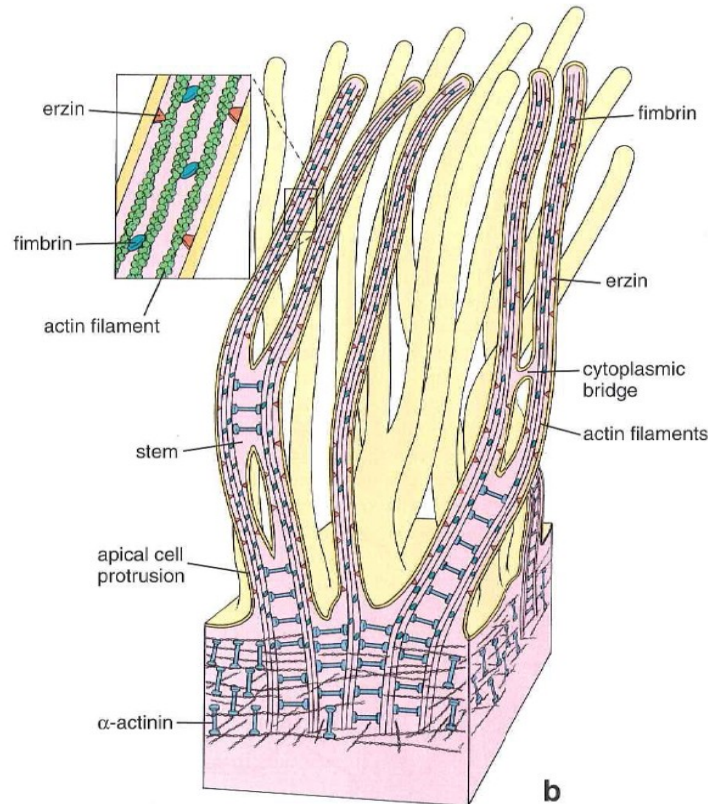
(c) TEM of microvilli sectioned longitudinally and transversely (inset) reveals the microfilament arrays that form the core of these projections. The terminal web (TW) of the cytoskeleton is also seen. The glycocalyx (G) extending from glycoproteins and glycolipids of the microvilli plasmalemma contains certain enzymes for late stages of macromolecule digestion. (X15,000)



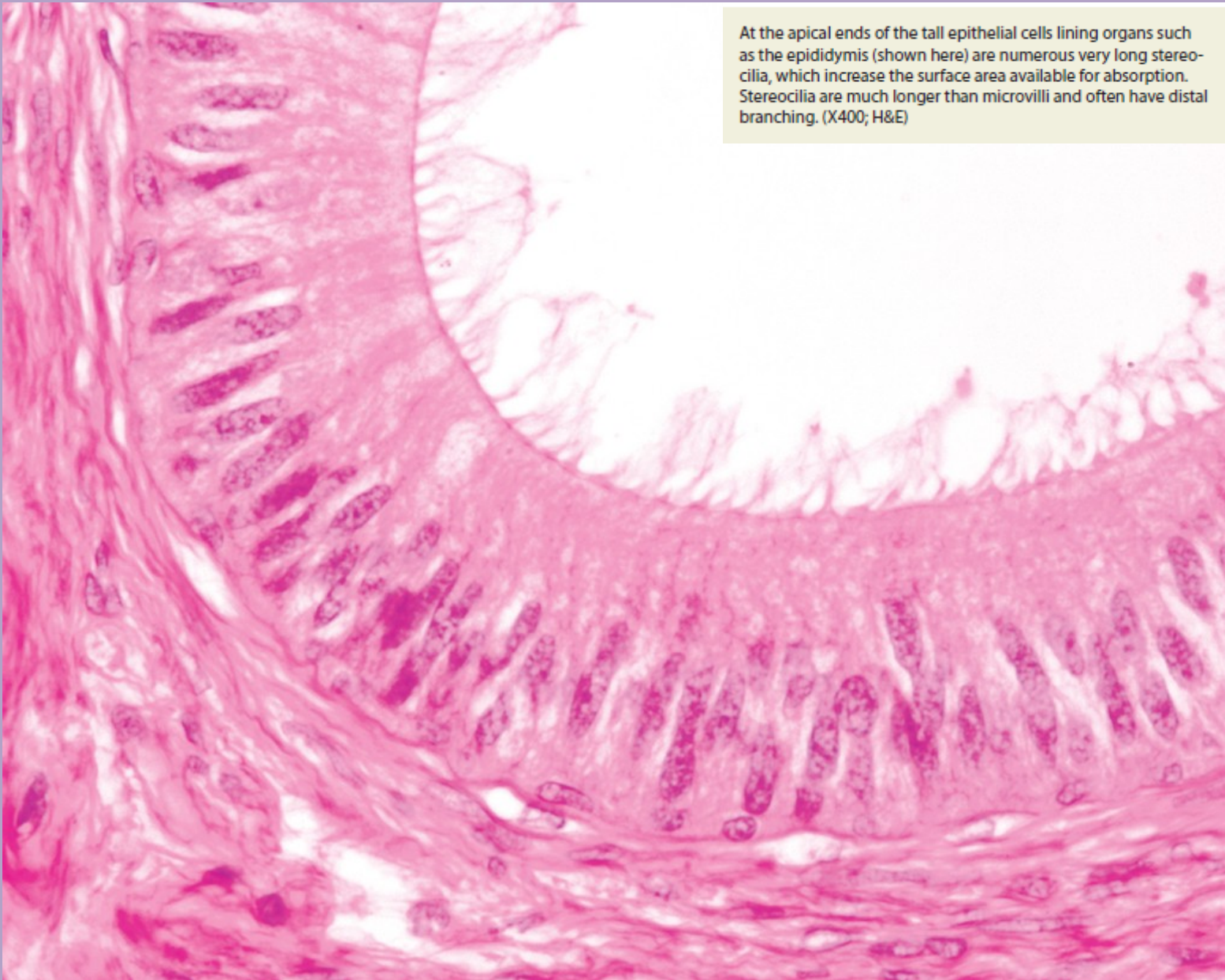
EPITHELIAL TISSUE

SURFACE SPECIALIZATIONS

- **Stereocilia**
 - Large, non-motile microvilli; not cilia
 - Contain a core of actin microfilaments
 - Increase surface area
 - Present on cells lining the epididymis and ductus deferens in the male reproductive tract



epididimis



At the apical ends of the tall epithelial cells lining organs such as the epididymis (shown here) are numerous very long stereocilia, which increase the surface area available for absorption. Stereocilia are much longer than microvilli and often have distal branching. (X400; H&E)

EPITHELIAL TISSUE

SURFACE SPECIALIZATIONS

- **Cilia**
 - Multiple hair-like extensions from free surface of the cell; 7-10 microns in height
 - Highly motile; beat in a wave-like motion
 - Function to propel material along the surface of the epithelium (e.g., in the respiratory system and the oviduct of the female reproductive system)
 - Core of a cilium is called the axoneme, in which nine pairs of microtubules surround two central, individual microtubules (9 + 2 arrangement).
 - The axoneme of each cilium originates from a basal body that is located at the apex of the cell and is composed of nine triplets of microtubules.

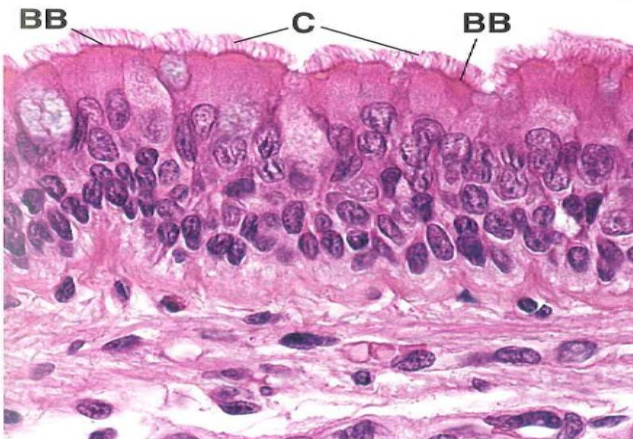


FIGURE 5.6 ▲ Ciliated epithelium. Photomicrograph of an H&E-stained specimen of tracheal pseudostratified ciliated epithelium. The cilia (C) appear as hair-like processes extending from the apical surface of the cells. The dark line immediately below the ciliary processes is produced by the basal bodies (BB) associated with the cilia. $\times 750$.

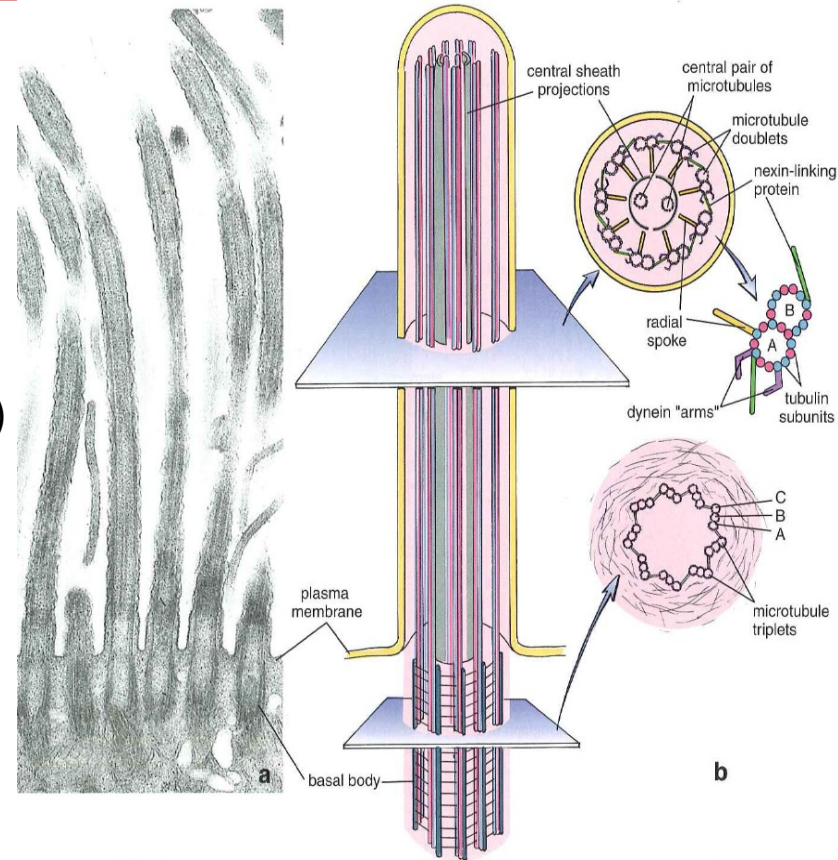
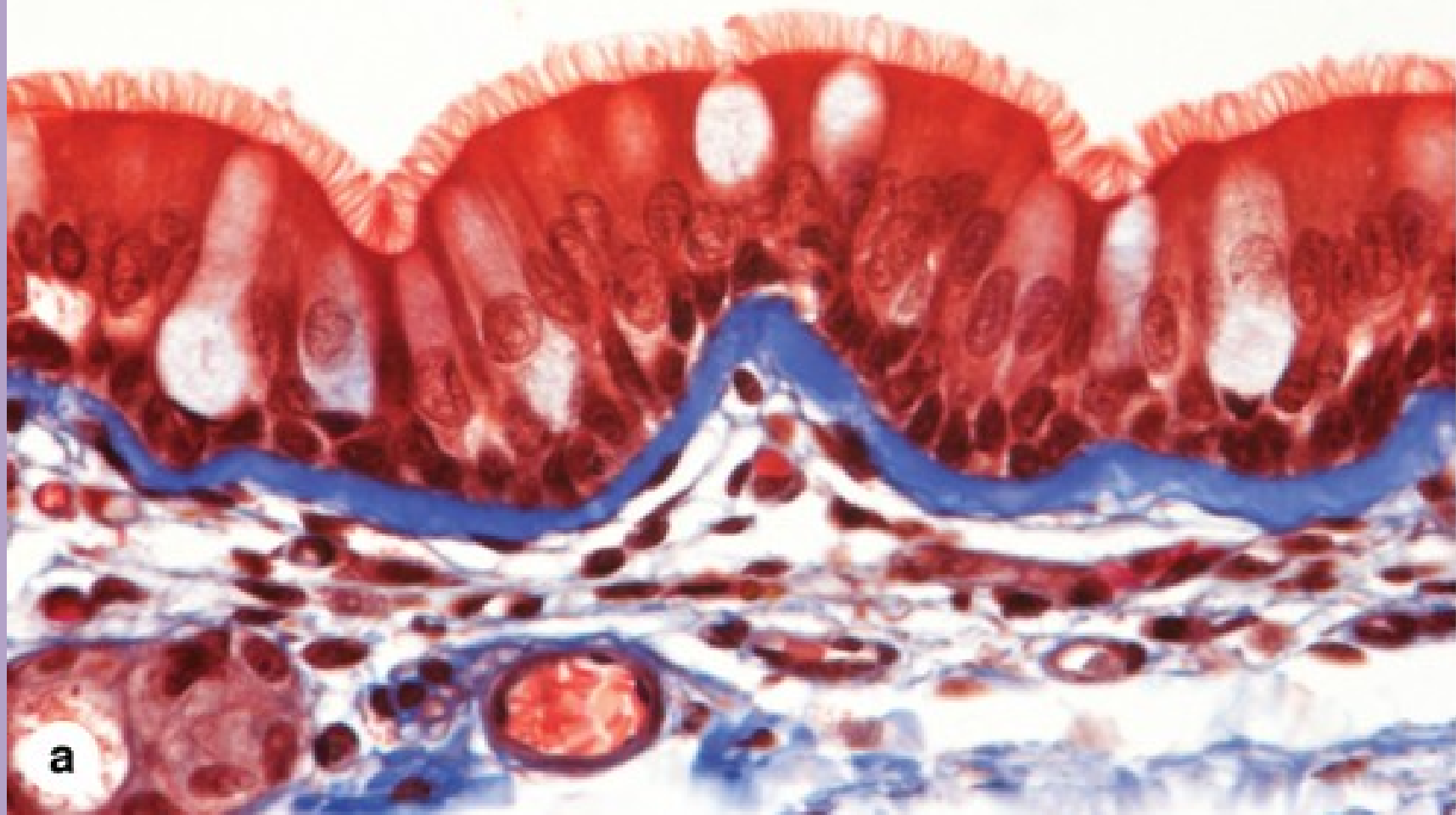


FIGURE 4.6

Molecular structure of cilia. **a.** Electron micrograph of longitudinally sectioned cilia from the oviduct. The internal structures within the ciliary process are microtubules. Most of the basal bodies appear "empty" because of the absence of the central pair of microtubules in this portion of the cilium. One basal body (second from left) has been sectioned peripherally through the outer microtubule triplet. $\times 20,000$. **b.** Schematic diagram of cilium, showing its cross section (upper plane) with the pair of central microtubules and the nine surrounding microtubule doublets. The dynein arms extend from the A microtubule and make temporary cross-bridges with the B microtubule of the adjacent doublet. **Inset.** Compare the diagram with the cross section in the electron micrograph (c) and identify corresponding structures. $\times 180,000$. The molecular structure of the microtubule doublet is shown adjacent to the cross section. Note that the A microtubule of the doublet is composed of 13 tubulin dimers arranged in a side-by-side configuration, whereas the B microtubule is composed of 10 tubulin dimers and shares the remaining dimers with those of the A microtubule. The cross section of the basal body (lower plane) shows the arrangement of nine microtubule triplets. These structures form a ring structure. Each microtubule doublet of the cilium is an extension of two inner microtubules of the corresponding triplet.

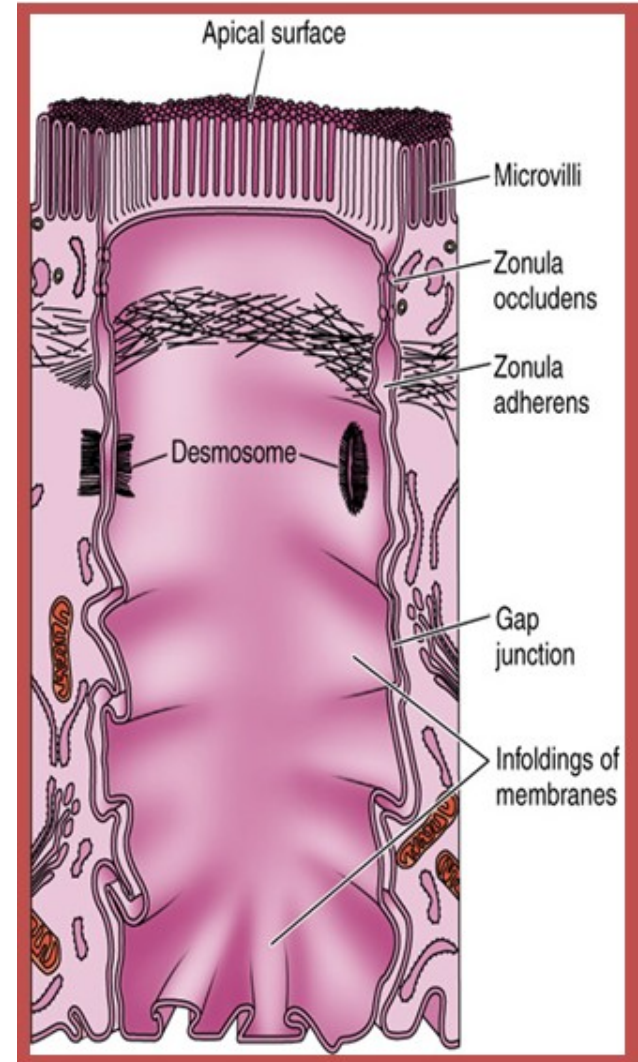
Respiratory tract, LM, Mallory trichrome, x400



EPITHELIAL TISSUE

INTERCELLULAR JUNCTIONS

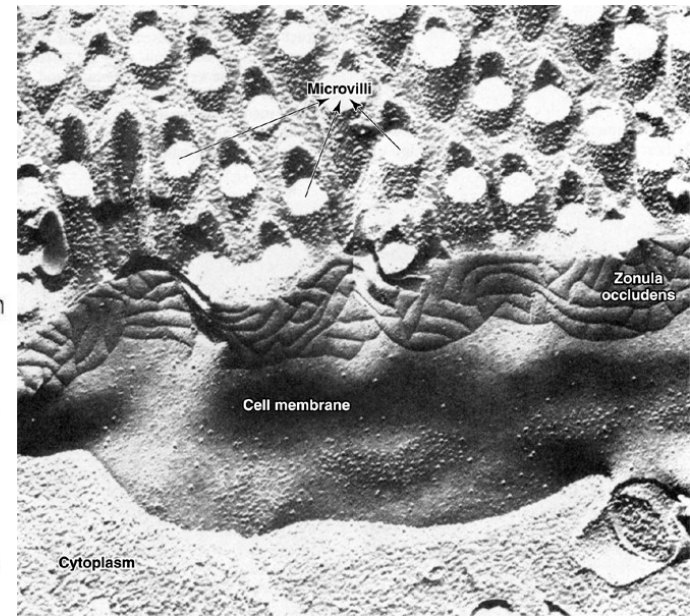
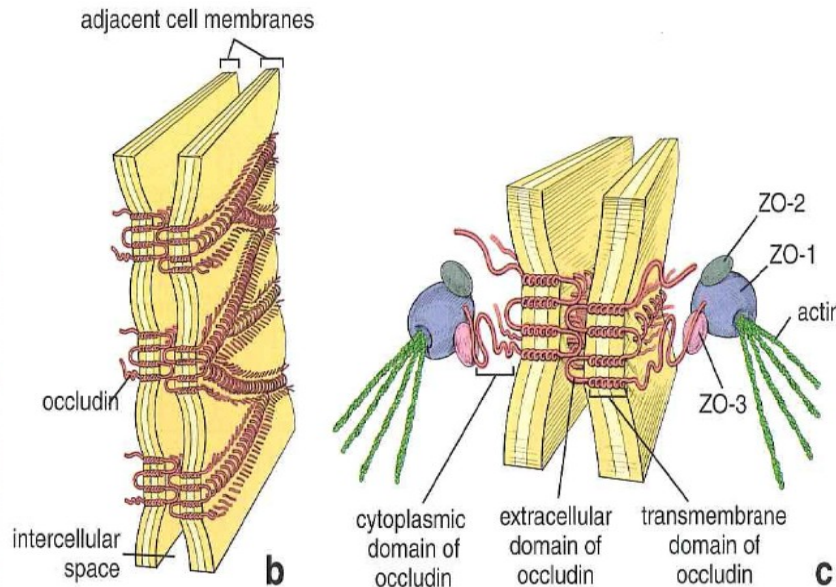
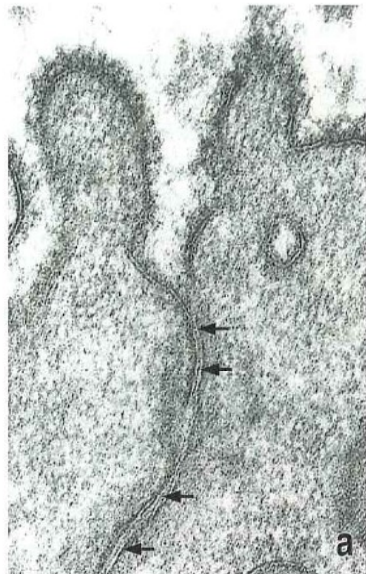
- Specialized structures of the plasma membrane that:
 - Attach and anchor cells
 - Establish apical and basolateral membrane domains by sealing adjacent plasma membranes
 - Provide channels for ionic and metabolic coupling
- Not restricted to epithelial cells; cell junctions occur, however, in large number in epithelial tissues to resist the physical forces acting on the cells.
- Types:
 - Occluding junctions:
 - Zonula occludens (tight junction)
 - Adhesive and anchoring junctions:
 - Zonula adherens (belt desmosome)
 - Macula adherens (desmosome)
 - Hemidesmosome – in basal part of cell
 - Communication between adjacent cells:
 - Gap junctions (nexus)



EPITHELIAL TISSUE

Types of intercellular junctions

- **Tight junction (zonula occludens)**
 - Belt-like, barrier junction around apex of the cell
 - Provides close apposition of adjacent plasma membranes and occludes the intercellular space
 - Functions:
 - Prevents diffusion of material between the intercellular space and the lumen of the organ
 - Establishes apical and basolateral membrane domains in the cell by preventing the lateral migration of proteins in the plasma membrane



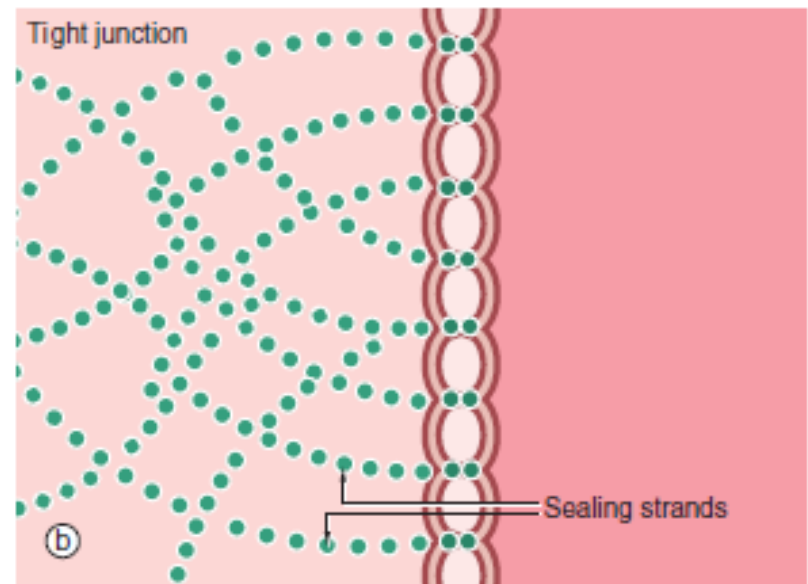
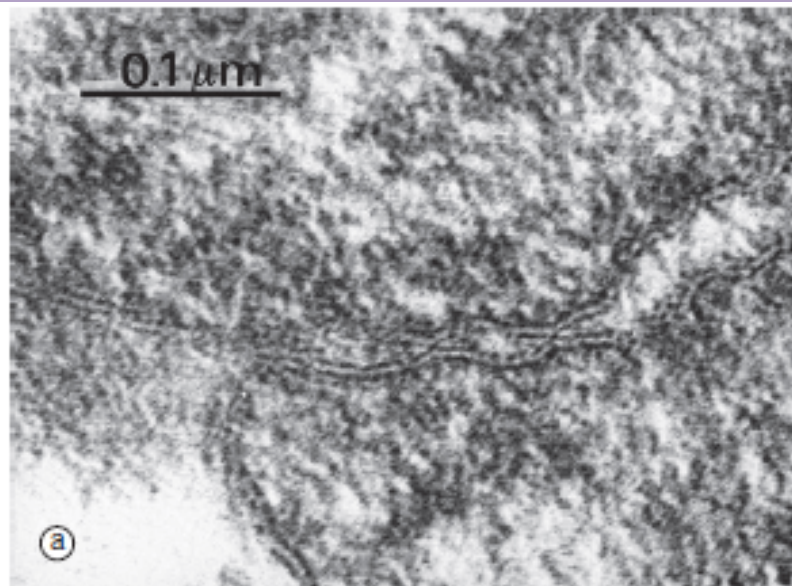


FIG. 5.10 Tight junctions
(a) EM $\times 190\,000$ (b) Schematic diagram

The tight junction (occluding junction or zonula occludens) forms a collar around each cell immediately beneath the apical surface, blocking passage of luminal contents between cells and also lateral movement of plasma membrane proteins and lipids in the plane of the membrane between the apical and the basolateral plasma membrane. As seen in this electron micrograph, the outer electron-dense layers of opposing cell membranes come extremely close together and, in places, appear to fuse completely. At the molecular level, members of the transmembrane protein families, the *claudins* and *occludins*, form tight links between adjacent cells. Claudins allow passage of selected cations between cells, acting as ion channels (the

paracellular pathway). The presence of different claudin molecules in different epithelia explains the variability in permeability between epithelia. *Tricellullin* is also present at junctions where three cells meet. Multiple aggregates of tight junction proteins form a branching network known as *sealing strands*. On the cytoplasmic side of the plasma membrane, the tight junctions are linked to the actin cytoskeleton.

Structurally similar but discontinuous strips of tight junction, called *fascia occludens*, are found between the endothelial cells lining blood vessels, except in the vessels of the brain where they are of the continuous (zonula occludens) type.

EPITHELIAL TISSUE

Types of intercellular junctions

- **Adherent junctions**

- Attach cells to each other or anchor them to the basal lamina; no fusion of the plasma membrane
- Types of adherent junctions:
 - **Belt desmosome (zonula adherens).** Belt-like junction that encircles the apex of the cell like a barrel strap and is located immediately beneath the zonula occludens; serves to attach adjacent cells together; associated with actin filaments.
 - **Spot desmosome (macula adherens).** Disk-like junctions scattered over the surface of the cell, which are paired with similar structures in adjacent cells; associated with intermediate filaments (e.g., keratin filaments in epithelial cells).
 - **Hemidesmosome.** Represents a "half desmosome"; these junctions anchor the basal surface of the cell to the basal lamina.
 - **Junctional complex.** Consists of the zonula occludens, zonula adherens, and desmosomes; because these structures cannot be resolved as separate structures at the light microscopic level, they appear as a single, bar-shaped, dark region at the apical corners of adjacent cells. The term terminal bar was used by early microscopists to define the zonula occludens and zonula adherens at the light microscopic level.

EPITHELIAL TISSUE

Belt desmosome (zonula adherens). Belt-like junction that encircles the apex of the cell like a barrel strap and is located immediately beneath the zonula occludens; serves to attach adjacent cells together; associated with actin filaments.

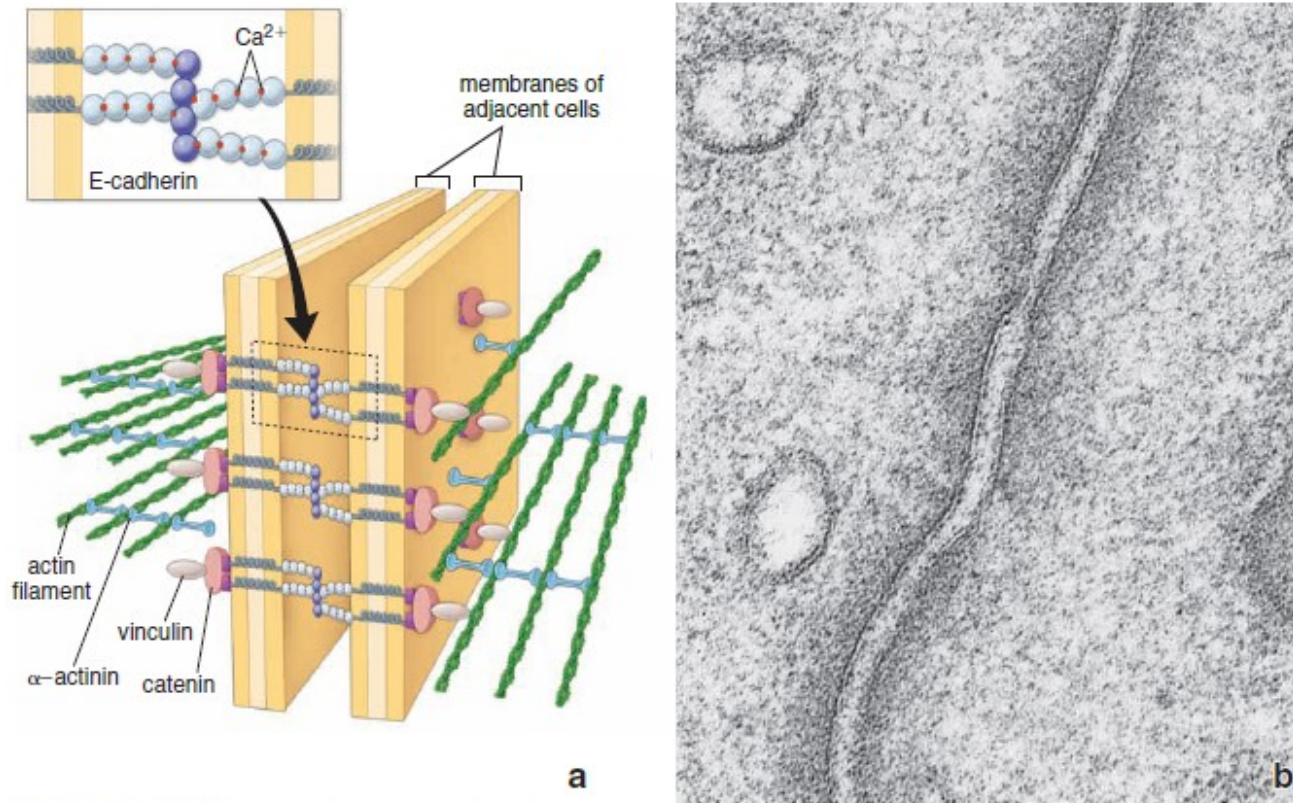


FIGURE 5.19 ▲ **Zonula adherens.** **a.** Molecular organization of zonula adherens. Actin filaments of adjacent cells are attached to the E-cadherin–catenin complex by α -actinin and vinculin. The E-cadherin–catenin complex interacts with identical molecules embedded in the plasma membrane of the adjacent cell. Interactions between transmembrane proteins are mediated by calcium ions. **b.** Electron micrograph of the zonula adherens from Figure 5.14a at higher magnification. The plasma membranes are separated here by a relatively uniform intercellular space. This space appears clear, showing only a sparse amount of diffuse electron-dense substance, which represents extracellular domains of E-cadherin. The cytoplasmic side of the plasma membrane exhibits a moderately electron-dense material containing actin filaments. $\times 100,000$.

EPITHELIAL TISSUE

Spot desmosome (macula adherens). Disk-like junctions scattered over the surface of the cell, which are paired with similar structures in adjacent cells; associated with intermediate filaments (e.g., keratin filaments in epithelial cells).

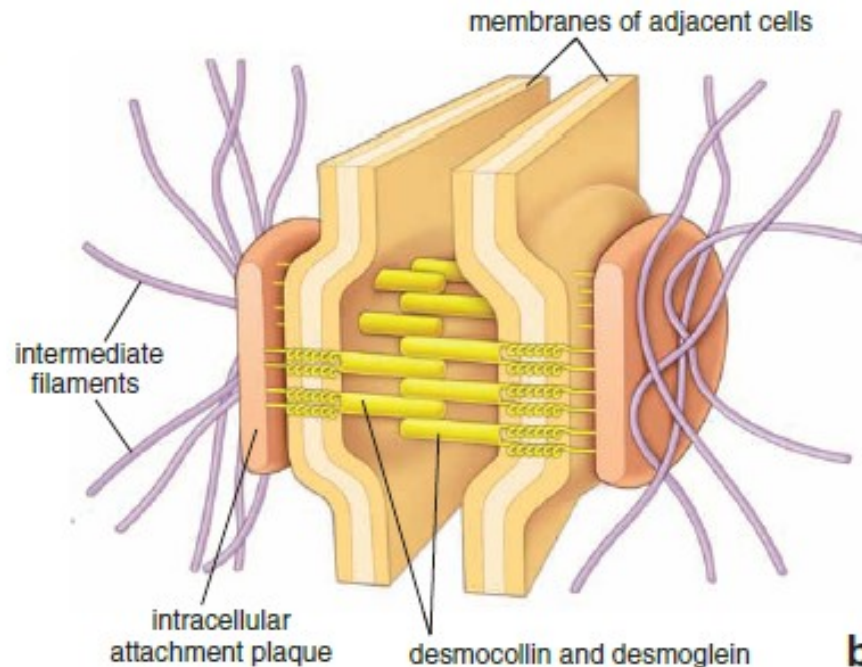
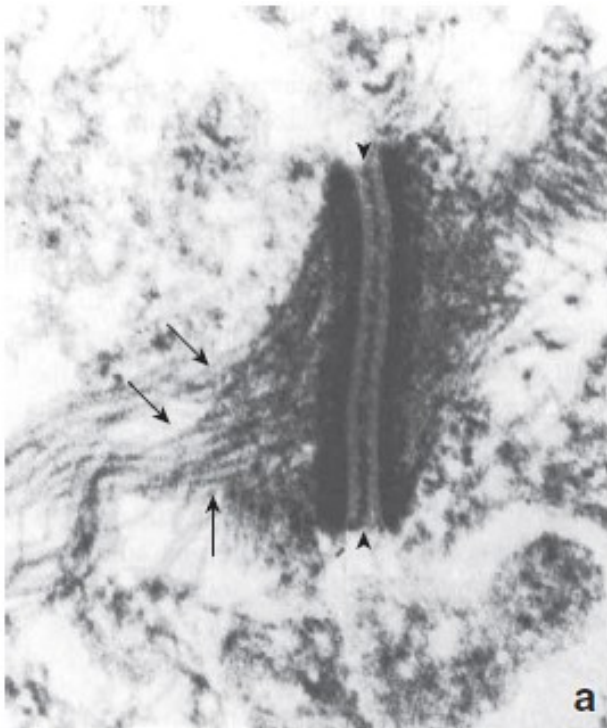


FIGURE 5.21 ▲ **Molecular structure of the macula adherens (desmosome).** **a.** Electron micrograph of a macula adherens, showing the intermediate filaments (*arrows*) attaching into a dense, intracellular attachment plaque located on the cytoplasmic side of the plasma membrane. The intercellular space is also occupied by electron-dense material (*arrowheads*) containing desmocollins and desmogleins. The intercellular space above and below the macula adherens is not well defined because of extraction of the plasma membrane to show components of this structure. $\times 40,000$. (Courtesy of Dr. Ernst Kallenbach.) **b.** Schematic diagram showing the structure of a macula adherens. Note the intracellular attachment plaque with anchored intermediate filaments. The extracellular portions of desmocollins and desmogleins from opposing cells interact with each other in the localized area of the desmosome, forming the cadherin "zipper."

EPITHELIAL TISSUE

Hemidesmosome. Represents a "half desmosome"; these junctions anchor the basal surface of the cell to the basal lamina.

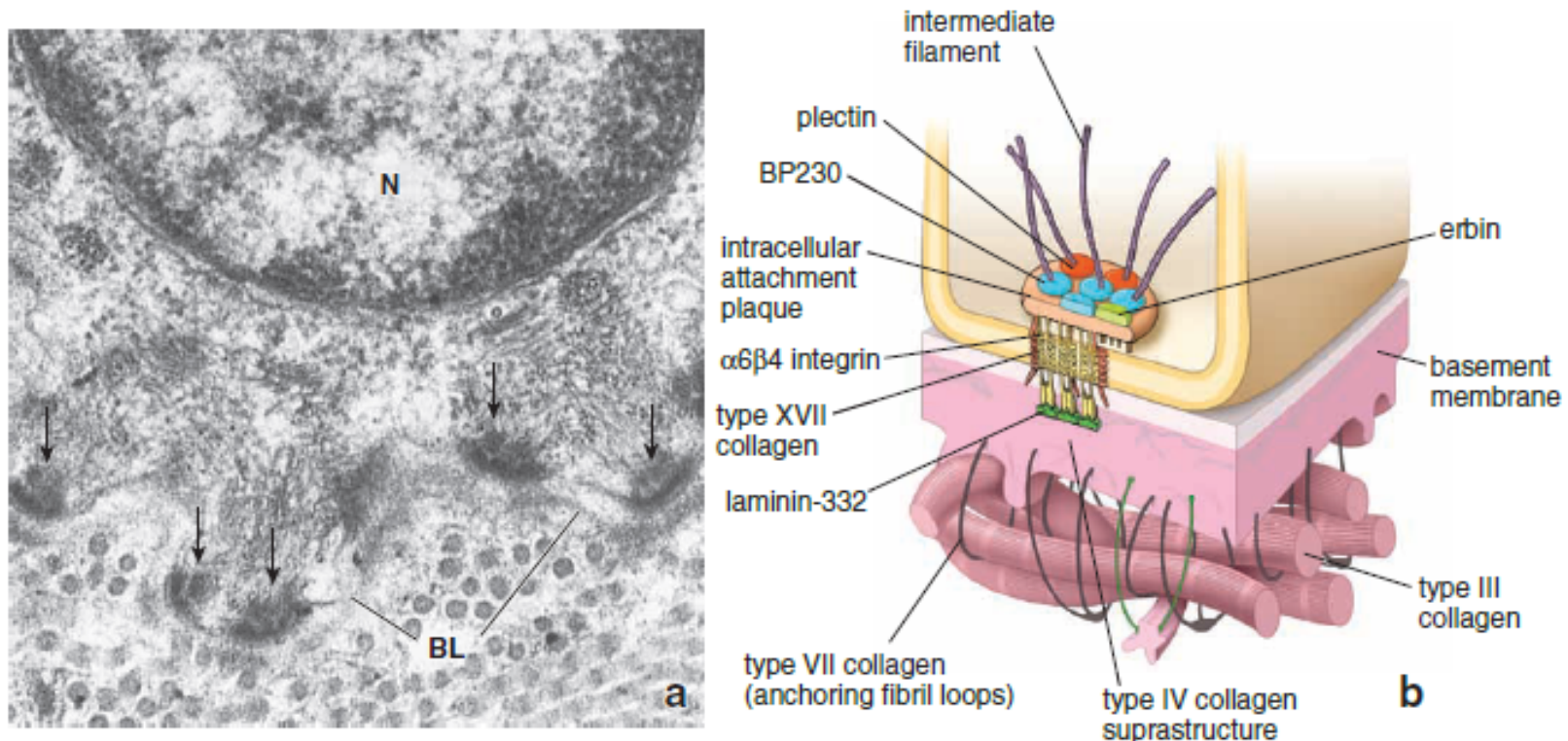


FIGURE 5.36 ▲ **Molecular structure of hemidesmosome.** **a.** Electron micrograph of the basal aspect of a gingival epithelial cell. Below the nucleus (*N*), intermediate filaments are seen converging on the intracellular attachment plaques (*arrows*) of the hemidesmosome. Below the plasma membrane are the basal lamina (*BL*) and collagen (reticular) fibrils (most of which are cut in cross-section) of the connective tissue. $\times 40,000$. **b.** Diagram showing the molecular organization of a hemidesmosome. The intracellular attachment plaque is associated with transmembrane adhesion molecules, such as the family of integrins and transmembrane type XVII collagen, and contains plectin, BP 230, and erbin. Note that the intermediate filaments seem to originate or terminate in the intracellular attachment plaque. Extracellular portions of integrins bind to laminin-332 and type IV collagen. With the help of anchoring fibrils (type VII collagen), laminin, and integrin, the attachment plaque is secured to the reticular fibers (type III collagen) of the extracellular matrix.

EPITHELIAL TISSUE

Junctional complex. Consists of the *zonula occludens*, *zonula adherens*, and *desmosomes*; because these structures cannot be resolved as separate structures at the light microscopic level, they appear as a single, bar-shaped, dark region at the apical corners of adjacent cells. The term **terminal bar** was used by early microscopists to define the zonula occludens and zonula adherens at the light microscopic level.

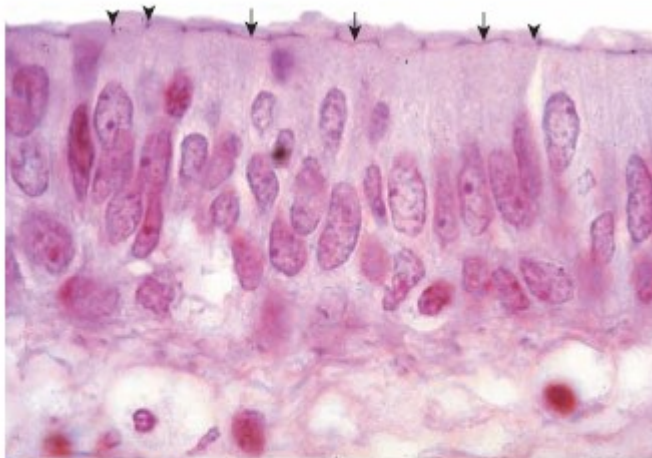
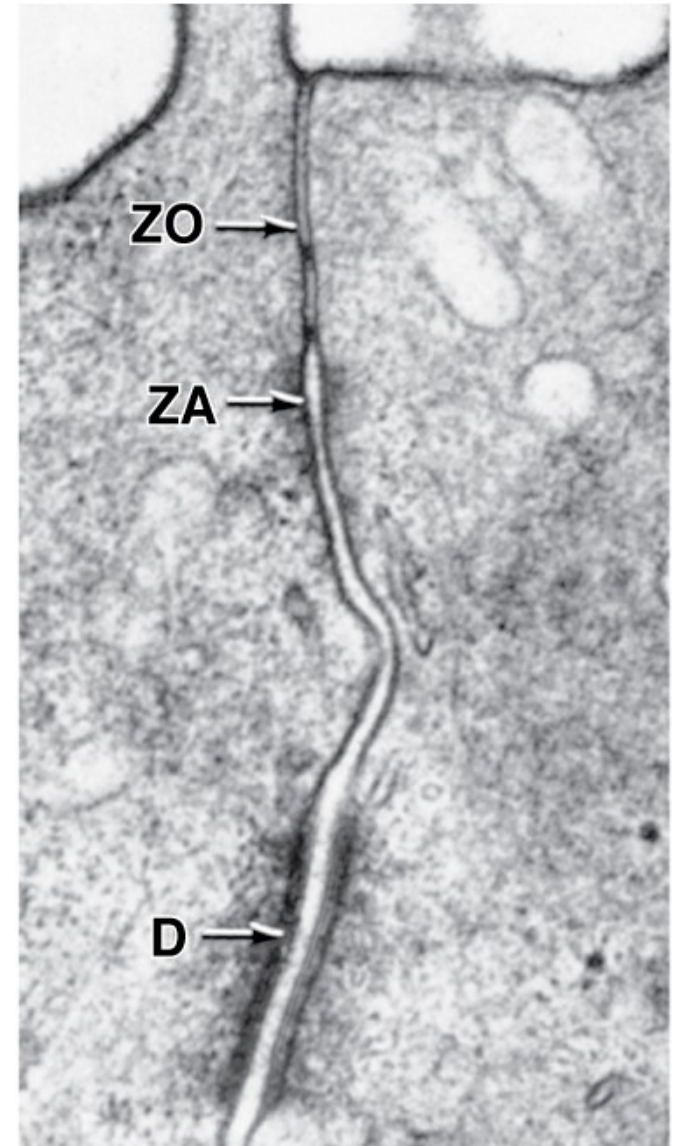


FIGURE 5.13 ▲ Terminal bars in pseudostratified epithelium. Photomicrograph of an H&E-stained specimen showing the terminal bars in a pseudostratified epithelium. The bar appears as a dot (*arrowheads*) when seen on its cut edge. When the bar is coursing parallel to the cut surface and lying within the thickness of the section, it is seen as a linear or bar-like profile (*arrows*). $\times 550$.



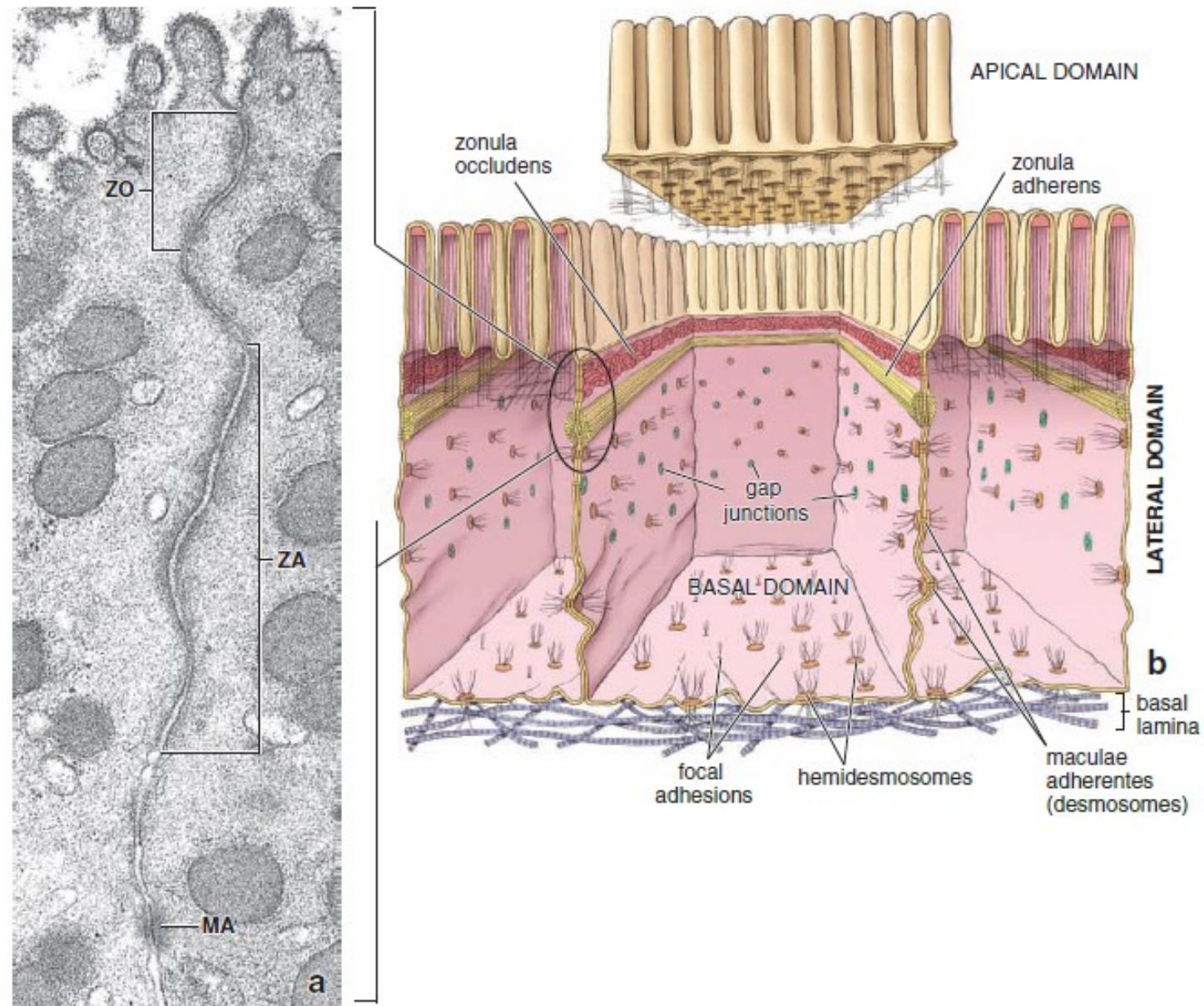
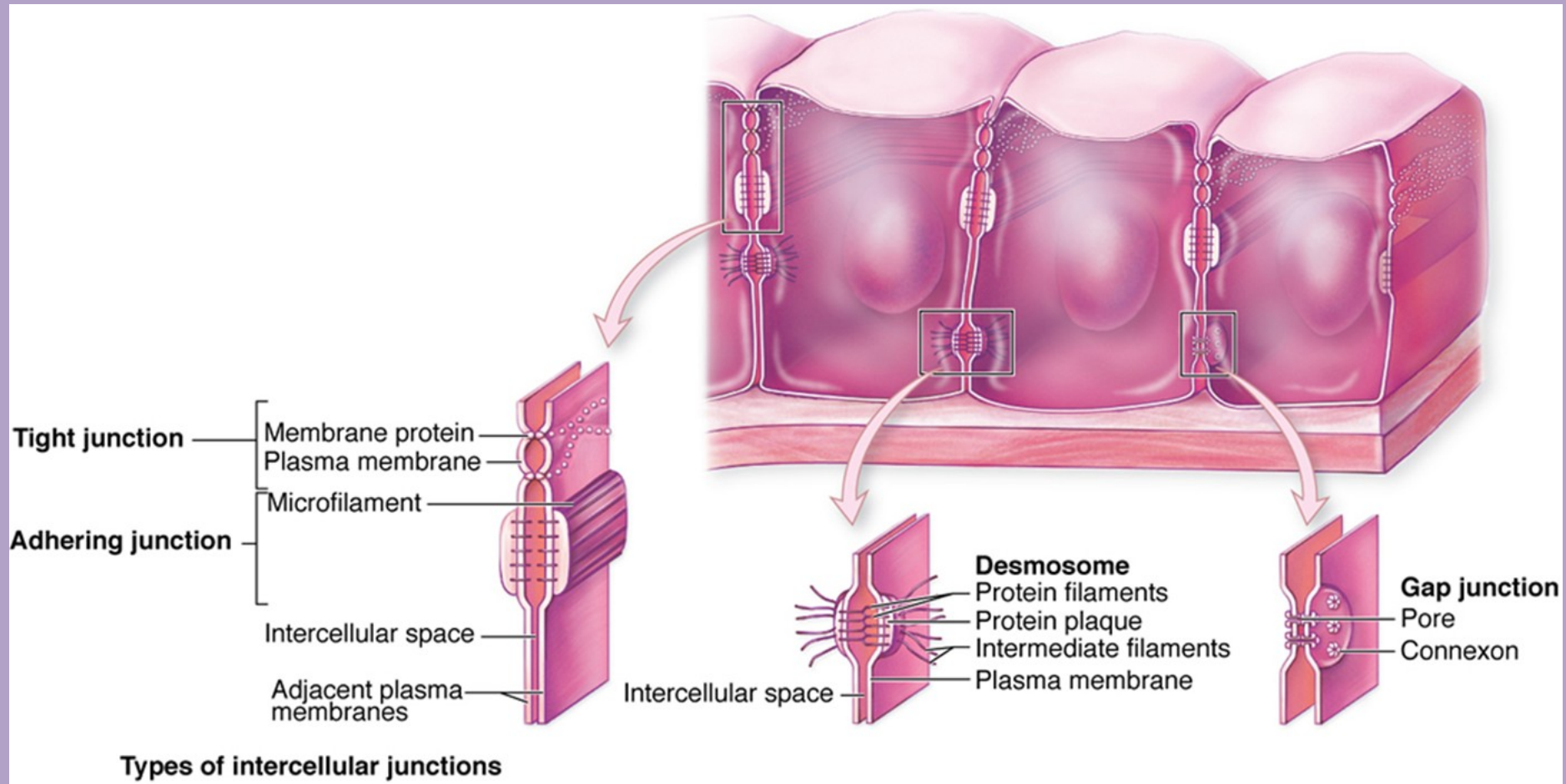


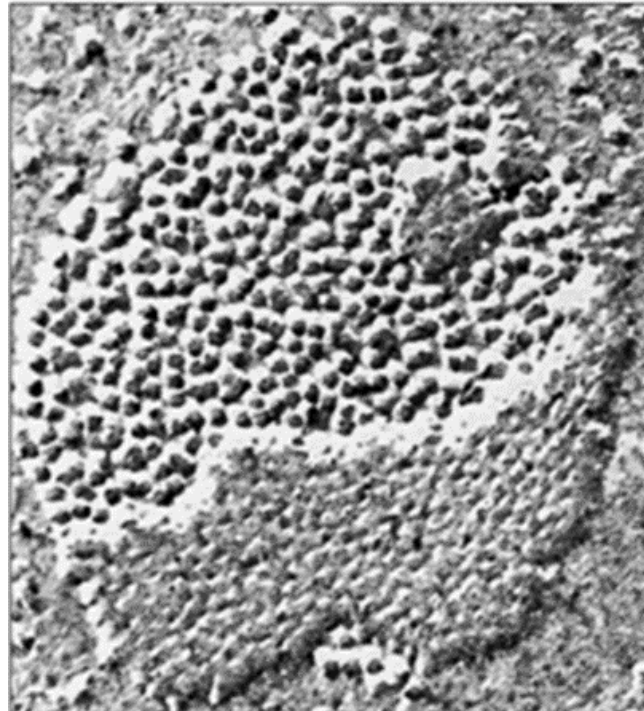
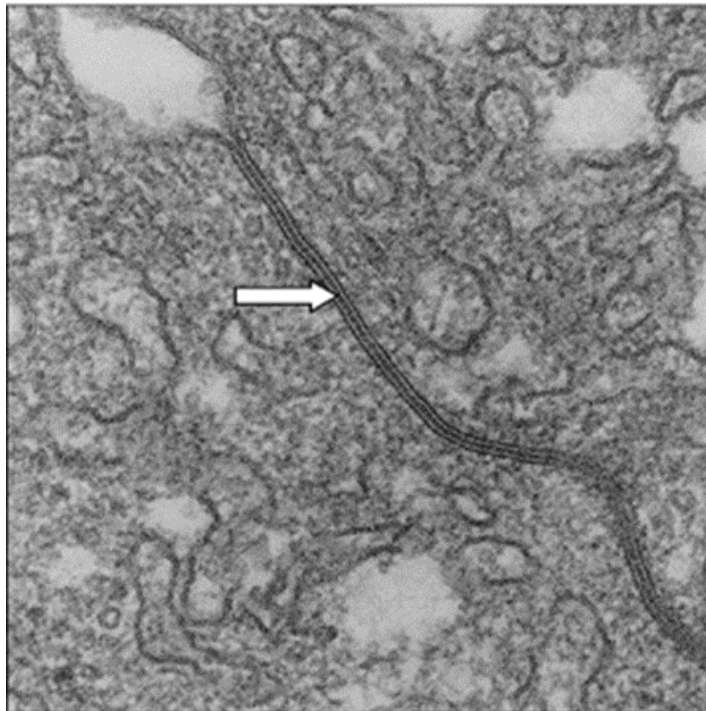
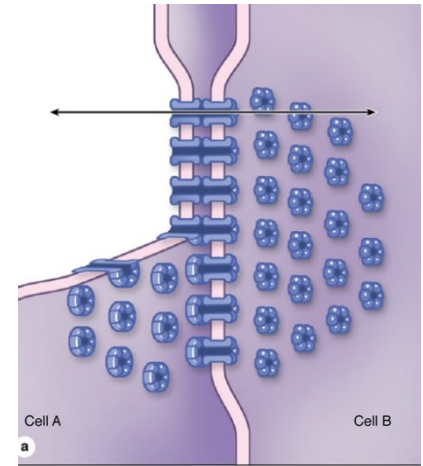
FIGURE 5.14 ▲ Junctional complex. **a.** Electron micrograph of the apical portion of two adjoining epithelial cells of the gastric mucosa, showing the junctional complex. It consists of the zonula occludens (ZO), zonula adherens (ZA), and macula adherens (MA). $\times 30,000$. **b.** Diagram showing the distribution of cell junctions in the three cellular domains of columnar epithelial cells. The apical domain with microvilli has been lifted to better illustrate spatial arrangements of junctional complexes within the cell.



EPITHELIAL TISSUE

Gap junction

- Gap junctions (protein channels connecting plasma membranes) consist of connexons, six transmembrane proteins clustered in a rosette that form a central pore. Connexons from adjacent cells abut one another, forming a continuity between cells.
- Provides metabolic and electrical continuity (coupling) via the pores between cells



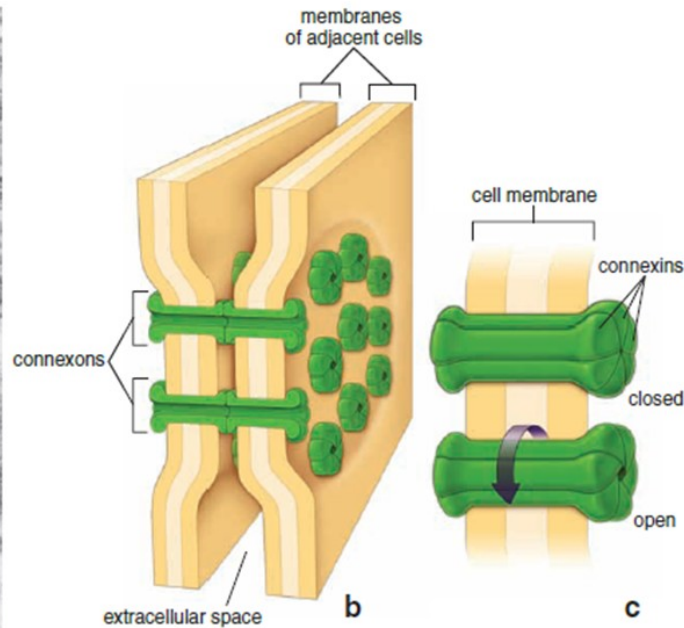
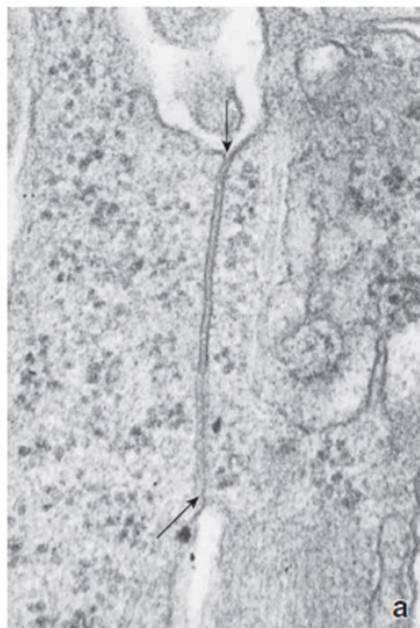


FIGURE 5.22 ▲ Structure of a gap junction. **a.** Electron micrograph showing the plasma membranes of two adjoining cells forming a gap junction. The unit membranes (arrows) approach one another, narrowing the intercellular space to produce a 2-nm-wide gap. $\times 76,000$. **b.** Drawing of a gap junction showing the membranes of adjoining cells and the structural components of the membrane that form channels or passageways between the two cells. Each passageway is formed by a circular array of six subunits, dumbbell-shaped transmembrane proteins that span the plasma membrane of each cell. These complexes, called *connexons*, have a central opening of about 2 nm in diameter. The channels formed by the registration of the adjacent complementary pairs of connexons permit the flow of small molecules through the channel but not into the intercellular space. Conversely, substances in the intercellular space can permeate the area of a gap junction by flowing around the connexon complexes, but they cannot enter the channels. **c.** The diameter of the channel in an individual connexon is regulated by reversible changes in the conformation of the individual connexins.

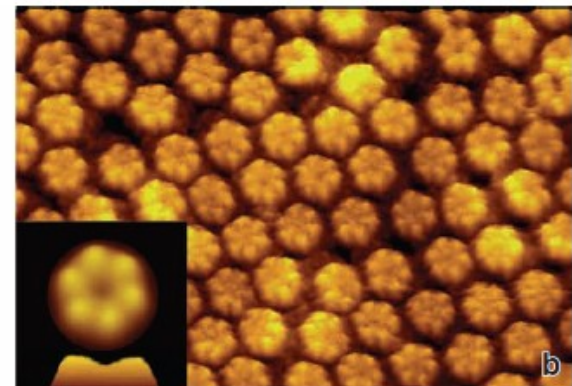
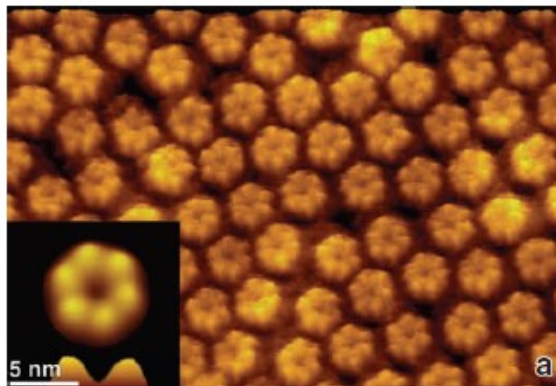


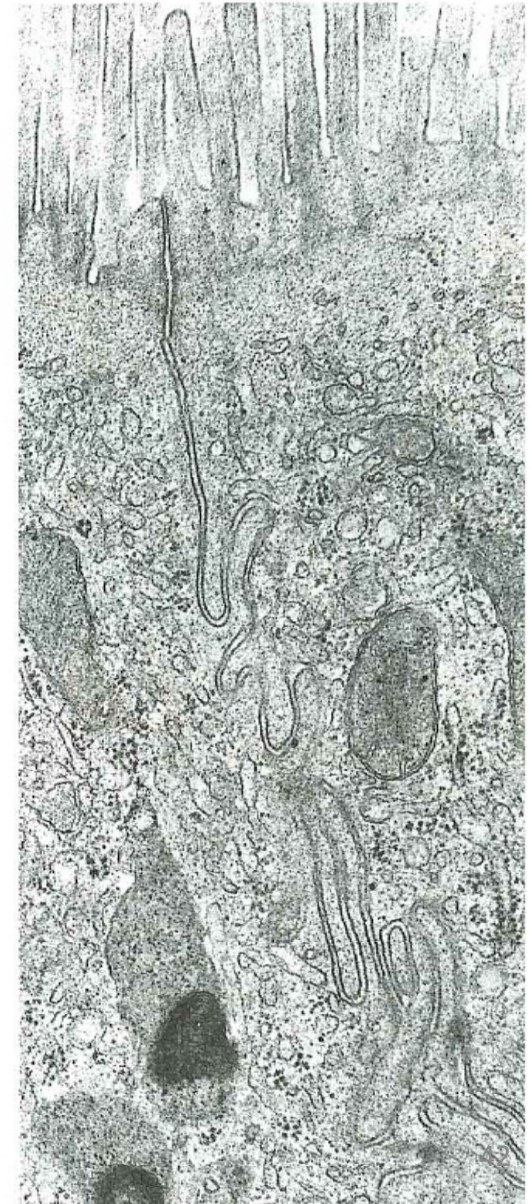
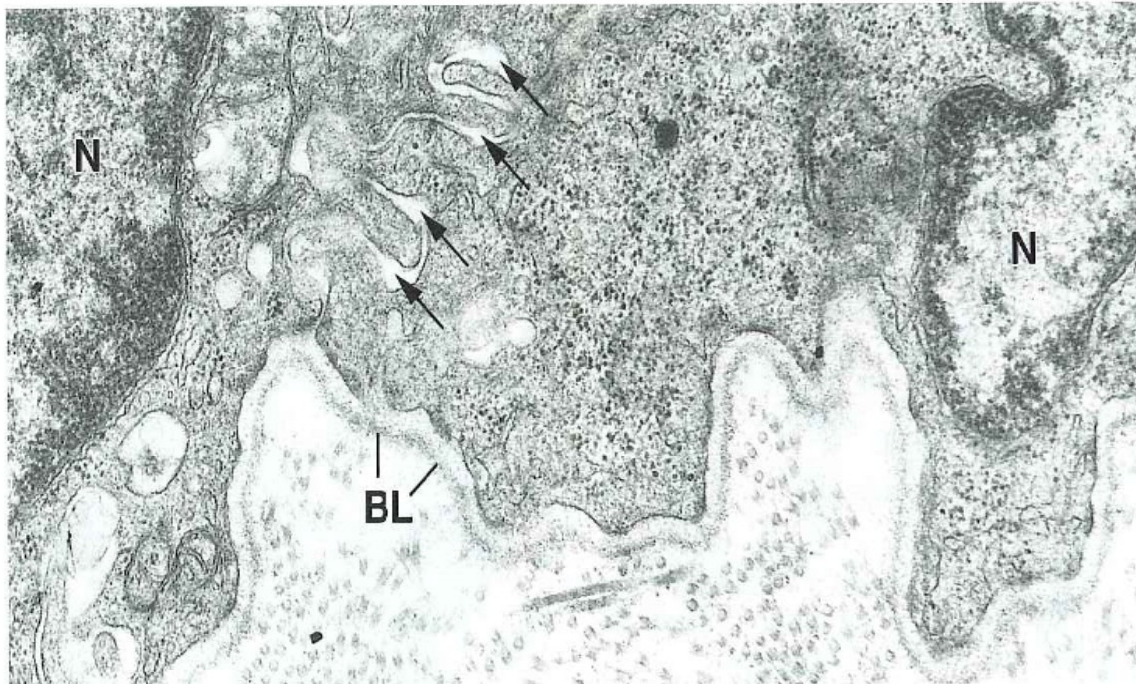
FIGURE 5.23 ▲ Atomic force microscopic (AFM) image of a gap junction. These images show the extracellular surface of a plasma membrane preparation from the HeLa cell line. Multiple copies of the connexin-26 gene were incorporated into the HeLa cell genome to achieve overexpression of the connexin protein. Connexin-26 proteins self-assemble into functional gap junctions, and they were observed with AFM in two different buffer solutions. **a.** Gap junction containing individual connexons in a calcium-free buffer solution. $\times 500,000$. *Inset* shows a single connexon at higher magnification. Note the clear profiles of individual connexin molecules assembled into the connexon. The open profile of the channel is also visible. $\times 2,000,000$. **b.** The same preparation of connexons in a buffer containing Ca^{2+} . $\times 500,000$. *Inset*. Note that the conformational change of the connexin molecules has caused the channel to close and has reduced the height of the connexon. $\times 2,000,000$. (Courtesy of Dr. Gina E. Sosinsky.)

EPITHELIAL TISSUE

MORPHOLOGIC SPECIALIZATIONS OF THE LATERAL CELL SURFACE

Cellular interdigitations

- Lateral cell surface folds create interdigitating cytoplasmic processes of adjoining cells.
- Infoldings increase the lateral surface.
- Electrolyte active fluid transport (intestinal, gallbladder epithelium)

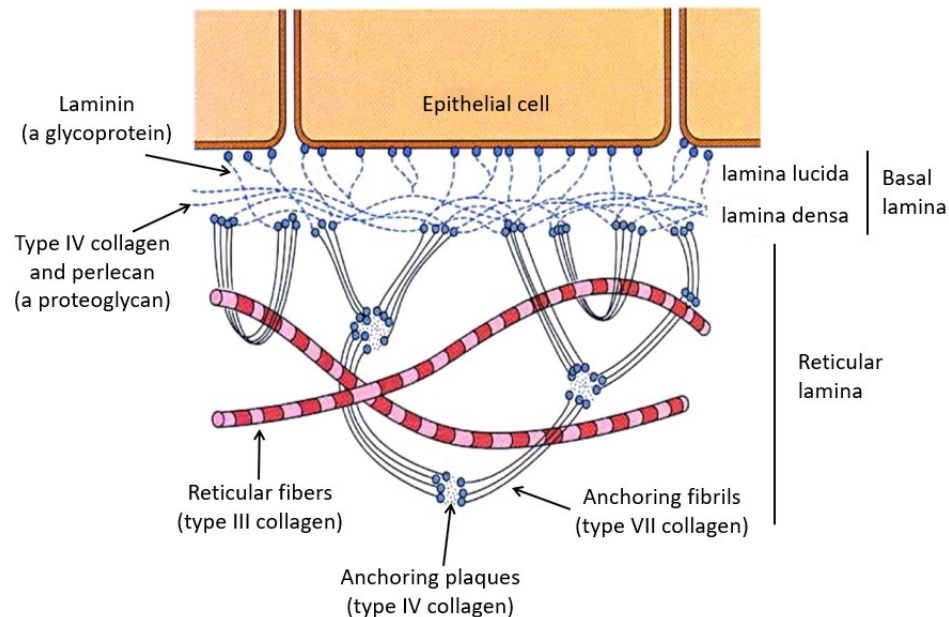


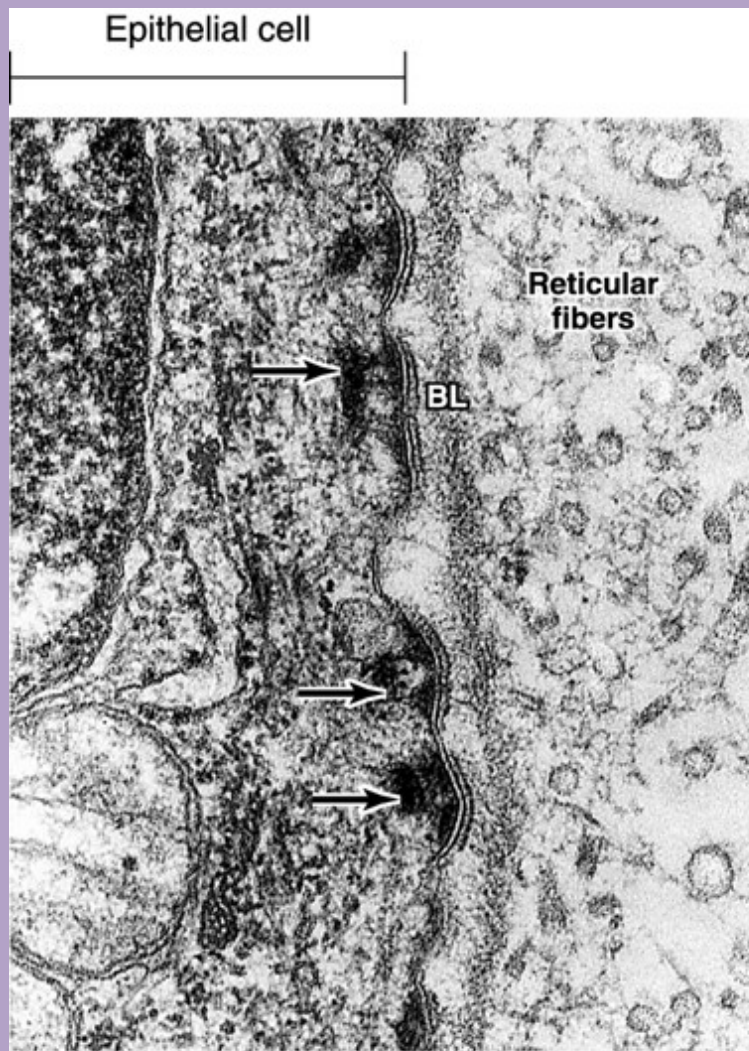
EPITHELIAL TISSUE

BASEMENT MEMBRANE

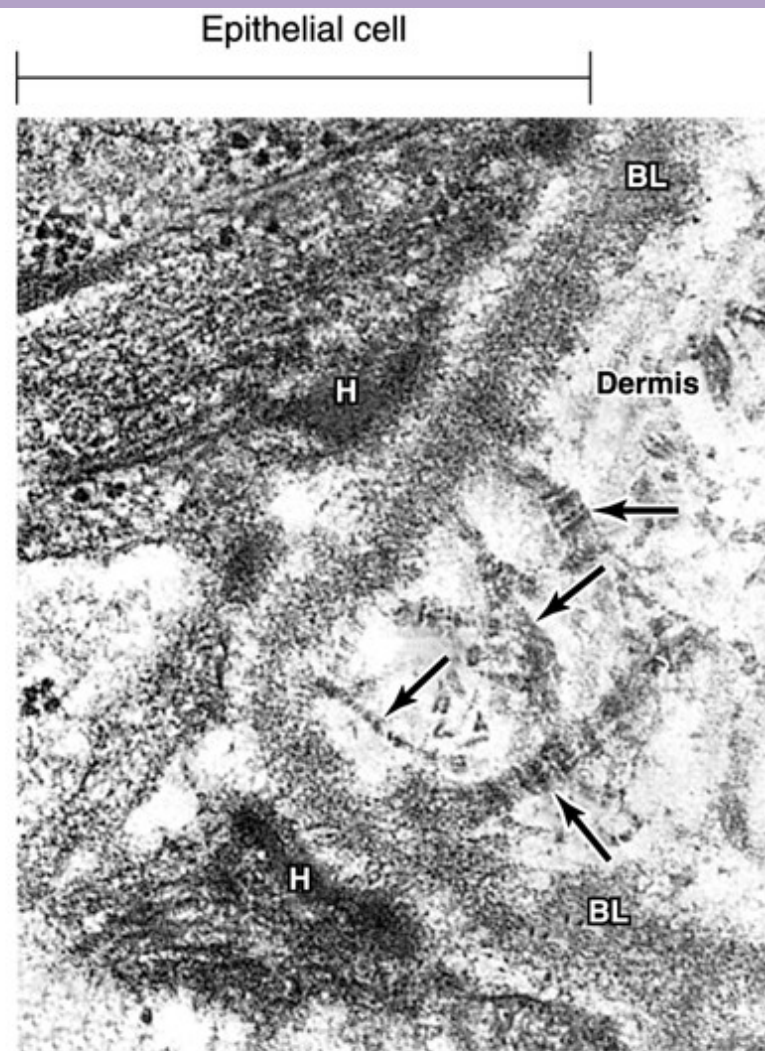
- **Basement membrane**

- The basement membrane is composed of a **basal lamina** and a **reticular lamina**.
- The basal lamina is secreted by the epithelial cells and consists of the *lamina lucida* and the *lamina densa*. A similar structure is also present in muscle and nervous tissue, where it is referred to as an external lamina.
- The reticular lamina is secreted by fibroblasts located in the underlying connective tissue.
- Functions of the basement membrane:
 - Provides support and attachment for the epithelial cells
 - Acts as a selective diffusion barrier





A



B

Ultrastructural components of the basal lamina. A: Basal lamina, hemidesmosomes (arrows) and underlying reticular fibres of the reticular lamina. B: The basal lamina (BL) is shown to have a dense layer with a clear on each side. The underlying dermis contain anchoring fibrils (arrows) of collagen which help anchor the epithelium to the underlying connective tissue. Hemidesmosome (H) occur at the epithelial-connective tissue junction.

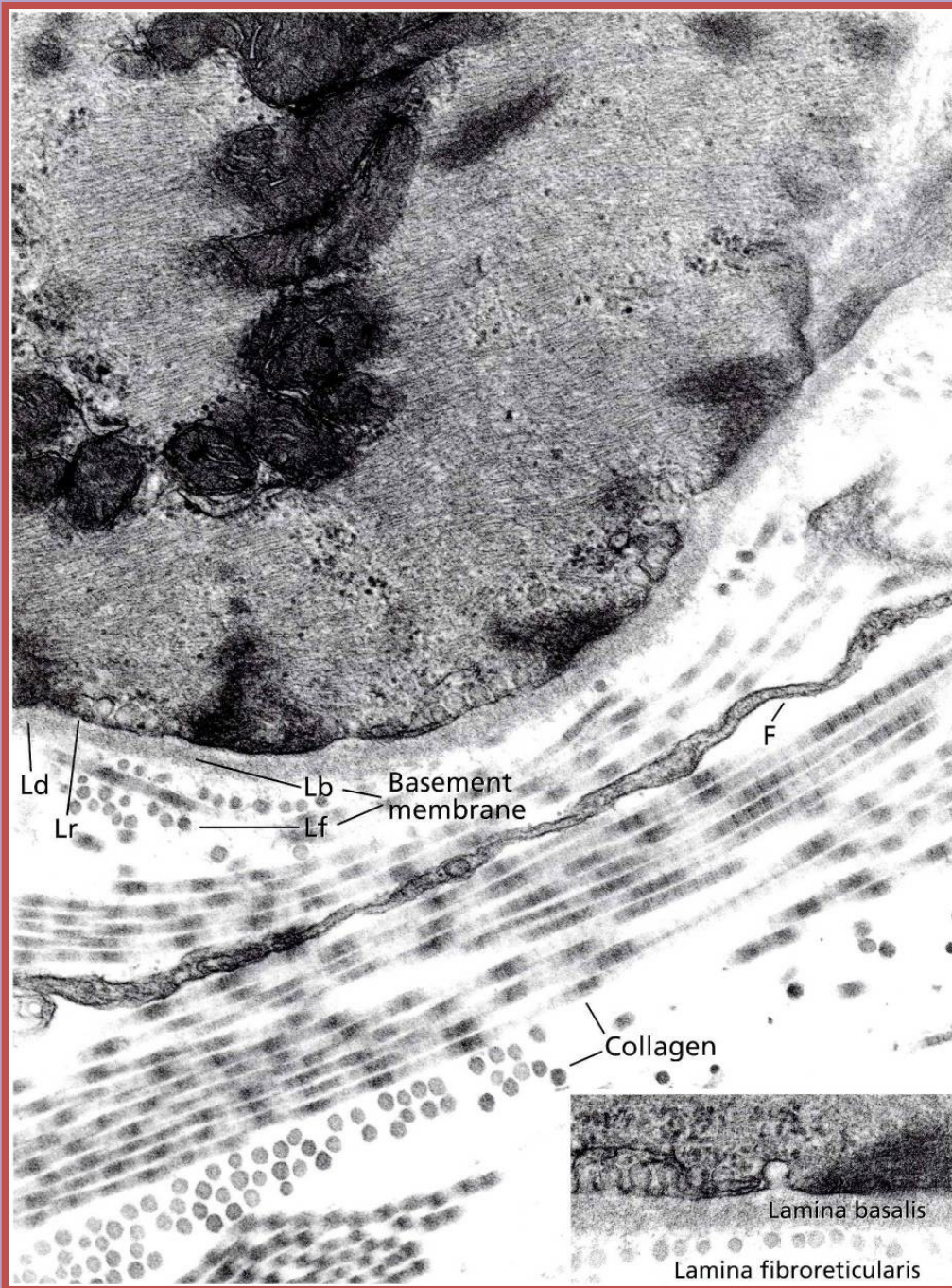
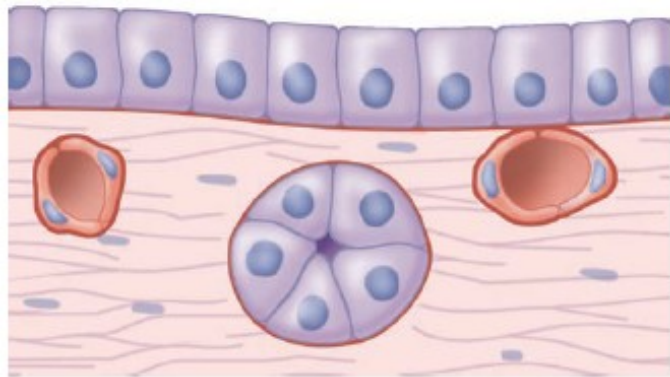
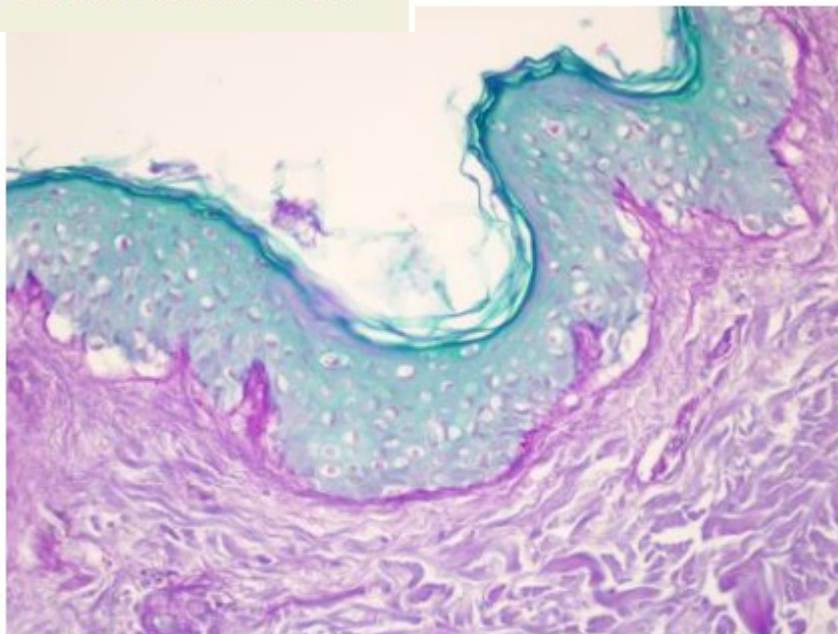


FIGURE 4-1 Epithelia and adjacent connective tissue.

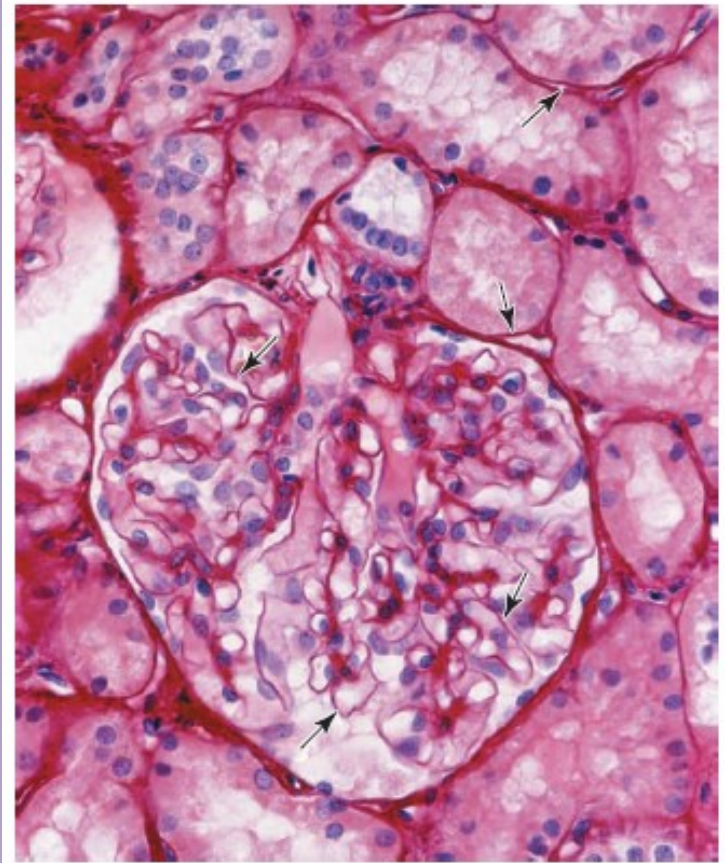


Cuboidal or pyramidal cells of epithelia generally have spherical nuclei, while nuclei of squamous epithelial cells are flattened. An extracellular **basement membrane** (red) always lies at the interface of epithelial cells and connective tissue. Nutrients for epithelial cells must diffuse across the basement membrane. Nerve fibers normally penetrate this structure, but small blood capillaries (being epithelial themselves) normally never enter epithelia.



1.2 PAS of normal skin. The basement membrane stained with periodic acid-schiff stain.

FIGURE 4-2 Basement membranes.



This section of kidney shows the well-stained basement membranes (arrows) of epithelia forming structures within the large, round renal glomerulus and its surrounding tubules. In kidney glomeruli the basement membrane, besides having a supporting function, has a highly developed role as a filter that is key to renal function. (X100; Picrosirius-hematoxylin [PSH])

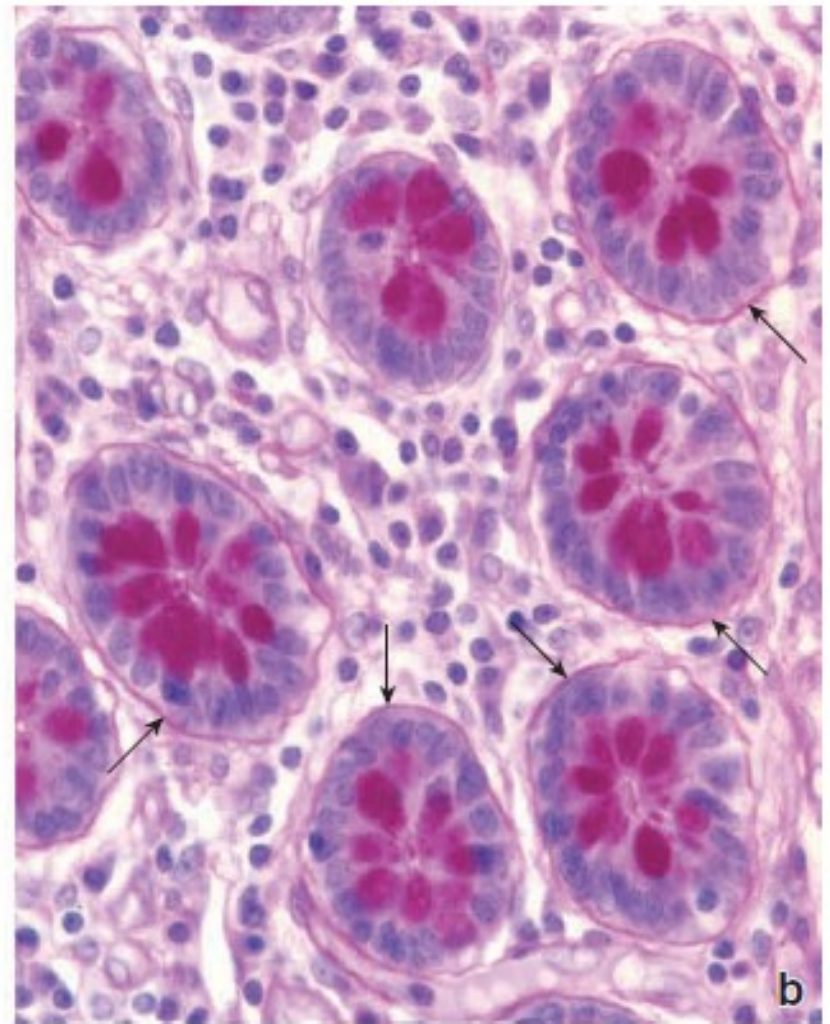
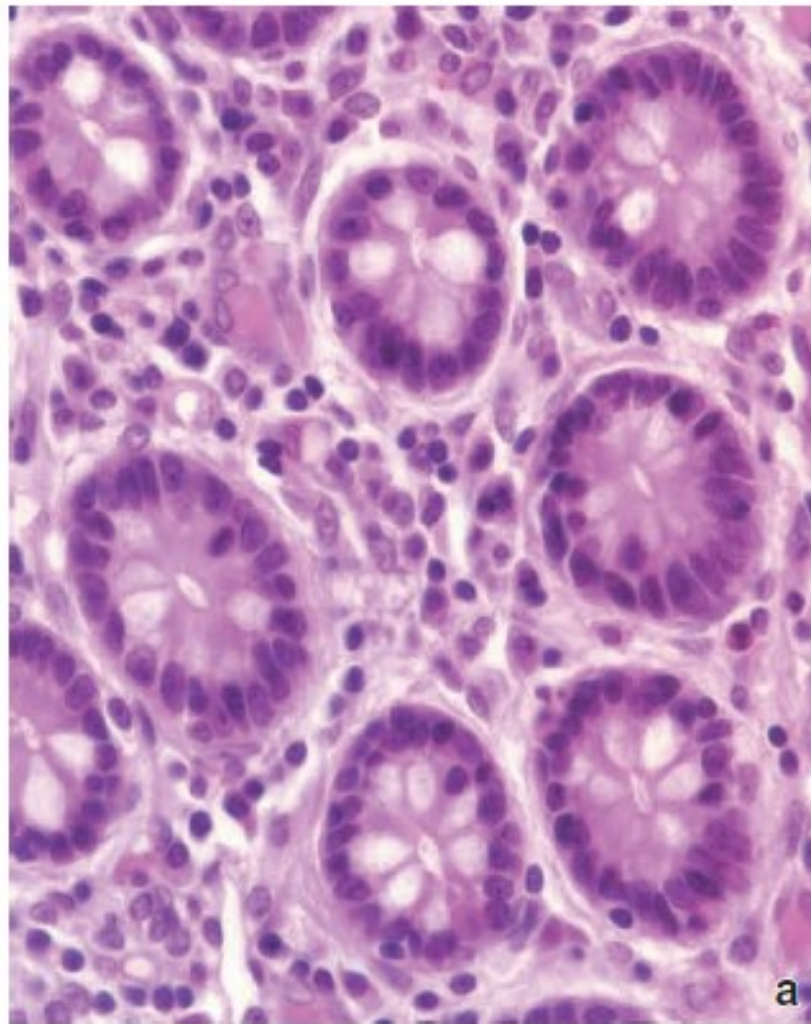


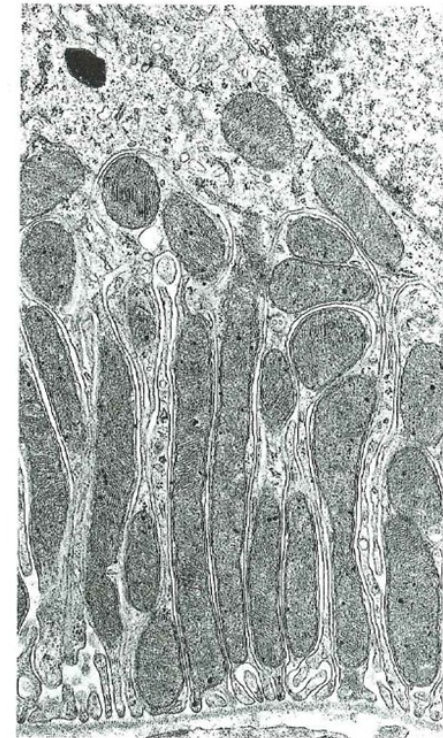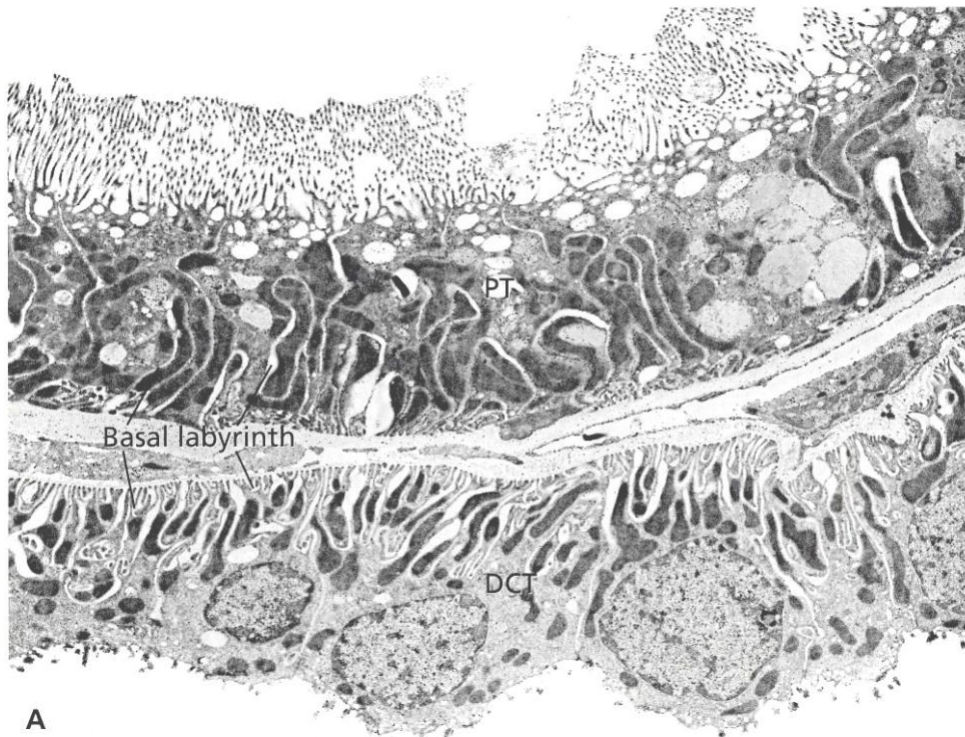
FIGURE 5.26 ▲ Photomicrographs showing serial sections of intestinal glands of the colon. The glands in this specimen have been cross-sectioned and appear as round profiles. **a.** This specimen was stained with H&E. Note that neither the basement membrane nor the mucin that is located within the goblet cells is stained. $\times 550$. **b.** This section was stained by the PAS method. It reveals the basement membrane as a thin, magenta layer (*arrows*) between the base of the epithelial cells of the glands and the adjacent connective tissue. The mucin within the goblet cells is also PAS positive. $\times 550$.

EPITHELIAL TISSUE

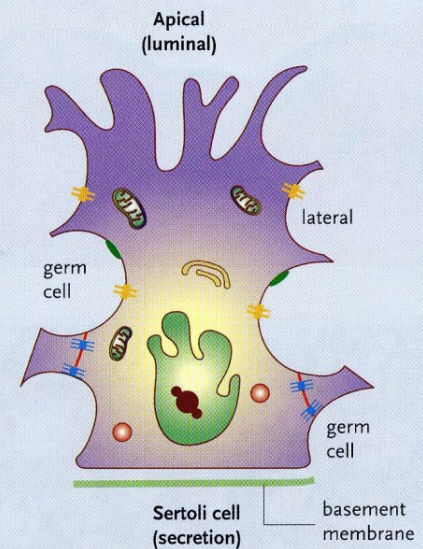
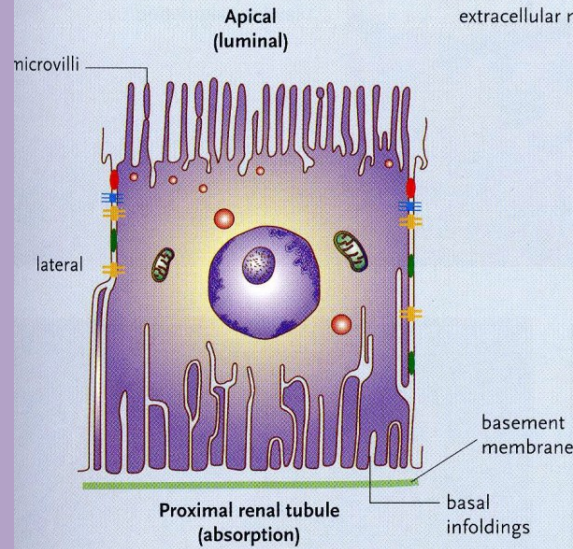
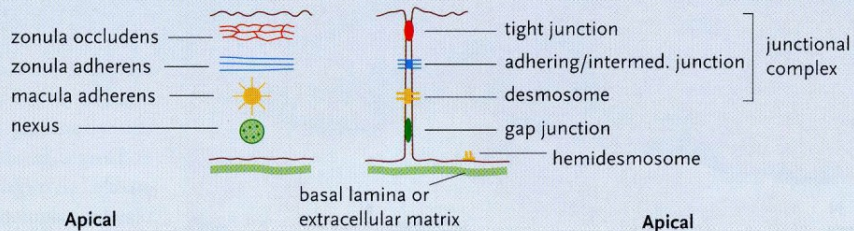
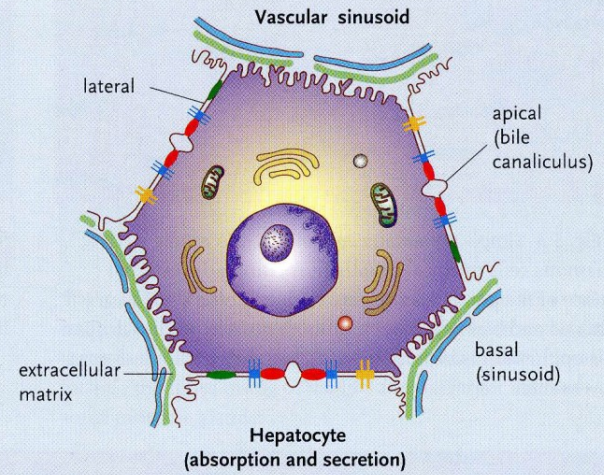
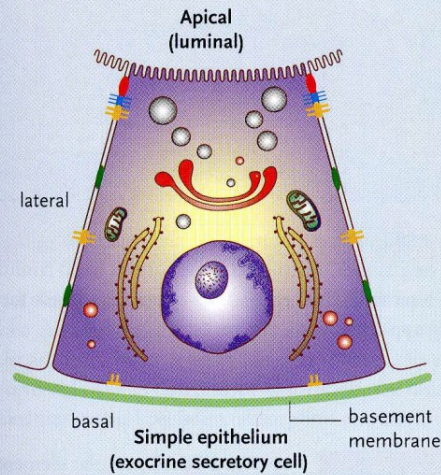
MORPHOLOGIC MODIFICATIONS OF THE BASAL CELL SURFACE

Basal Labyrinth

- Many cells that transport fluid have infoldings at the basal cell surface.
- They significantly increase the surface area of the basal cell domain, allowing for more transport proteins and channels to be present.
- Prominent infoldings – cells with active transport of molecules (e.g., in proximal and distal tubules of the kidney)
- Mitochondria – typically concentrated, vertically oriented within the folds, energy for active



Cell polarity - examples

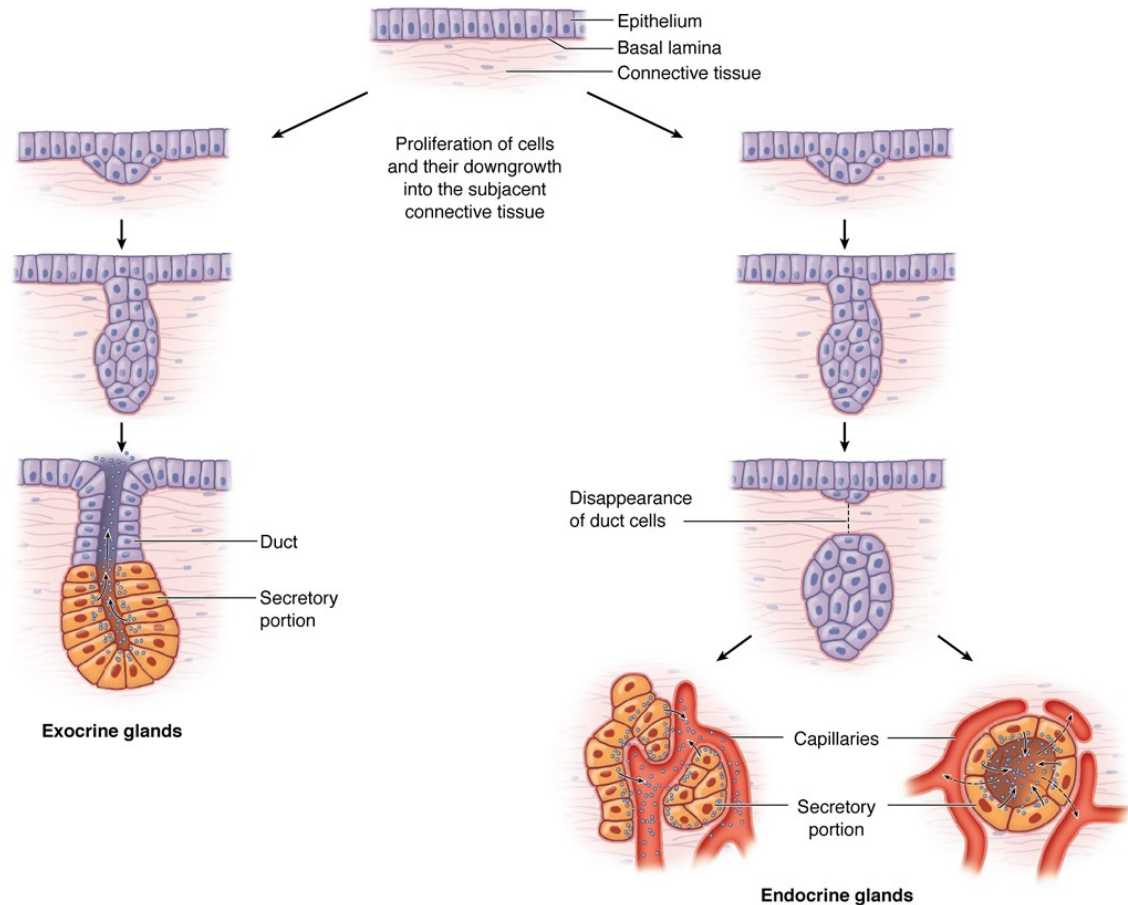


EPITHELIAL TISSUE

GLANDULAR EPITHELIAL TISSUES

GENERAL CONCEPTS

- Develop from or within a lining or covering epithelium
- Secretory cells may
 - Differentiate but remain in the lining epithelium
 - Invaginate into the underlying connective tissue and remain attached to the lining epithelium
 - Invaginate into the underlying connective tissue but lose their connection to the epithelium



During fetal development epithelial cells proliferate and penetrate the underlying connective tissue. These cells may—or may not—maintain a connection with the surface epithelium. The connection is maintained to form a duct in exocrine glands; it is lost as endocrine glands develop. Exocrine glands secrete substances to specific organs via duct systems. Endocrine glands produce hormones and

are always rich in capillaries. Hormones are released outside the cells and picked up by these blood vessels for distribution throughout the body, where specific target cells are identified by receptors for the hormones. Endocrine glands can have secretory cells arranged as irregular cords (left) or as rounded follicles (right) with lumens for temporary storage of the secretory product.

EPITHELIAL TISSUE

EXOCRINE VS. ENDOCRINE GLANDS

Major classification of glands, which is based on the method by which their secretory product is distributed.

- **Exocrine glands** (retains connection with surface epithelium)
 - Secretory products are released onto an external or internal epithelial surface, either directly or via a duct or duct system.
 - Secretory cells display polarized distribution of organelles.
- **Endocrine glands** (no connection with surface epithelium)
 - No ducts; secretory products are released directly into the extracellular fluid where they can affect adjacent cells (paracrine secretion) or enter the bloodstream to influence cells throughout the body (endocrine secretion).
 - No polarization of organelles, except the thyroid gland and enteroendocrine cells of the digestive tract.
 - Secretory products are called hormones.

EPITHELIAL TISSUE

GLANDULAR EPITHELIAL TISSUES

METHODS OF PRODUCT RELEASE FROM GLANDULAR CELLS

- **Merocrine.** Secretory product is released by exocytosis of contents contained within membrane-bound vesicles. This method of release is used by both exocrine and endocrine glands. Examples are digestive enzymes from pancreatic acinar cells and insulin from pancreatic islet cells.
- **Apocrine.** Secretory material is released in an intact vesicle along with some cytoplasm from the apical region of the cell. This method of release is used by exocrine glands only. An example is the lipid component of the secretory product of the mammary gland.
- **Holocrine.** Entire cell is released during the secretory process. Cells that are released may be viable (oocyte or sperm) or dead (sebaceous glands). This method of release is used by exocrine glands only.
- **Diffusion.** Secretory product passes through the cell membrane without the formation of secretory granules. Examples are steroid hormones. This method of release is used by endocrine glands only.

EPITHELIAL TISSUE

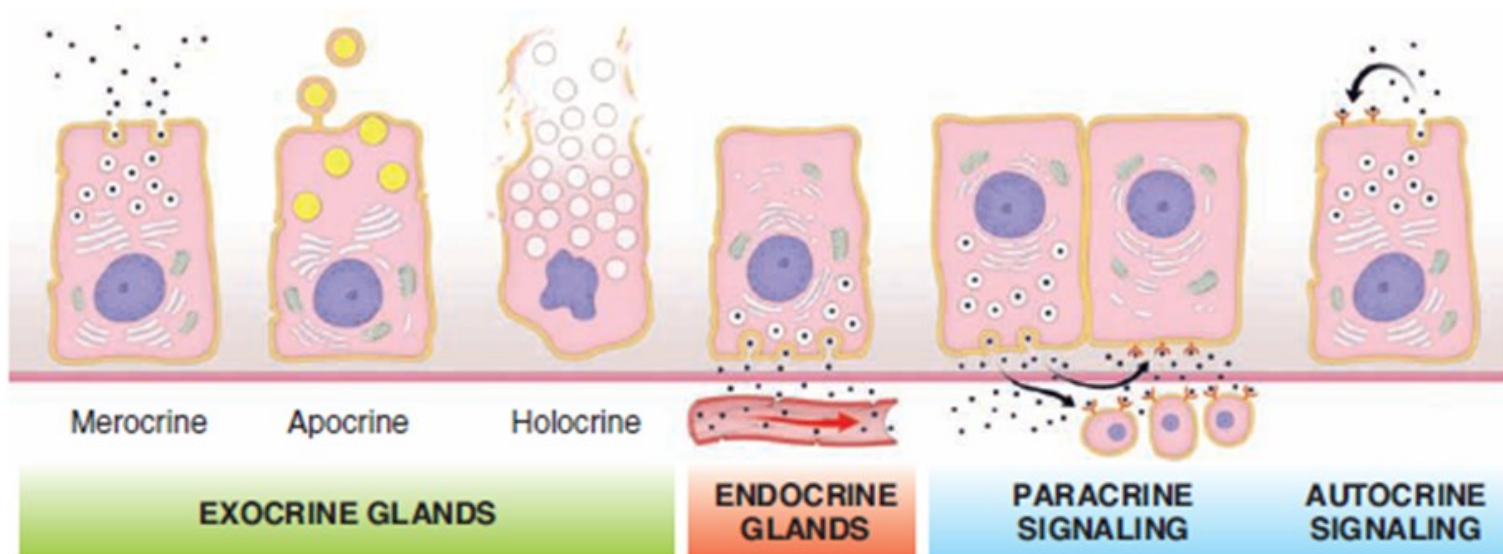
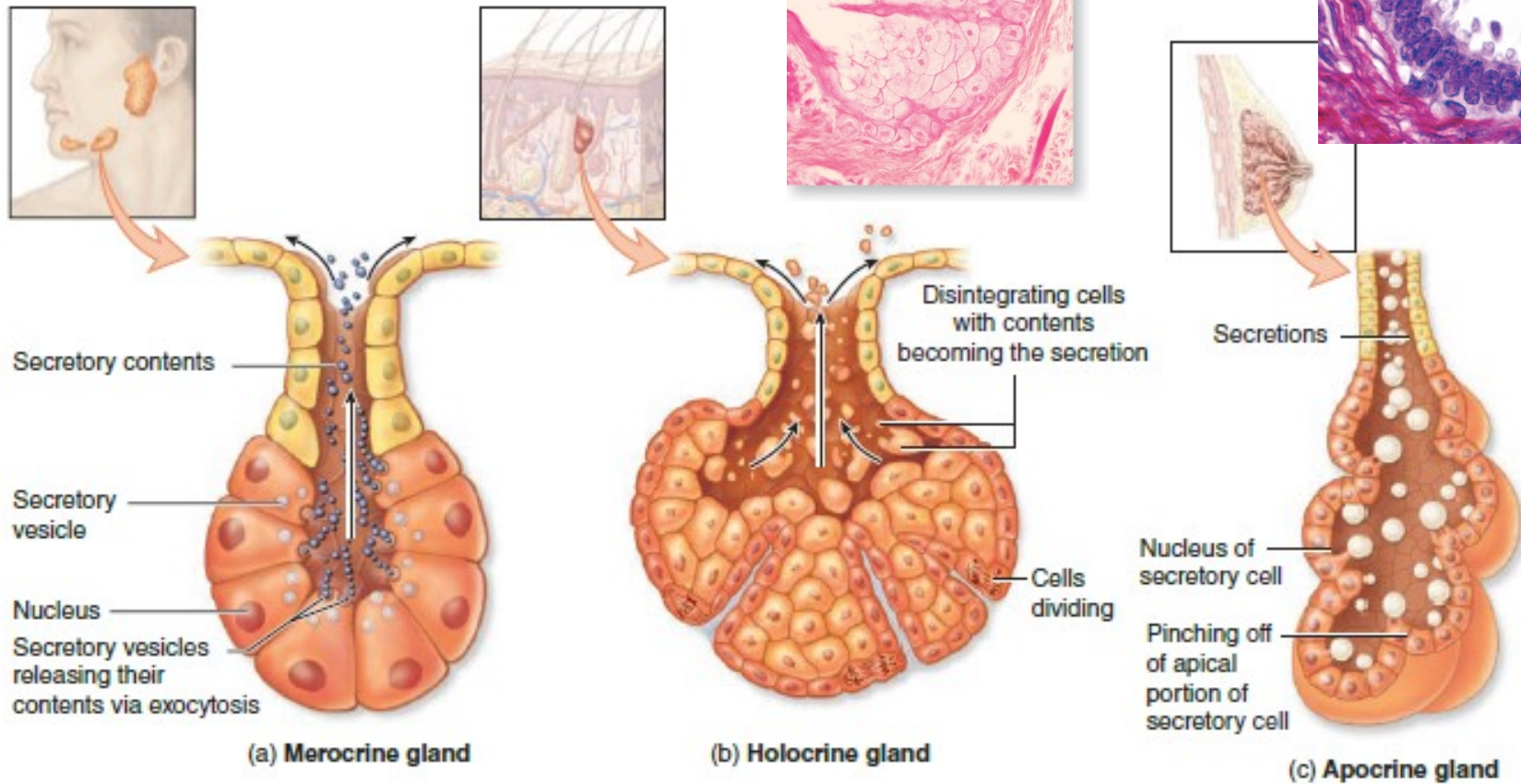


FIGURE 5.38 ▲ Types of glands and their mechanism of secretion. This diagram shows two types of glands (exocrine and endocrine) and two types of signaling mechanisms (paracrine and autocrine) that are used to influence behavior of nearby cells. Note that the three basic types of secretions are shown in cells of the exocrine glands. Merocrine secretion is the most common and involves exocytosis of the vesicle content at the apical cell membrane. The best example of holocrine secretion causing disintegration of secretory cells is seen in sebaceous glands of hair follicles, whereas apocrine secretion is best observed in mammary gland cells that secrete lipid droplets into milk.

FIGURE 4-21 Mechanisms of exocrine gland secretion.



Three basic types of secretion are used by cells of exocrine glands, depending on what substance is being secreted.

(a) Merocrine secretion releases products, usually containing proteins, by means of exocytosis at the apical end of the secretory cells. Most exocrine glands are merocrine.

(b) Holocrine secretion is produced by the disintegration of the secretory cells themselves as they complete their terminal

differentiation, which involves becoming filled with product. Sebaceous glands of hair follicles are the best examples of holocrine glands.

(c) Apocrine secretion involves loss of membrane-enclosed apical cytoplasm, usually containing one or more lipid droplets. Apocrine secretion, along with merocrine secretion, is seen in mammary glands.

EPITHELIAL TISSUE

TYPES OF SECRETORY PRODUCTS (Exocrine glands)

- **Mucus.** Thick, viscous, glycoprotein secretion
 - Secretory cells are usually organized into tubules with wide lumens.
 - Cytoplasm appears vacuolated, containing mucigen that, upon release, becomes hydrated to form mucus.
 - Nucleus is flattened and located in the base of the cell.
- **Serous.** Thin, watery, protein secretion
 - Secretory cells are usually organized into a flask-shaped structure with a narrow lumen, called an acinus.
 - Cytoplasm contains secretory granules.
 - Nucleus is round and centrally located in the cell.

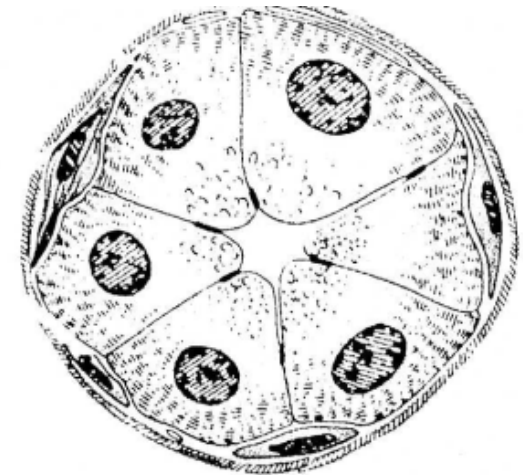
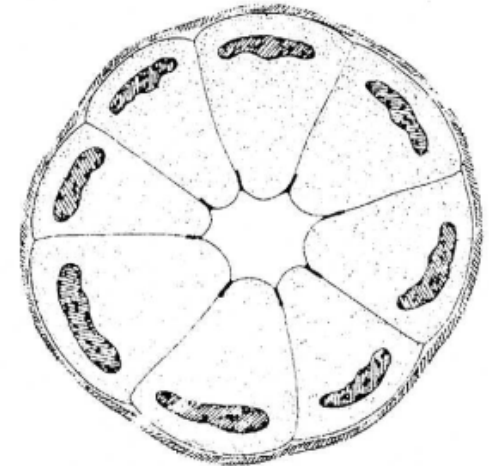
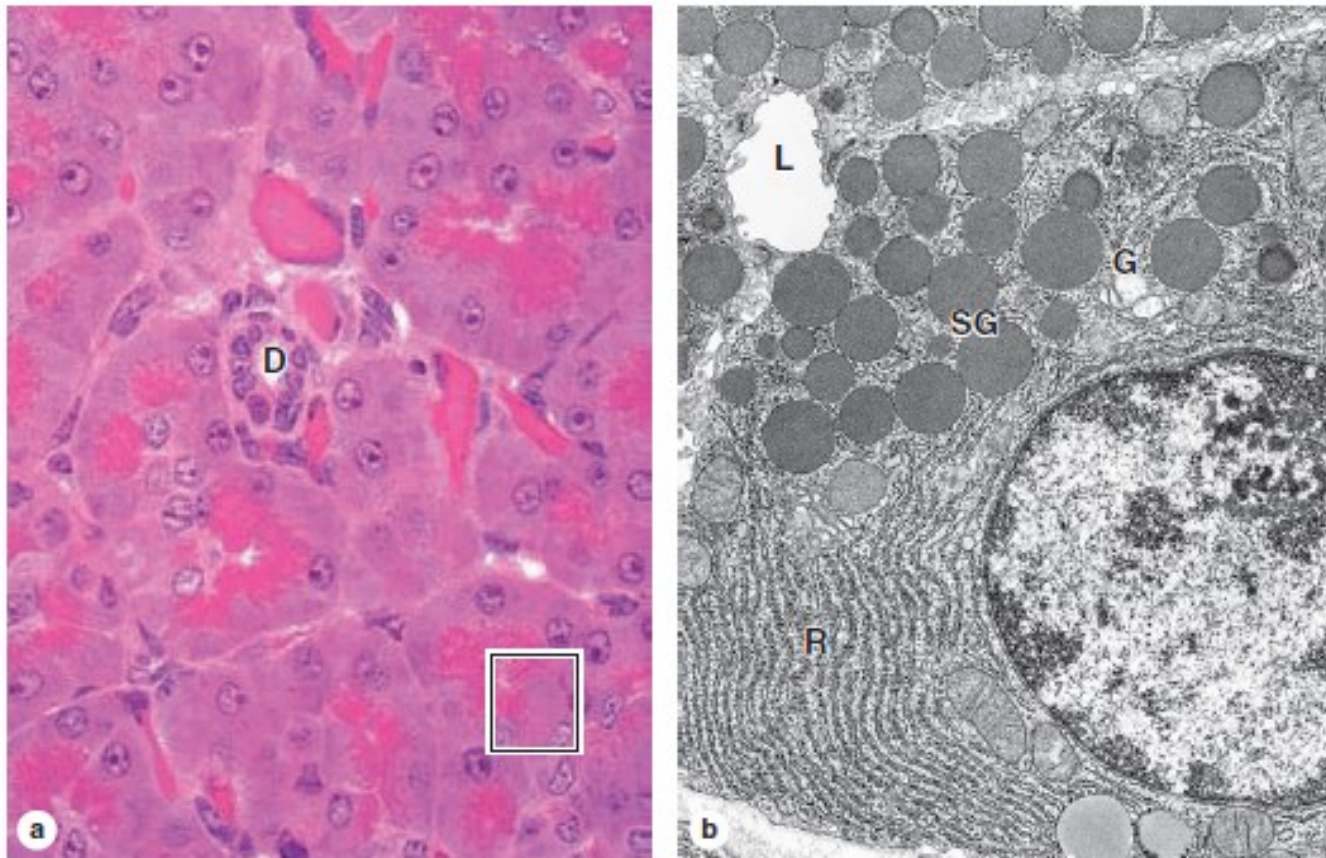


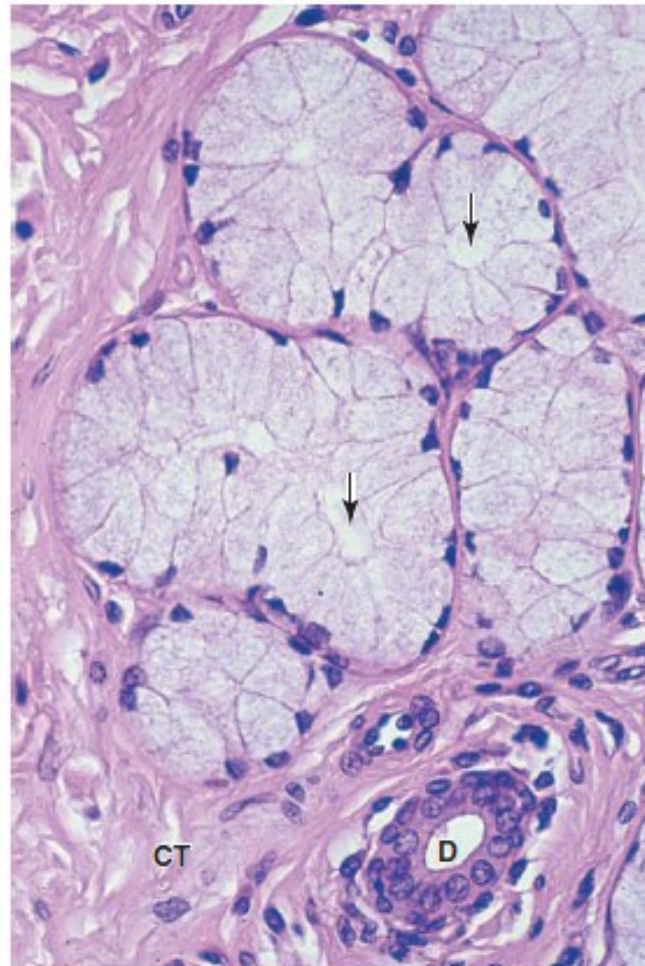
FIGURE 4-24 Serous cells.



The small serous acini of the exocrine pancreas each have 5-10 cells facing a very small central lumen. Each acinar cell is roughly pyramidal, with its apex at the lumen. **(a)** As seen by light microscopy, the apical ends are very eosinophilic due to the abundant secretory granules present there. The cells' basal ends contain the nuclei and an abundance of RER, making this area basophilic. A

small duct (**D**) is seen, but lumens of acini are too small to be readily visible. The enclosed area is comparable to that shown in part **b**. (X300; H&E) **(b)** A portion of one acinar cell is shown ultrastructurally, indicating the abundant RER (**R**), a Golgi complex (**G**), apical secretory granules (**SG**), and the small acinar lumen (**L**). (X13,000)

FIGURE 4-25 Mucous cells.



Mucous cells of salivary glands are typically larger than serous cells, with flattened basal nuclei. Most of the cytoplasm is filled with secretory granules containing mucinogen like that of goblet cells. The RER and Golgi complexes of mucous cells produce heavily glycosylated glycoproteins with water-binding properties. The lumens (arrows) of mucous tubules are larger than those of serous acini. Much connective tissue surrounds the mucous tubules and ducts (**D**). (X200; PT)

EPITHELIAL TISSUE

CLASSIFICATION OF EXOCRINE GLANDS

- **Unicellular glands**
 - Individual cells located within an epithelium, such as goblet cells that secrete mucus

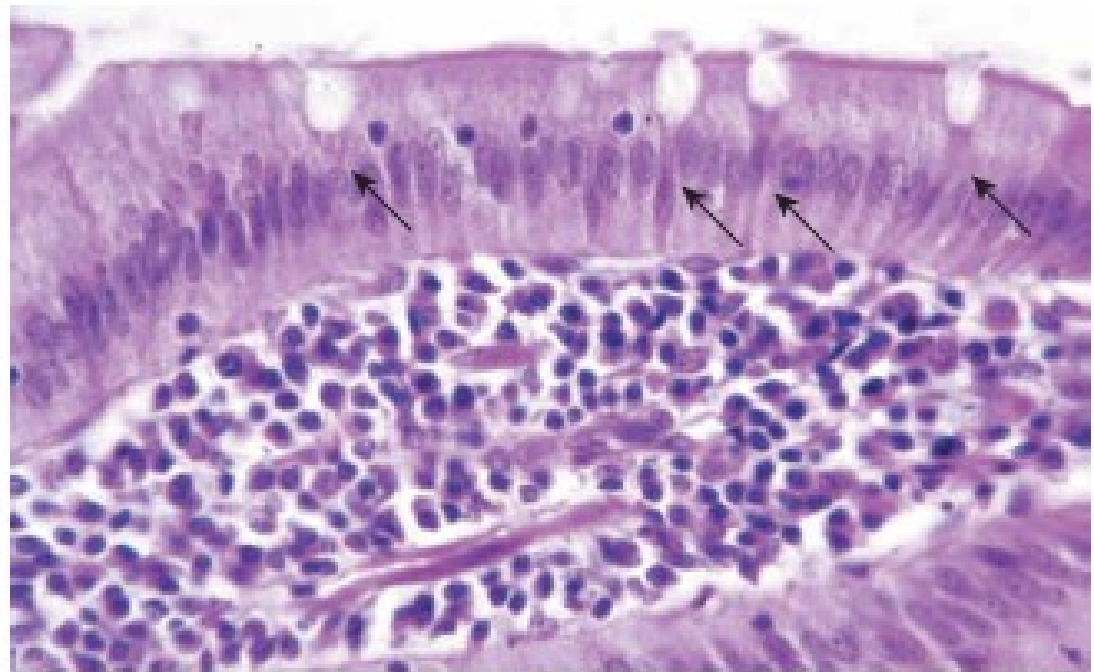
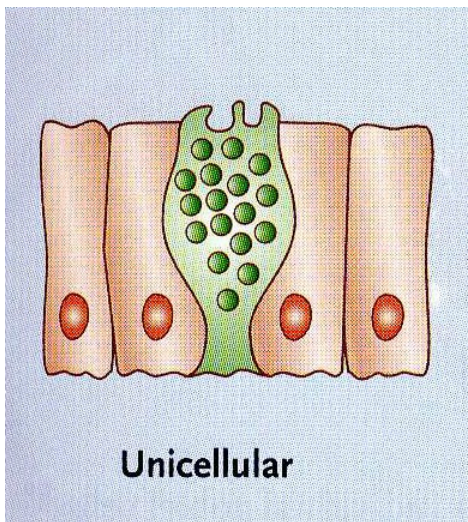
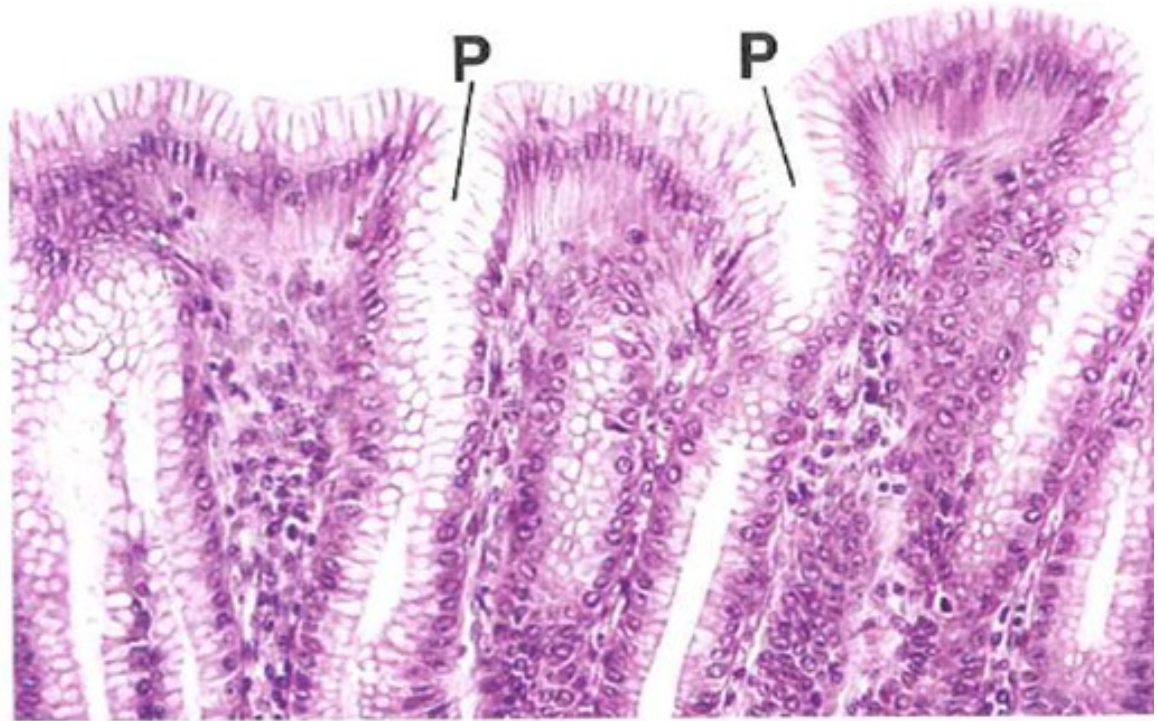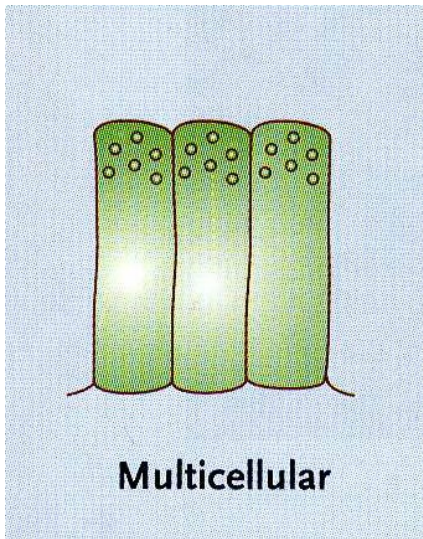


FIGURE 5.39 ▲ Unicellular glands. Photomicrograph of intestinal epithelium showing single goblet cells (arrows) dispersed among absorptive cells. Each goblet cell may be regarded as a unicellular gland—the simplest exocrine type gland. $\times 350$.

EPITHELIAL TISSUE

CLASSIFICATION OF EXOCRINE GLANDS

- **Multicellular glands**
 - Sheet gland. Composed of a surface epithelium in which every cell is a mucus-secreting cell. A sheet gland is unique to the lining of the stomach.



EPITHELIAL TISSUE

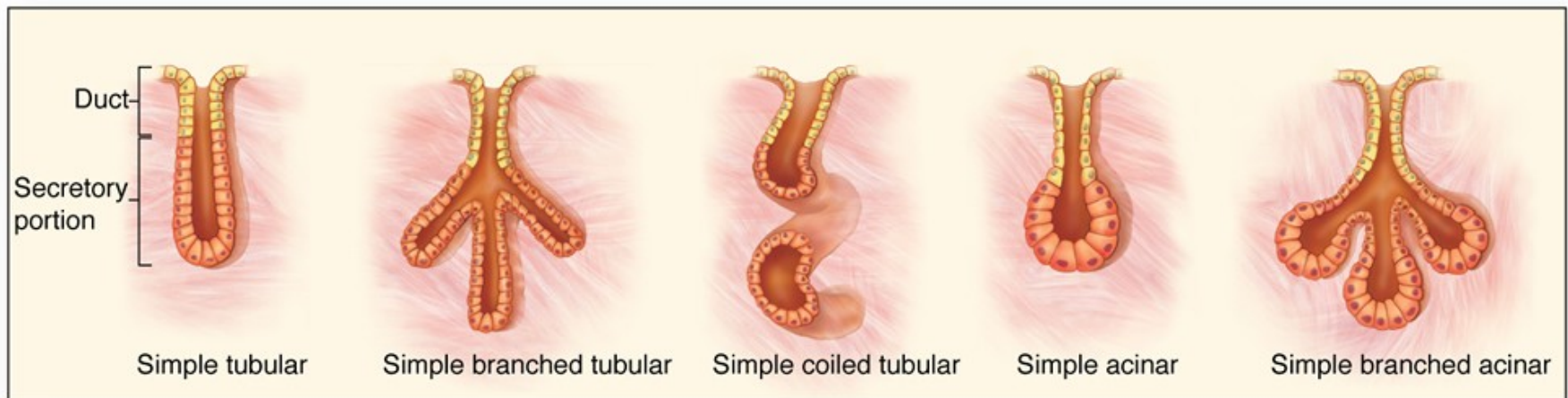
CLASSIFICATION OF EXOCRINE GLANDS

- The remaining multicellular glands are classified according to:
 - **The shape(s) of the secretory units**
 - Presence of tubules only
 - Presence of only acini (singular, acinus) or alveoli (singular, alveolus) (these two terms are synonymous), which are flask-shaped structures
 - Presence of both tubules and acini
 - **The presence and configuration of the duct**
 - Simple. No duct or a single, unbranched duct is present.
 - Compound. Branching duct system

EPITHELIAL TISSUE

CLASSIFICATION OF EXOCRINE GLANDS

- **Classification and types of multicellular glands**
 - Simple tubular. No duct; secretory cells are arranged like a test tube that connects directly to the surface epithelium (e.g., intestinal glands).
 - Simple, branched tubular. No duct; tubular glands whose secretory units branch (e.g., fundic glands of stomach)
 - Simple, coiled tubular. Long unbranched duct; the secretory unit is a long coiled tube (e.g., sweat glands).
 - Simple, branched acinar (alveolar). Secretory units are branched and open into a single duct (e.g., sebaceous glands).



a Simple glands

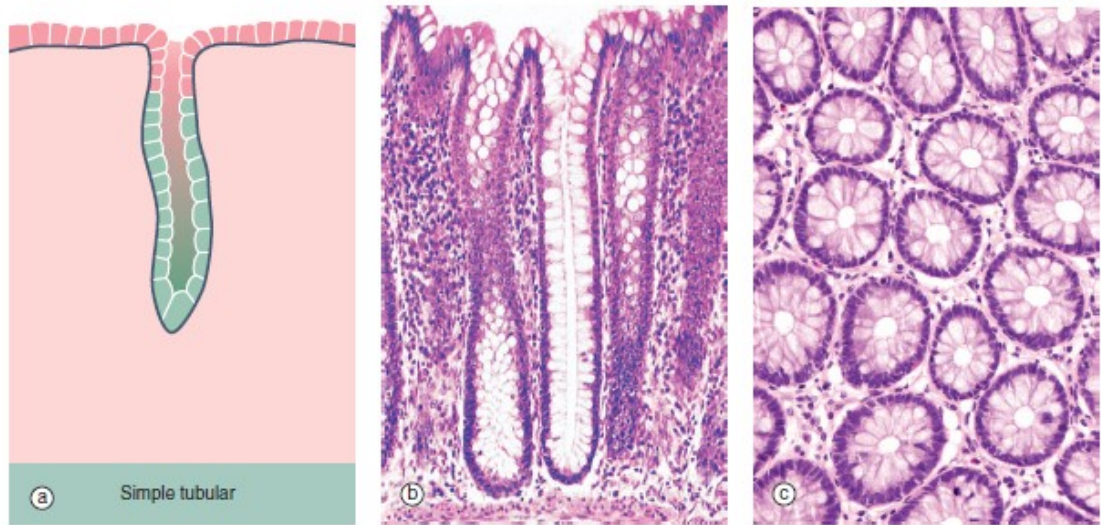


FIG. 5.18 Simple tubular glands
 (a) Diagram (b) H&E (LP) (c) H&E (MP)

This example of simple tubular glands is taken from the large intestine. This type of gland has a single, straight tubular lumen into which the secretory products are discharged. In this example, secretory cells line the entire duct; the secretory cells are goblet cells. The glands are shown in longitudinal section in

micrograph (b) and in transverse section in (c), which emphasizes the regular arrangement of the glands and the large number of mucus-secreting goblet cells in the epithelium. At other sites, mucus is secreted by columnar cells that do not have the classic goblet shape but nonetheless function in a similar manner.

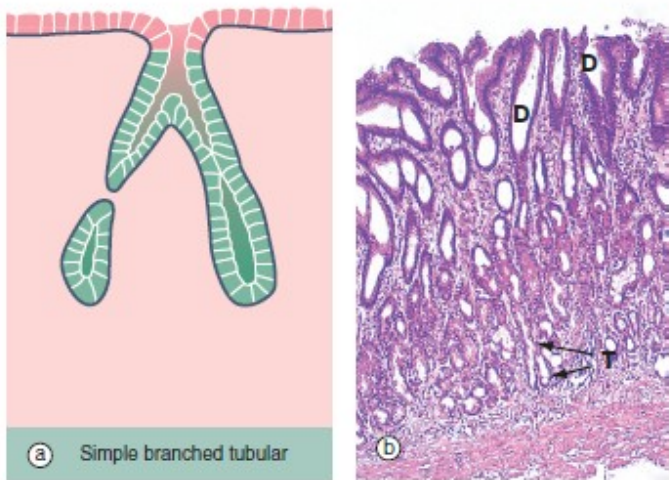


FIG. 5.20 Simple branched tubular glands
 (a) Diagram (b) H&E (LP)

Simple branched tubular glands are found mainly in the stomach. The mucus-secreting glands of the pyloric part of the stomach are shown in this example. Each gland consists of several tubular secretory portions T, which converge onto a single unbranched duct D of wider diameter. Mucus-secreting cells also line the duct but, unlike those of the large intestine (see Fig. 5.18), these mucus cells do not have a goblet shape.

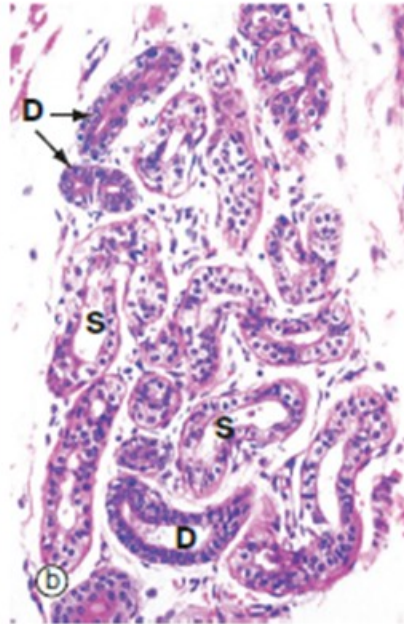



FIG. 5.19 Simple coiled tubular glands
(a) Diagram (b) H&E (LP)

Sweat glands are almost the only example of simple coiled tubular glands. Each consists of a single tube that is tightly coiled in three dimensions; portions of the gland are thus seen in various planes of section. Sweat glands have a terminal secretory portion **S** lined by simple cuboidal epithelium, which gives way to a non-secretory (*excretory*) duct **D** lined by stratified cuboidal epithelium.

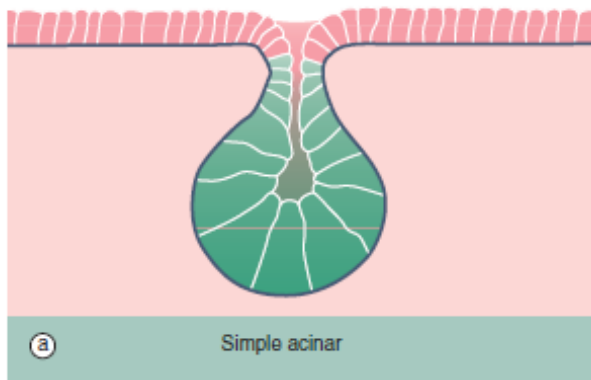


FIG. 5.21 Simple acinar glands
(a) Diagram (b) H&E (LP)

Simple acinar glands occur in the form of pockets in epithelial surfaces and are lined by secretory cells. In this example of the mucus-secreting glands of the penile urethra, the secretory cells are pale stained compared to the non-secretory cells lining the urethra U. Note that the term *acinus* can be used to describe any rounded exocrine secretory unit.

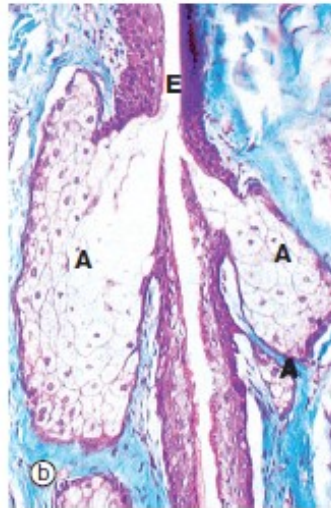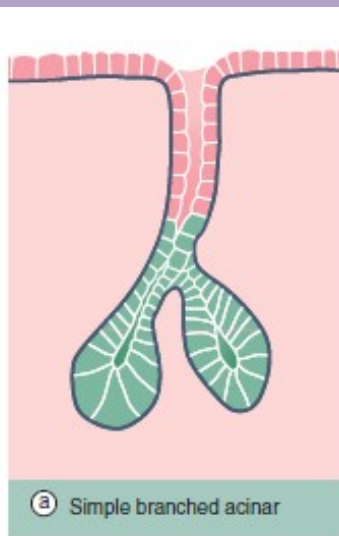
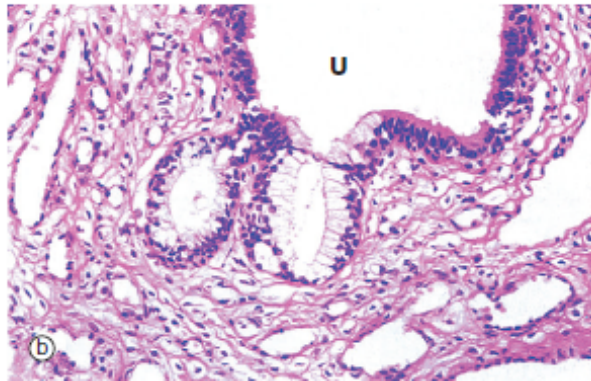


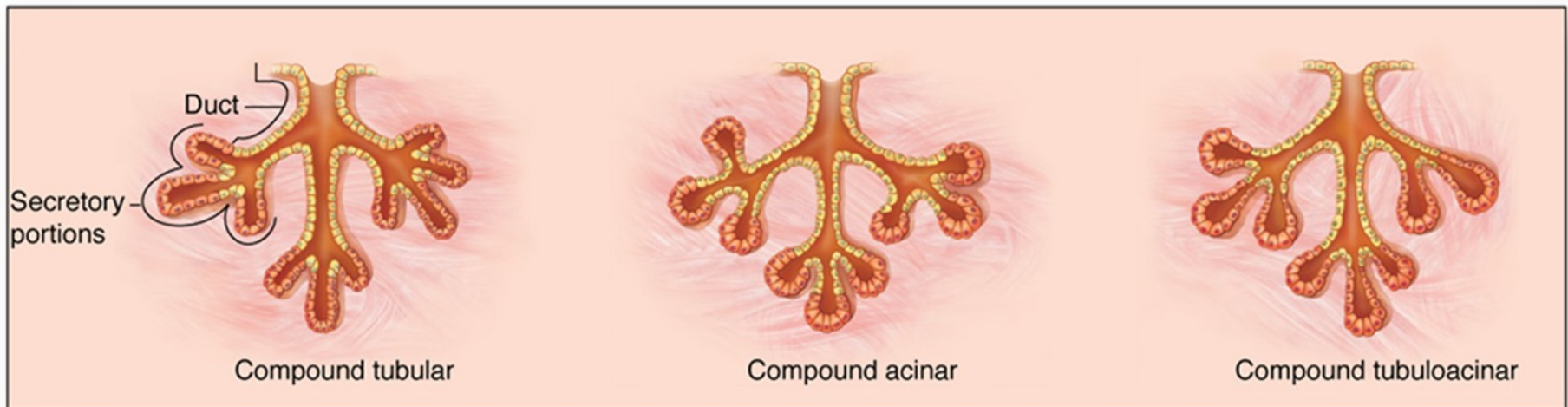
FIG. 5.22 Simple branched acinar gland
(a) Diagram (b) Masson trichrome (LP)

Sebaceous glands provide a good example of simple branched acinar glands. Each gland consists of several secretory acini A that empty into a single excretory duct; the excretory duct E is formed by the stratified epithelium surrounding the hair shaft. The mode of secretion of sebaceous glands is holocrine, i.e. the secretory product, sebum, accumulates within the secretory cells and is discharged by degeneration of the cells.

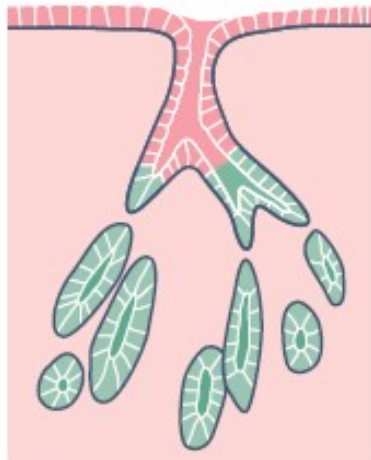
EPITHELIAL TISSUE

CLASSIFICATION OF EXOCRINE GLANDS

- **Classification and types of multicellular glands**
 - Compound tubular. Branching ducts with tubular secretory units (e.g., Brunner's gland of the duodenum)
 - Compound acinar (alveolar). Branching ducts with acinar secretory units (e.g., parotid salivary gland)
 - Compound tubuloacinar (alveolar). Branching ducts with both tubular and acinar secretory units (e.g., submaxillary salivary gland)



b Compound glands



(a) Compound branched tubular

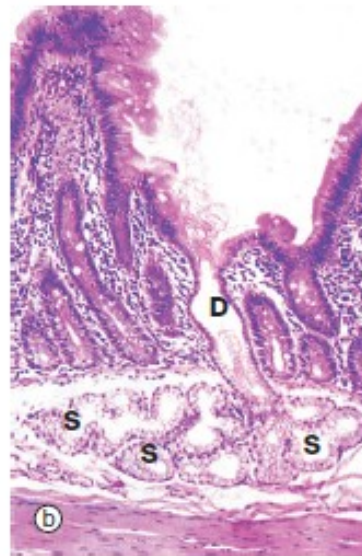
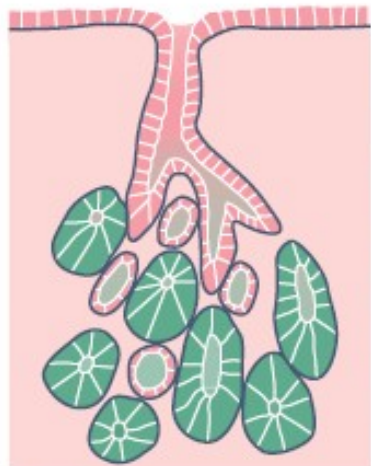


FIG. 5.23 Compound branched tubular gland
(a) Diagram (b) H&E (LP)

Brunner's glands of the duodenum, as shown in this example, are described as compound branched tubular glands. Although difficult to visualise here, the duct system **D** is branched, thus defining the glands as compound glands, and the secretory portions **S** have a tubular form which is branched and coiled.



(a) Compound acinar

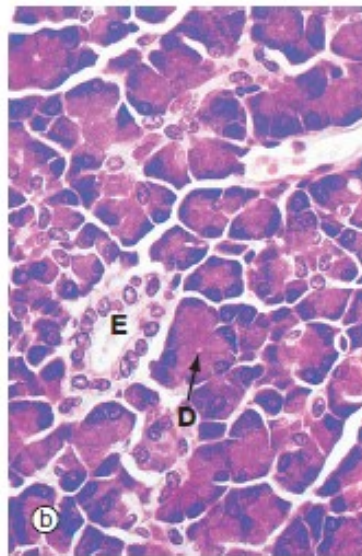
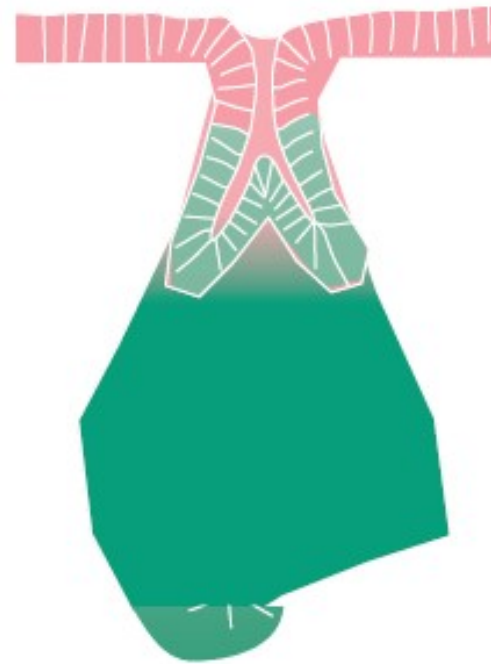
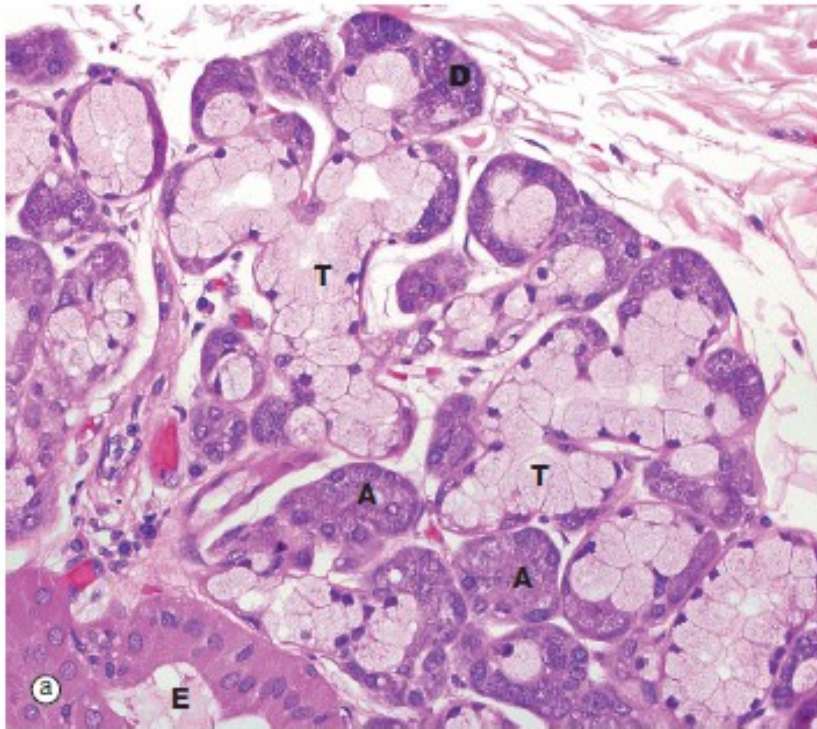


FIG. 5.24 Compound acinar gland
(a) Diagram (b) Chrome alum haematoxylin/
phloxine (MP)

Compound acinar glands are those in which the secretory units are acinar in form and drain into a branched duct system. The pancreas shown in this micrograph consists of numerous acini, each of which drains into a minute duct. These minute ducts **D**, which are just discernible in the centre of some acini, drain into a system of branched excretory ducts **E** of increasing diameter which are lined by simple cuboidal epithelium.



**FIG. 5.25 Compound tubulo-acinar gland
H&E (MP)**

Compound tubulo-acinar glands have three types of secretory units: branched tubular, branched acinar and branched tubular with acinar end-pieces called *demilunes*. The submandibular salivary gland shown here is the classic example. It contains two types of secretory cells, mucus-secreting cells and serous cells; the former are pale but the latter, which have a

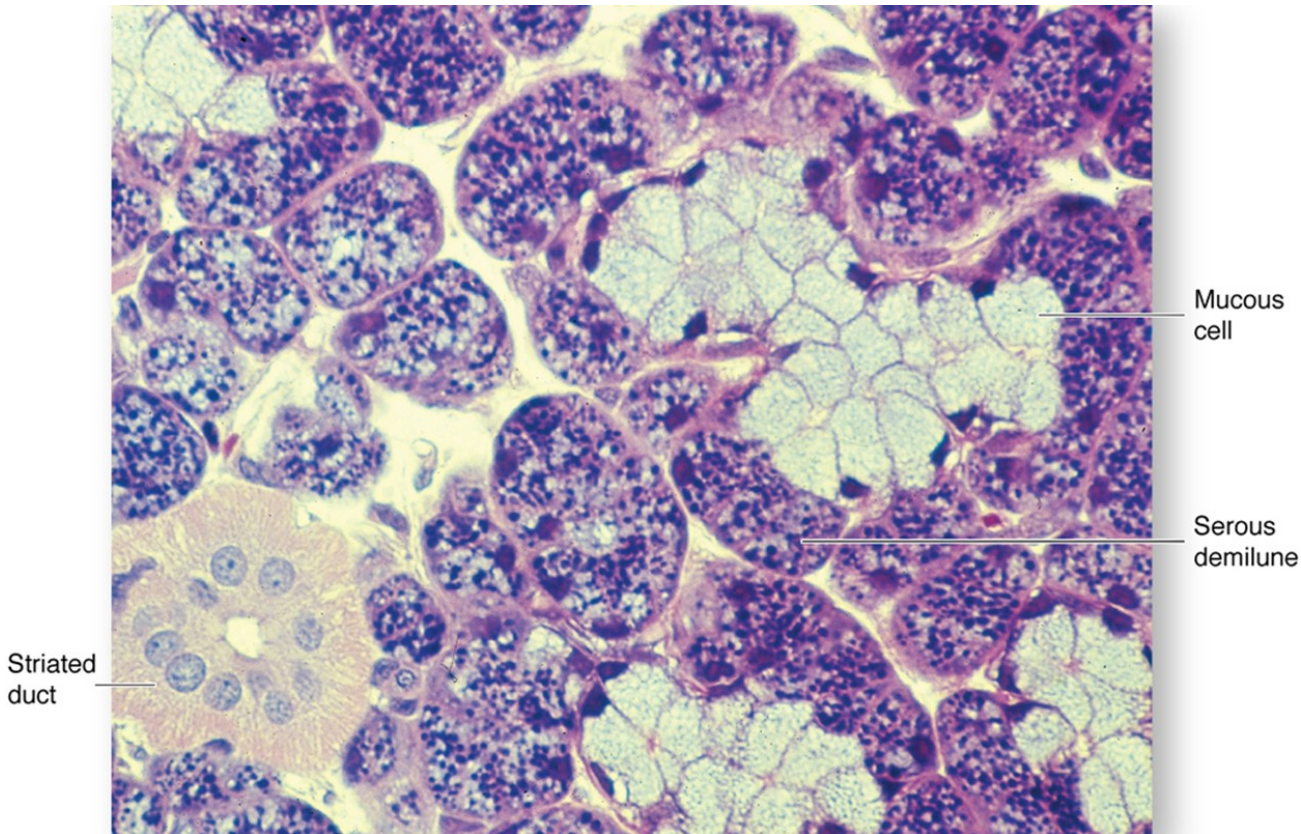
protein-rich secretion (digestive enzymes), stain strongly due to their prominent content of rough endoplasmic reticulum. Generally, the mucous cells form tubular components **T**, whereas the serous cells form acinar components **A** and demilunes **D**. Part of an excretory duct **E** is also seen in the lower left corner of the micrograph.

EPITHELIAL TISSUE

SPECIAL FEATURES OF SOME EXOCRINE GLANDS

Serous demilunes

- Consist of a "cap" of serous cells around the end of a mucous tubule; appear half-moon shaped in section



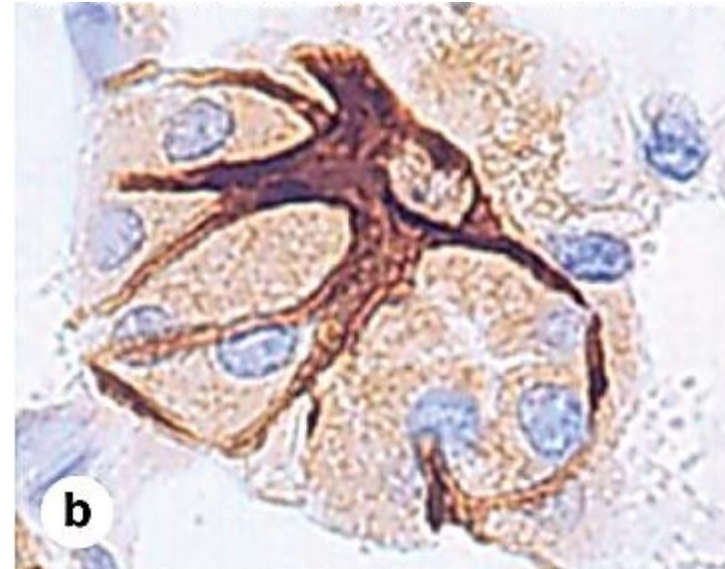
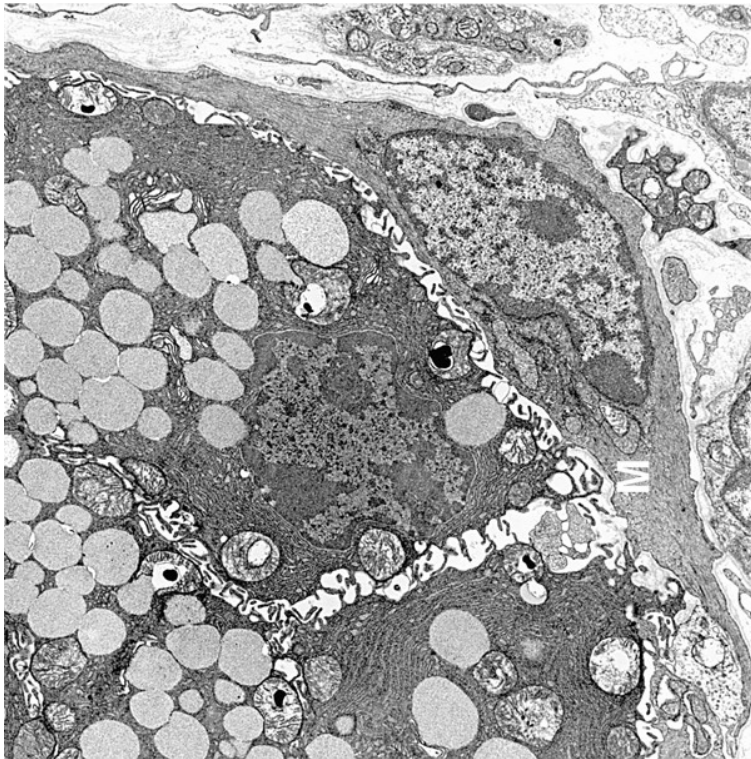
Seromucous, compound tubuloacinar gland. The submandibular salivary glands have both mucous and serous secretory units, typically shaped as acini and tubules respectively. 68

EPITHELIAL TISSUE

SPECIAL FEATURES OF SOME EXOCRINE GLANDS

Myoepithelial cells

- Resemble smooth muscle cells in their fine structure but are of epithelial origin; prominent in sweat and mammary glands, they surround secretory units, lying inside the basement membrane, and aid in the expulsion of secretory products from the gland.

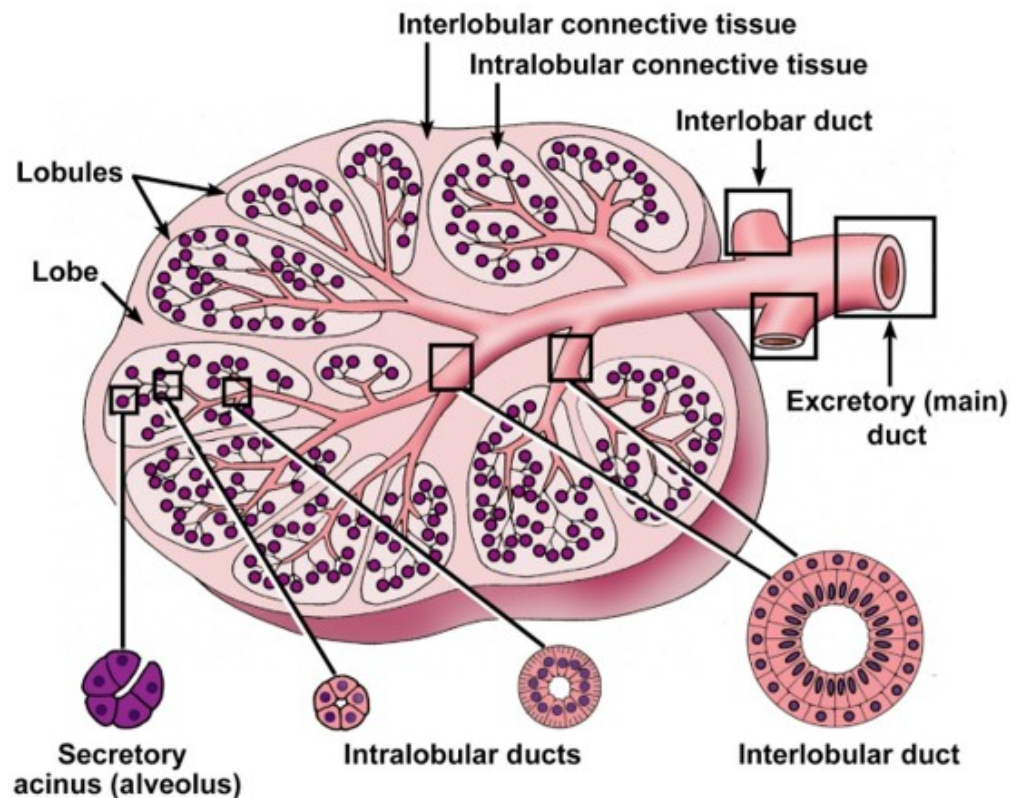


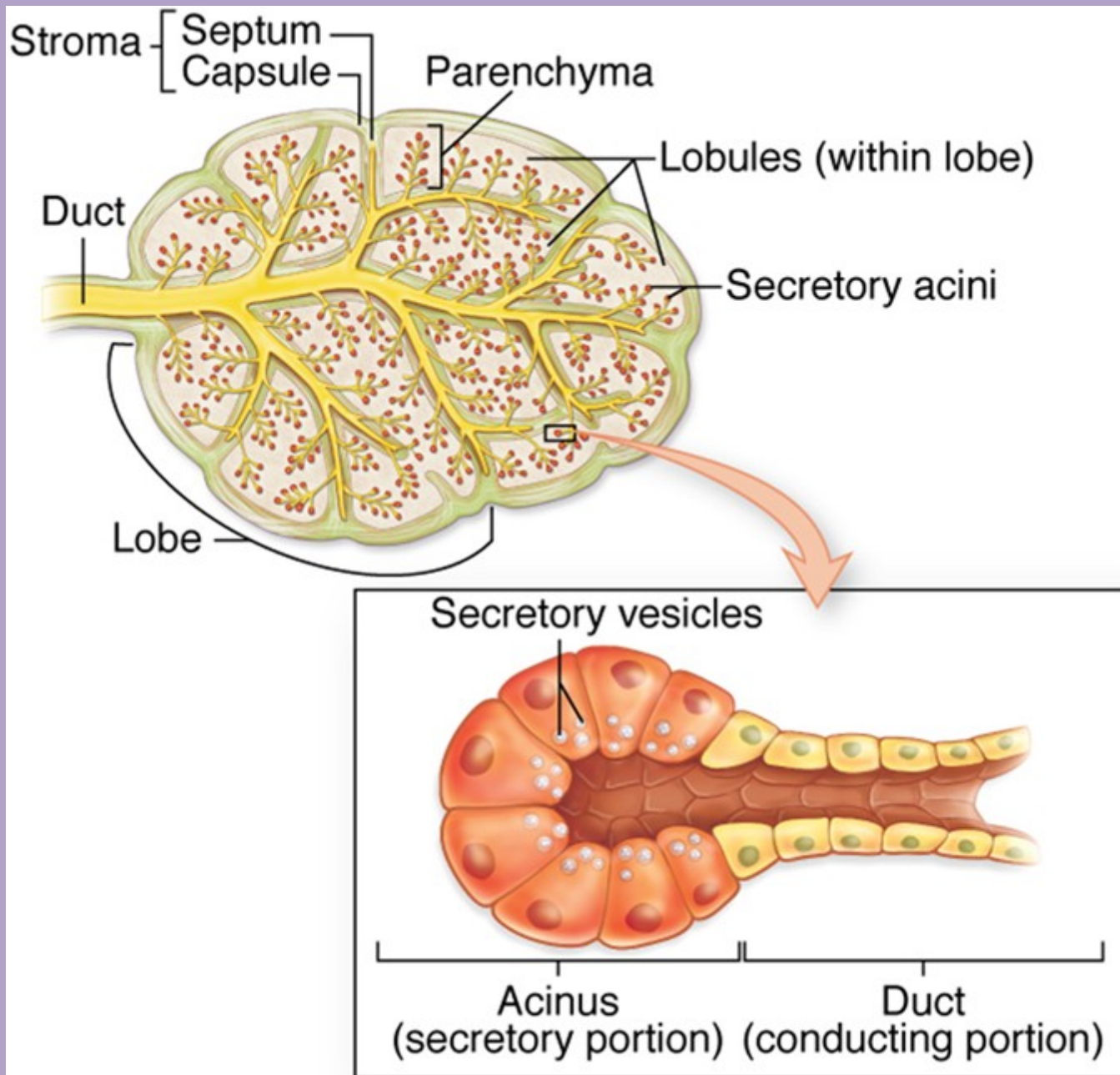
(a) The TEM shows two salivary gland cells containing secretory granules, with an associated myoepithelial cell (M). (X20,000)
(b) A myoepithelial cell immunostained brown with antibodies against actin shows its association with cells of an acinus stained by H&E. Contraction of the myoepithelial cell compresses the acinus and aids in the expulsion of secretory products into the duct. (X200)

EPITHELIAL TISSUE

DUCT SYSTEM OF COMPOUND, EXOCRINE GLANDS

- **Intralobular ducts.** Contained within a lobule; simple cuboidal to columnar epithelium
- **Interlobular ducts.** Receive numerous intralobular ducts; located in the connective tissue between lobules; stratified columnar epithelium
- **Excretory (main) duct.** Macroscopic duct draining the entire gland





EPITHELIAL TISSUE

ENDOCRINE GLANDS

- No ducts; generally, cells are not polarized
- Occurrence:
 - Unicellular (e.g., enteroendocrine cells of the digestive tract); these cells do show polarity because they are located within an epithelium and secrete away from the free surface of the epithelium.
 - Small clusters of cells (e.g., islet of Langerhans in pancreas)
 - Organs (e.g., thyroid gland, adrenal gland)
- Secretory cells of multicellular glands are usually arranged as plates or cords. The thyroid gland, where the cells form fluid-filled spheres, is an exception to this pattern.
- Highly vascular with fenestrated capillaries
- Secretory products are called hormones. Hormones can be:
 - Derived from amino acids (e.g, thyroxine and epinephrine)
 - Peptides and proteins (e.g., insulin and oxytocin)
 - Steroids (e.g., testosterone and cortisol); steroid-secreting cells display mitochondria with tubular cristae and contain large amounts of lipid droplets and smooth endoplasmic reticulum.
- Secrete by the merocrine or diffusion methods only

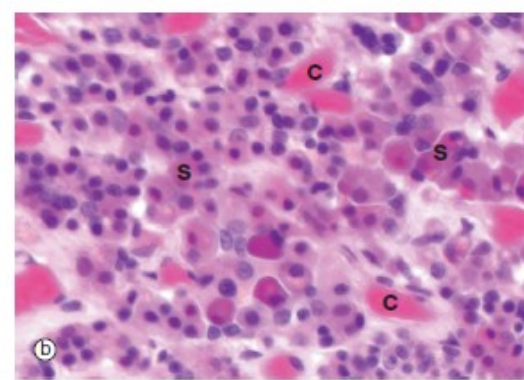
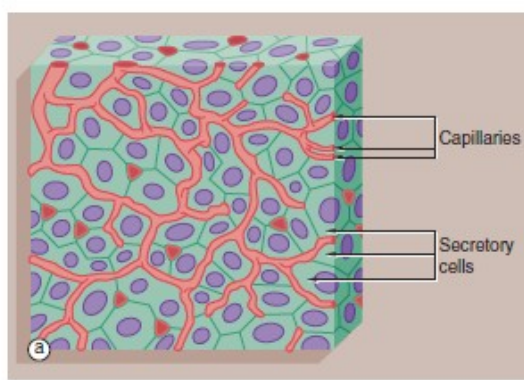


FIG. 5.26 Endocrine gland
(a) Diagram (b) H&E (MP)

Most endocrine glands consist of clusters or cords of secretory cells surrounded by a rich network of small blood vessels. Each cluster of endocrine cells is surrounded by a basement membrane, reflecting its epithelial origin. Endocrine cells release hormones into the intercellular spaces, from which they diffuse rapidly into surrounding blood vessels and from there throughout the body.

Micrograph (b) of the anterior pituitary gland shows the typical features of endocrine glands. The secretory cells S are

arranged in cords and clusters and are surrounded by delicate supporting tissue containing a rich network of broad capillaries C. The basement membrane surrounding each group of endocrine cells is not visible at this magnification. Like many other endocrine glands, the secretory cells of the pituitary are of several different types; in this case, the majority are acidophilic (red stained), while some stain blue (basophilic) and some stain very little (chromophobes).

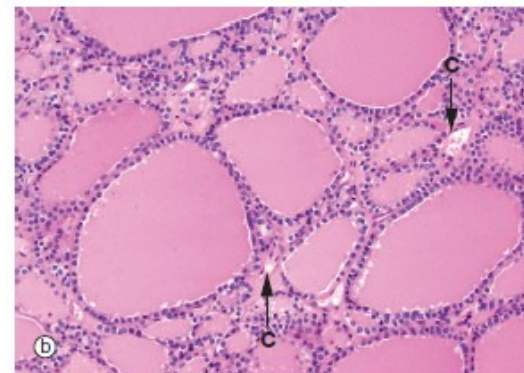
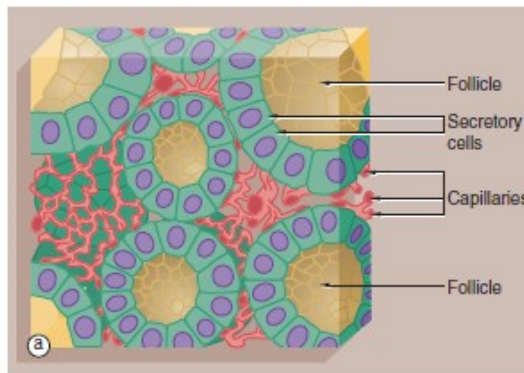


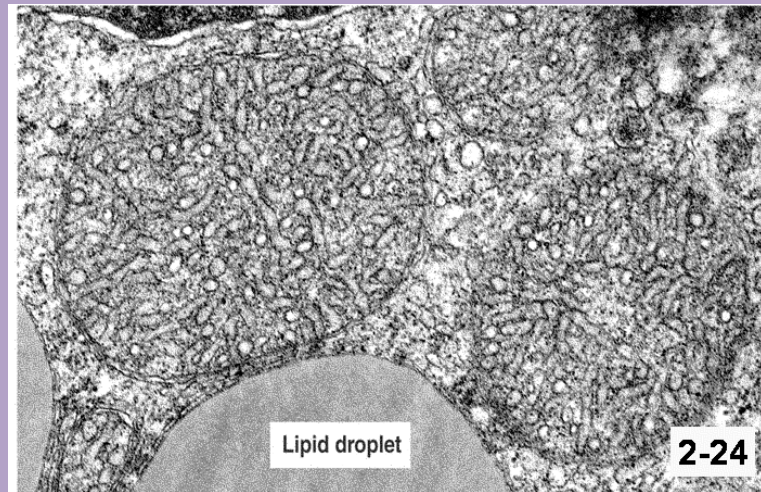
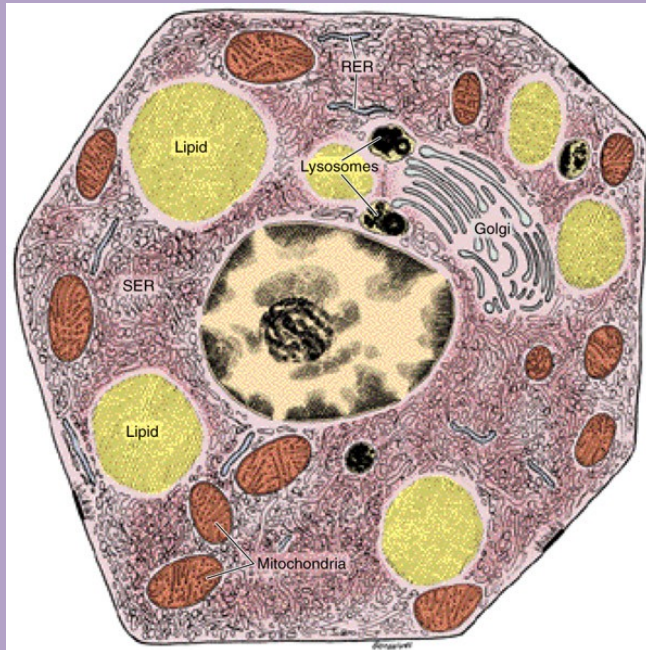
FIG. 5.27 Follicular endocrine gland
(a) Diagram (b) H&E (LP)

The thyroid gland is an unusual endocrine gland in that it stores hormone (*thyroxine*) within roughly spherical cavities enclosed by the secretory cells; these units are called *follicles*. Secretion of stored hormone involves reabsorption of hormone from the follicular lumen, release into the surrounding interstitial spaces, and then diffusion into the rich capillary network that embraces each follicle.

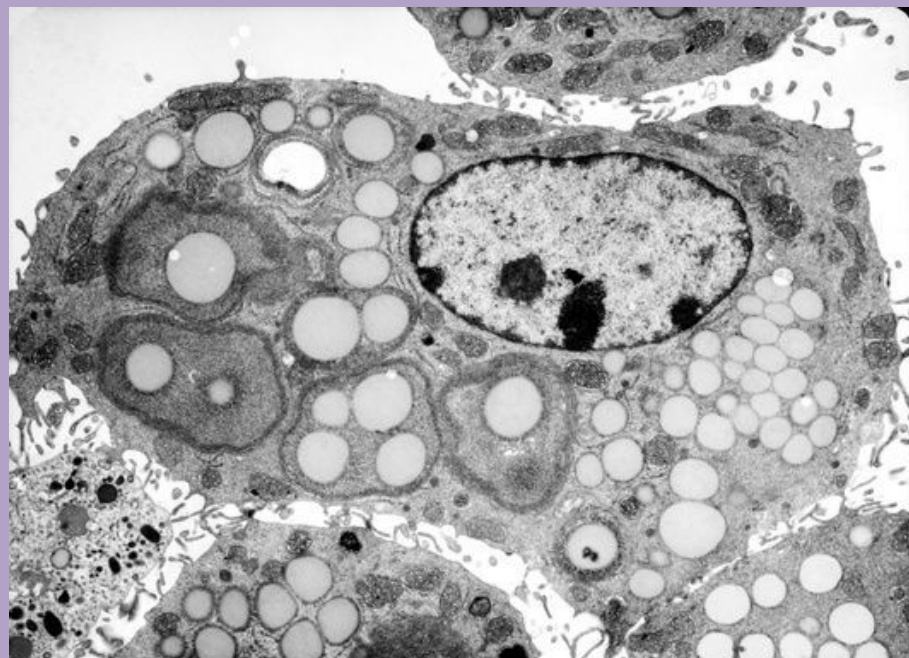
Micrograph (b) shows typical thyroid follicles F. The secretory cells lining the follicles are of flattened cuboidal

shape, although they may vary from low cuboidal to tall columnar depending on the state of activity of the gland. Stored thyroxine is bound to a glycoprotein (*thyroglobulin*), which is strongly eosinophilic and fills the centre of the follicle. The relatively sparse interfollicular supporting tissue is mainly occupied by capillaries C (see also Fig. 17.6).

Steroid-secreting cells display mitochondria with tubular cristae and contain large amounts of lipid droplets and smooth endoplasmic reticulum



Mitochondria with **tubular cristae** are typical of steroid-producing cells –adrenal cortex (shown above), corpus luteum (ovary), Leydig cells (testis).

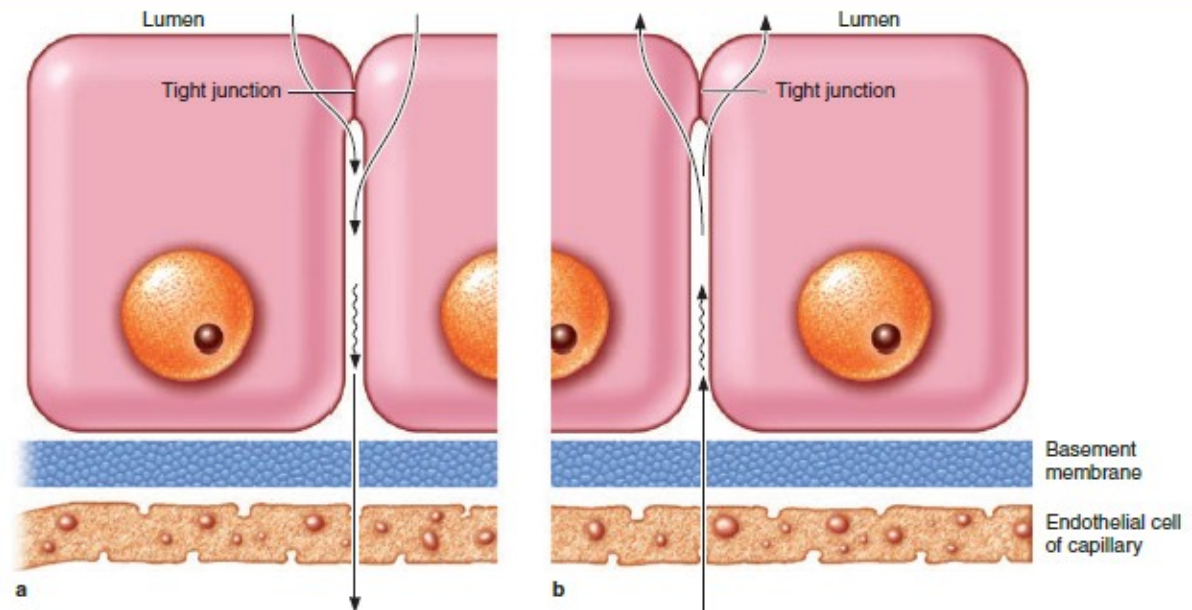


EPITHELIAL TISSUE

EXAMPLES OF GLANDULAR EPITHELIAL CELLS

- Ion transporting cells
- Serous secretory cells
- Mucous secretory cells
- Neuroendocrine cells
- Myoepithelial cells

FIGURE 4–27 Ion and water absorption and secretion.



Ion and water transport across epithelia can occur in either direction, depending on the organ involved. **(a) Absorption** is the process of transport from an organ or duct's lumen to capillaries near the epithelial basement membrane and involves movement from the apical to the basolateral cell membrane domains. Absorption occurs for example in the epithelium of the gallbladder and intestine where it serves to concentrate bile or obtain water and ions from digested material.

(b) Secretion involves transport in the other direction from the capillaries into a lumen, as in many glands and the choroid plexus. Secretion by epithelial cells removes water from the neighboring interstitial fluid or plasma and releases it as part of the specialized aqueous fluids in such organs.

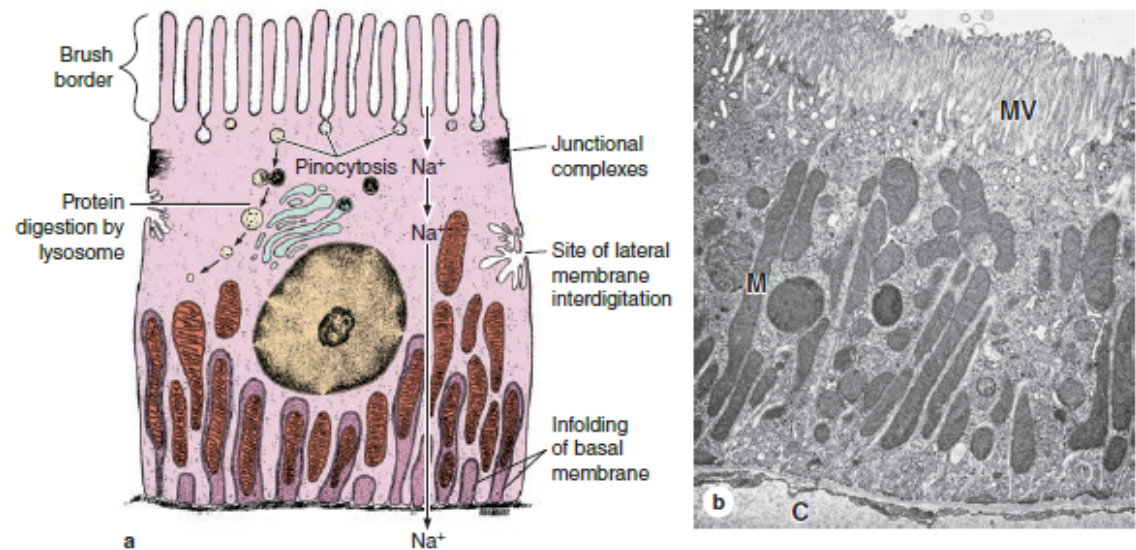
No matter whether an epithelium is involved in absorption or secretion, apical occluding junctions are necessary to maintain tight separation of the apical and basolateral compartments of either side of the epithelium.

EPITHELIAL TISSUE

Ion-transporting cells

- Deep invaginations of basal cell membranes
- Zonula occludens
- Mitochondria in basal cytoplasm provide energy for ion transport
- Examples: proximal tubules in kidney

FIGURE 4-28 Features of absorptive cells.



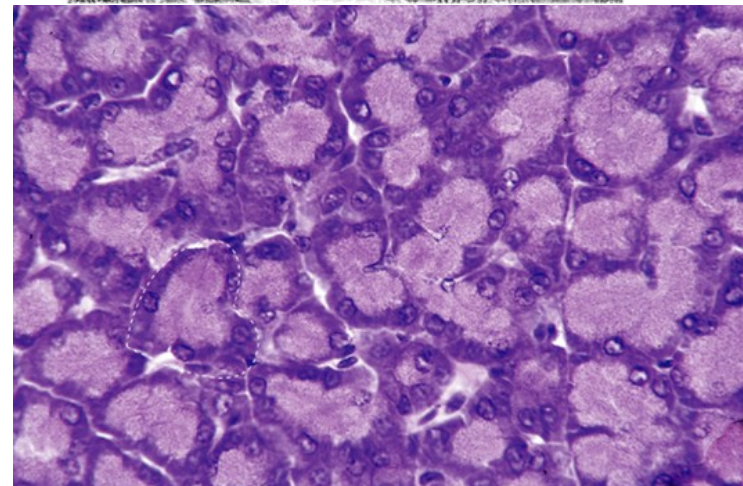
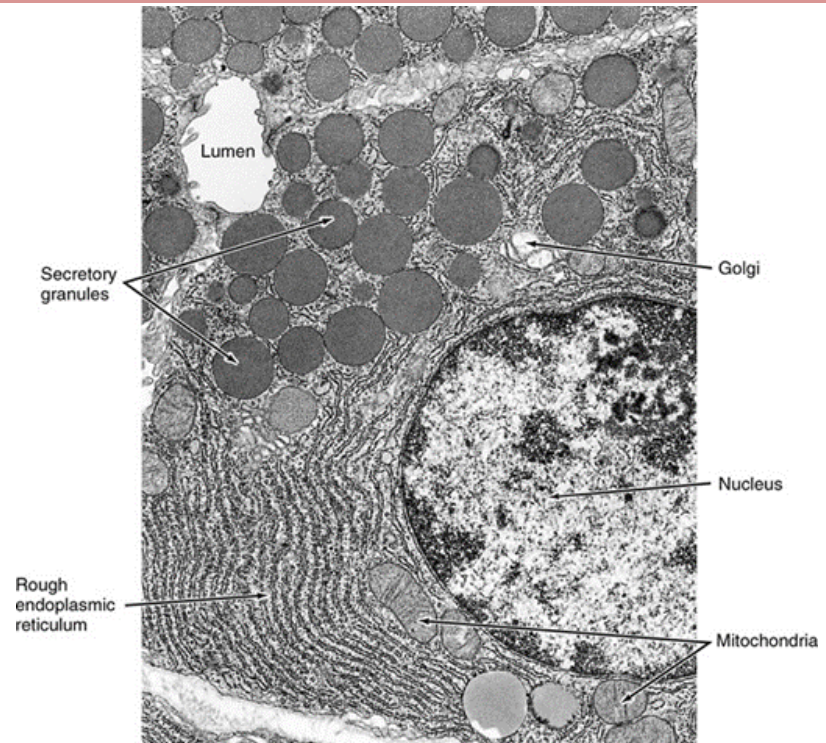
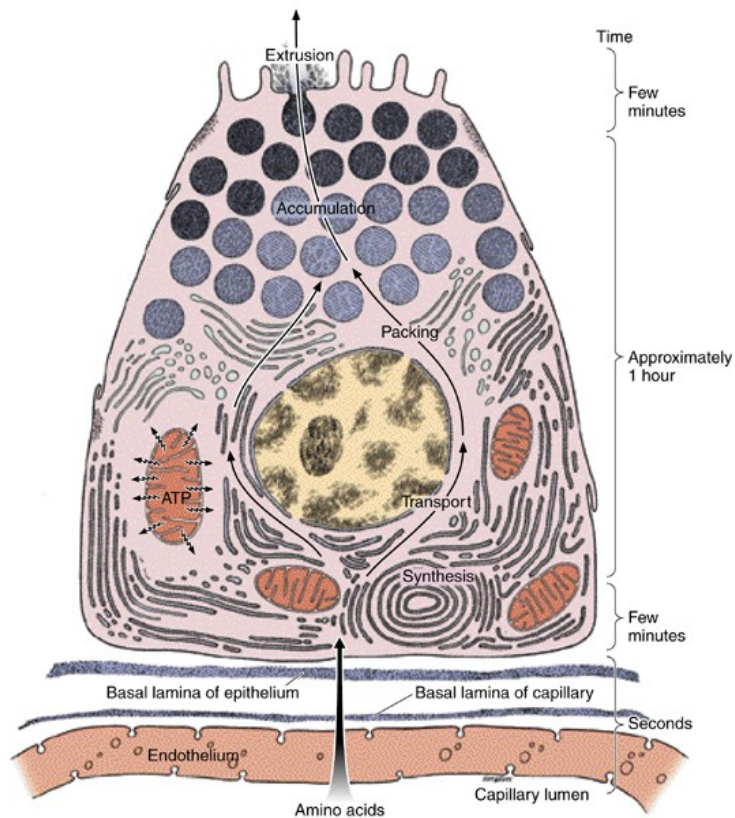
A diagram and TEM photo showing the major ultrastructural features of a typical epithelial cell highly specialized for absorption, cells of proximal convoluted tubule of the kidney. The apical cell surface has a brush border consisting of uniform microvilli (MV) that increase the area of that surface to facilitate all types of membrane transport. Vesicles formed during pinocytosis may fuse with lysosomes as shown in (a) or mediate transcytosis by secreting their contents at the basolateral cell membrane. The basal cell surface is also enlarged, here by invaginations of the cell membrane which are associated with mitochondria (M) providing ATP for active transport. Basolateral membrane infoldings from

neighboring cells (the more heavily stippled structures) also with mitochondria interdigitate with those of this cell. Various ions entering through the apical membranes of renal epithelial cells undergo active transport out of the cells across the basolateral membrane. Immediately below the basal lamina shown in (b) is a capillary (C) that removes water and other substances absorbed across the epithelium. Junctional complexes between individual cells separate the apical and basolateral compartments on either side of the epithelium. Epithelial cells also show lateral membrane interdigitations with neighboring cells. (X9600)

EPITHELIAL TISSUE

Serous secretory cells

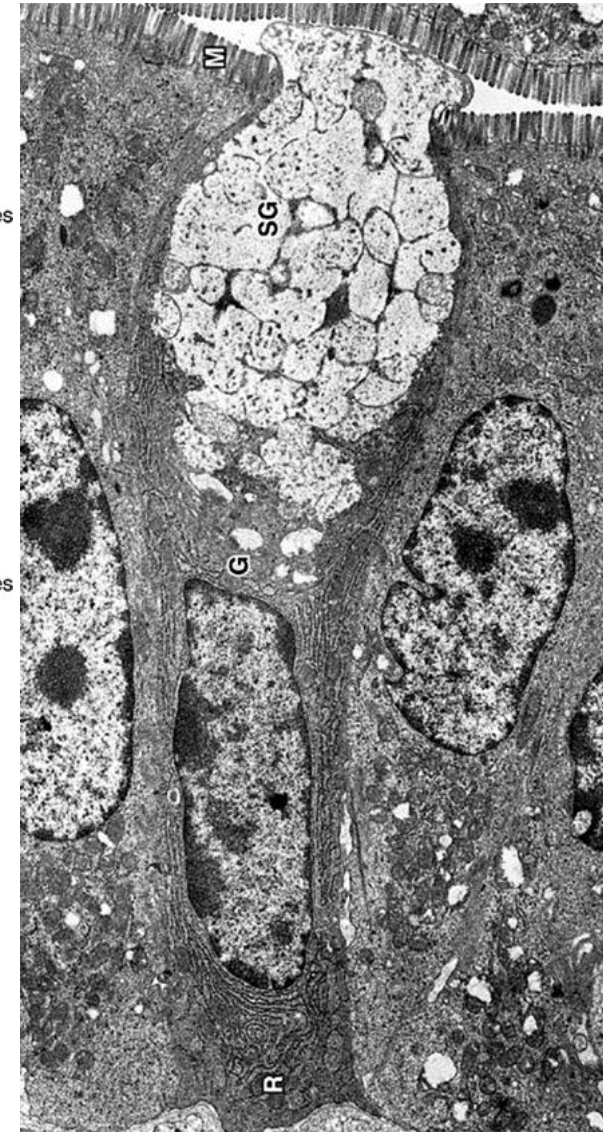
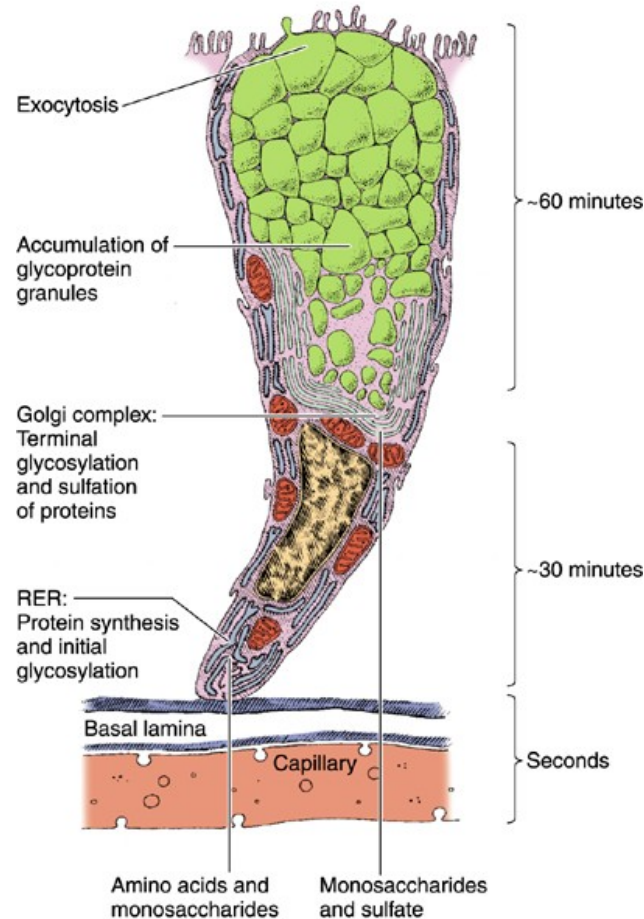
- Large rounded nucleus and abundant rough ER, Golgi and secretory granules
- Examples: pancreatic acinar cells, serous cells in salivary glands

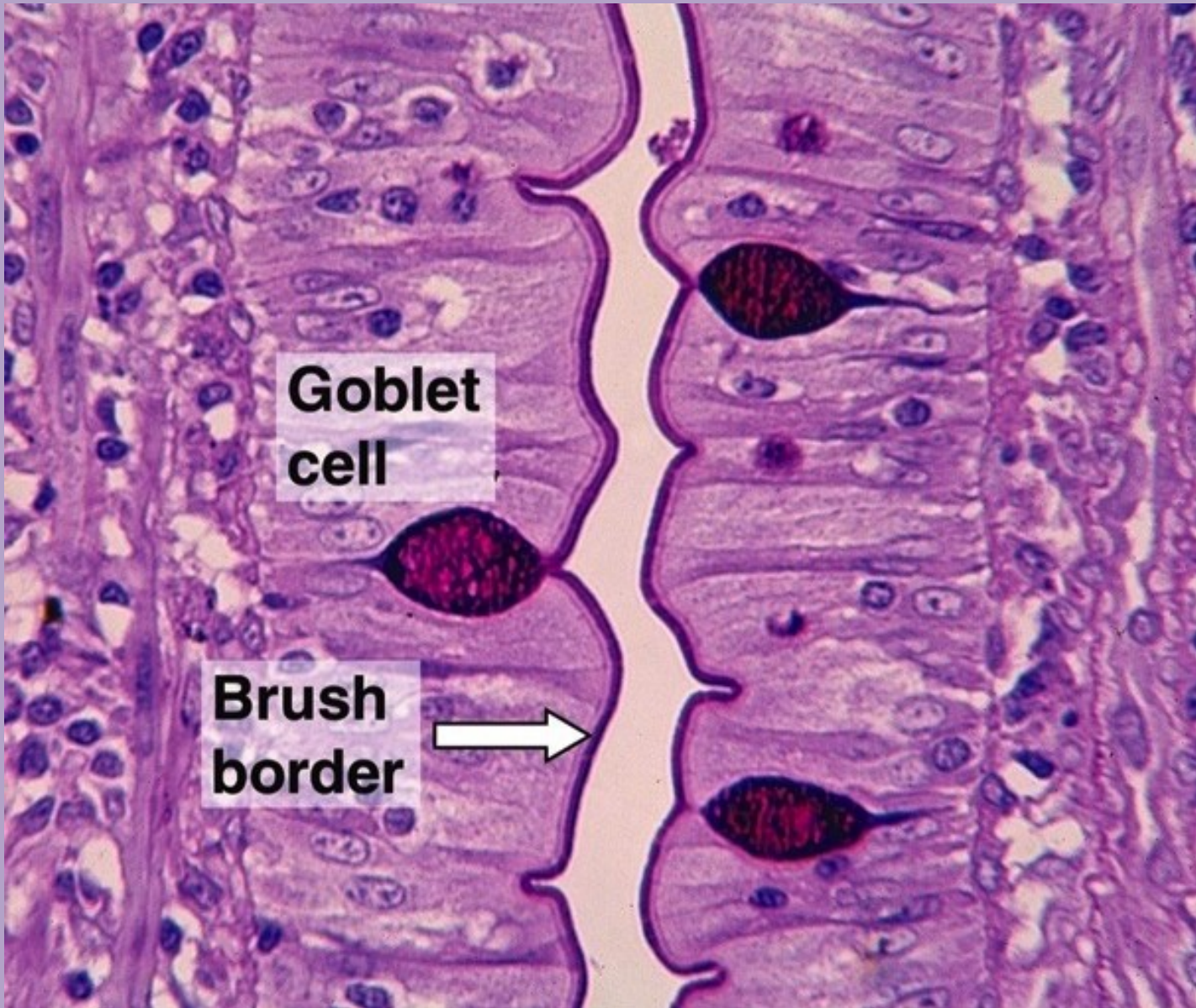


EPITHELIAL TISSUE

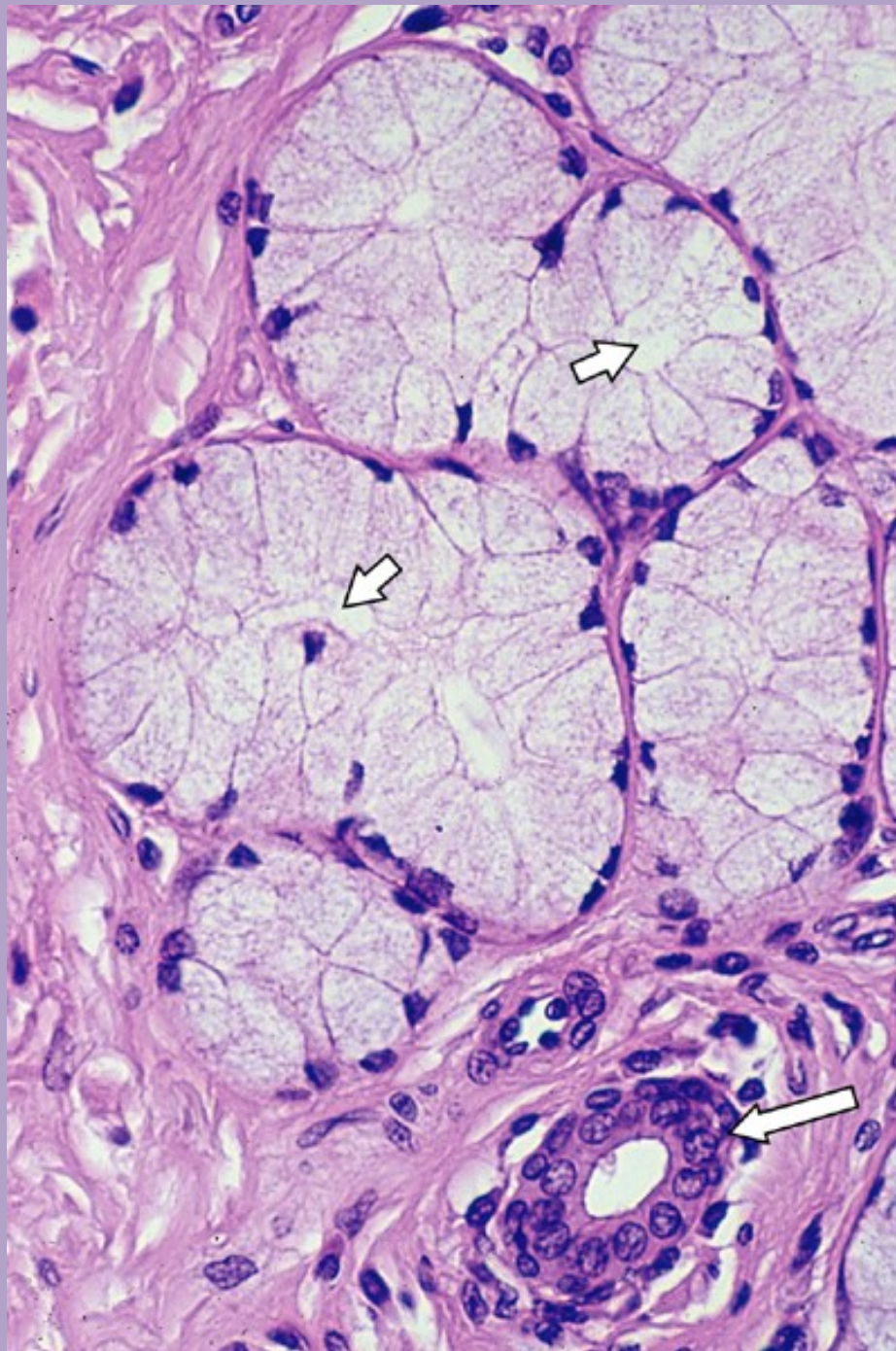
Mucous secretory cells

- Abundant rough ER, Golgi and secretory granules
- Produce mucins (protective, lubricant glycoproteins)
- Examples: mucous cells in stomach, goblet cells in small and large intestine, and mucous cells in salivary glands





Goblet cells in small intestine

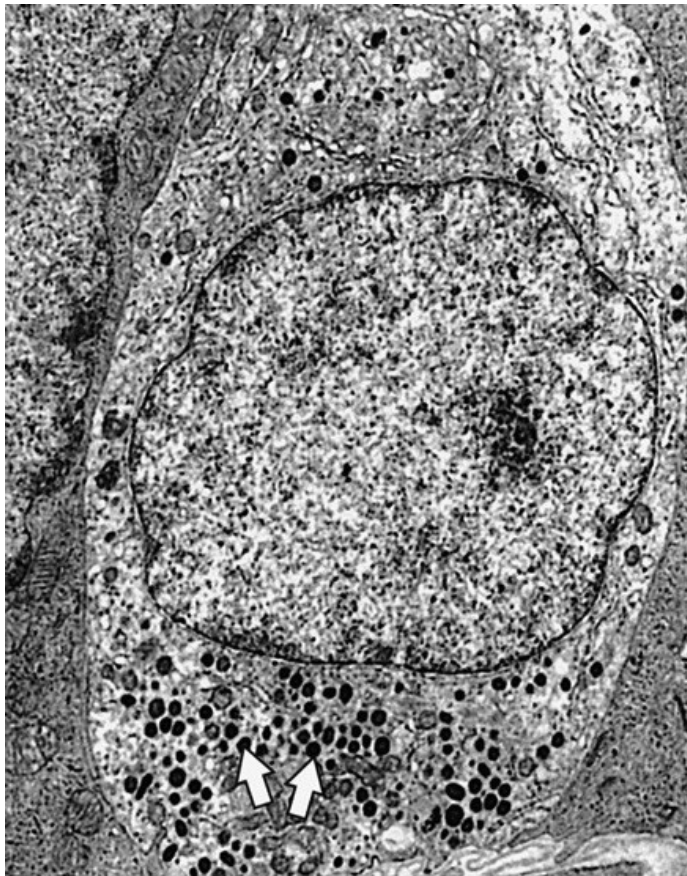


Mucous secretory cells,
oesophagus

EPITHELIAL TISSUE

Neuroendocrine cells

- Dense secretory granules in cytoplasm contain polypeptides and/or amines (like epinephrine and norepinephrine)
- Scattered throughout the body



Myoepithelial cells

- Spindle-shaped cells found in glandular epithelial between basal lamina and basal cytoplasm
- Embrace gland acini
- Contain actin: contract and squeeze out secretory product

