

A microscopic image of skeletal muscle tissue, showing multiple parallel muscle fibers with distinct striations (myofibrils). The fibers are arranged in a regular, repeating pattern, and the overall color is a deep purple. The text "MUSCLE TISSUE" is overlaid in the center in a bold, red, sans-serif font.

# MUSCLE TISSUE

# MUSCLE TISSUE

## GENERAL CONCEPTS

- **Muscle tissue is specialized for the ability to shorten or contract.** While all cells possess the cellular machinery necessary for shape change and contraction, these structures are significantly more prominent in muscle cells. For some muscle types, the cells are non-proliferative due to this high degree of specialization and differentiation.
- **Muscle contraction** is accomplished by the reciprocating sliding of intracellular filaments composed of actin and myosin.
- Muscle tissue comprises the "flesh" of the body and much of the walls of hollow organs. Due to its high degree of specialization, **unique terms** are used for certain structures in muscle cells.
  - Muscle fibers, Myocytes. Individual muscle cells.
  - Sarcoplasm. The cytoplasm of muscle fibers.
  - Sarcolemma. The muscle fiber plasma membrane.
  - Sarcoplasmic reticulum. The smooth endoplasmic reticulum.
- „sarco-“ from Greek sarkos – flesh; „myo-“ from Greek mys – muscle

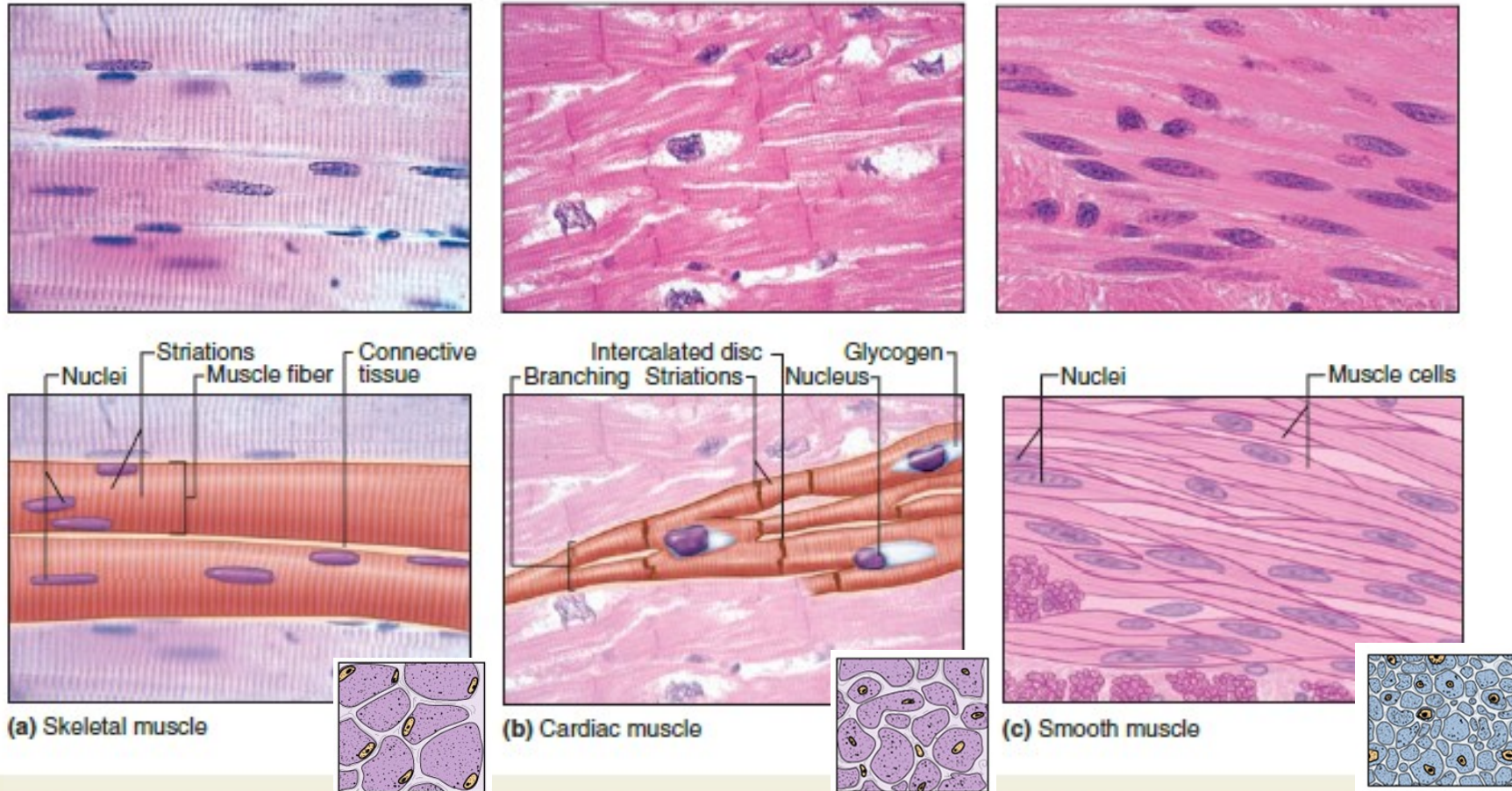
# MUSCLE TISSUE

## CLASSIFICATION OF MUSCLE

- Functional classification is based on the **type of neural control**.
  - Voluntary
  - Involuntary
- Structural classification is based on the **presence or absence of cross striations**.
  - Striated
  - Nonstriated (smooth)
- **Combined functional and structural classification**
  - Skeletal muscle
    - Striated and voluntary
    - Found mostly attached to the skeleton
  - Cardiac muscle
    - Striated and involuntary
    - Composes the majority of the heart wall (myocardium)
  - Smooth (visceral) muscle
    - Nonstriated and involuntary
    - Found mostly in the walls of hollow organs and vessels

# MUSCLE TISSUE

FIGURE 10-1 Three types of muscle.



Light micrographs of each type, accompanied by labeled drawings. **(a) Skeletal muscle** is composed of large, elongated, multinucleated fibers that show strong, quick, voluntary contractions. **(b) Cardiac muscle** is composed of irregular branched cells bound together longitudinally by intercalated discs and shows

strong, involuntary contractions. **(c) Smooth muscle** is composed of grouped, fusiform cells with weak, involuntary contractions. The density of intercellular packing seen reflects the small amount of extracellular connective tissue present. ([a, b]: X200; [c]: X300; All H&E)



	<b>Skeletal</b>	<b>Cardiac</b>	<b>Smooth</b>
Location	Near bones	Heart wall	Walls of hollow organs and blood vessels
Nuclei	Many. Flat. Peripheral.	1-2 per cell. Plump. Central.	One per cell. Central.
Cell diameter	Largest	Intermediate	Smallest
Striations	Yes	Yes	No
Sarcoplasmic reticulum	Yes	Yes	No
T tubules	At junction of A-I bands. Form triads.	At Z lines. Form diads.	None
Motor control	Voluntary	Involuntary	Involuntary
Contraction	Quick and strong	Quick, strong, rhythmic	Slow, in waves
Blood supply	Moderate	Extensive	Less abundant
Other features	Prominent fascicles	Intercalated disks, branching cells	Cells overlap; can synthesize collagen and elastin

# MUSCLE TISSUE

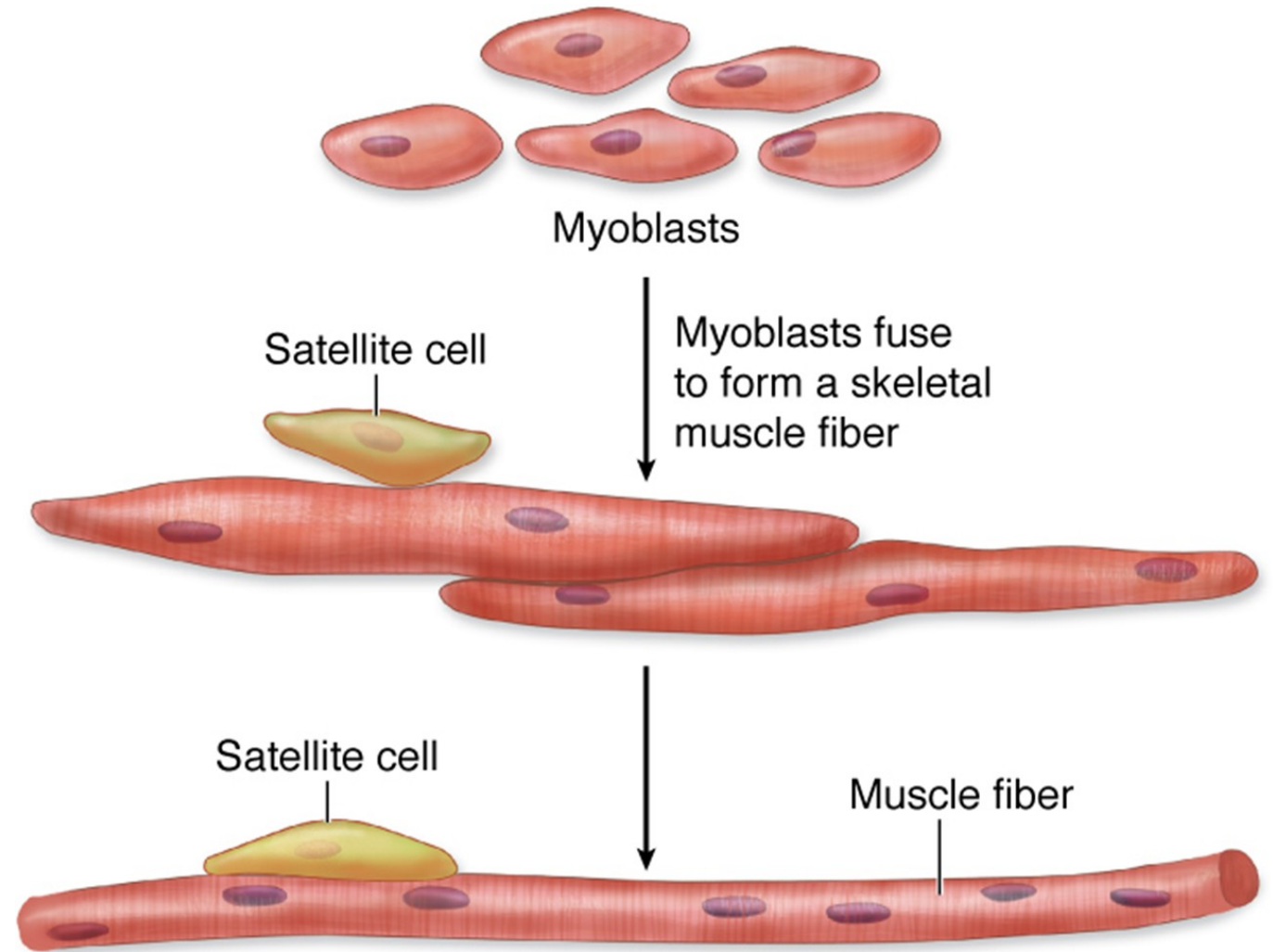
## SKELETAL MUSCLE

### Histogenesis

- Skeletal muscle cells derived from mesenchymal cells, which give rise to *myoblasts*.
- Myoblasts are spindle-shaped. Fuse to form multinucleated *myotubes* which elongate.
- Mature skeletal *muscle cells (fibers)*: long, unbranched tubes with many flattened nuclei.
- Sarcoplasm (cytoplasm) contains mitochondria, glycogen, and myoglobin.
- Mature skeletal muscle cells can't divide.

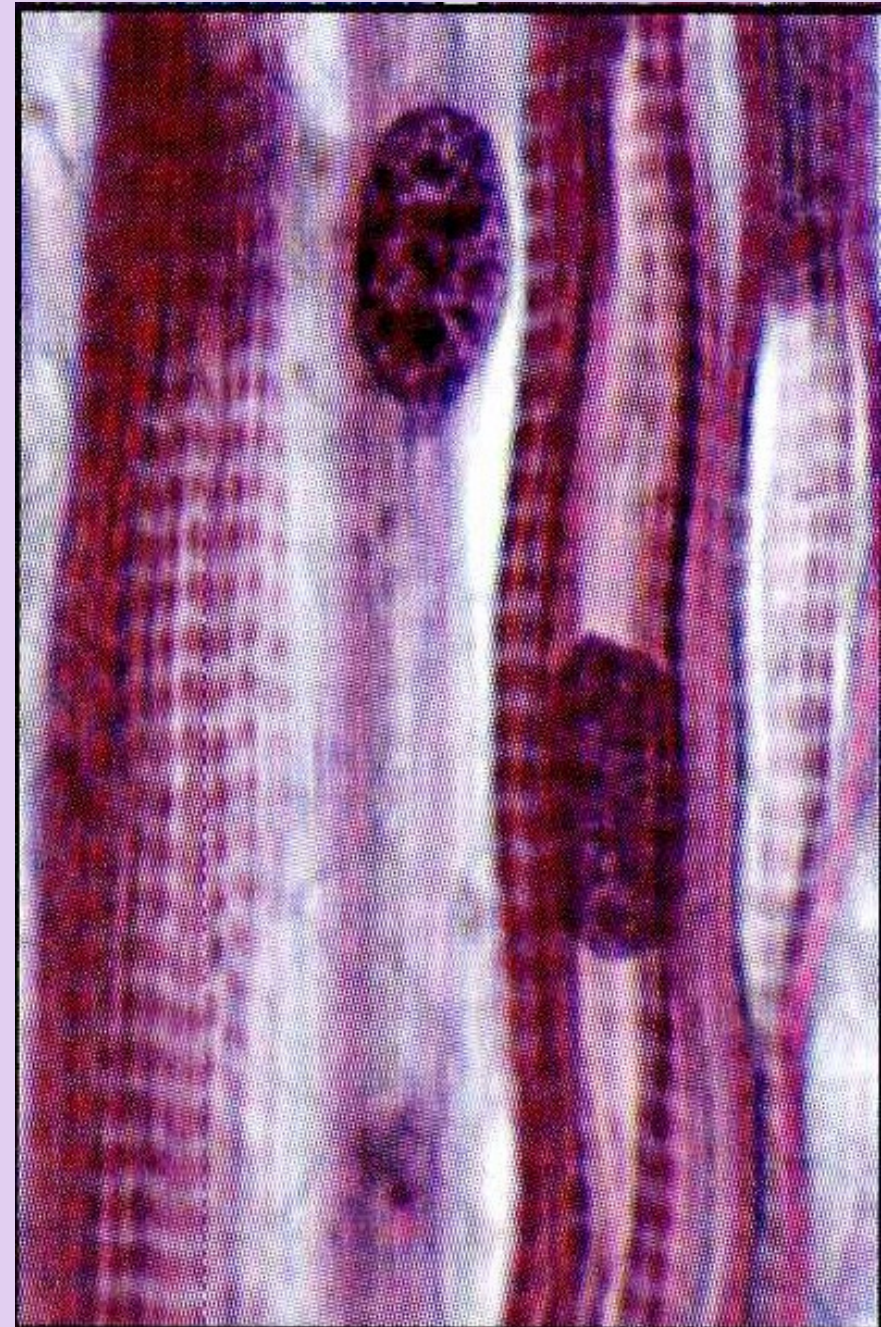
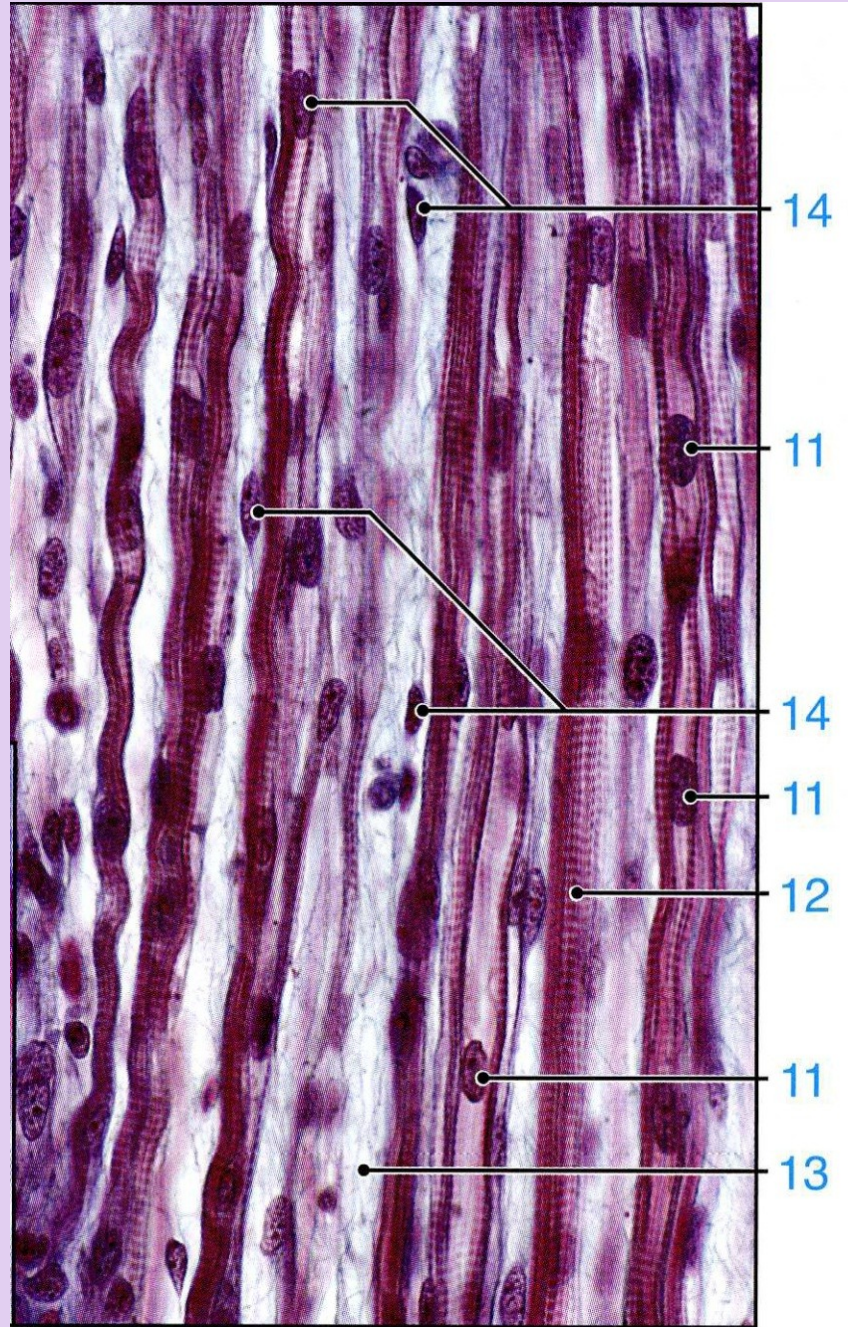
Skeletal muscle begins to differentiate when mesenchymal cells, called **myoblasts**, align and fuse together to make longer, multinucleated tubes called **myotubes**. Myotubes synthesize the proteins to make up myofilaments and gradually begin to show cross-striations by light microscopy. Myotubes continue differentiating to form functional myofilaments, and the nuclei are displaced against the sarcolemma.

Part of the myoblast population does not fuse and differentiate but remains as a group of mesenchymal cells called muscle **satellite cells** located on the external surface of muscle fibers inside the developing external lamina. Satellite cells proliferate and produce new muscle fibers following muscle injury.

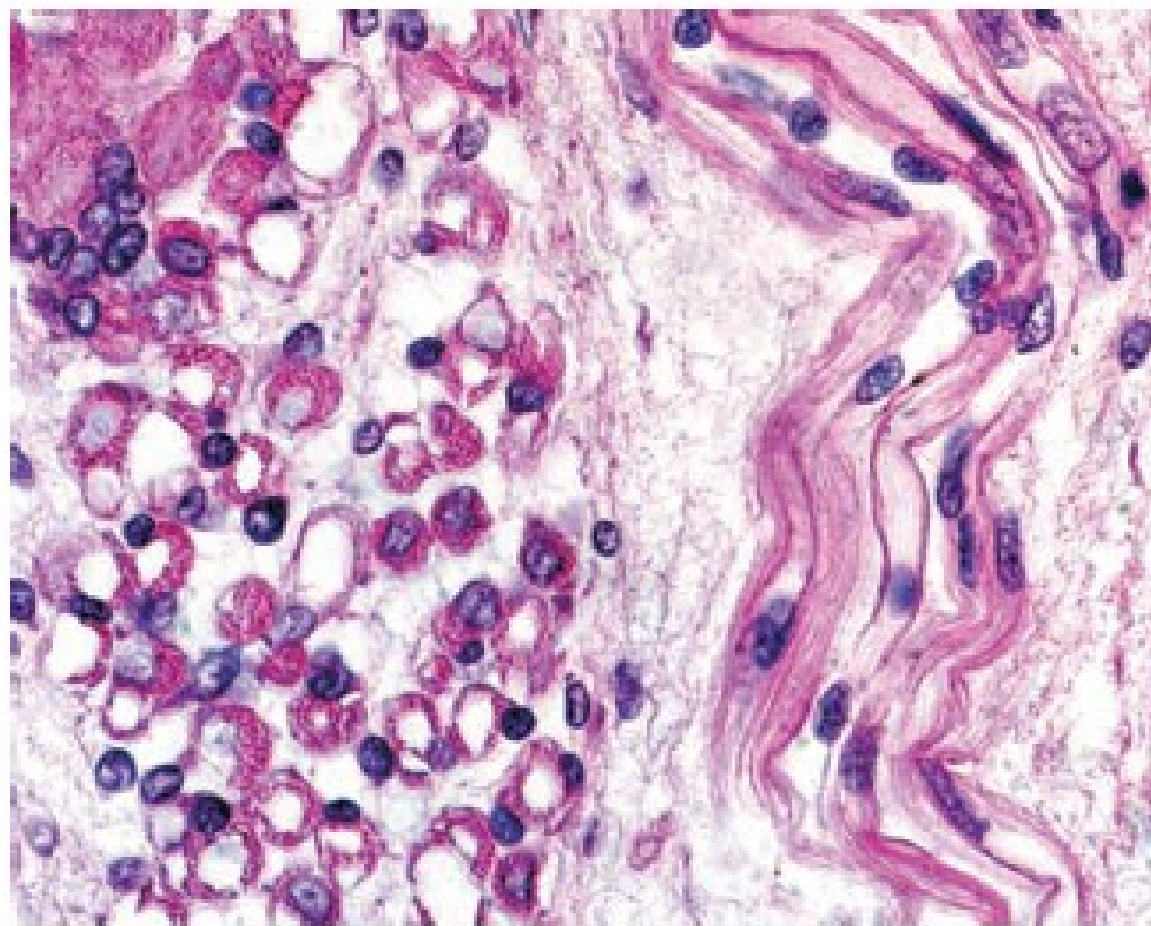




# Myotubes

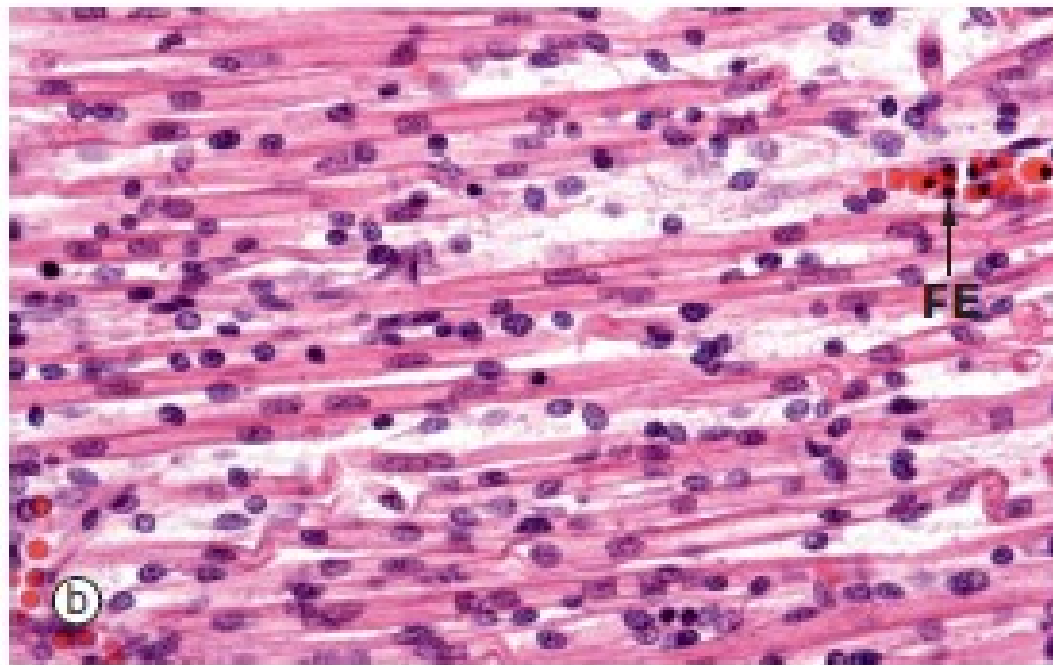
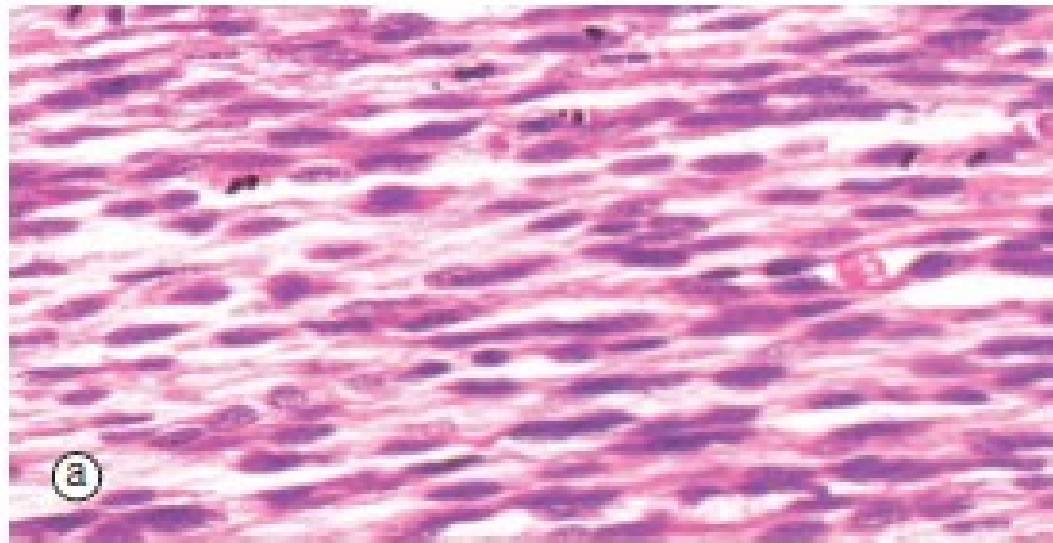






**FIGURE 11.17 ▲ Photomicrograph of developing skeletal muscle myotubes.** This photomicrograph shows a cross-section (on the *left*) and a longitudinal section (on the *right*) of developing skeletal muscle fibers in the stage of secondary myotubes. These myotubes are formed by sequential fusion of myoblasts, forming elongated tubular structures. Note that the myotubes have a small diameter and widely spaced, centrally positioned nuclei that gradually become displaced into the cell periphery by the increased number of newly synthesized myofilaments. In the mature multinucleated muscle fiber (*upper left*), all nuclei are positioned in the peripheral sarcoplasm, just inside the plasma cell membrane.  $\times 220$ .





**FIG. 6.4 Skeletal muscle embryogenesis**  
(a) H&E (MP) (b) H&E (HP)

During embryological development, mesenchymal cells in each myotome differentiate into long, mononuclear skeletal muscle precursors called *myoblasts*, which then proliferate by mitosis. Subsequently, the myoblasts fuse end to end forming elongated multinucleate cells called *myotubes* which may eventually contain up to 100 nuclei. These myotubes then synthesise contractile proteins to form *myofilaments* and so cross-striations gradually become visible. Proliferating myoblasts and early developing myotubes are illustrated in micrograph (a). Micrograph (b) illustrates a slightly later stage in development, and here there is a suggestion of very early cross-striation in some of the myotubes. Note the nucleated fetal erythrocytes **FE** within a small vessel on one edge of the image.

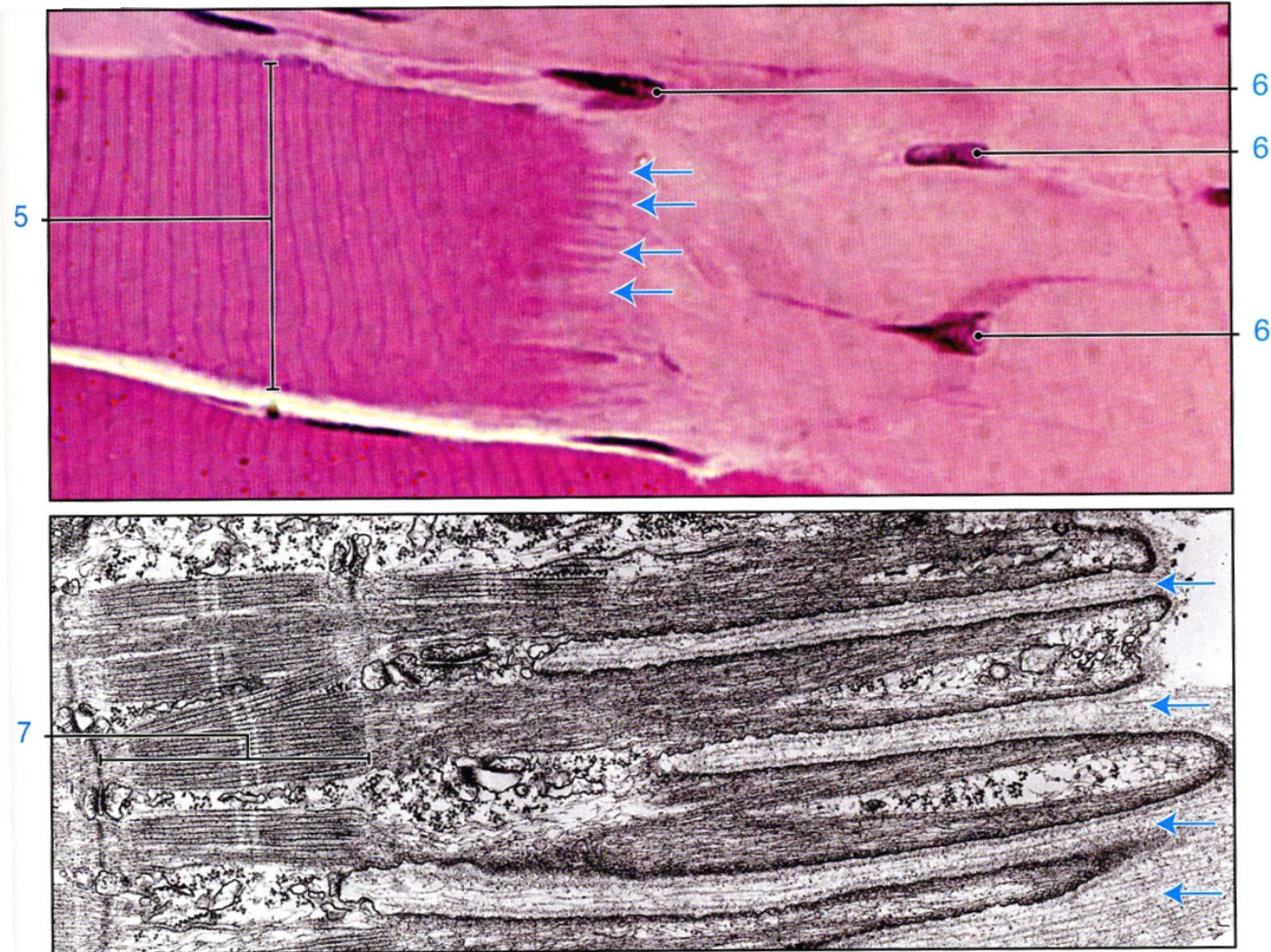
Mature muscle cells can regenerate if damaged, by proliferation of *stem cells* which remain in adult muscles. These muscle stem cells resemble myoblasts and are called *satellite cells*. They enter mitosis after muscle damage, and several fuse to form differentiated muscle fibres. Muscle fibres which have formed as a result of regeneration after damage have nuclei in the centre of the fibre rather than at the periphery.

# MUSCLE TISSUE

## SKELETAL MUSCLE

### Myotendinous junction

- Tendons develop together with skeletal muscles and join muscles to the periosteum of bones.
- The dense collagen fibers of a tendon are continuous with those in the connective tissue layers around muscle fibers, forming a strond unit that allows muscle contraction to move other structures.



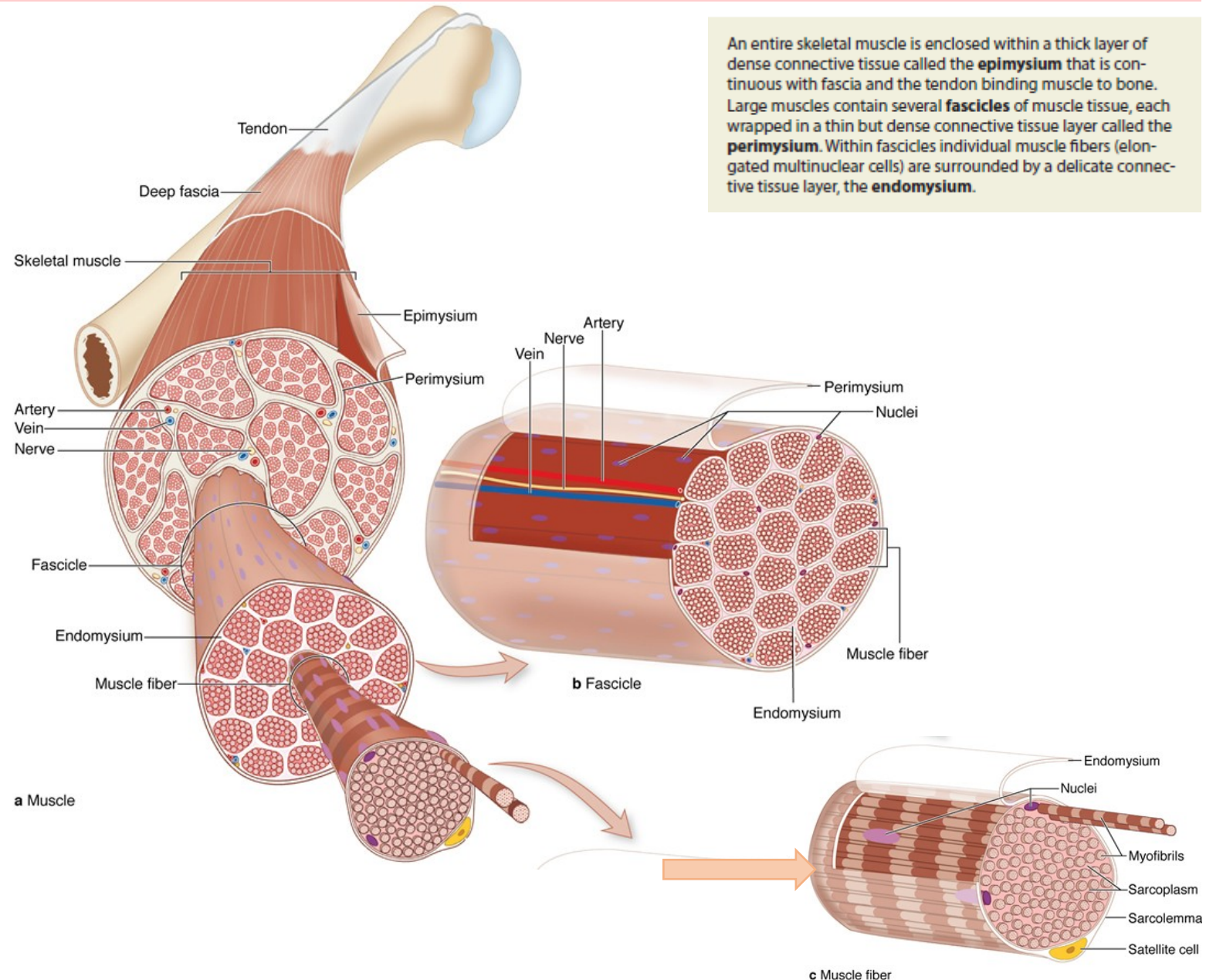


# MUSCLE TISSUE

## SKELETAL MUSCLE

### Connective tissue investments of a skeletal muscle

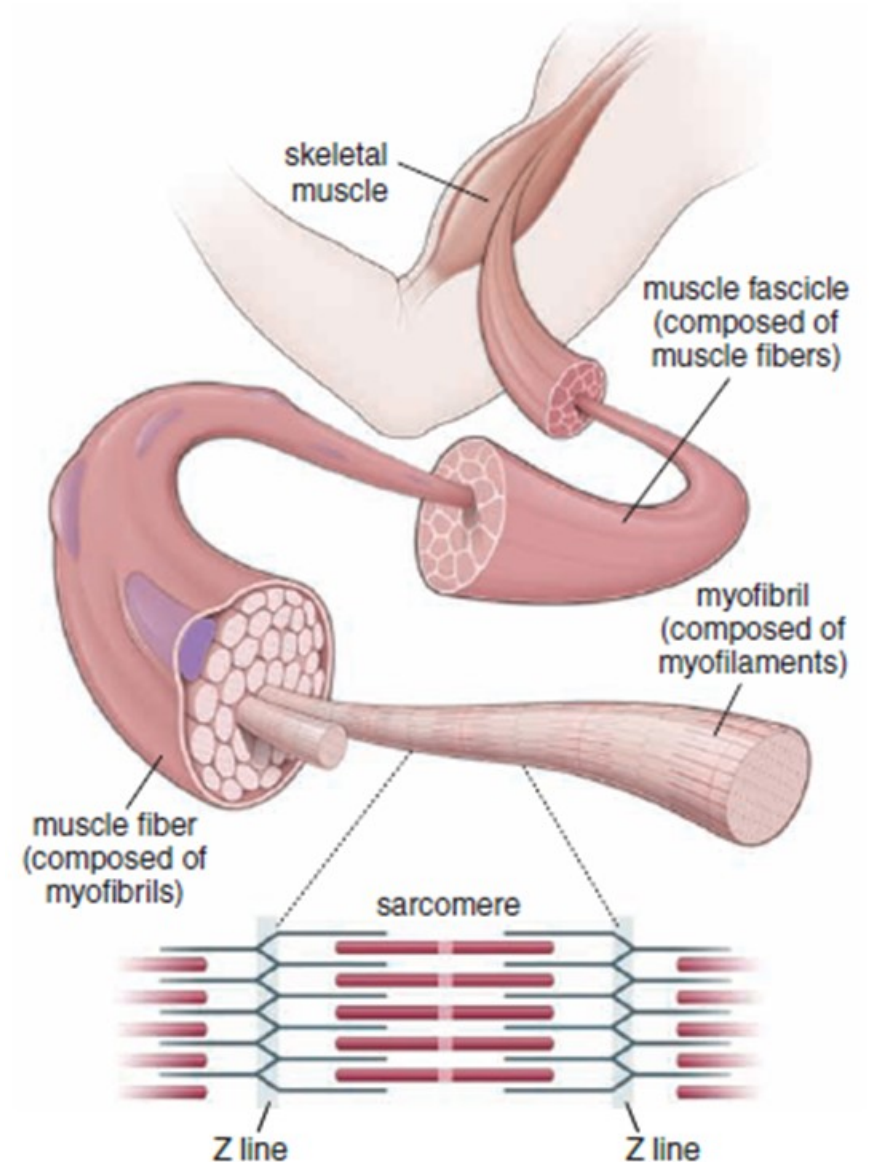
- Function:
  - Separate muscle into compartments
  - Transmit the force of contraction to insertion points
- Components:
  - *Endomysium*. Reticular fibers surrounding each muscle fiber plus the external lamina produced by the muscle fiber
  - *Perimysium*. Dense connective tissue surrounding groups of fibers and dividing the muscle into fascicles
  - *Epimysium*. Dense connective tissue surrounding the entire muscle, blends with the deep fascia and tendons



# MUSCLE TISSUE

## Hierarchy of skeletal muscle organization

- *Myofilaments*. Visible only with the electron microscope; composed primarily of actin, which forms 5-nm wide thin filaments, and myosin, which forms 15-nm wide thick filaments
- *Myofibrils*. Visible with the light microscope, 1-2 microns wide, oriented parallel to the long axis of the cell; composed of bundles of overlapping myofilaments that are arranged in register, producing an alternating light-dark, striated banding pattern
- *Muscle fiber*. Specialized term for a muscle cell, 10-100 microns wide; sarcoplasm is filled with hundreds of myofibrils, which are oriented parallel to each other and to the long axis of the muscle fiber.
- *Muscle fascicle*. Collection of muscle fibers surrounded by perimysium; collections of muscle fascicles are surrounded by the epimysium and form a named muscle such as the biceps brachii or latissimus dorsi.



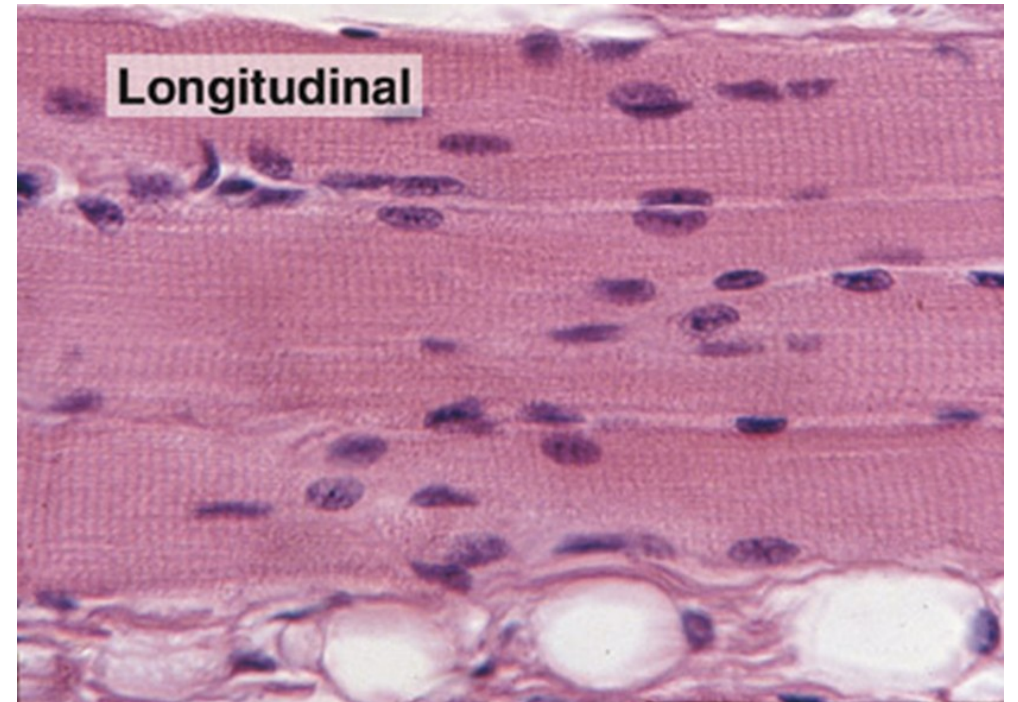
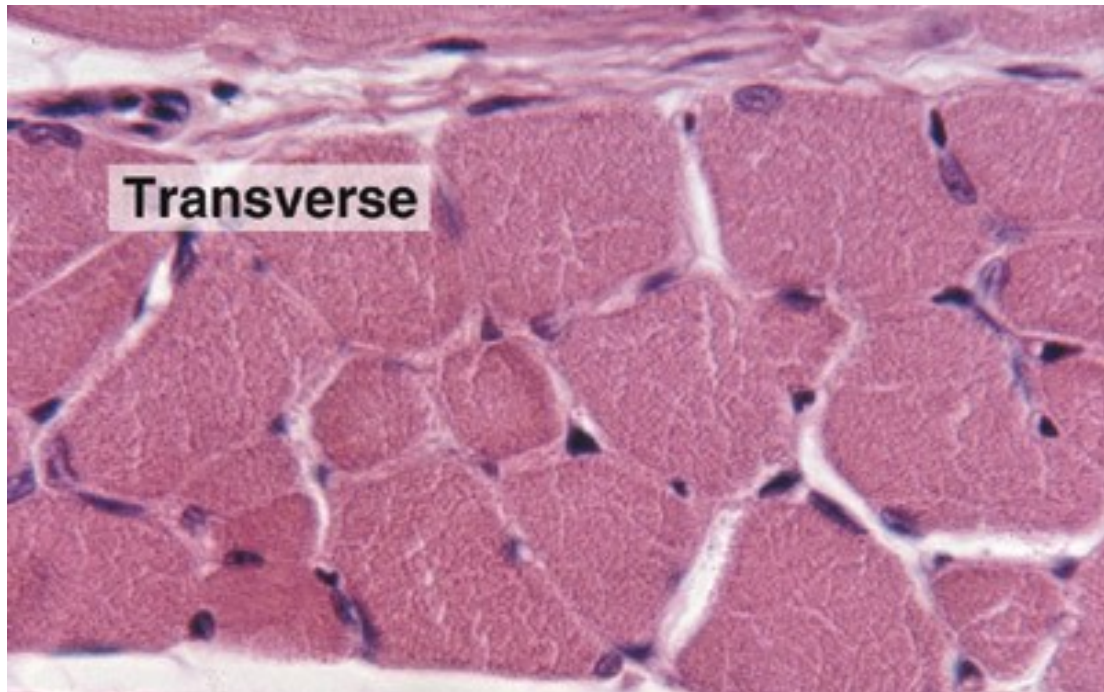
**FIGURE 11.4** ▲ **Organization of a skeletal muscle.** A skeletal muscle consists of bundles of muscle fibers called fascicles. In turn, each fascicle consists of a bundle of elongate muscle fibers (cells). The muscle fiber represents a collection of longitudinal units, the myofibrils, which in turn are composed of myofilaments of two types: thick (myosin) filaments and thin (actin) filaments. The myofilaments are organized in a specific manner that imparts a cross-striated appearance to the myofibril and to the fiber. The functional unit of the myofibril is the sarcomere; it extends in both directions from one Z line to the next Z line. The A band marks the extent of the myosin filaments. Actin filaments extend from the Z line into the region of the A band, where they interdigitate with the myosin filaments as shown.



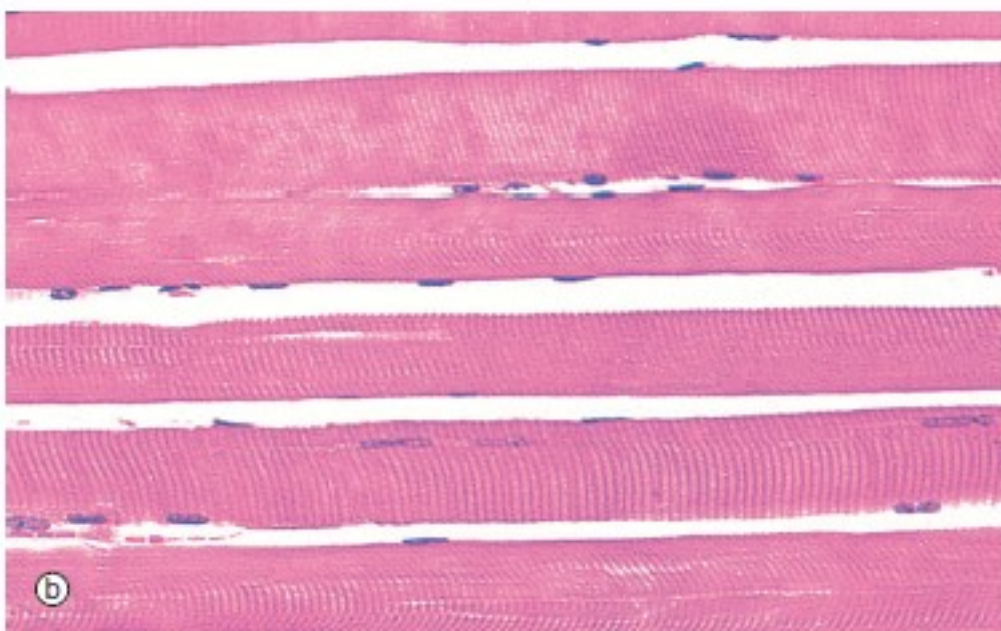
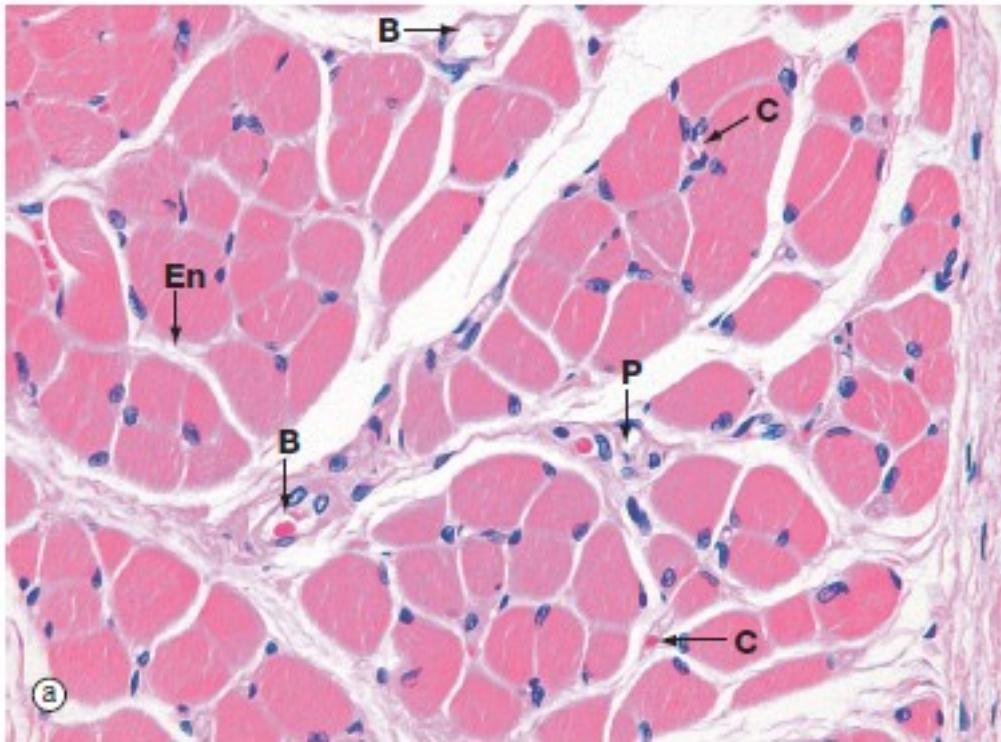
# MUSCLE TISSUE

## Structure of skeletal muscle fibers

- Largest fiber type, fibers can be 1-30 mm in length and 10-100 microns in diameter.
- Each muscle fiber is **cylindrical, unbranched, and multinucleated**.
- The multiple **nuclei are located at the periphery of the muscle fiber** immediately **beneath the sarcolemma**.
- Extensive smooth endoplasmic reticulum is called the **sarcoplasmic reticulum**.
- Each fiber is surrounded by an **external lamina** which contributes to the endomysium of the muscle fiber.
- Fibers can increase in size (**hypertrophy**) but not in number (hyperplasia).
- Fibers show prominent, alternating light and dark bands (**cross-striations**) due to the alignment and overlap of the myofilaments within myofibrils.







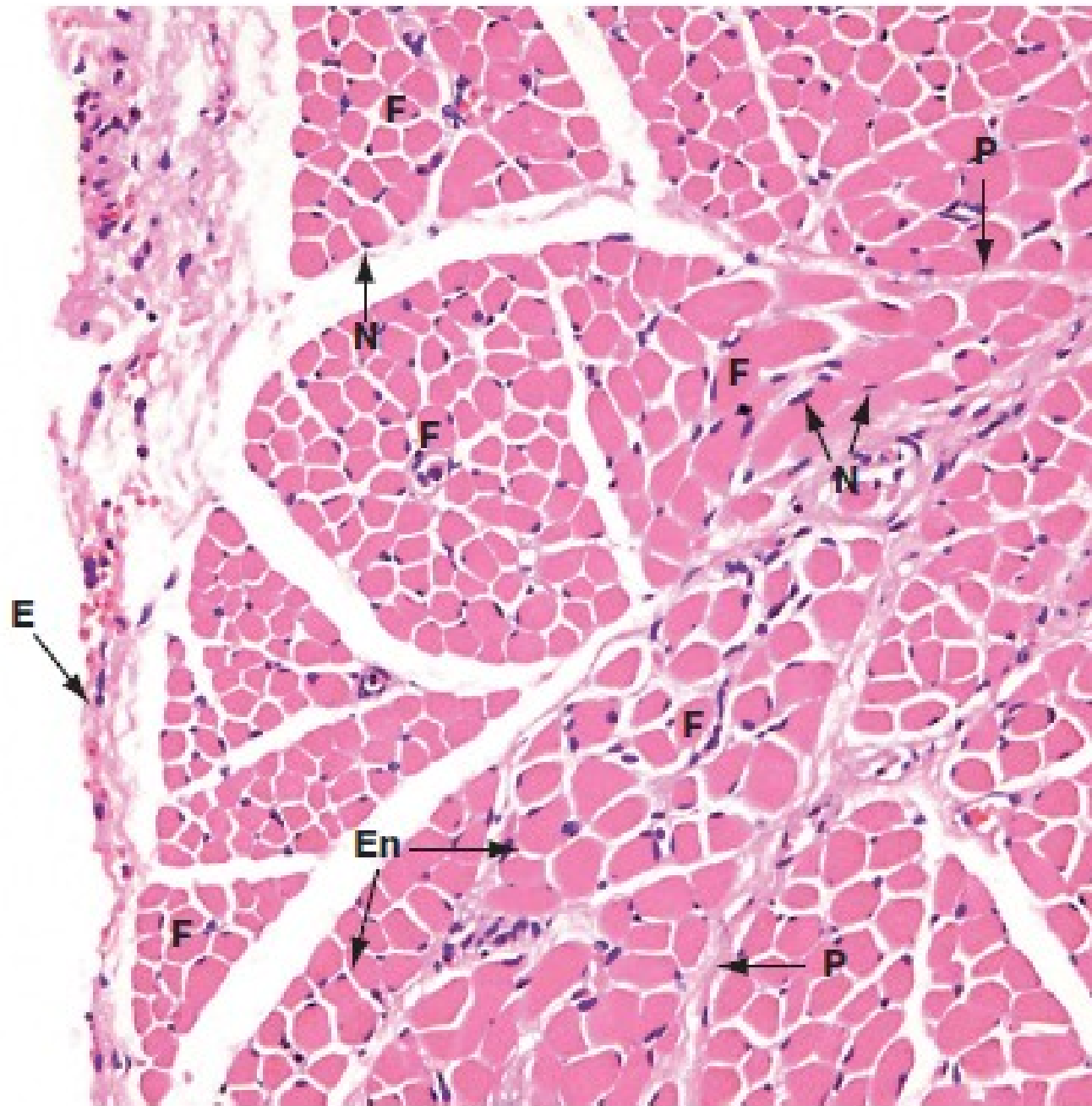
**FIG. 6.3 Skeletal muscle**  
 (a) H&E, TS (HP) (b) H&E, LS (HP)

These micrographs show skeletal muscle from human limb muscles. Micrograph (a) in transverse section shows the muscle to be made up of numerous small fasciculi. The spaces between the fasciculi are filled with loose collagenous tissue, the *perimysium P*, which is continuous with the delicate *endomysium En*, separating individual muscle fibres in each fasciculus. The supporting tissue of skeletal muscle also contains elastin fibres (not distinguishable in this preparation) which are most numerous in muscles attached to soft tissues as in the tongue and face. Note the rich network of capillaries *C* in the endomysium. Small blood vessels *B* and nerves run in the perimysium.

Micrograph (b) demonstrates the characteristic histological features of skeletal muscle fibres in longitudinal section. Skeletal muscle fibres are extremely elongated, unbranched cylindrical cells with numerous flattened nuclei located at fairly regular intervals just beneath the *sarcolemma* (plasma membrane).

Each muscle fibre has multiple nuclei arranged at the cell periphery. In transverse section, as in micrograph (a), most muscle fibre profiles appear to contain only a single nucleus, while some do not include any because the plane of section has cut between the zones containing a nucleus.

In routine histological preparations stained with H&E, it is often possible to see the striations in skeletal muscle when cut in longitudinal section. Special stains are required for better resolution of these structures (see Fig. 6.6a).



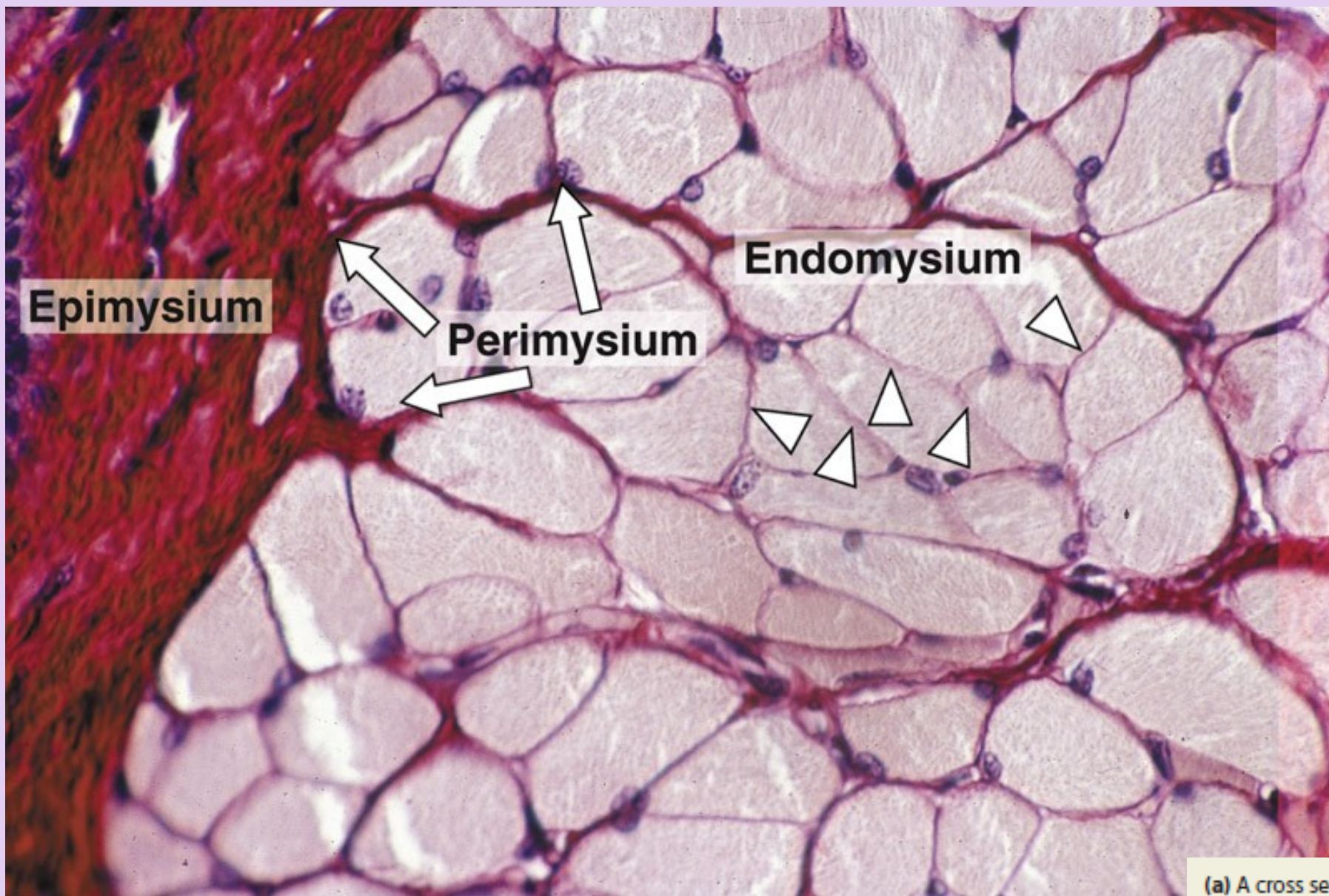
**FIG. 6.2** Skeletal muscle  
H&E (MP)

This micrograph shows the general arrangement of muscle fibres in skeletal muscle. Here, there are several distinct fasciculi.

The individual pink-stained muscle cells (fibres) are cut in transverse section and appear polygonal in shape, with nuclei **N** lying at the peripheries of the cells. The spaces between the cells are occupied by small amounts of barely visible endomysial supporting tissue. The endomysium, which consists mainly of reticulin fibres and a small amount of collagen, conveys numerous small blood vessels, lymphatics and nerves throughout the muscle.

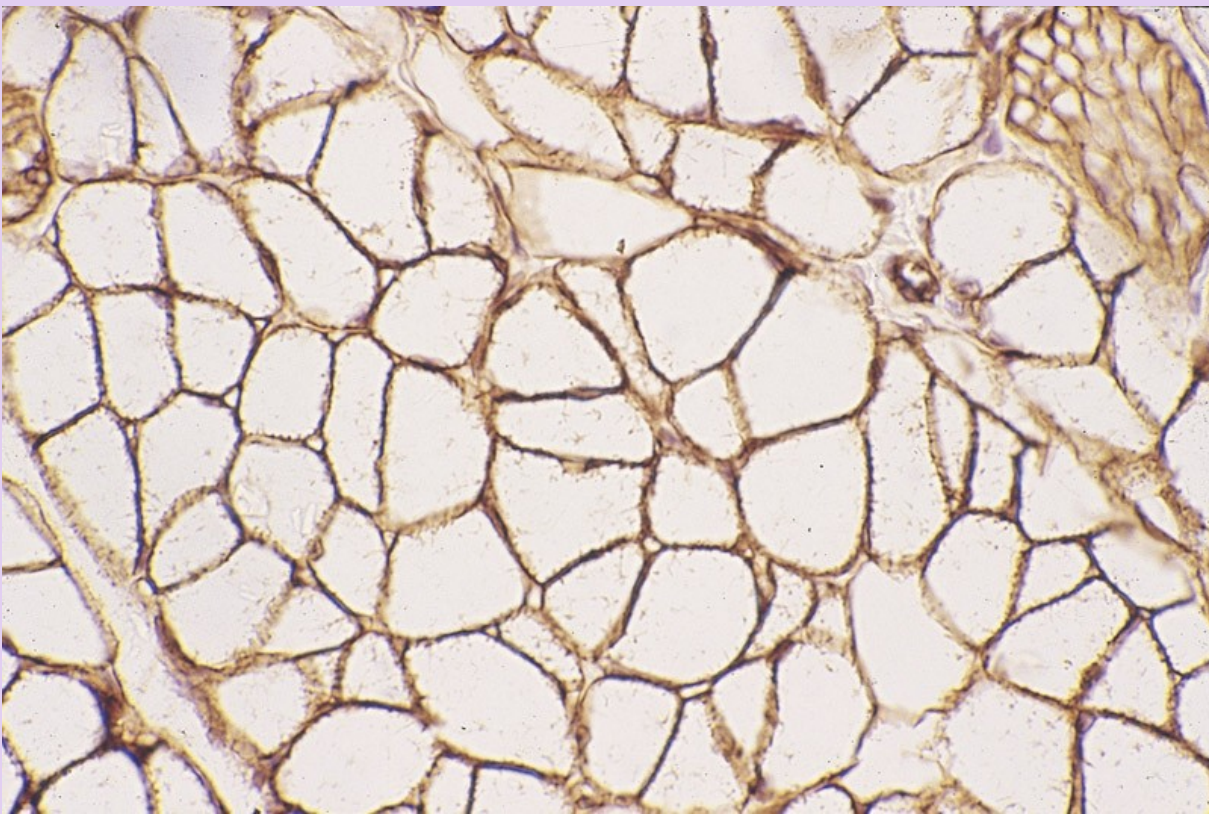
Surrounding the individual fasciculi **F** is the *perimysium* **P**, composed of collagen and through which larger vessels and nerves run. The *epimysium* **E** is a collagenous sheath that binds the fascicles into a single muscle. The *endomysium* **En** is barely visible as the delicate support tissue surrounding each muscle fibre.





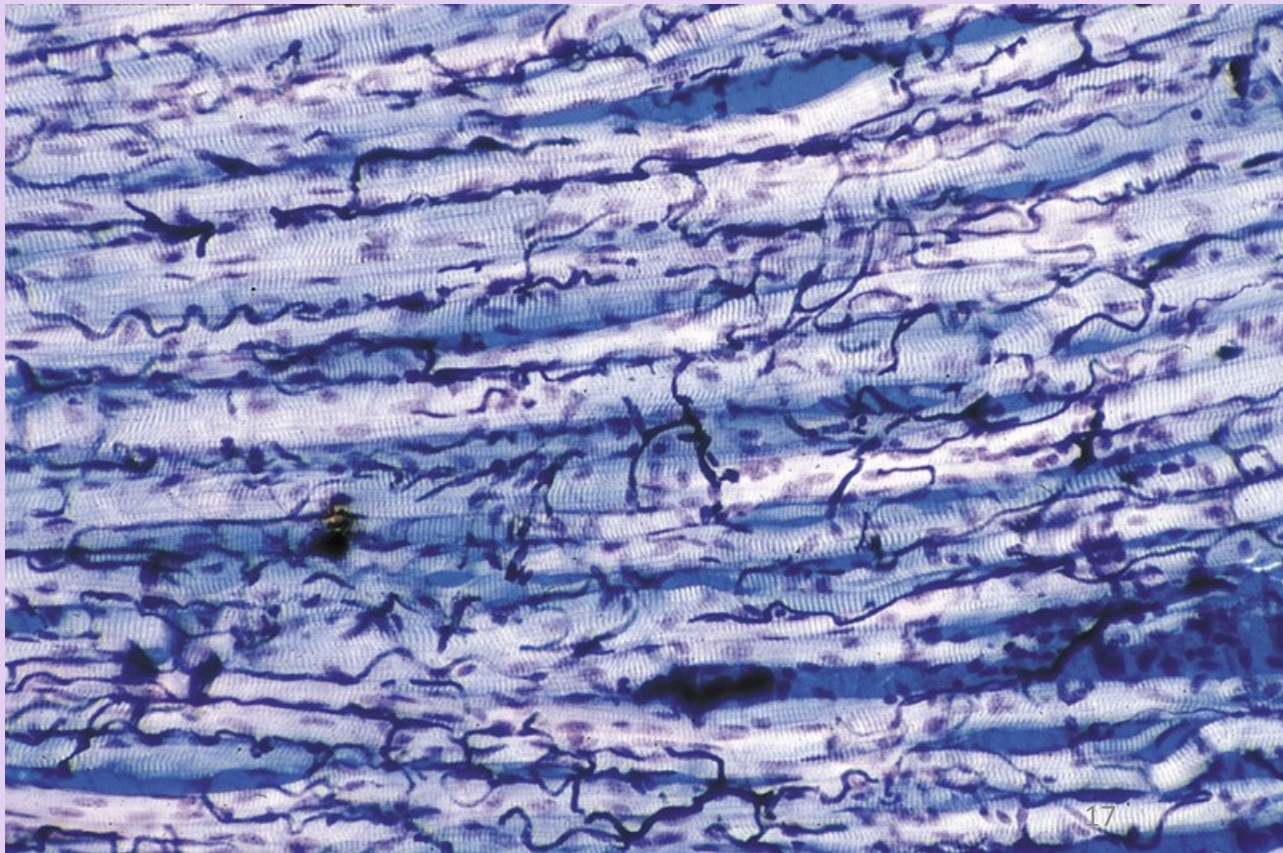
(a) A cross section of striated muscle demonstrating all three layers of connective tissue and cell nuclei. The endomysium (**En**) surrounds individual muscle, and perimysium (**P**) encloses a group of muscle fibers comprising a fascicle. A thick epimysium (**E**) surrounds the entire muscle. All three of these tissues contain collagen types I and III (reticulin). (X200; H&E)





**(b)** An adjacent section immunohistochemically stained for laminin, which specifically stains the external laminae of the muscle fibers, surrounded by endomysium. (X400; Immunoperoxidase)

The blood vessels were injected with a dark plastic polymer before the muscle was collected and sectioned longitudinally. A rich network of capillaries in endomysium surrounding muscle fibers is revealed by this method. (X200; Giemsa with polarized light)





# MUSCLE TISSUE

## Structure of skeletal muscle fibers

- **Myofilaments** within a myofibril are arranged in register and adjacent myofibrils are similarly aligned, causing the banding pattern seen at both the light and electron microscopic levels.
  - *A band* appears dark and contains both actin and myosin myofilaments.
  - *I band* appears light and contains actin myofilaments only.
  - *Z line*, composed of alpha-actinin and Cap Z proteins, is located in the center of the I band and serves as the attachment site for actin myofilaments.
  - *H band* is located in the center of the A band and represents the area where actin myofilaments are not present.
  - *M band* is located in the center of the H band and represents areas of cross-connections between myosin myofilaments.



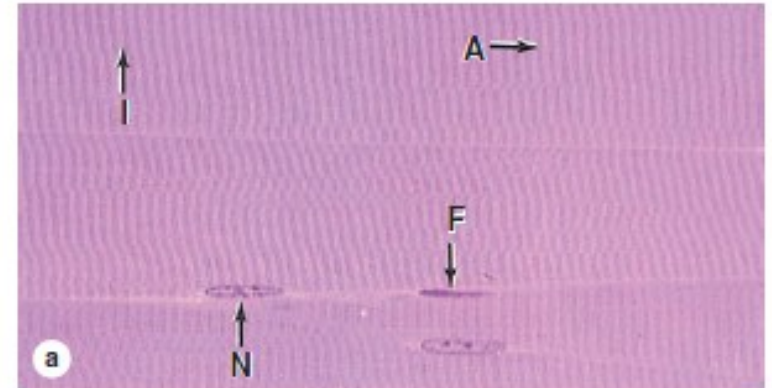
Longitudinal sections reveal the striations characteristic of skeletal muscle.

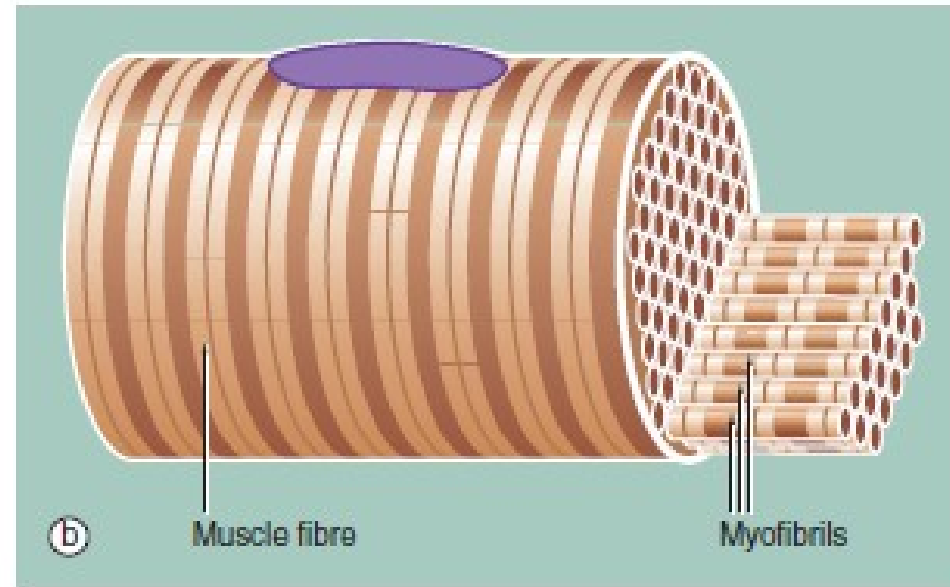
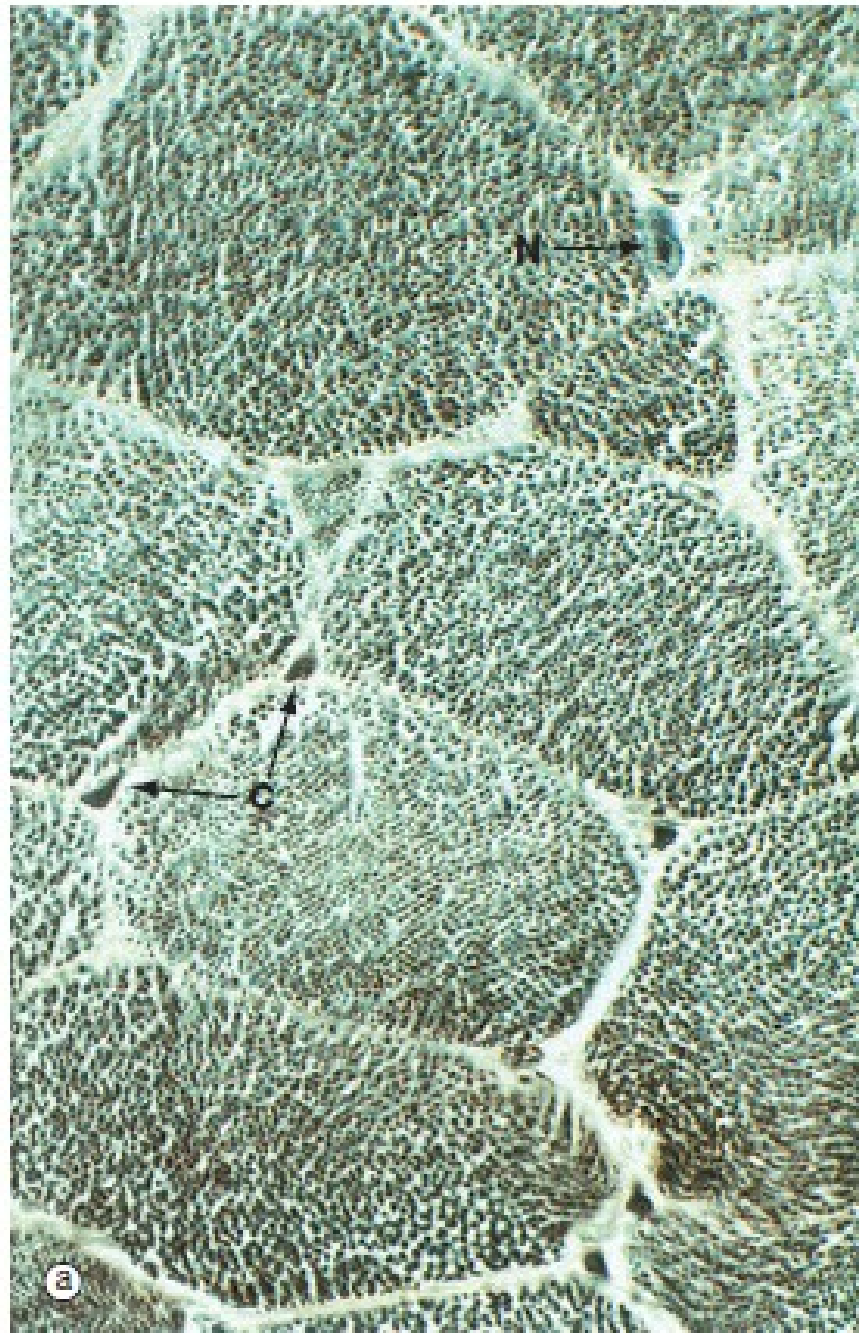
(a) Parts of three muscle fibers are separated by very thin endomysium that includes one fibroblast nucleus (F). Muscle nuclei (N) are found against the sarcolemma. Along each fiber thousands of dark-staining A bands alternate with lighter I bands. (X200; H&E)

(b) At higher magnification, each fiber can be seen to have three or four myofibrils, here with their striations slightly out of alignment with one another. Myofibrils are cylindrical bundles of thick and thin myofilaments which fill most of each muscle fiber. (X500; Giemsa)

(c) TEM showing one contractile unit (**sarcomere**) in the long series that comprises a myofibril. In its middle is an electron-dense **A band** bisected by a narrow, less dense region called the **H zone**. On each side of the A band are the lighter-stained **I bands**, each bisected by a dense **Z disc** which marks one end of the sarcomere. Mitochondria (**M**), glycogen granules, and small cisternae of SER occur around the Z disc. (X24,000)

(Figure 10-6c, used with permission from Mikel H. Snow, Department of Cell and Neurobiology, Keck School of Medicine at the University of Southern California, Los Angeles.)






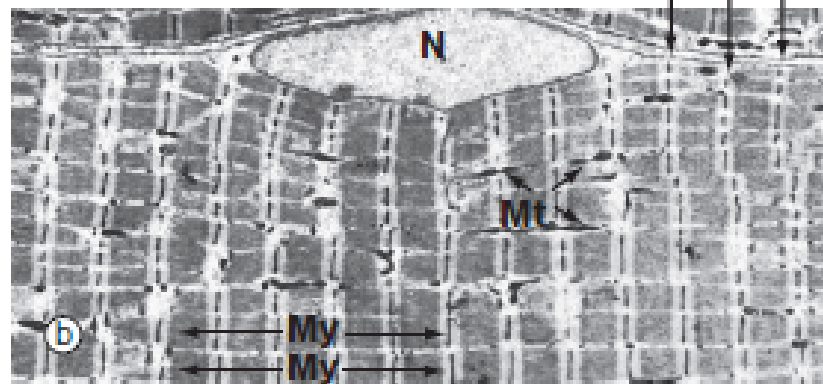

**FIG. 6.5 Skeletal muscle**

**(a) Iron haematoxylin, TS (HP) (b) Schematic diagram**

Micrograph (a) shows a transverse section through several skeletal muscle fibres at very high magnification. The plane of section includes only one skeletal muscle cell nucleus N. Note the presence of erythrocytes in endomysial capillaries C.

In preparations such as this, the transversely sectioned muscle fibres appear packed with numerous dark dots. These represent the cut ends of myofibrils, elongated cylindrical structures which lie parallel to one another in the sarcoplasm.

Figure (b) shows part of a single muscle fibre. The diagram illustrates that each myofibril exhibits a repeating pattern of cross-striations which is a product of the highly ordered arrangement of the contractile proteins within it; detail of this arrangement can only be seen using electron microscopy (see Fig. 6.6). Furthermore, the parallel myofibrils are each arranged with their cross-striations in register, giving rise to the regular striations which may be seen with light microscopy in longitudinal sections of skeletal muscle as in Fig. 6.3.



**FIG. 6.6 Skeletal muscle**

(a) Heidenhain's haematoxylin (HP) (b) EM  $\times 2860$

(c) EM  $\times 18\ 700$

This series of micrographs shows the arrangement of the contractile proteins within skeletal muscle and explains the striations seen with light microscopy.

Micrograph (a) shows the striations of a skeletal muscle fibre at a magnification close to the limit of resolution. They are composed of alternating broad light I bands (isotropic in polarised light) and dark (anisotropic) A bands. Fine dark lines called Z lines (Zwischenscheiben) Z can be seen bisecting the I bands. Note the nucleus N at the periphery of the cell.

Micrograph (b) shows the electron microscopic appearance of muscle with a nucleus N situated in a similar position. The sarcoplasm is filled with myofibrils My oriented parallel to the long axis of the cell. These are separated by a small amount of sarcoplasm containing rows of mitochondria Mt in a similar orientation. Each myofibril has prominent regular cross-striations arranged in register with those of the other myofibrils and corresponding to the I, A and Z bands seen in light microscopy. The Z bands are the most electron-dense and divide each myofibril into numerous contractile units called sarcomeres, arranged end to end.

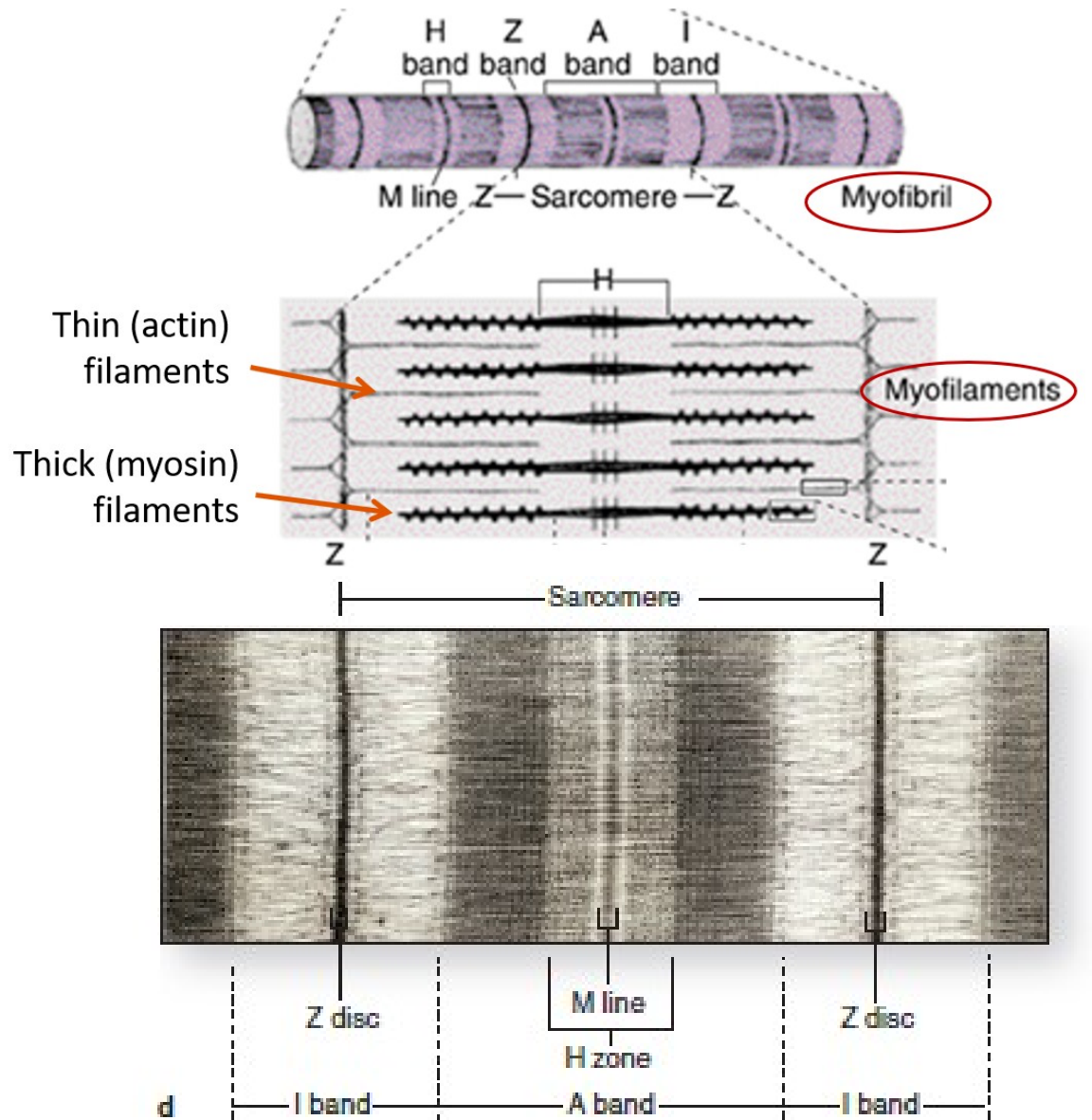
With further magnification in micrograph (c), the arrangement of the contractile proteins (myofilaments) may be seen in each sarcomere. The dark A band is bisected by the lighter H (Heller) band, which is further bisected by a more dense M (Mittelscheibe) line. Irrespective of the degree of contraction of the muscle fibre, the A band remains constant in width. In contrast, the I and H bands narrow during contraction, and the Z lines are drawn closer together. These findings are explained by the sliding filament theory (Fig. 6.7). Mitochondria Mt and numerous glycogen granules G provide a rich energy source in the scanty cytoplasm between the myofibrils. The mature muscle cell contains little rough endoplasmic reticulum; it contains, however, a smooth membranous system S which is involved in activation of the contractile mechanism (see Figs 6.8 to 6.10).

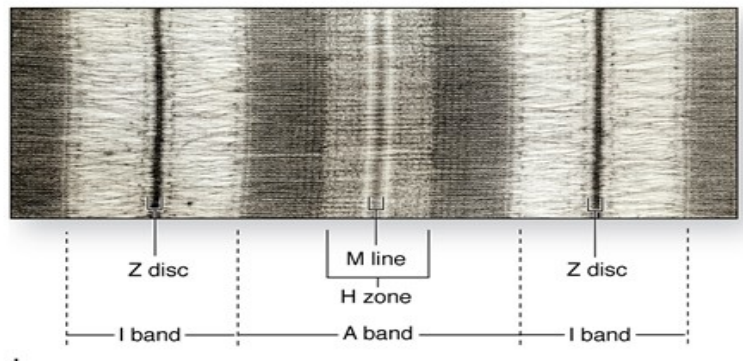
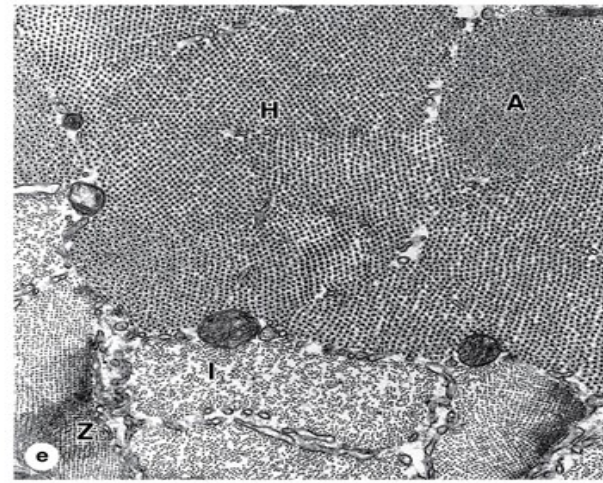
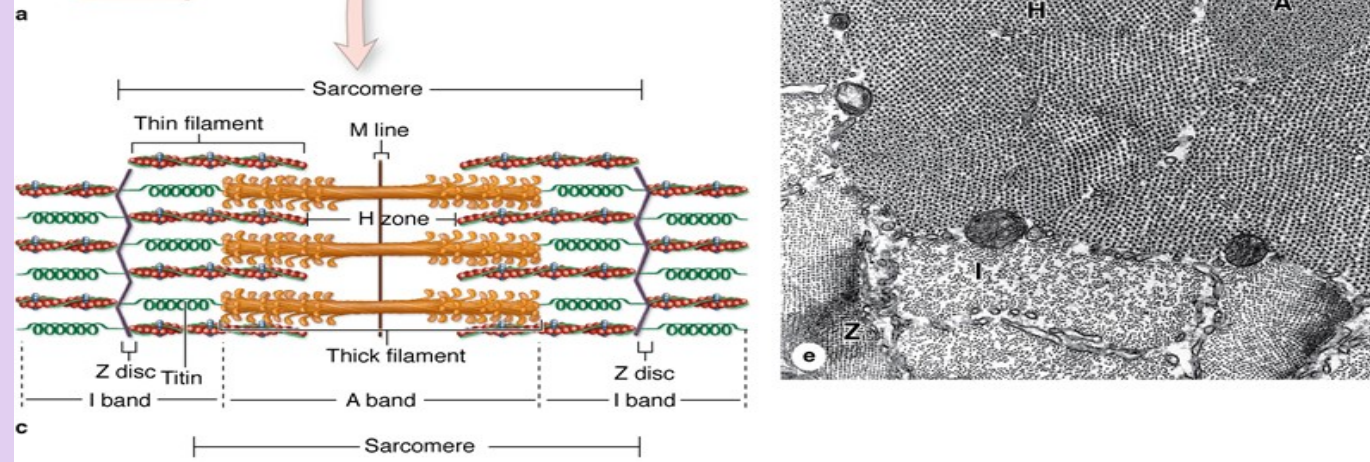
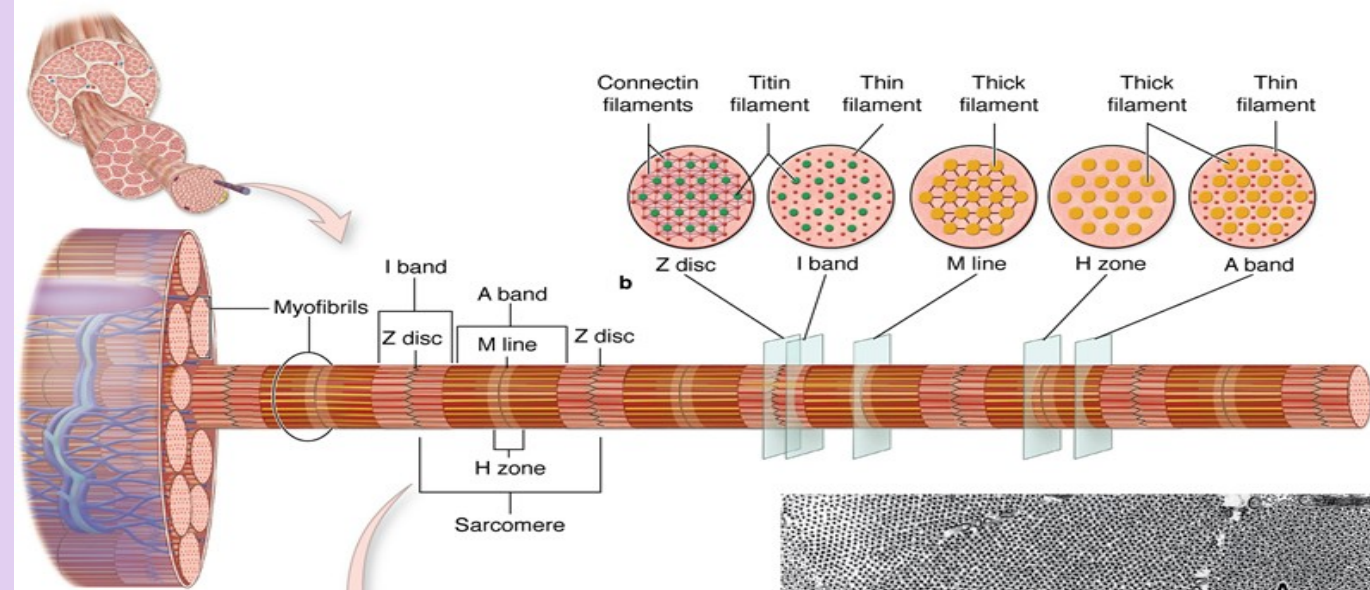


# MUSCLE TISSUE

## Structure of skeletal muscle fibers

- **Sarcomere**
  - Contractile unit of striated muscle fibers, seen in both skeletal and cardiac muscle fibers
  - Extends from Z line to Z line
  - Sarcomeres are repeated in series along the length of each myofibril. Adjacent myofibrils maintain the alignment of sarcomeres.





(a) The diagram shows that each muscle fiber contains several parallel bundles called **myofibrils**.

(b) Each myofibril consists of a long series of sarcomeres, separated by Z discs and containing thick and thin filaments which overlap in certain regions.

(c) Thin filaments are actin filaments with one end bound to  $\alpha$ -actinin in the Z disc. Thick filaments are bundles of myosin, which span the entire A band and are bound to proteins of the M line and to the Z disc across the I bands by a very large protein called **titin**, which has springlike domains.

(d) The molecular organization of the sarcomeres produces staining differences which cause the dark- and light-staining bands seen by light microscopy and TEM. (X28,000)

(e) With the TEM an oblique section of myofibrils includes both **A** and **I** bands and shows hexagonal patterns that indicate the relationships between thin and thick myofibrils and other proteins, as shown in part **b** of this figure. Thin and thick filaments are arranged so that each myosin bundle contacts six actin filaments. Large mitochondria in cross section and SER cisternae are seen between the myofibrils. (X45,000)

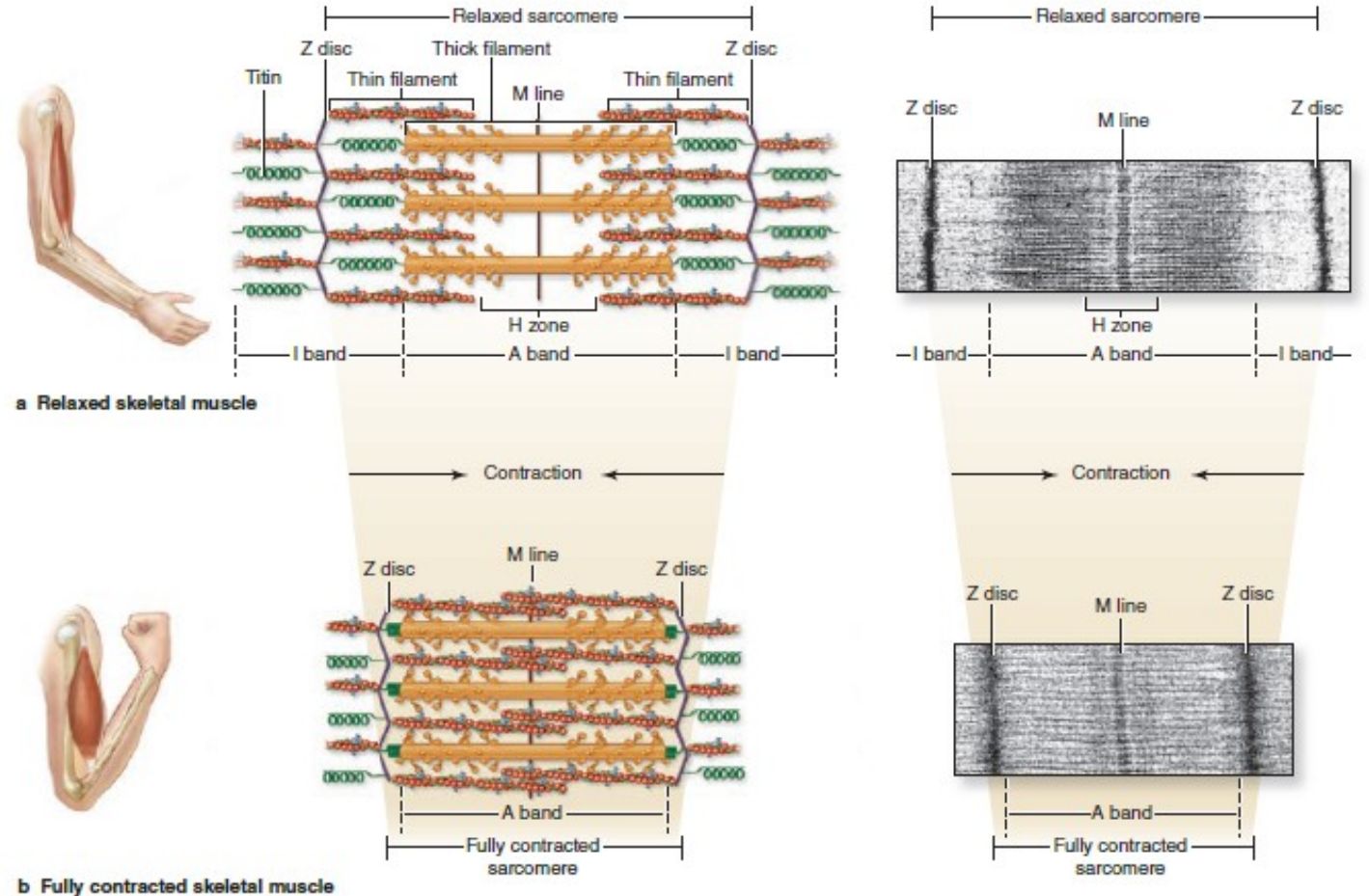


# MUSCLE TISSUE

## Structure of skeletal muscle fibers

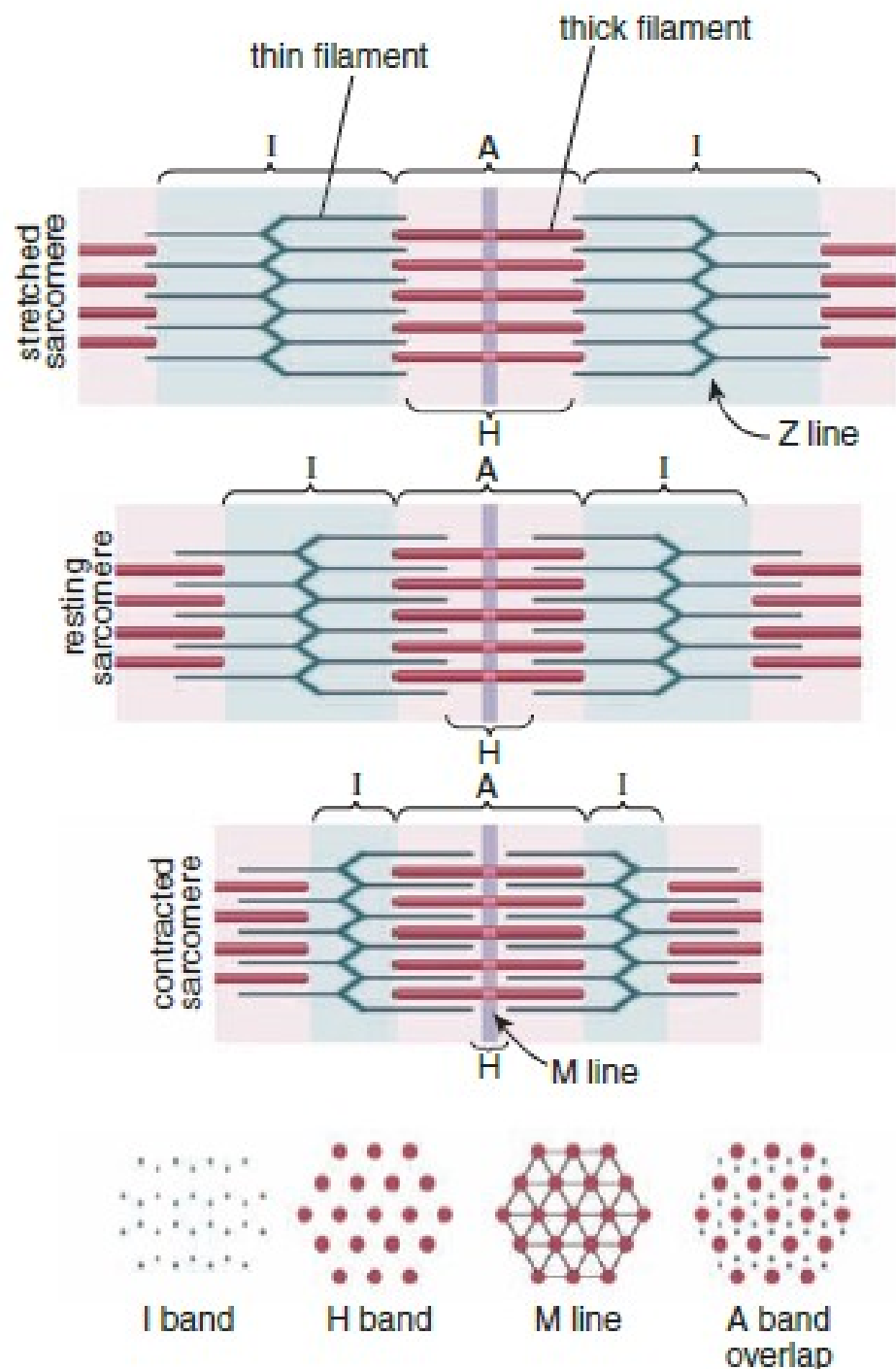
- **Alterations in sarcomeres during contraction**
  - Sarcomeres shorten as actin myofilaments are pulled past the myosin myofilaments.
  - Z line interval narrows.
  - Width of H and I bands decreases.
  - A band width remains unchanged.

**FIGURE 10–12** Sliding filaments and sarcomere shortening in contraction.



Diagrams and TEM micrographs show sarcomere shortening during skeletal muscle contraction. **(a)** In the relaxed state the sarcomere, I band, and H zone are at their expanded length. The springlike action of titin molecules, which span the I band, helps pull thin and thick filaments past one another in relaxed muscle.

**(b)** During muscle contraction, the Z discs at the sarcomere boundaries are drawn closer together as they move toward the ends of thick filaments in the A band. Titin molecules are compressed during contraction.



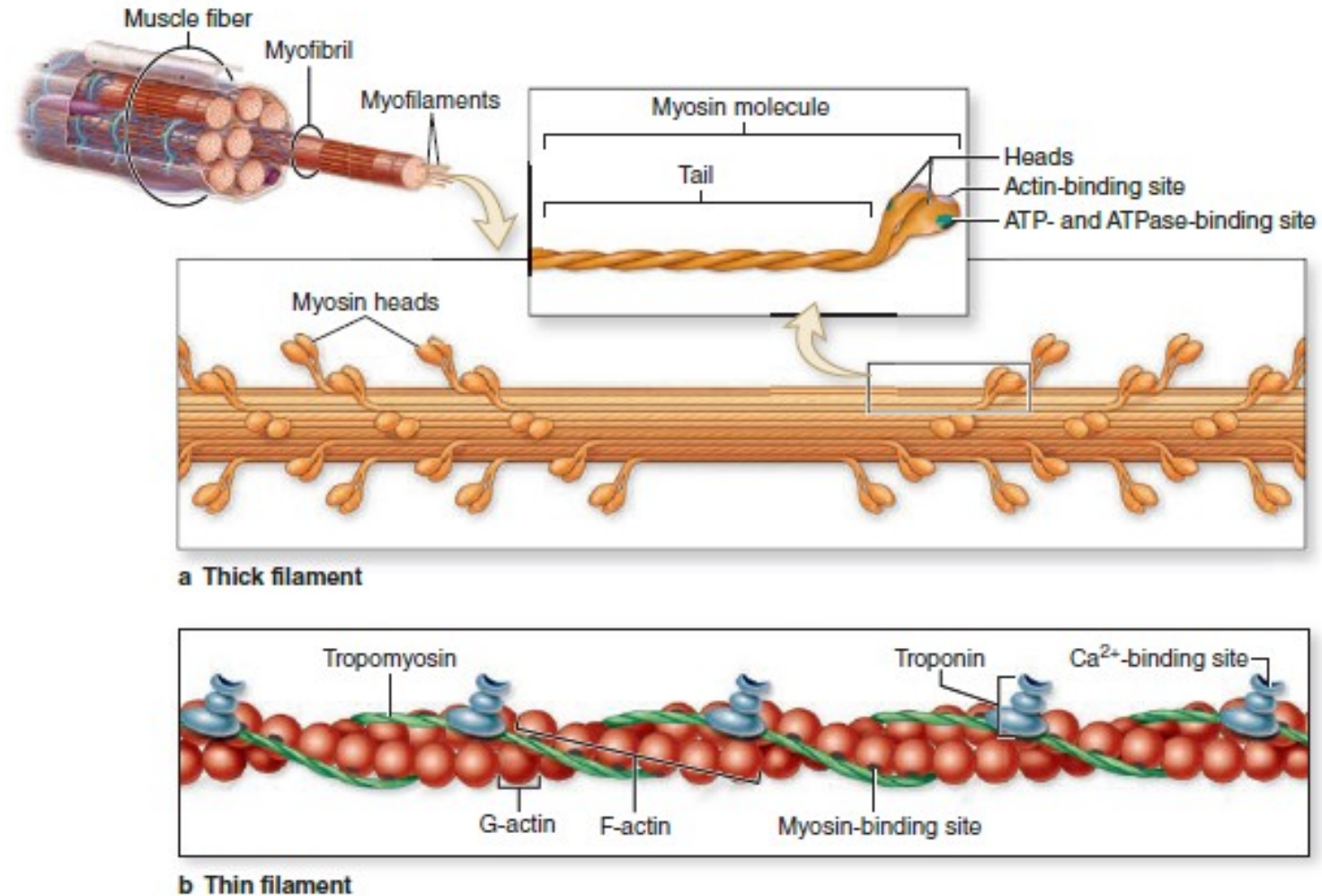
**FIGURE 11.6 ▲ Sarcomeres in different functional stages.**

In the resting state (*middle*), interdigitation of thin (actin) and thick (myosin) filaments is not complete; the H and I bands are relatively wide. In the contracted state (*bottom*), the interdigitation of the thin and thick filaments is increased according to the degree of contraction. In the stretched state (*top*), the thin and thick filaments do not interact; the H and I bands are very wide. The length of the A band always remains the same and corresponds to the length of the thick filaments; the lengths of the H and I bands change, again in proportion to the degree of sarcomere relaxation or contraction. The cross-sections through different regions of the sarcomere are also shown (*from left to right*): through thin filaments of the I band; through thick filaments of the H band; through the center of the A band where adjacent thick filaments are linked to form the M line; and through the A band, where thin and thick filaments overlap. Note that each thick filament is within the center of a hexagonal array of thin filaments.



# MUSCLE TISSUE

FIGURE 10-7 Molecules composing thin and thick filaments.



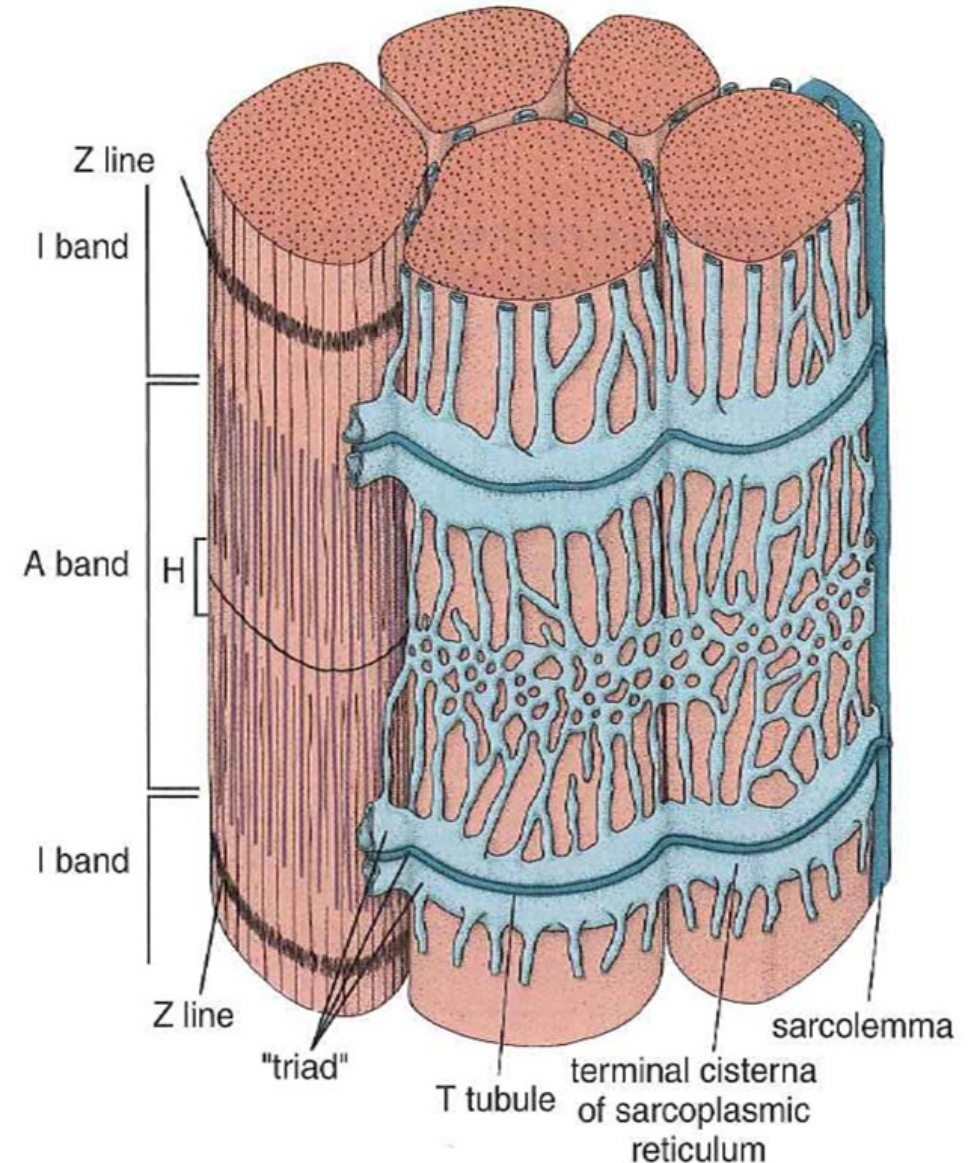
**Myofilaments**, which include both thick and thin filaments, consist of contractile protein arrays bundled within myofibrils. **(a)** A thick

myofilament contains 200-500 molecules of **myosin**. **(b)** A thin filament contains **F-actin**, **tropomyosin**, and **troponin**.

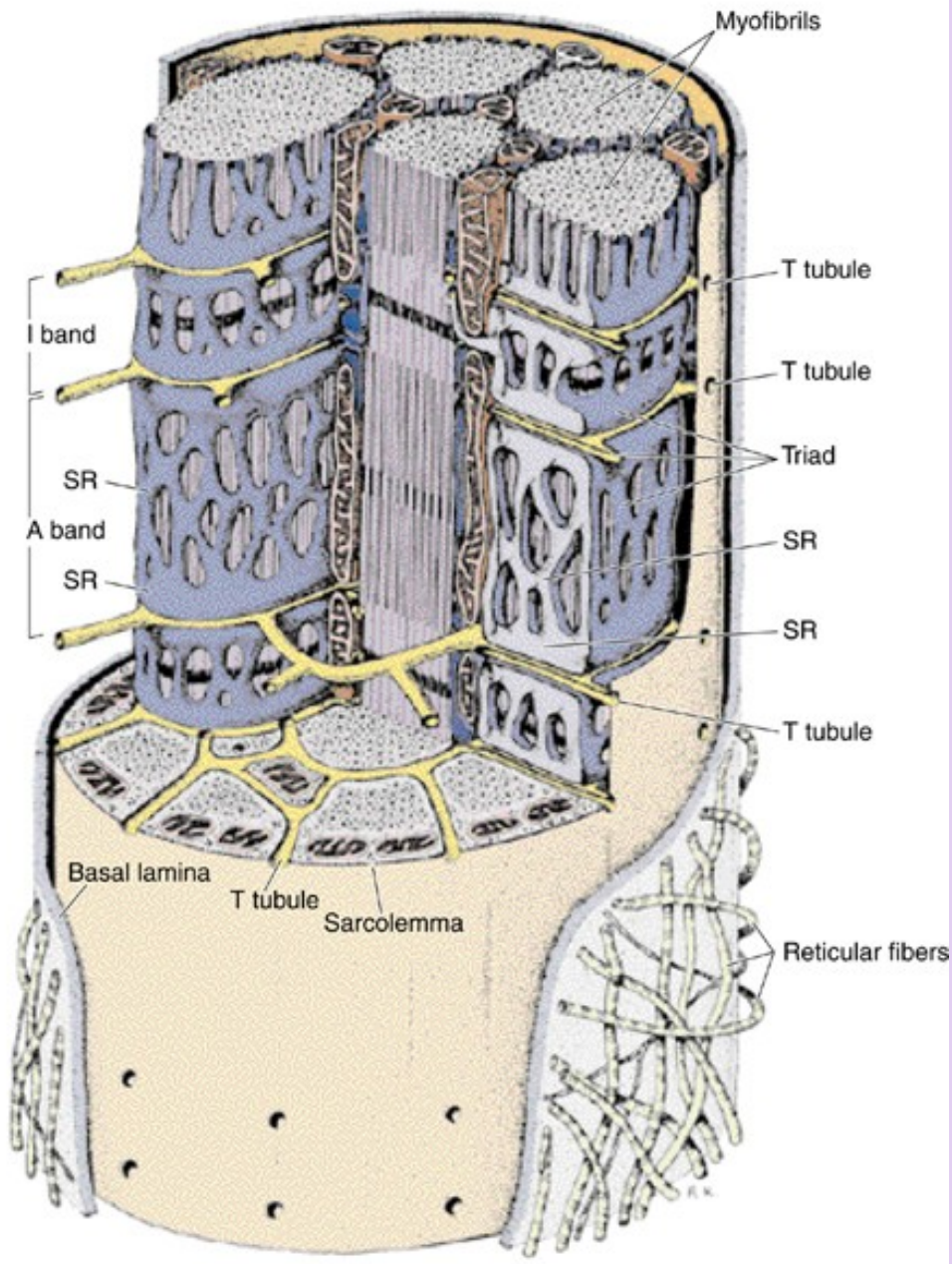
# MUSCLE TISSUE

## Coordination of skeletal muscle fiber contraction

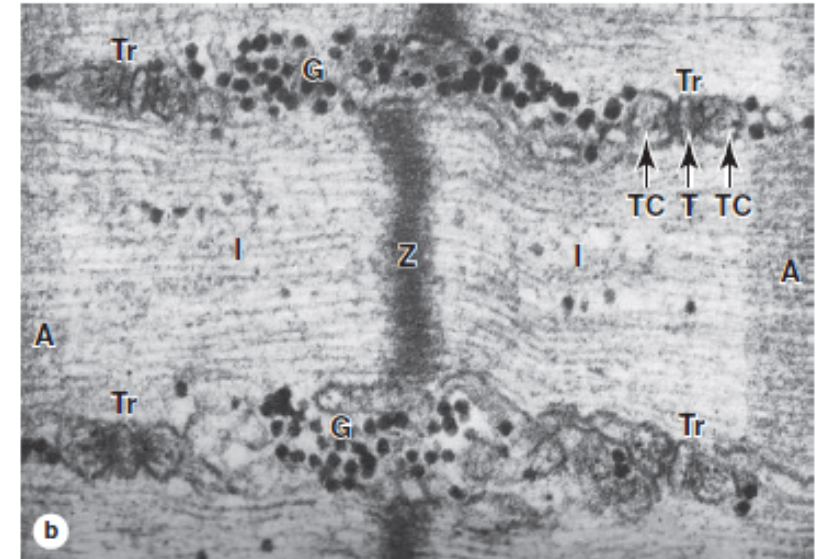
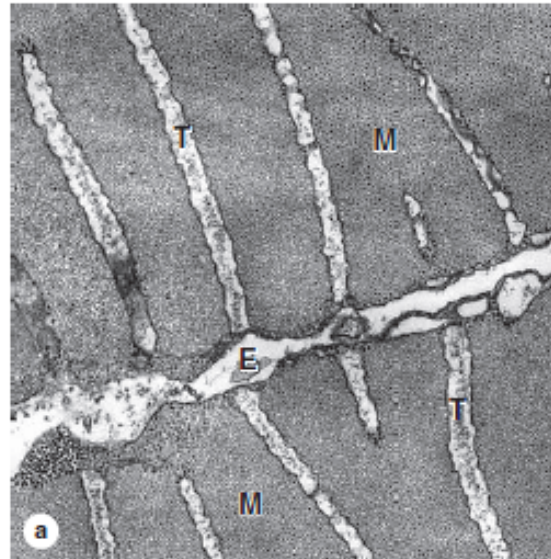
- A complex system of intracellular, membranous structures called **the triad** ensures coordinated contraction throughout the muscle fiber by:
  - Allowing the nervous impulse to penetrate and simultaneously reach all parts of the muscle fiber.
  - Releasing calcium in response to the nervous impulse.
- Triads. Composed of **one T-tubule** plus **two adjacent terminal cisterns** of the sarcoplasmic reticulum.
  - T-tubules are invaginations of the sarcolemma that occur at the junction between A and I bands of the myofibrils.
  - Terminal cisterns are expanded portions of the sarcoplasmic reticulum that lie adjacent to the T tubule and release calcium to initiate contraction.







**FIGURE 10-10** Transverse tubule system and triads.



Transverse tubules are invaginations of the sarcolemma that penetrate deeply into the muscle fiber around all myofibrils.

**(a)** TEM cross section of fish muscle shows portions of two fibers and the endomysium (E) between them. Several transverse or T-tubules (T) are shown, perpendicular to the fiber surface, penetrating between myofibrils (M). (X50,000)

**(b)** Higher-magnification TEM of skeletal muscle in longitudinal section shows four membranous triads (Tr) cut transversely near the A-band-I-band junctions. Each triad consists of a central

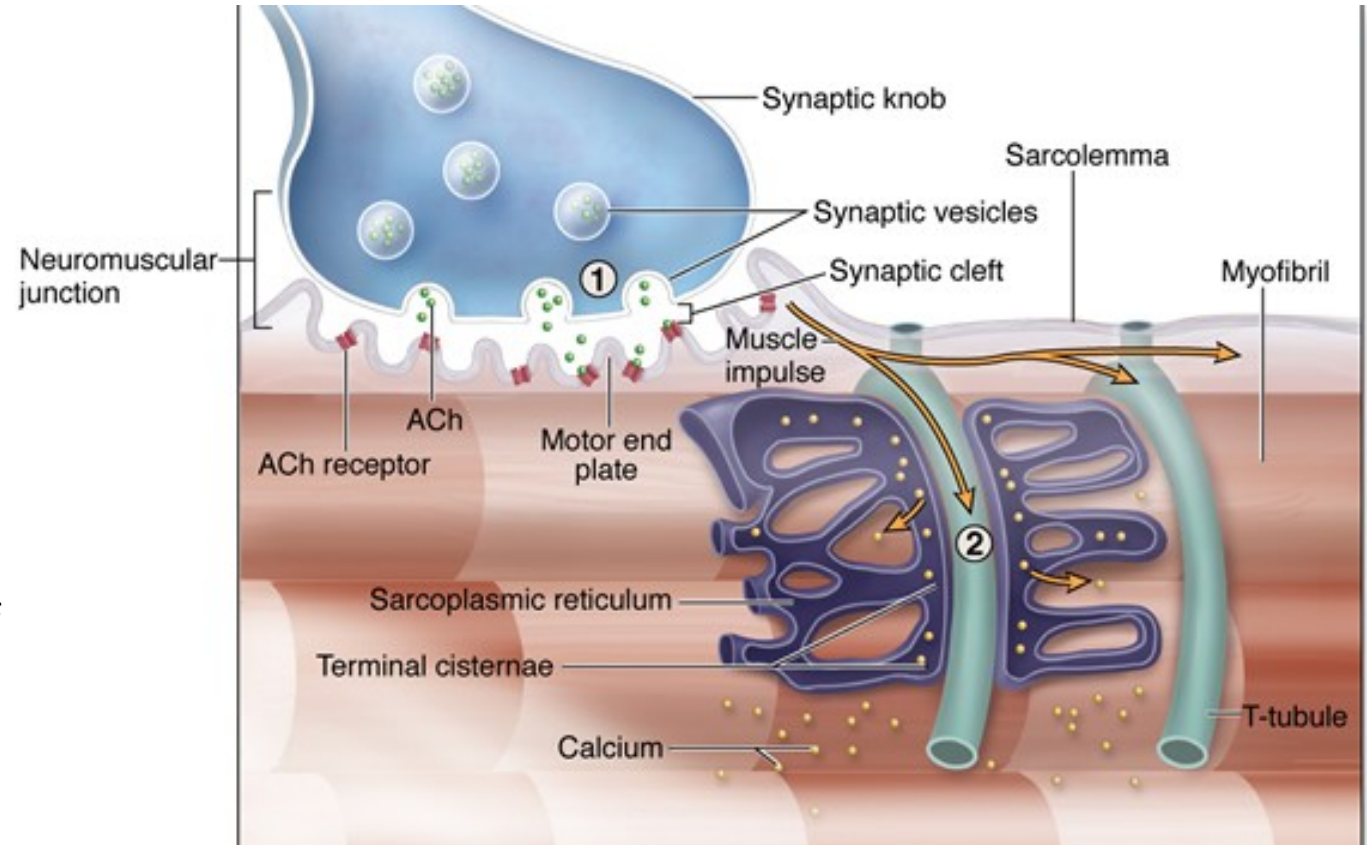
transverse tubule (T) and two adjacent terminal cisternae (TC) extending from the sarcoplasmic reticulum. Centrally located is the Z disc. Besides elements of the triad, sarcoplasm surrounding the myofibril also contains dense glycogen granules (G).

Components of the triad are responsible for the cyclic release of  $\text{Ca}^{2+}$  from the cisternae and its sequestration again which occurs during muscle contraction and relaxation. The association between SR cisternae and T-tubules is shown diagrammatically in Figure 10-11. (X90,000)

# MUSCLE TISSUE

## Coordination of skeletal muscle fiber contraction

- Role of triad in muscle contraction
  - A nerve impulse arriving at the muscle fiber depolarizes the sarcolemma at the neuromuscular junction.
  - The membrane depolarization propagates along the sarcolemma and extends down the T-tubules.
  - T-tubule depolarization is transmitted to the terminal cisterns and the remainder of the sarcoplasmic reticulum, causing release of stored calcium.
  - Calcium initiates the interaction between actin and myosin myofilaments, leading to muscle contraction.
  - Calcium is recaptured by sarcoplasmic reticulum during relaxation



① A nerve impulse triggers release of ACh from the synaptic knob into the synaptic cleft. ACh binds to ACh receptors in the motor end plate of the neuromuscular junction, initiating a muscle impulse in the sarcolemma of the muscle fiber.

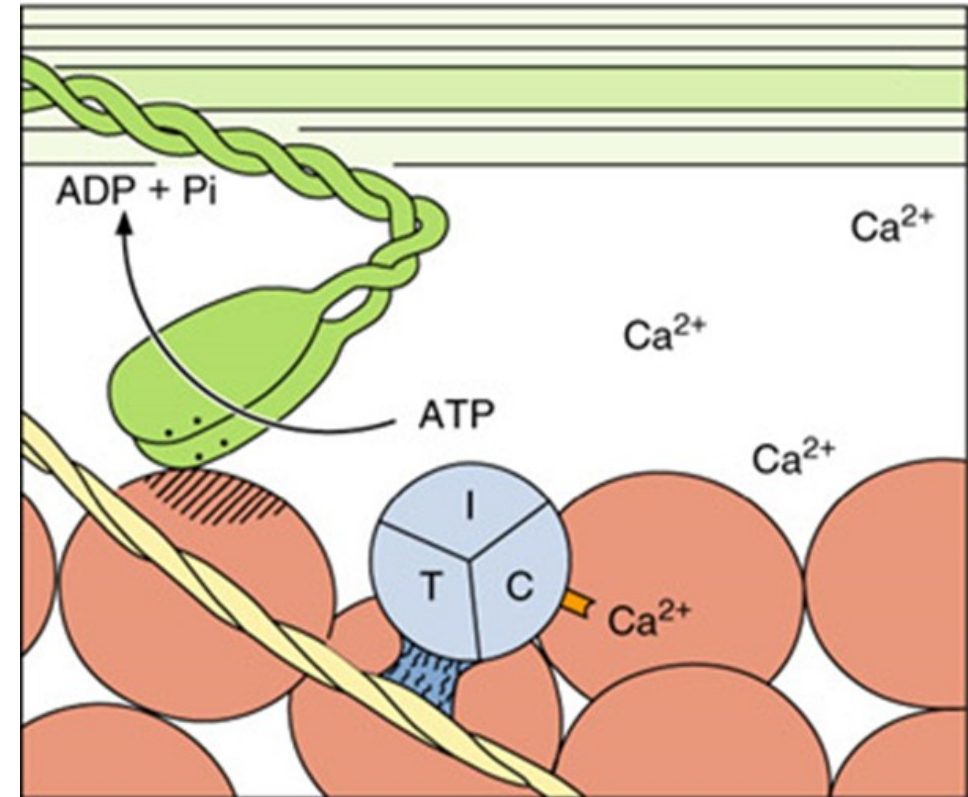
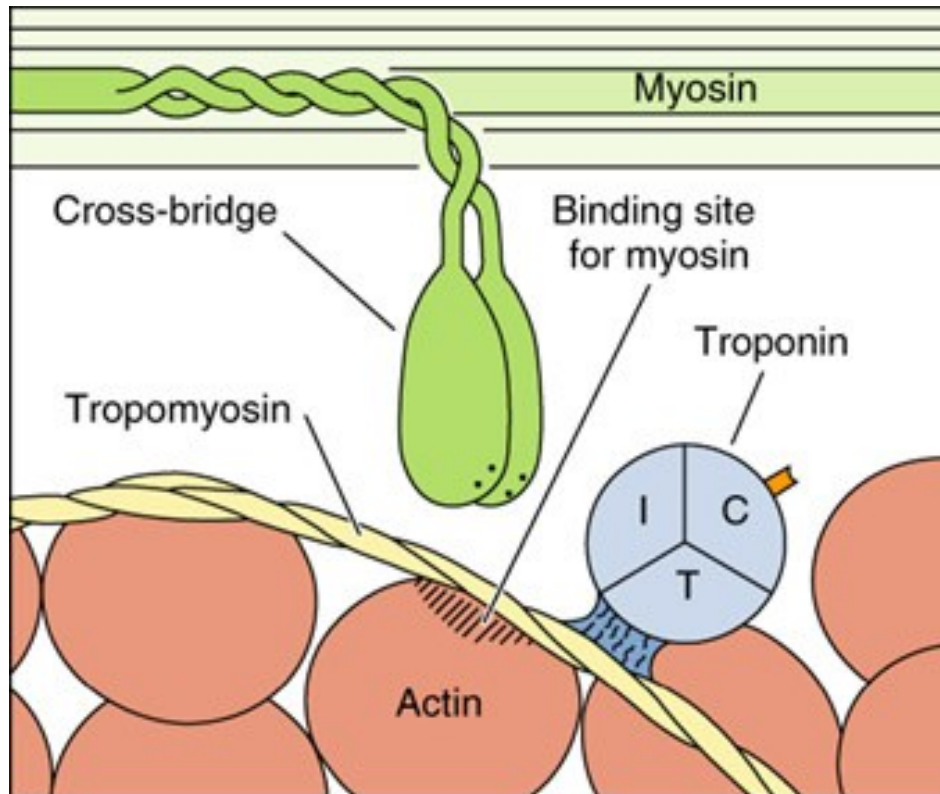
② As the muscle impulse spreads quickly from the sarcolemma along T tubules, calcium ions are released from terminal cisternae into the sarcoplasm.



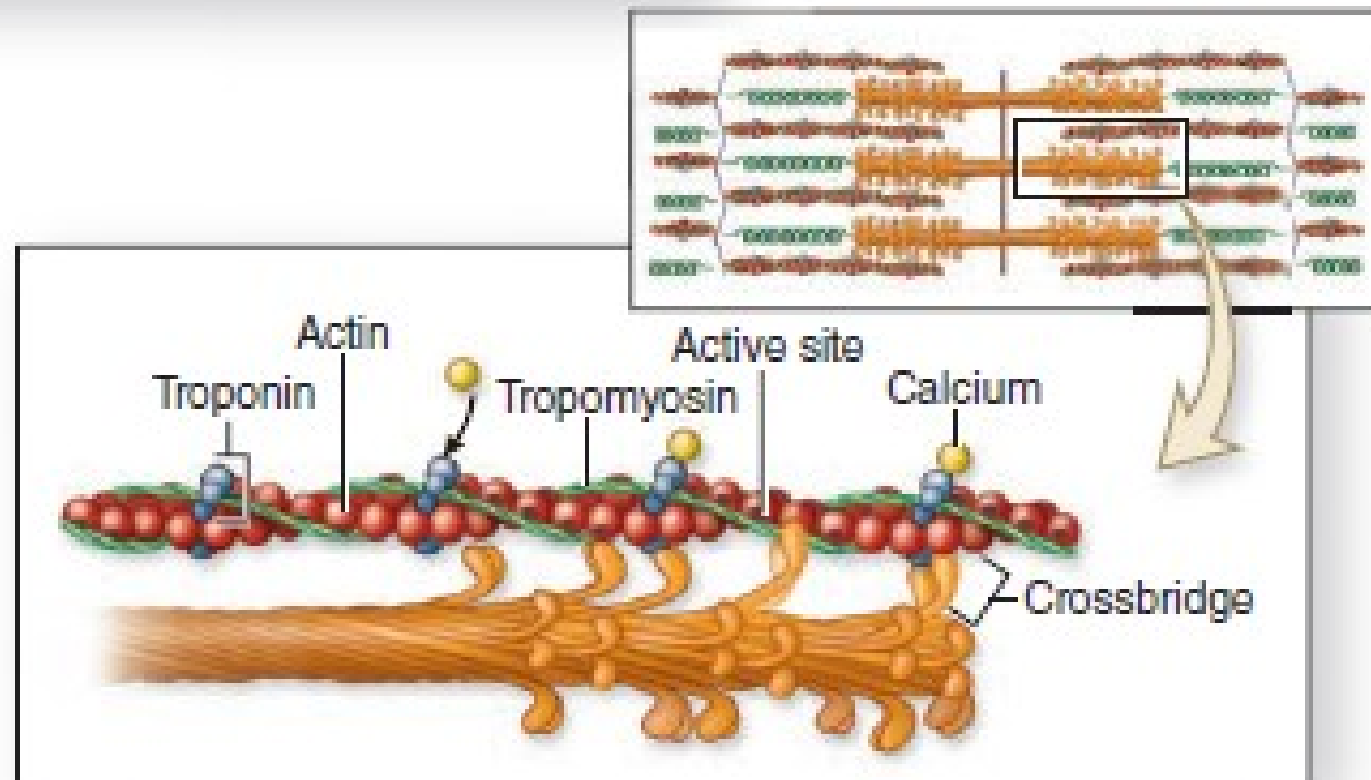
# MUSCLE TISSUE

## Mechanism of contraction, sliding filament model

- Increased calcium concentration triggers the initiation of contraction by allowing the myosin head groups to contact the actin myofilaments.
- A conformation change of the myosin head groups associated with the hydrolysis of ATP and the release of ADP results in a sliding of the actin myofilament past the myosin. Since the actin filaments are anchored at the Z line, the result of the sliding is shortening of the sarcomere.



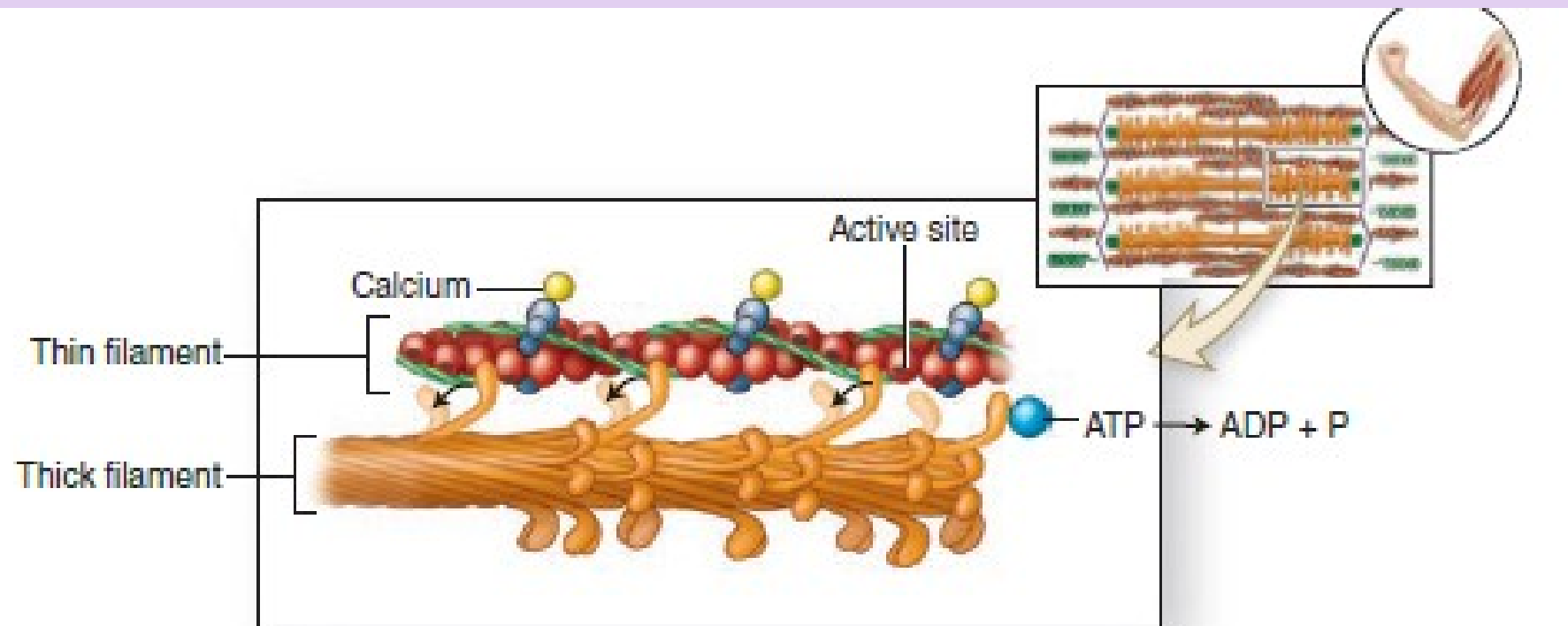
# MUSCLE TISSUE



- ③ Calcium ions bind to troponin. Troponin changes shape, moving tropomyosin on the actin to expose active sites on actin molecules of thin filaments. Myosin heads of thick filaments attach to exposed active sites to form crossbridges.

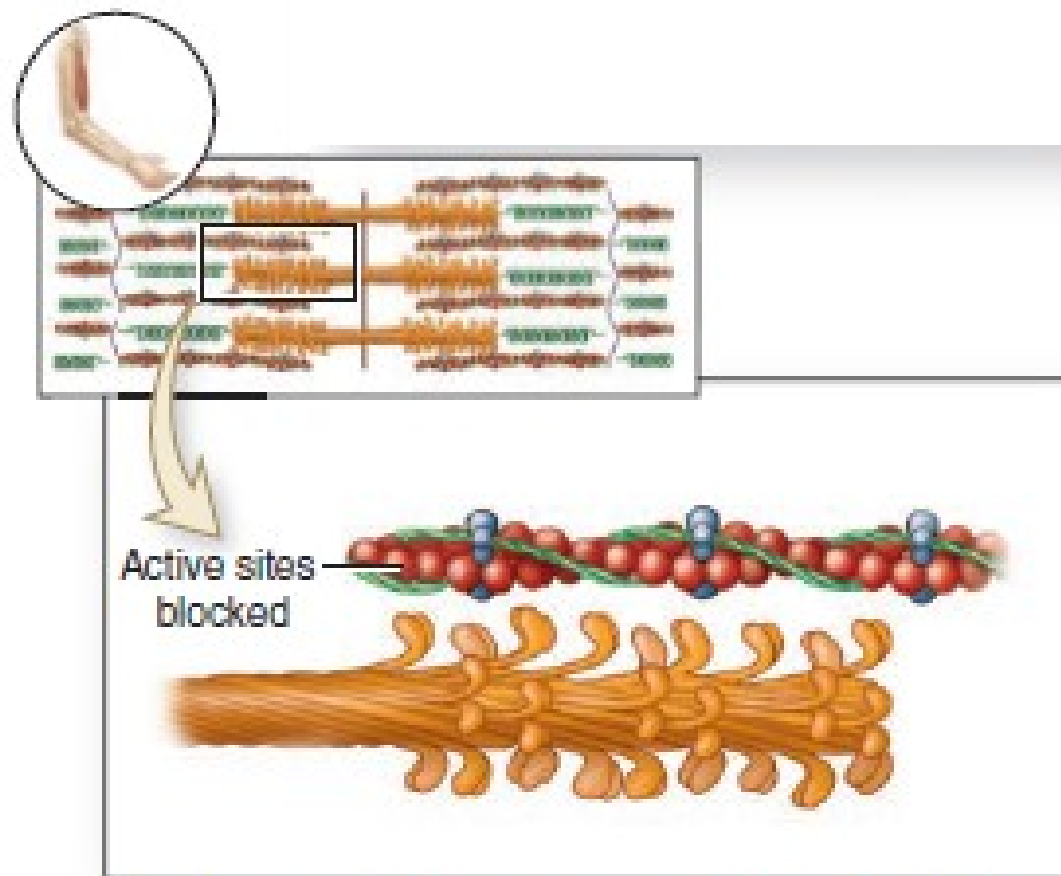


# MUSCLE TISSUE



- ④ Myosin heads pivot, moving thin filaments toward the sarcomere center. ATP binds myosin heads and is broken down into ADP and P. Myosin heads detach from thin filaments and return to their prepivot position. The repeating cycle of *attach-pivot-detach-return* slides thick and thin filaments past one another. The sarcomere shortens and the muscle contracts. The cycle continues as long as calcium ions remain bound to troponin to keep active sites exposed.

# MUSCLE TISSUE

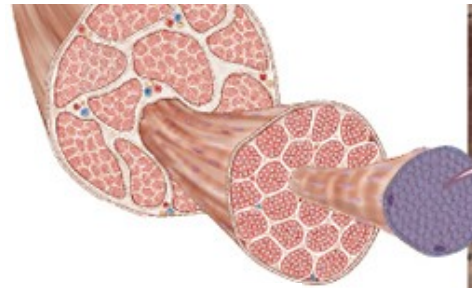


- ⑤ When the impulse stops, calcium ions are actively transported into the sarcoplasmic reticulum, tropomyosin re-covers active sites, and filaments passively slide back to their relaxed state.

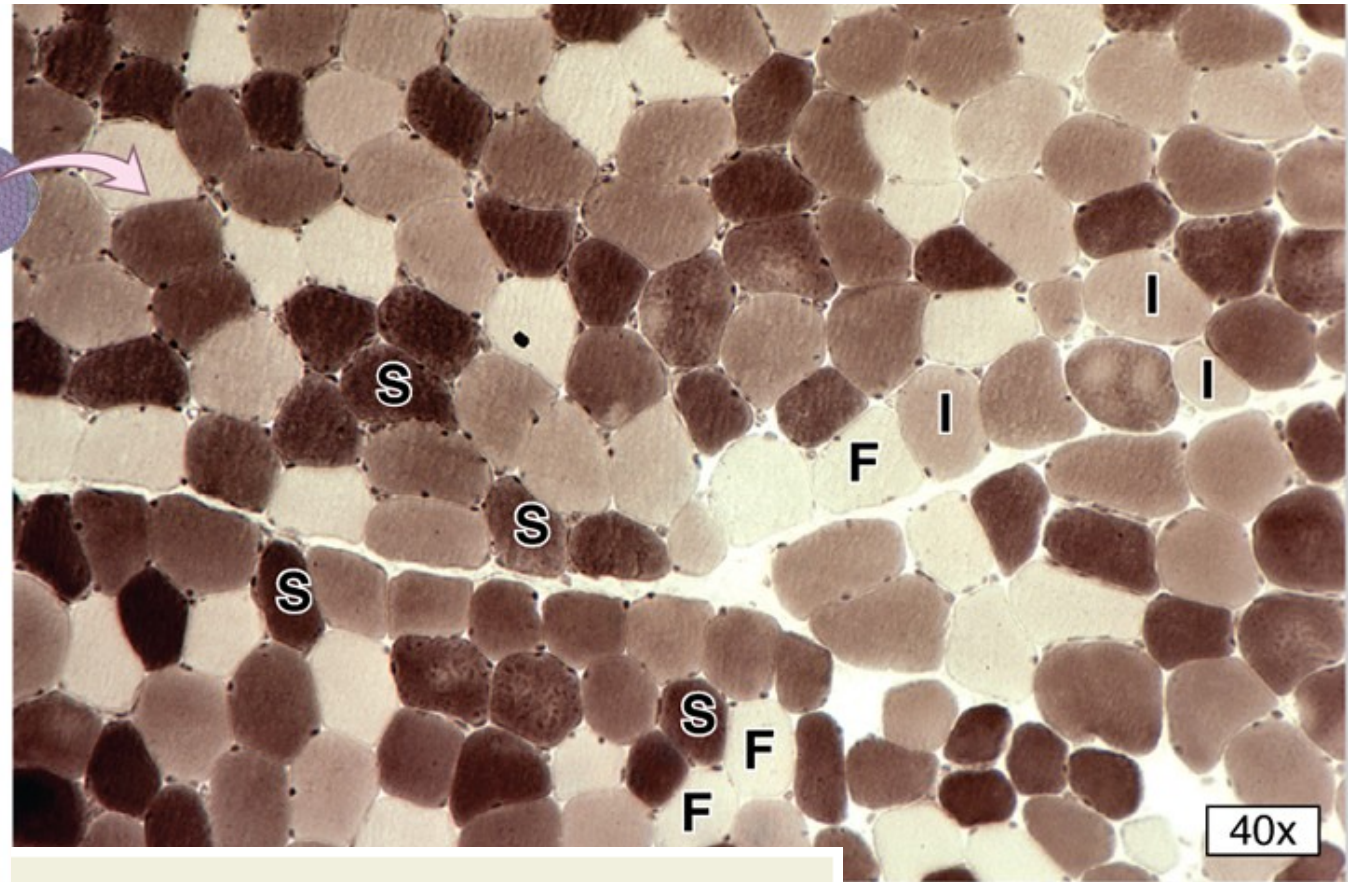


# MUSCLE TISSUE

## Skeletal muscle fibers types:



- **Slow oxidative** muscle fibers are adapted for slow contractions over long periods without fatigue, having many mitochondria, many surrounding capillaries, and much myoglobin, all features that make fresh tissue rich in these fibers dark or red in color.
- **Fast glycolytic** fibers are specialized for rapid, short-term contraction, having few mitochondria or capillaries and depending largely on anaerobic metabolism of glucose derived from stored glycogen, features which make such fibers appear white. Rapid contractions lead to rapid fatigue as lactic acid produced by glycolysis accumulates.
- **Fast oxidative-glycolytic** fibers have physiological and histological features intermediate between those of the other two types.



Cross section of a skeletal muscle stained histochemically for myosin ATPase at acidic pH, which reveals activity of the "slow" ATPase and shows the distribution of the three main fiber types. Slow oxidative (SO) or type I fibers have high levels of acidic ATPase activity and stain the darkest. Fast glycolytic (FG) or type IIb fibers stain the lightest. Fast oxidative-glycolytic (FOG) or type IIa fibers are intermediate between the other two types (X40). ATPase histochemistry of unfixed, cryostat section, pH 4.2.

S = SO; F = FG; I = FOG

**TABLE 10-2****Major characteristics of skeletal muscle fiber types.**

	Slow, Oxidative Fibers (Type I)	Fast, Oxidative-Glycolytic Fibers (Type IIa)	Fast, Glycolytic Fibers (Type IIb)
Mitochondria	Numerous	Numerous	Sparse
Capillaries	Numerous	Numerous	Sparse
Fiber diameter	Small	Intermediate	Large
Size of motor unit	Small	Intermediate	Large
Myoglobin content	High (red fibers)	High (red fibers)	Low (white fibers)
Glycogen content	Low	Intermediate	High
Major source of ATP	Oxidative phosphorylation	Oxidative phosphorylation	Anaerobic glycolysis
Glycolytic enzyme activity	Low	Intermediate	High
Rate of fatigue	Slow	Intermediate	Fast
Myosin-ATPase activity	Low	High	High
Speed of contraction	Slow	Fast	Fast
Typical major locations	Postural muscles of back	Major muscles of legs	Extraocular muscles

# MUSCLE TISSUE

## Associated structures

- **Neuromuscular junction (motor end plate)**
  - Specialized "synapse" between the terminals of a motor axon and the sarcolemma of a muscle fiber
  - Motor unit. Consists of the motor neuron, its axon, and all the muscle fibers it innervates

Before it terminates in a skeletal muscle, each motor axon bundled in the nerve forms many branches, each of which forms a synapse with a muscle fiber.

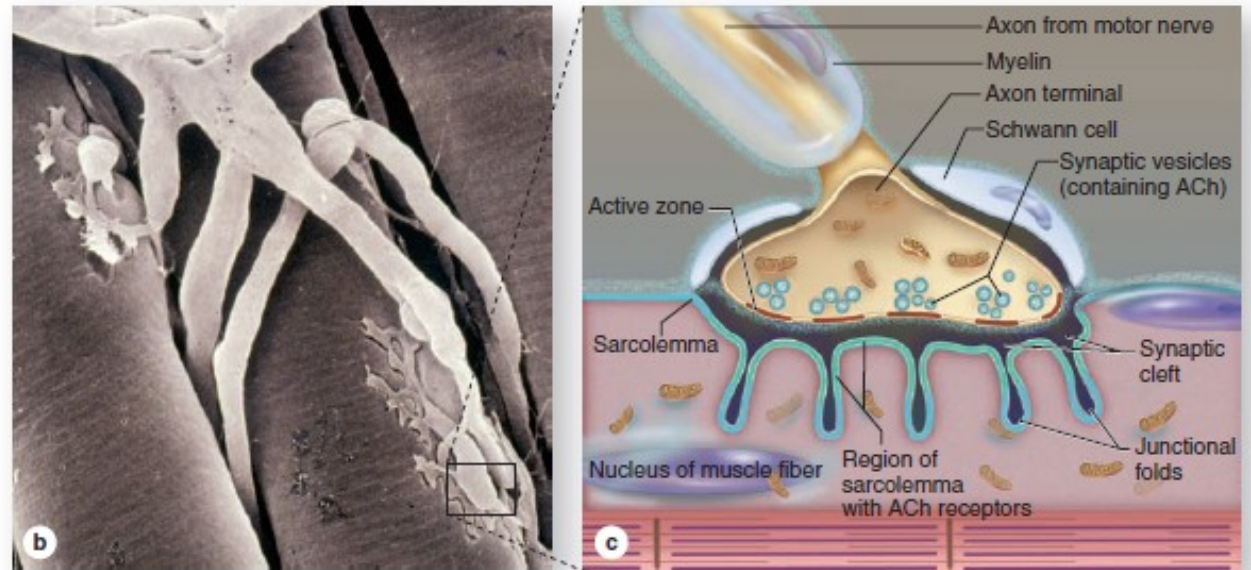
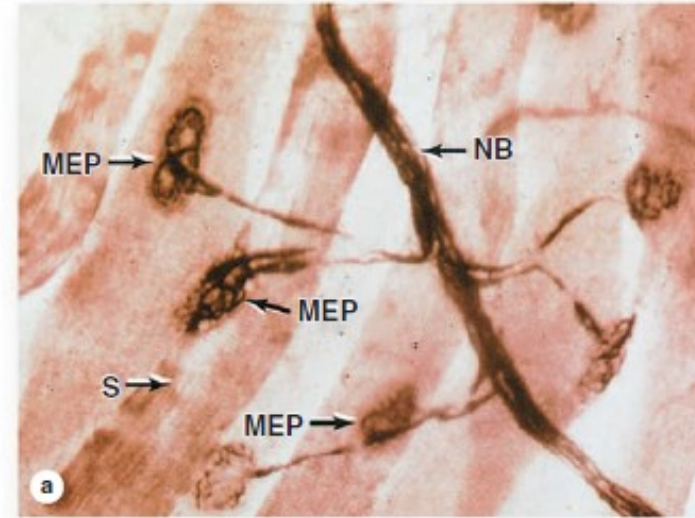
(a) Silver staining can reveal the nerve bundle (NB), the terminal axonal twigs, and the motor end plates (MEPs, also called neuromuscular junctions or NMJ) on striated muscle fibers (S). (X1200)

(b) An SEM shows the branching ends of a motor axon, each covered by an extension of the last Schwann cell and expanded

terminally as an MEP embedded in a groove in the external lamina of the muscle fiber.

(c) Diagram of enclosed portion of the SEM indicating key features of a typical MEP: synaptic vesicles of acetylcholine (ACh), a synaptic cleft, and a postsynaptic membrane. This membrane, the sarcolemma, is highly folded to increase the number of ACh receptors at the MEP. Receptor binding initiates muscle fiber depolarization, which is carried to the deeper myofibrils by the T-tubules.

FIGURE 10-13 The neuromuscular junction (NMJ).





# MUSCLE TISSUE

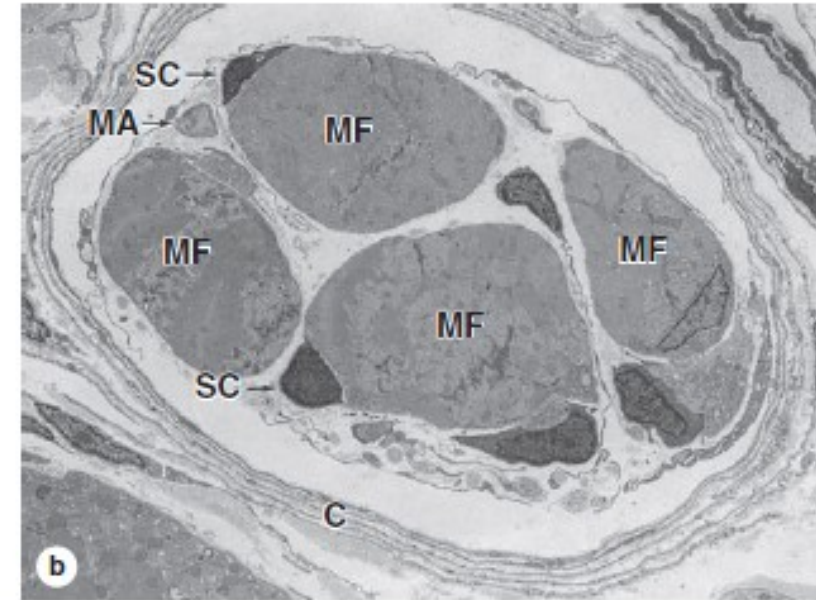
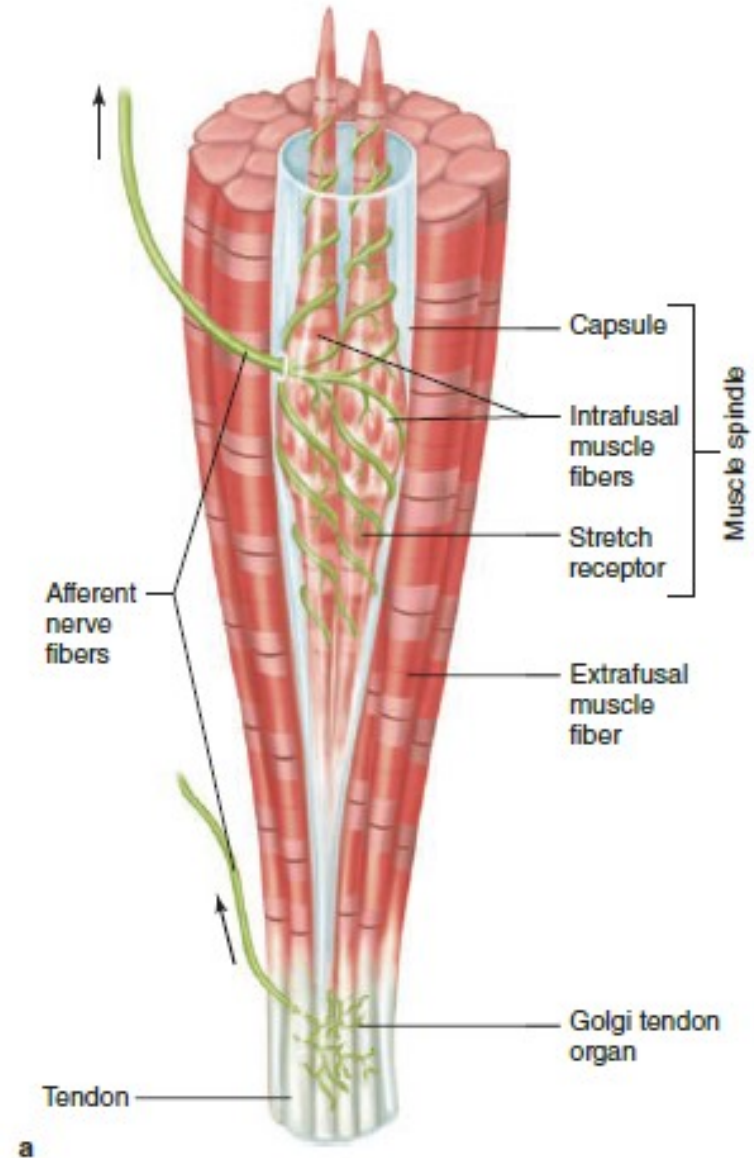
## Associated structures

- **Proprioceptors**

- Sensory receptors, encapsulated by connective tissue, serve to regulate muscle tension and tone.

- **Types:**

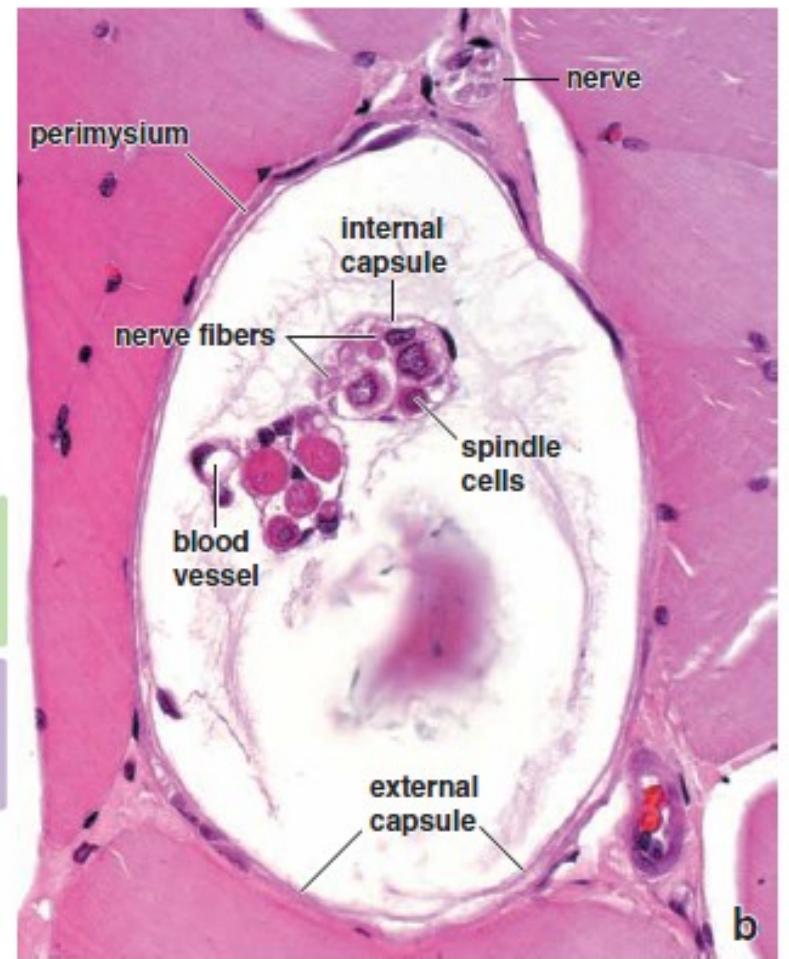
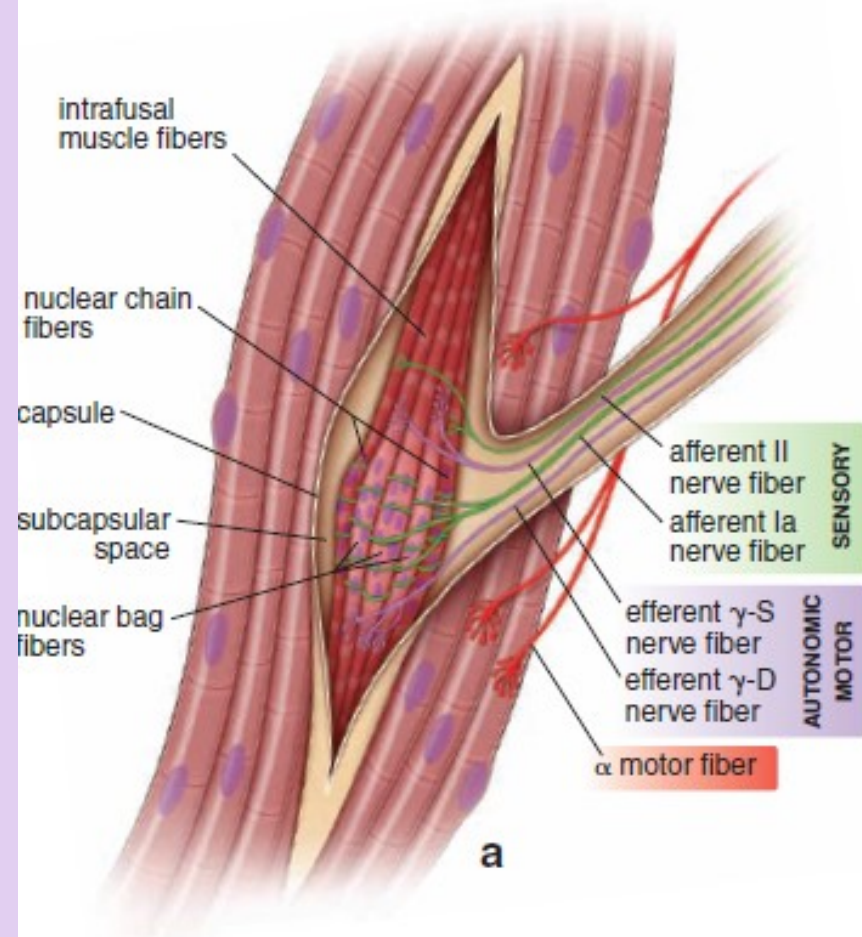
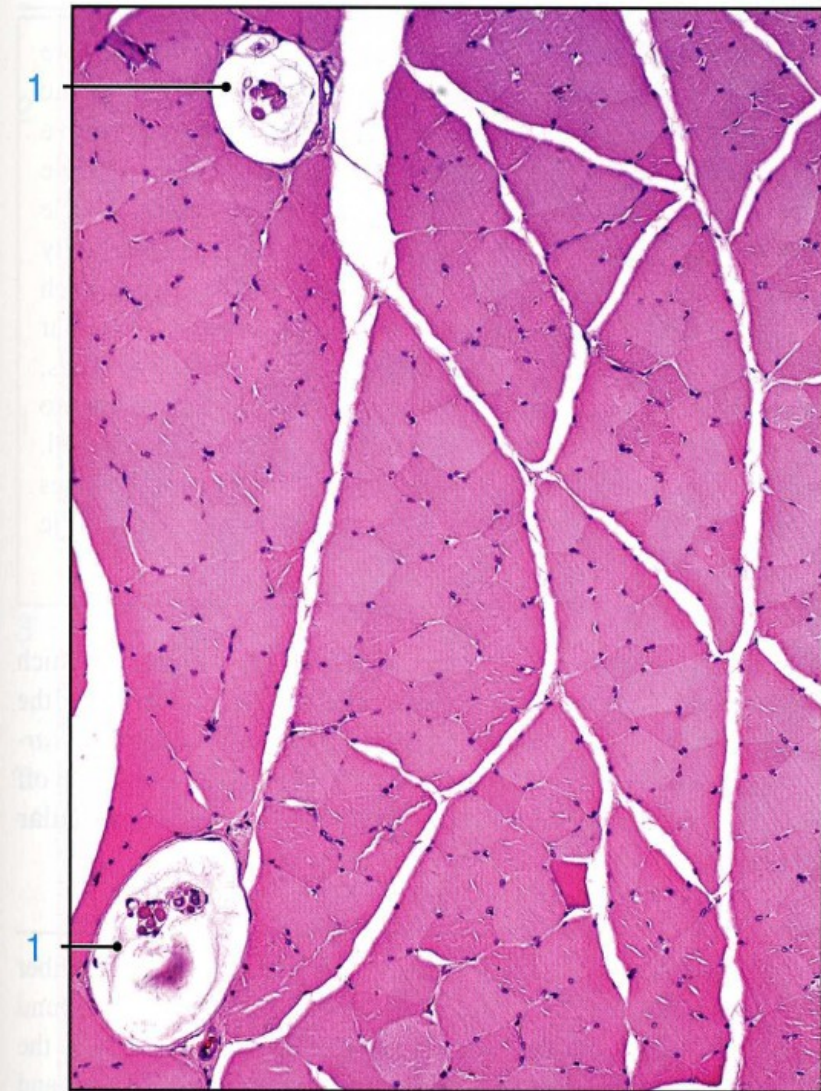
- **Muscle spindle.** Highly modified skeletal muscle fibers, intra-fusal fibers, are aligned with and surrounded by normal skeletal muscle fibers.
- **Golgi tendon organs.** Located within tendons



(a) The diagram shows both a **muscle spindle** and a **tendon organ**. Muscle spindles have **afferent sensory** and efferent motor nerve fibers associated with the **intrafusal fibers**, which are modified muscle fibers. The size of the spindle is exaggerated relative to the extrafusal fibers to show better the nuclei packed in the intrafusal fibers. Both types of sensory receptors provide the CNS with information concerning degrees of stretch and tension within the musculoskeletal system.

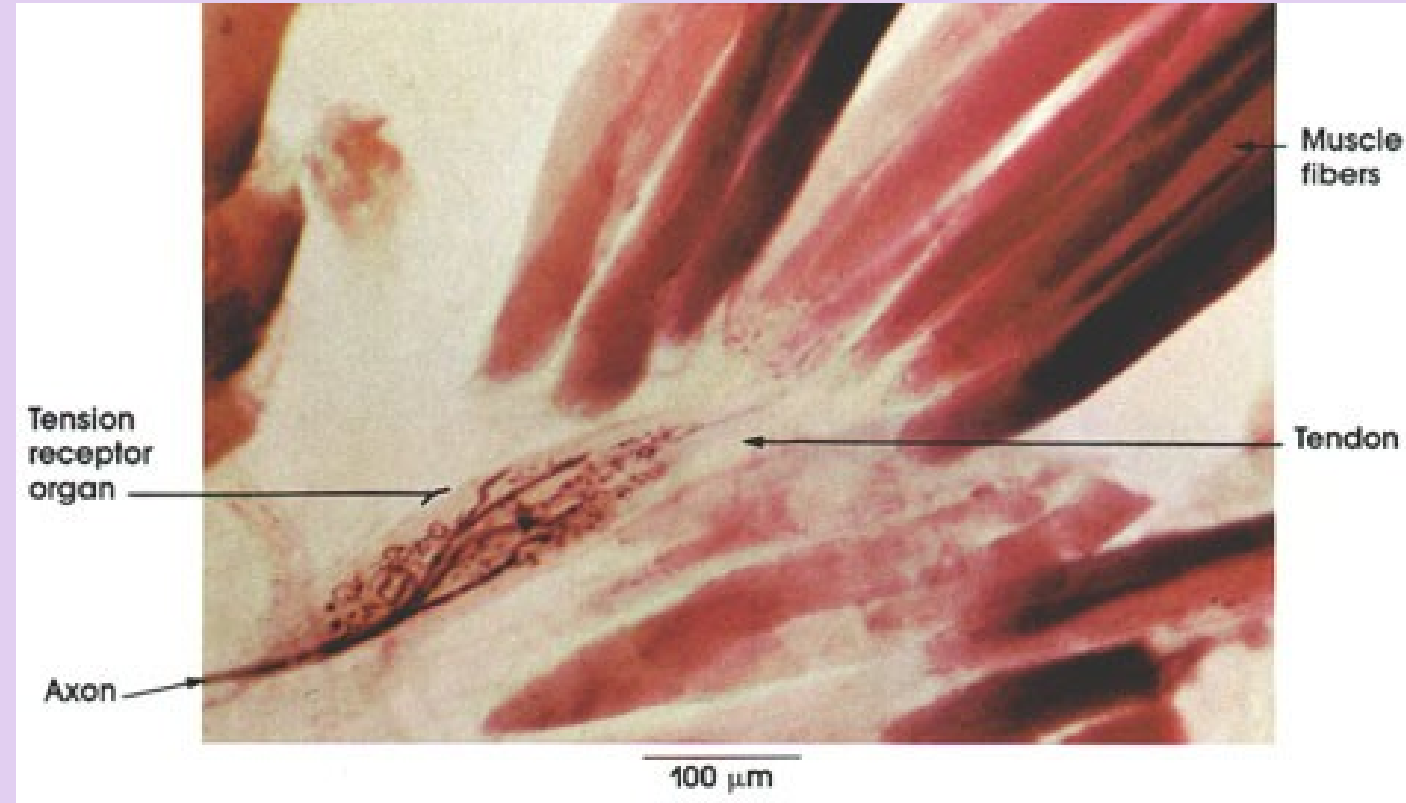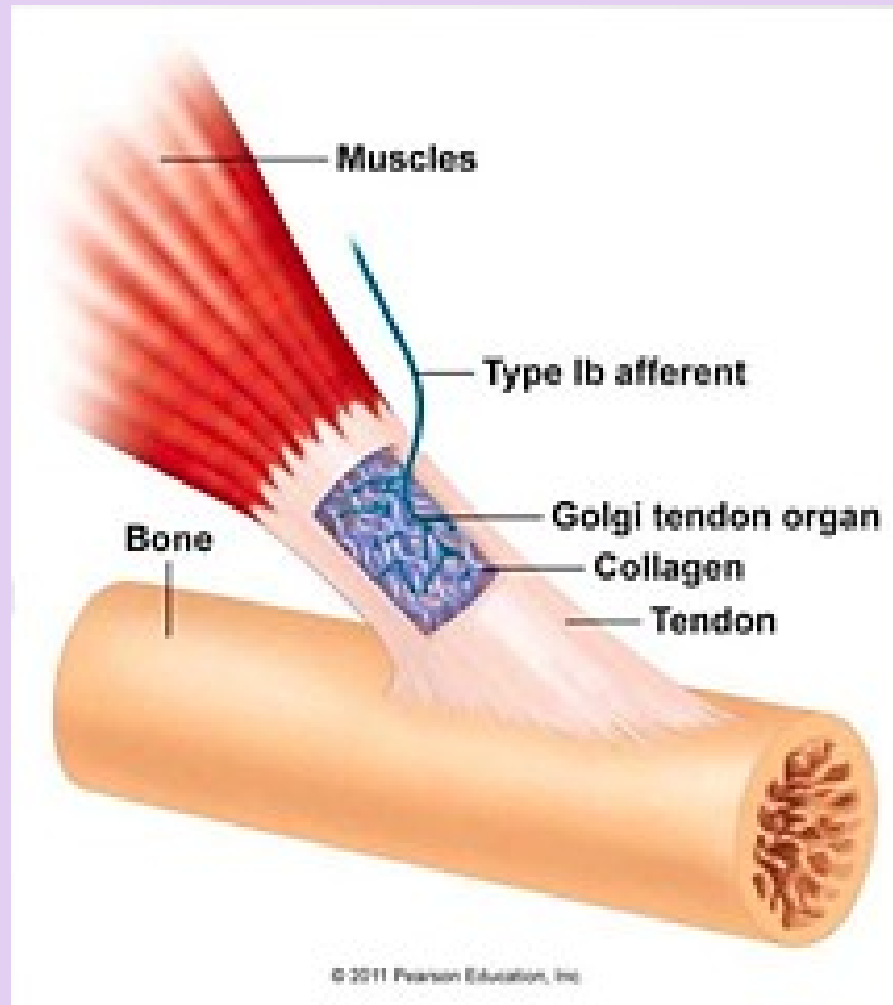
(b) A TEM cross section near the end of a muscle spindle shows the capsule (C), lightly myelinated axons (MA) of a sensory nerve, and the intrafusal muscle fibers (MF). These thin fibers differ from the ordinary skeletal muscle fibers in having very few myofibrils. Their many nuclei can either be closely aligned (nuclear chain fibers) or piled in a central dilation (nuclear bag fibers). Muscle satellite cells (SC) are also present within the external lamina of the intrafusal fibers. (X3600)





**FIGURE 11.16 ▲ Muscle spindle.** **a.** Schematic diagram of a muscle spindle. The diameter of the spindle is expanded to illustrate structural details. Each spindle contains approximately two to four nuclear bag fibers and six to eight nuclear chain fibers. In the nuclear bag fibers, the muscle fiber nuclei are clumped in the expanded central portion of the fiber, hence the name *bag*. In contrast, the nuclei concentrated in the central portion of the nuclear chain fibers are arranged in a chain. Both afferent II and Ia (sensory) and  $\gamma$  efferent (motor) nerve fibers supply muscle spindle cells. The afferent nerve fibers respond to excessive stretching of the muscle, which in turn inhibits the somatic motor stimulation of the muscle. The efferent nerve fibers regulate the sensitivity of the afferent endings in the muscle spindle. **b.** Photomicrograph of a cross-section of a muscle spindle, showing two bundles of spindle cells in the encapsulated, fluid-filled receptor. In one bundle, several of the spindle cells are cut at the level that reveals their nuclei. An internal capsule surrounds the spindle cells. The external capsule of the muscle spindle and the adjacent perimysium can be seen as a faint double-layer boundary of the receptor. Immediately above and outside of the muscle spindle is a nerve that may be supplying the spindle. The several types of nerves associated with the spindle cells as well as the type of spindle cells cannot be distinguished in this H&E-stained section. Near one of the bundles of spindle cells is a small blood vessel. The flocculent material within the capsule consists of precipitated proteoglycans and glycoproteins from the fluid that filled the spindle before fixation.  $\times 550$ .







# MUSCLE TISSUE

## CARDIAC MUSCLE

- Cardiac muscle occurs only in the myocardium of the heart and, to a variable extent, in the roots of large vessels where they join the heart.
- During embryonic development, the mesoderm cells of the primitive heart tube align into chainlike arrays. No fusion, cardiac muscle cells form complex junctions between extended processes.
- **Structure of cardiac muscle cells**
  - Intermediate in size between skeletal and smooth muscle
  - Cells are cylindrical, branch, and form interwoven bundles.
  - Usually, one nucleus per cell is located in the center.
  - Organelles are clustered at the poles of the nucleus.
  - Myofilament organization into myofibrils is identical to skeletal muscle. **Cross-striations** and bands identical to skeletal muscle are present, but not as prominent.

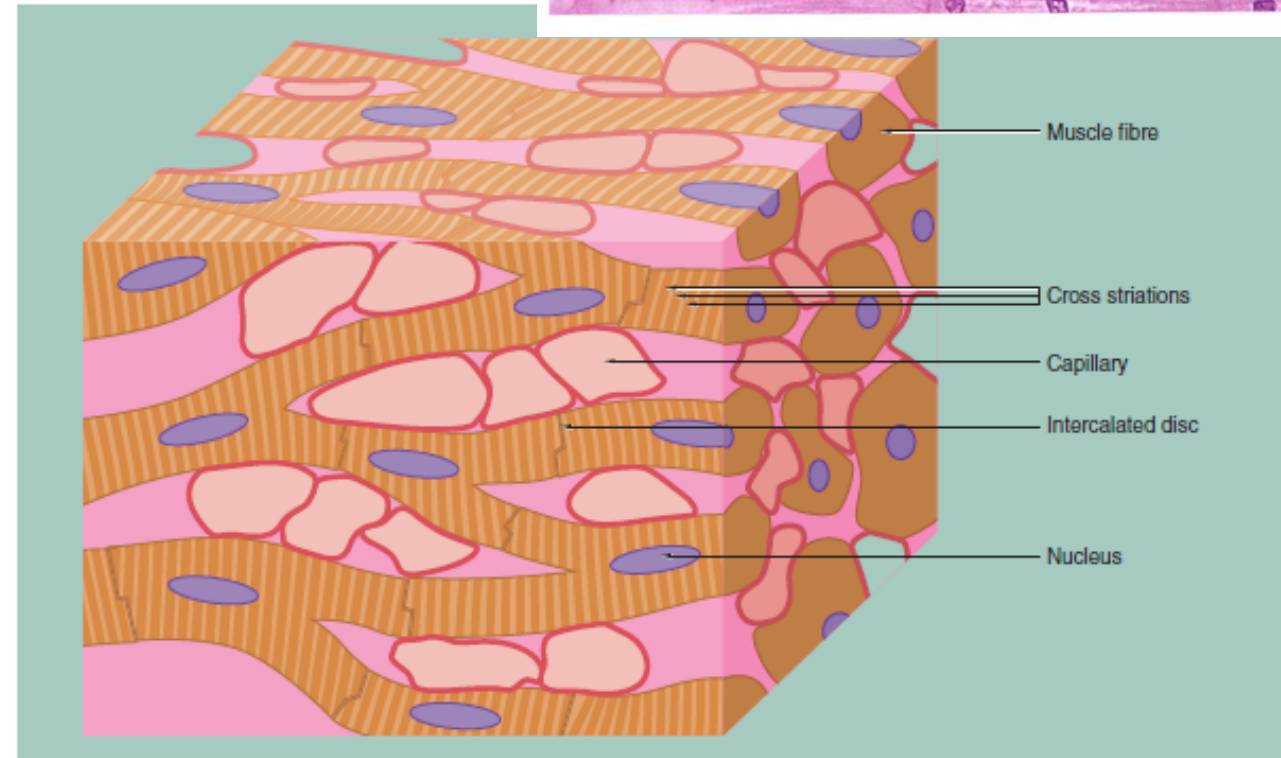
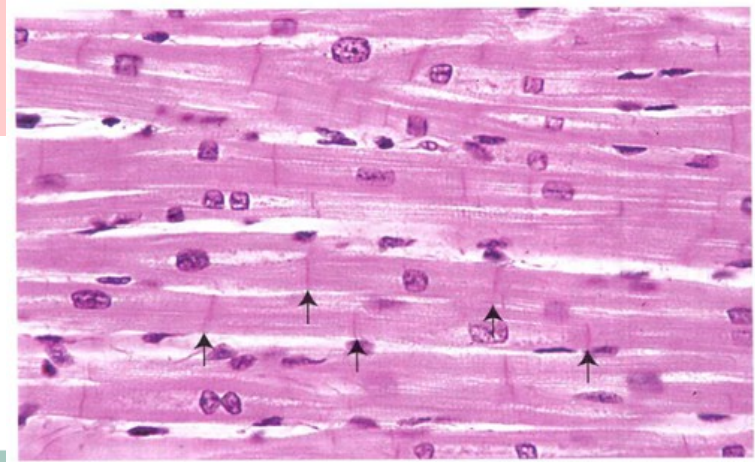


FIG. 6.21 Cardiac muscle

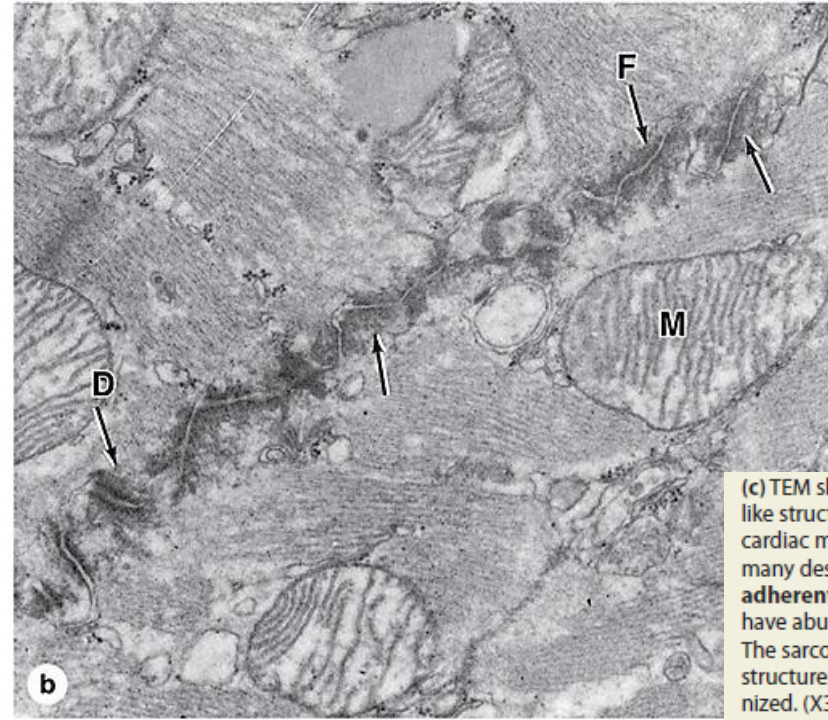
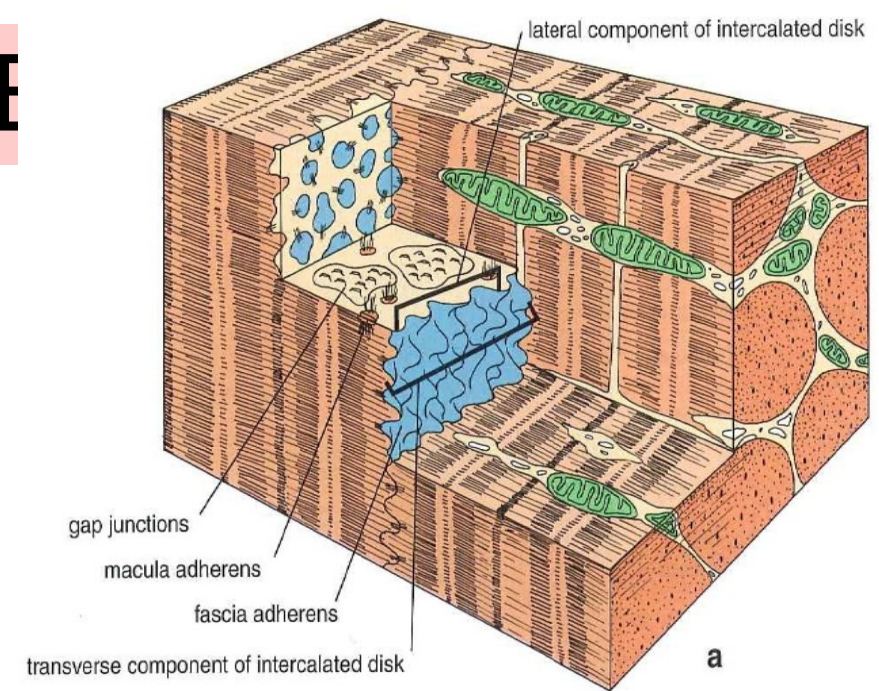
This schematic representation highlights the key features of cardiac muscle. The cardiac myocytes are long, branching cells with central nuclei. The cells are joined together end to end via specialised intercellular junctions termed intercalated discs.

These produce both structural and electrical coupling between the myocytes, allowing them to act as a functional syncytium. There are large numbers of capillaries between the cells, reflecting the high metabolic requirements of cardiac muscle.

# MUSCLE TISSUE

## CARDIAC MUSCLE

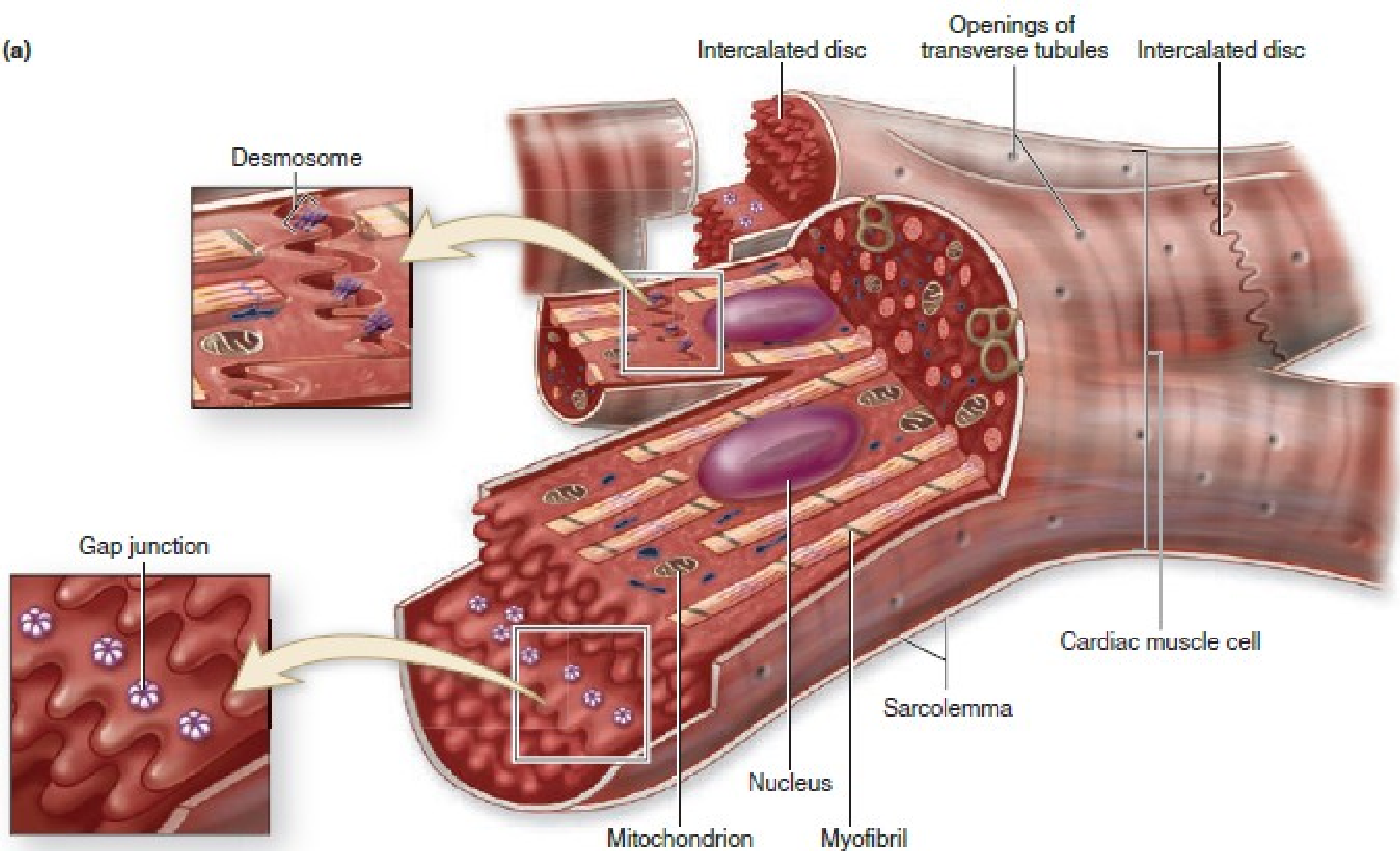
- **Intercalated discs**
  - Junctional complexes that are unique to cardiac muscle cells
  - Consist of specialized cell junctions and interdigitations of the sarcolemma at the ends of the cells.
  - Contain **three types of junctions**:
    - *Fascia adherens*. Similar to zonula adherens of epithelia; serve to attach cardiac muscle fibers and anchor actin filaments of the terminal sarcomeres at the ends of the cell. Acts as a hemi-Z line.
    - *Desmosomes*. Bind ends of fibers together
    - *Gap junctions*. Provide ionic coupling between fibers
- **Highly vascular** with **large numbers of mitochondria** reflecting the high metabolic requirements of cardiac muscle fibers.
- Fibers are capable of hypertrophy but not hyperplasia.

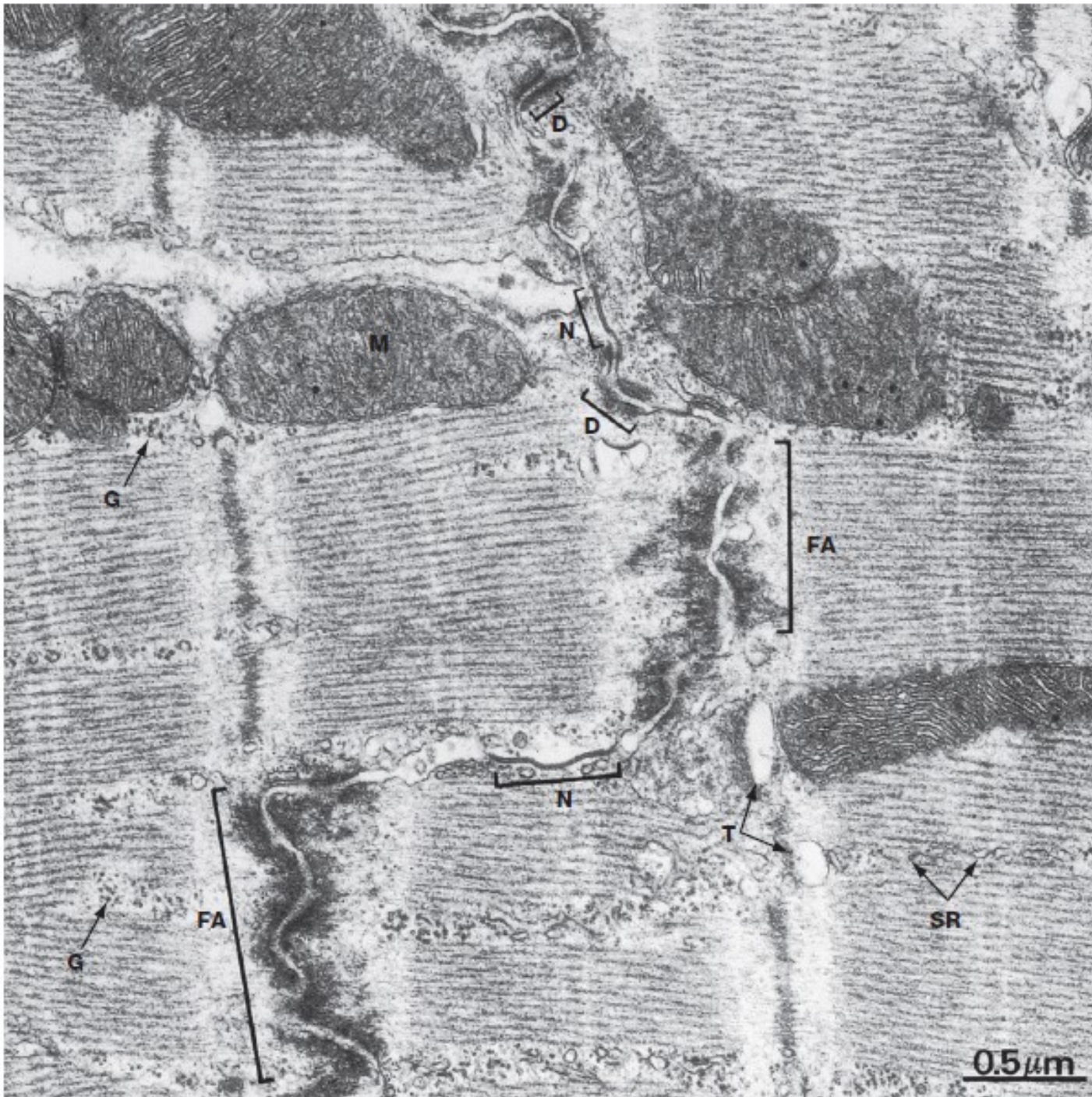


(c) TEM showing an electron-dense intercalated disc with a step-like structure along the short interdigitating processes of adjacent cardiac muscle cells. As shown here transverse disc regions have many desmosomes (D) and adherent junctions called fascia adherentes (F) which join the cells firmly. Other regions of the disc have abundant gap junctions which join the cells physiologically. The sarcoplasm has numerous mitochondria (M) and myofibrillar structures similar to those of skeletal muscle but slightly less organized. (X31,000)



(a)





**FIG. 6.26 Cardiac muscle, intercalated disc, LS**  
EM  $\times 31\ 000$

Intercalated discs are specialised transverse junctions between cardiac muscle cells at sites where they meet end to end; they always coincide with the Z lines. Intercalated discs bind the cells, transmit forces of contraction and provide areas of low electrical resistance for the rapid spread of excitation throughout the myocardium.

The intercalated disc is an interdigitating junction and consists of three types of membrane-to-membrane contact. The predominant type of contact, the *fascia adherens* FA, resembles the *zonula adherens* of epithelial junctional complexes (see Fig. 5.11) but is more extensive and less regular. The actin filaments at the ends of terminal sarcomeres insert into the fasciae adherentes and thereby transmit contractile forces from

cell to cell. *Desmosomes* D occur less frequently and provide anchorage for intermediate filaments of the cytoskeleton. *Gap (nexus) junctions* N (see Fig. 5.12) are present mainly in the longitudinal portions of the interdigitations and are sites of low electrical resistance through which excitation passes from cell to cell.

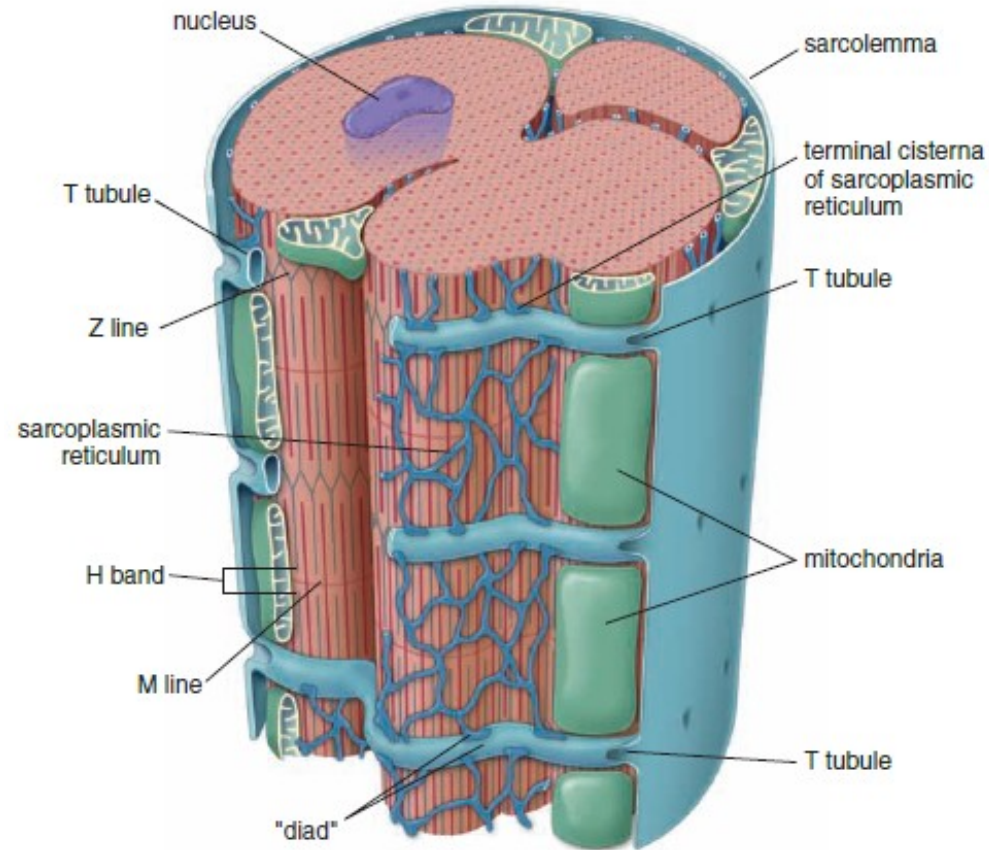
Note the similarity of the sarcomeres of cardiac and skeletal muscle (see Fig. 6.9). The mitochondria M are elongated or spheroidal and have abundant closely packed cristae rich in oxidative enzyme systems. The sarcoplasm within and between the sarcomeres is rich in glycogen granules G. Lace-like profiles of sarcoplasmic reticulum SR and parts of T tubules T can be identified.



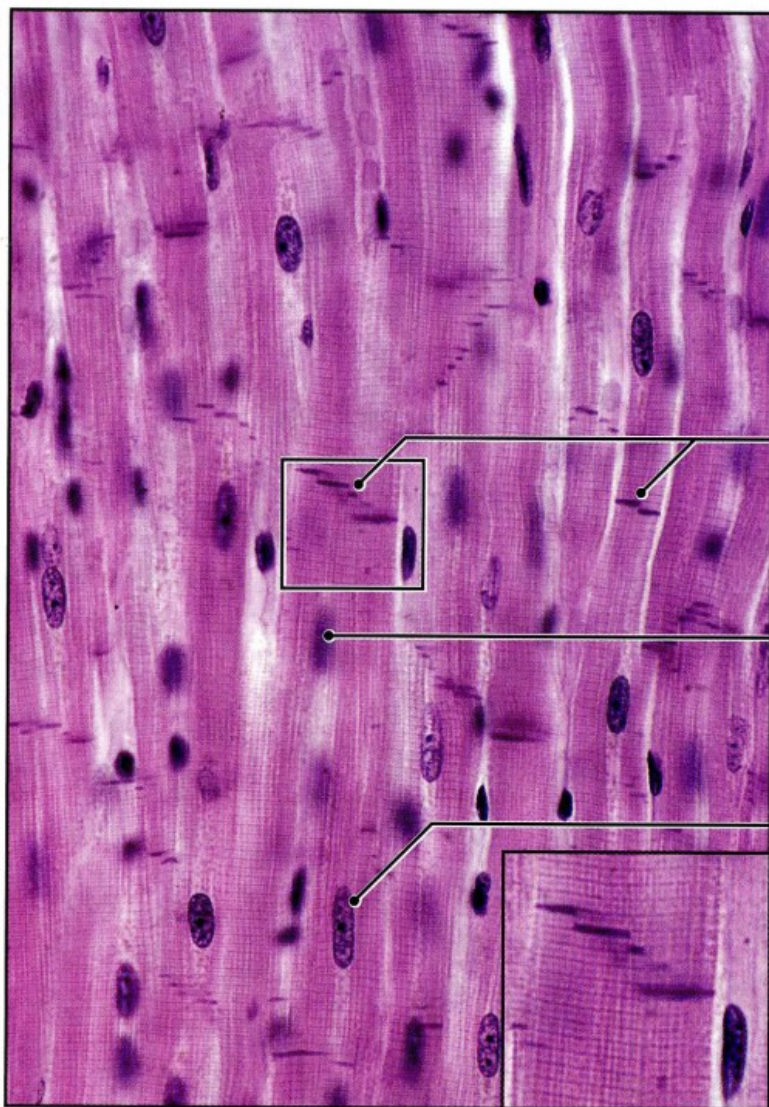
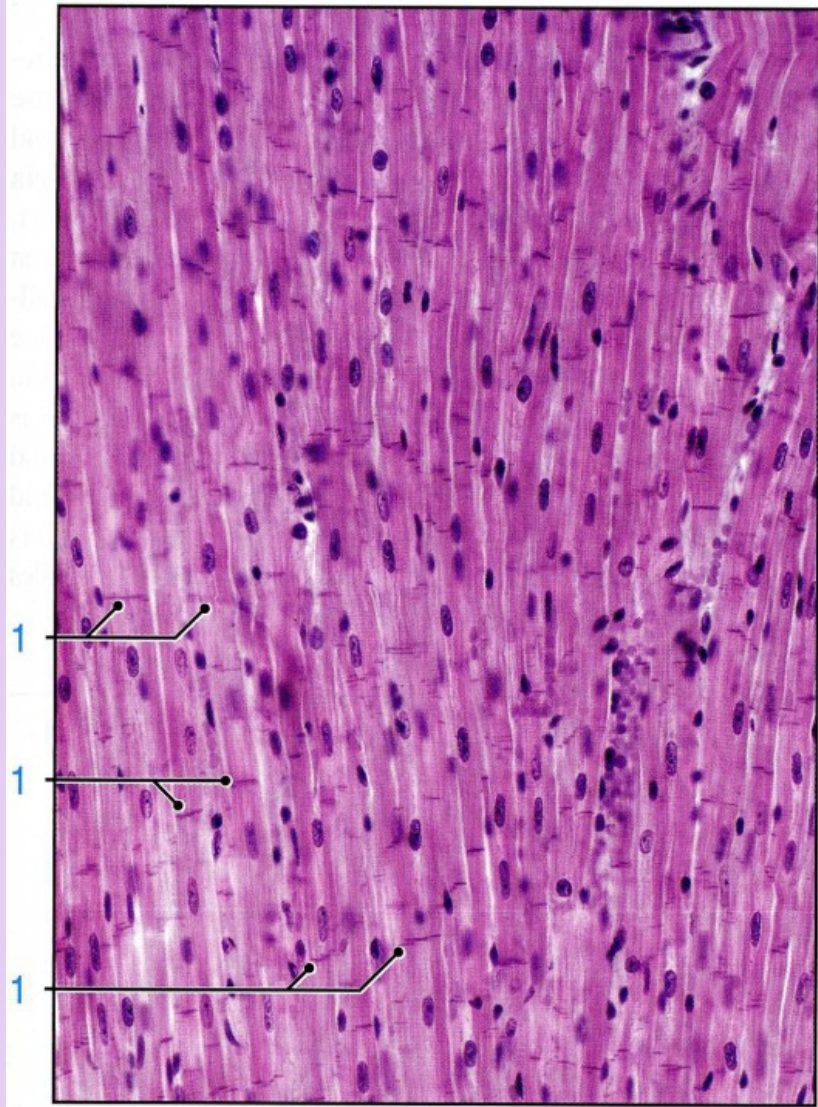
# MUSCLE TISSUE

## CARDIAC MUSCLE

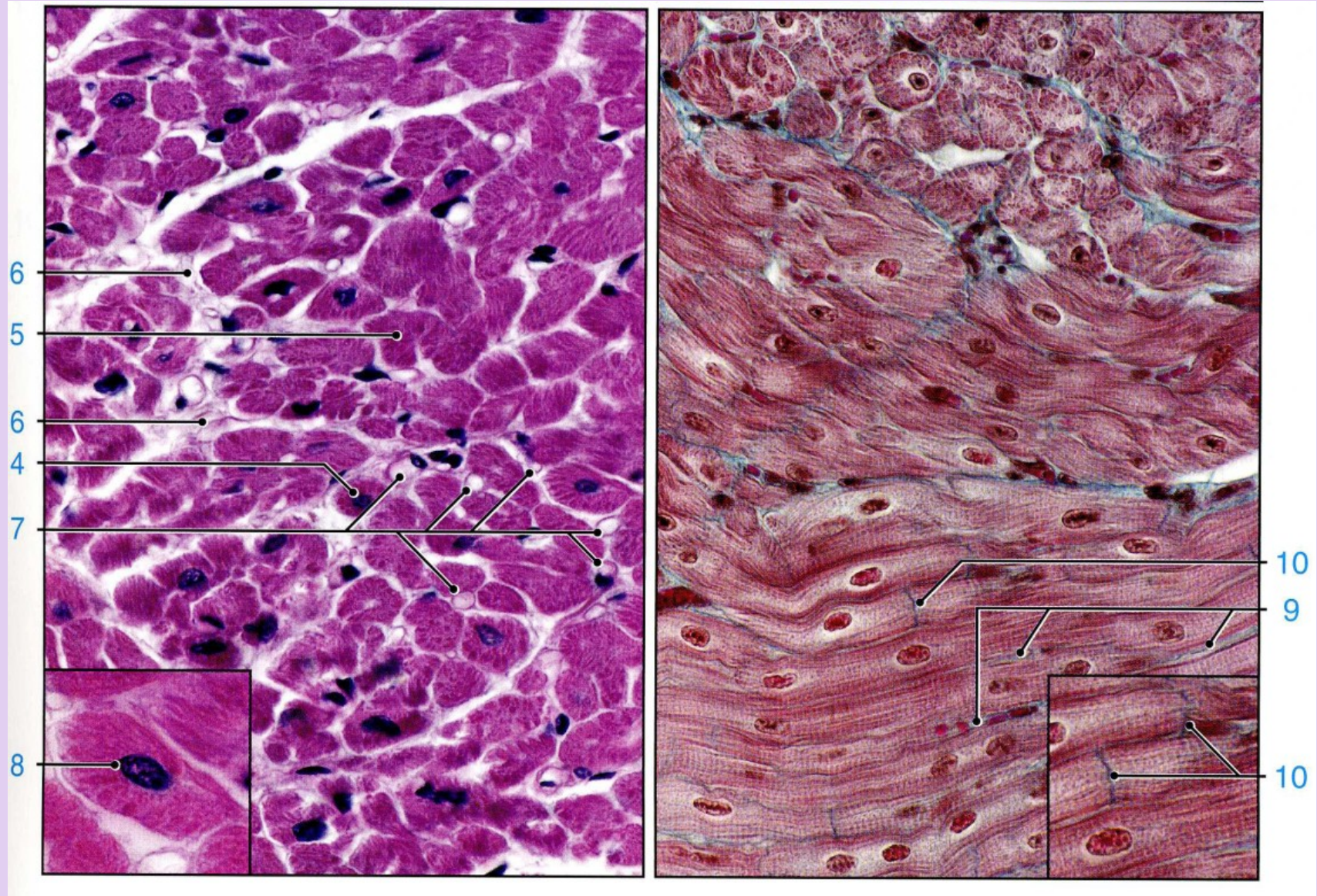
- **Coordination of cardiac muscle contraction**
  - Sarcomeres, myofibrils, and myofilaments are the same as skeletal muscle fibers.
  - T-tubules are located at the level of the Z lines, rather than at junction of A and I bands as in skeletal muscle.
  - No triads. Sarcoplasmic reticulum is not as well developed as in skeletal muscle fibers and does not form terminal cisterns. Contraction is initiated by intracellular calcium release.
  - Contraction can spread through the myocardium due to the presence of gap junctions which allow current to flow from one cell into another. Heart beat is initiated and regulated by specialized conducting cardiac muscle cells.



**FIGURE 11.20** ▲ **Diagram of the organization of cardiac muscle fiber.** The T tubules of cardiac muscle are much larger than the T tubules of skeletal muscle and carry an investment of external lamina material into the cell. They also differ in that they are located at the level of the Z line. The portion of the sarcoplasmic reticulum adjacent to the T tubule is not in the form of an expanded cisterna but rather is organized as a "diad" anastomosing network.





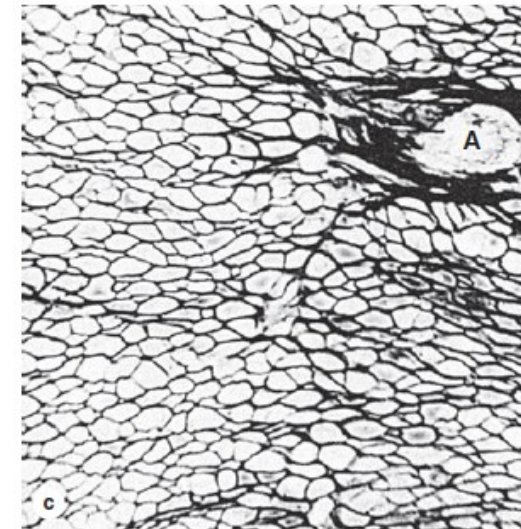
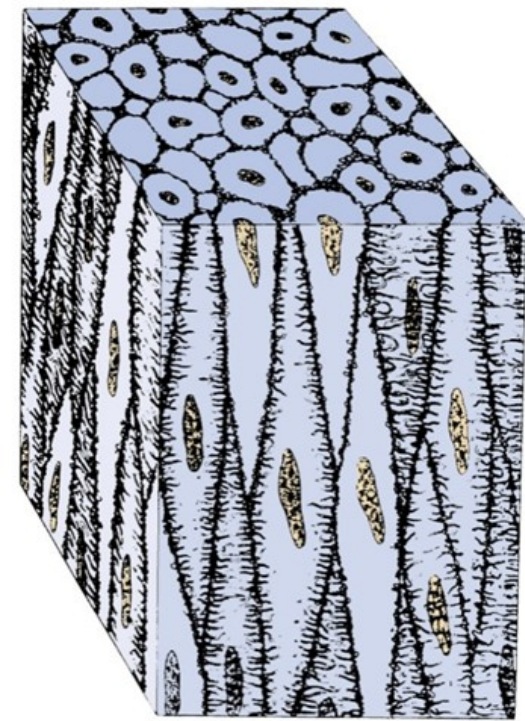




# MUSCLE TISSUE

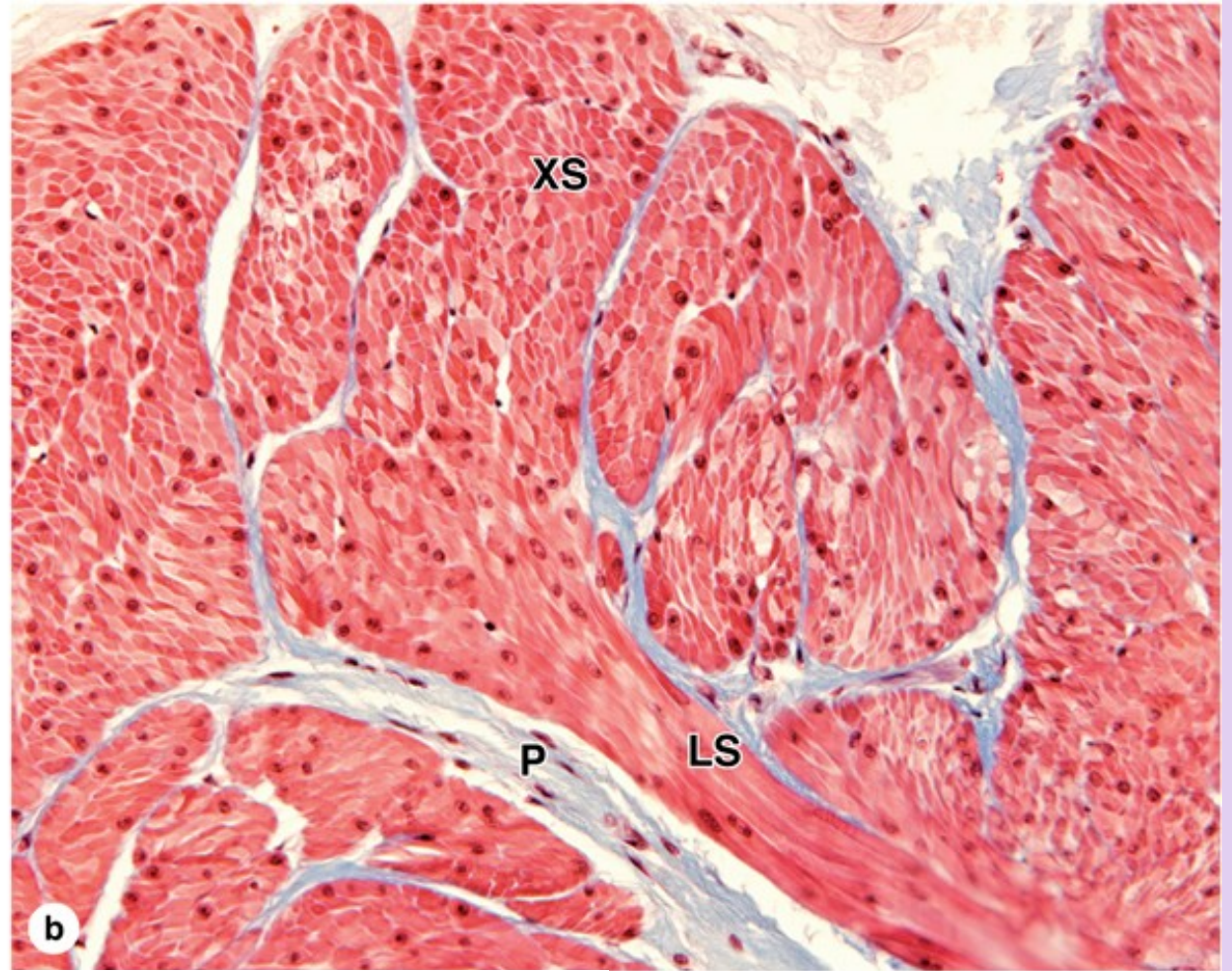
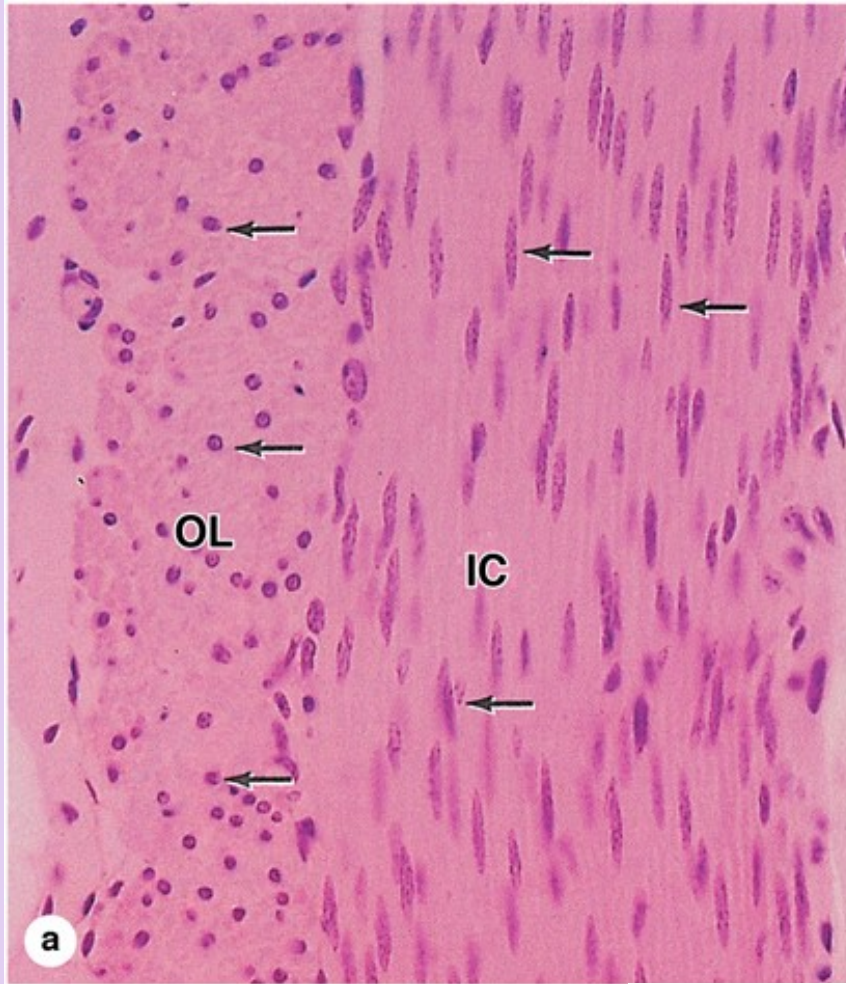
## SMOOTH MUSCLE

- Smooth muscle is present in walls of most hollow organs, including most blood vessels, many respiratory passageway, genital ducts and the ureter. The wall of the heart is an exception, as the myocardium is composed of cardiac muscle.
- Histogenesis: from mesoderm
- **Structure of smooth muscle cells**
  - Smallest type, length varies from 20 microns in blood vessels to 500 microns in the uterus
  - Unbranched **spindle-shaped cells** are elongated with tapering ends.
  - Possess a single, **centrally placed, oval nucleus**, which can appear spiraled or „kork-screw,, shaped when the cell is contracted.
  - Organelles are clustered at the poles of the nucleus.
  - **Nonstriated**; no myofibrils are present.
  - External lamina is present along with **reticular fibers**.
  - Abundant **gap junctions**
  - Capable of both hypertrophy and hyperplasia
  - In addition to their contractile properties, smooth muscle cells produce collagen, elastin, proteoglykans.



(c) Section stained only for reticulin reveals the thin endomysium around each fiber, with more reticulin in the connective tissue of small arteries (A). Reticulin fibers associated with the basal laminae of smooth muscle cells help hold the cells together as a functional unit during the slow, rhythmic contractions of this tissue. (X200; Silver)





Cells or fibers of smooth muscle are long, tapering structures with elongated nuclei centrally located at the cell's widest part.

(a) In most of the digestive tract and certain similar structures smooth muscle is organized into two layers which contract in a coordinated manner to produce a wave that moves the tract's contents in a process termed **peristalsis**. In smooth muscle of the small intestine wall cut in cross section, cells of the inner circular (IC) layer are cut lengthwise and cells of the outer longitudinal layer (OL) are cut transversely. Only some nuclei (arrows) of the latter cells are in the plane of section so that many cells appear to be devoid of nuclei. (X140; H&E)

(b) Section of smooth muscle in bladder shows interwoven bundles of muscle fibers in cross section (XS) and longitudinal section (LS) with the same fascicle. There is much collagen in the branching perimysium (P), but the endomysium can barely be seen by routine staining. (X140; Mallory trichrome)

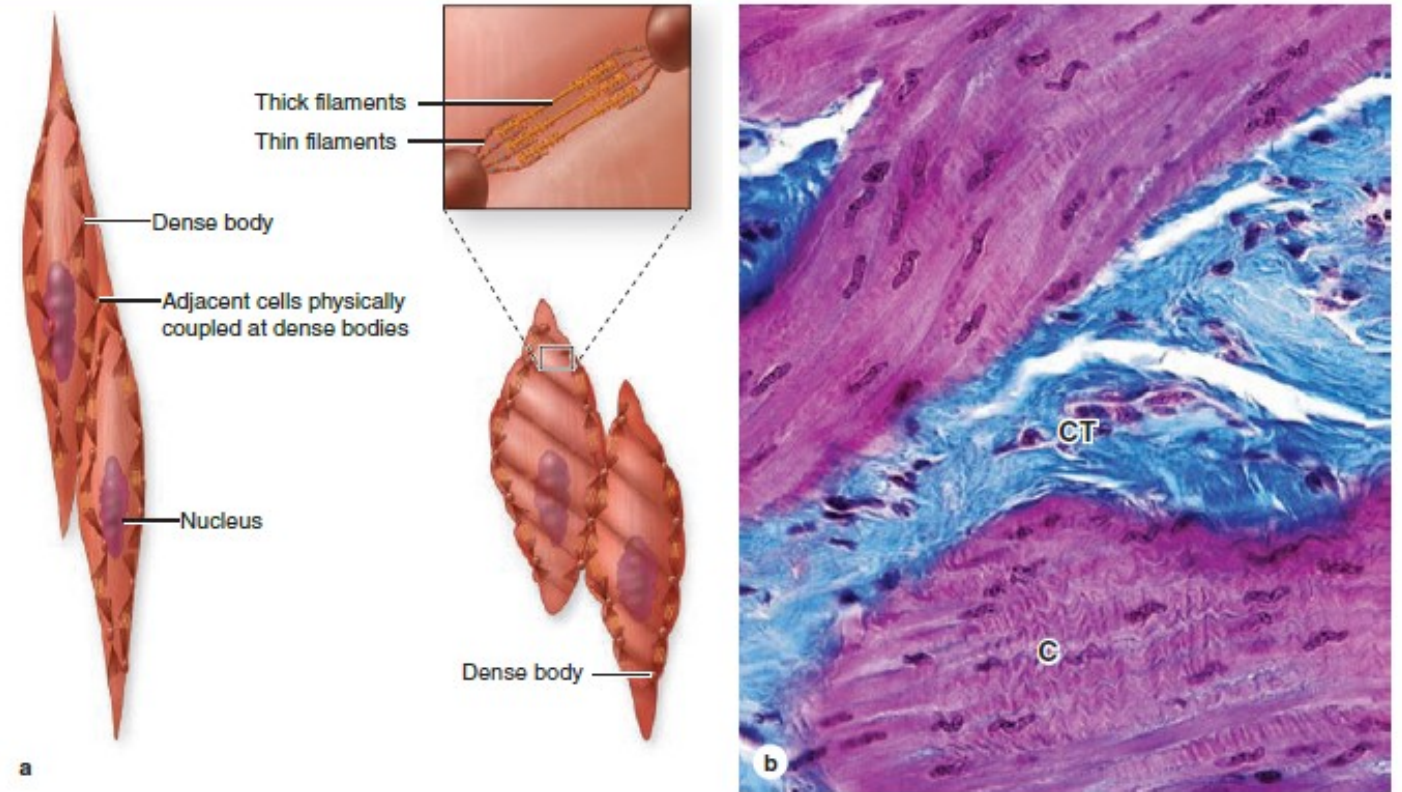


# MUSCLE TISSUE

## SMOOTH MUSCLE

- **Organization of the contractile proteins**
  - *Actin and myosin myofilaments* are present, but they are not organized into myofibrils.
  - Myofilaments overlap as in striated muscle and crisscross throughout the sarcoplasm, forming a reticulum.
  - *Dense bodies*
    - Serve as insertion points for myofilaments to transmit the force of filament sliding
    - Comparable to Z-lines of skeletal and cardiac muscle.
    - Present in the cytoplasm and associated with the sarcolemma

FIGURE 10–20 Smooth muscle contraction.



Most molecules that allow contraction are similar in the three types of muscle, but the filaments of smooth muscle are arranged differently and appear less organized.

(a) The diagram shows that thin filaments attach to **dense bodies** located at the cell membrane and deep in the cytoplasm. Dense bodies contain  $\alpha$ -actinin for thin filament attachment. Dense bodies at the membrane are also attachment sites for intermediate filaments and for adhesive junctions between cells. This arrangement of both the

cytoskeleton and contractile apparatus allows the multicellular tissue to contract as a unit, providing better efficiency and force.

(b) Micrograph showing a contracted (C) region of smooth muscle, with contraction decreasing the cell length and deforming the nuclei. The long nuclei of individual fibers assume a cork-screw shape when the fibers contract, reflecting the reduced cell length at contraction. Connective tissue (CT) of the perimysium outside the muscle fascicle is stained blue. (X240; Mallory trichrome)

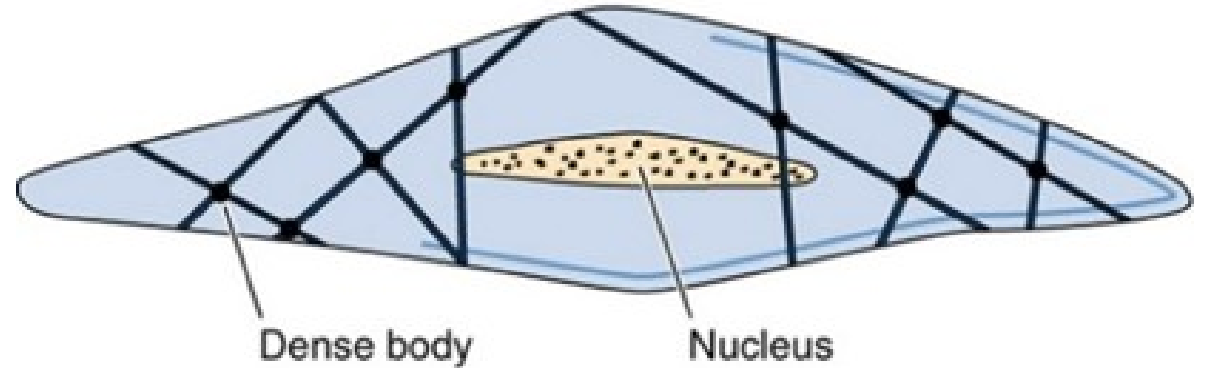


# MUSCLE TISSUE

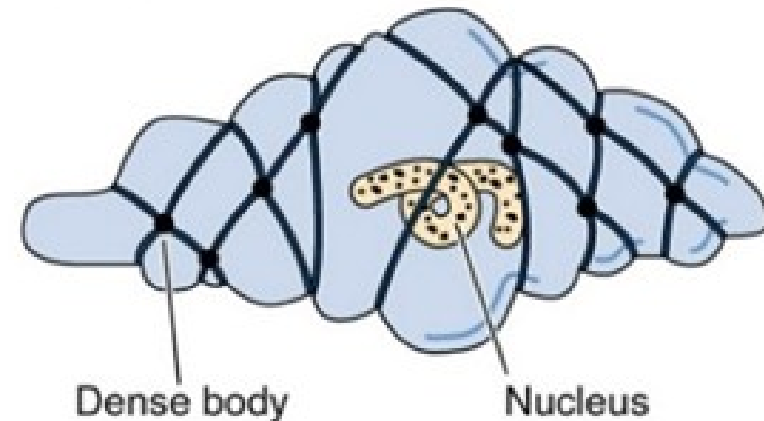
## SMOOTH MUSCLE

- **Coordination of smooth muscle contraction**
  - There's no real sarcoplasmic reticulum (no T-tubules are present). Just a few little storage areas (pinocytotic vesicles) for calcium right under the sarcolemma.
  - *Sliding filament mechanism*. Regulated by intracellular release of calcium but with some differences from striated muscle fibers

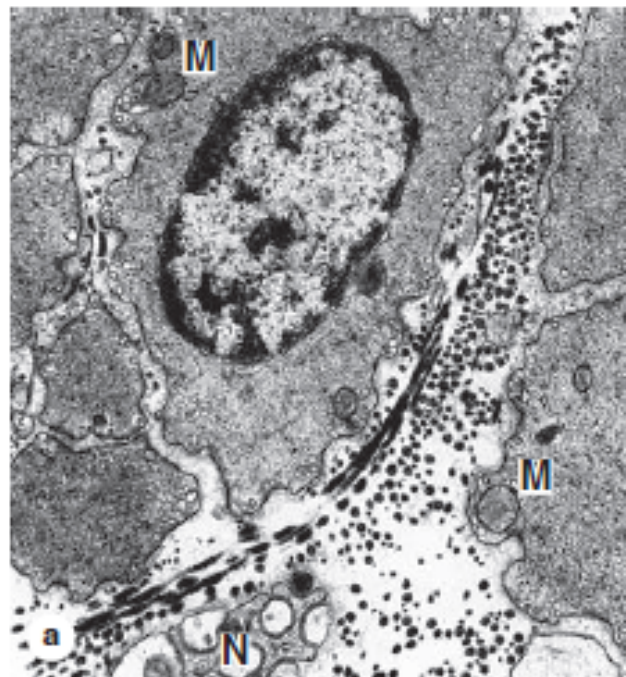
Relaxed smooth muscle cell



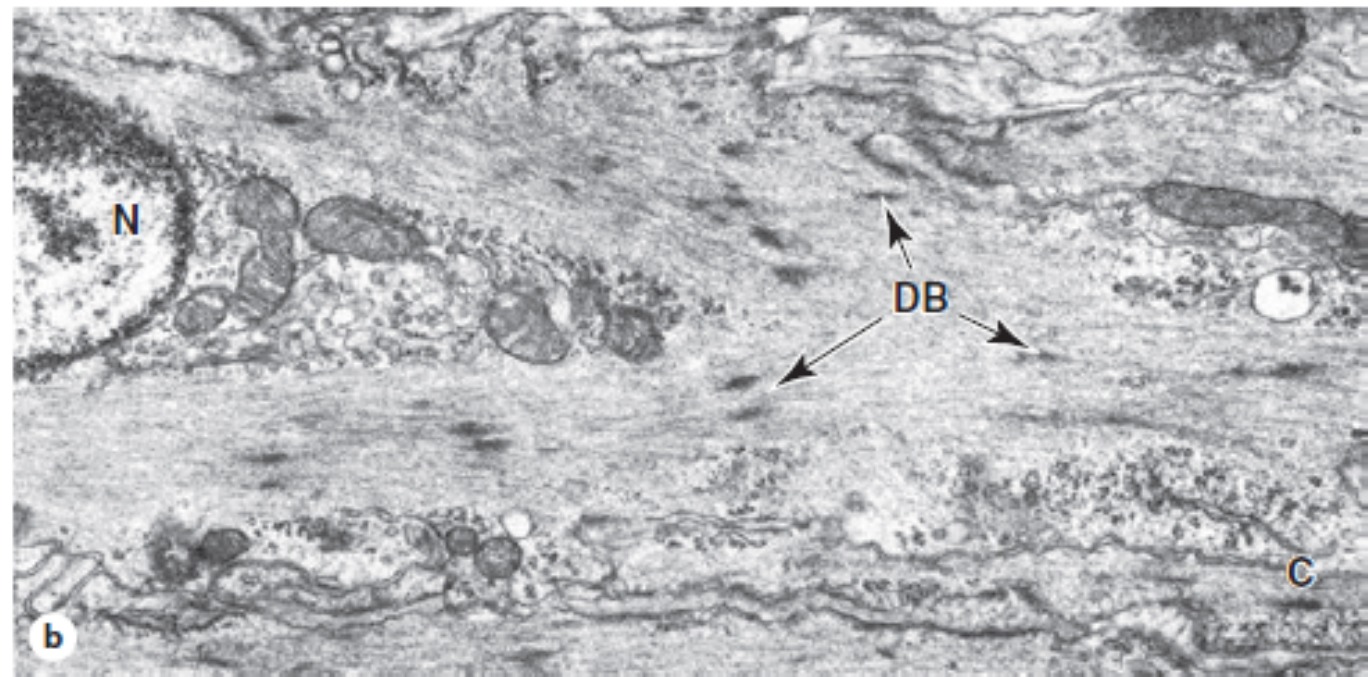
Contracted smooth muscle cell



**FIGURE 10–19** Smooth muscle ultrastructure.



(a) TEM of a transverse section of smooth muscle showing several cells sectioned at various points along their lengths, yielding profiles of various diameters with only the largest containing a nucleus. Thick and thin filaments are not organized into myofibril bundles and there are few mitochondria (M). A sparse external lamina surrounds each cell and reticular fibers are abundant in the ECM. A small unmyelinated nerve (N) is also seen between the cells. (X6650)



(b) Longitudinal section showing several dense bodies (DB) in the cytoplasm and at the cell membrane. Both thin filaments and intermediate filaments attach to the dense bodies. Near the nucleus (N) are mitochondria, glycogen granules, and Golgi complexes. In both photos the cell membranes show invaginations called caveolae (C) with various membrane proteins for cell signaling and regulating uptake and release of  $\text{Ca}^{2+}$  from sarcoplasmic reticulum. (X9000)



# MUSCLE TISSUE

## SMOOTH MUSCLE

- **Types of smooth muscle:**
  - **Visceral smooth muscle**
    - Occurs in sheets in the wall of hollow organs (e.g., digestive tract)
    - Minimally innervated; contraction spreads in peristaltic waves facilitated by large numbers of gap junctions.
    - Specialized for slow, prolonged contraction
  - **Multiunit smooth muscle**
    - Richly innervated, fewer gap junctions than visceral smooth muscle
    - Specialized for precise, graded contraction (e.g., iris of the eye)

# MUSCLE TISSUE

## REGENERATION OF MUSCLE TISSUE

- **Cardiac muscle has no regenerative ability.**  
Death of cardiac muscle leads to replacement by dense connective tissue scar.
- **Skeletal muscle can undergo limited regeneration.**
- Satellite cells are inactive myoblasts. After an injury, they can become activated and make new muscle cells.
- **Smooth muscle is capable of active regeneration.**
- Muscle fibers undergo mitosis and replace damaged tissue.