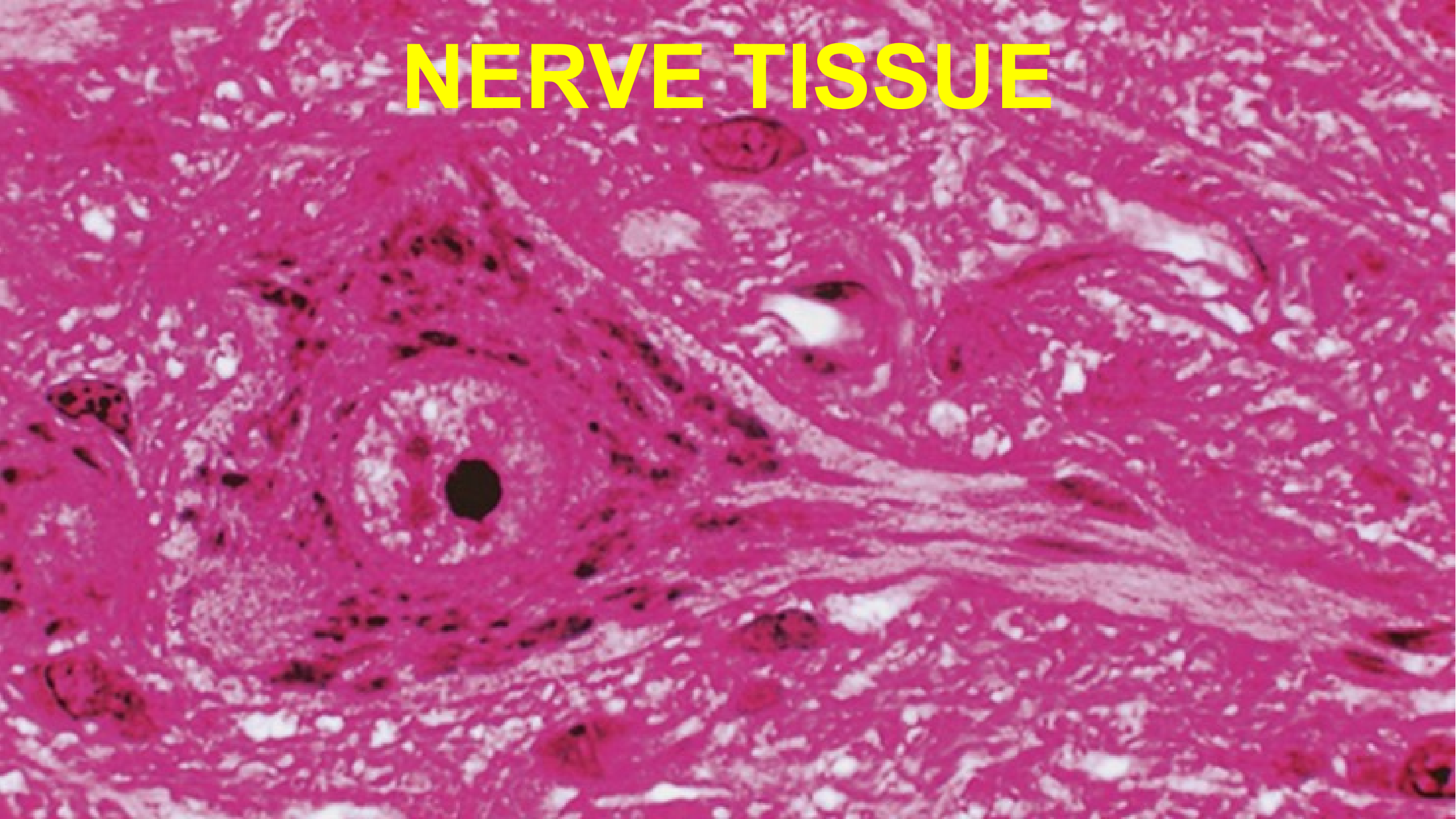


NERVE TISSUE



NERVE TISSUE

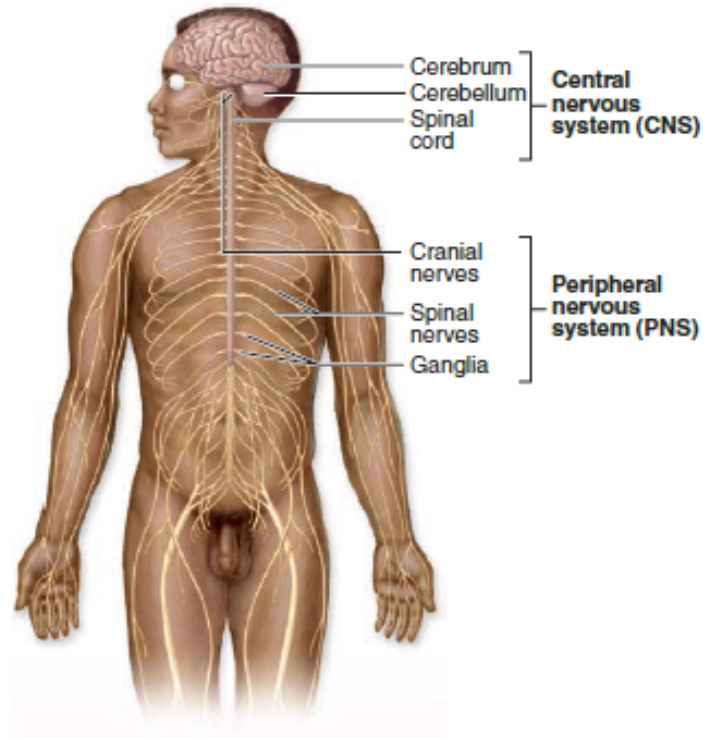
GENERAL CONCEPTS

- Nerve tissue is highly specialized to employ modifications in membrane electrical potentials to relay signals throughout the body. Neurons form intricate circuits that:
 - Relay sensory information from the internal and external environments.
 - Integrate information among millions of neurons
 - Transmit effector signals to muscles and glands.

• Anatomical subdivisions of nervous tissue

- *Central nervous system (CNS)*
 - Brain
 - Spinal cord
- *Peripheral nervous system (PNS)*
 - Nerves
 - Ganglia (singular, ganglion)
- Motor and sensory components

FIGURE 9–1 The general organization of the nervous system.



Anatomically the nervous system is divided into the **CNS** and **PNS**, which have the major components shown in the diagram.

Functionally the nervous system consists of the following:

1. Sensory division (afferent)

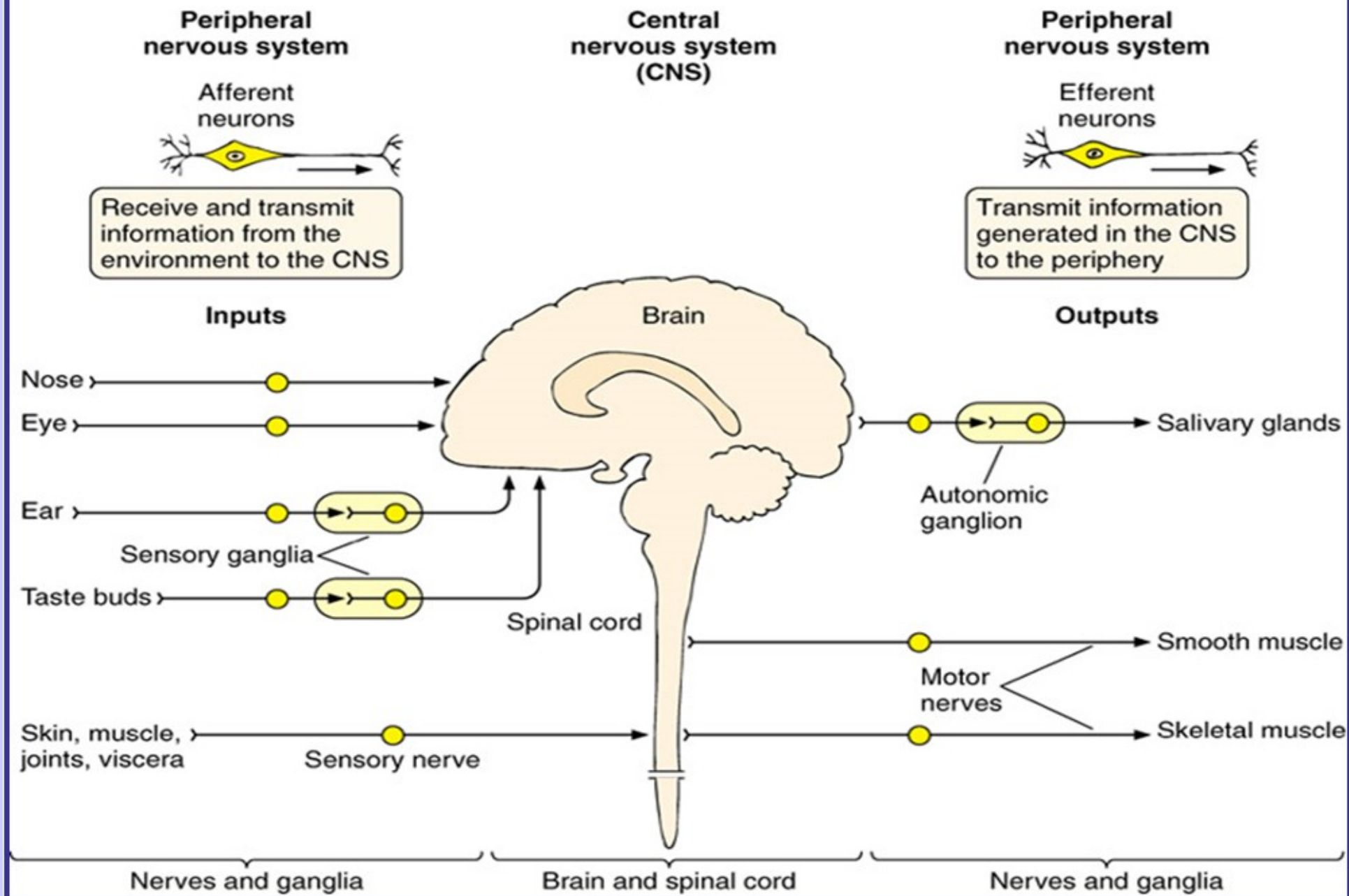
- A. **Somatic**—sensory input perceived consciously (eg, from eyes ears, skin, and musculoskeletal structures)
- B. **Visceral**—sensory input *not* perceived consciously (eg, from internal organs and cardiovascular structures)

2. Motor division (efferent)

- A. **Somatic**—motor output controlled consciously or voluntarily (eg, by skeletal muscle effectors)
- B. **Autonomic**—motor output *not* controlled consciously (eg, by heart or gland effectors)

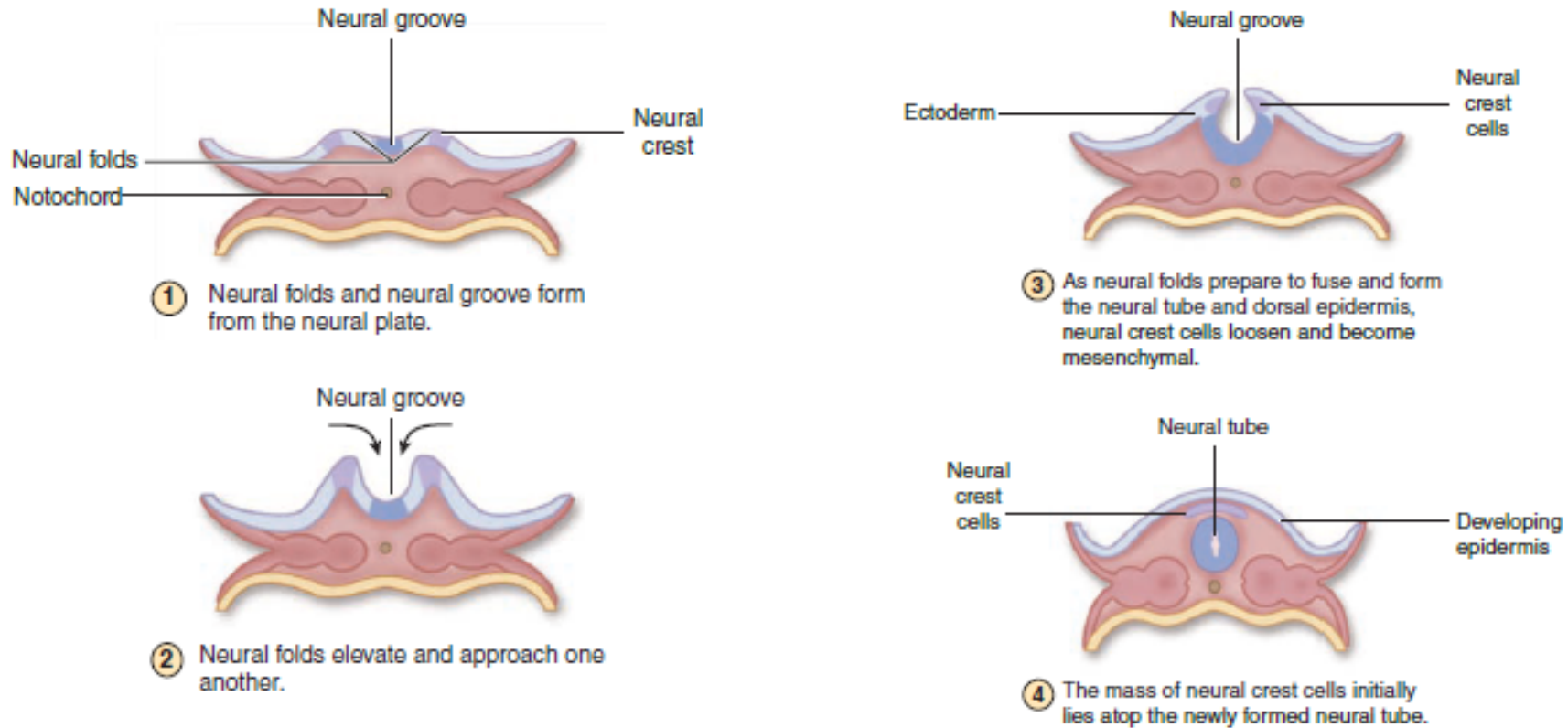
The autonomic motor nerves, comprising what is often called the **autonomic nervous system (ANS)**, all have pathways involving two neurons: a **preganglionic neuron** with the cell body in the CNS and a **postganglionic neuron** with the cell body in a ganglion. The ANS has two divisions: (1) The **parasympathetic division**, with its ganglia within or near the effector organs, maintains normal body homeostasis. (2) The **sympathetic division** has its ganglia close to the CNS and controls the body's responses during emergencies and excitement. ANS components located in the wall of the digestive tract are sometimes referred to as the enteric nervous system.

NERVOUS SYSTEM



NERVE TISSUE

FIGURE 9-2 Neurulation in the early embryo.



Stages in the process of **neurulation**, by which cells of the CNS and PNS are produced, are shown in diagrammatic cross sections of a 3- and 4-week human embryo with the extraembryonic membranes removed. Under an inductive influence from the medial notochord, the overlying layer of ectodermal cells thickens as a bending **neural plate**, with a medial neural groove and lateral neural folds (1). All other ectoderm will become epidermis. The plate bends further, making the **neural folds** and **groove** more prominent (2). The neural folds rise and fuse at the midline (3),

converting the groove into the **neural tube** (4), which is large at the cranial end of the embryo and much narrower caudally. The neural tube will give rise to the entire CNS.

As the neural tube detaches from the now overlying ectoderm, many cells separate from it and produce a mass of mesenchymal cells called the **neural crest**. Located initially above the neural tube, neural crest cells immediately begin migrating laterally. Cell derived from the neural crest will form all components of the PNS and also contribute to certain non-neural tissues.

NERVE TISSUE

CELLS OF NERVE TISSUE

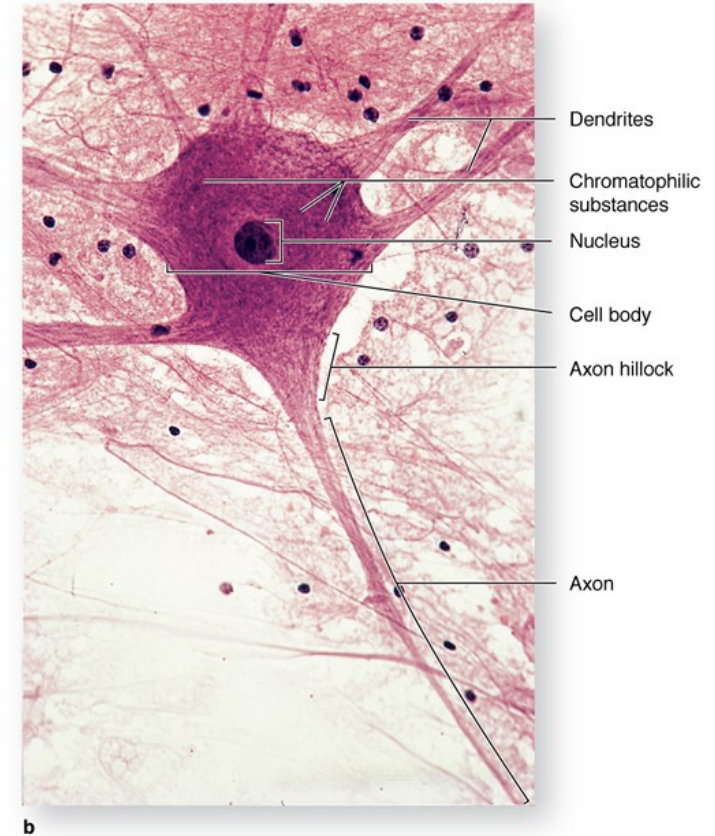
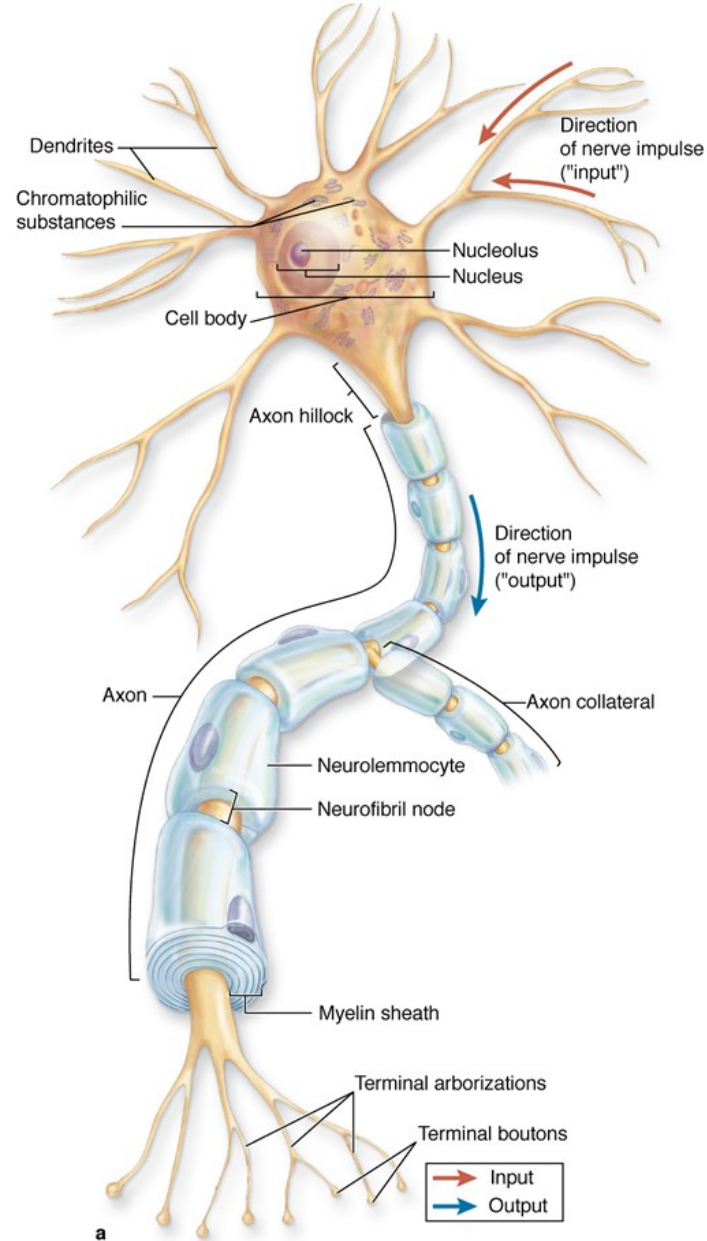
- *Neurons*
 - Functional units of the nervous system; receive, process, store, and transmit information to and from other neurons, muscle cells, or glands
 - Composed of a cell body, dendrites, axon and synapses
 - Form complex and highly integrated circuits
- *Supportive (glial) cells*
 - Provide metabolic and structural support for neurons, insulate neurons via a myelin sheath, maintain homeostasis, and perform phagocytic functions
 - Comprised of:
 - Astrocytes
 - Oligodendrocytes
 - Microglia
 - ependymal cells in the CNS
 - Schwann cells in the PNS

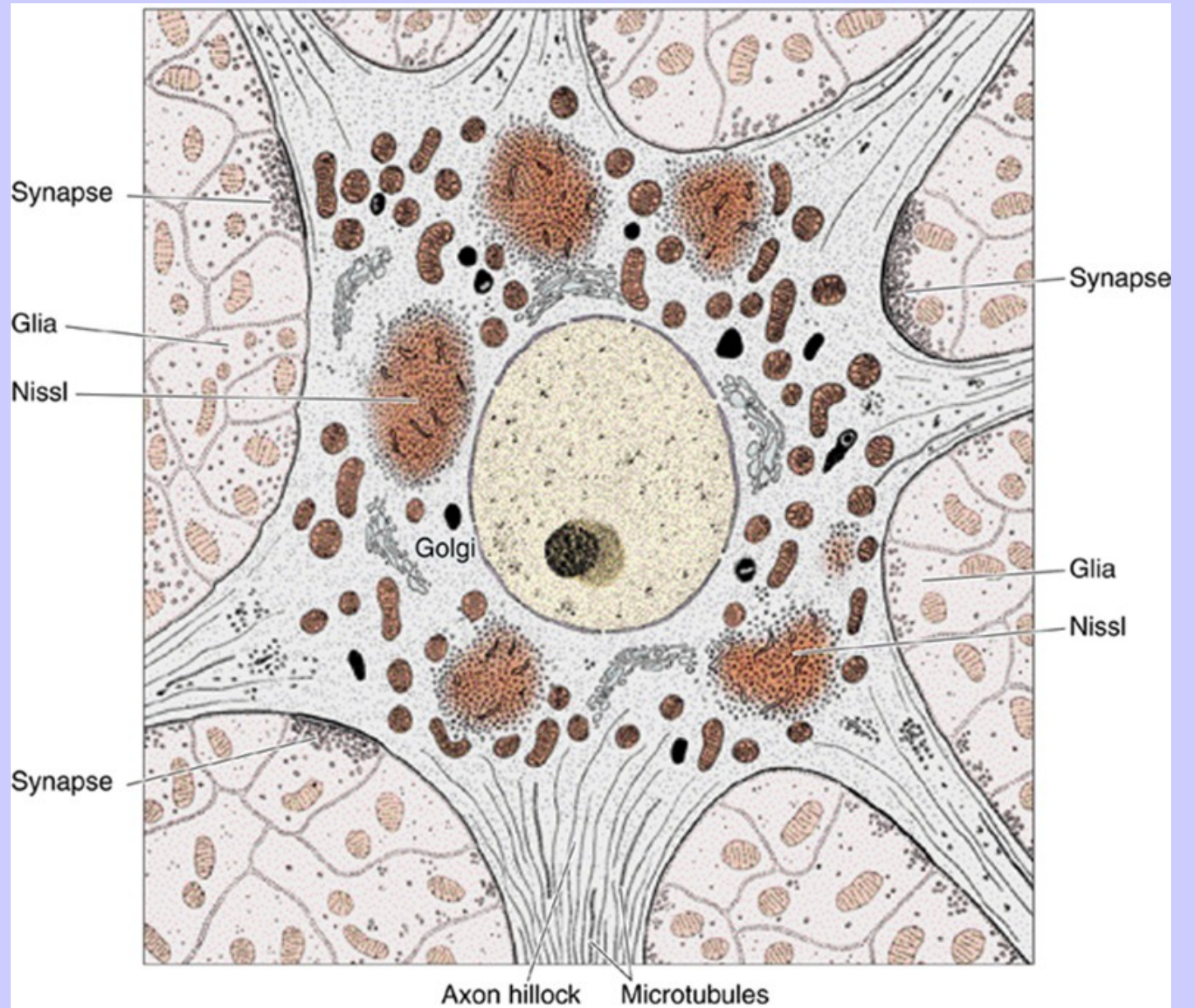
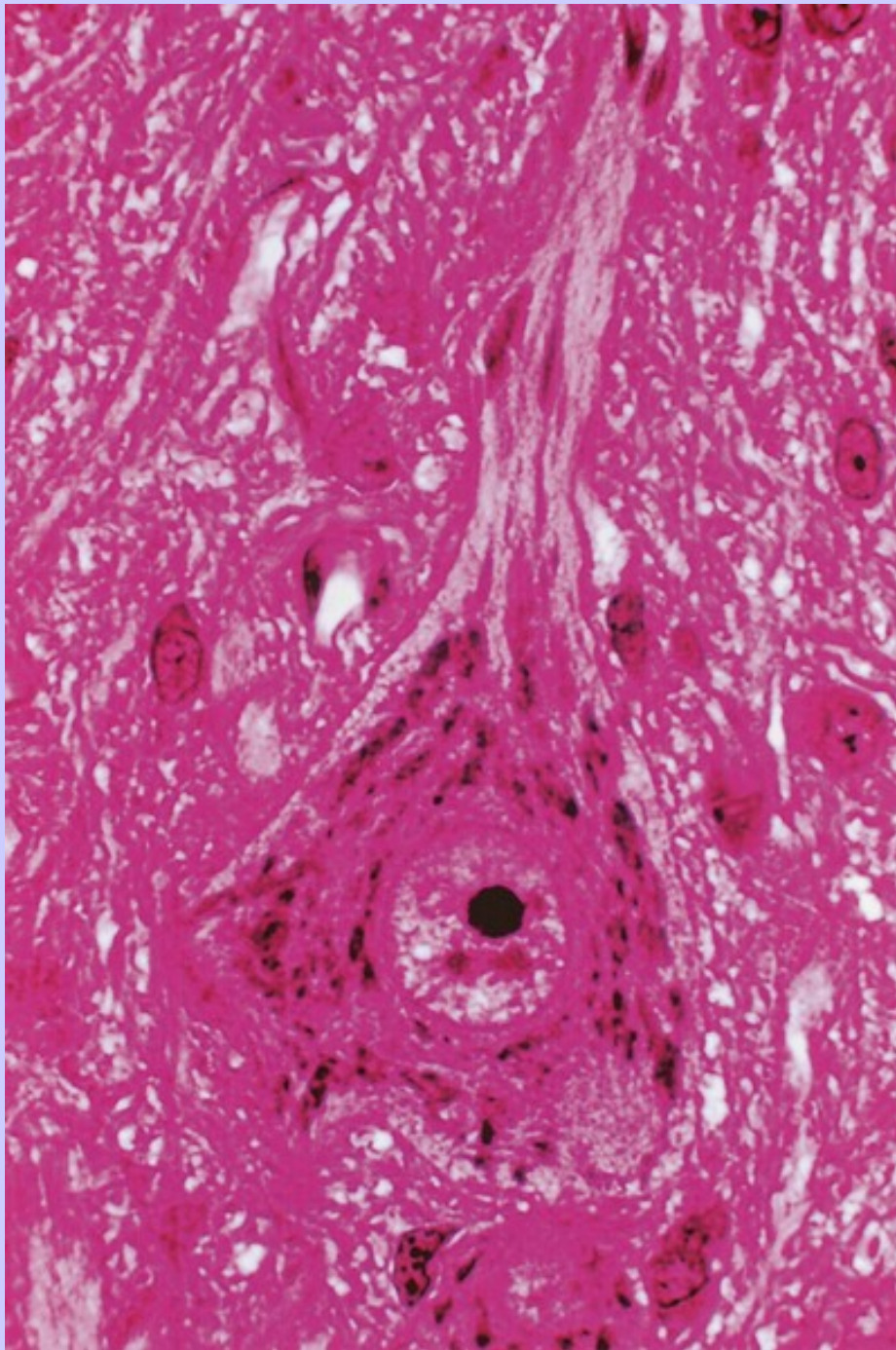
NERVE TISSUE

STRUCTURE OF A "TYPICAL" NEURON

Cell body (soma, perikaryon)

- *Nucleus*
 - Large, spherical, usually centrally located in the soma
 - Highly euchromatic with a large, prominent nucleolus
- *Cytoplasm*
 - Well-developed *cytoskeleton*
 - Intermediate filaments (neurofilaments)
 - Microtubules
 - Abundant rough endoplasmic reticulum and polysomes (*Nissl substance*)
 - Well-developed *Golgi apparatus*
 - Numerous *mitochondria*





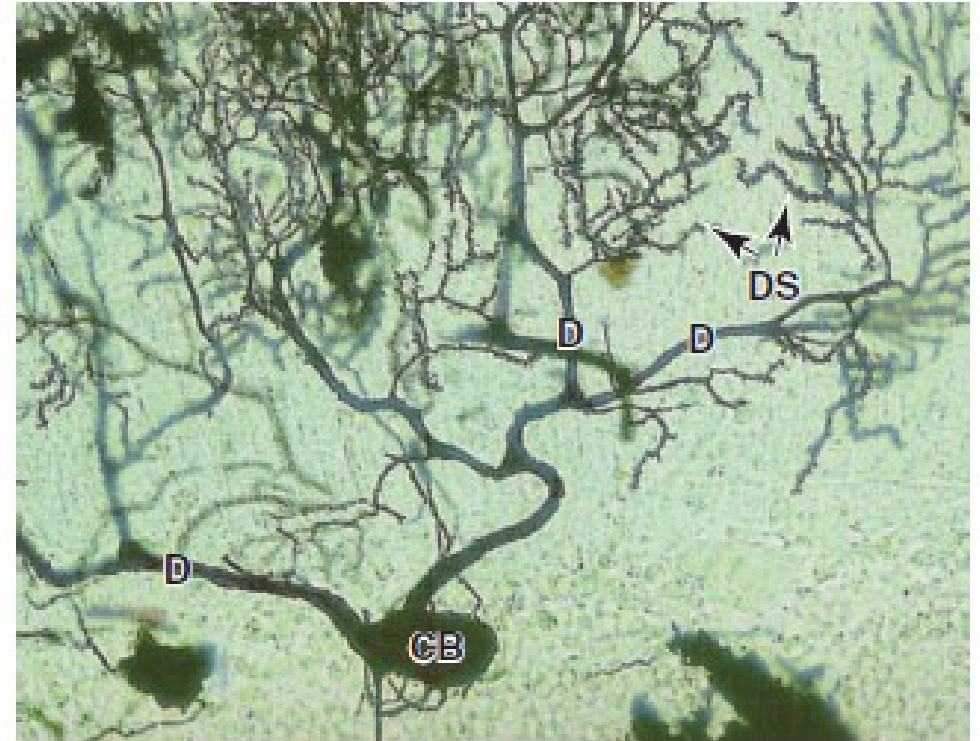
NERVE TISSUE

STRUCTURE OF A "TYPICAL" NEURON

Dendrite(s)

- Usually multiple and highly branched at acute angles
- May possess spines small membranous elevations which form excitatory synapses
- Collectively, form the majority of the receptive field of a neuron; conduct impulses toward the cell body
- Cytoplasmic components
 - Microtubules and neurofilaments
 - Rough endoplasmic reticulum and polysomes
 - Smooth endoplasmic reticulum
 - Mitochondria

FIGURE 9-5 Dendrites and dendritic spines.



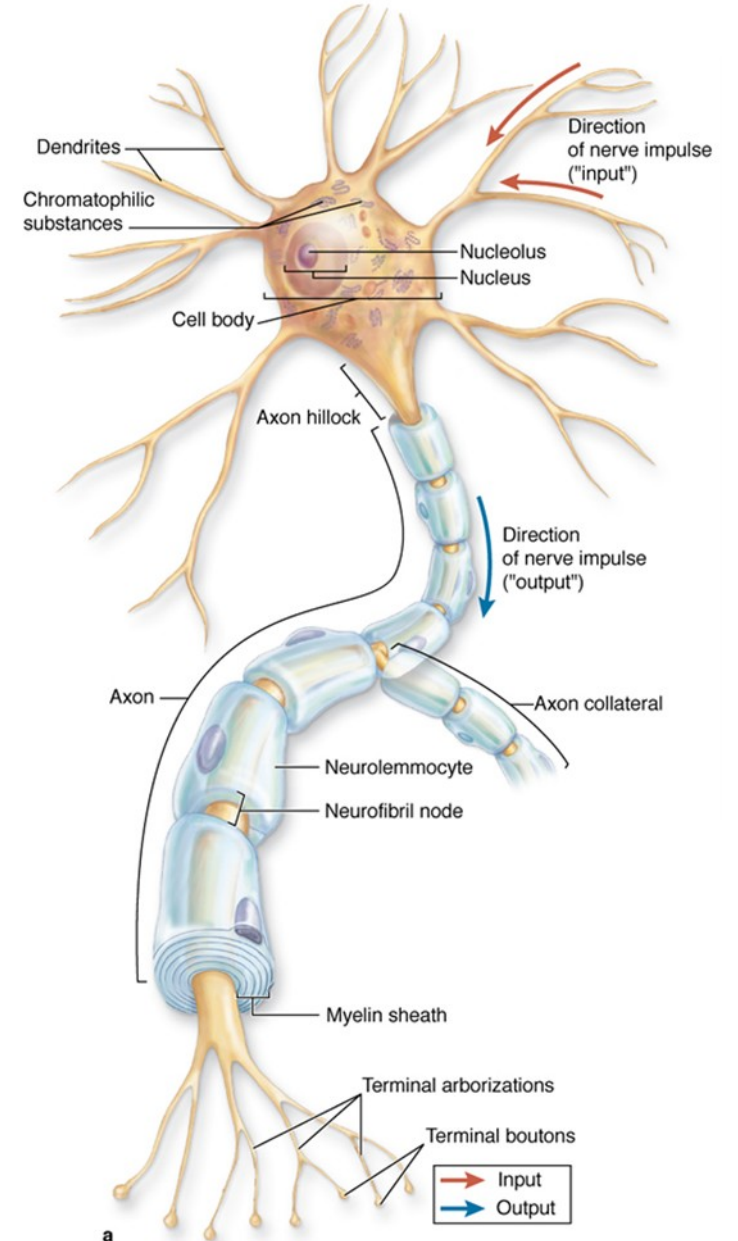
The large Purkinje neuron in this silver-impregnated section of cerebellum has many dendrites (D) emerging from its cell body (CB) and forming branches. The small dendritic branches each have many tiny projecting dendritic spines (DS) spaced closely along their length, each of which is a site of a synapse with another neuron. Dendritic spines are highly dynamic, the number of synapses changing constantly. (X650; Silver stain)

NERVE TISSUE

STRUCTURE OF A "TYPICAL" NEURON

Axon

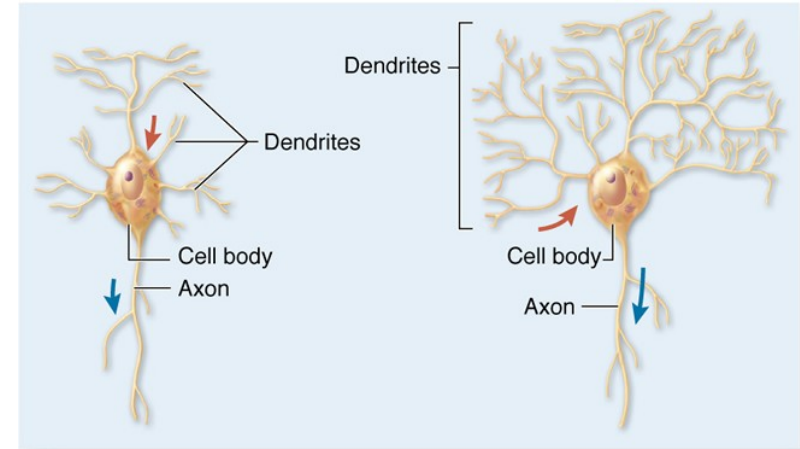
- Usually *only one* per neuron
- Generally, of smaller caliber and longer than dendrites
- Branches at right angles, fewer branches than dendrites
- *Cytoplasmic components*
 - Microtubules and neurofilaments
 - Lacks rough endoplasmic reticulum and polysomes
 - Smooth endoplasmic reticulum
 - Mitochondria
- *Axon hillock*. Region of the cell body where axon originates
 - Devoid of rough endoplasmic reticulum and so stains pale
 - Continuous with initial segment of the axon that is a highly electrically excitable zone for initiation of nervous impulse
- Usually, ensheathed by supporting cells
- Transmits impulses away from the cell body to
 - Neurons
 - Effector structures such as muscle and glands
- Branches extensively near its target, each branch ends in a swelling, the *terminal bouton*, which is the presynaptic element of a synapse



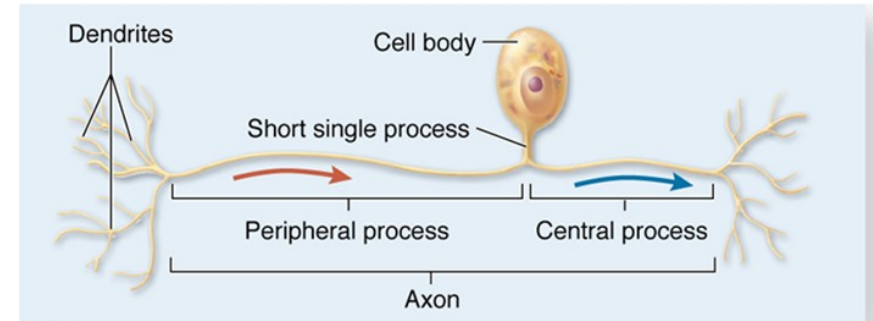
NERVE TISSUE

TYPES OF NEURONS BY SHAPE AND FUNCTION

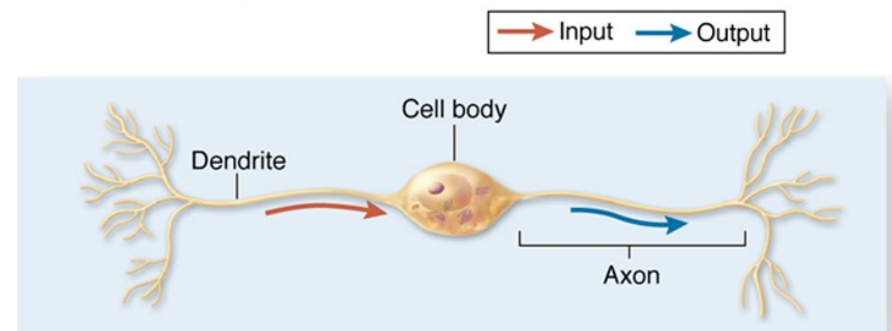
- **Multipolar neuron.** Most numerous and structurally diverse type
 - Efferent. Motor, carrying impulses out of the CNS or innervating smooth muscle from autonomic ganglia
 - Integrative function, axons remain in the CNS
 - Found throughout the CNS and in autonomic ganglia in the PNS
- **(Pseudo)unipolar neuron**
 - Afferent. Sensory function, carrying impulses from peripheral receptors into the CNS
 - Found in selected areas of the CNS and in sensory ganglia of cranial nerves and spinal nerves (dorsal root ganglia)
- **Bipolar neuron**
 - Afferent. Sensory function
 - Found associated with organs of special sense (retina of the eye, olfactory epithelium, vestibular and cochlear ganglia of the inner ear)
 - Developmental stage for all neurons



a Multipolar neurons



c Unipolar neuron



b Bipolar neuron

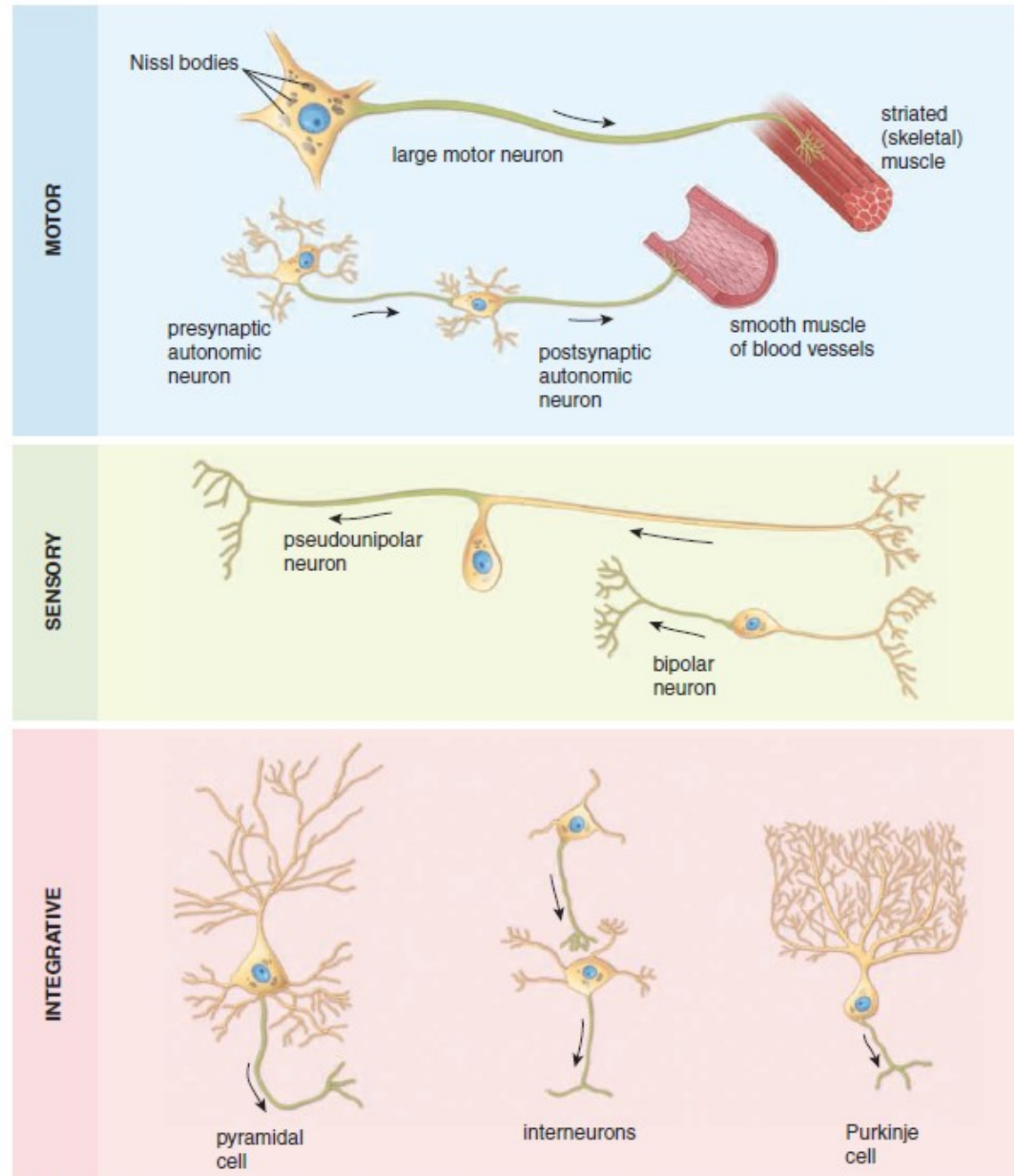


FIGURE 12.2 ▲ Diagram illustrating different types of neurons. The cell bodies of pseudounipolar (unipolar), bipolar, and postsynaptic autonomic neurons are located outside the CNS. Purkinje and pyramidal cells are restricted to the CNS; many of them have elaborate dendritic arborizations that facilitate their identification. Central axonal branch and all axons in remaining cells are indicated in *green*.

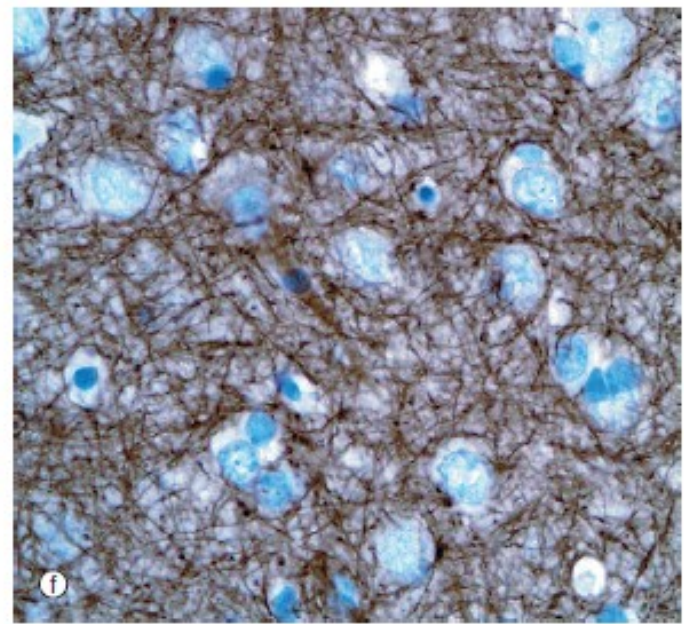
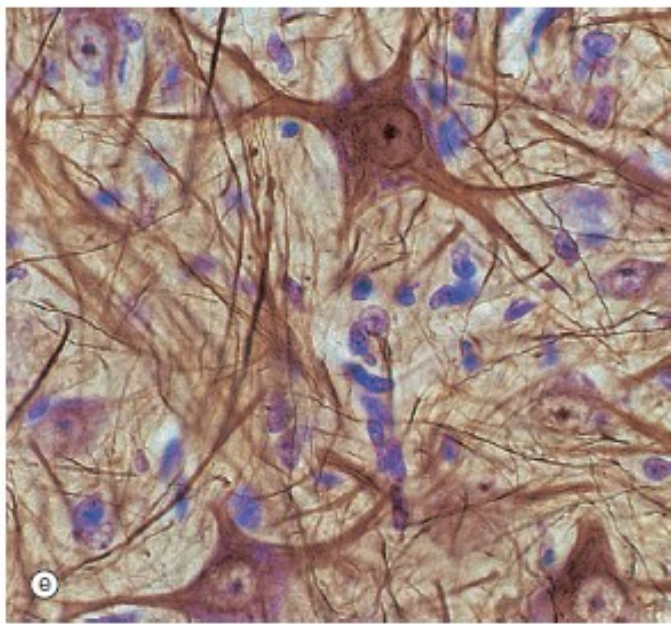
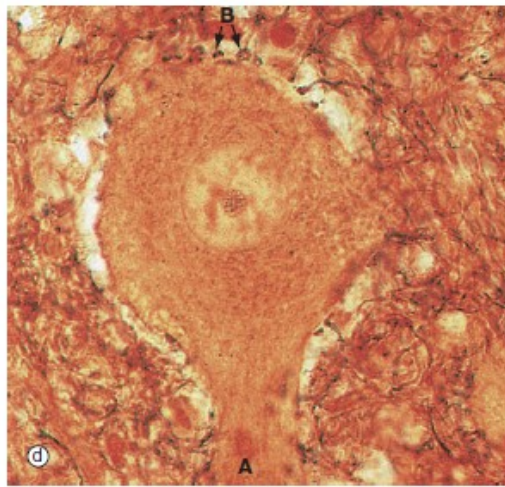
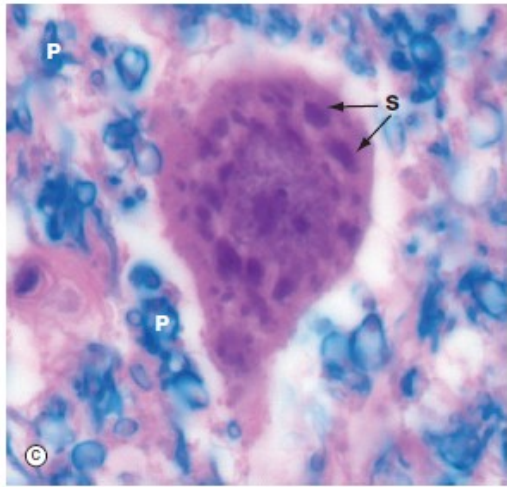
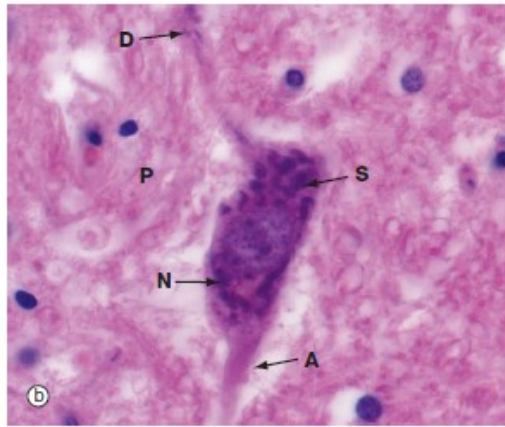
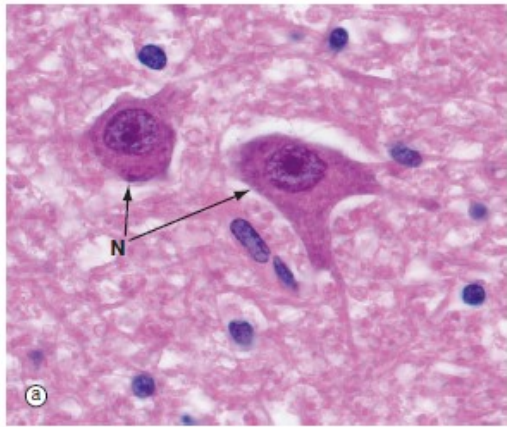


FIG. 7.4 Neurons and methods of study with light microscopy (*caption and illustrations (g) and (h) opposite*)
 (a, b) H&E (HP) (c) Luxol fast blue, H&E (HP) (d) Gold method (HP) (e) Gold/toluidine blue (HP) (f) Immunohistochemistry for neurofilament protein (HP) (g) Spread preparation, gold method (MP) (h) Golgi-Cox (HP)

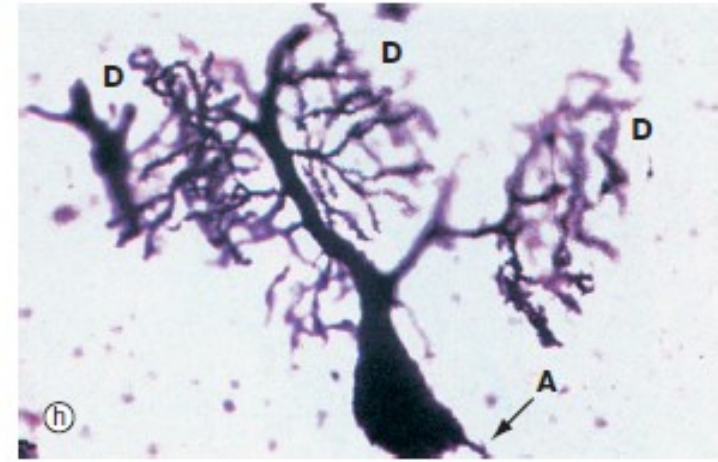
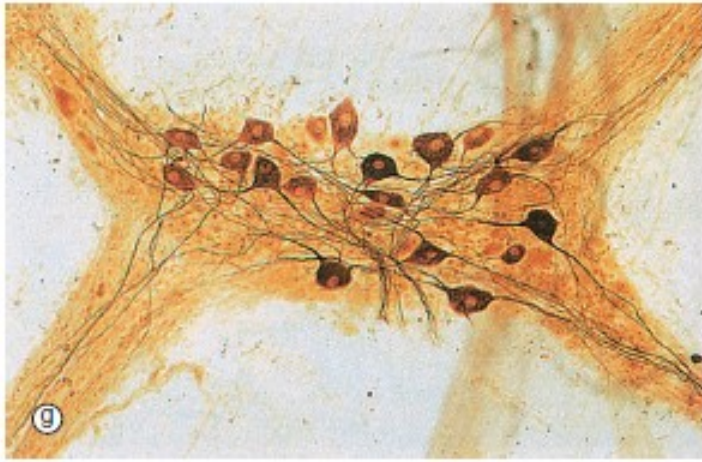

FIG. 7.4 Neurons and methods of study with light microscopy (*illustrations (a-f) opposite*)
 (a, b) H&E (HP) (c) Luxol fast blue, H&E (HP) (d) Gold method (HP) (e) Gold/toluidine blue (HP) (f) Immunohistochemistry for neurofilament protein (HP) (g) Spread preparation, gold method (MP) (h) Golgi-Cox (HP)

NERVE TISSUE

ARRANGEMENT OF NEURONAL CELL BODIES AND THEIR PROCESSES

In both CNS and PNS, cell bodies are found in clusters or layers and axons travel in bundles. These groupings are based on common functions and/or common connections.

	Group of cell bodies	Bundle of processes
Central nervous system	Nucleus or cortex (gray matter)	Tract (white matter)
Peripheral nervous system	Ganglion	Nerve

NERVE TISSUE

THE REFLEX ARC

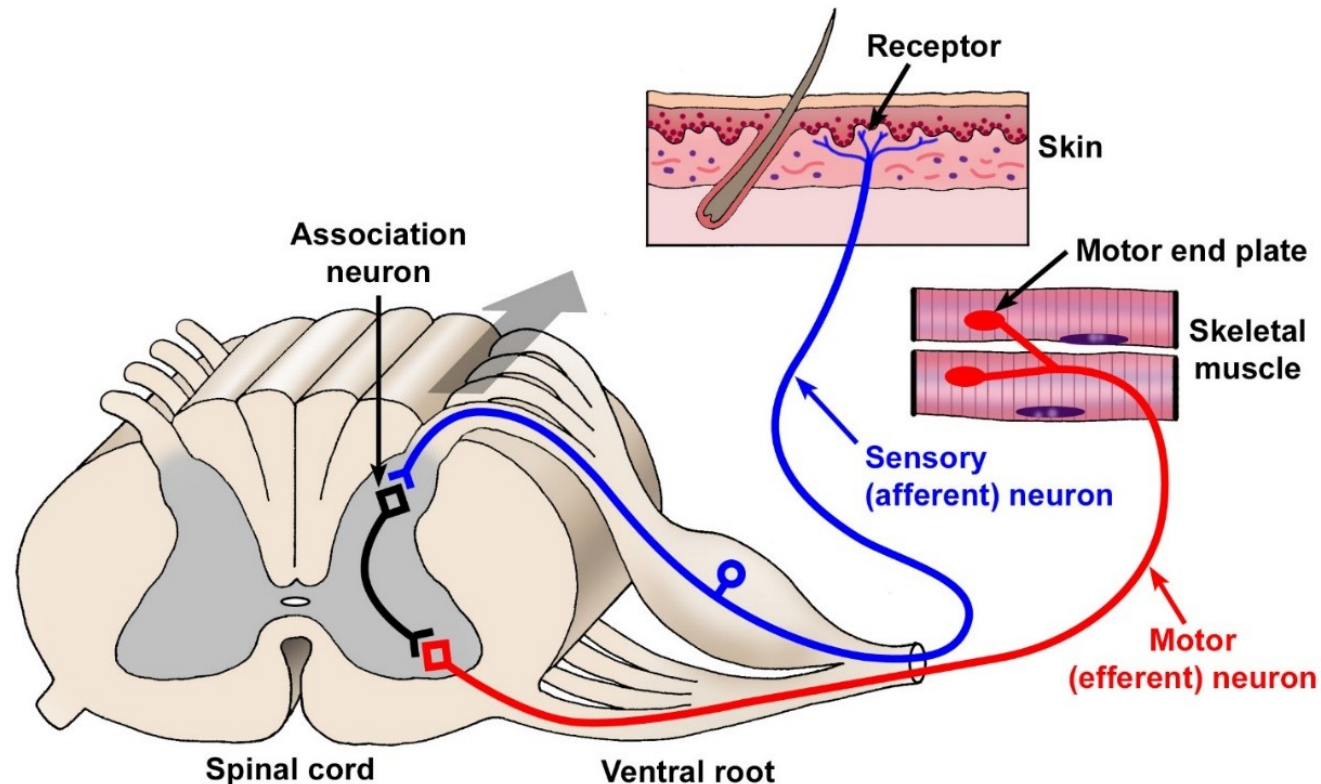
The reflex arc is the simplest neuronal circuit.

These circuits provide rapid, stereotyped reactions to help maintain homeostasis.

To begin the reflex, a pseudounipolar, sensory neuron is activated by a receptor.

The axon carries an afferent signal from the skin into the spinal cord where it synapses on a multipolar association neuron or interneuron.

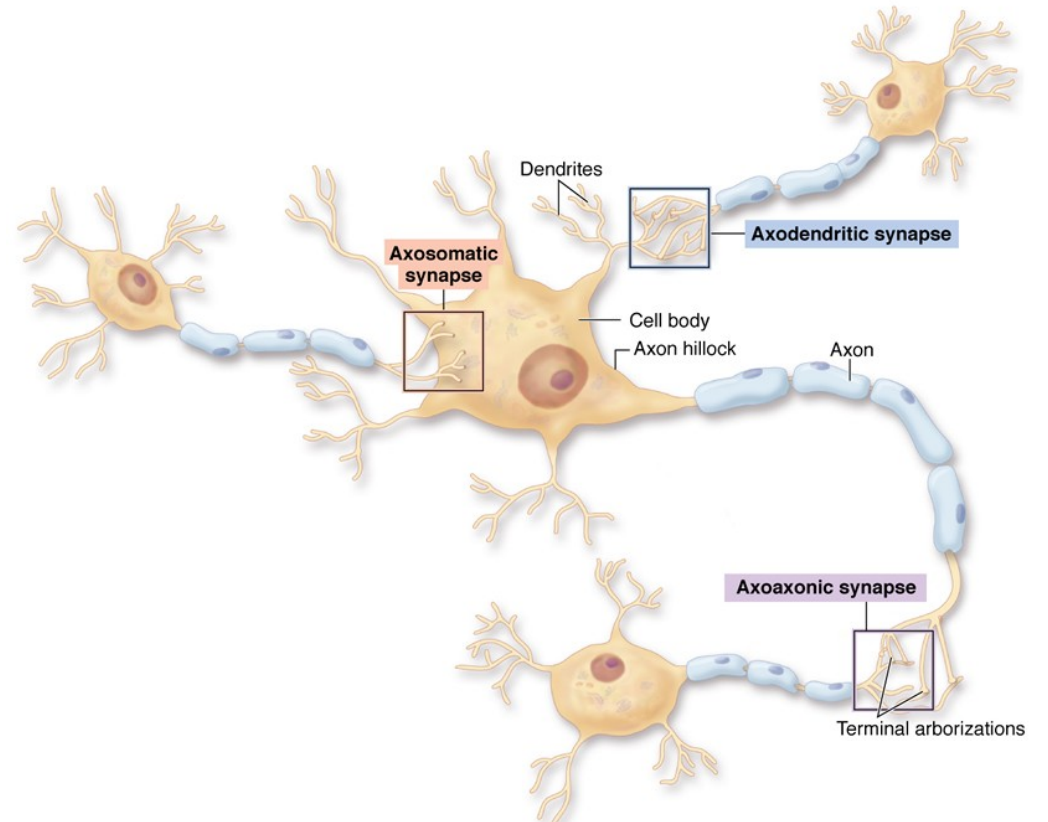
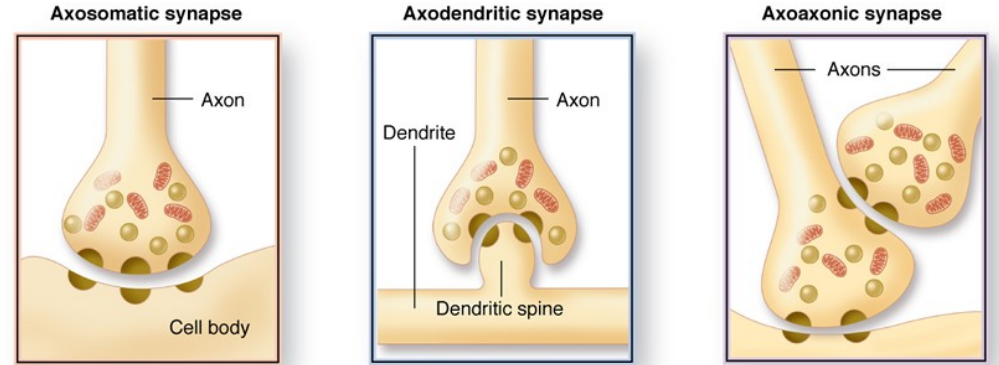
The interneuron signals a multipolar, motor neuron whose axon then carries an efferent signal to skeletal muscle to initiate contraction.



NERVE TISSUE

SYNAPSE

- The function of the synapse is to alter the membrane potential of the postsynaptic target cell to either facilitate or inhibit the likelihood of the stimulus to be propagated by the postsynaptic cell. Most neurons receive thousands of synaptic contacts, both stimulatory and inhibitory, and the algebraic sum of these inputs determines whether the postsynaptic cell will depolarize.
- **Classified according to postsynaptic target:**
 - Axodendritic. Most common
 - Axosomatic
 - Axoaxonic. Occur mostly at presynaptic terminals
 - Neuromuscular junction



NERVE TISSUE

SYNAPSE

• Structure of the synapse

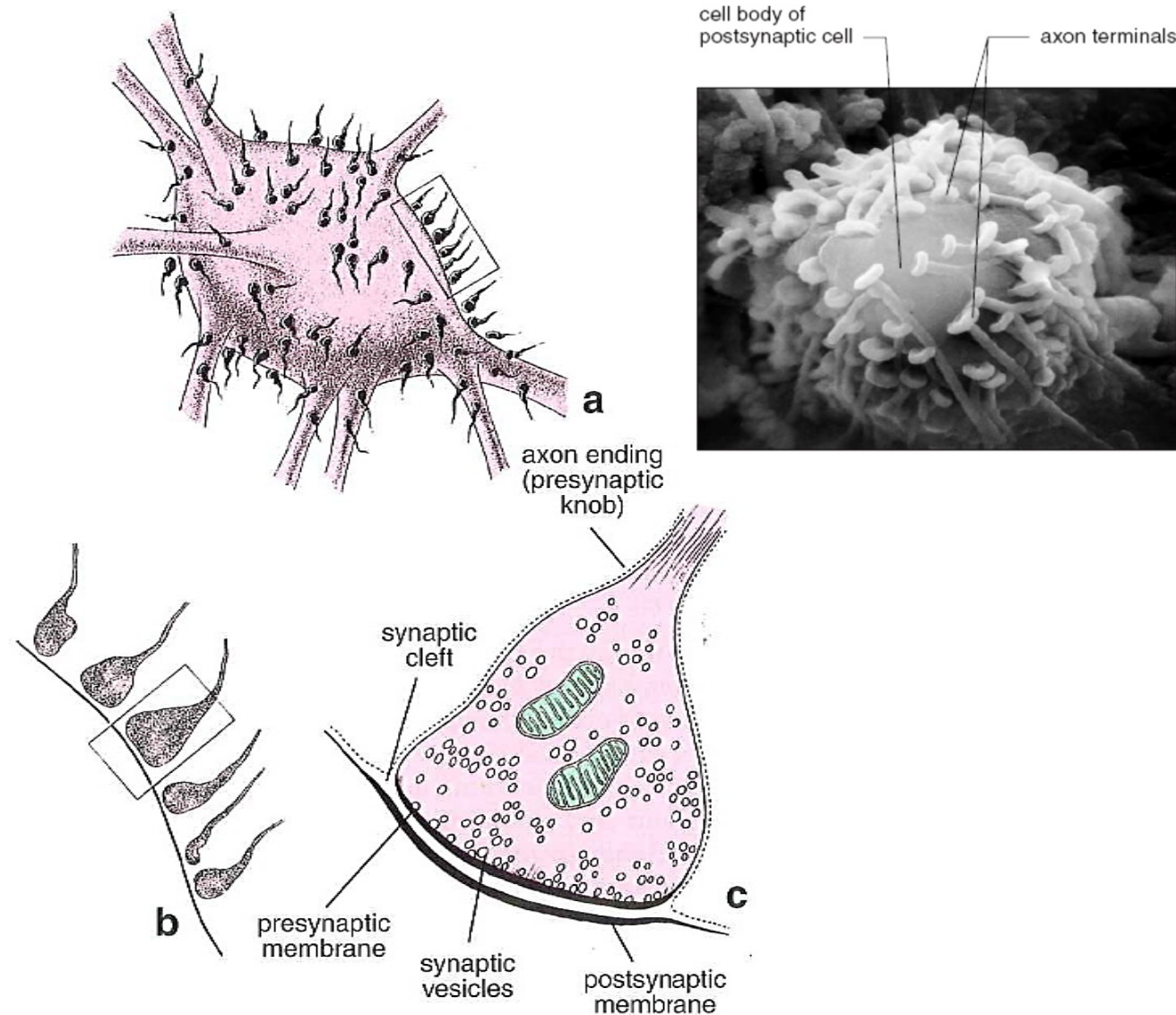
• Presynaptic component

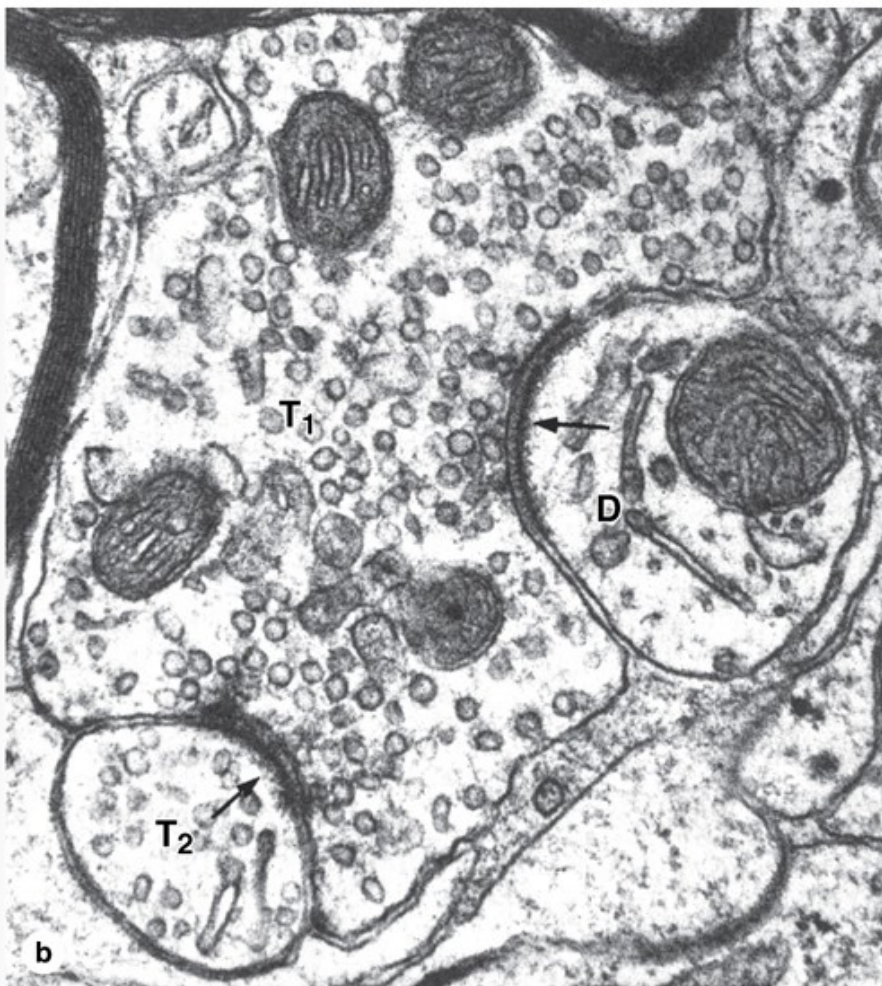
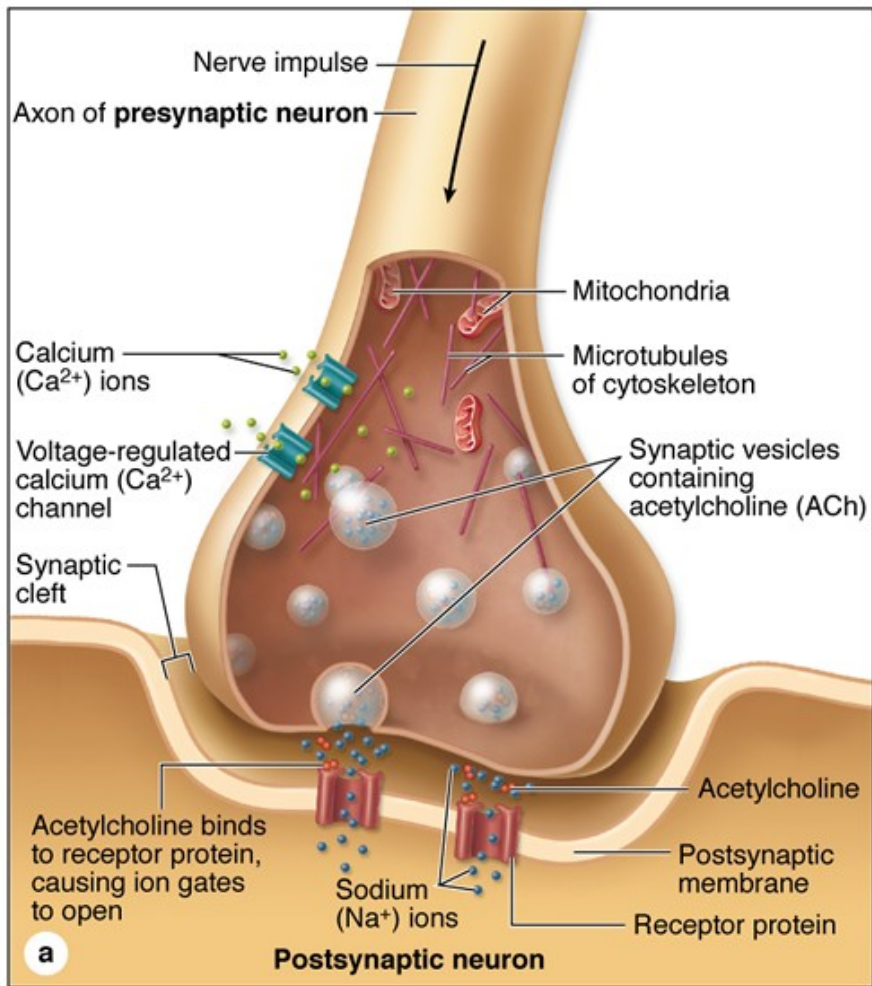
- Distal end of the axon branches, each branch terminating in a swelling or button called the terminal bouton.
- Boutons with neurotransmitter-containing synaptic vesicles and numerous mitochondria.

• Synaptic gap/cleft. Separation (20-30 nm) between pre- and postsynaptic cells.

• Postsynaptic component

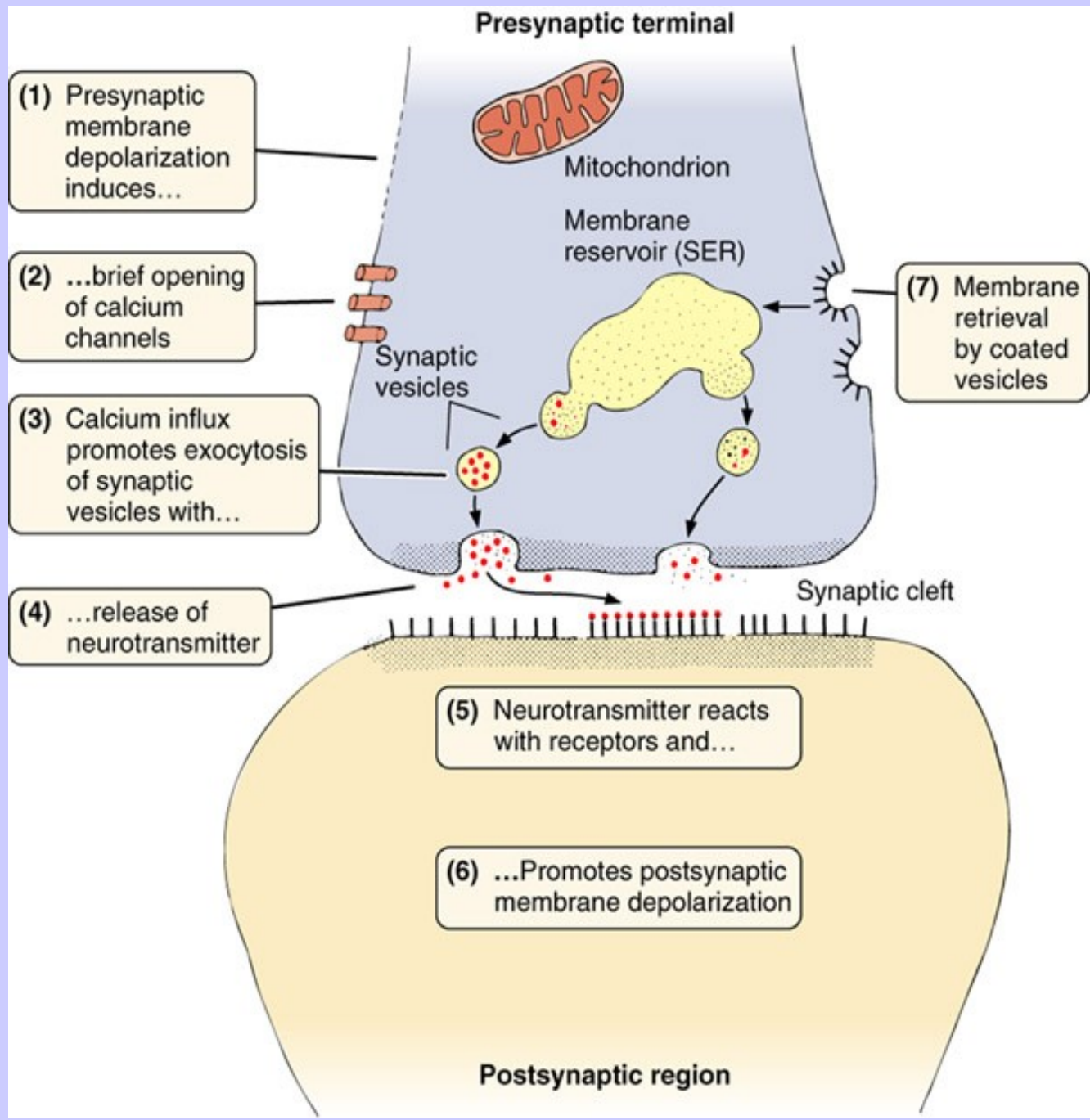
- Formed by the membrane of the postsynaptic neuron or muscle cell and contains receptors for neurotransmitters
 - Membrane shows a postsynaptic density or thickening on its cyto-plasmic side.
- "Bouton-like" swellings along the length of an axon, allow a single axon to contact many distant cells. Common in smooth muscle innervation.





(a) Diagram showing a synapse releasing neurotransmitters by exocytosis from the terminal bouton. Presynaptic terminals always contain a large number of **synaptic vesicles** containing neurotransmitters, numerous **mitochondria**, and smooth ER as a source of new membrane. Some neurotransmitters are synthesized in the cell body and then transported in vesicles to the presynaptic terminal. Upon arrival of a nerve impulse, voltage-regulated Ca^{2+} channels permit Ca^{2+} entry, which triggers neurotransmitter release into the synaptic cleft. Excess membrane accumulating at the presynaptic region as a result of exocytosis is recycled by clathrin-mediated endocytosis, which is not depicted here.

(b) The TEM shows a large presynaptic terminal (T_1) filled with synaptic vesicles and asymmetric electron-dense regions around 20- to 30-nm-wide synaptic clefts (**arrows**). The postsynaptic membrane contains the neurotransmitter receptors and mechanisms to initiate an impulse at the postsynaptic neuron. The postsynaptic membrane on the right is part of a dendrite (D), associated with fewer vesicles of any kind, showing this to be an axodendritic synapse. On the left is another presynaptic terminal (T_2), suggesting an axoaxonic synapse with a role in modulating activity of the other terminal. (X35,000)



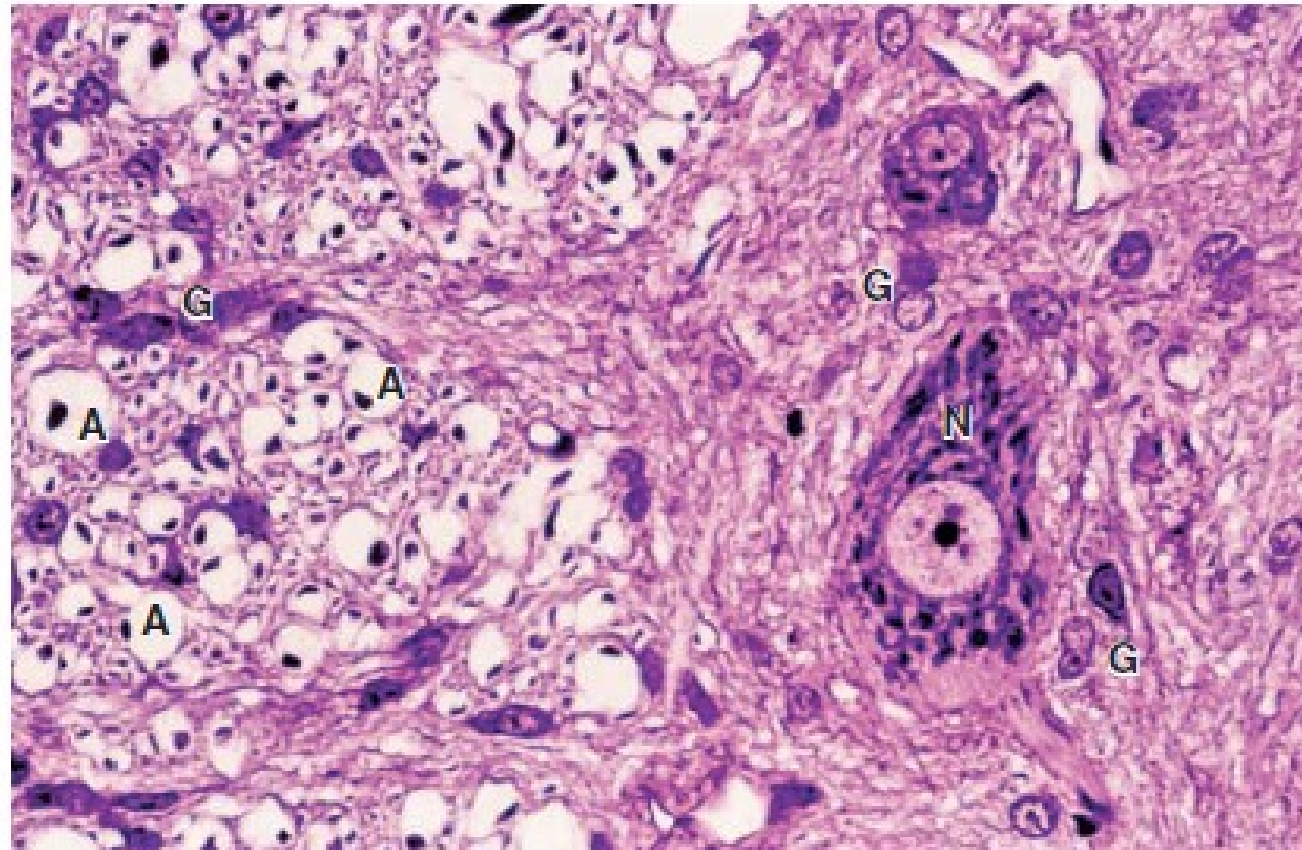
NERVE TISSUE

SUPPORTIVE (GLIAL) CELLS

- 10x more abundant than neurons
- Support and protect neurons
- **Supporting cells of the CNS**
 - *Astrocytes*
 - *Oligodendrocytes*
 - *Ependymal cells*
 - *Microglial cells*
- **Supporting cells of the PNS**
 - *Schwann cells*
 - *Satelite cells*

Glial Cell Type	Origin	Location	Main Functions
Oligodendrocyte	Neural tube	CNS	Myelin production, electrical insulation
Astrocyte	Neural tube	CNS	Structural and metabolic support of neurons, especially at synapses; repair processes
Ependymal cell	Neural tube	Line ventricles and central canal of CNS	Aid production and movement of CSF
Microglia	Bone marrow (monocytes)	CNS	Defense and immune-related activities
Schwann cell	Neural crest	Peripheral nerves	Myelin production, electrical insulation
Satellite cells (of ganglia)	Neural crest	Peripheral ganglia	Structural and metabolic support for neuronal cell bodies

FIGURE 9-14 White versus gray matter.

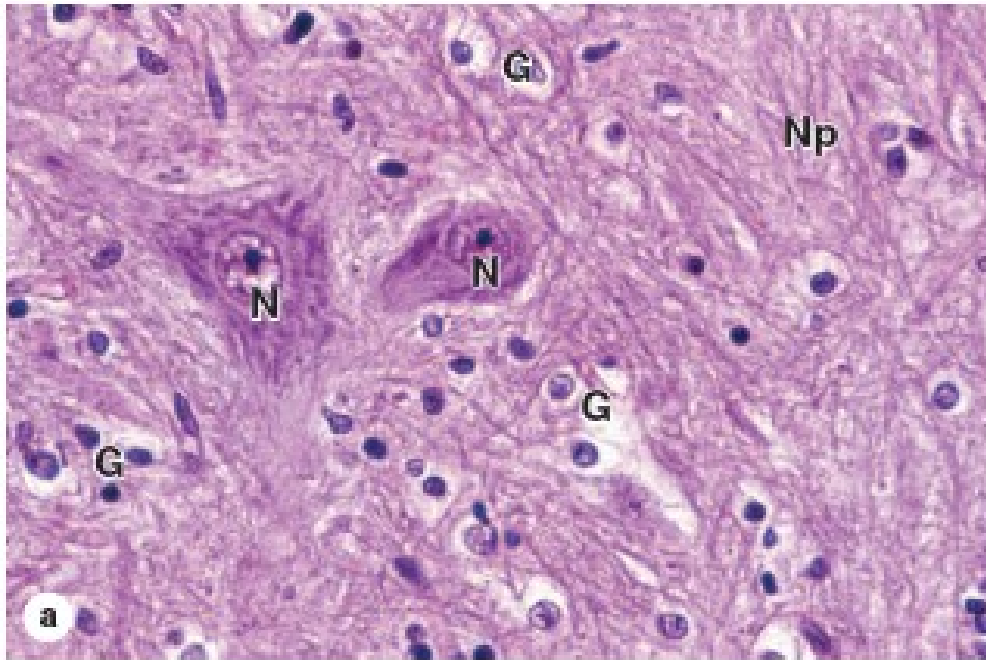


A cross section of H&E-stained spinal cord shows the transition between white matter (left region) and gray matter (right). The gray matter has many glial cells (G), neuronal cell bodies (N), and neuropil; white matter also contains glia (G) but consists mainly of axons (A) whose myelin sheaths were lost during preparation, leaving the round empty spaces shown. Each such space surrounds a dark-stained spot that is a small section of the axon. (X400)

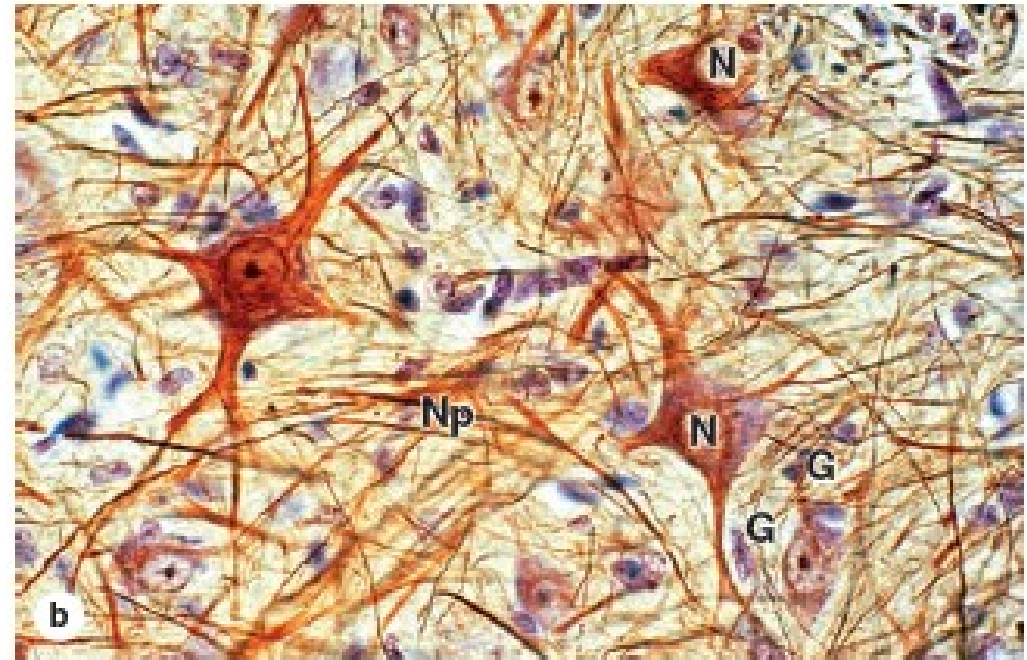
White matter – axons, glial cells

Grey matter – glial cells, neuronal cell bodies, neuropil

FIGURE 9–8 Neurons, neuropil, and the common glial cells of the CNS.



(a) Most neuronal cell bodies (N) in the CNS are larger than the much more numerous glial cells (G) that surround them. The various types of glial cells and their relationships with neurons are difficult to distinguish by most routine light microscopic methods. However, oligodendrocytes have condensed, rounded nuclei and unstained cytoplasm due to very abundant Golgi complexes, which stain poorly and are very likely represented by the cells with

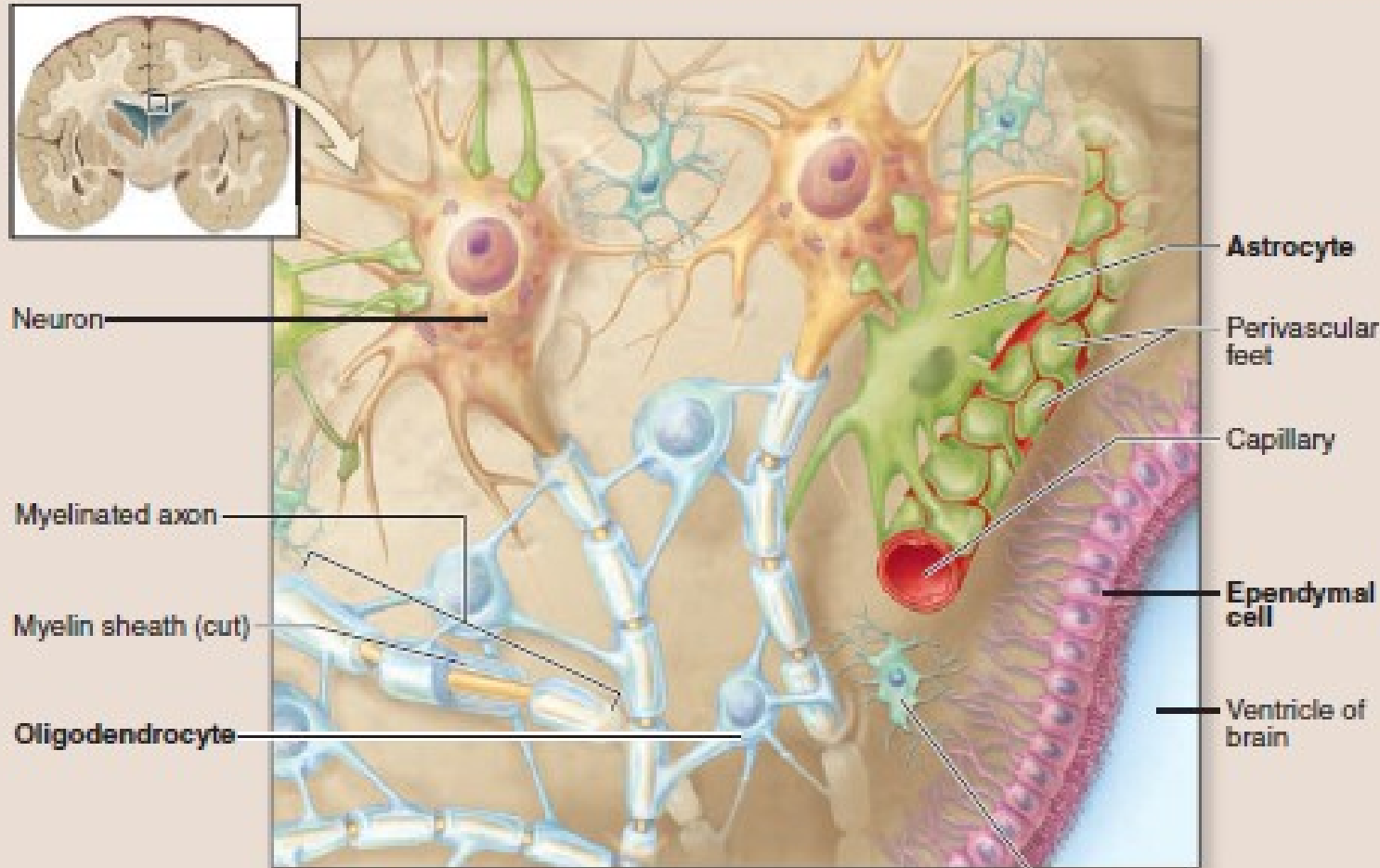


those properties seen here. The other glial cells seen here similar in overall size, but with very little cytoplasm and more elongated or oval nuclei, are mostly astrocytes. Routine H&E staining does not allow neuropil to stand out well. (X200; H&E)

(b) With the use of gold staining for neurofibrils, neuropil (Np) is more apparent. (X200; Gold chloride and hematoxylin)

Neuropil – dense network of astrocyte processes, axons and dendrites in gray matter.

FIGURE 9–9 Glial cells of the CNS and PNS.



Functions of Astrocyte

1. Helps form the blood-brain barrier
2. Regulates interstitial fluid composition
3. Provides structural support and organization to the central nervous system (CNS)
4. Assists with neuronal development
5. Replicates to occupy space of dying neurons

Functions of Ependymal Cell

1. Lines ventricles of brain and central canal of spinal cord
2. Assists in production and circulation of cerebrospinal fluid (CSF)

Functions of Microglial Cell

1. Phagocytic cells that move through the CNS
2. Protects the CNS by engulfing infectious agents and other potential harmful substances

Functions of Oligodendrocyte

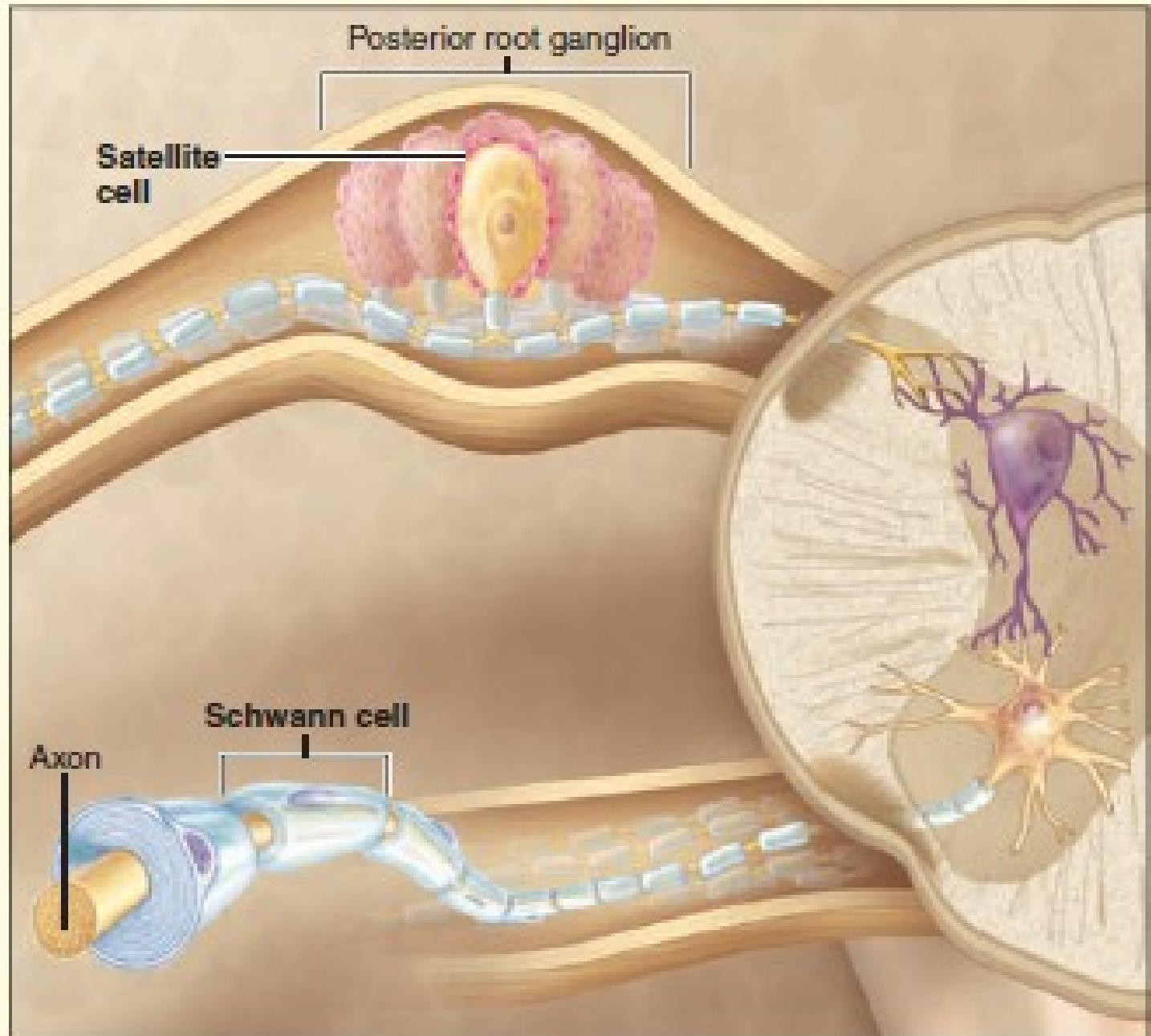
1. Myelinates and insulates CNS axons
2. Allows faster action potential propagation along axons in the CNS

Functions of Satellite Cell

1. Electrically insulates PNS cell bodies.
2. Regulates nutrient and waste exchange for cell bodies in ganglia

Functions of Neurolemmocyte

1. Surround and insulate PNS axons and myelinate those having large diameters
2. Allows for faster action potential propagation along an axon in the PNS



NERVE TISSUE

SUPPORTIVE CELLS

- Supporting cells of the CNS
- Astrocytes
 - Stellate morphology
 - Types:
 - Fibrous astrocytes in white matter
 - Protoplasmic astrocytes in gray matter
 - Functions:
 - Physical support
 - Transport nutrients
 - Maintain ionic homeostasis
 - Take up neurotransmitters
 - Form glial scars (gliosis)

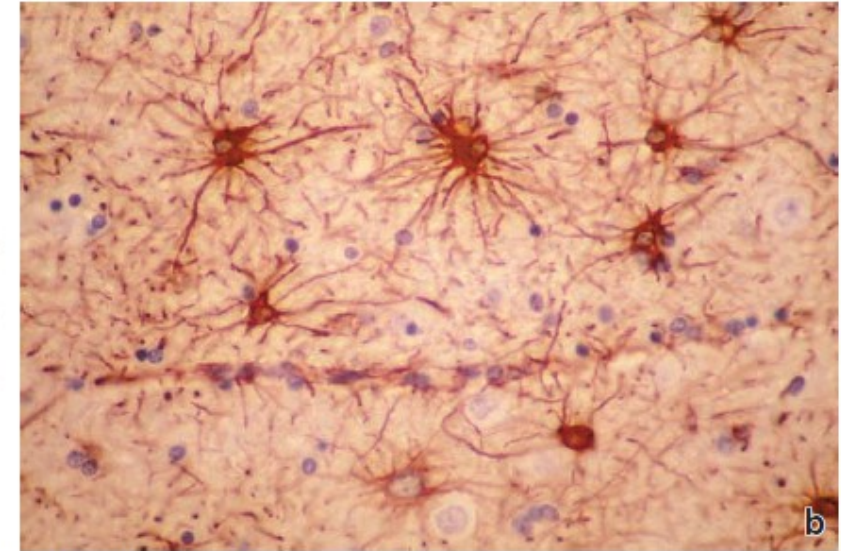
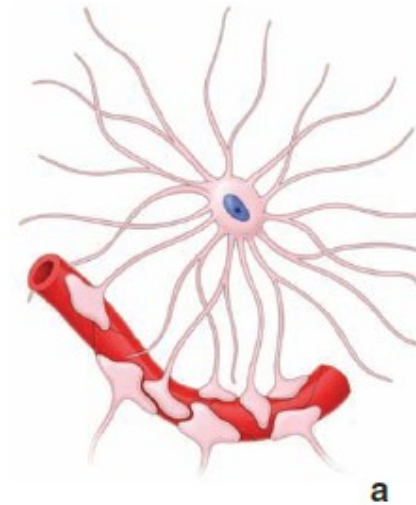


FIGURE 12.18 ▲ Fibrous astrocytes in the white matter of the brain. **a.** Schematic drawing of a fibrous astrocyte in the white matter of the brain. **b.** Photomicrograph of the white matter of the brain, showing the extensive radiating cytoplasmic processes (for which astrocytes are named). They are best visualized, as shown here, with immunostaining methods that use antibodies against GFAP. $\times 220$. (Reprinted with permission from Fuller GN, Burger PC. Central nervous system. In: Sternbera SS, ed. Histology for Pathologists. Philadelphia: Lippincott-Raven, 1997.)

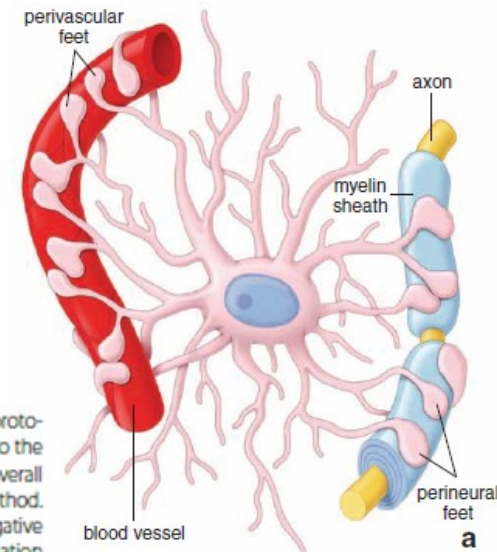


FIGURE 12.17 ▲ Protoplasmic astrocyte in the gray matter of the brain. **a.** This schematic drawing shows the foot processes of the protoplasmic astrocyte terminating on a blood vessel and the axonal process of a nerve cell. The foot processes terminating on the blood vessel contribute to the blood-brain barrier. The bare regions of the vessel as shown in the drawing would be covered by processes of neighboring astrocytes, thus forming the overall barrier. **b.** This laser-scanning confocal image of protoplasmic astrocyte in the gray matter of the dentate gyrus was visualized by intracellular labeling method. In lightly fixed tissue slices, selected astrocytes were impaled and iontophoretically injected with fluorescent dye (Alexa Fluor 568) using pulses of negative current. Note the density and spatial distribution of cell processes. $\times 480$. (Reprinted with permission from Bushong EA, Martone ME, Ellisman MH. Examination of the relationship between astrocyte morphology and laminar boundaries in the molecular layer of adult dentate gyrus. *J Comp Neurol* 2003;462:241–251.)

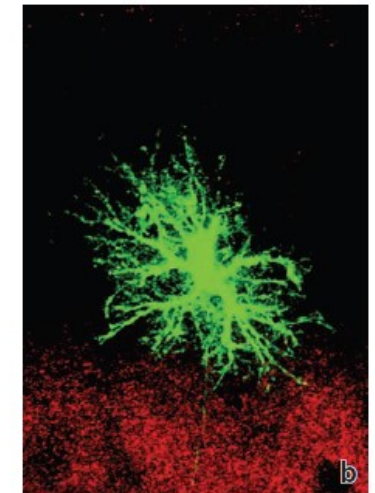
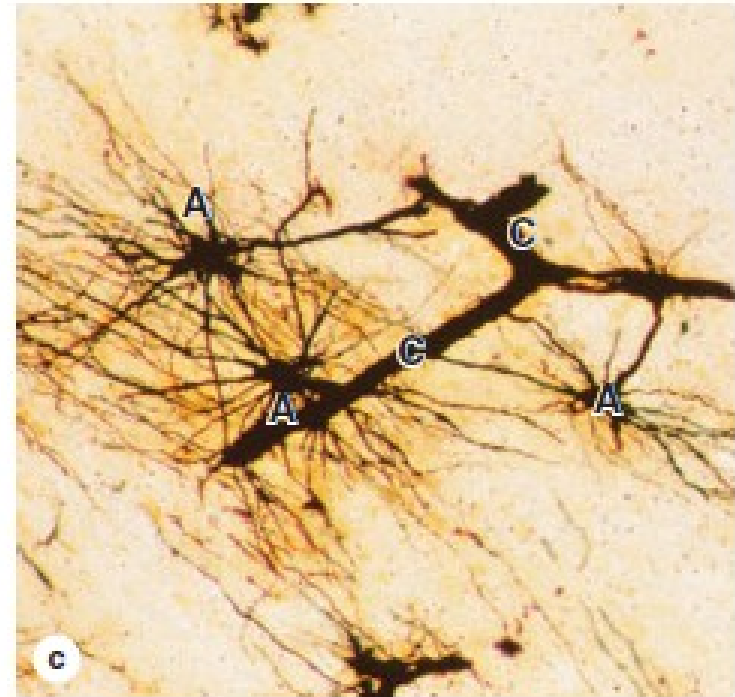
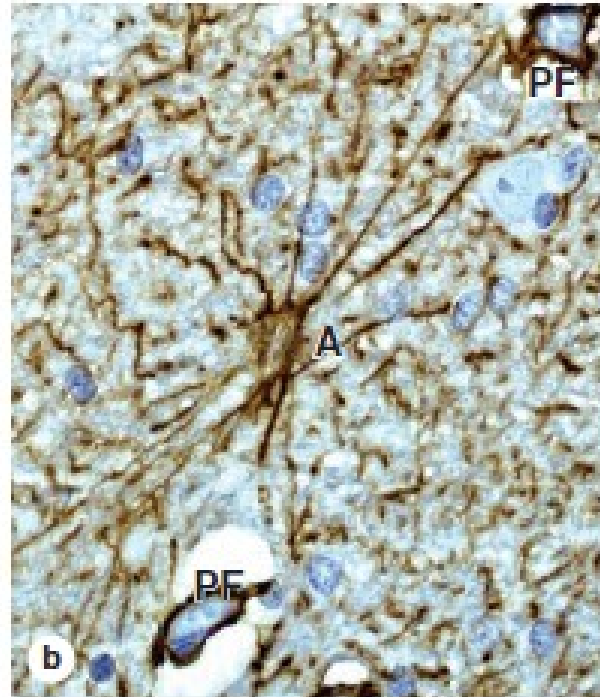
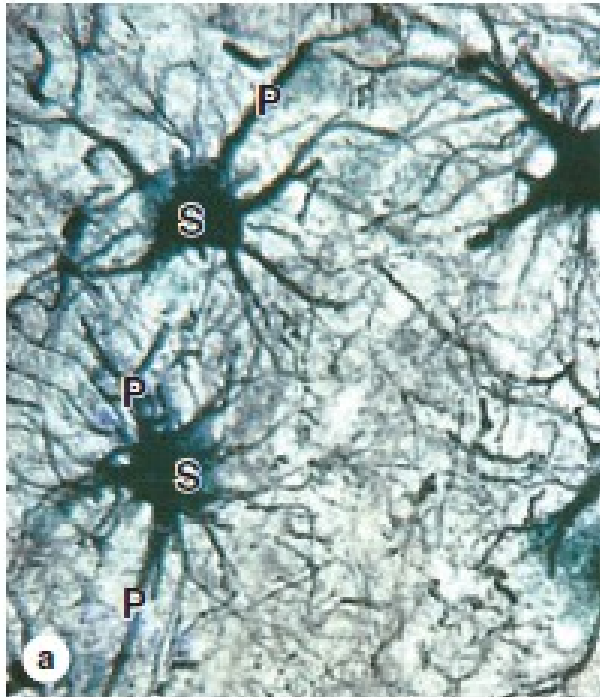


FIGURE 9–10 Astrocytes.



(a) Astrocytes are the most abundant glial cells of the CNS and are characterized by numerous cytoplasmic processes (P) radiating from the glial cell body or soma (S). Astrocytic processes are not seen with routine light microscope staining but are easily seen after gold staining. Morphology of the processes allows astrocytes to be classified as fibrous (relatively few and straight processes) or protoplasmic (numerous branching processes), but functional differences between these types are not clear. (X500; Gold chloride)

(b) All astrocytic processes contain intermediate filaments of GFAP, and antibodies against this protein provide a simple method to stain these cells, as seen here in a fibrous astrocyte (A) and its

processes. The small pieces of other GFAP-positive processes in the neuropil around this cell give an idea of the density of this glial cell and its processes in the CNS. Astrocytes form part of the blood-brain barrier (BBB) and help regulate entry of molecules and ions from blood into CNS tissue. Capillaries at the extreme upper right and lower left corners are enclosed by GFAP-positive perivascular feet (PF) at the ends of numerous astrocytic processes. (X500; Anti-GFAP immunoperoxidase and hematoxylin counterstain)

(c) A length of capillary (C) is shown here completely covered by silver-stained terminal processes extending from astrocytes (A). (X400; Rio Hortega silver)

NERVE TISSUE

SUPPORTIVE CELLS

- Supporting cells of the CNS
- *Oligodendrocytes*
 - Present in white and gray matter
 - Oligodendrocytes located in the white matter of the CNS produce the myelin sheath.
 - They can myelinate multiple axons

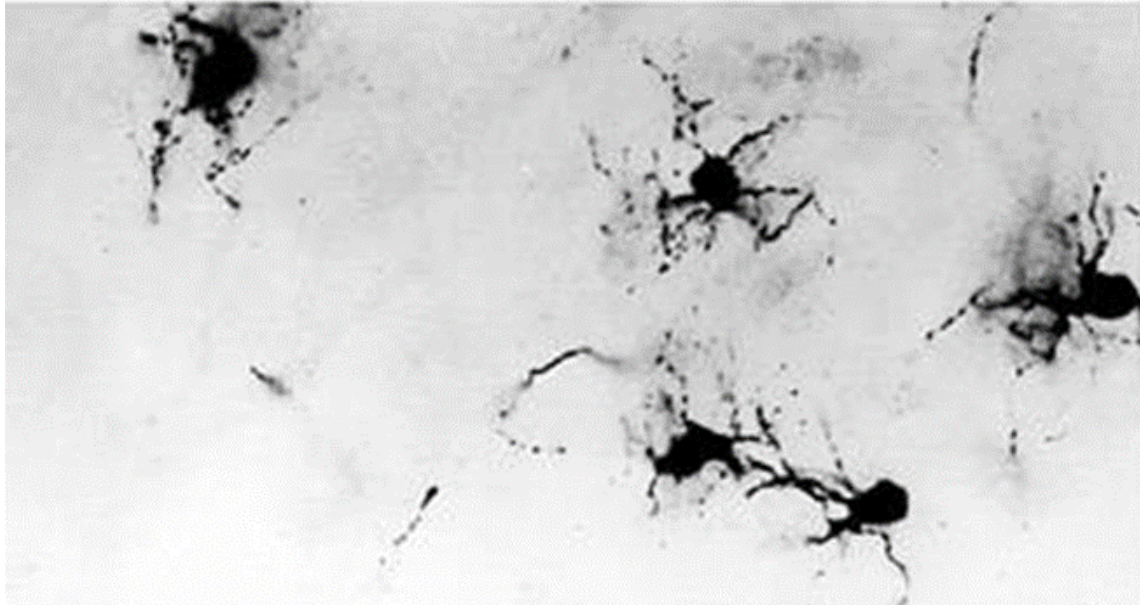
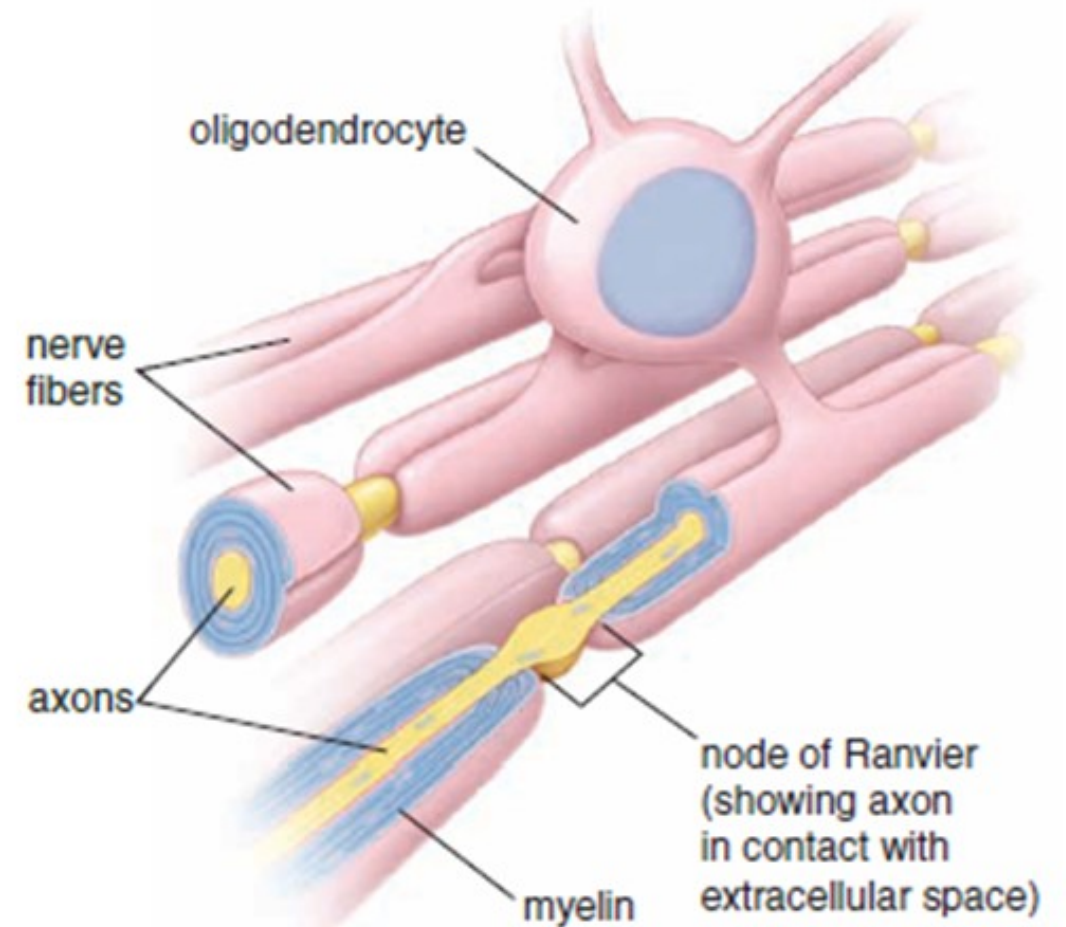
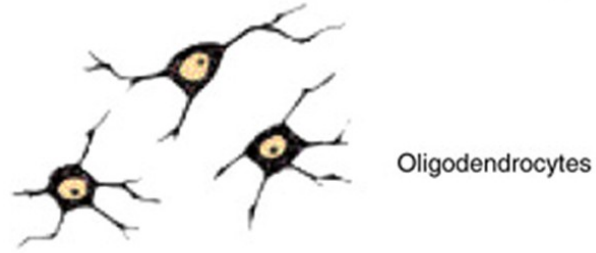


FIGURE 12.20 ▲ **Three-dimensional view of an oligodendrocyte as it relates to several axons.** Cytoplasmic processes from the oligodendrocyte cell body form flattened cytoplasmic sheaths that wrap around each of the axons. The relationship of cytoplasm and myelin is essentially the same as that of Schwann cells.

NERVE TISSUE

SUPPORTIVE CELLS

- Supporting cells of the CNS
- *Ependymal cells*
 - Line central canal of spinal cord and ventricles of brain
 - Cuboidal to columnar, with cilia and microvilli

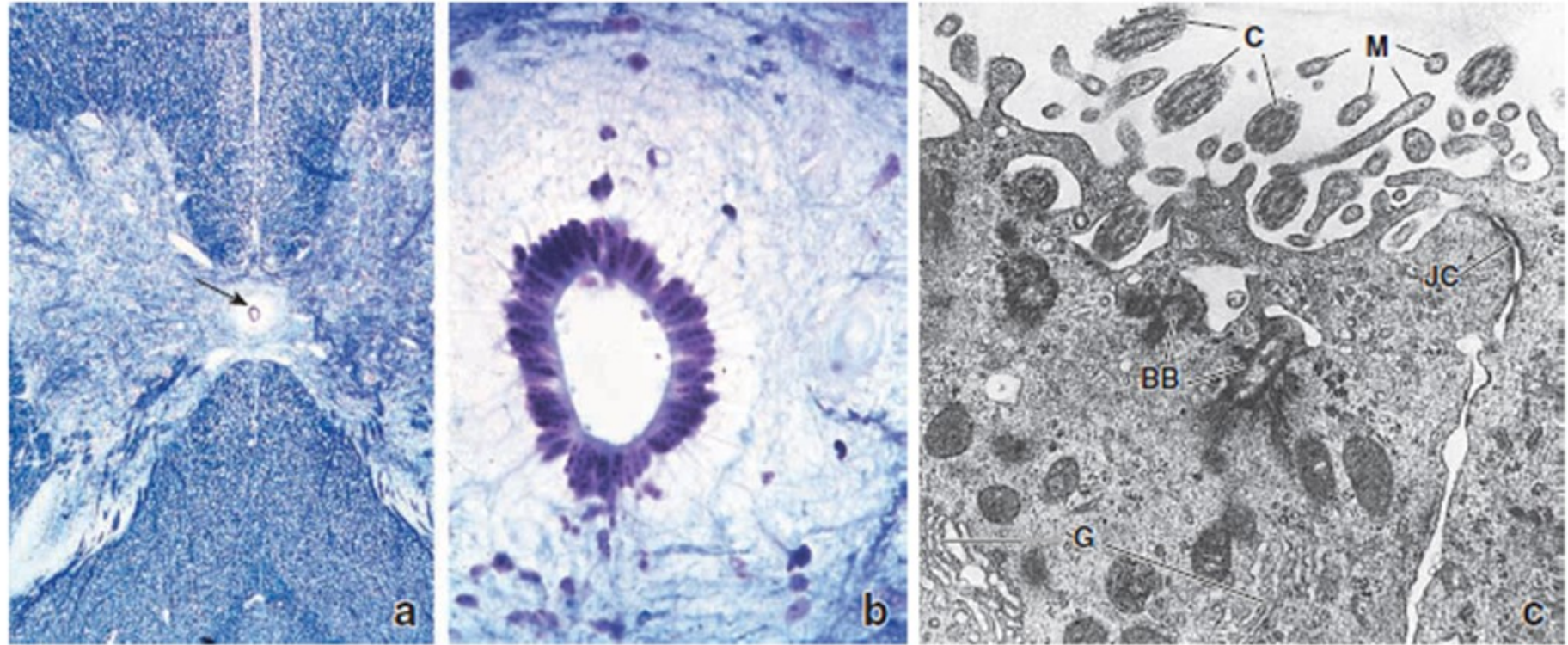
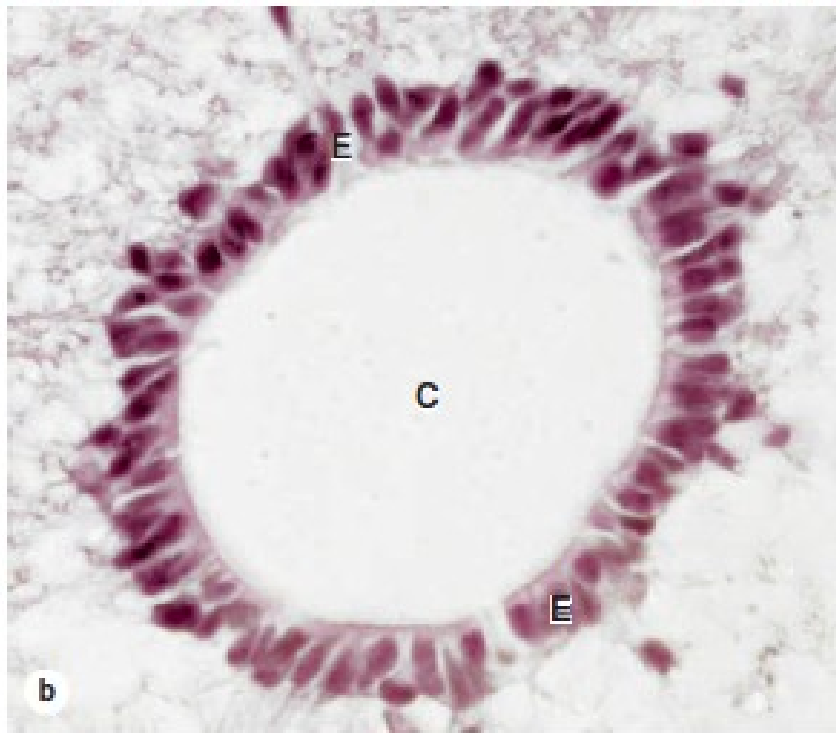
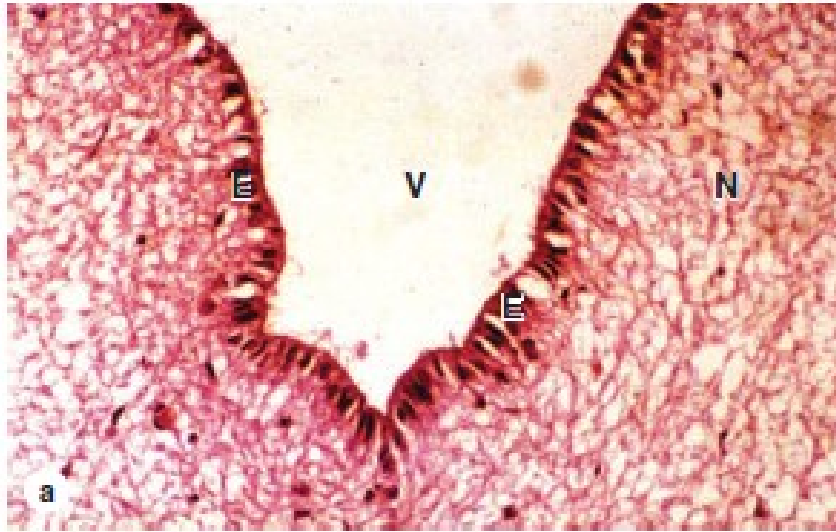


FIGURE 12.22 ▲ Ependymal lining of the spinal canal. **a.** Photomicrograph of the central region of the spinal cord stained with toluidine blue. The *arrow* points to the central canal. $\times 20$. **b.** At higher magnification, ependymal cells, which line the central canal, can be seen to consist of a single layer of columnar cells. $\times 340$. (Courtesy of Dr. George D. Pappas.) **c.** Transmission electron micrograph showing a portion of the apical region of two columnar ependymal cells. They are joined by a junctional complex (*JC*) that separates the lumen of the canal from the lateral intercellular space. The apical surface of the ependymal cells has both cilia (*C*) and microvilli (*M*). Basal bodies (*BB*) and a Golgi apparatus (*G*) within the apical cytoplasm are also visible. $\times 20,000$. (Courtesy of Dr. Paul Reier.)

FIGURE 9-11 Ependymal cells.



Ependymal cells are epithelial-like cells that form a single layer lining the fluid-filled ventricles and central canal of the CNS.

(a) Lining the ventricles of the cerebrum, columnar ependymal cells (E) extend cilia and microvilli from the apical surfaces into the ventricle (V). These modifications help circulate the CSF and monitor its contents. Ependymal cells have junctional complexes at their apical ends like those of epithelial cells but lack a basal lamina. The cells' basal ends are tapered, extending processes that branch and penetrate some distance into the adjacent neuropil (N). Other areas of ependyma are responsible for production of CSF. (X100; H&E)

(b) Ependymal cells (E) lining the central canal (C) of the spinal cord help move CSF in that CNS region. (X200; H&E)

NERVE TISSUE

SUPPORTIVE CELLS

- Supporting cells of the CNS
- *Microglia*
 - Small cells with short irregular processes, elongated nuclei
 - Originate from monocytes and have similar phagocytic function
 - Provide immune surveillance and produce immunomodulatory compounds

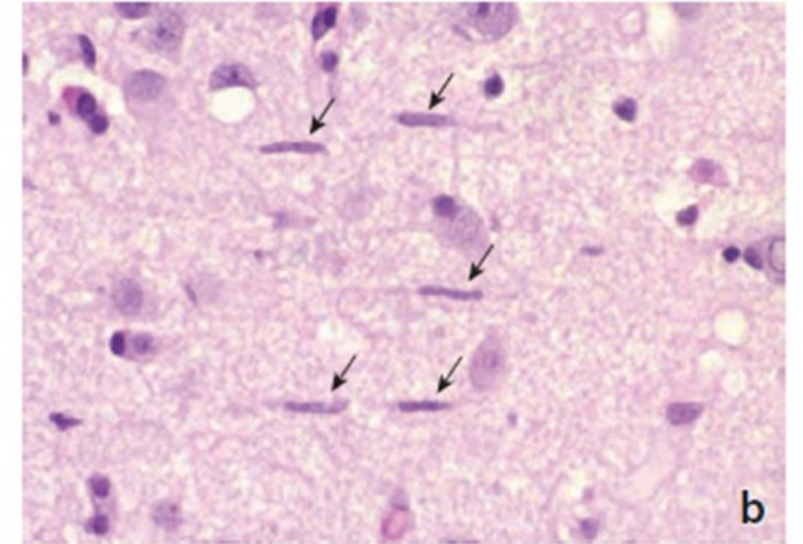
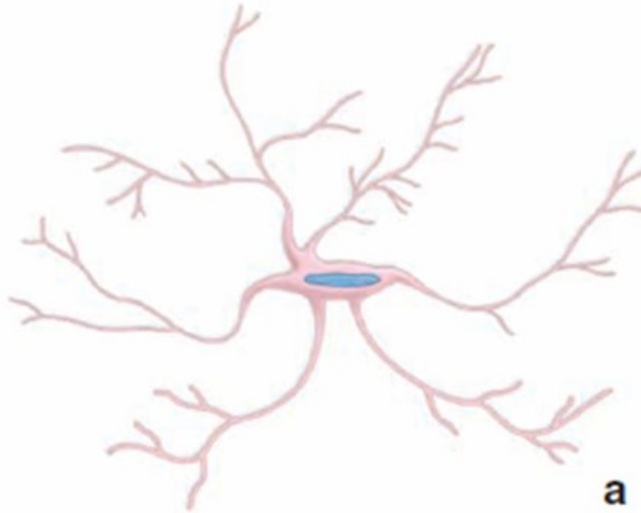


FIGURE 12.21 ▲ Microglial cell in the gray matter of the brain. **a.** This diagram shows the shape and characteristics of a microglial cell. Note the elongated nucleus and relatively few processes emanating from the body. **b.** Photomicrograph of microglial cells (*arrows*) showing their characteristic elongated nuclei. The specimen was obtained from an individual with diffuse microgliosis. In this condition, the microglial cells are present in large numbers and are readily visible in a routine H&E preparation. $\times 420$. (Reprinted with permission from Fuller GN, Burger PC. Central nervous system. In: Sternberg SS, ed. Histology for Pathologists. Philadelphia: Lippincott-Raven, 1997.)

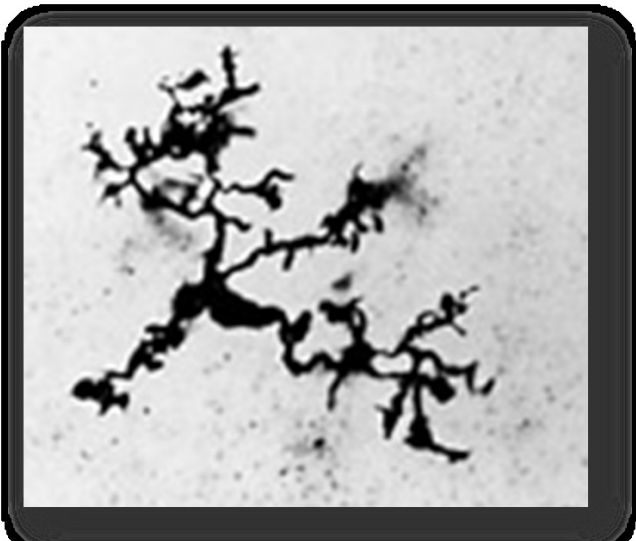
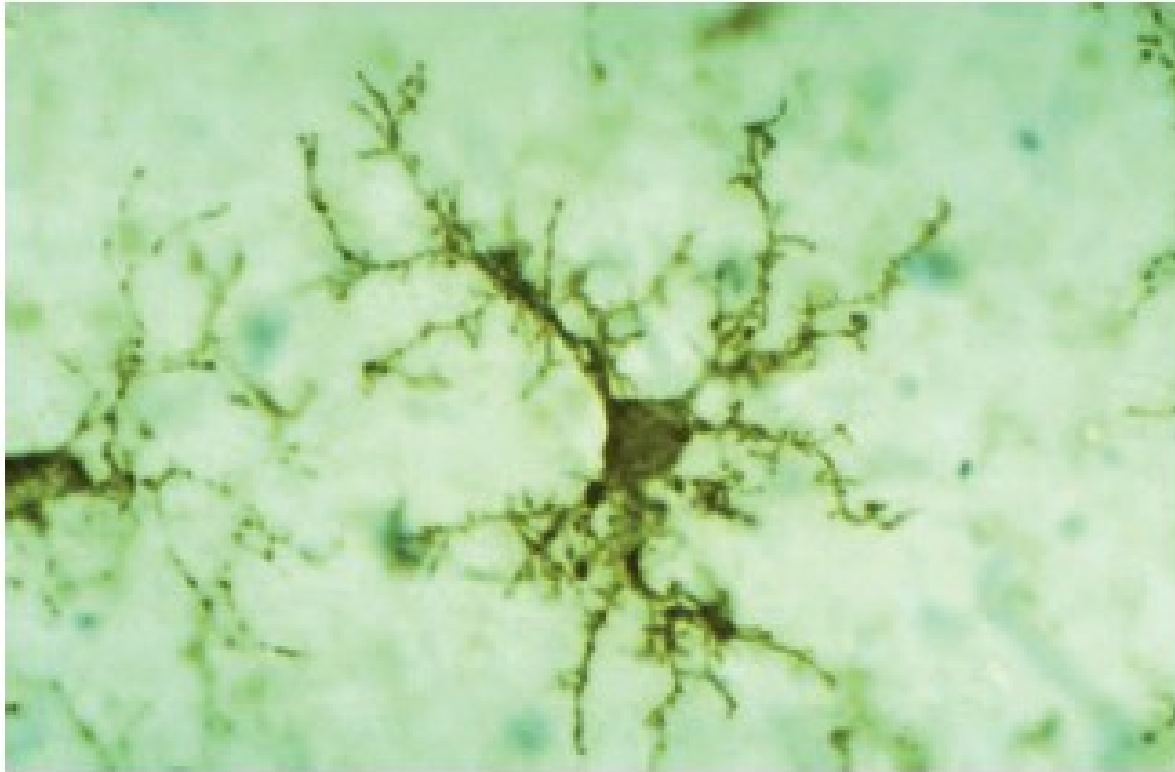


FIGURE 9-12 Microglial cells.



Microglia are monocyte-derived, antigen-presenting cells of the CNS, less numerous than astrocytes but nearly as common as neurons and evenly distributed in both gray and white matter. By immunohistochemistry, here using a monoclonal antibody against human leukocyte antigens (HLA) of immune-related cells, the short branching processes of microglia can be seen. Routine staining demonstrates only the small dark nuclei of the cells. Unlike other glia of the CNS, microglia are not interconnected; they are motile cells, constantly used in immune surveillance of CNS tissues. When activated by products of cell damage or by invading microorganisms, the cells retract their processes, begin phagocytosing the damage- or danger-related material, and behave as antigen-presenting cells. (X500; Antibody against HLA-DR and peroxidase)

(Used with permission from Wolfgang Streit, Department of Neuroscience, University of Florida College of Medicine, Gainesville.)

NERVE TISSUE

Main components of the peripheral nervous system

- Nerves.
 - Bundle of nerve fibres (axons) surrounded by glial cells (Schwann cells) and connective tissue
- Ganglia.
 - Collections of neuron cell bodies
- Specialized nerve endings

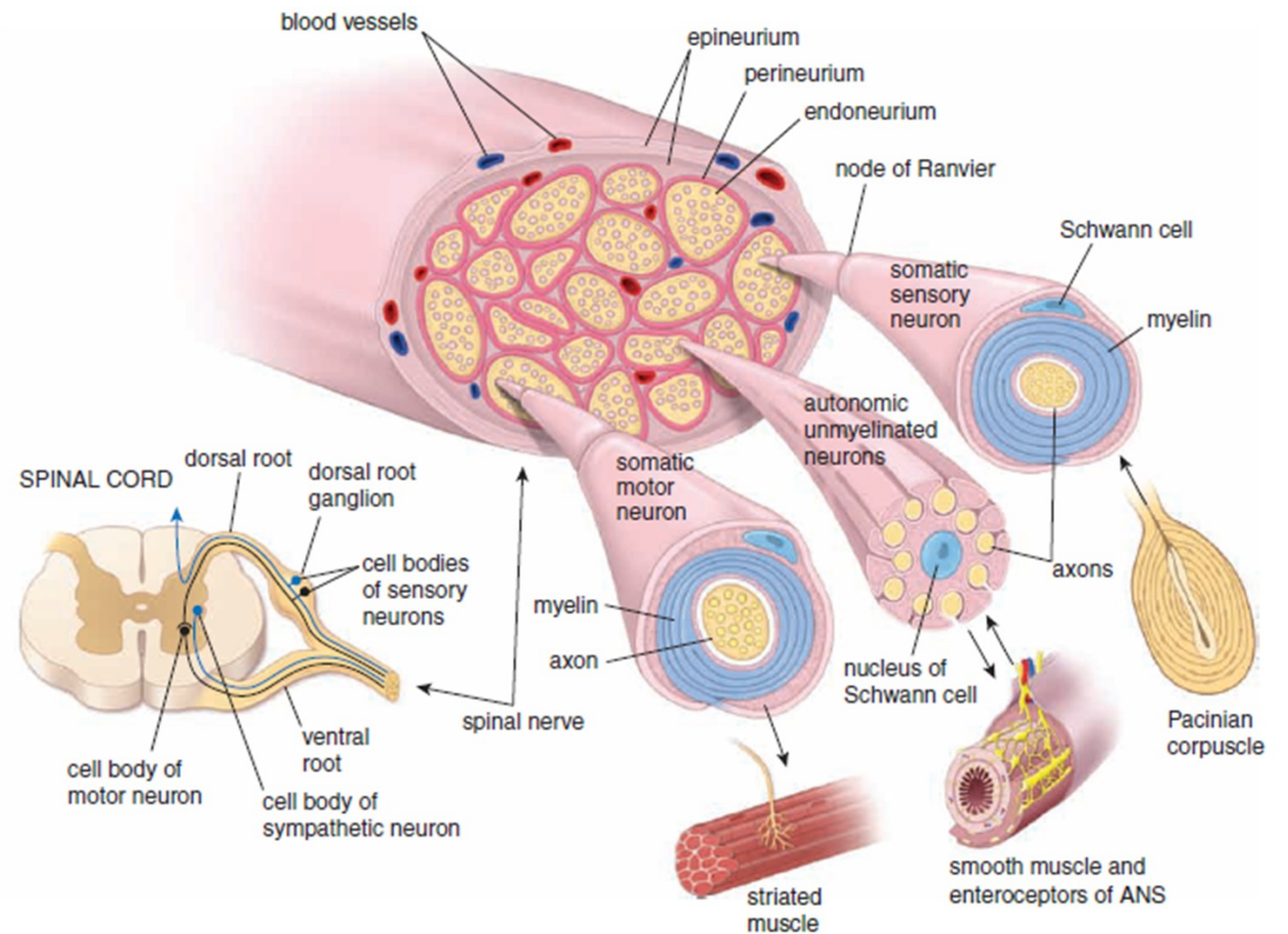


FIGURE 12.3 ▲ Schematic diagram showing arrangement of motor and sensory neurons. The cell body of a motor neuron is located in the ventral (anterior) horn of the gray matter of the spinal cord. Its axon, surrounded by myelin, leaves the spinal cord via a ventral (anterior) root and becomes part of a spinal nerve that carries it to its destination on striated (skeletal) muscle fibers. The sensory neuron originates in the skin within a receptor (here, a Pacinian corpuscle) and continues as a component of a spinal nerve, entering the spinal cord via the dorsal (posterior) root. Note the location of its cell body in the dorsal root ganglion (sensory ganglion). A segment of the spinal nerve is enlarged to show the relationship of the nerve fibers to the surrounding connective tissue (endoneurium, perineurium, and epineurium). In addition, segments of the sensory, motor, and autonomic unmyelinated neurons have been enlarged to show the relationship of the axons to the Schwann cells. ANS, autonomic nervous system.

NERVE TISSUE

SUPPORTIVE CELLS

- Supporting cells of the PNS
 - *Satellite cells*
 - surround cell bodies in ganglia

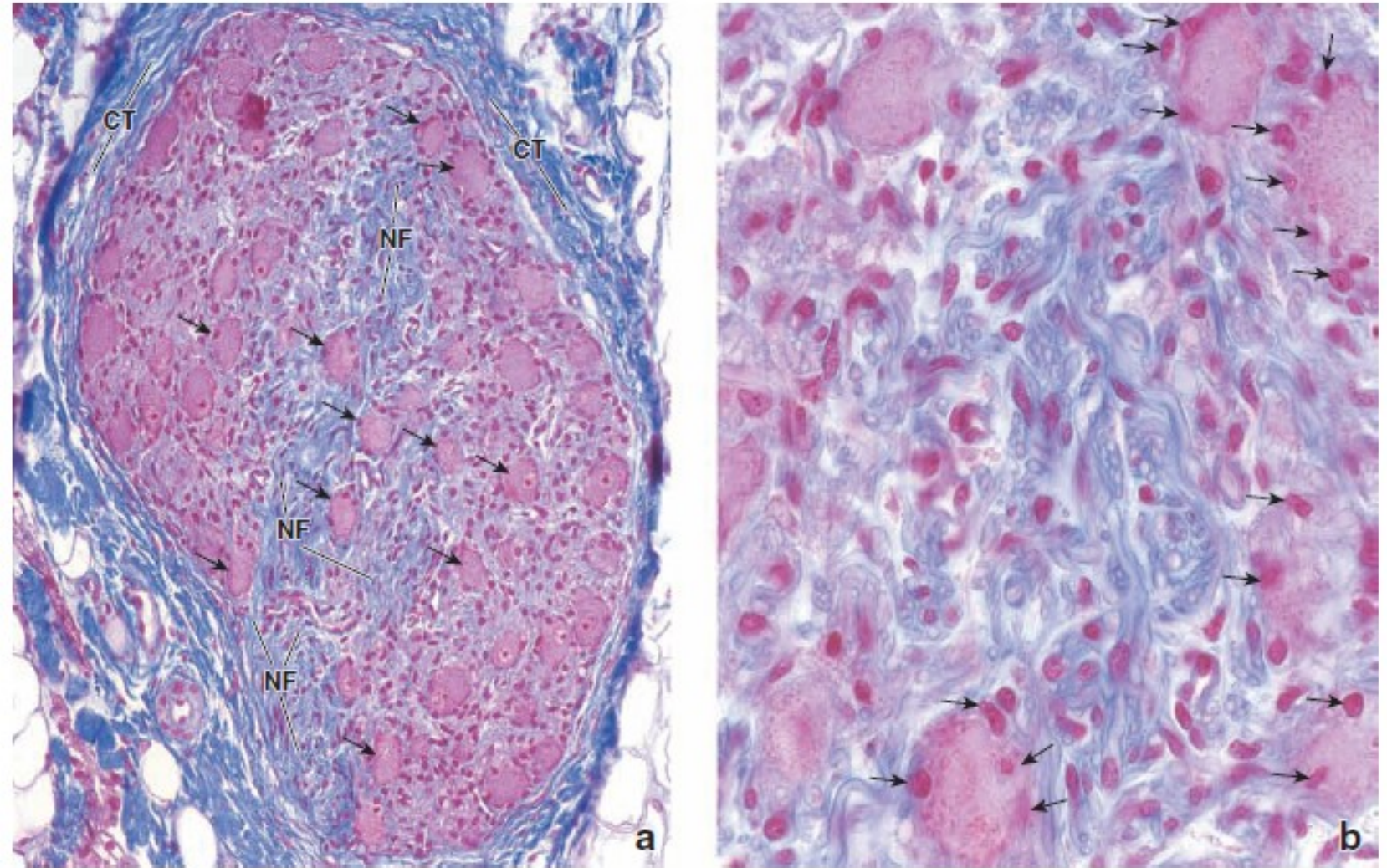
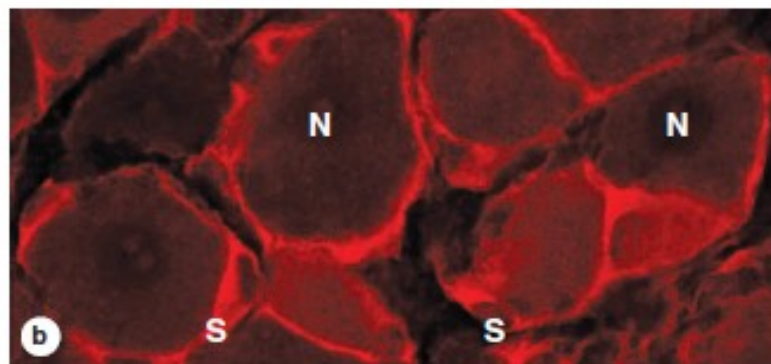
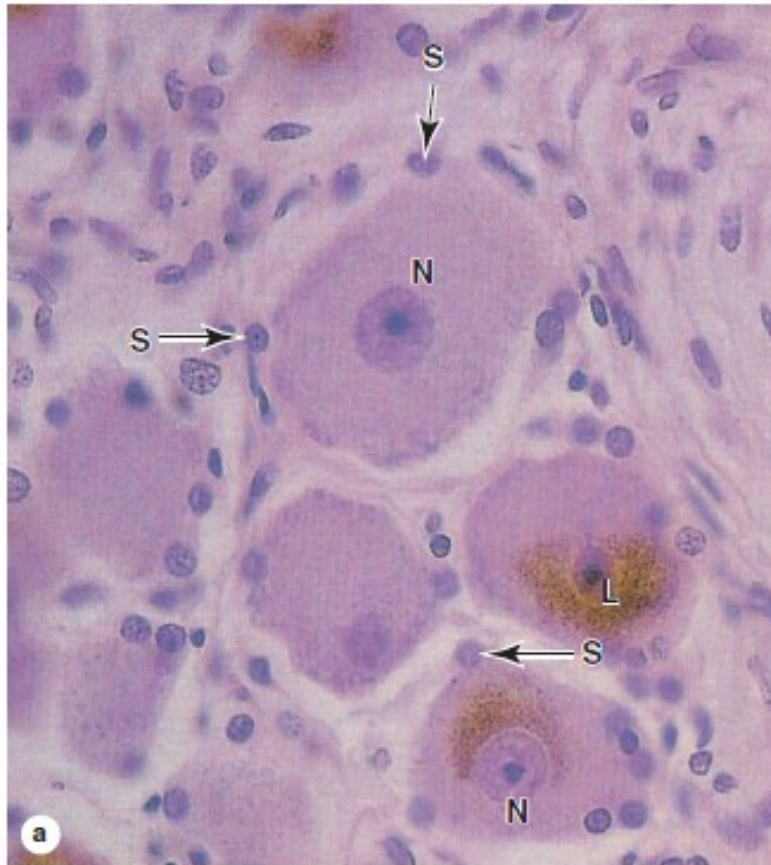


FIGURE 12.16 ▲ Photomicrograph of a nerve ganglion. a. Photomicrograph showing a ganglion stained by the Mallory-Azan method. Note the large nerve cell bodies (*arrows*) and nerve fibers (NF) in the ganglion. Satellite cells are represented by the very small nuclei at the periphery of the neuronal cell bodies. The ganglion is surrounded by a dense irregular connective tissue capsule (CT) that is comparable to, and continuous with, the epineurium of the nerve. $\times 200$. **b.** Higher magnification of the ganglion, showing individual axons and a few neuronal cell bodies with their satellite cells (*arrows*). The nuclei in the region of the axons are mostly Schwann cell nuclei. $\times 640$.

FIGURE 9–13 Satellite cells around neurons of ganglia in the PNS.



Satellite cells are very closely associated with neuronal cell bodies in sensory and autonomic ganglia of the PNS and support these cells in various ways.

(a) Nuclei of the many satellite cells (**S**) surrounding the perikarya of neurons (**N**) in an autonomic ganglion can be seen by light microscopy, but their cytoplasmic extensions are too thin to see with H&E staining. These long-lived neurons commonly accumulate brown lipofuscin (**L**). (X560; H&E)

(b) Immunofluorescent staining of satellite cells (**S**) reveals the cytoplasmic sheets extending from these cells and surrounding the neuronal cell bodies (**N**). The layer of satellite cells around each soma is continuous with the myelin sheath around the axon. Like the effect of Schwann cells on axons, satellite glial cells insulate, nourish, and regulate the microenvironment of the neuronal cell bodies. (X600; Rhodamine red-labeled antibody against glutamine synthetase)

(Used with permission from Menachem Hanani, Laboratory of Experimental Surgery, Hadassah University Hospital, Jerusalem, Israel.)

NERVE TISSUE

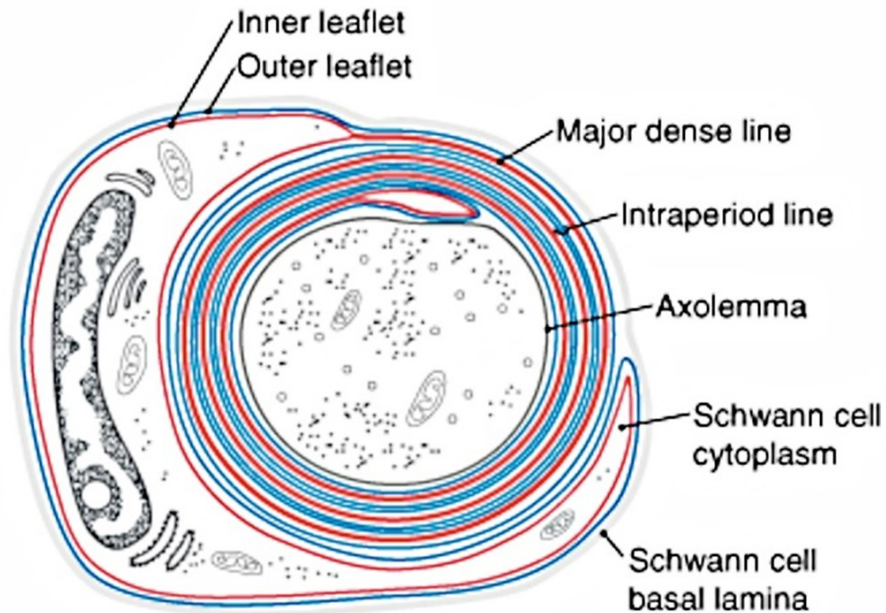
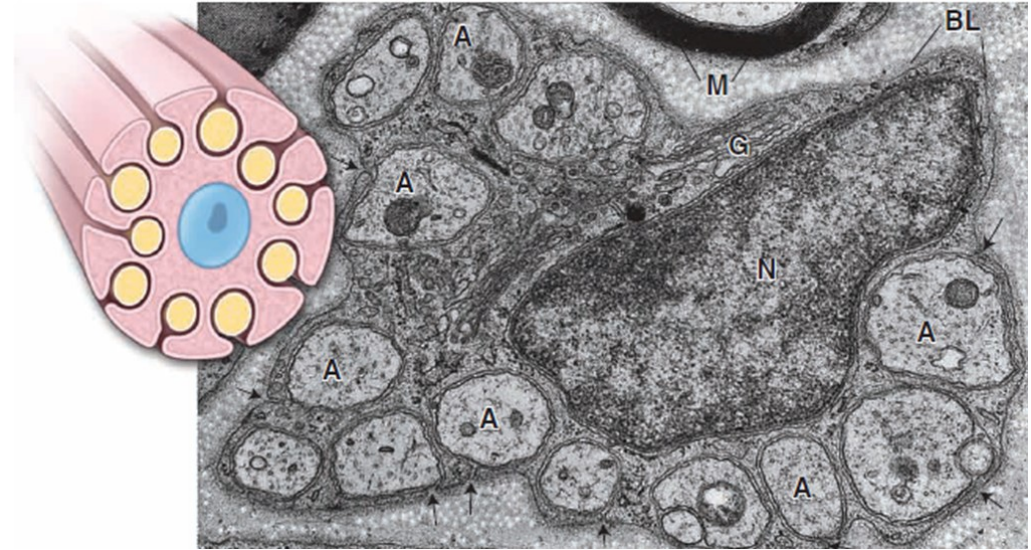SUPPORTIVE CELLS

- Supporting cells of the PNS

- Schwann cells*

- Surround unmyelinated axons. Numerous axons indent the Schwann cell cytoplasm and, therefore, are surrounded by a single plasma membrane.

- Produce the myelin sheath around axons



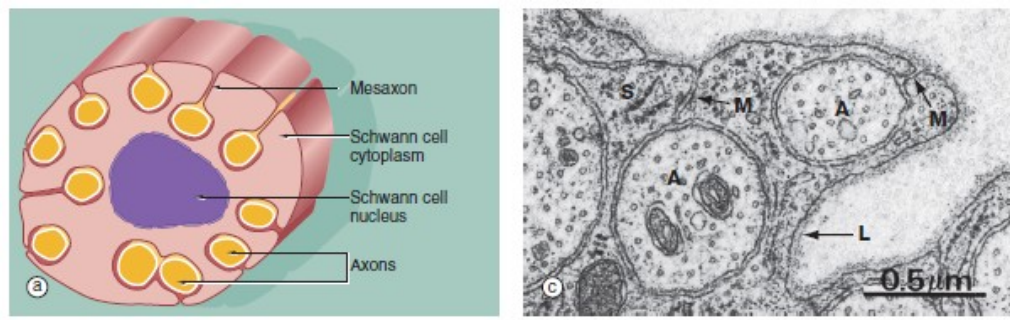


FIG. 7.5 Non-myelinated nerve fibres
(a) Diagram (b) EM $\times 15\,000$ (c) EM $\times 36\,000$

The relationship of non-myelinated axons with their supporting Schwann cell is illustrated in diagram (a). One or more axons become longitudinally invaginated into the Schwann cell so that each axon is embedded in a channel, invested by the Schwann cell plasma membrane and cytoplasm. The Schwann cell plasma membrane becomes apposed to itself along the opening of the channel, thus effectively sealing the axon within an extracellular compartment bounded by the Schwann cell. The zone of apposition of the Schwann cell membrane is called the *mesaxon*. Note that more than one axon may occupy a single channel within the Schwann cell. Each Schwann cell extends for only a short distance along the nerve tract, and at its termination the ensheathment is continued by another Schwann cell with which it interdigitates closely end to end.

At low magnification in micrograph (b), non-myelinated axons *A* of various sizes are seen ensheathed by Schwann cells *S*; one of the Schwann cells has been sectioned transversely through its nucleus *N*. Note the variable number of axons enclosed by each Schwann cell. Delicate cytoplasmic extensions of fibroblasts *F* can be seen in the endoneurium.

At high magnification in micrograph (c), part of the cytoplasm of a Schwann cell *S* is shown ensheathing several axons *A*; axons are readily identified by their content of smooth endoplasmic reticulum and microtubules, seen in cross-section. Several mesaxons *M* can be seen. The external surface of the Schwann cell is bounded by an external lamina *L*, equivalent to lamina densa in epithelia.

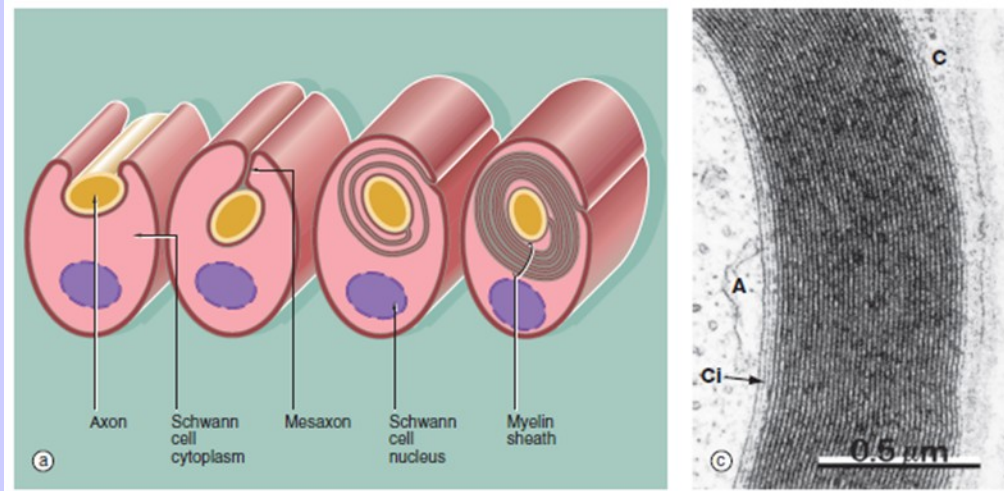


FIG. 7.6 Myelinated nerve fibre
(a) Diagram (b) EM $\times 20\,000$ (c) EM $\times 46\,000$

In peripheral nerves, *myelination* begins with the invagination of a single nerve axon into a Schwann cell; a mesaxon is then formed. As myelination proceeds, the mesaxon rotates around the axon thereby enveloping the axon in concentric layers of Schwann cell cytoplasm and plasma membrane. The cytoplasm is then excluded so that the inner leaflets of plasma membrane fuse with each other and the axon becomes surrounded by multiple layers of membrane which together constitute the *myelin sheath*. The single segment of myelin produced by each Schwann cell is termed an *internode*; this ensheathes the axon between one *node of Ranvier* and the next (see Fig. 7.7).

In micrograph (b), a myelinated nerve fibre from the PNS is sectioned transversely at the level of the nucleus of an ensheathing Schwann cell *N*. The single axon *A* is enveloped by many layers of fused Schwann cell plasma membrane forming the myelin sheath *My*.

Micrograph (c) shows that the compact myelin sheath consists of many regular layers of membrane. The darker lines, termed the *major dense lines*, arise by fusion of cytoplasmic leaflets. The intervening intraperiod lines represent closely apposed external membrane leaflets. The substantial lipid content of these modified membrane layers insulate the underlying axon *A*, preventing ion fluxes across the axonal plasma membrane except at the nodes of Ranvier. The main bulk of the Schwann cell cytoplasm *C* encircles the myelin sheath. However, a thin layer of Schwann cell cytoplasm also persists immediately surrounding the axon *Cl*.

In the CNS, oligodendrocytes are responsible for myelination; a single oligodendrocyte, however, forms multiple myelin internodes which contribute to the ensheathment of as many as 50 individual axons (see Fig. 20.3).

NERVE TISSUE

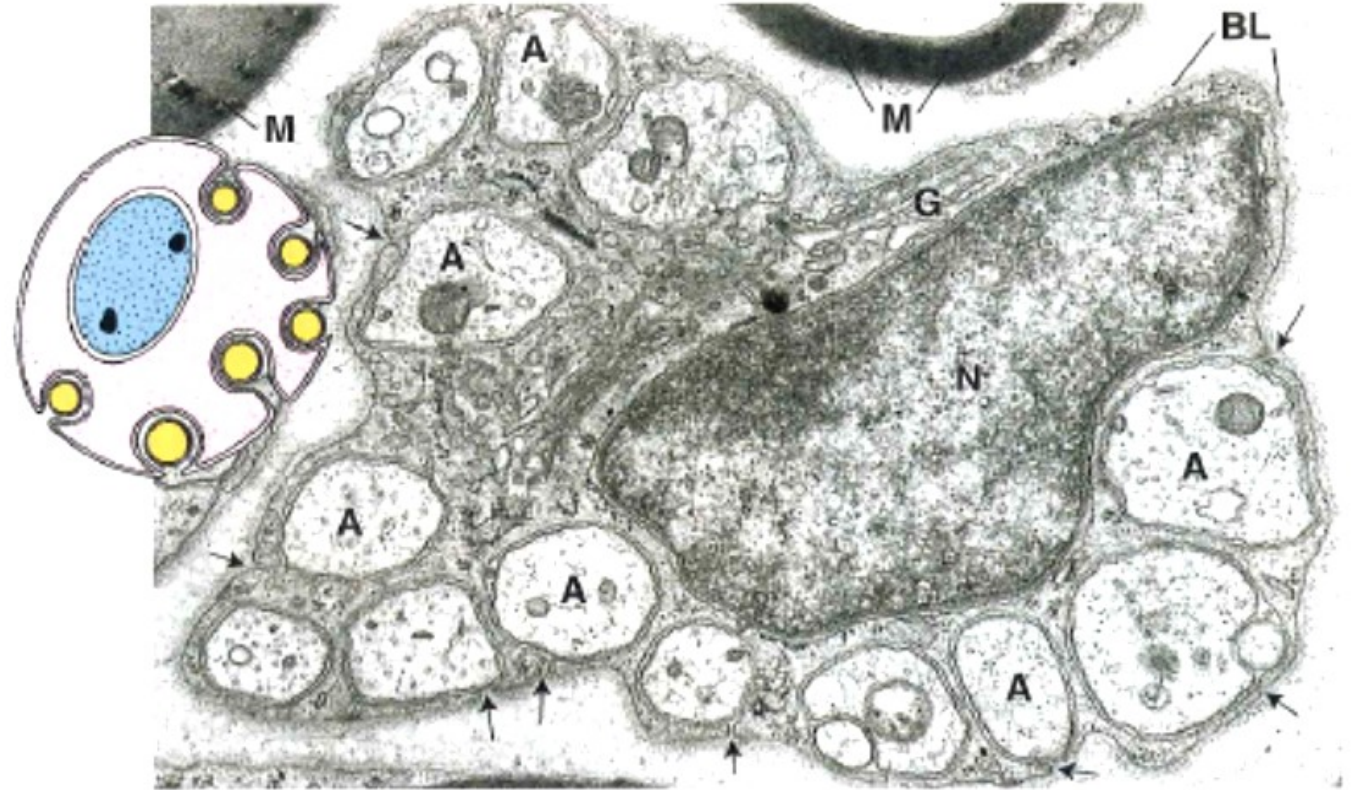
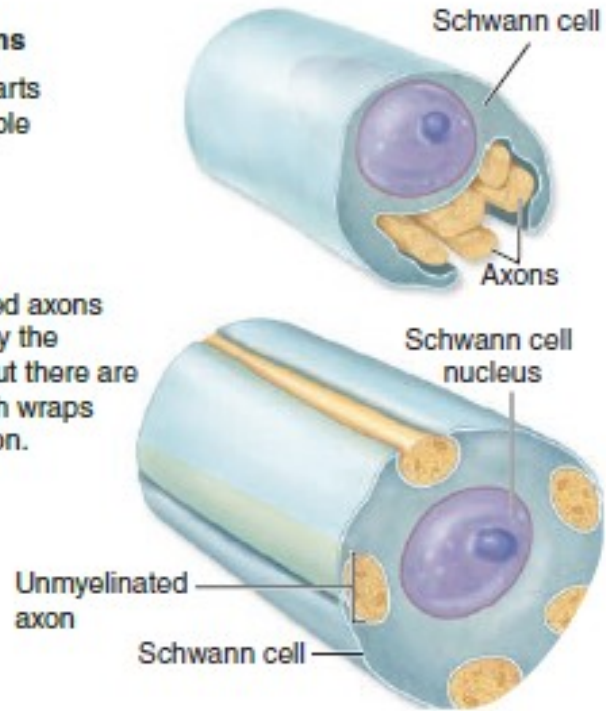
Unmyelinated axons

FIGURE 9-25 Unmyelinated nerves.

Unmyelinated axons

① Schwann cell starts to envelop multiple axons.

② The unmyelinated axons are enveloped by the Schwann cell, but there are no myelin sheath wraps around each axon.

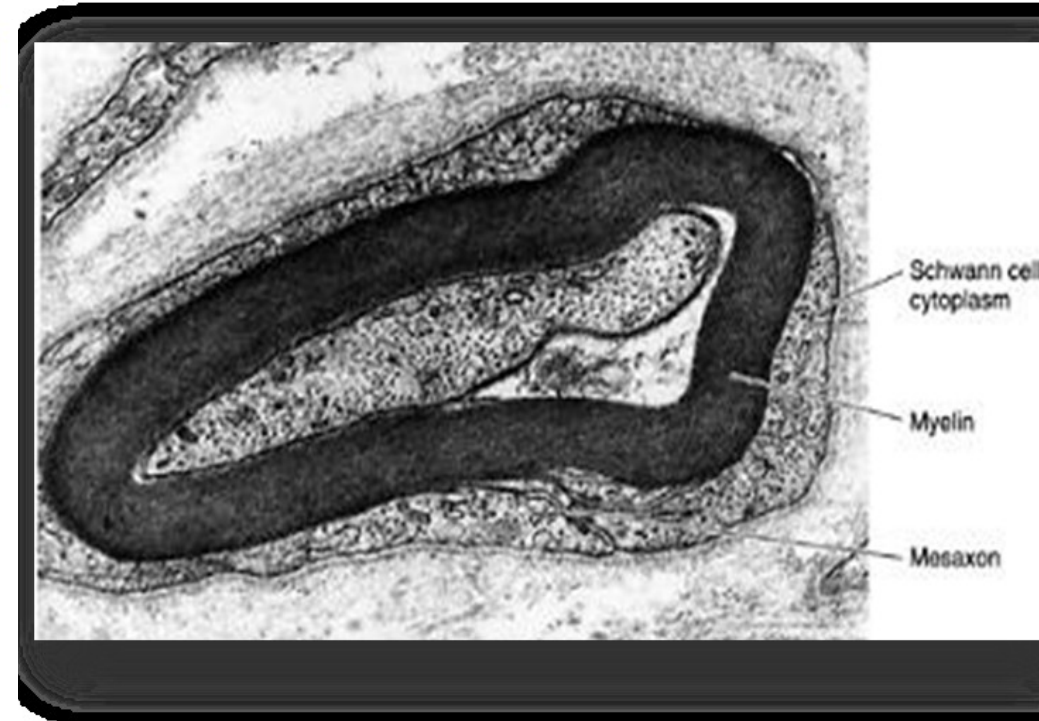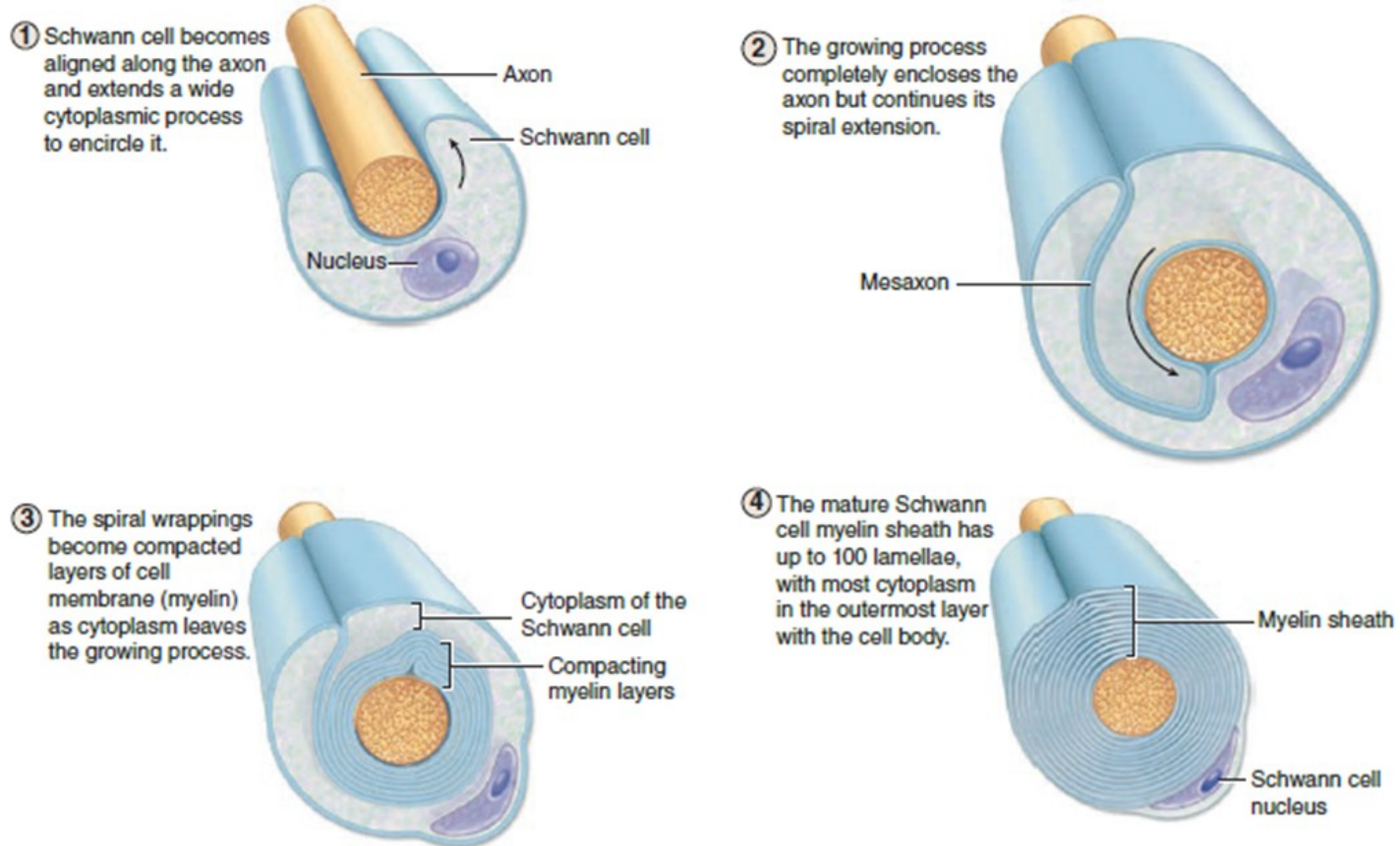


During development, portions of several small-diameter axons are engulfed by one Schwann cell. Subsequently the axons are separated and each typically becomes enclosed within its own fold of Schwann cell surface. No myelin is formed by wrapping. Small-diameter axons utilize action potentials whose formation and maintenance do not depend on the insulation provided by the myelin sheath required by large-diameter axons.

NERVE TISSUE

Myelinated axons

FIGURE 9–21 Myelination of large-diameter PNS axons.



A Schwann cell (neurolemmocyte) engulfs one portion along the length of a large-diameter axon. The Schwann cell membrane fuses around the axon and one thin extension of the Schwann cell elongates greatly and wraps itself repeatedly around the axon to form multiple, compacted layers. The Schwann cell membrane

wrappings constitute the myelin sheath, with the Schwann cell body always on its outer surface. The myelin layers are very rich in lipid, and provide insulation and facilitate formation of action potentials along the axolemma.

NERVE TISSUE

MYELIN SHEATH

- The myelin sheath is formed by the plasma membrane of supporting cells wrapping around the axon. The sheath consists of multilamellar, lipid-rich segments produced by Schwann cells in the PNS and oligodendrocytes in the CNS.
- Functions:
 - Increases speed of conduction (saltatory conduction)
 - Insulates the axon
- Similar structure in CNS and PNS with some differences in protein composition
- Organization:
 - *Internode*. Single myelin segment
 - *Paranode*. Ends of each internode where they attach to the axon
 - *Node of Ranvier*. Specialized region of the axon between myelin internodes where depolarization occurs
- In the **PNS**, each *Schwann cell* associates with **only one axon** and forms a **single internode of myelin**.
- In the **CNS**, each *oligodendrocyte* associates with **many axons** (i.e., each oligodendrocyte forms **multiple internodes on different axons**).

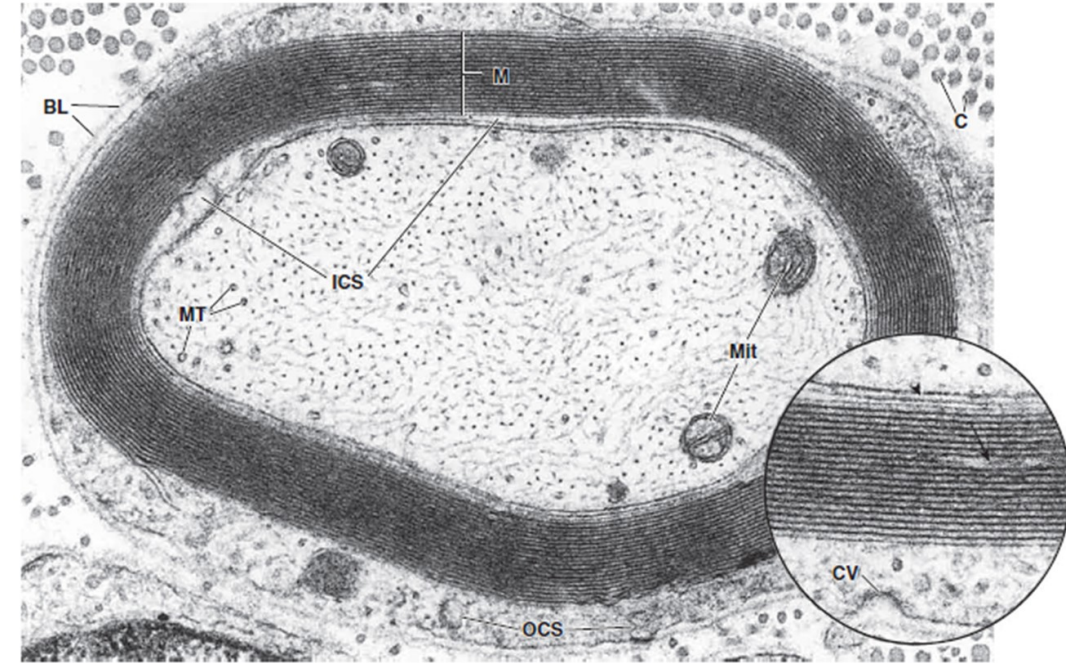


FIGURE 12.12 ▲ **Electron micrograph of a mature myelinated axon.** The myelin sheath (M) shown here consists of 19 paired layers of Schwann cell membrane. The pairing of membranes in each layer is caused by the extrusion of the Schwann cell cytoplasm. The axon displays an abundance of neurofilaments, most of which have been cross-sectioned, giving the axon a stippled appearance. Also evident in the axon are microtubules (MT) and several mitochondria (Mit). The outer collar of Schwann cell cytoplasm (OCS) is relatively abundant compared with the inner collar of Schwann cell cytoplasm (ICS). The collagen fibrils (C) constitute the fibrillar component of the endoneurium. BL, basal (external) lamina. $\times 70,000$. **Inset.** Higher magnification of the myelin. The arrow points to cytoplasm within the myelin that would contribute to the appearance of the Schmidt-Lanterman cleft as seen in the light microscope. It appears as an isolated region here because of the thinness of the section. The intercellular space between axon and Schwann cell is indicated by the arrowhead. A coated vesicle (CV) in an early stage of formation appears in the outer collar of the Schwann cell cytoplasm. $\times 130,000$. (Courtesy of Dr. George D. Pappas.)

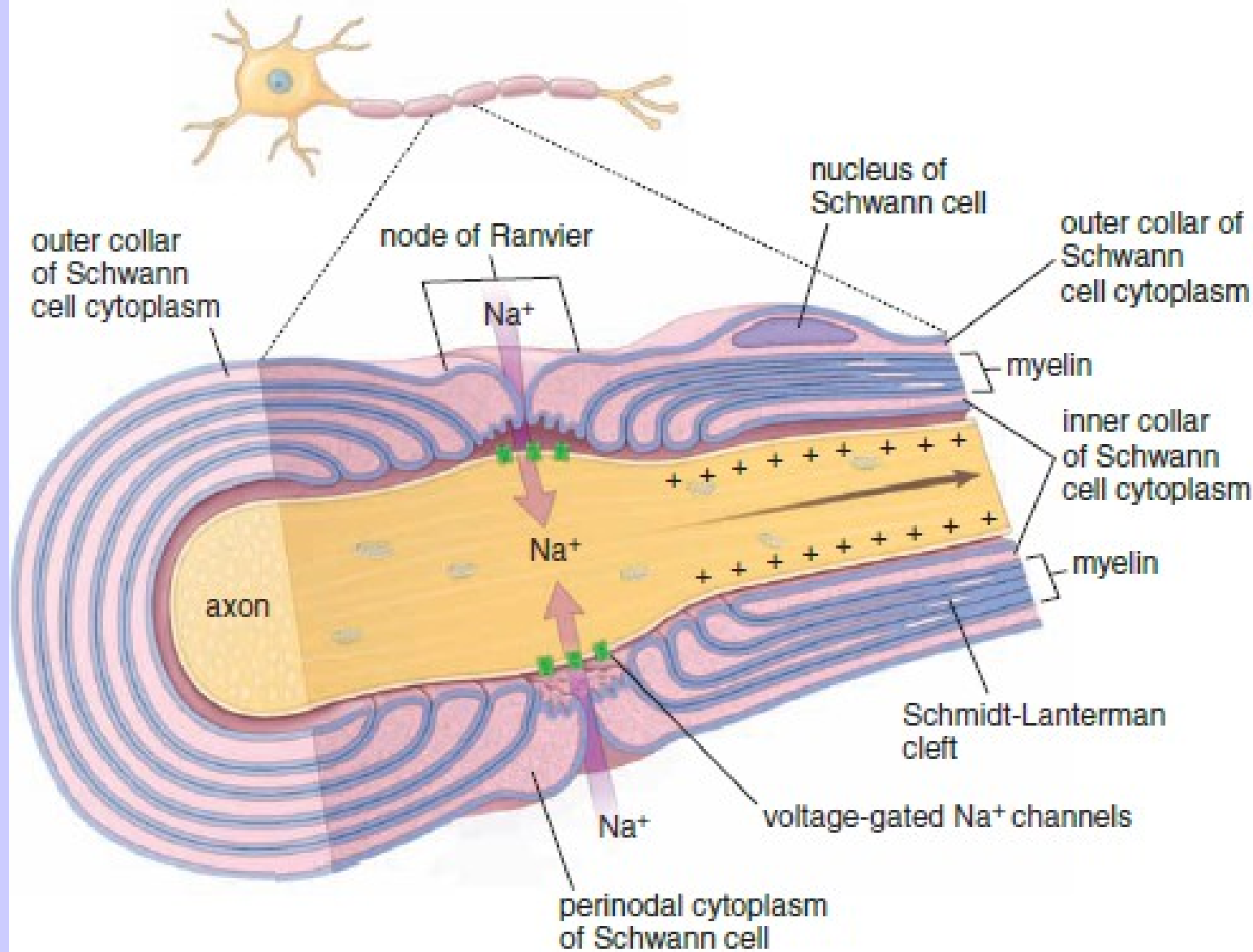
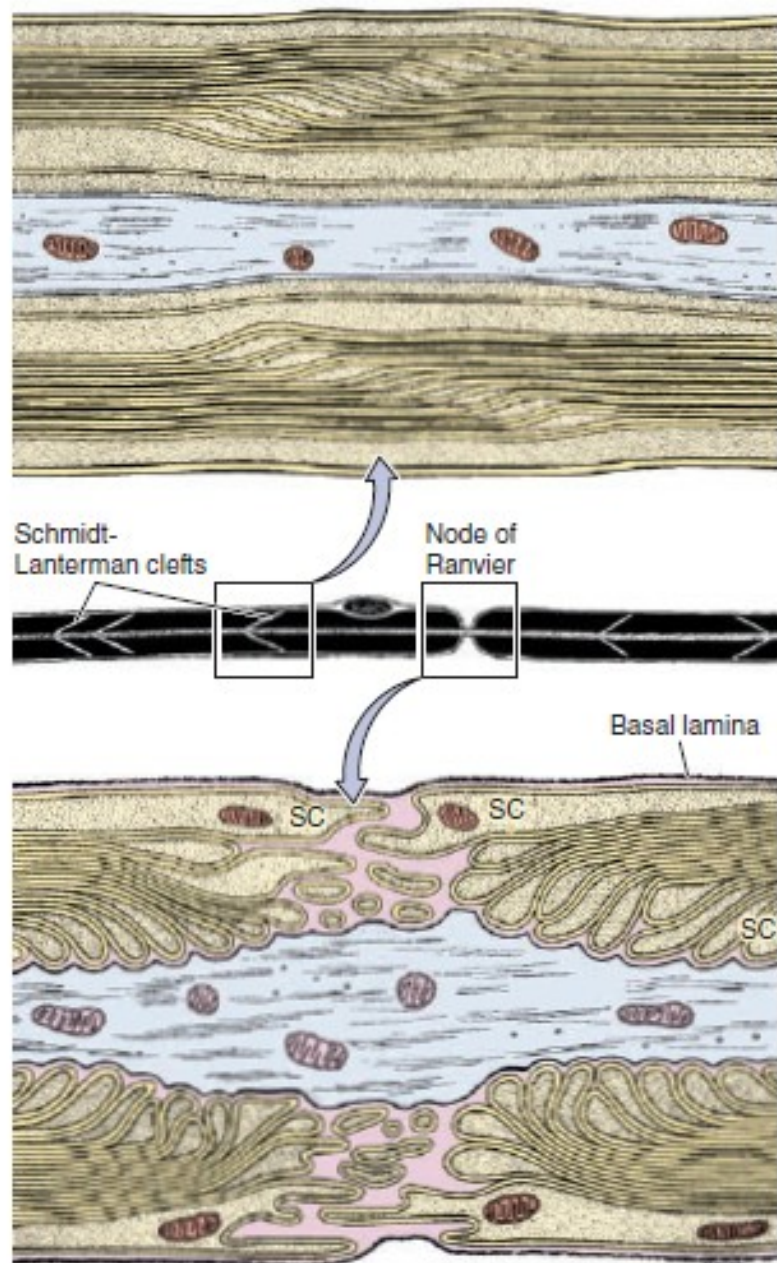


FIGURE 12.13 ▲ Diagram of the node of Ranvier and associated Schwann cells. This diagram shows a longitudinal section of the axon and its relationships to the myelin, cytoplasm of the Schwann cell, and node of Ranvier. Schwann cell cytoplasm is present at four locations: the inner and the outer cytoplasmic collar of the Schwann cell, the nodes of Ranvier, and the Schmidt-Lanterman clefts. Note that the cytoplasm throughout the Schwann cell is continuous (see Fig. 12.14); it is not a series of cytoplasmic islands as it appears on the longitudinal section of the myelin sheath. The node of Ranvier is the site at which successive Schwann cells meet. The adjacent plasma membranes of the Schwann cells are not tightly apposed at the node, and extracellular fluid has free access to the neuronal plasma membrane. Also, the node of Ranvier is the site of depolarization of the neuronal plasma membrane during nerve impulse transmission and contains clusters of high-density, voltage-gated Na⁺ channels.

FIGURE 9–23 Myelin maintenance and nodes of Ranvier.



The middle diagram shows schematically a myelinated peripheral nerve fiber as seen under the light microscope. The axon is enveloped by the myelin sheath, which, in addition to membrane, contains some Schwann cell cytoplasm in spaces called **Schmidt-Lanterman or myelin clefts** between the major dense lines of membranes.

The upper diagram shows one set of such clefts ultrastructurally. The clefts contain Schwann cell cytoplasm that was not displaced to the cell body during myelin formation. This cytoplasm moves slowly along the myelin sheath, opening temporary spaces (the clefts) that allow renewal of some membrane components as needed for maintenance of the sheath.

The lower diagram depicts the ultrastructure of a single node of Ranvier or nodal gap. Interdigitating processes extending from the outer layers of the Schwann cells (SC) partly cover and contact the axolemma at the nodal gap. This contact acts as a partial barrier to the movement of materials in and out of the periaxonal space between the axolemma and the Schwann sheath. The basal or external lamina around Schwann cells is continuous over the nodal gap. The axolemma at nodal gaps has abundant voltage-gated Na^+ channels important for impulse conduction in these axons.

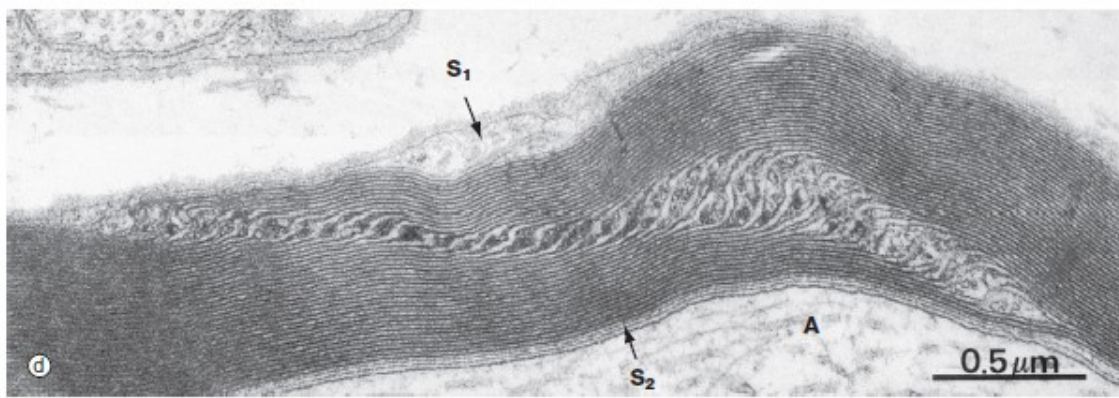
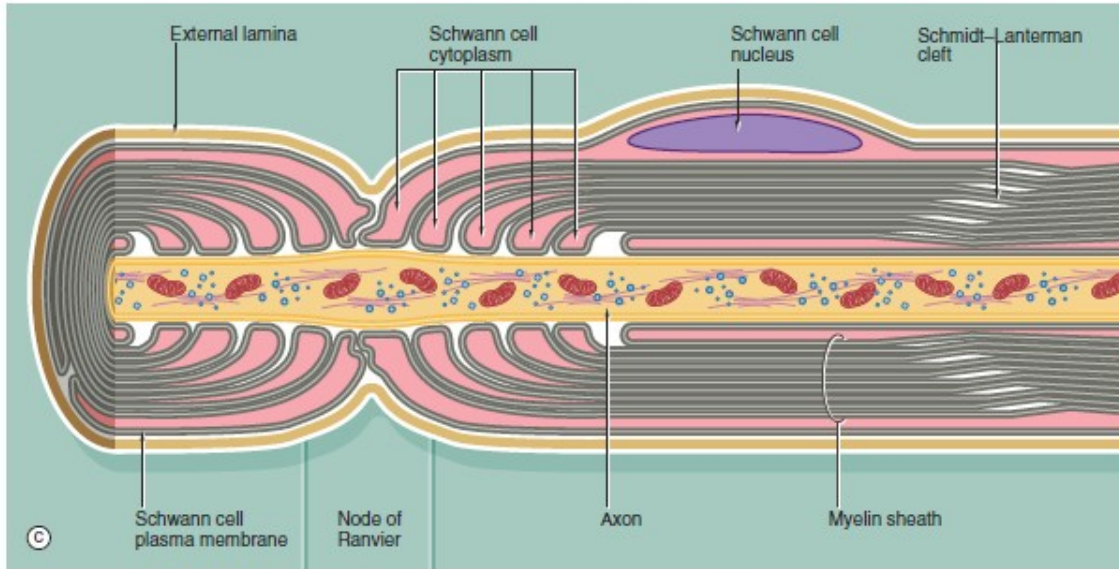
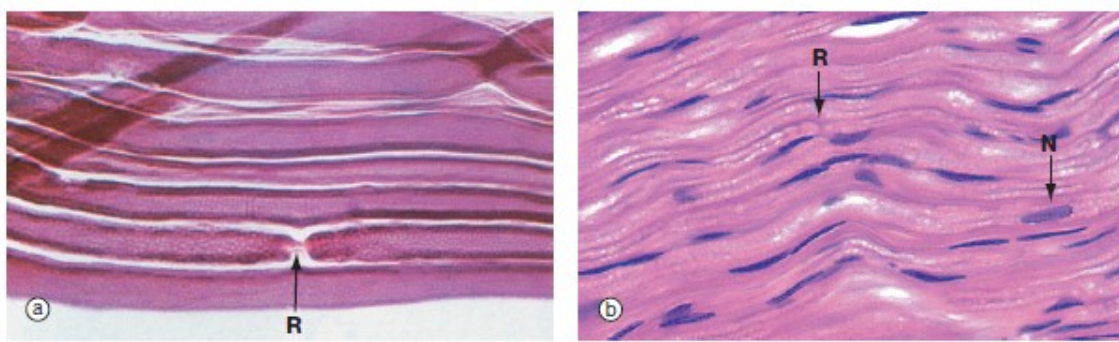


FIG. 7.7 Nodes of Ranvier and Schmidt-Lanterman incisures (caption and illustration (e) opposite)
 (a) Teased preparation, Sudan black (MP) (b) H&E (MP) (c) Schematic diagram (d) EM $\times 42\,000$ (e) EM $\times 14\,000$

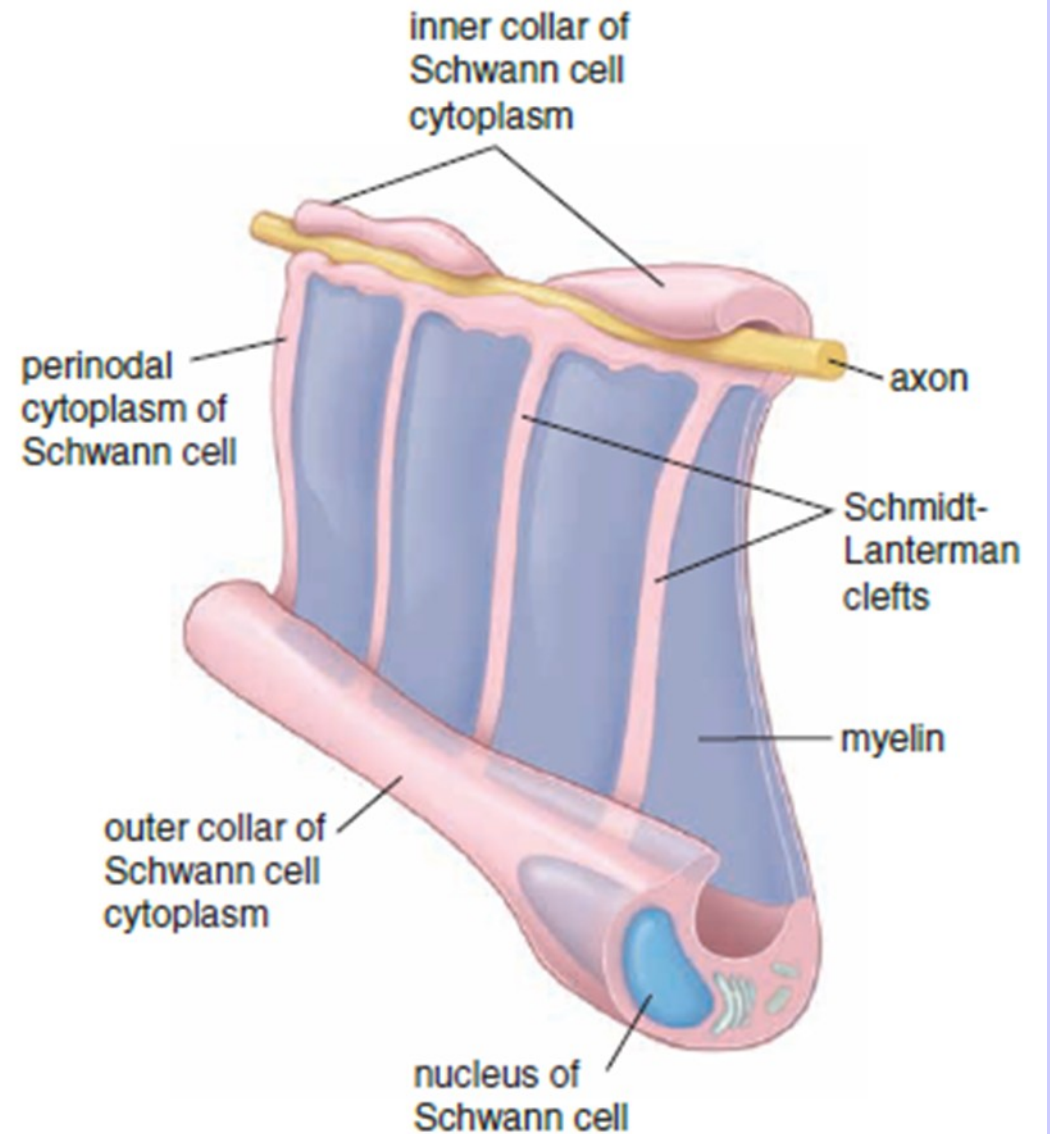


FIGURE 12.14 ▲ Three-dimensional diagrams conceptualizing the relationship of myelin and cytoplasm of a Schwann cell. This diagram shows a hypothetically uncoiled Schwann cell. Note how the inner collar of the Schwann cell cytoplasm is continuous with the outer collar of Schwann cell cytoplasm via Schmidt-Lanterman clefts.

NERVE TISSUE

CONNECTIVE TISSUE INVESTMENTS OF NERVOUS TISSUE

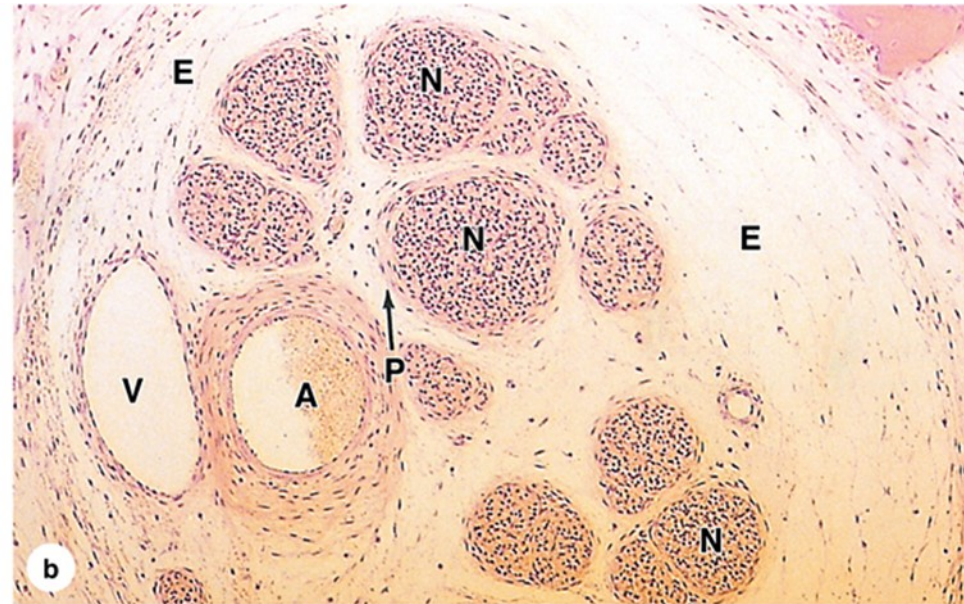
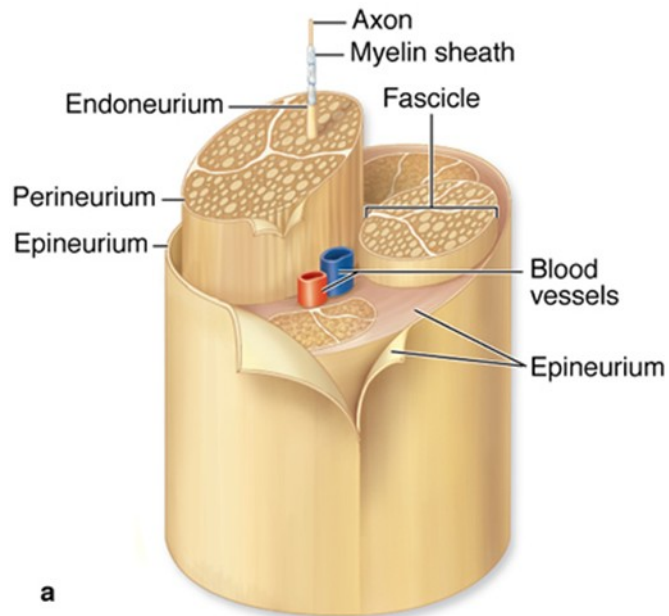
- **Central nervous system (meninges)**
 - *Pia mater*
 - Thin membrane lying directly on the surface of the brain and spinal cord
 - Accompanies larger blood vessels into the brain and spinal cord
 - *Arachnoid membrane*
 - Separated from pia mater by connective tissue trabeculae
 - Encloses the subarachnoid space, which contains blood vessels and the cerebrospinal fluid (CSF) produced by the cells of the choroid plexus
 - Together with pia mater, constitute the leptomeninges; inflammation of these membranes produces meningitis
 - *Dura mater*
 - Outermost of the meninges
 - Dense connective tissue that includes the periosteum of the skull

NERVE TISSUE

CONNECTIVE TISSUE INVESTMENTS OF NERVOUS TISSUE

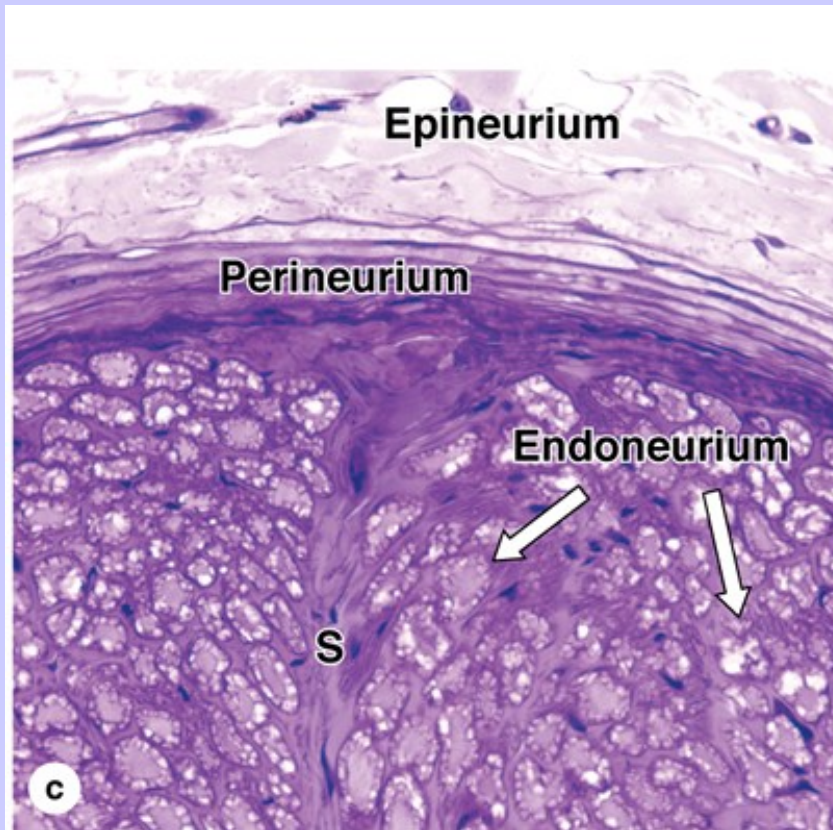
- **Peripheral nervous system**

- *Epineurium*. Dense connective tissue surrounding fascicles and the entire nerve
- *Perineurium*. Dense tissue surrounding groups of axons and their surrounding Schwann cells, forming fascicles; forms the blood-nerve barrier
- *Endoneurium*. Delicate connective tissue surrounding Schwann cells; includes the basal lamina secreted by Schwann cells as well as reticular fibers

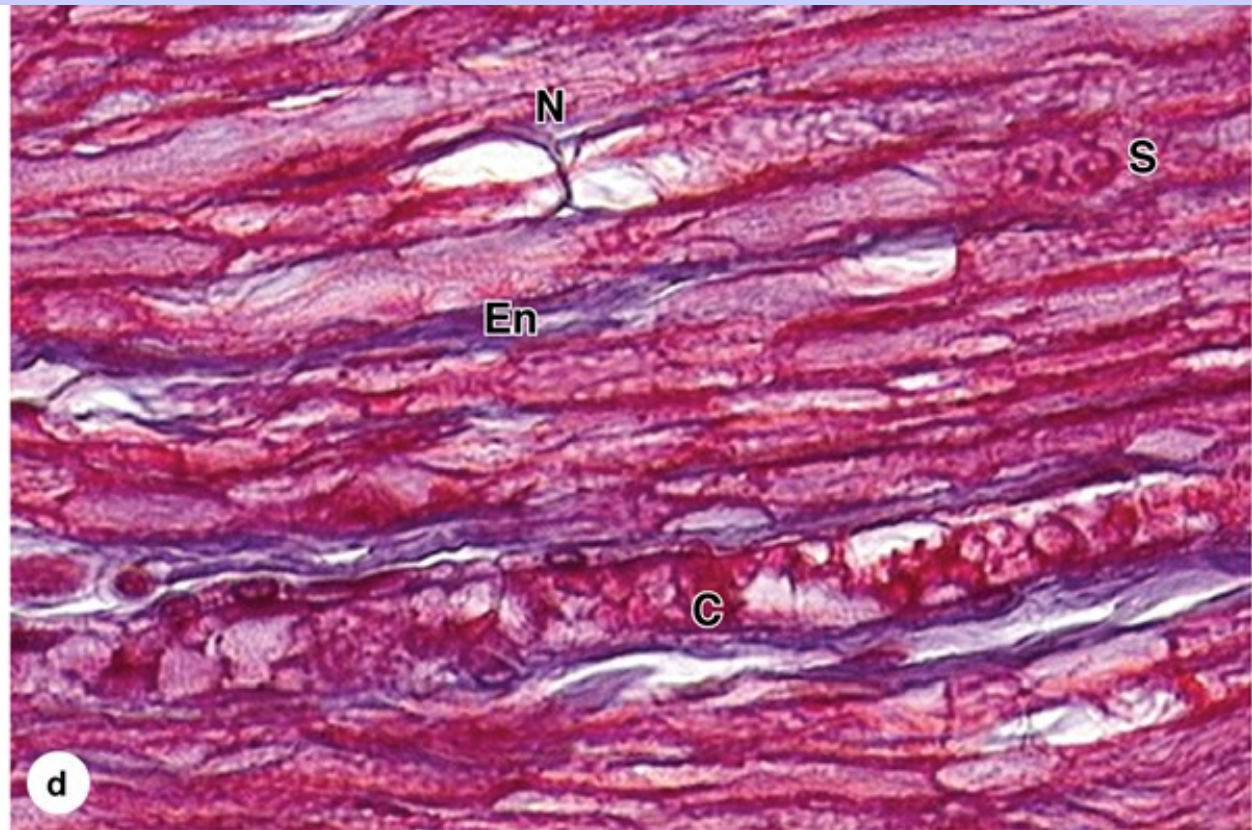


(a) The diagram shows the relationship among these three connective tissue layers in large peripheral nerves. The epineurium (E) consists of a dense superficial region and a looser deep region that contains the larger blood vessels.

(b) The micrograph shows a small vein (V) and artery (A) in the deep epineurium (E). Nerve fibers (N) are bundled in fascicles. Each fascicle is surrounded by the perineurium (P), consisting of a few layers of unusual squamous fibroblastic cells that are all joined at the peripheries by tight junctions. The resulting blood-nerve barrier helps regulate the microenvironment inside the fascicle. Axons and Schwann cells are in turn surrounded by a thin layer of endoneurium. (X140; H&E)



(c) As shown here and in the diagram, septa (S) of connective tissue often extend from the perineurium into larger fascicles. The endoneurium (En) and lamellar nature of the perineurium (P) are also shown at this magnification, along with some adjacent epineurium (E). (X200; PT)



A longitudinally oriented nerve shows one node of Ranvier (N) with the axon visible. Collagen of the sparse endoneurium (En), blue in this trichrome stain, surrounds the Schwann cell nucleus (S) and a capillary (C). At least one Schwann cell nucleus (S) is also clearly seen. (X400; Mallory trichome)

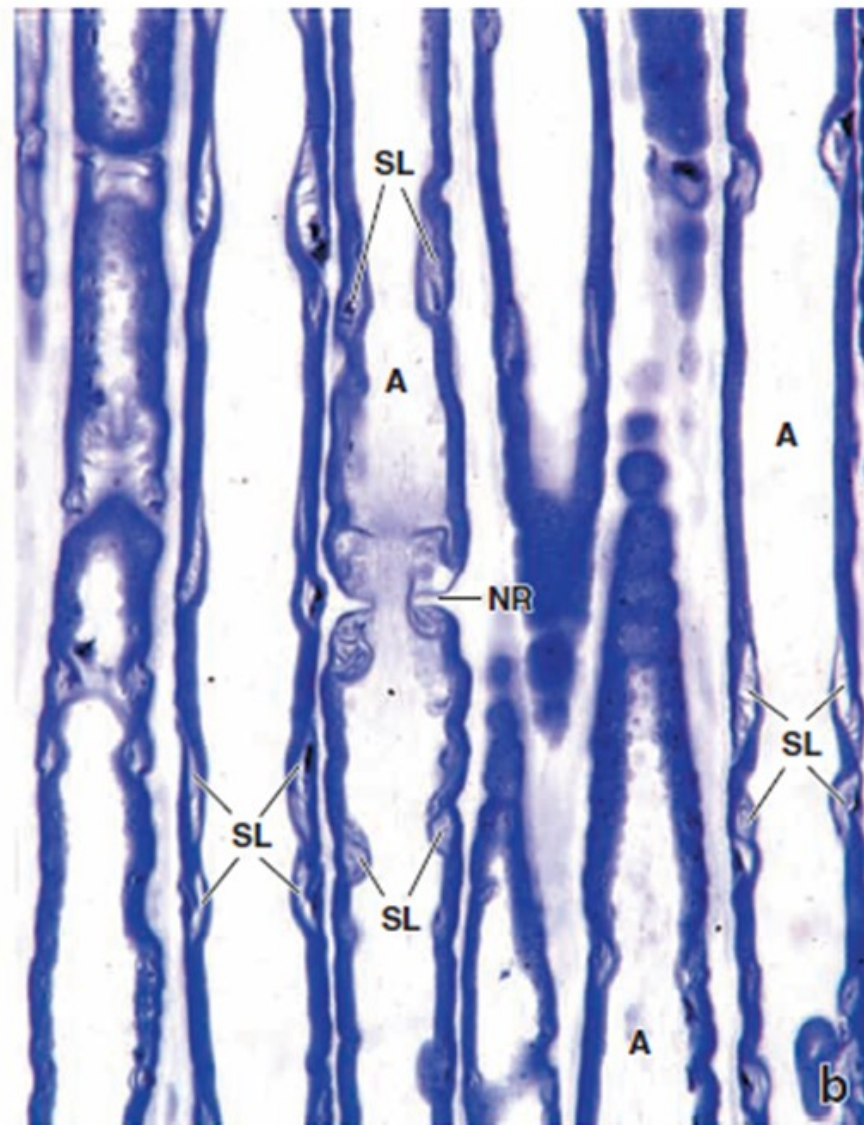
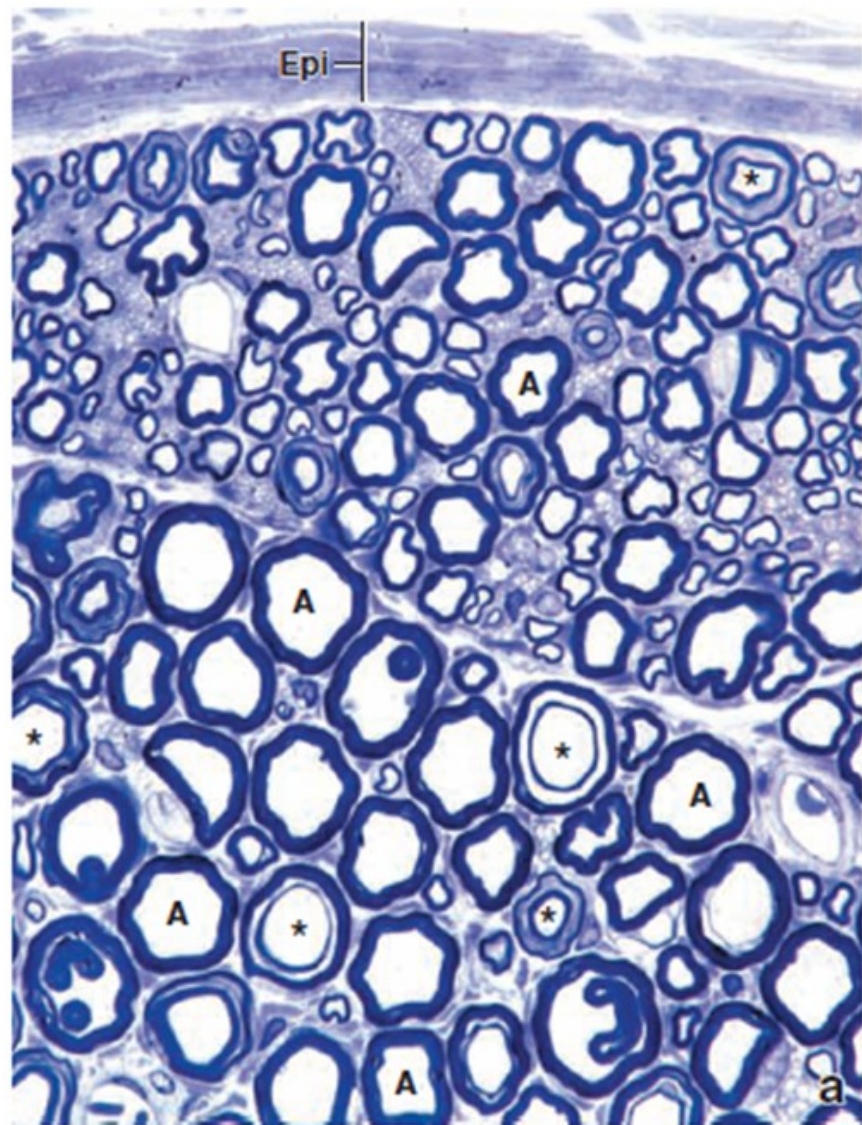
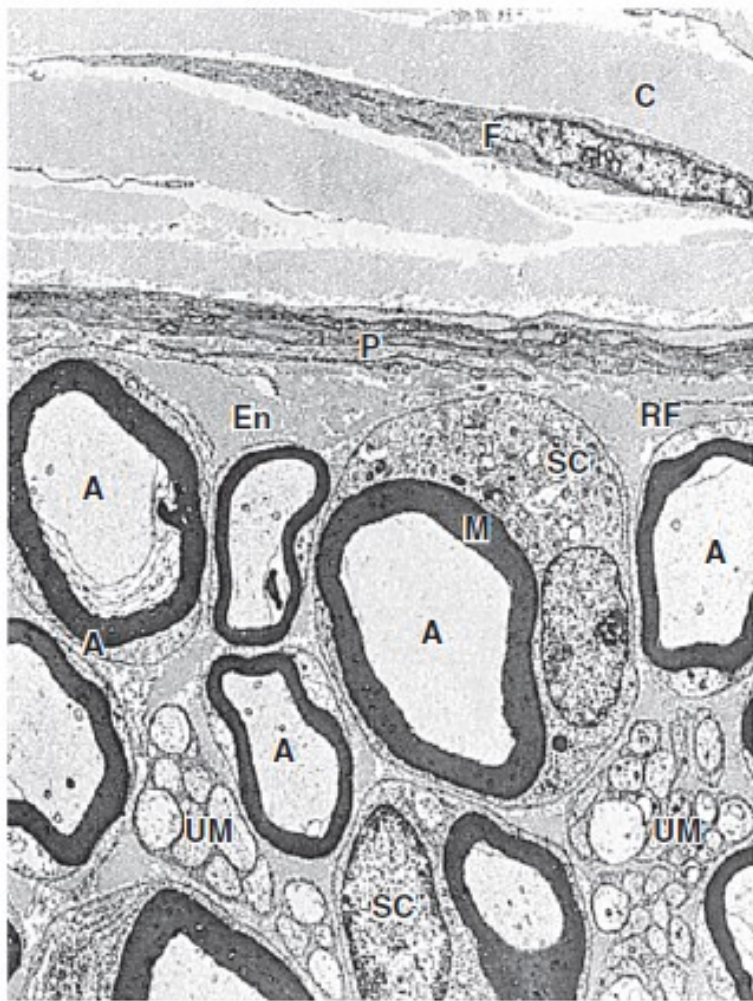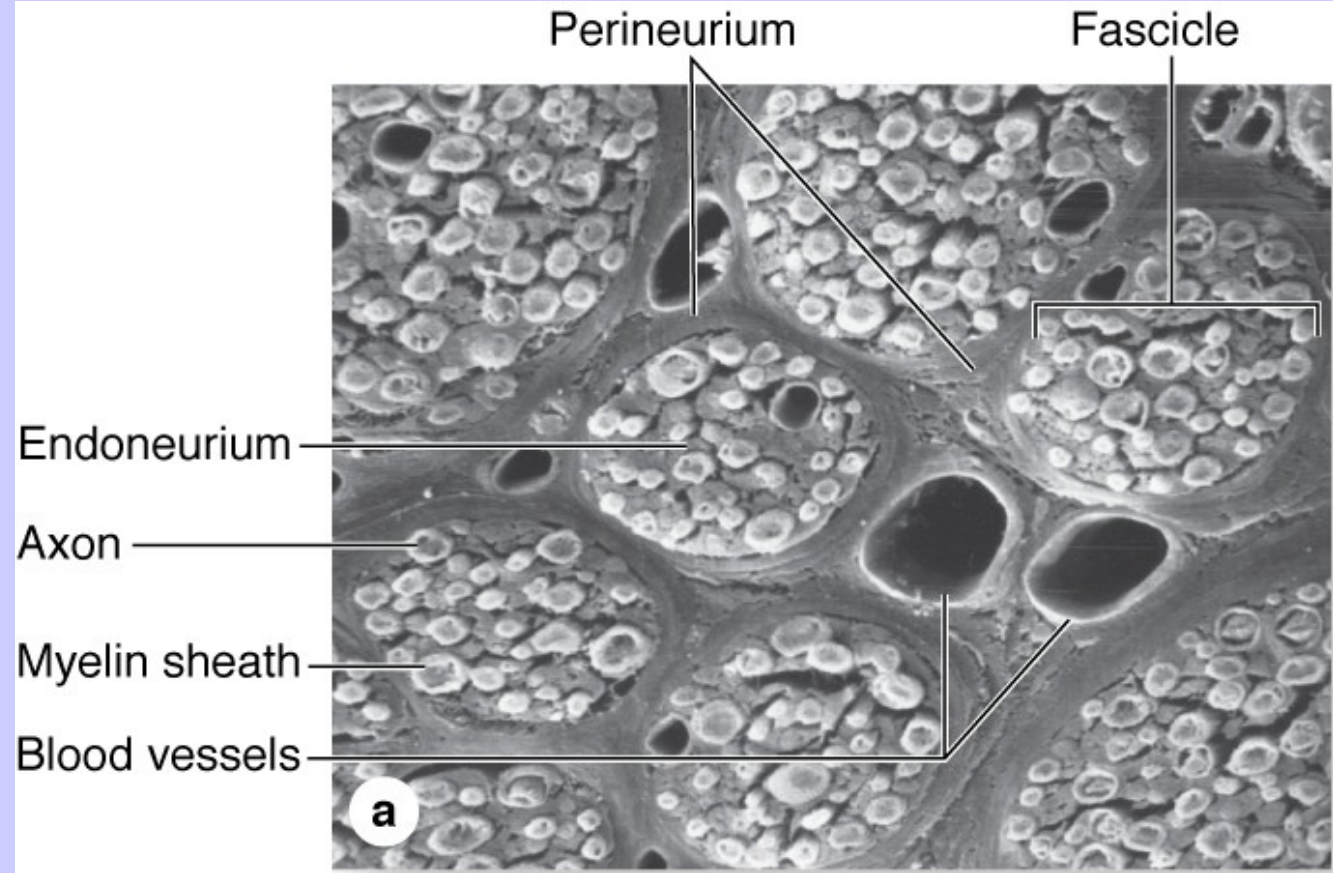


FIGURE 12.9 ▲ Photomicrographs of a peripheral nerve in cross and longitudinal sections. a. Photomicrograph of an osmium-fixed, toluidine blue–stained peripheral nerve cut in cross-section. The axons (A) appear clear. The myelin is represented by the *dark ring* surrounding the axons. Note the variation in diameter of the individual axons. In some of the nerves, the myelin appears to consist of two separate rings (*asterisks*). This is caused by the section passing through a Schmidt-Lanterman cleft. *Epi*, epineurium. $\times 640$. **b.** Photomicrograph showing longitudinally sectioned myelinated nerve axons (A) in the same preparation as above. A node of Ranvier (NR) is seen *near the center* of the micrograph. In the same axon, a Schmidt-Lanterman cleft (SL) is seen on each side of the node. In addition, a number of Schmidt-Lanterman clefts can be seen in the adjacent axons. The perinodal cytoplasm of the Schwann cell at the node of Ranvier and the Schwann cell cytoplasm at the Schmidt-Lanterman cleft appear virtually unstained. $\times 640$.

FIGURE 9-27 Peripheral nerve ultrastructure.



This low-magnification TEM shows a fibroblast (F) surrounded by collagen (C) in the epineurium (E) and three layers of flattened cells in the perineurium (P) that form another part of the blood-nerve barrier. Inside the perineurium the endoneurium (En) is rich in reticulin fibers (RF) that surround all Schwann cells. Nuclei of two Schwann cells (SC) of myelinated axons (A) are visible as well as many unmyelinated axons (UM) within Schwann cells. (X1200)



(d) SEM of transverse sections of a large peripheral nerve showing several fascicles, each surrounded by perineurium and packed with endoneurium around the individual myelin sheaths. Each fascicle contains at least one capillary. Endothelial cells of these capillaries are tightly joined as part of the blood-nerve barrier and regulate the kinds of plasma substances released to the endoneurium. Larger blood vessels course through the deep epineurium that fills the space around the perineurium and fascicles. (X450)

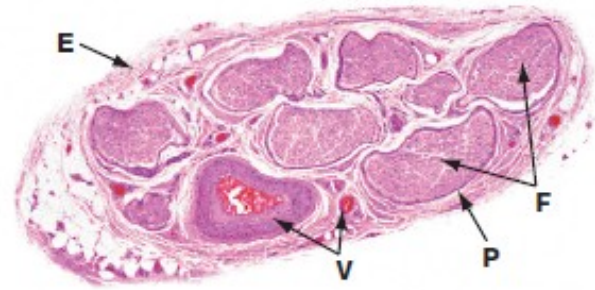

FIG. 7.13 Peripheral nerve
H&E (LP)

This micrograph illustrates the typical appearance of a medium-sized peripheral nerve in transverse section. This specimen consists of eight fascicles **F**, each of which contains many nerve fibres. Each fascicle is invested by perineurium **P** and the nerve as a whole is encased in a loose collagenous tissue sheath, the epineurium **E**, which is condensed at its outermost aspect. Blood vessels **V** of various sizes can be seen in the epineurial connective tissue.

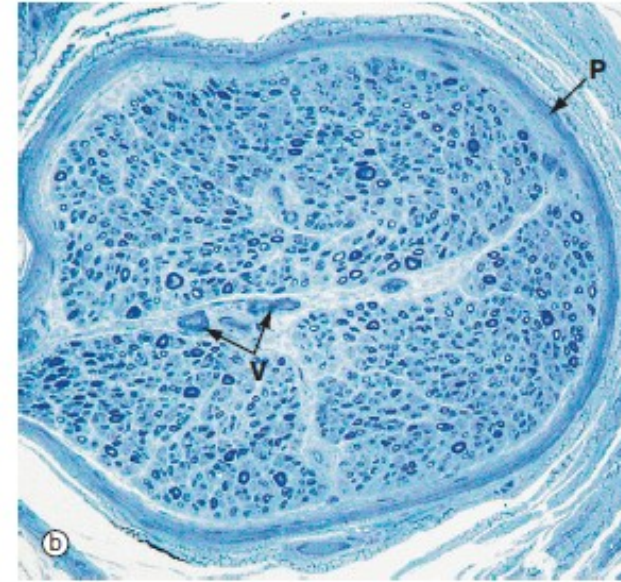
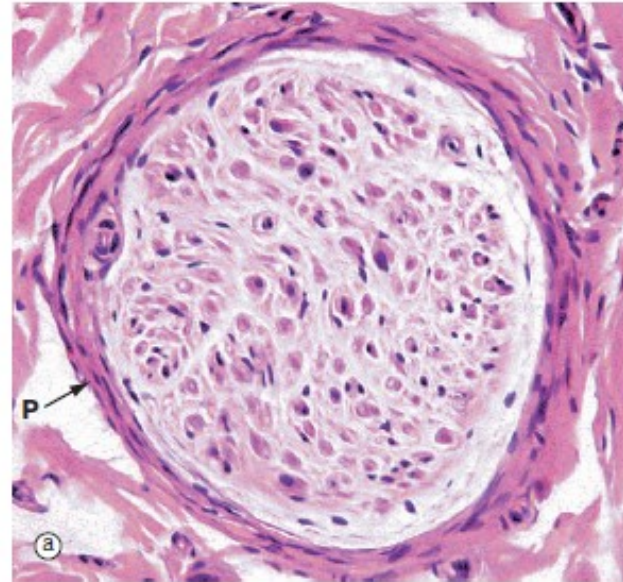


FIG. 7.14 Peripheral nerve
(a) H&E (MP) (b) Resin toluidine blue (MP)

The peripheral nerves shown in transverse section in micrographs (a) and (b) each consists of a single fascicle, invested by the perineurium **P** composed of several layers of flattened cells with elongated nuclei.

In micrograph (a) individual myelin sheaths are just visible as small circular structures, formed of myelin sheath proteins left after removal of lipid by tissue processing. Most of the nuclei seen within the fascicle are those of Schwann cells which mark the course of individual axons. Fibroblasts of the endoneurium are scattered amongst the much more numerous Schwann cells. It is possible to distinguish a minority of the

large myelinated axons in this paraffin-embedded material stained with H&E. Around the outside of the perineurium are bundles of pink-staining epineurial collagen.

Micrograph (b) is a preparation of nerve embedded in epoxy resin and stained with toluidine blue. The myelin sheaths are stained dark blue and can be seen as small circular structures. Axons run down the centre of each myelin sheath but are not resolved at this magnification. In the centre of the fascicle are small endoneurial blood vessels **V**. The perineurium **P** runs around the fascicle.

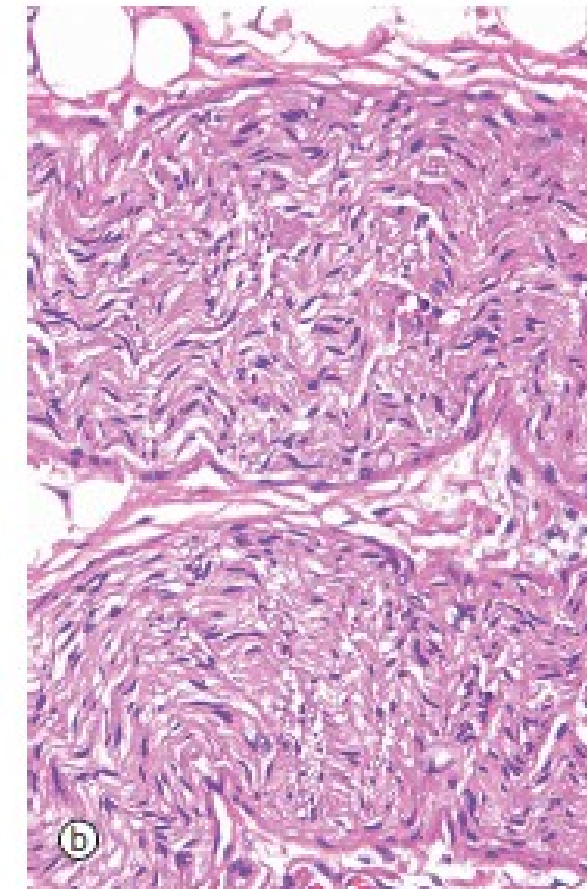
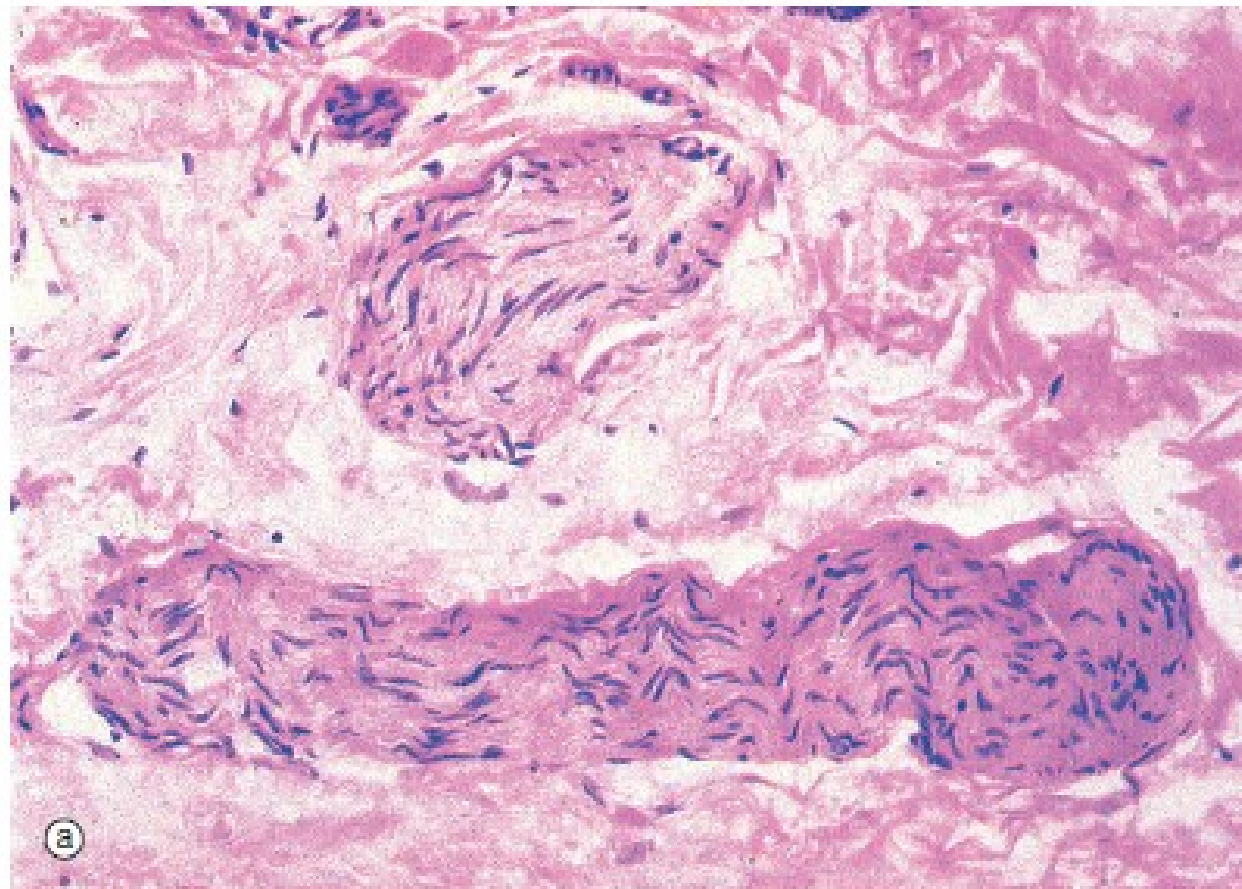


FIG. 7.19 Small peripheral nerves
 (a) H&E (HP) (b) H&E (HP)

These micrographs illustrate the appearance of small peripheral nerves in the tissues. Micrograph (a) shows two small nerves in the dermis of the skin, each nerve consisting of a single fascicle of fibres. The nerve at the bottom of the field is cut in longitudinal section; the wavy shape of the Schwann cell nuclei reflects the course of the axons, which are thereby protected from damage when the skin is stretched. The nerve in the

upper part of the field is cut in oblique section. Note the dense irregular collagenous dermal tissue surrounding the nerves in this specimen. Micrograph (b) shows a small peripheral nerve in the submucosa of the large bowel. This nerve runs a zigzag course in the tissue and the plane of section has cut it in the long axis as it folds. This allows the nerve to stretch as the bowel moves with peristalsis.