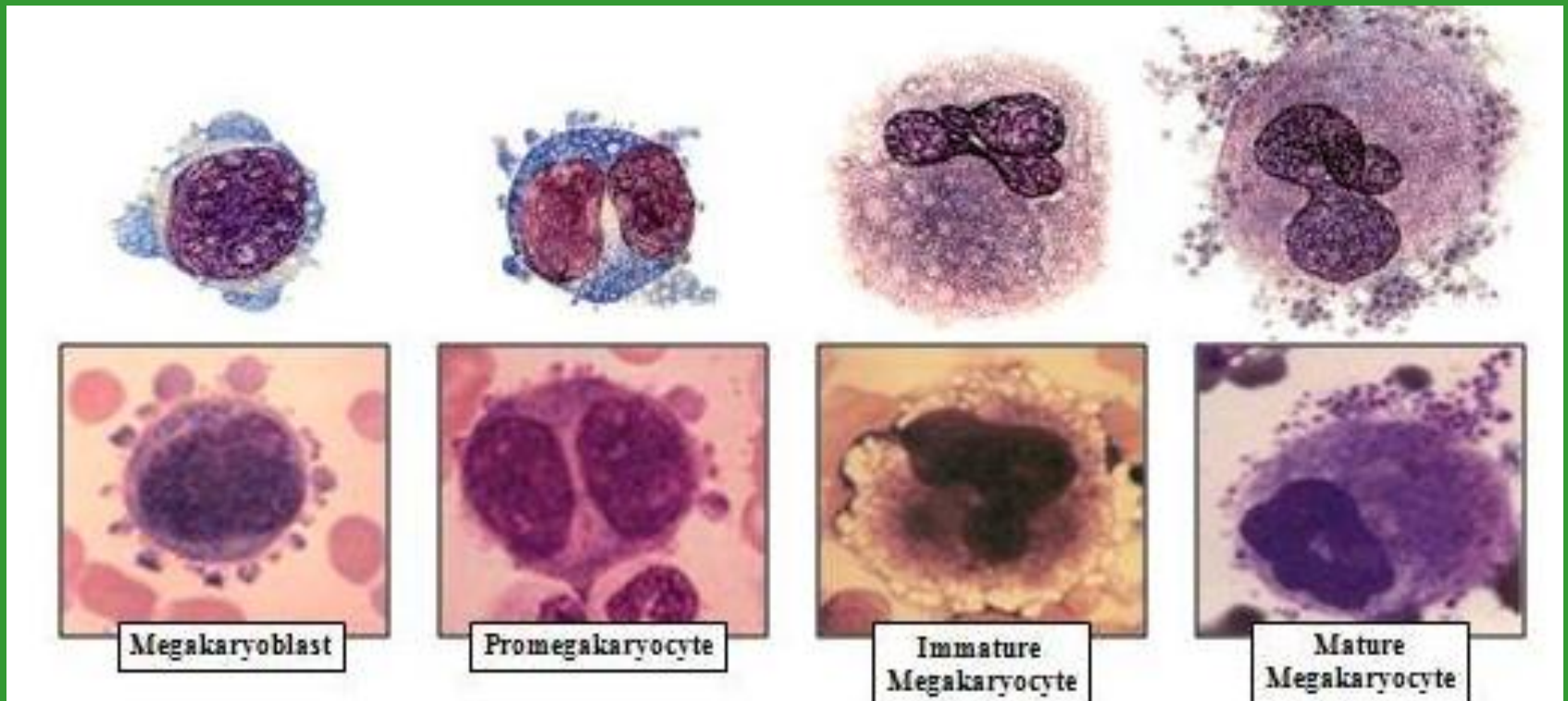


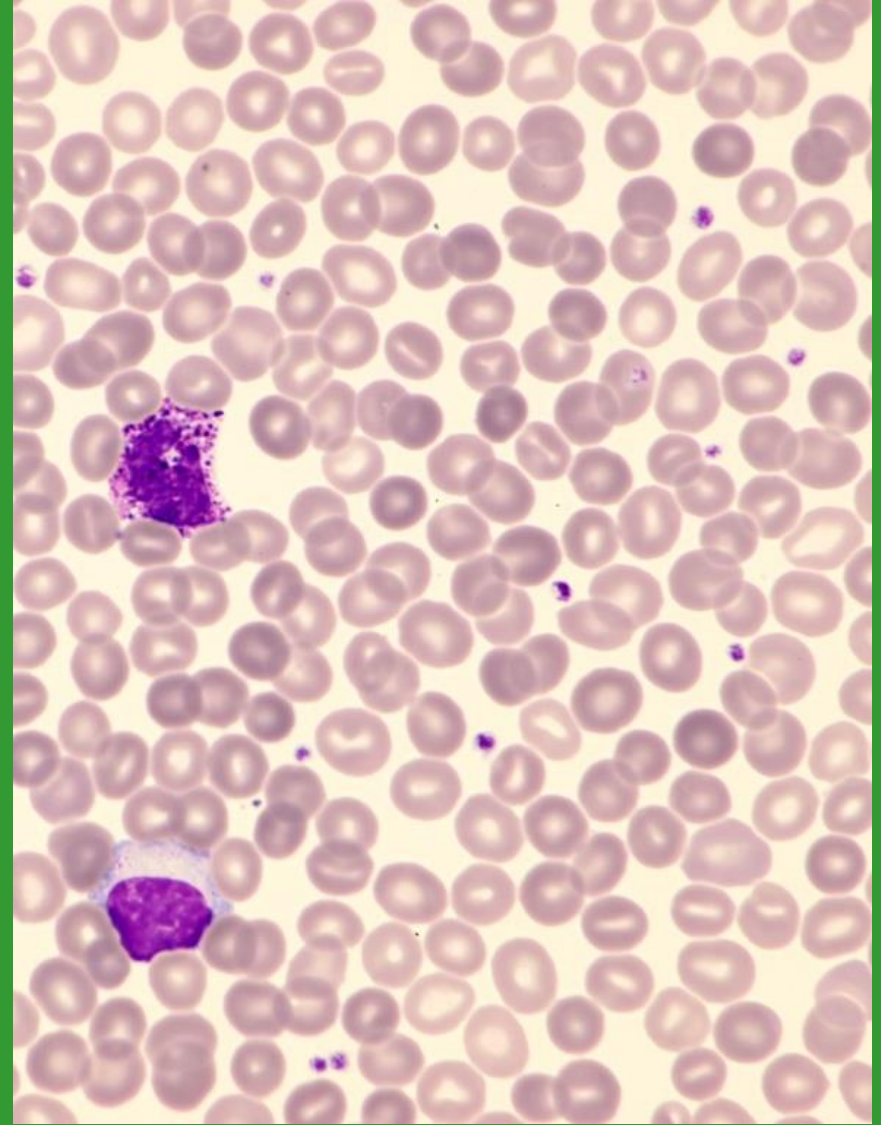
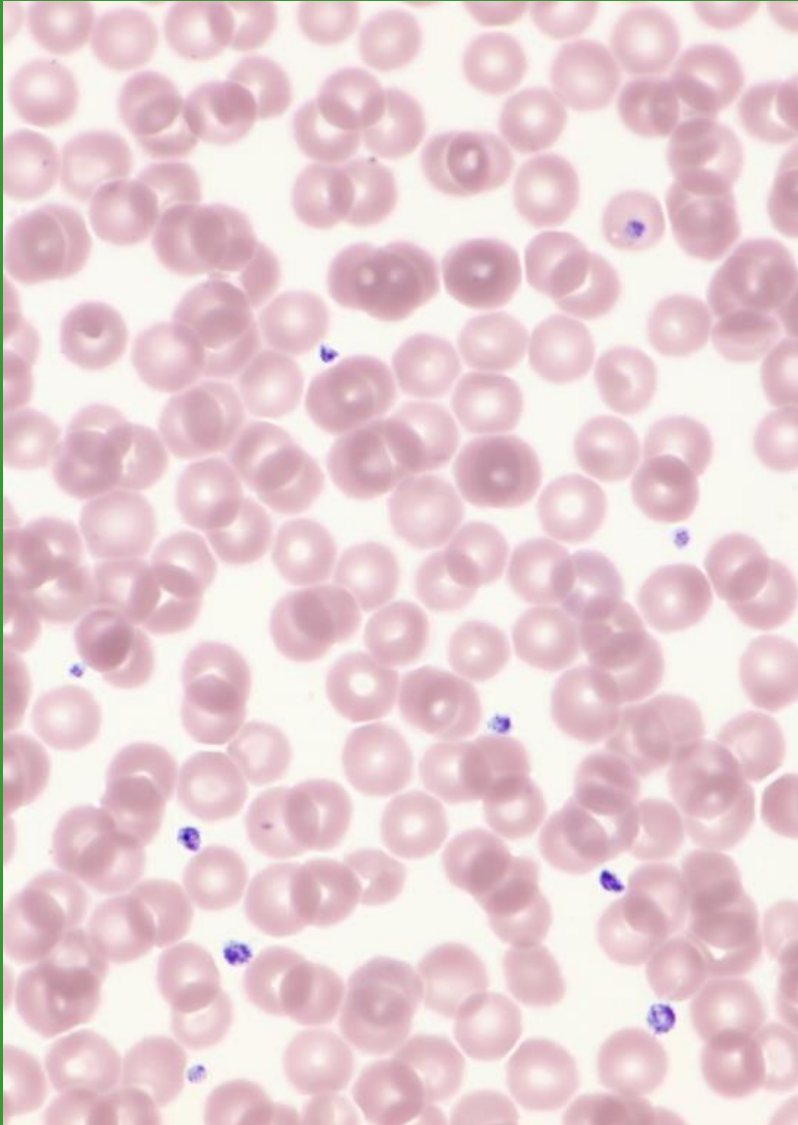
# Morfologie trombocytů

*Bourková L., OKH FN Brno*

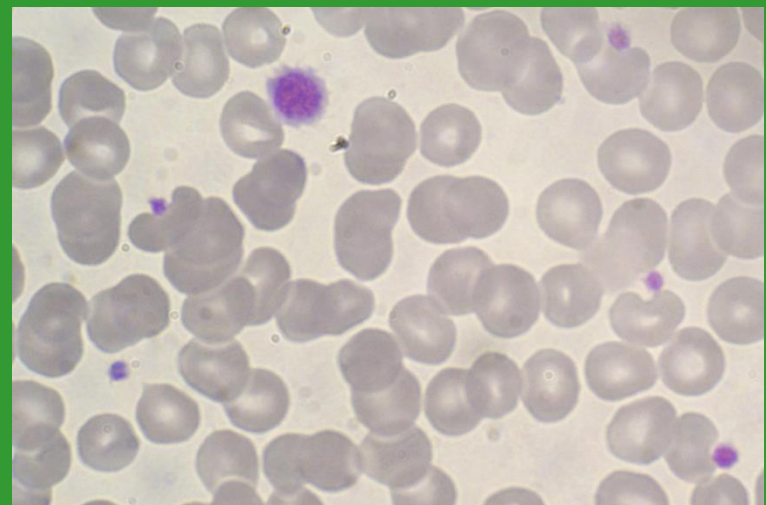
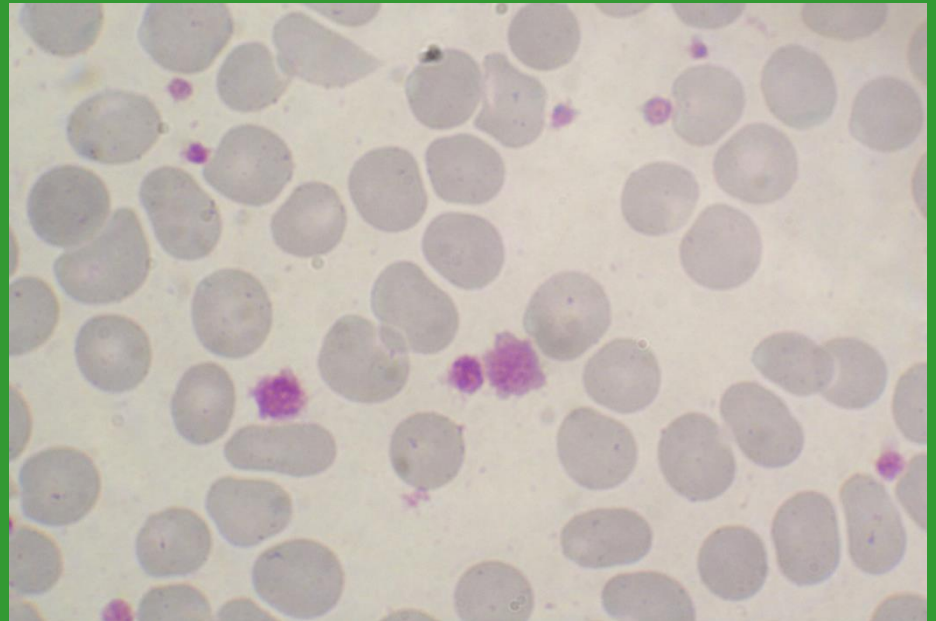
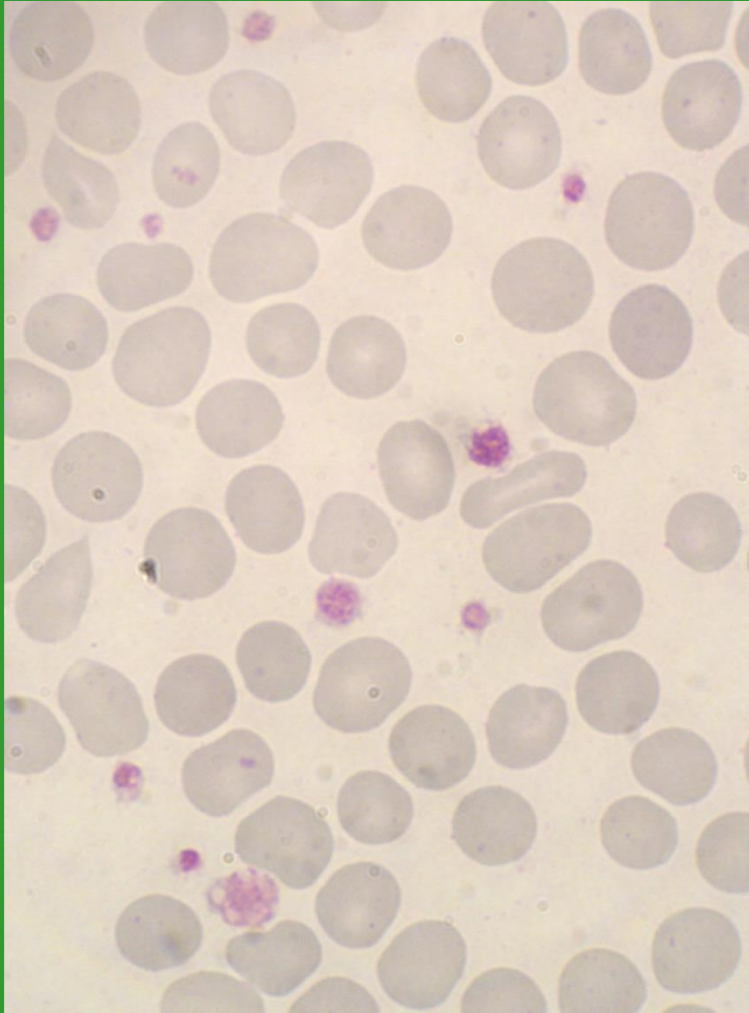
# Příklad vývojových stádií megakaryocytů



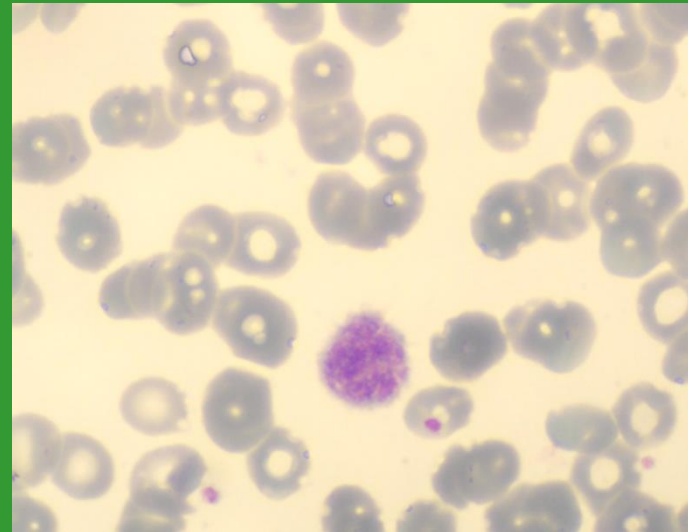
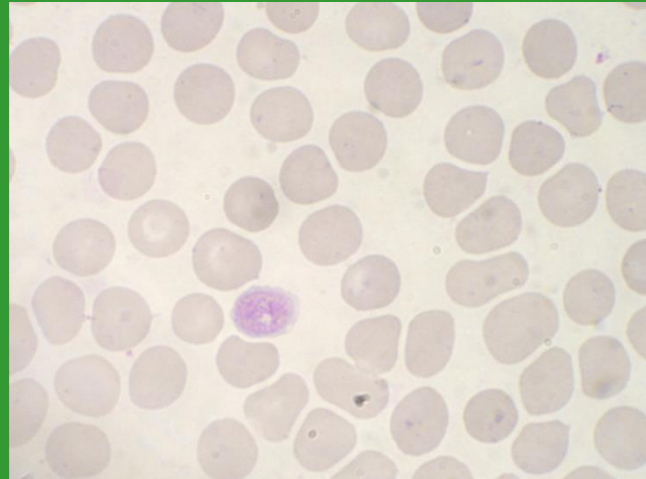
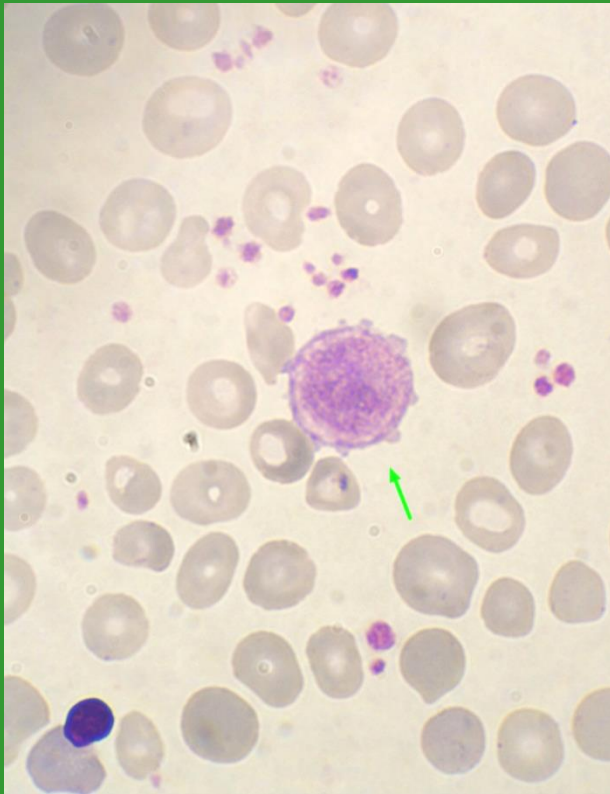
# Fyziologické trombocyty



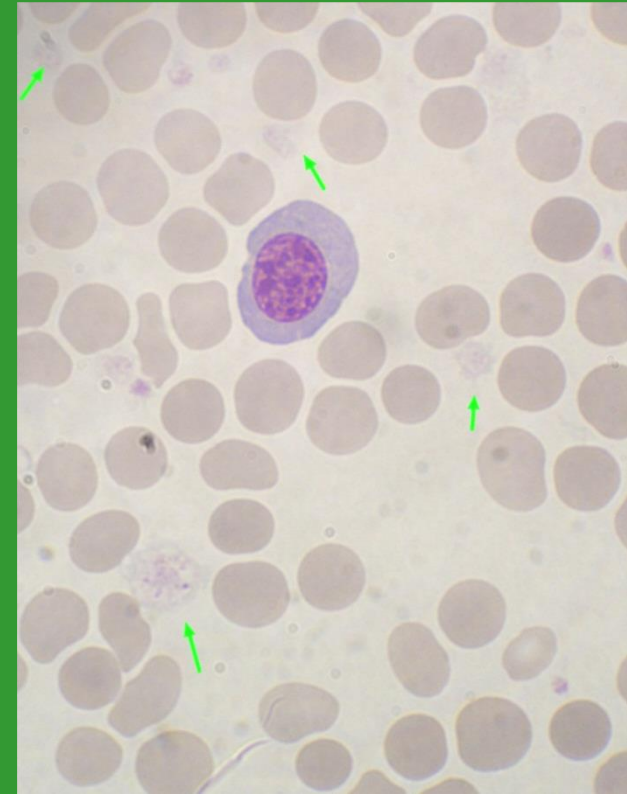
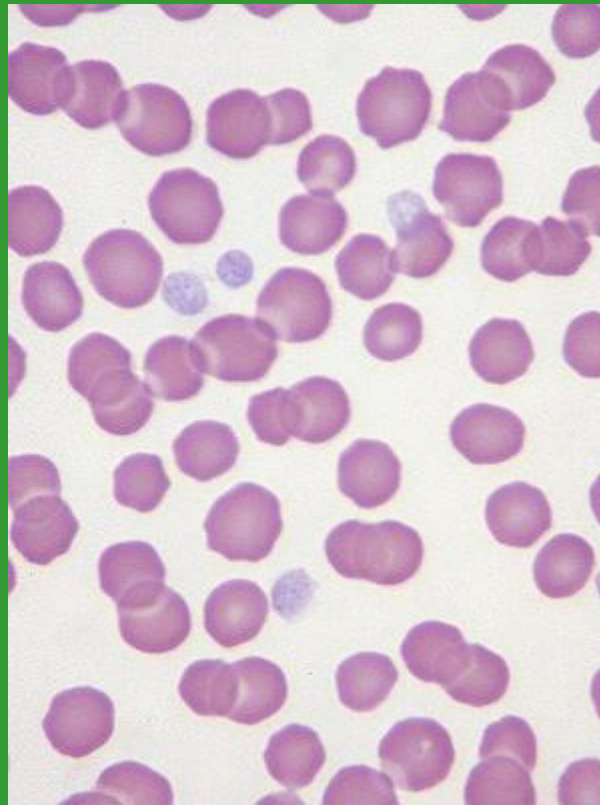
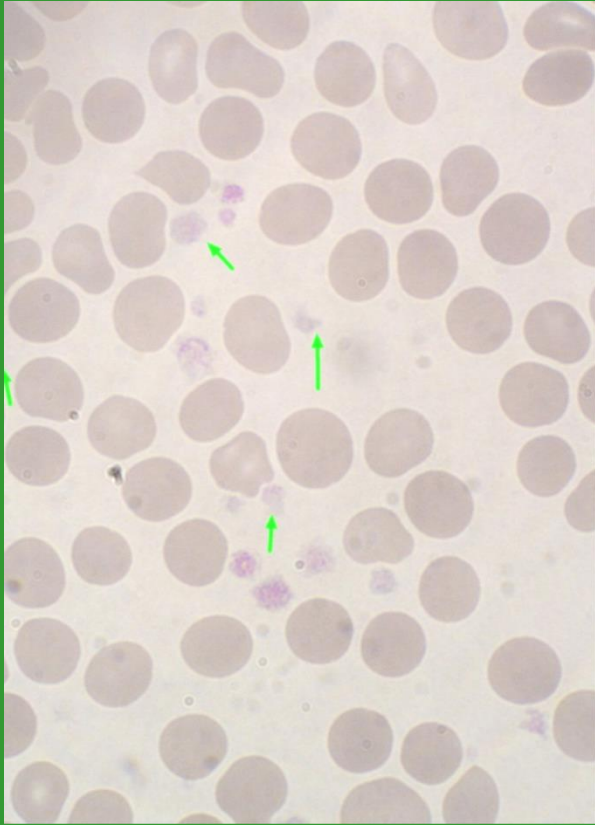
# Anizocytóza trombocytů



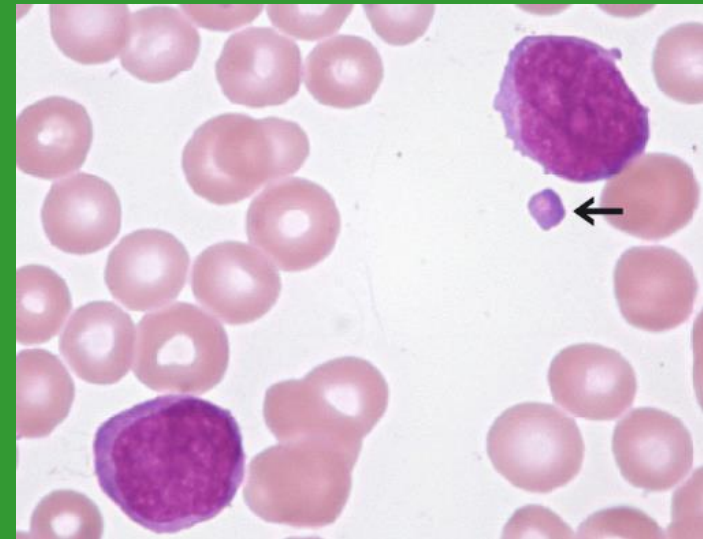
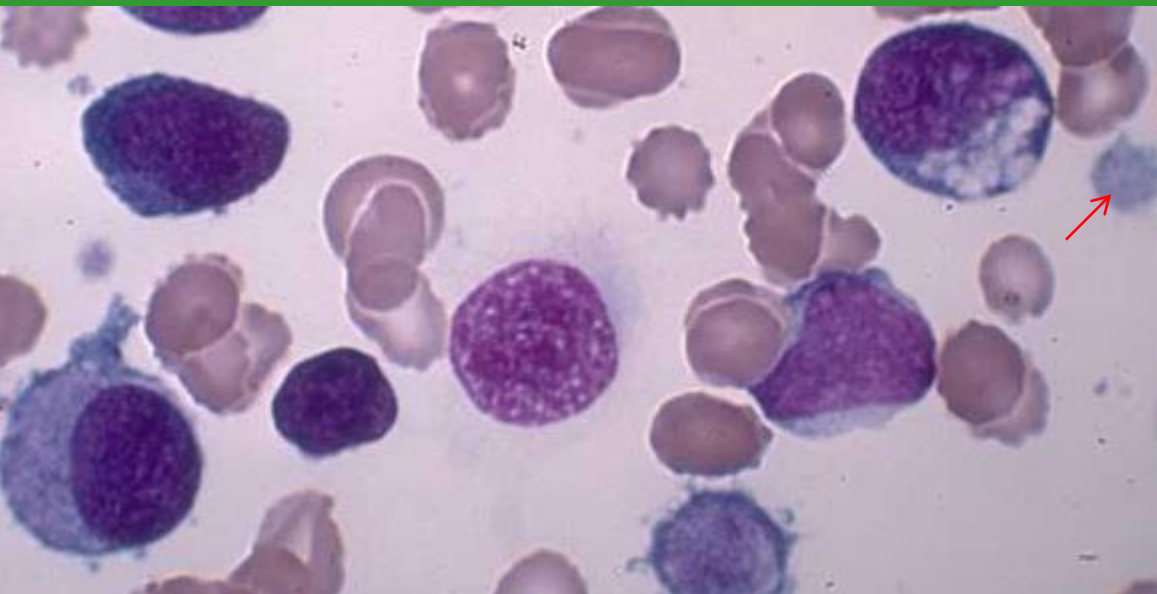
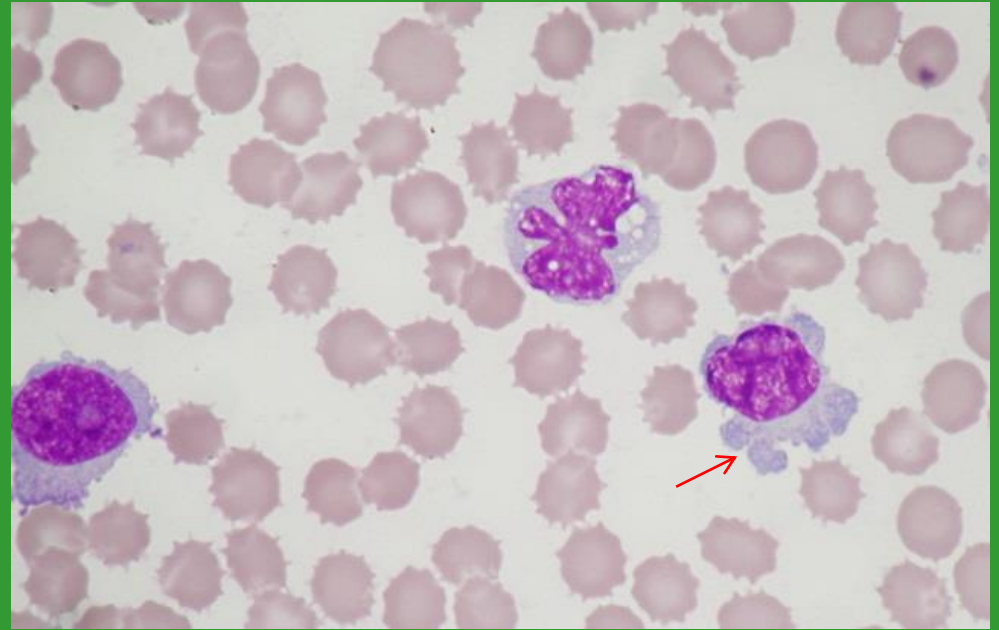
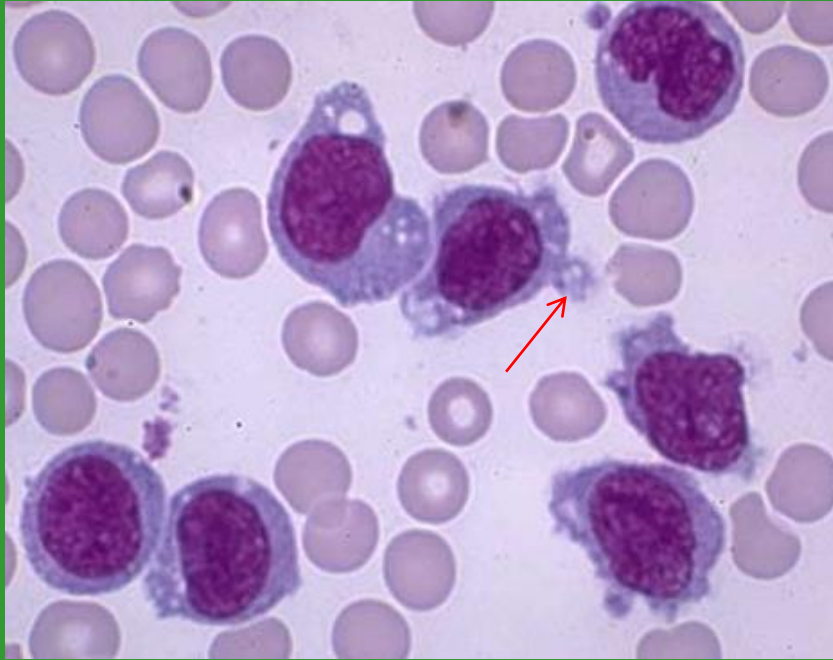
# Makrotrombocyty – gigantické trombocyty



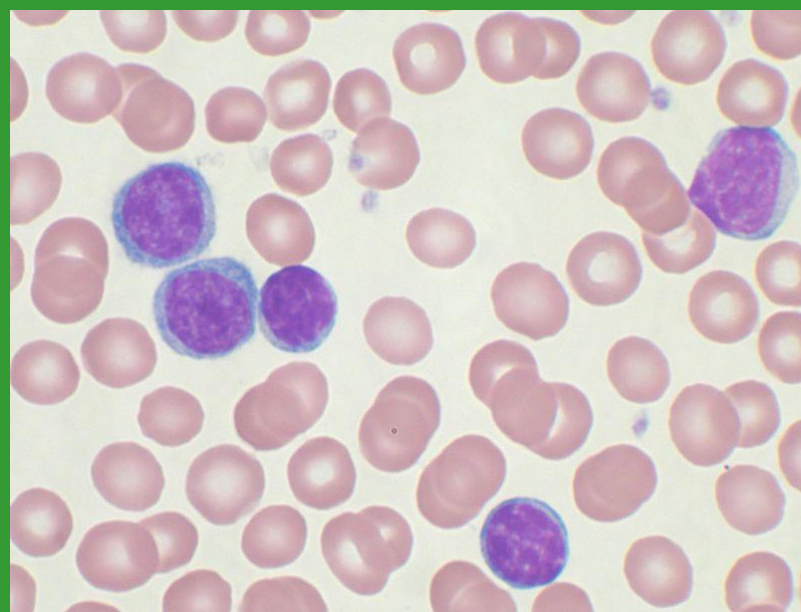
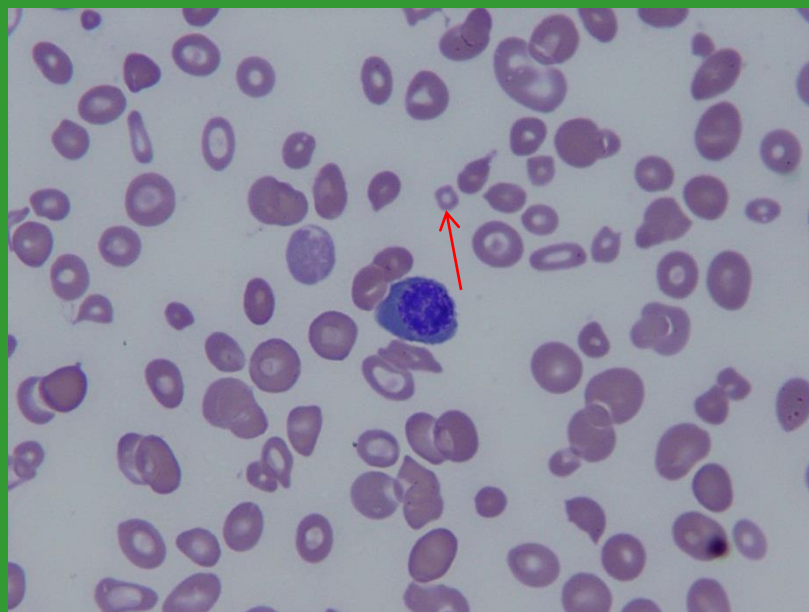
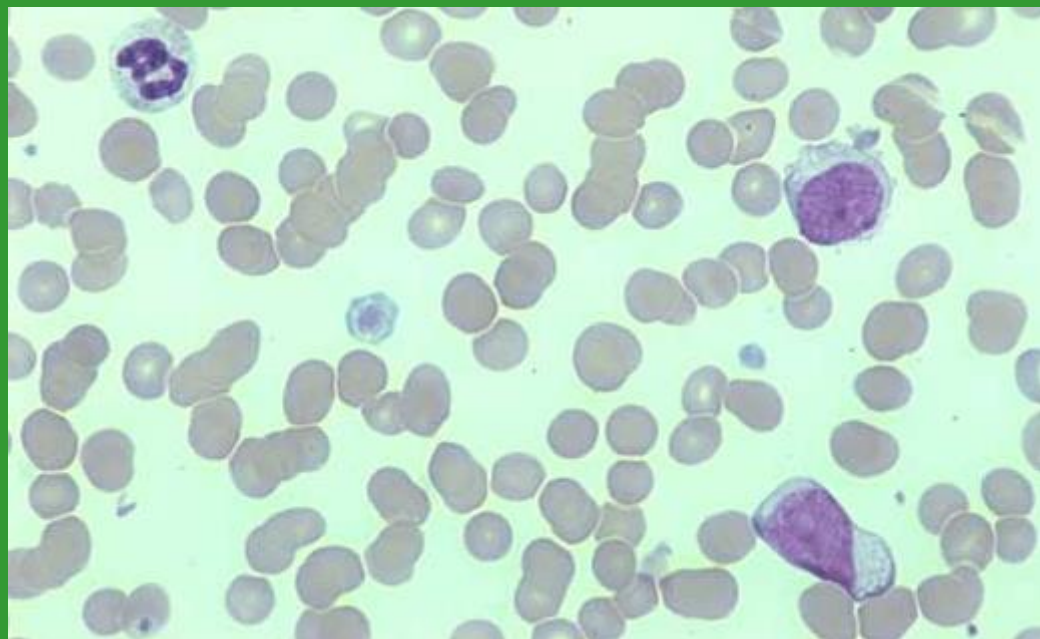
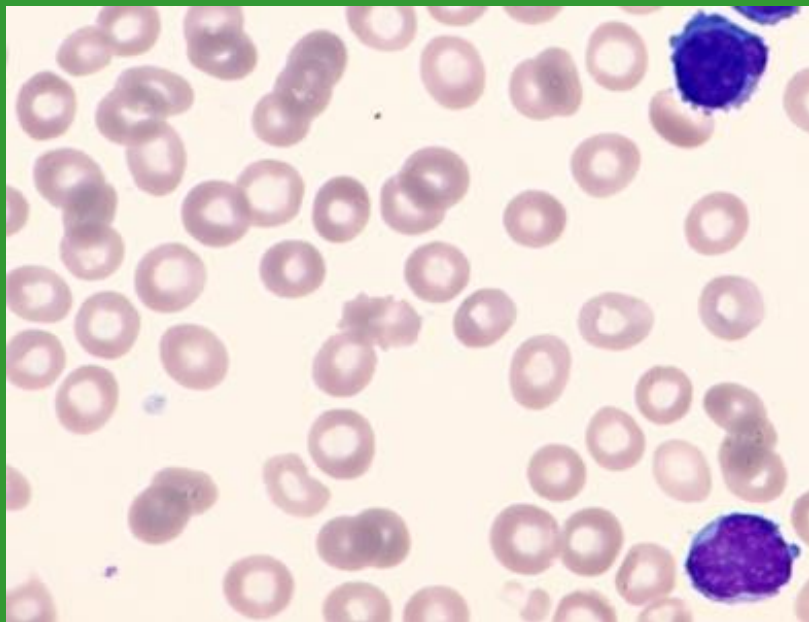
# Hypogranulární trombocyty



# *Fragmenty cytoplazmy (MGK x WBC)*

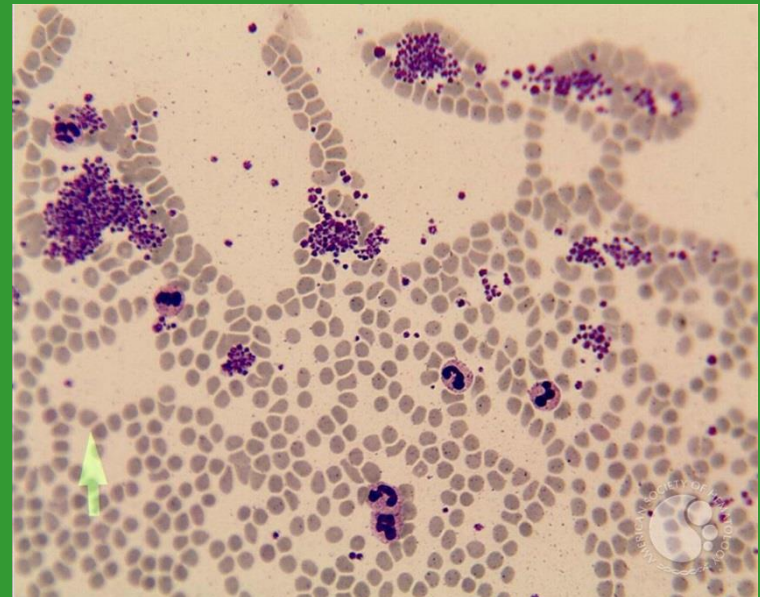
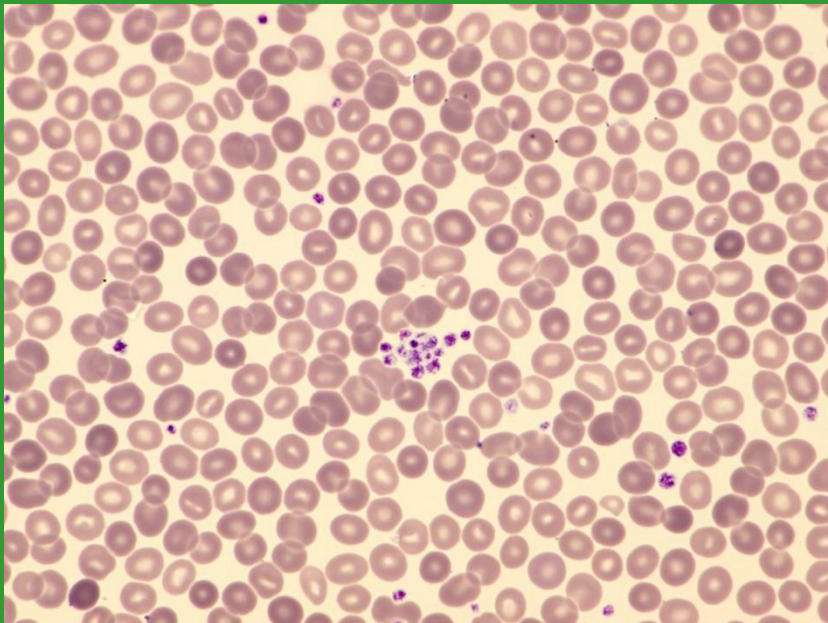
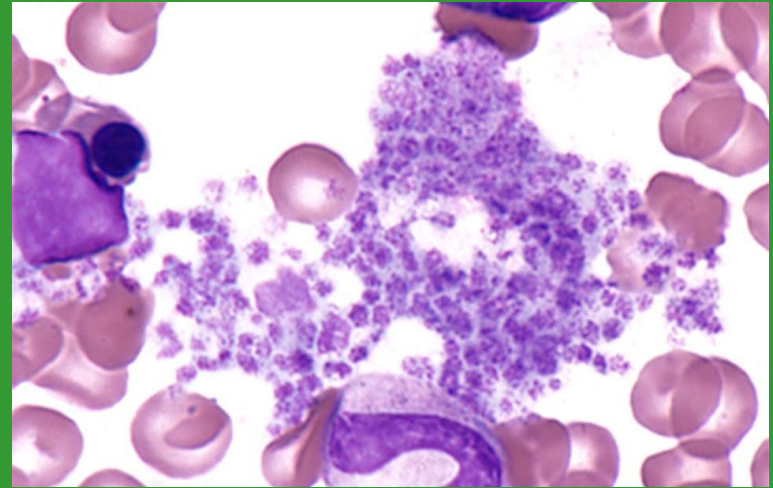
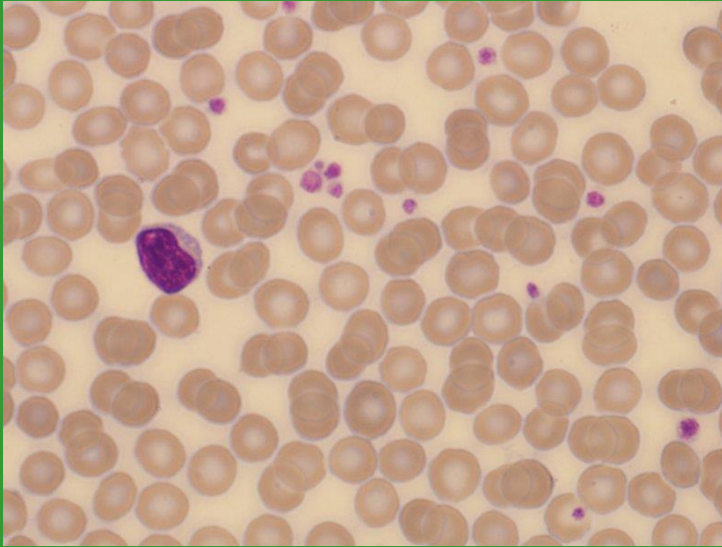


# PLT – hypogranulace x buněčné fragmenty x mikrocyty

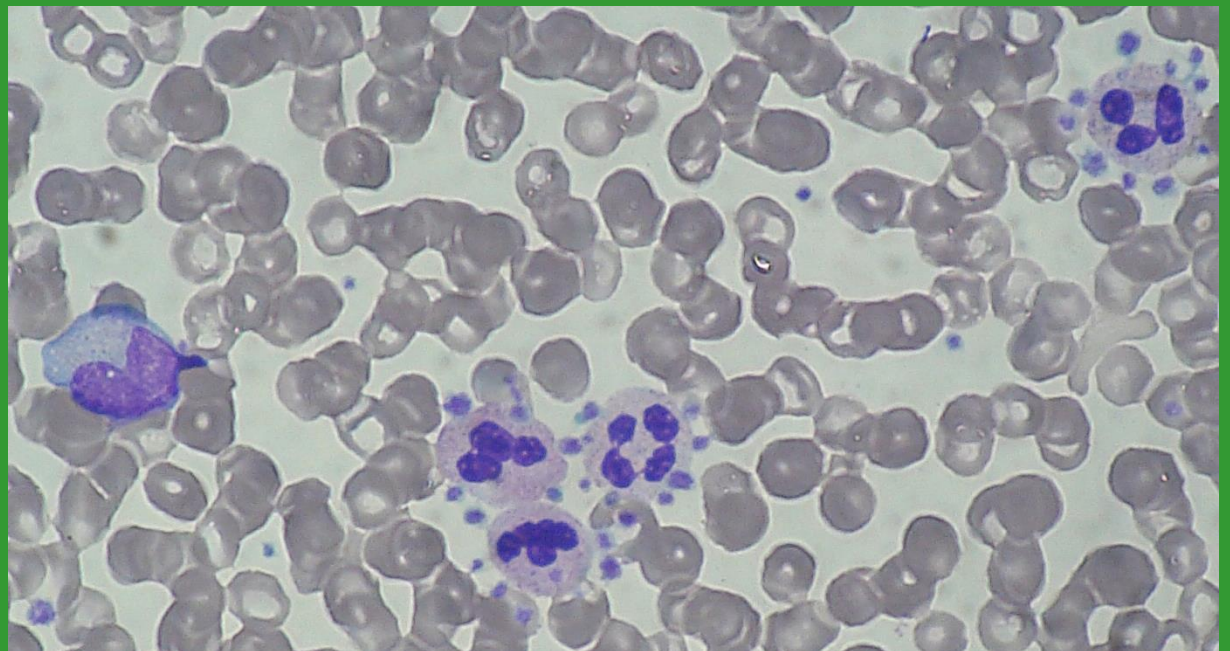
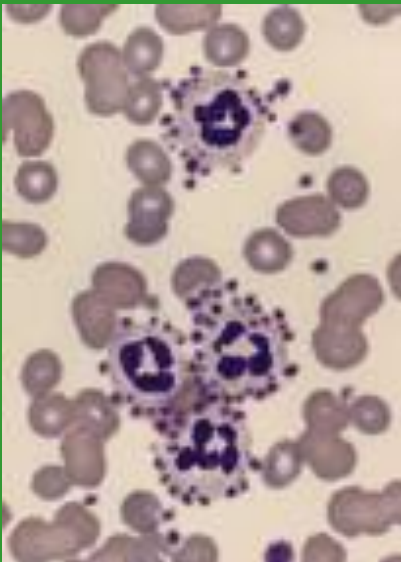
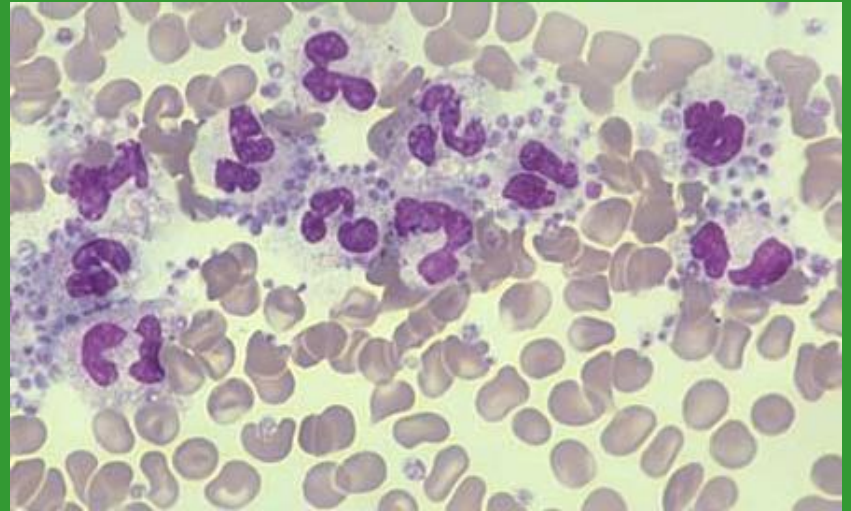
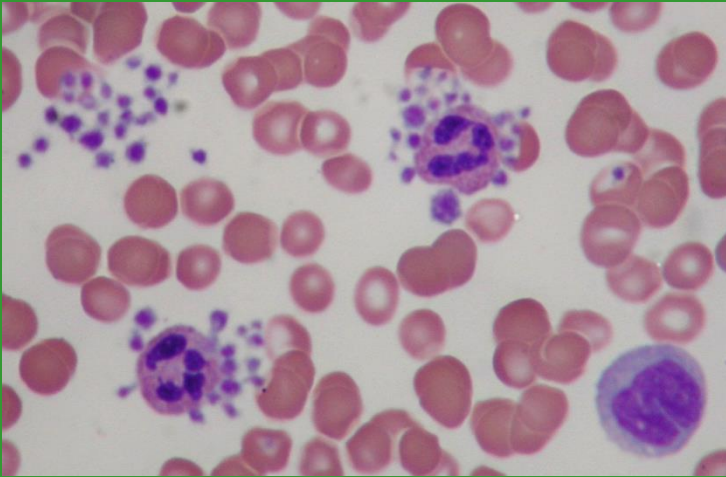




# Shluky/sraženiny trombocytů

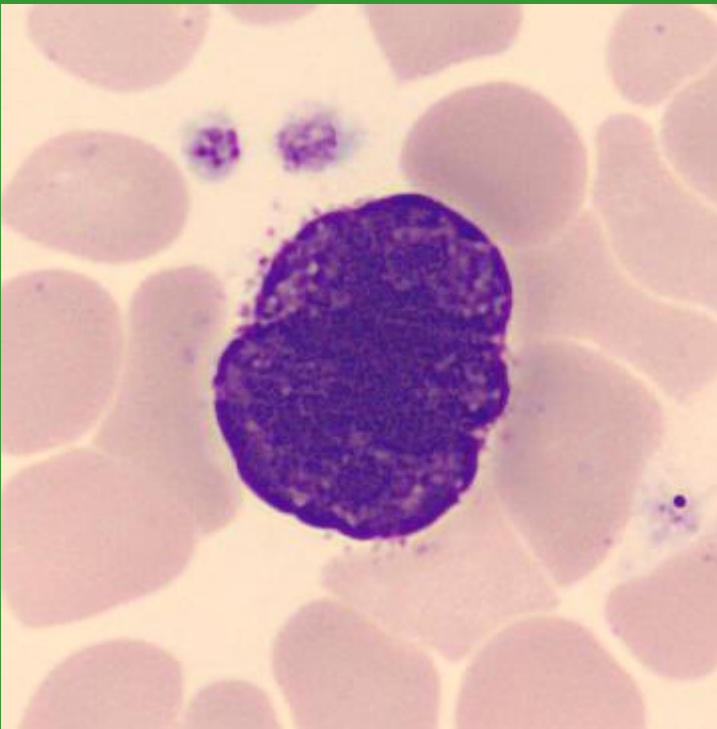


# Satelitismus trombocytů



# Megakaryocyty

holé jádro MGK v PK



MGK v KD

