

# **Skeletal Remains of Princess Buried at “Žuráň” Barrow**

## **(South Moravia, Czech Republic)**



**Eva Drozdová**

Laboratory of Biological and Molecular Anthropology, Department of Experimental Biology, Faculty of Science, Masaryk University Brno, Czech Republic

**Josef Unger**

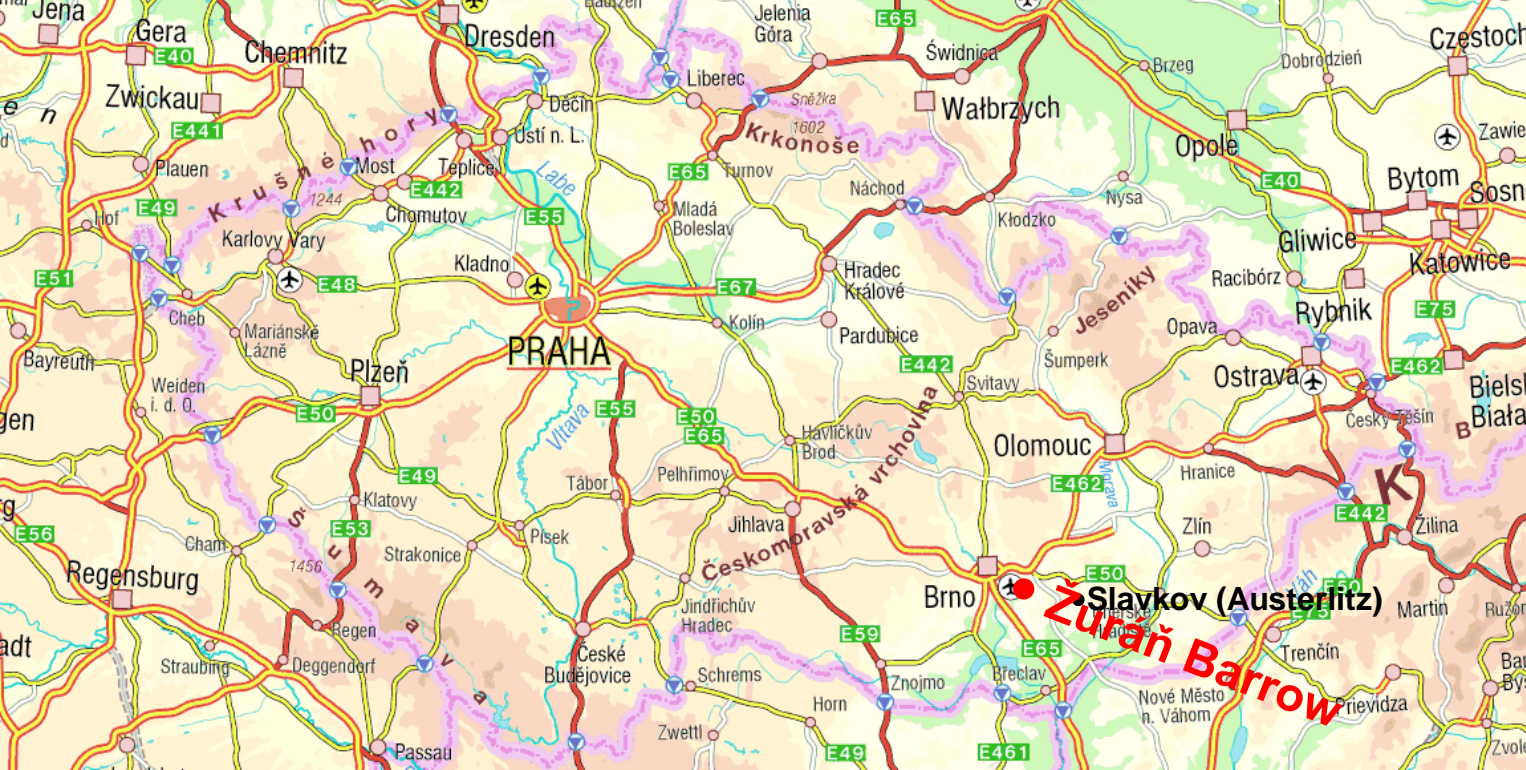
Department of Anthropology, Faculty of Science, Masaryk University Brno, Czech Republic

**Václav Smrčka**

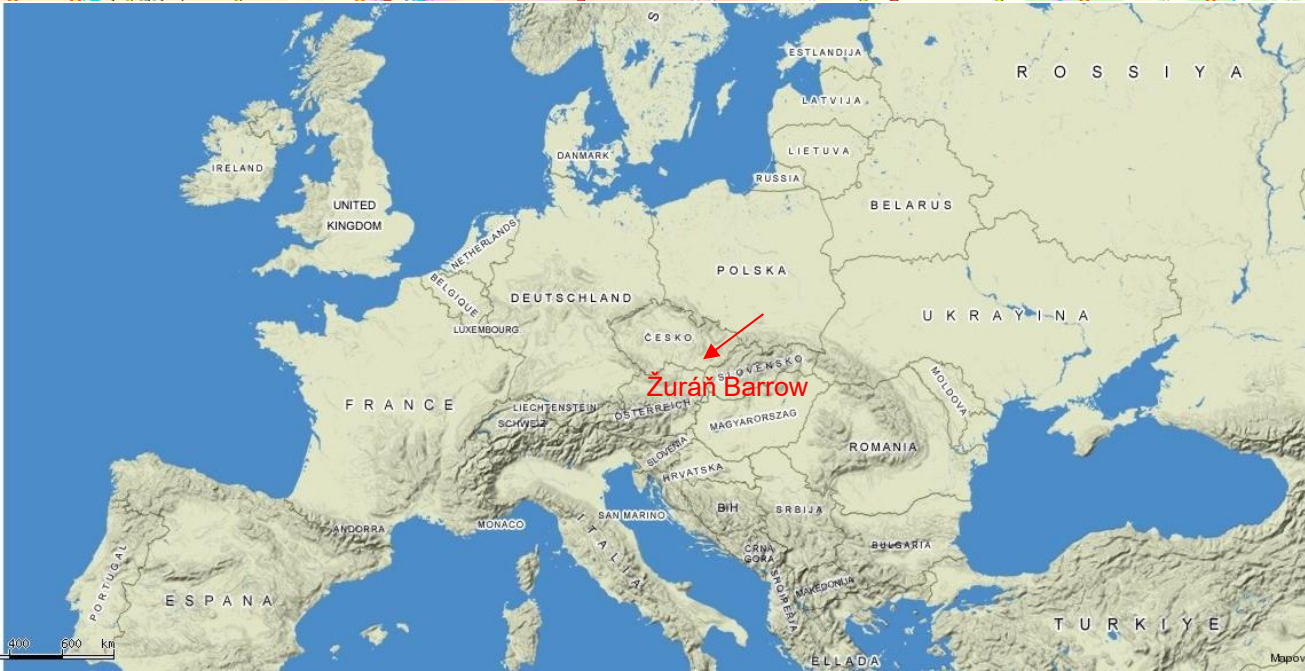Institute for History of Medicine and Foreign Languages, First Medical Faculty, Charles University in Prague, Czech Republic

**Petr Krupa**

Department of Medical Imaging, Medical Faculty, Masaryk University Brno, Czech Republic



It is located at Moravia - South part of Czech Republic between South-Moravian capital Brno and little town Austerlitz




The Žuráň Hill is 14 meters high round with 65 meter in diameter.

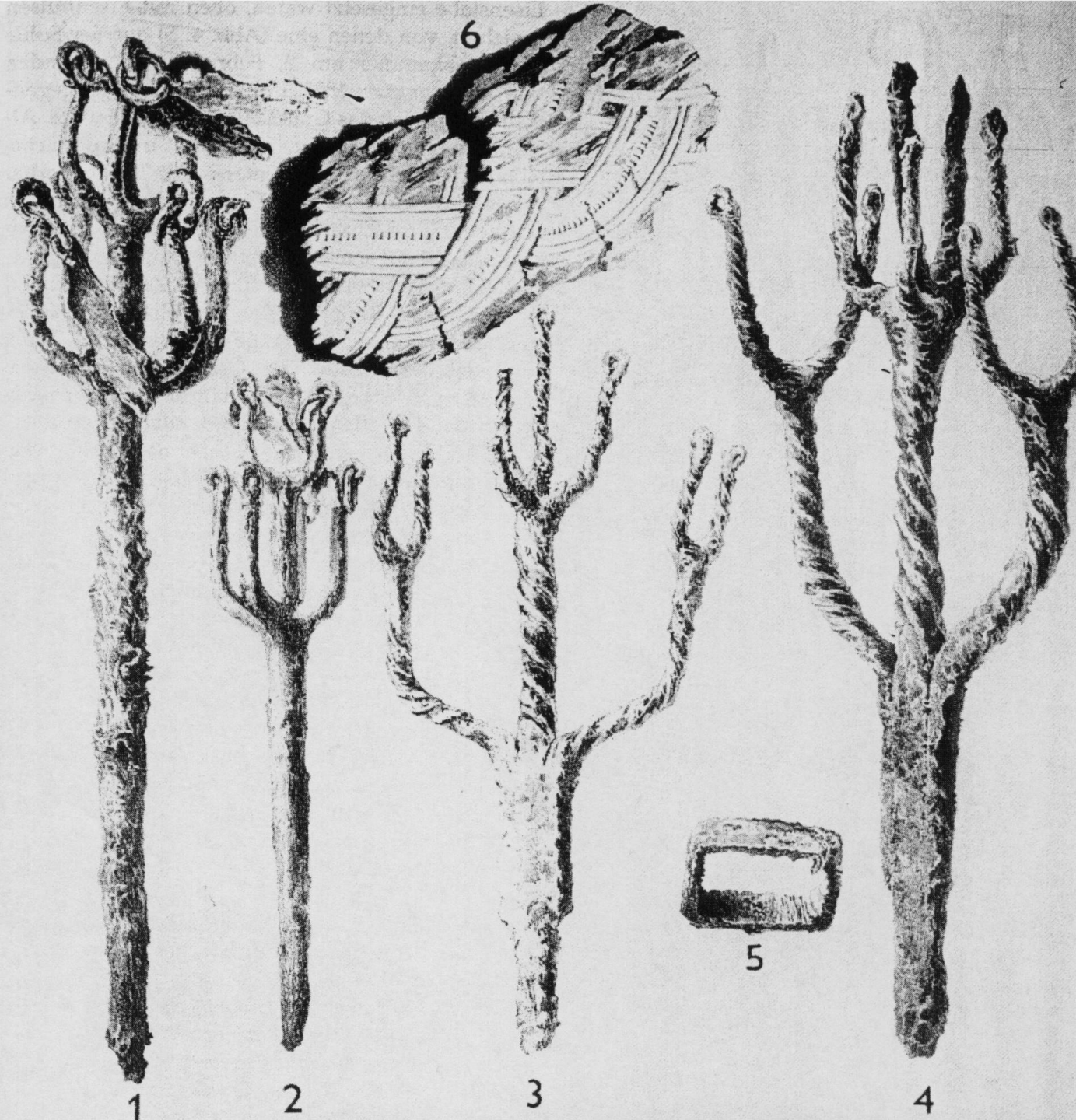




The Žuráň Hill came to history as the place from Napoleon Bonaparte directed the Austerlitz battle at 5th December 1805.

This hill is in fact a great barrow dated to archaeological period of Nations Movement (5th – 6th century A.D.).





The first archeological exploration of Žuráň barrow was implemented in the year 1853 by the Moravian historian Ritter von Chlumetzky. His activity is counted for one of the oldest archeological exploration at Moravia.

At his research were found ferrous “dendriform” artifacts, as well as of wooden piece decorated with girdle garniture.






The **real archeological exploration** was managed 100 years after Chlumetzky in the years **1948 – 1950** handled by Josef Poulík (Poulík 1995). Early medieval finds from the site were interpreted by Poulík so that **in 5th and 6th century A.D. at the site were created two funeral chambers for members of sovereign rank of certain German tribes which settled Moravia in this time.**

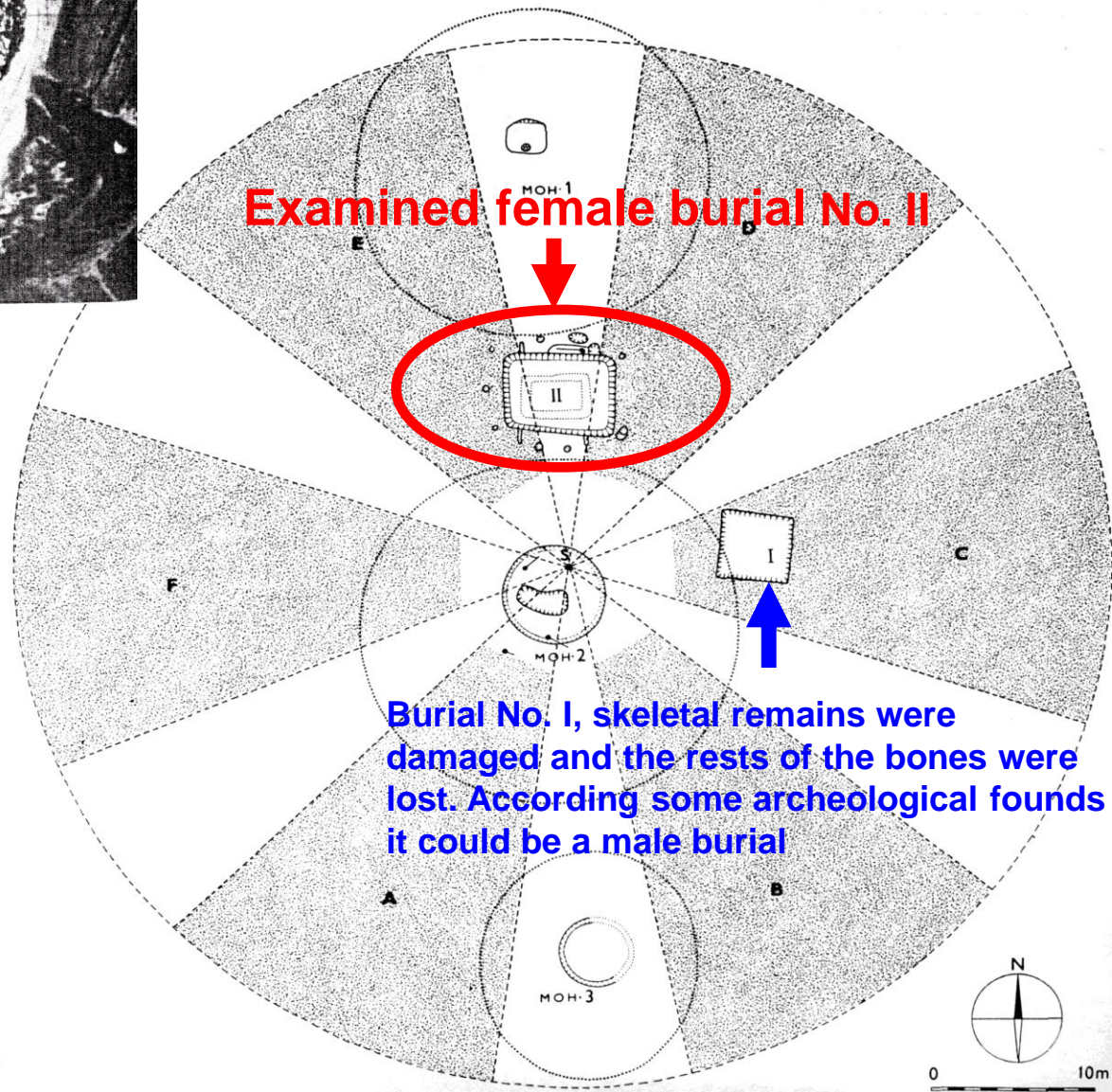
**Subsequently, earliest in 6th century great stone and soil construction was build above these graves.** This construction was very large for this time. It was round 65meters in diameter. Poulík interpreted this construction as a rest of 14meters high mausoleum. **The Žuráň mausoleum according Poulík should simulate mausoleum of Roman emperors Augustus and Hadrian.** But this interpretation is not explicit. **Such mausoleum in the ambient of Moravia in 6th century A.D. would be very rear. Rather then mausoleum we speak today about great barrow.**

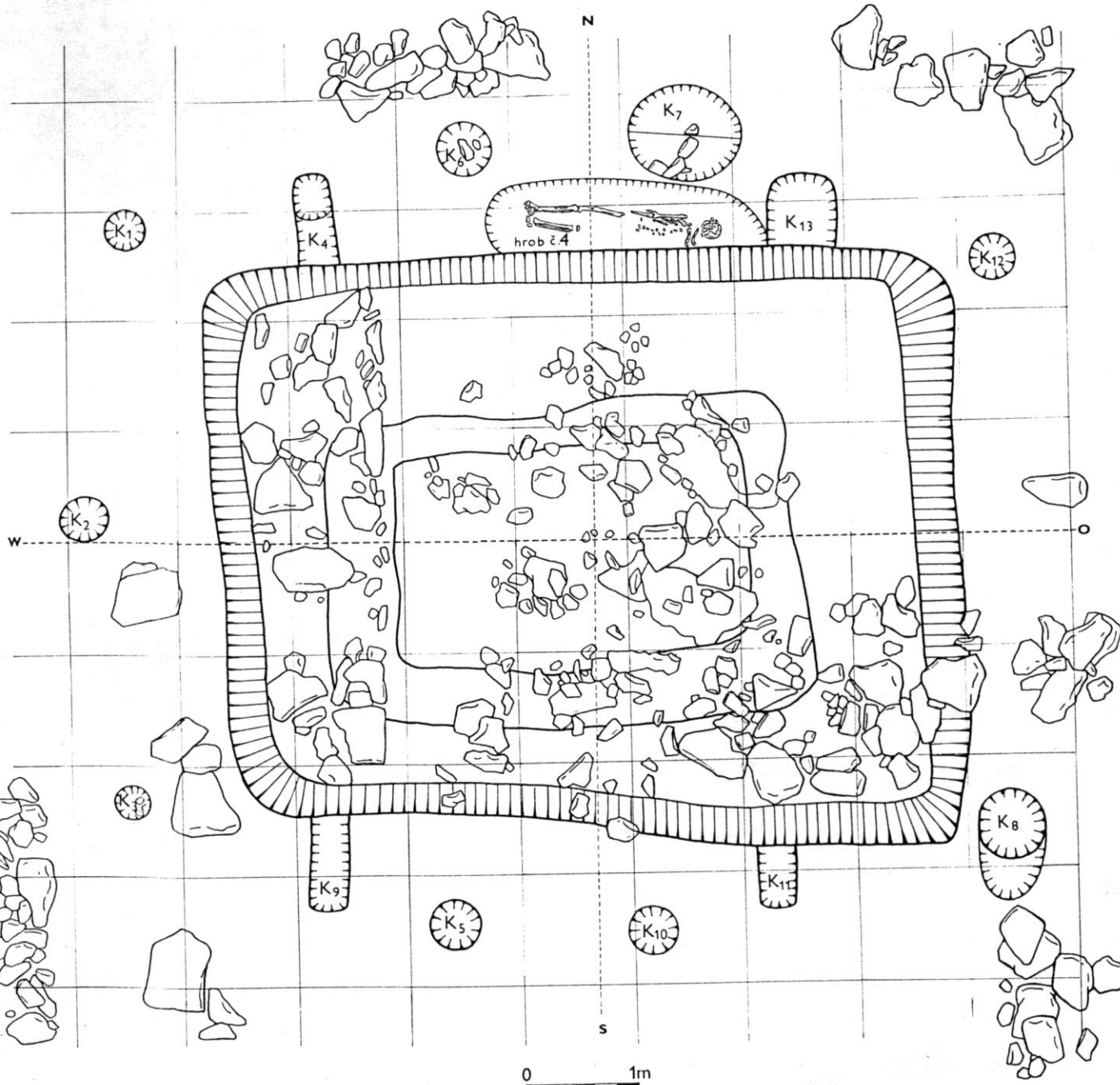




During the exploration two skeletal burials were found. The archeological finds from this burials were very rich.

According found artifacts Poulík interpreted the two graves as a burials of members of sovereign rank of certain German tribes which settled Moravia in this time.





## Detail of burial chamber No. II

It has square shape. It was 5,4 m deep.

Together with human skeletal remains and cultural artifacts

**Horse bones** were found pertaining of **two individuals**

The burial chamber had a **wooden roof**.





## The artifacts found in burial No. II



- Rest of ivory pyxis

Dating of the barrow is based on datation of this pyxis to 6th century A.D.




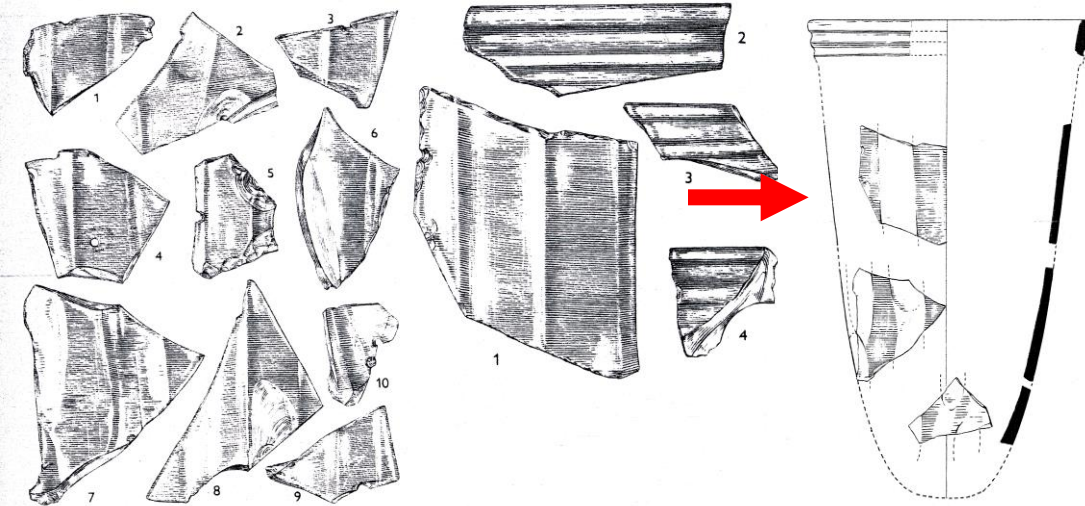
- Ivory plates



## The artifacts found in burial No. II

Glass pieces from two receptacles, reconstruction of the greater one

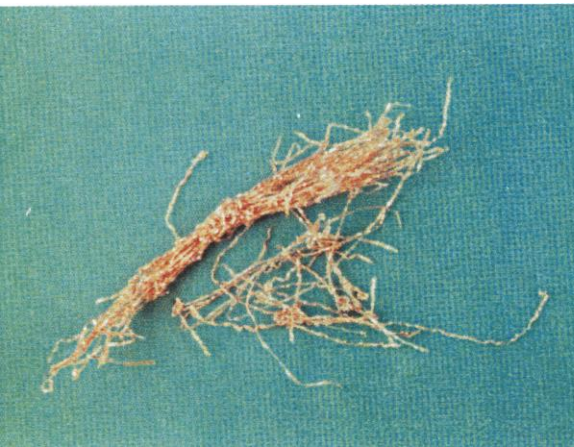

Small pieces of silver decorations




Golden fibers possibly from cloth decoration

Pieces of ring and plates all made from animal bone

Pearls made from Golden fitting of a belt

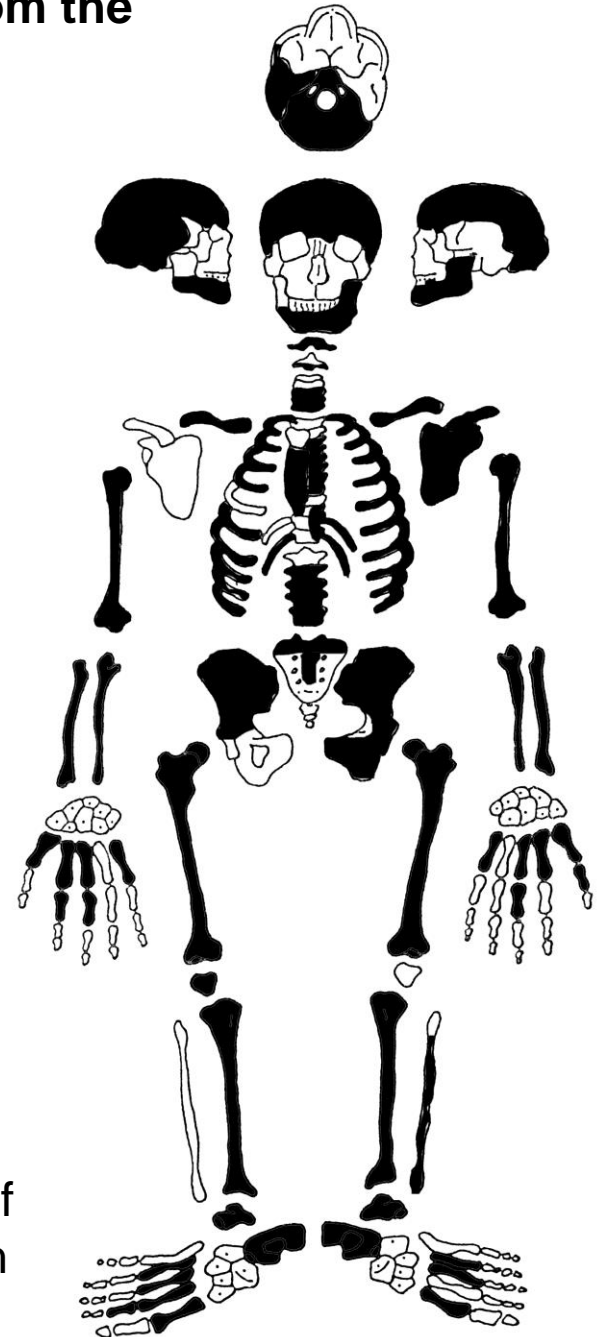




## Human skeletal remains from the burial No. II

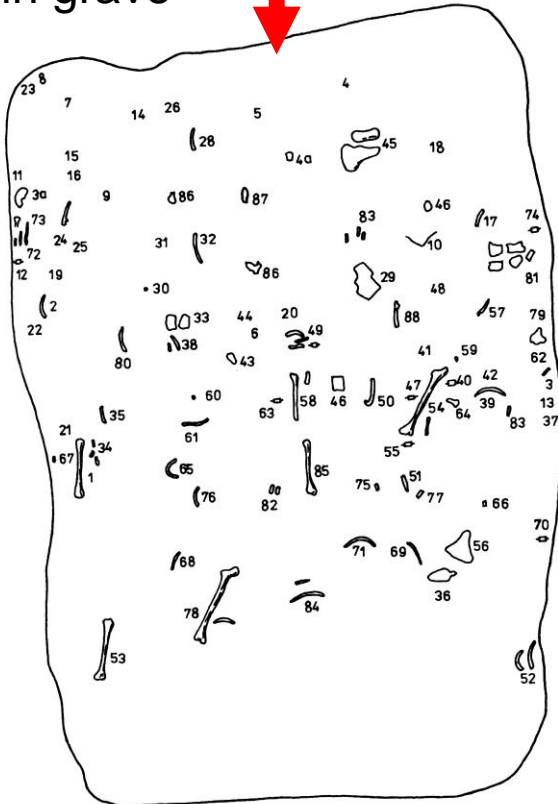
The skeletal remains were found in excavation period **1948 – 1950**. They were **never anthropologically evaluated until this time**.

They were lost and found again in year 2006 on the occasion of depository revision at Faculty of Science Masaryk University in Brno, Czech Republic.



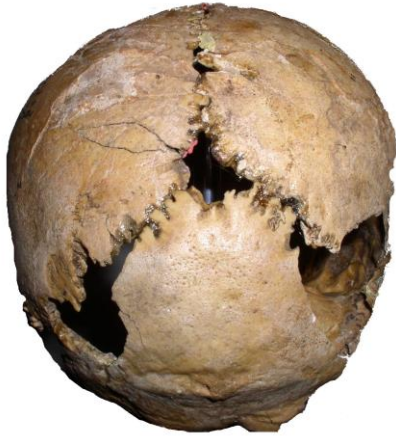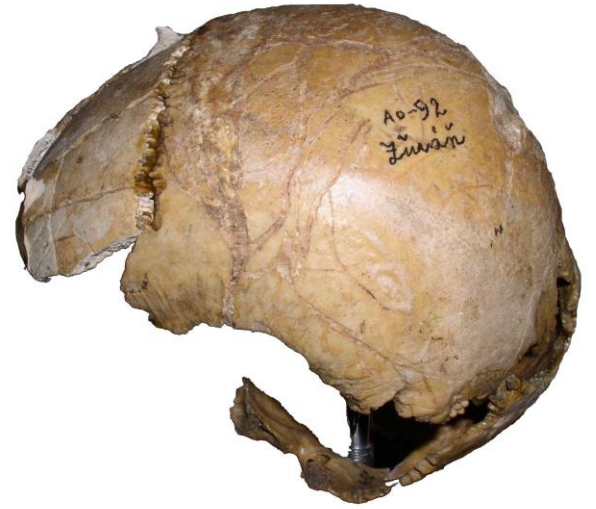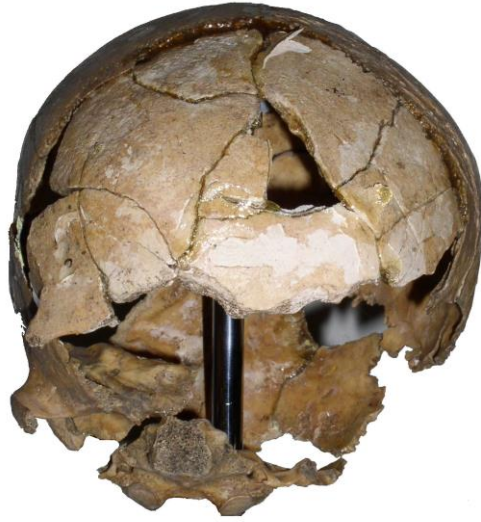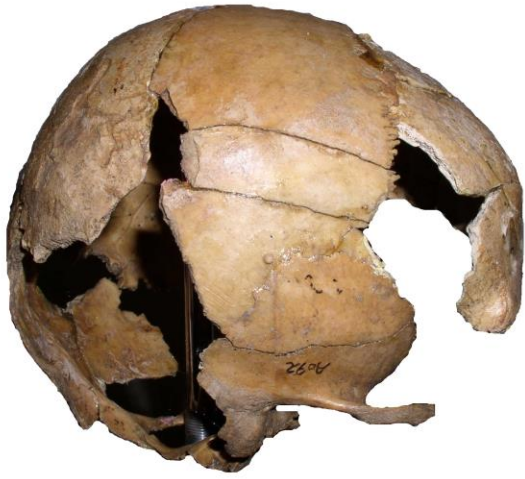The burial chamber

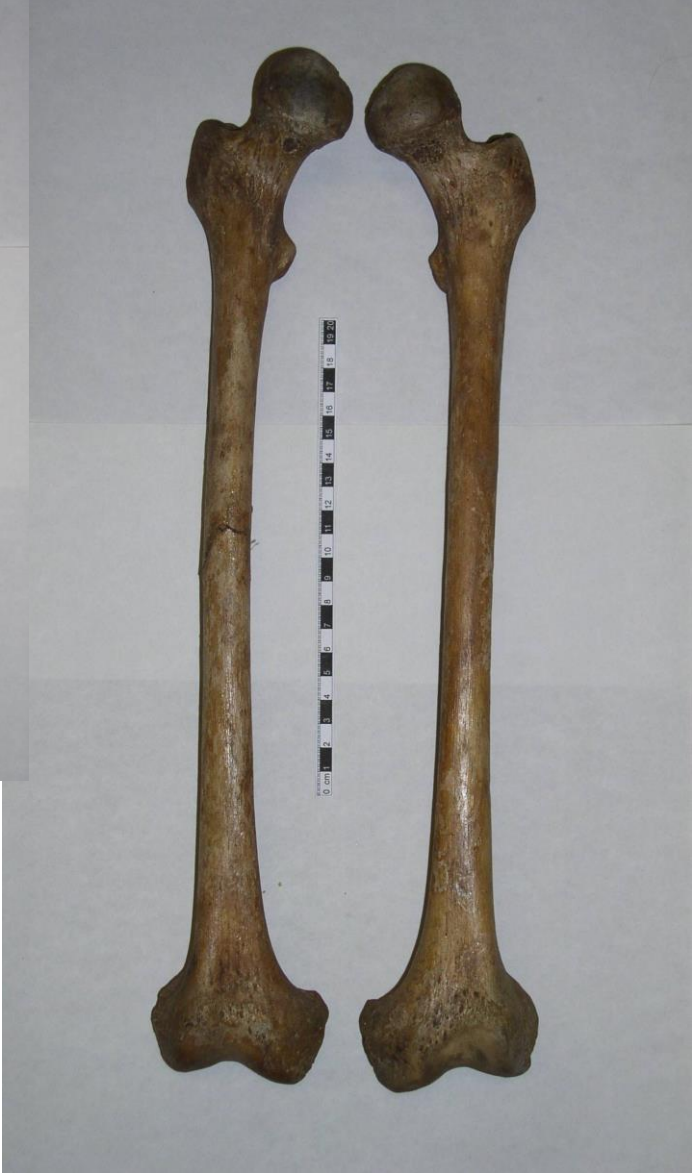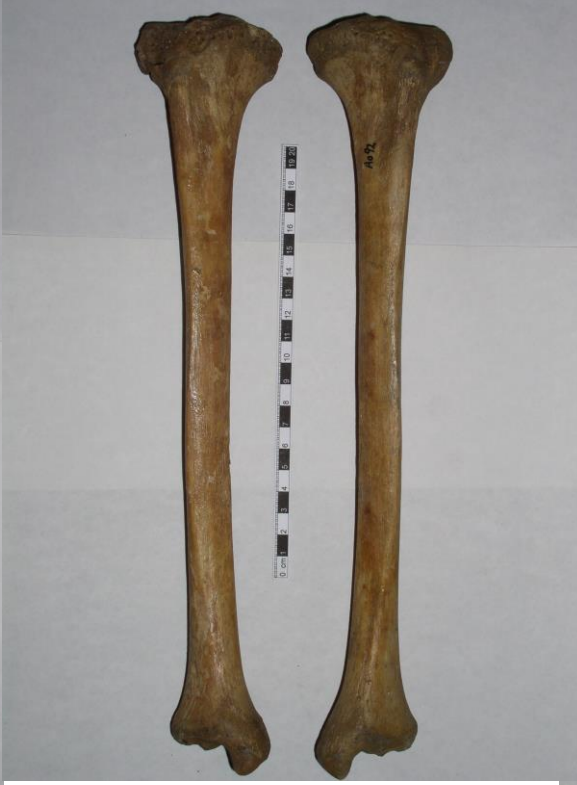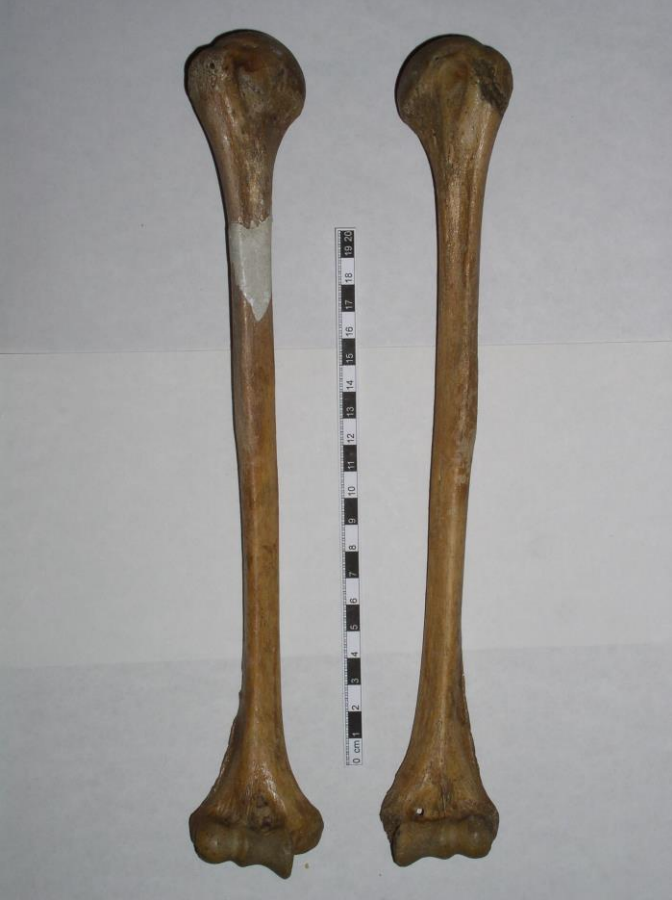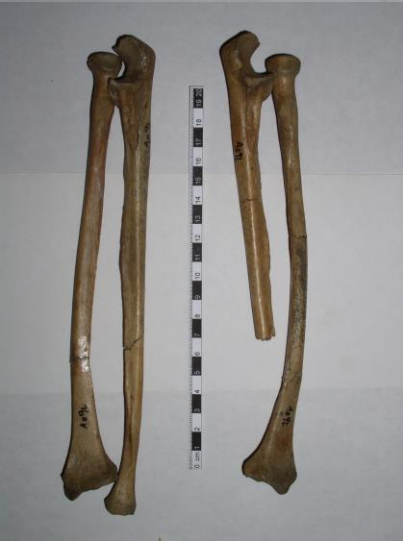Distribution of human bones in grave



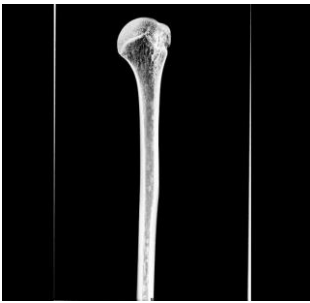
The skeletal remains are composed from damaged braincase (lacking facial skeleton) and very good preserved postcranial skeleton. The skeletal remains pertain to woman of very gracile constitution with outstanding muscular relief.



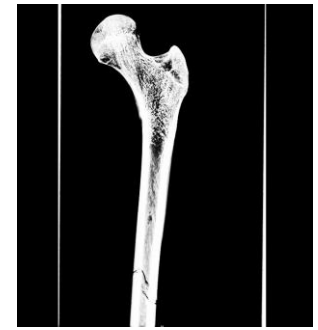








## Skeletal remains of the „Žuráň“ princess



The sex determination is based on morphometry and morphology of pelvic bones. In all indices according Novotny (1985) are the pelvic bones ultrahyperfeminine, according Murail, Brůžek et al. (2005) are clasified as feminine. Result: the pelvic bones pertain to very gracile **woman**.

The changes at sulcus preauricularis at the pelvic bones shows that **she gave birth to a child**.

Age at death was determined by method of Nemeskéri et al. Based on four traits (structure of bone in proximal ends of humers and femur, structure of relief facies symphysialis ossis pubis and degree of closure of ectocranial skull suturas).

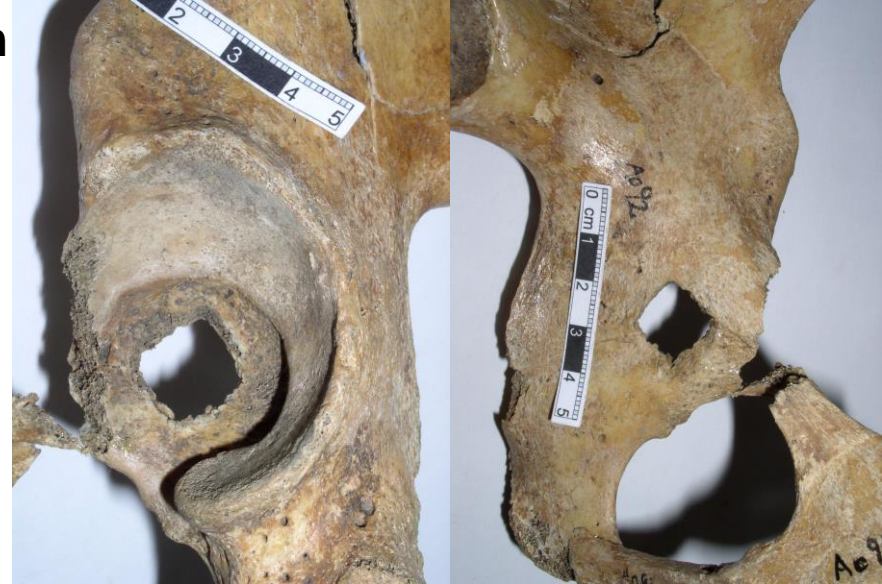According this method died the woman in age of **37,75 year**.

Stature height was counted according the Sjøvold (1990) method at **158,6 ± 4,49 cm** (according the lenght of right femur).

## Quadratic defect in acetabulum of left pelvic bone



Os coxae dx. without any  
defects

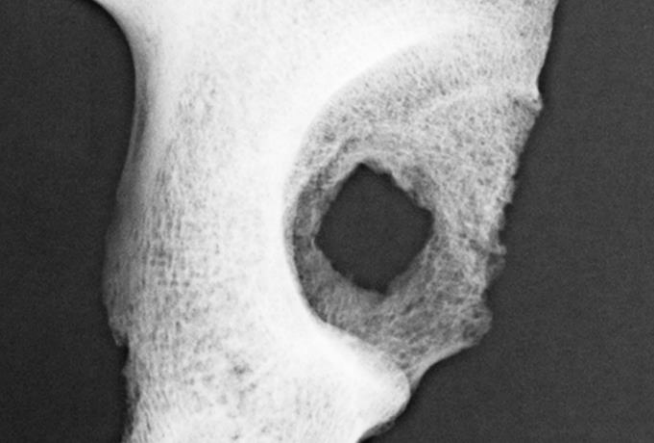


Os coxae sin.

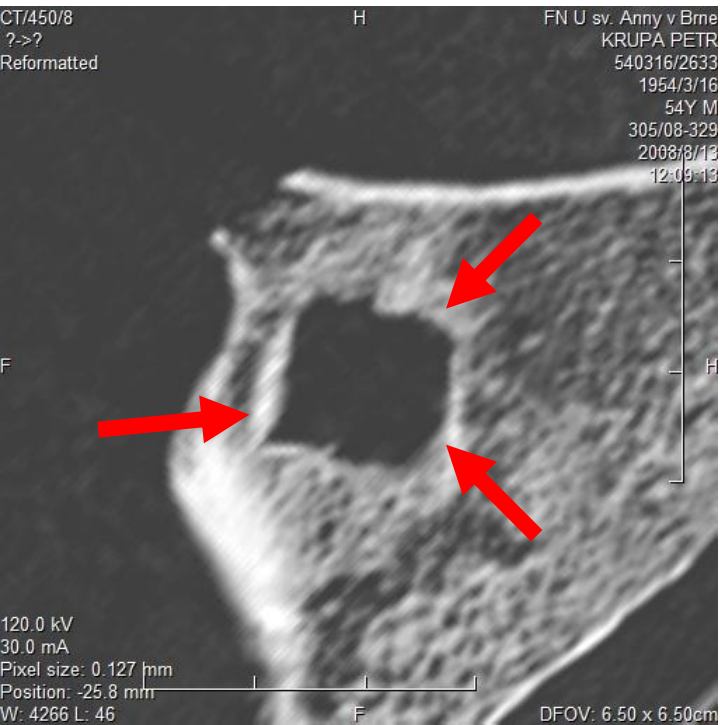
Possible origins of the defect:

1. It was made ante-mortem and caused her death (death by killing or by an accident).
2. It was made post-mortem as a cause of burial heisting (often in this historic period). It could be an evidence of probing by ferrous stick by muggers or an evidence of taking bones from the more meters deep grave by ferrous hook. Analogies are known e.g. from German sites Friedberg-Bruchenbrücken (Unger 2006a) and Eussenheim (Koch 1996).





**Radiographic screening** showed any changes indicating healing at the injury margins.



**Computer tomographic screening** showed the healing changes at the perforation margins. There is very slight pattern of bone reparation.

CT examination of the left pelvic bone shows that the defect was caused ante-mortem. The woman lived still short time after this accident. According the very slightly bone changes is evident that the healing process just started. She could survive approx. three weeks after accident causing this injury.

The caput femoris sin. was examined on changes connected with the acetabular injury. Any pattern of changes of the bone structure – trace of healing process or developmental abnormality at CT record is not present. The comparison of morphological traits of both caput femoris shows that left caput femoris has deeper fossa capitis. But we have not evidence for connecting this difference with the acetabular injury.

Why was the caput femoris sin. not affected by the acetabular injury? We can only expect that it could be by the injury exarticulated (and not affected) or the knife of the used weapon was short and didn't touched to the caput. But we don't know the instrument what caused the injury and this ideas are only speculations.

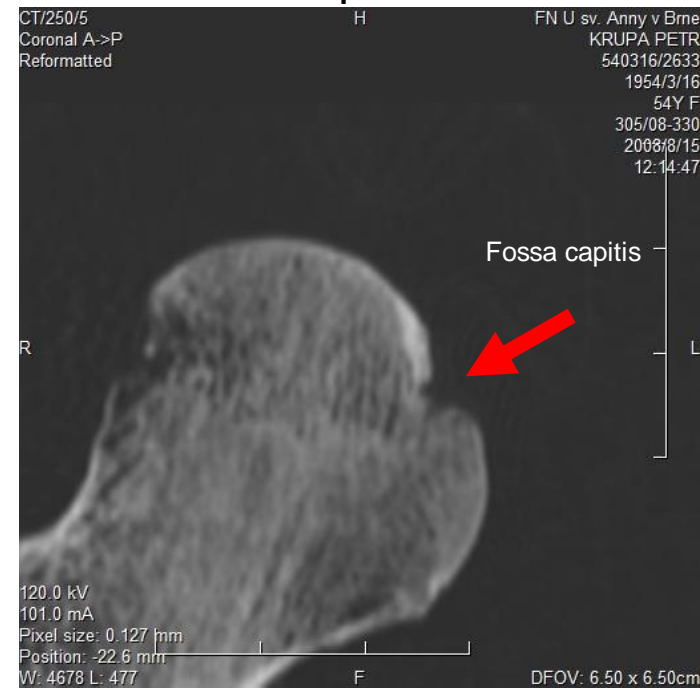
Caput femoris dx.



Caput femoris sin.



CT record of caput femoris sin.





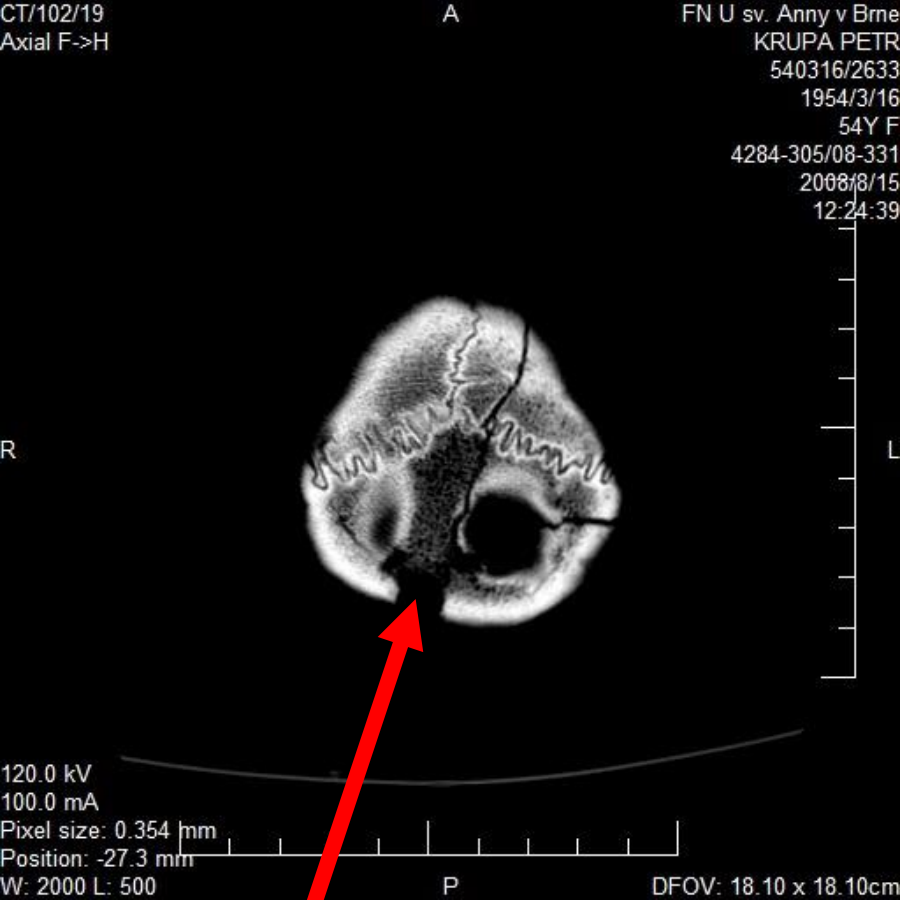
## Conclusions

In the burial chamber No. II at Žuráň site was found well preserved skeletal remains of a **woman, approx. 38 years old, 158 cm high, she had a children.**

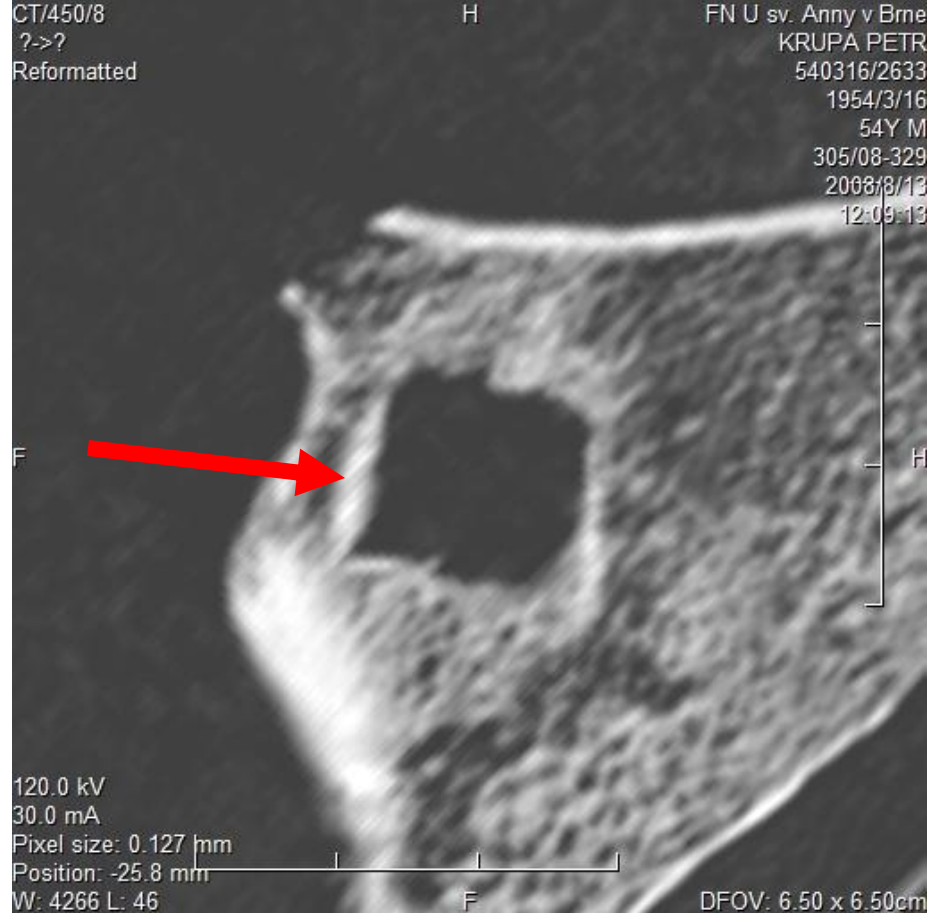
**Her death caused an injury located in centre of left acetabulum.** At margins of this defect are present changes caused by healing process. It means that **she survived short time after the injury.** The changes are very slight, the healing process started shortly before she died. We estimate her life after the accident on **three weeks maximally.** This injury could be **caused by outrage or by accident.**

**We don't know the weapon caused the injury.** Its knife must have a square shape, it could be a knife, an arrow or a lance. If we suppose the accidental cause - the weapon could be some object of daily use from the house equipment. To find the possible weapon is a task for archeologists. It is necessary to try to find this object among the known artifacts dated to the Nations movement period.

Archeological finds classify the woman as a member of the nobility rank of some German tribes which settled Moravia in this time (Nations Movement period). We don't know exactly her identity. But the richness of archaeological finds in her grave, especially the presence of the pyxis – connection with Christianity - could suggest us her identity. Some archaeologists and historians assume that it could be the **Langobardian queen Fritigil** who was present approx. in this time at Moravia (first half of 5th century). But this theory was not yet positive verified, it depends on new - contemporary - dating of the pyxis.



Occipital bone with shooting injury.  
There are no traces of healing



Examined pelvis with traces of healing  
(white lines around the perforation margin)

For verification of signs of healing process at the pelvic bone was chosen a skull with traces of shooting injury at the occipital and parietal bones (the person was immediately dead). The tomographic screening didn't show any changes at the injury margins - markers of healing. When the defect at the pelvic bone would be of post mortal origin, its margins would look similar to the shooting injury at the comparative skull.