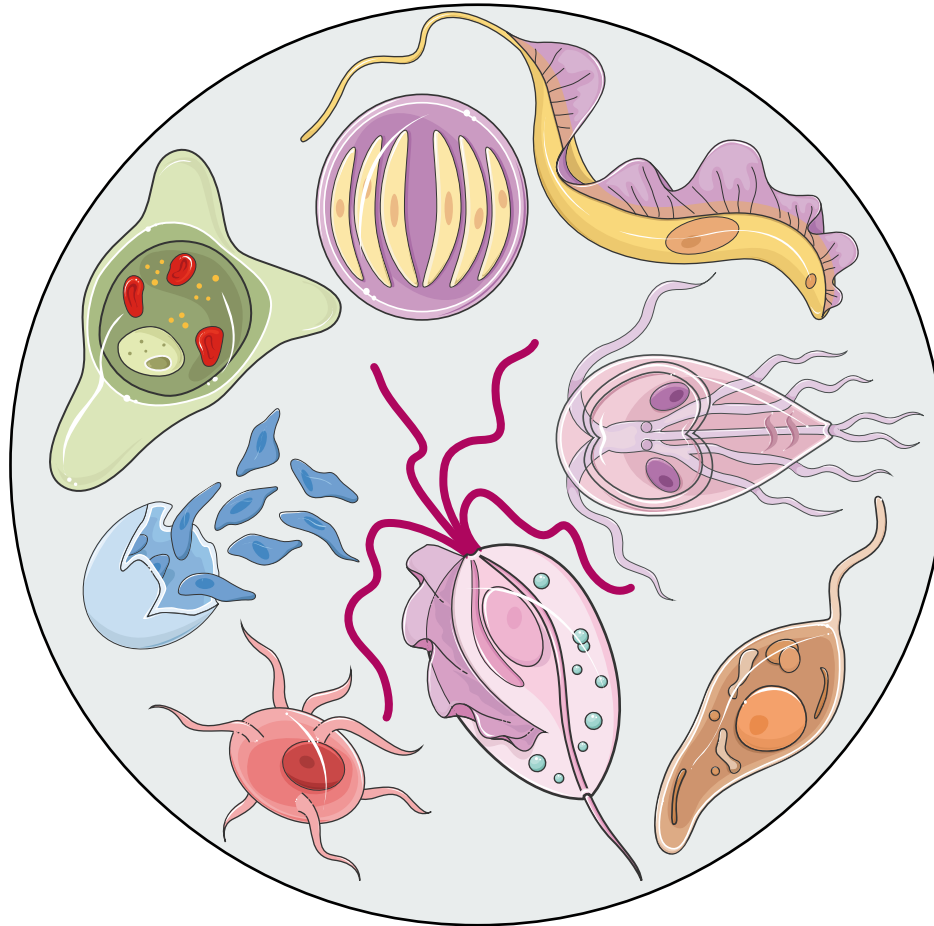


Biology of parasitic protozoa

IV. Apicomplexa I (SAR)



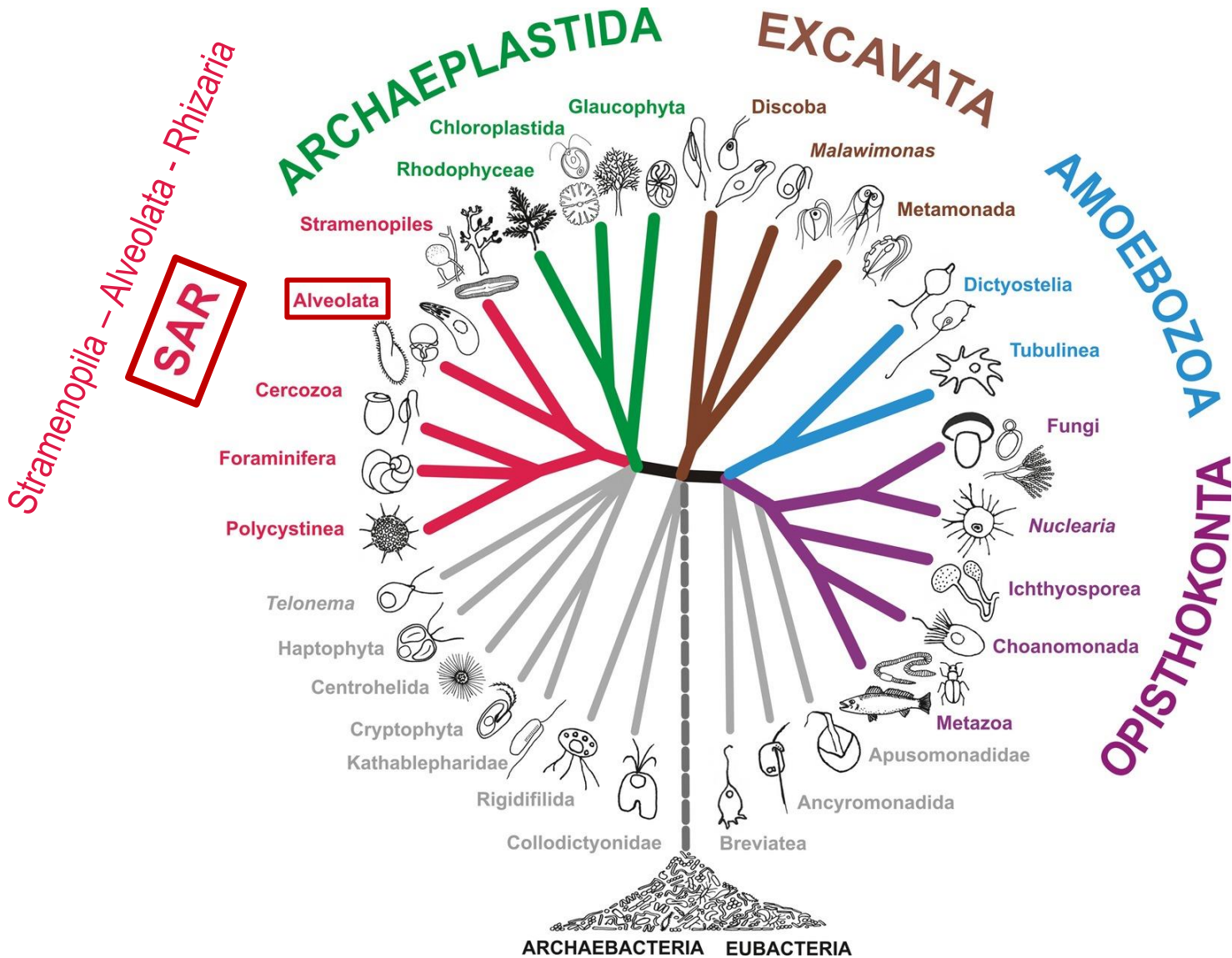
Andrea Bardůnek Valigurová

andreav@sci.muni.cz

Notice

This presentation contains some material available on the web without the permission of the creator or the copyright owner. This presentation is to be used for educational purposes only. Educational purposes are defined as a communicating material for a particular course of instruction or for the administration of such course. Educational purposes do not cover the use of copyright material in PowerPoint for public lectures or other purposes.

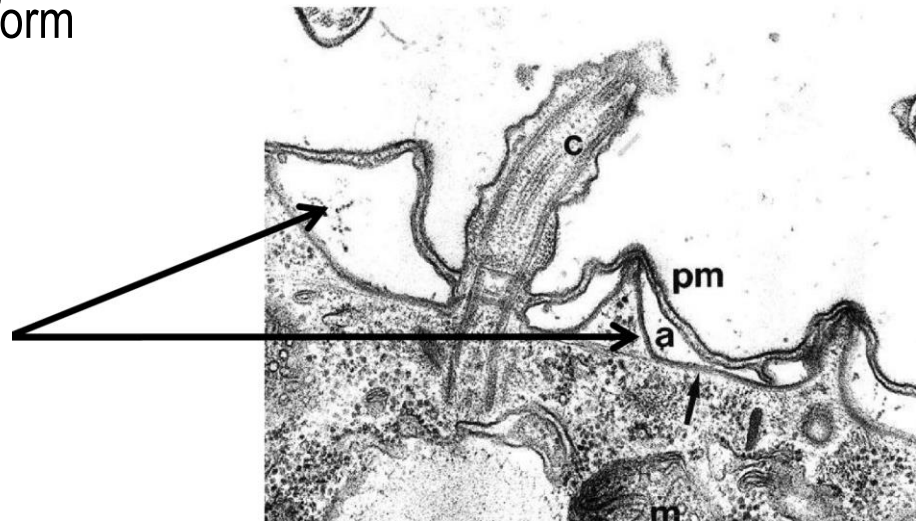
5 supergroups = megagroups



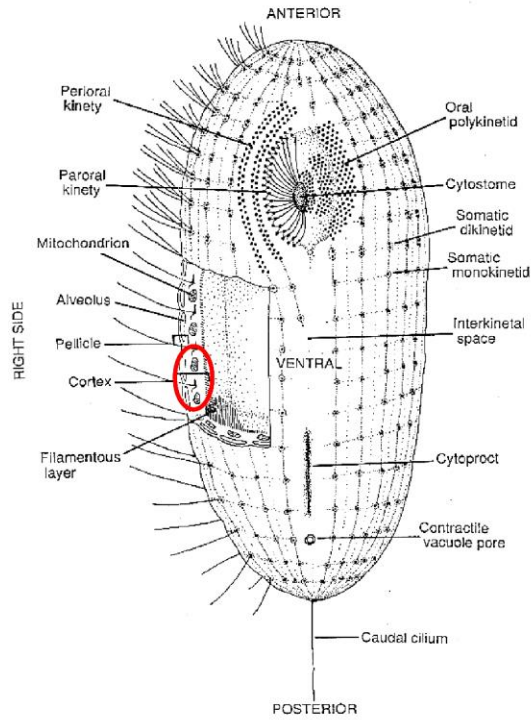
SAR (Harosa) - Alveolata

- **SAR supergroup**: Stramenopiles (heterokonts), Alveolata, and Rhizaria
- **Alveolata**: monophyletic group; 3 main subgroups: **ciliates**, **dinoflagellates** and **apicomplexans**
- extremely diverse modes of nutrition, such as predation, photoautotroph and intracellular parasitism
- **cortical alveolae** = system of flattened vesicles packed into a continuous layer supporting the membrane, sometimes secondarily lost
- ciliary pit or micropore
- mitochondrial cristae tubular or ampulliform

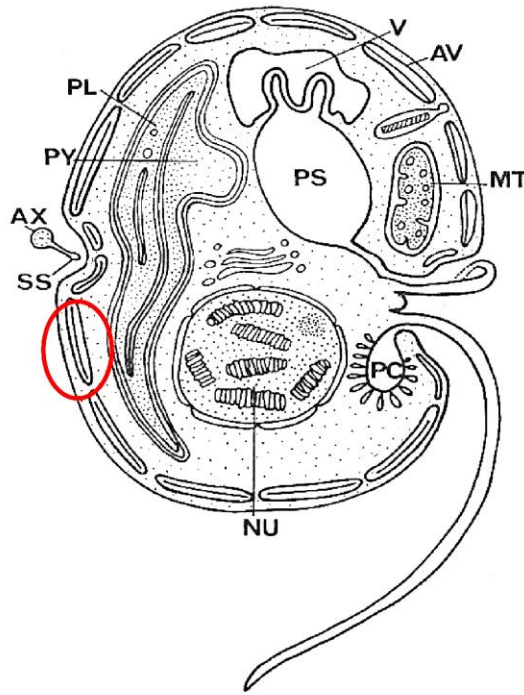
cortical alveolae
Tetrahymena (Ciliophora)



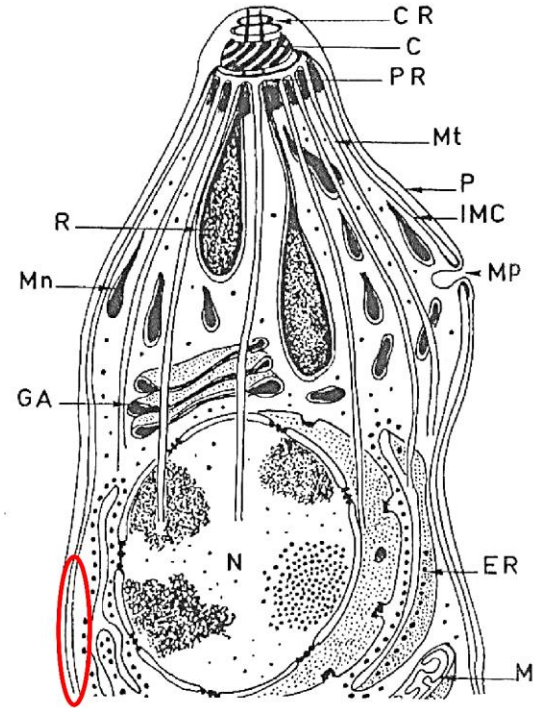
Cortical alveolae



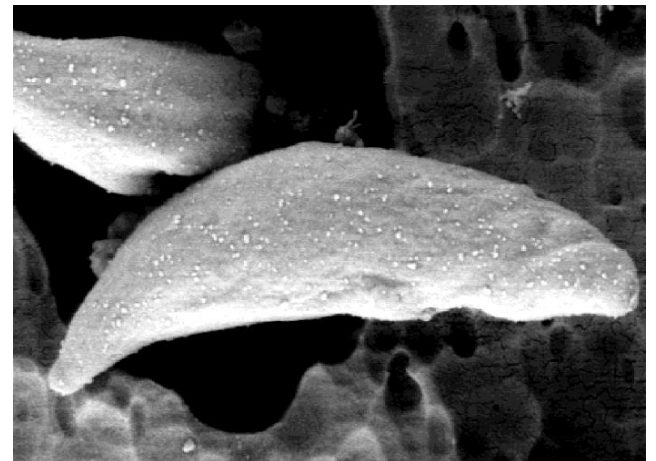

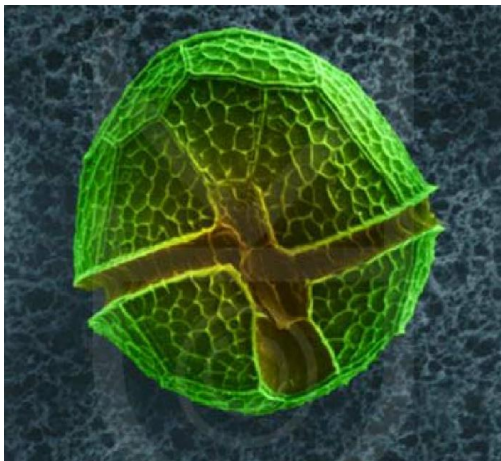
Ciliata



Dinofzoa



Apicomplexa

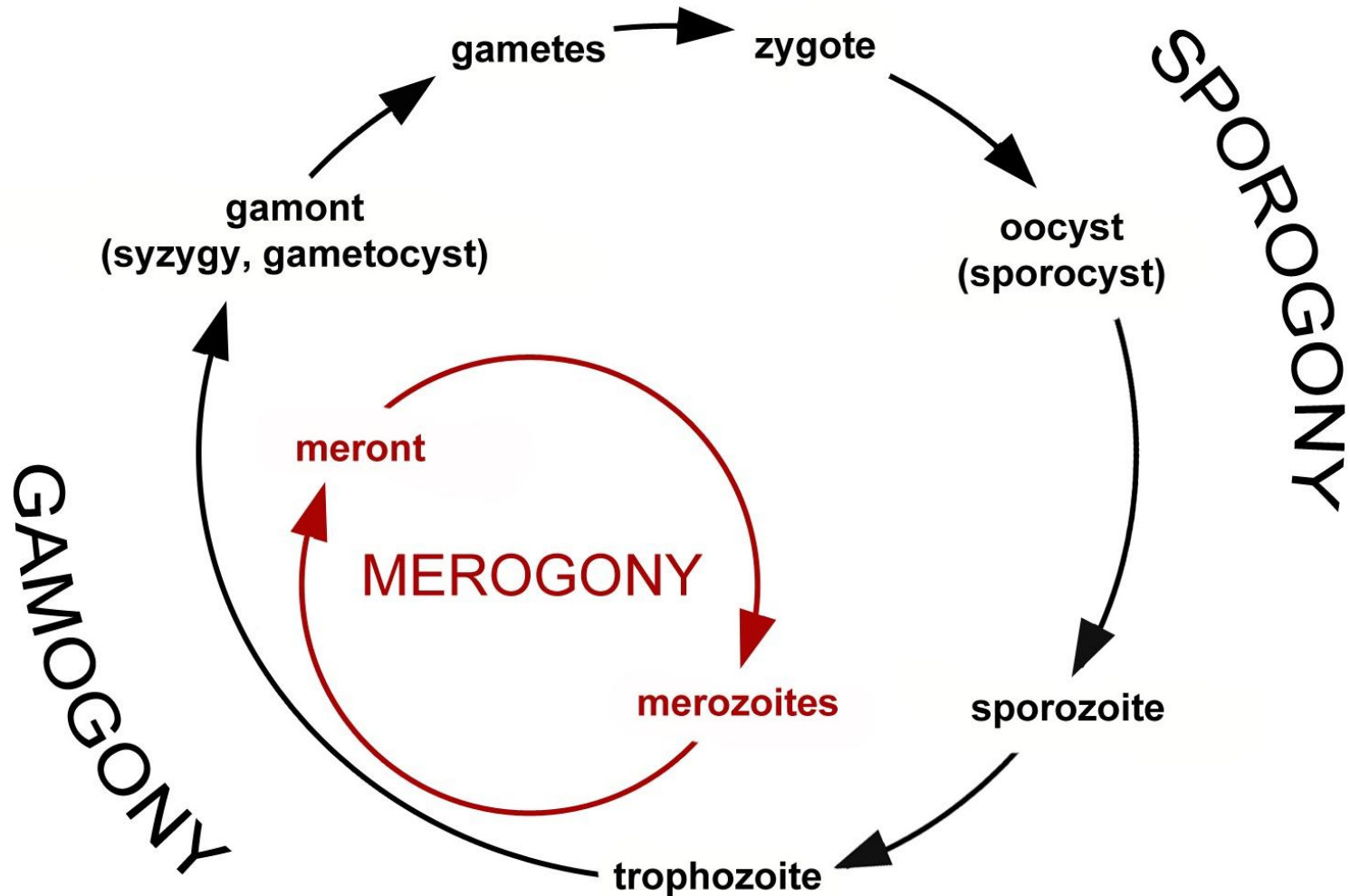


Apicomplexa

- monophyletic taxon
- 1.2 -10 million apicomplexan species, only about 0.1% have been named and described to date
- **all parasitic** = obligate parasites of vertebrates and invertebrates
- monoxenic or heteroxenous parasites
- at least 1 stage of the life cycle with flattened **cortical alveoles** and **apical complex**
- **apical complex** = 1 or more polar rings, conoid, rhoptries, micronemes, subpellicular microtubules
- cell movement / locomotion by gliding, body flexion, longitudinal folds, and/or cilia
- **complicated life cycle** usually comprising sexual (**gametogony**) and asexual (**merogony** also known as schizogony, **sporogony**) part

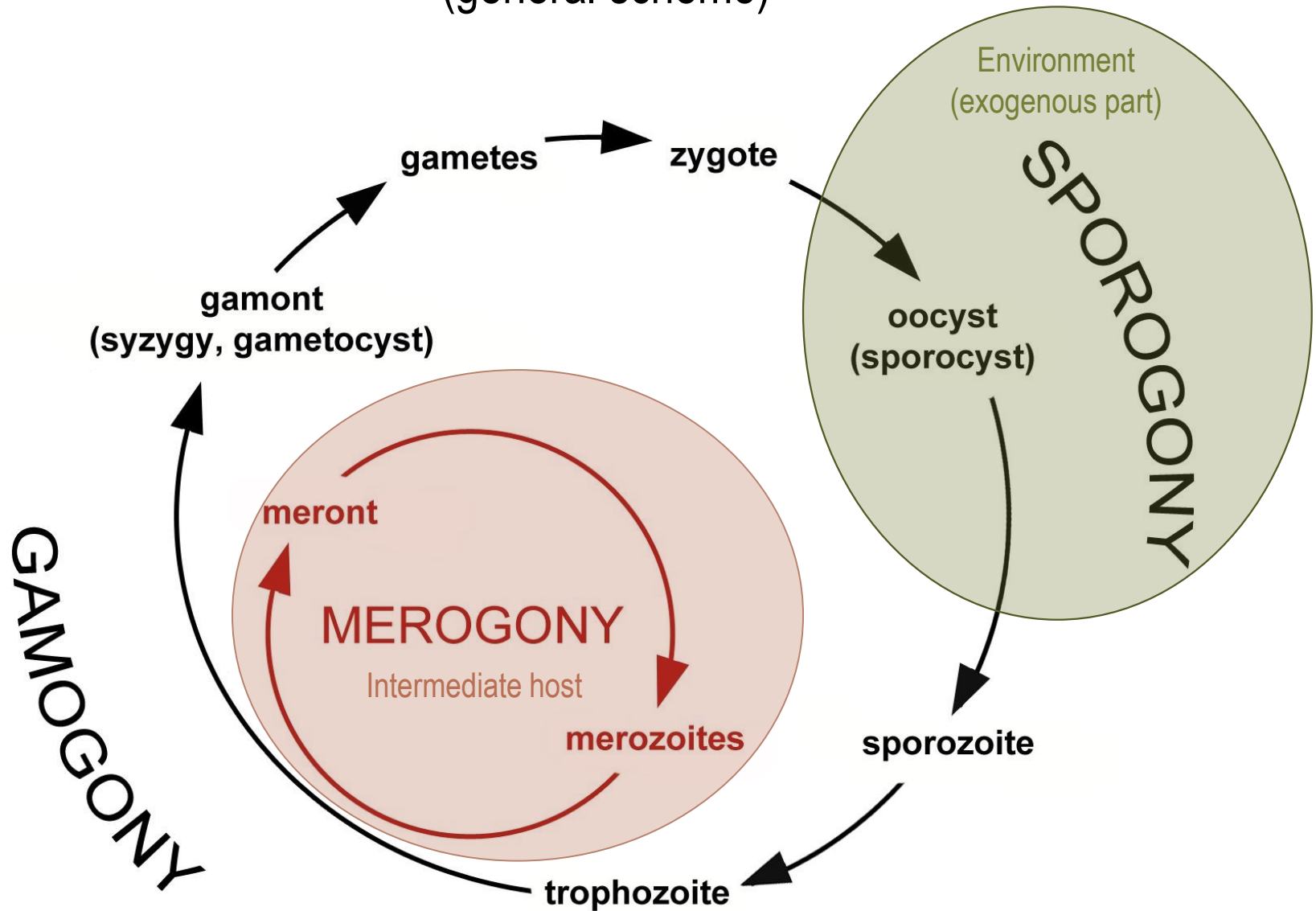
Apicomplexan life cycle

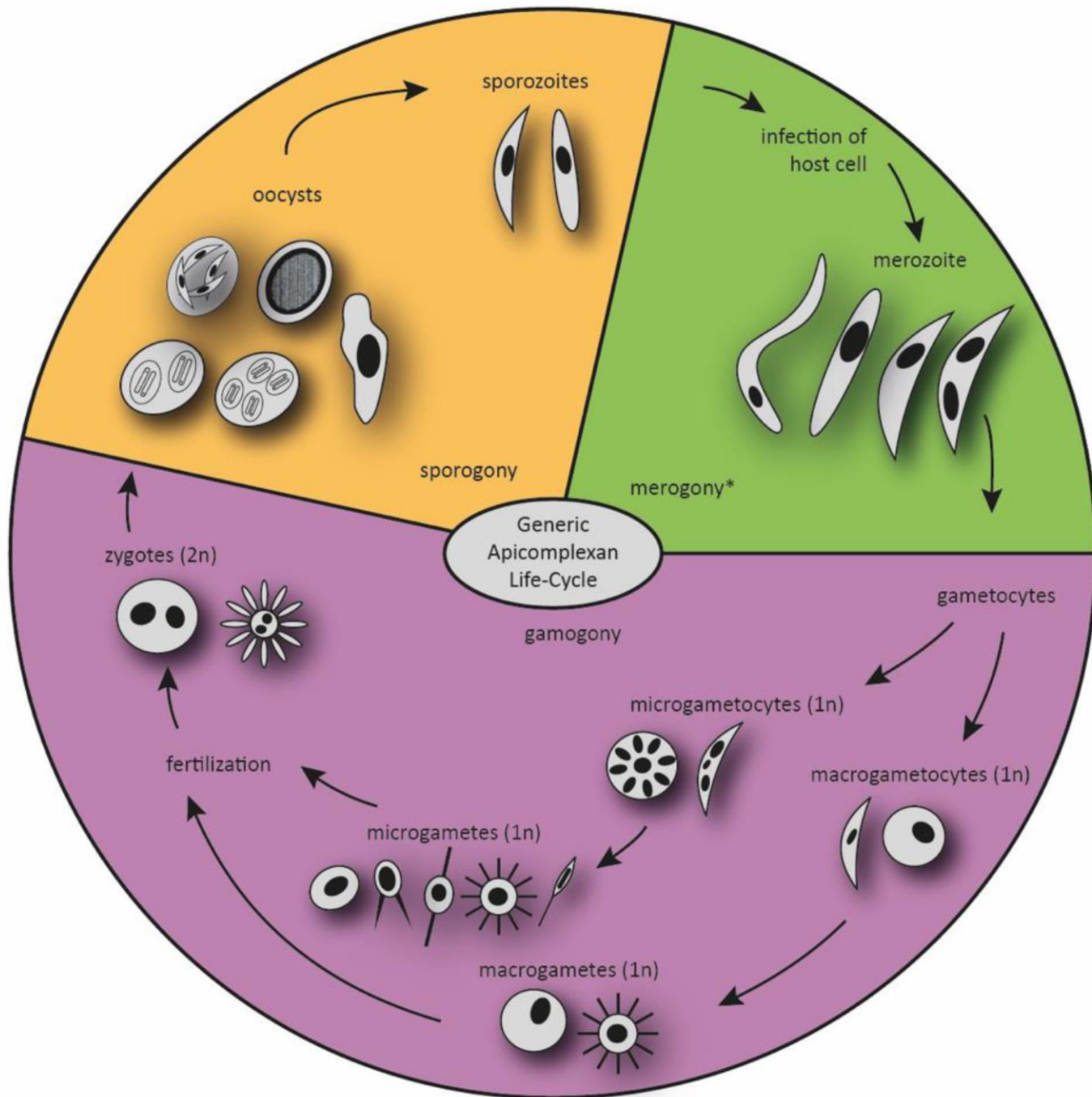
(general scheme)



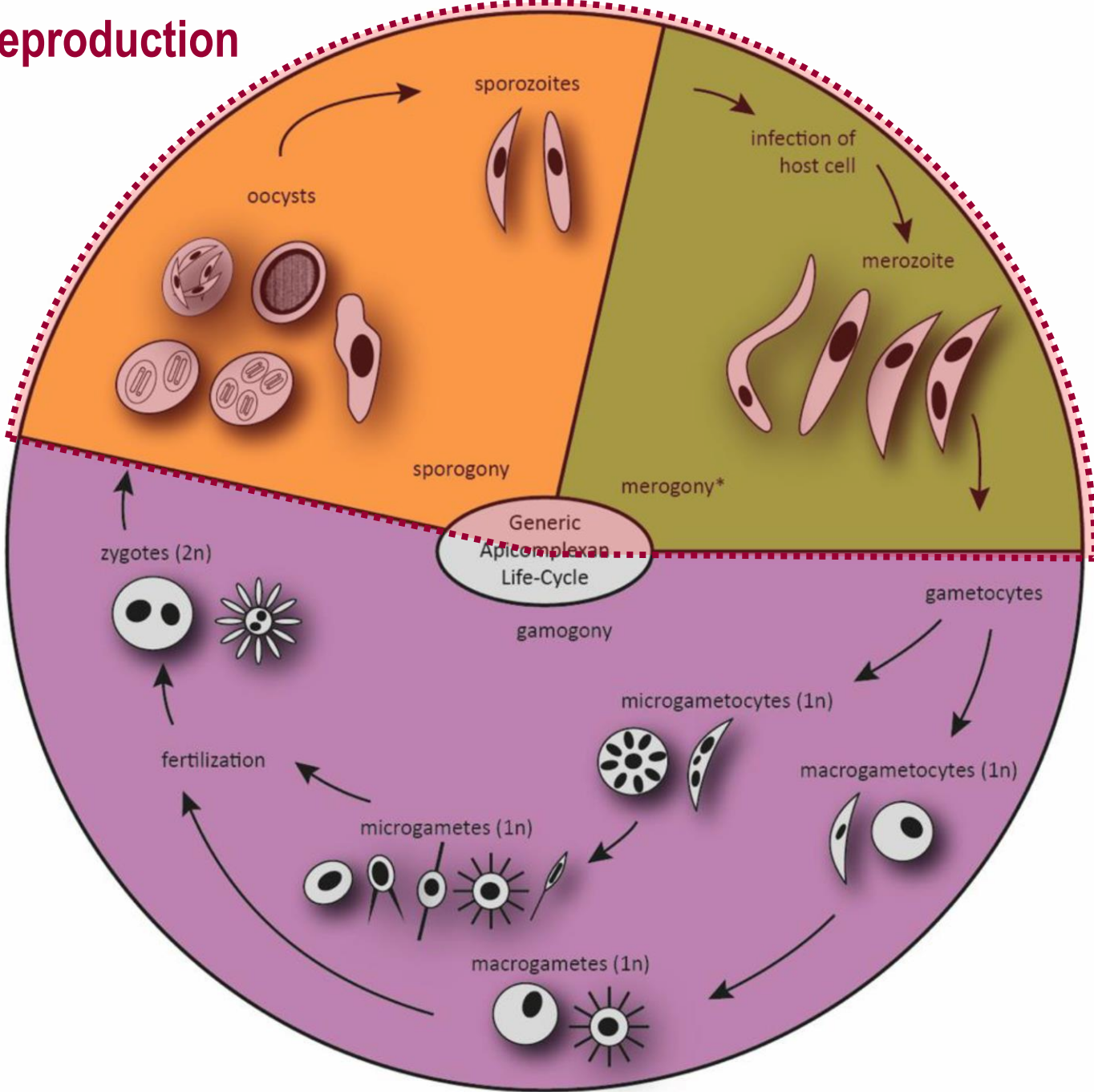
Apicomplexan life cycle

(general scheme)





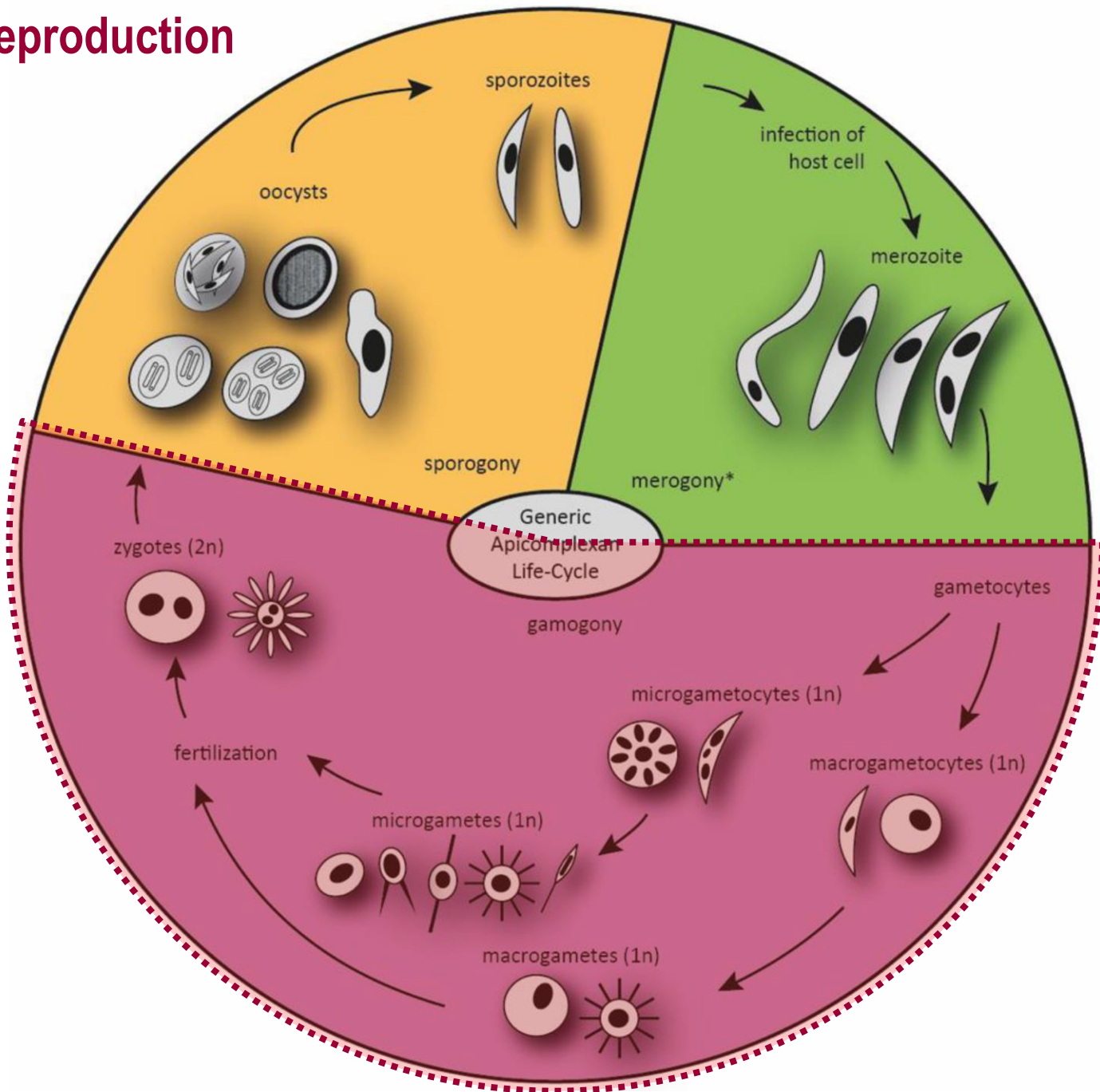
Asexual reproduction



Reproduction in Apicomplexa

- **Asexual reproduction** of haploid stages via **merogony**, **endodyogeny**, **endopolyogeny** and/or binary fission
 - ❑ **merogony (schizogony)** = multiple fission in which nuclei and other organelles in the meront (schizont) divide repeatedly and migrate to the cell periphery before internal membranes develop around them to produce a large number of daughter cells (merozoites) = budding takes place at the plasma membrane, nuclear division occurs before daughter assembly
 - ❑ **endopolyogeny** = internal budding resembling merogony, but budding takes place internally within the cytoplasm, daughter assembly precedes nuclear division
 - ❑ **endodyogeny** = only 2 daughter cells (**endozoites**) are assembled within the mother <https://doi.org/10.3389/fcimb.2020.00269>
 - ❑ **sporogony** = asexual division, development of zygote (motile zygote = ookinete) producing **sporozoites** within **oocysts** (usually inside sporocysts); reductive division of the zygote forms haploid nuclei which (along with other organelles) undergo multiple divisions to form a sporoblast; sporozoites arise by cytoplasmic division of the sporoblast (sporulation)

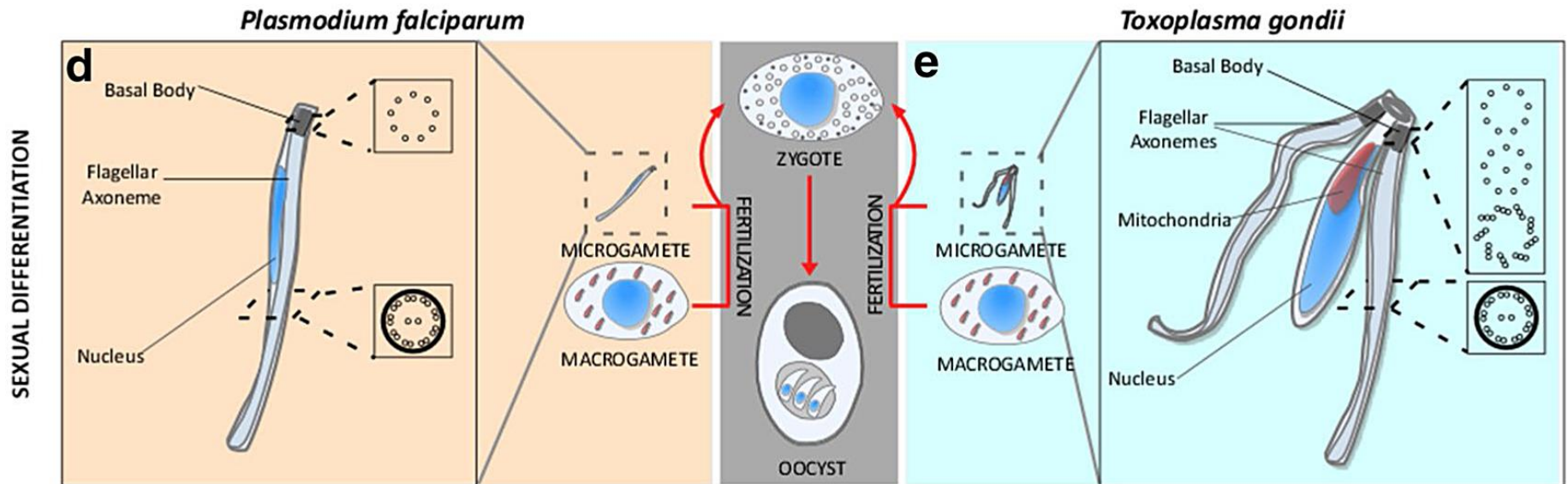
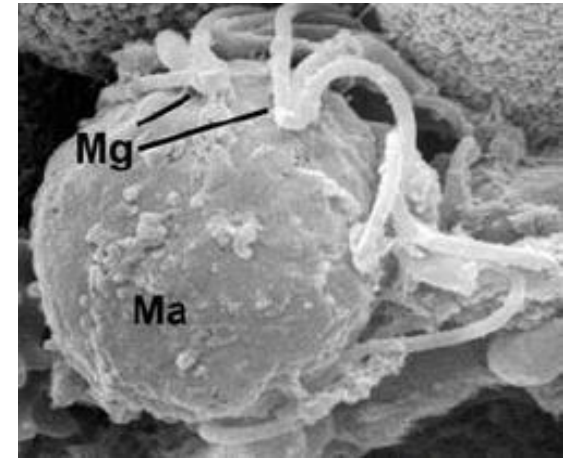
Sexual reproduction



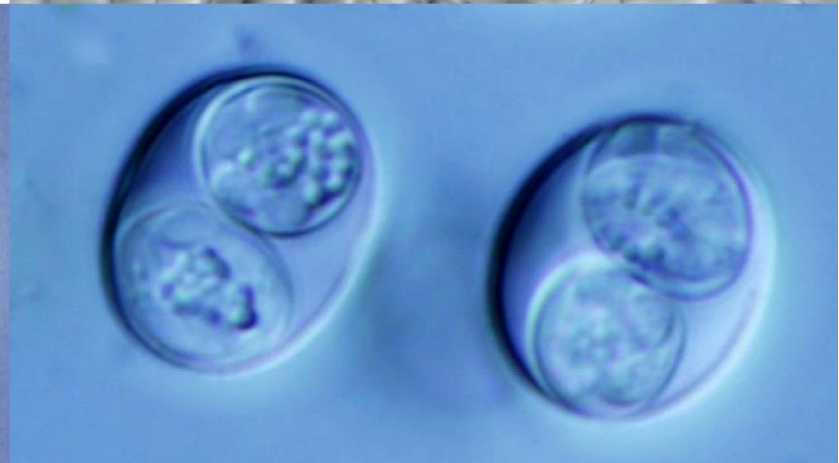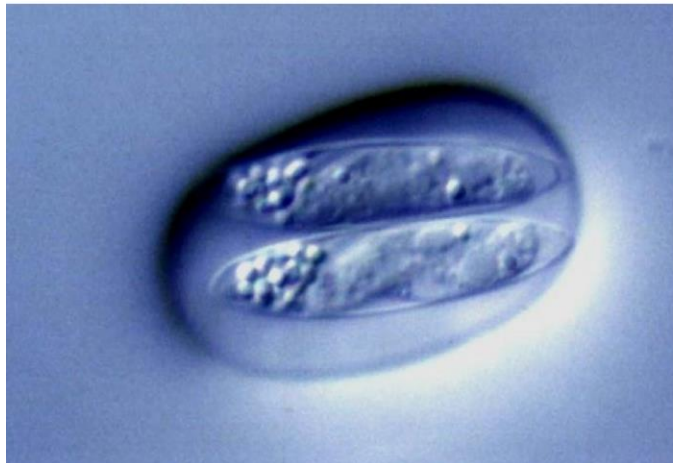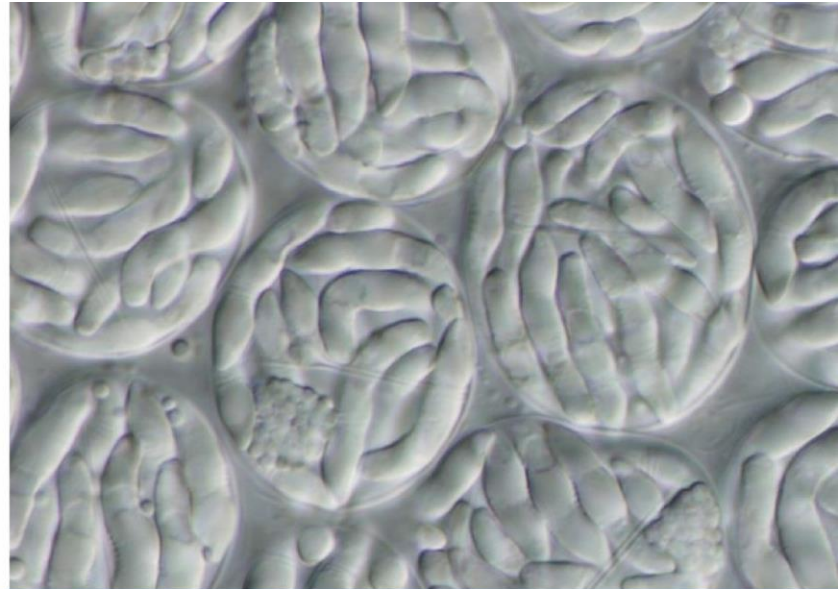
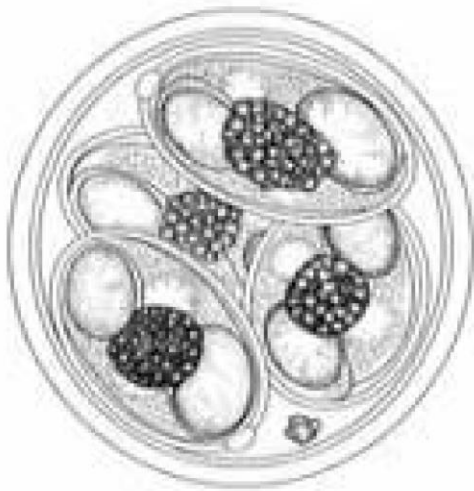
Reproduction in Apicomplexa

- **sexual reproduction** (where known) by syngamy followed by immediate meiosis to produce haploid progeny
 - **gametogony (gamogony)** = transformation into a **gamonts** that produce male and female **gametes**
 - **syzygy** and **gametocyst** formation (gregarines)
 - **isogamy** (similar gametes) x **anisogamy** (dissimilar gametes, flagellated microgametes in some taxa)
 - **syngamy** (fusion of gametes)

Fertilisation in *T. gondii*



Oocyst = resistant stage of apicomplexans

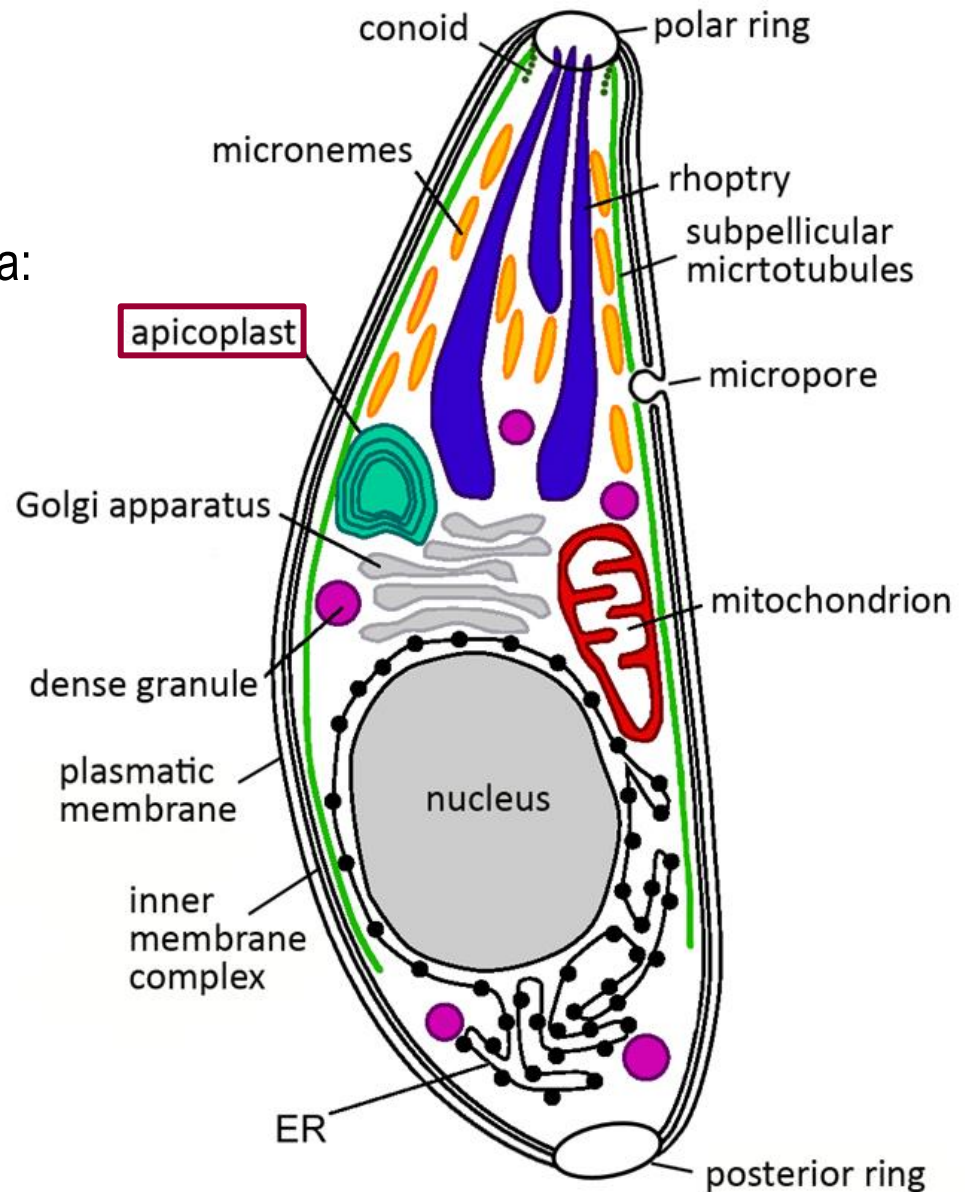


Zoite organisation

- standard equipment of the eukaryotic cell
- organelles characteristic of Apicomplexa: **apical complex** and **apicoplast**

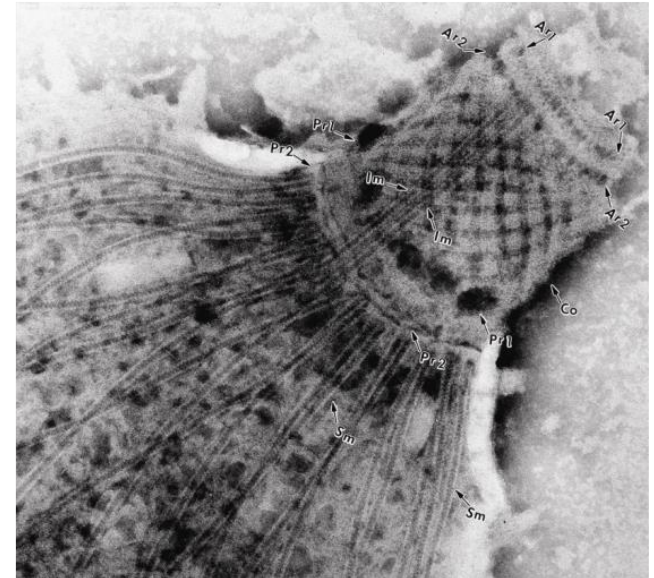Apicoplast

- ✓ relict, **non-photosynthetic plastid**
- ✓ secondary endosymbiotic chloroplast limited by 4 membranes
- ✓ 35 kb long circular DNA strand that codes for approximately 30 proteins
- ✓ heme and amino acid syntheses and likely involved in lipid metabolism
- ✓ sensitive to herbicides
- ✓ promising drug target

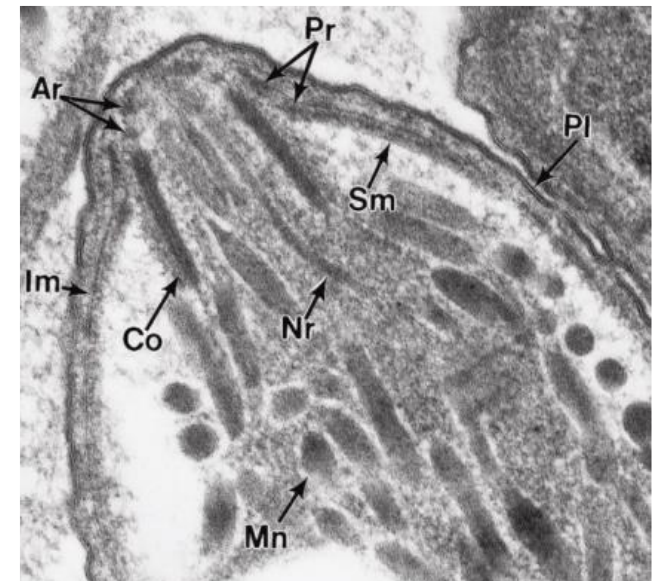


Apical complex

- **conoid** = hollow cone of spirally arranged fibers located within the polar rings
- **polar ring(s)** = 1-2 electron dense structures located just behind the zoite's apical tip and directly under the plasma membrane
- **micronemes** = convoluted, elongate bodies in zoite's anterior end whose contents are released during host cell invasion, likely involved in affecting plasma membrane fluidity
- **rhoptries** - elongated, club-shaped organelles in apical region of zoite whose contents are released during host cell invasion, likely involved in forming the membranous scaffolding supporting the zoite within the **parasitophorous vacuole (PV)**



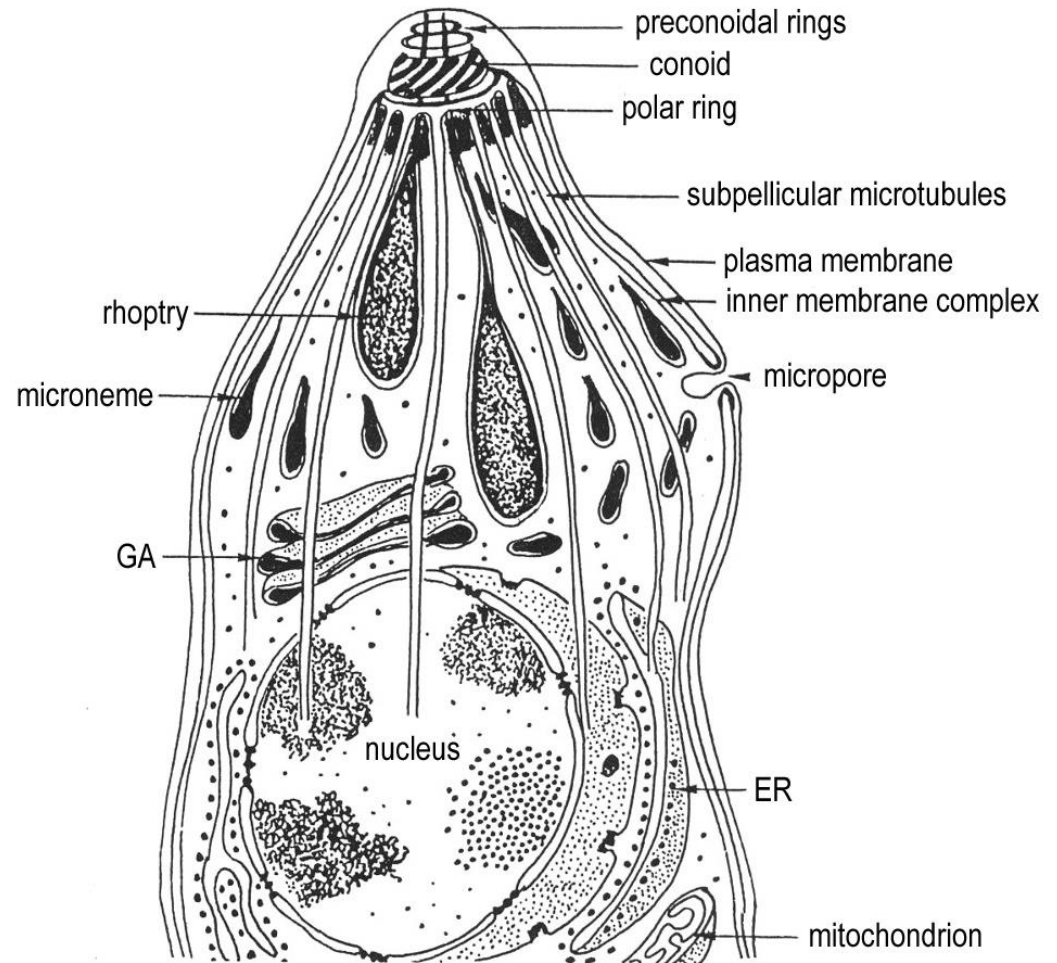
Tachyzoite of *Toxoplasma gondii*



Bradyzoite of *T. gondii*

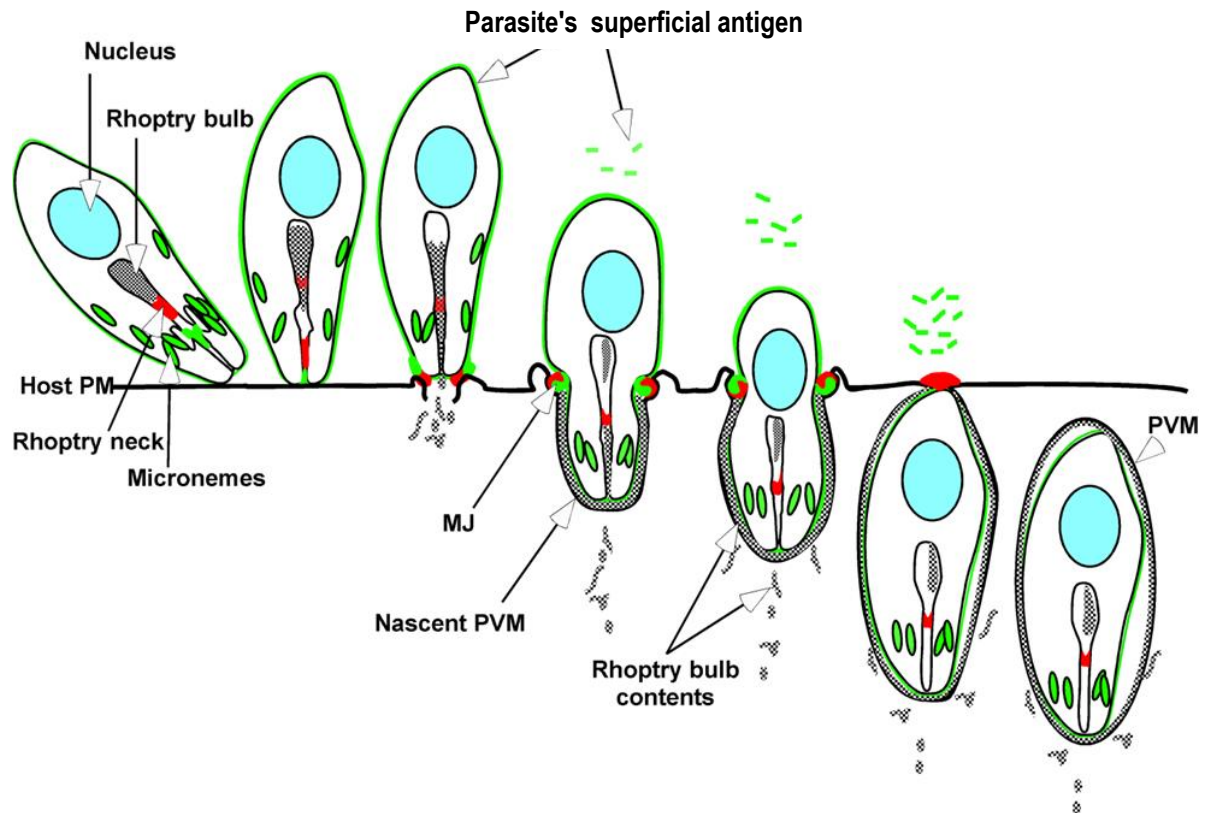
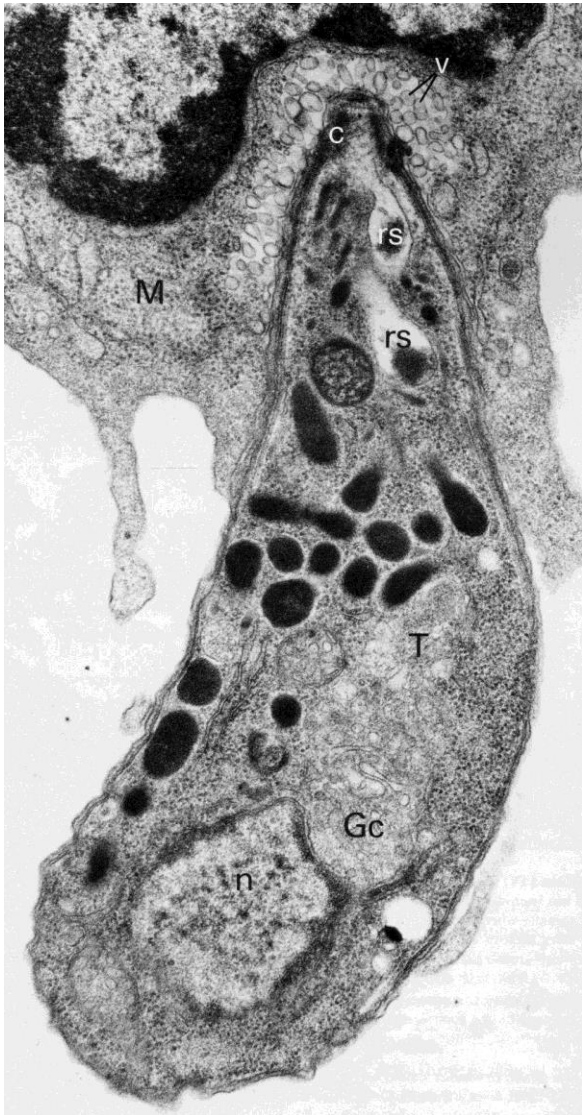
Apical complex

- **micropores** = usually present at some stage which are morphologically similar to clathrin-coated pits and are involved in endocytosis
- **subpellicular microtubules** = microtubules under the pellicle running posteriorly (parallel to the cell axis)



Host cell invasion

- zoite attachment, orientation and adhesion by its apical end ⇒ **moving junction**
- host cell penetration and formation of parasitophorous vacuole
- shedding of the zoite antigenic surface completion of PV and modification of the parasite's niche



Invasion process in *Toxoplasma gondii*

Host-parasite interactions in Apicomplexa

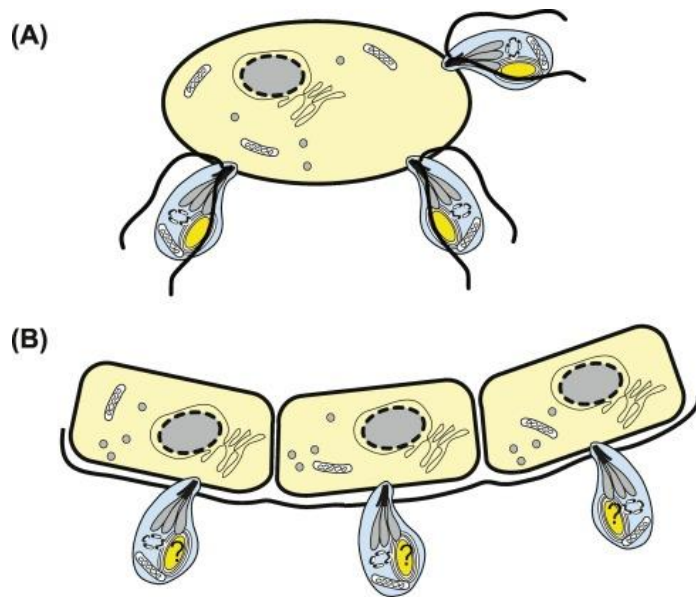
Parasite niche in host cell or tissue

- ✓ intercellular
- ✓ extracellular
- ✓ epicellular
- ✓ intracellular epiplasmatic
- ✓ intracellular

Hypothesis on evolution of parasitism in Apicomplexa:

Myzocytotic predation ⇒ **myzocytotic extracellular parasitism** + origin of **epicellular parasitism** (modification of attachment apparatus and motility in trophozoite) ⇒ **intracellular parasitism** (lost of cell polarity and motility in trophozoite)

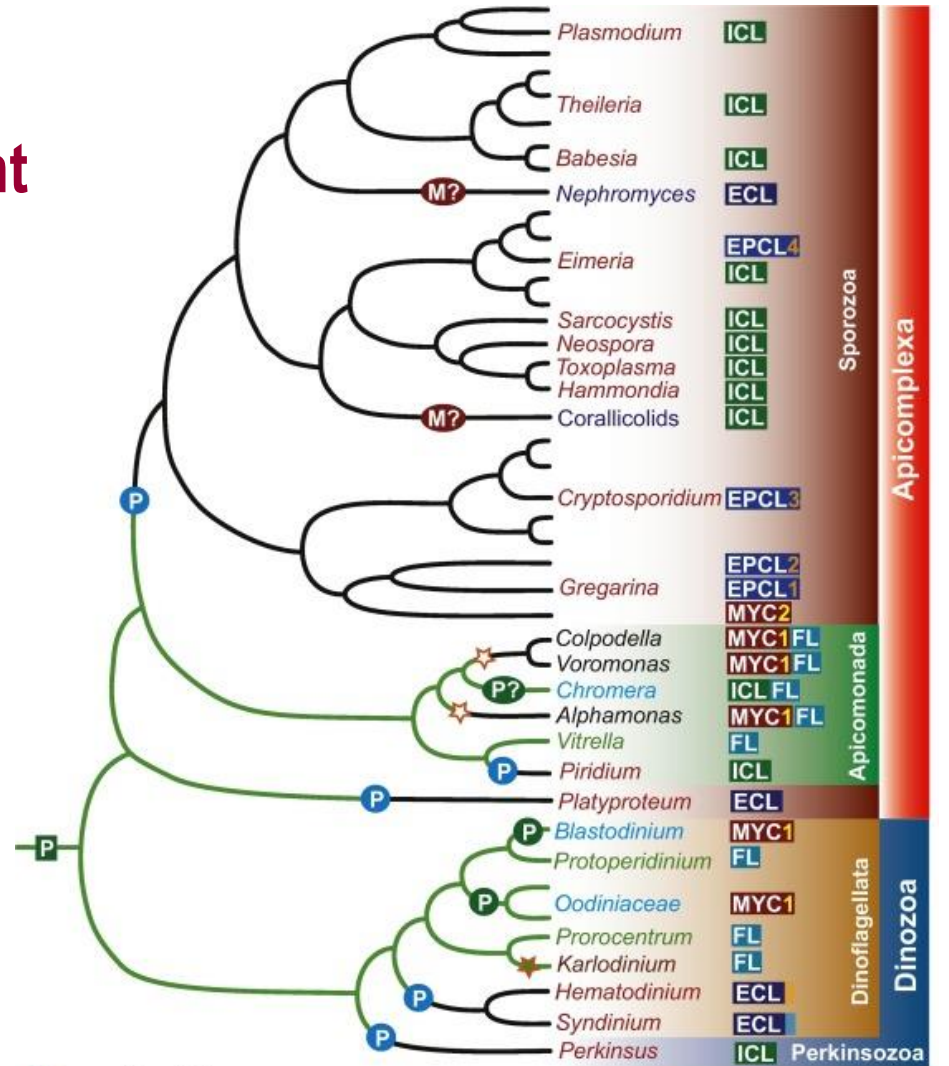
Phylogenetic distribution of diverse organism-environment interactions in Myzoza



Trends in Parasitology

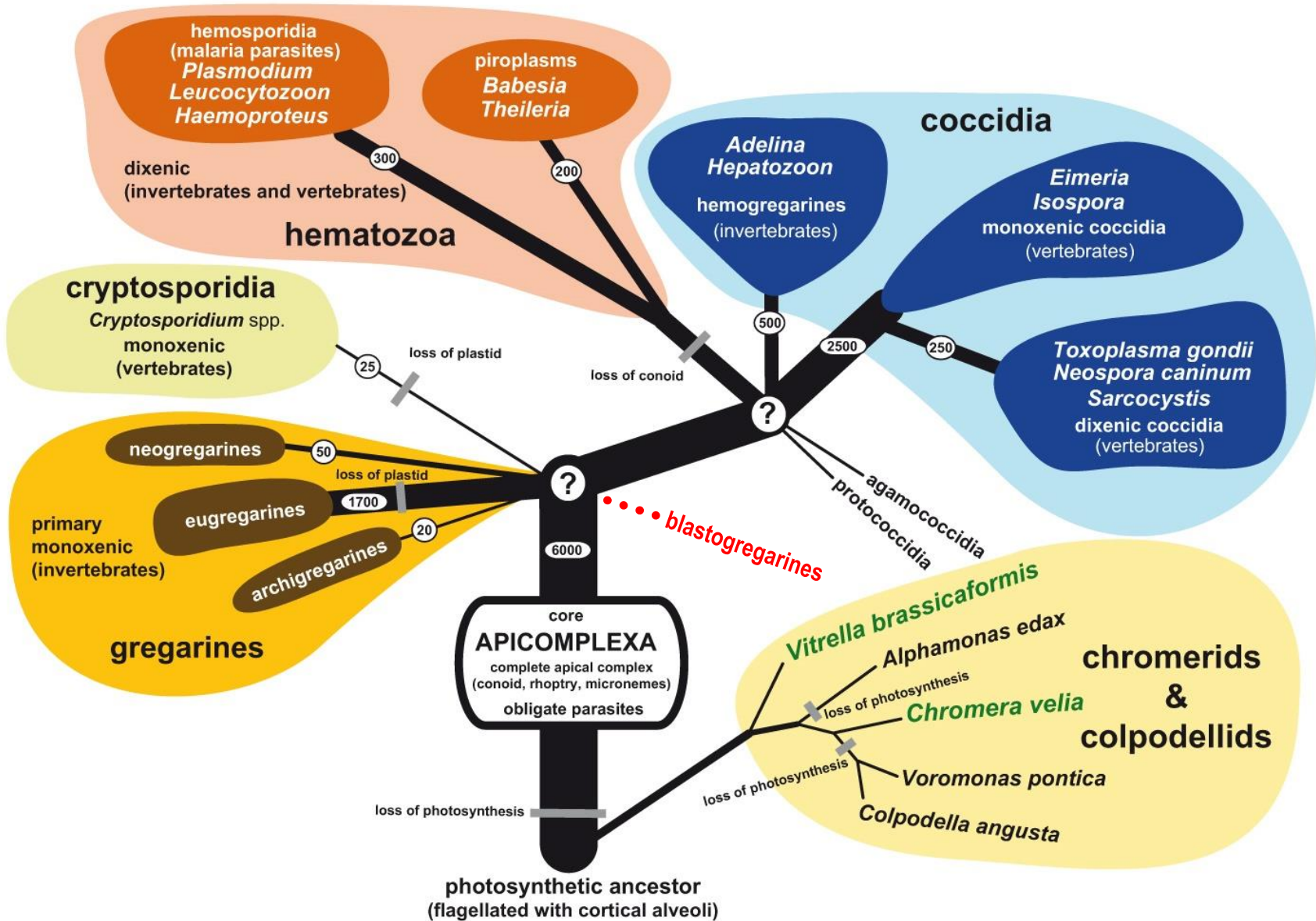
Co-occurrence of predation and parasitism. Colpodellids (A) are predators of algae and protists. They penetrate the cell surface to access the cytosol of the predated cell. The mode of action is, in principle, quite similar to that of early-branching apicomplexan parasites such as gregarines (B) living in the gut of various animals.

<https://doi.org/10.1016/j.pt.2020.06.002>

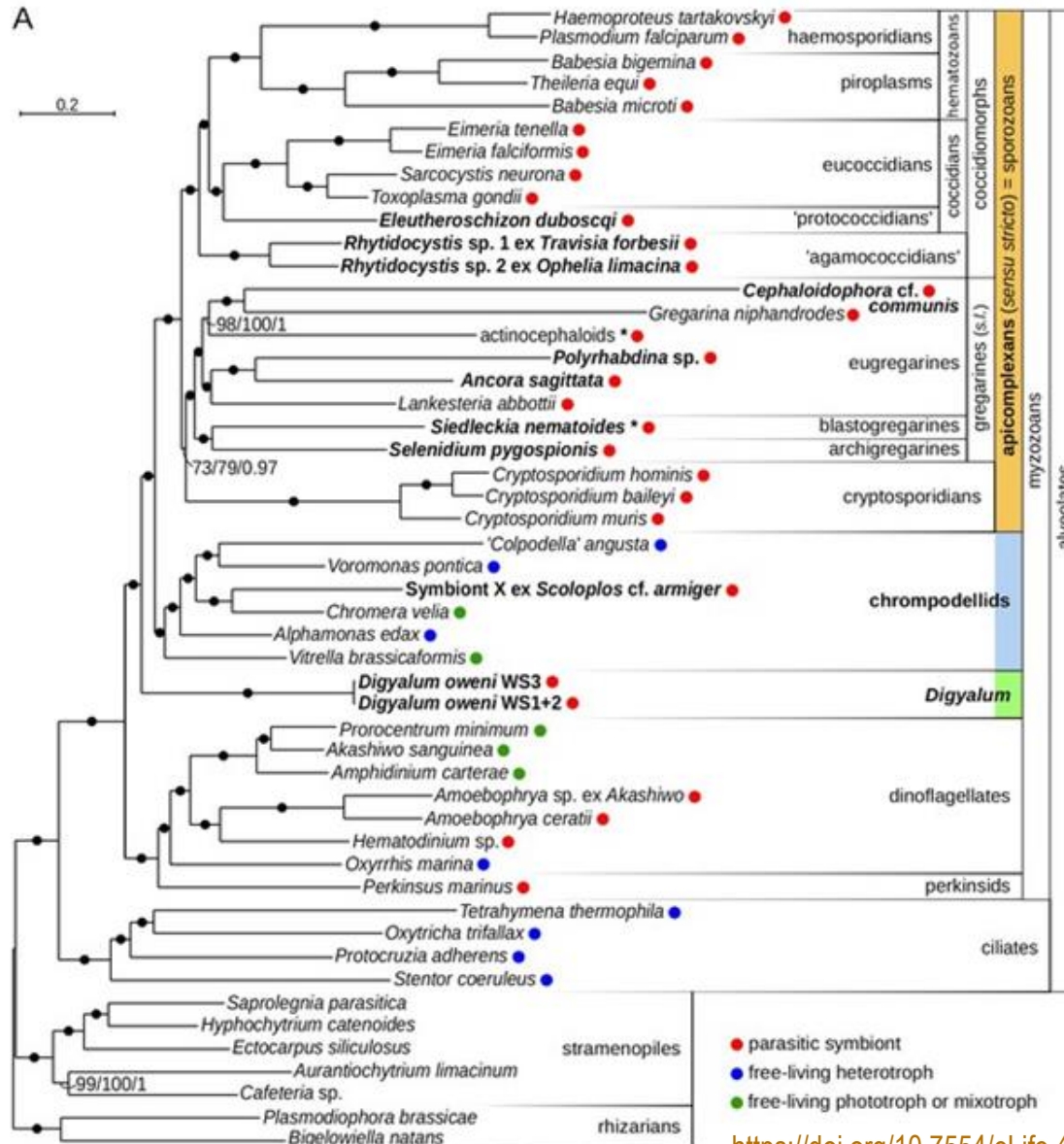


- FL** Free-living
- MYC¹** Myzocytosis, predation
- MYC²** Myzocytosis, parasitism
- EPCL¹** Epicellular, transmembrane
- EPCL²** Epicellular in matrix
- EPCL³** Epicellular in parasitophorous sac
- EPCL⁴** Epicellular in parasitophorous vacuole
- ICL** Intracellular
- ECL** Extracellular
- ECL** Extracellular in hemolymph and intercellular space
- ECL** Extracellular in various body cavities or intracellular; based on the species and host
- P** Phototrophy
- P** Parasitism
- P** Photoparasitism
- ☆** Predation
- ★** Photopredation
- M** Mutualism

Apicomplexa



Multiprotein phylogeny of Apicomplexa and related taxa



- apicomplexans are polyphyletic
- similar morphological features appeared convergently at least 3x
- gregarines and eugregarines are monophyletic
- *Eleutheroschizon* is related to Eucoccidia and *Rhytidocystis* has emerged as the basal group of Coccidiomorpha (the most medically important representatives)
- plastids are common in basal Apicomplexa; in eugregarines they are abnormally reduced or absent

Apicomplexa

Aconoidasida•••next lecture

- apical complex lacking conoid in asexual motile stages; some diploid motile zygotes (ookinetes), with conoid; macrogametes and microgametes forming independently; heteroxenous
 - **Haemospororida**••••
 - **Piroplasmorida**••••

Conoidasida•••this lecture

- **Gregarinasina**••••
- **Cryptosporidium**••••
- **Coccidia**••••
 - **Adeleorina**•••••
 - **Eimeriorina**•••••

Apicomplexa

Conoidasida•••

- complete apical complex, including a conoid in all or most asexual motile stages

Gregarinasina••••

- mature gamonts usually develop extracellularly; syzygy of gamonts generally occurring with production of gametocyst; similar numbers of macrogametes and microgametes maturing from paired gamonts in syzygy within the gametocyst
- syngamy of mature gametes leading to gametocyst that contains few to many oocysts

Cryptosporidium••••

- endogenous stages with attachment “feeder” organelle; microgametes non ciliated; oocysts without sporocysts, with 4 naked sporozoites
- extracytoplasmic localisation in host cell (based on Adl et al. 2012) vs. epicellular (Valigurová et al. 2008, 2015)

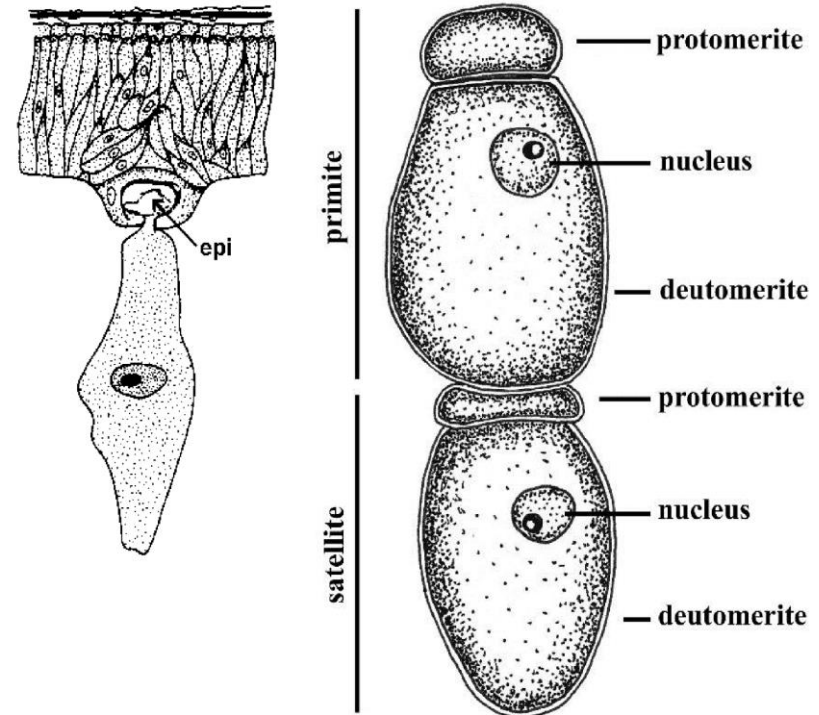
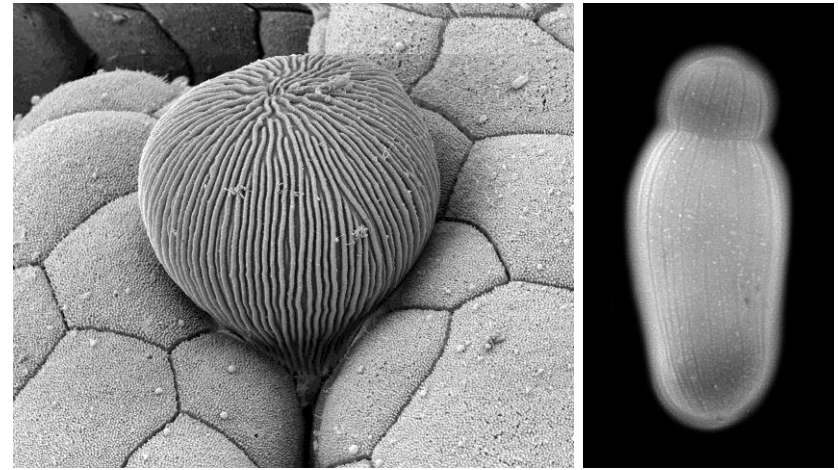
Coccidia••••

- mature gametes develop intracellularly; microgamont typically produces numerous microgametes
- syzygy absent; zygote rarely motile; sporocysts usually form within oocysts

Apicomplexa


Gregarinasina

- gregarines are highly diverse - intestine and body cavities of invertebrates (arthropods, annelids, molluscs, ...) and hemichordates
- considered the most ancestral Apicomplexa
- trophozoites **mucron** or **epimerite**
- large and motile trophozoites and gamonts (usually extracellular)
- **syzygy** - pairing of 2 gamonts before gametocyst formation
- syngamy of gametes within the **gametocyst**
⇒ zygotes ⇒ gametocyst containing few to many oocysts with sporozoites
 - Archigregarinorida
 - Eugregarinorida
 - Neogregarinorida

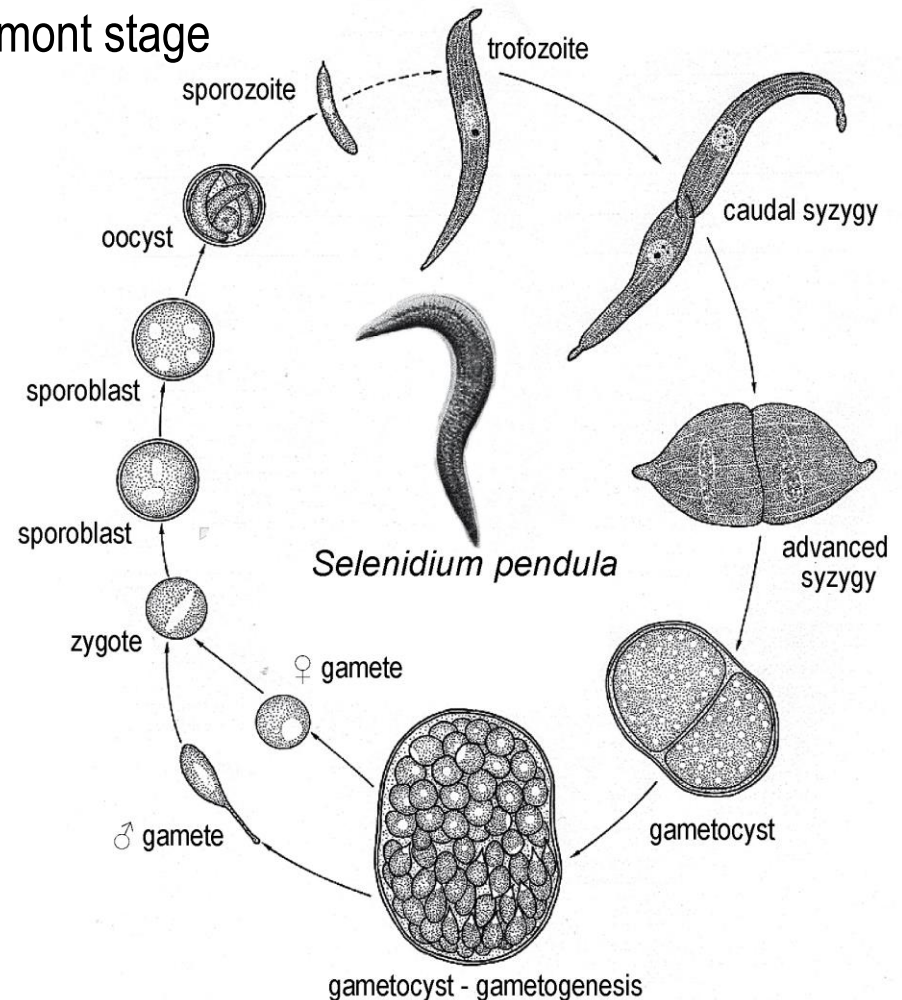


Archigregarinorida

- marine invertebrates (annelids, ascidians, hemichordates, sipunculids)
- ancestral to the other gregarines and probably all Apicomplexa
- epicellular development at brush border of enterocytes
- apical complex preserved at trophozoite/gamont stage
- aseptate trophozoite, **merogony**
- bending, rolling motility

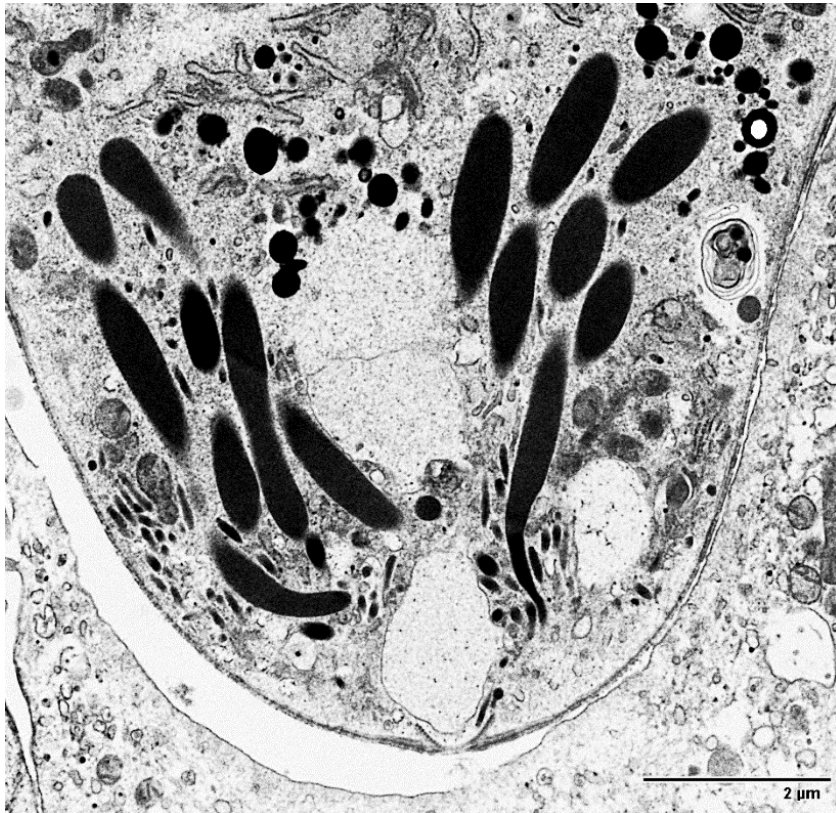


Selenidium pendula from polychaete

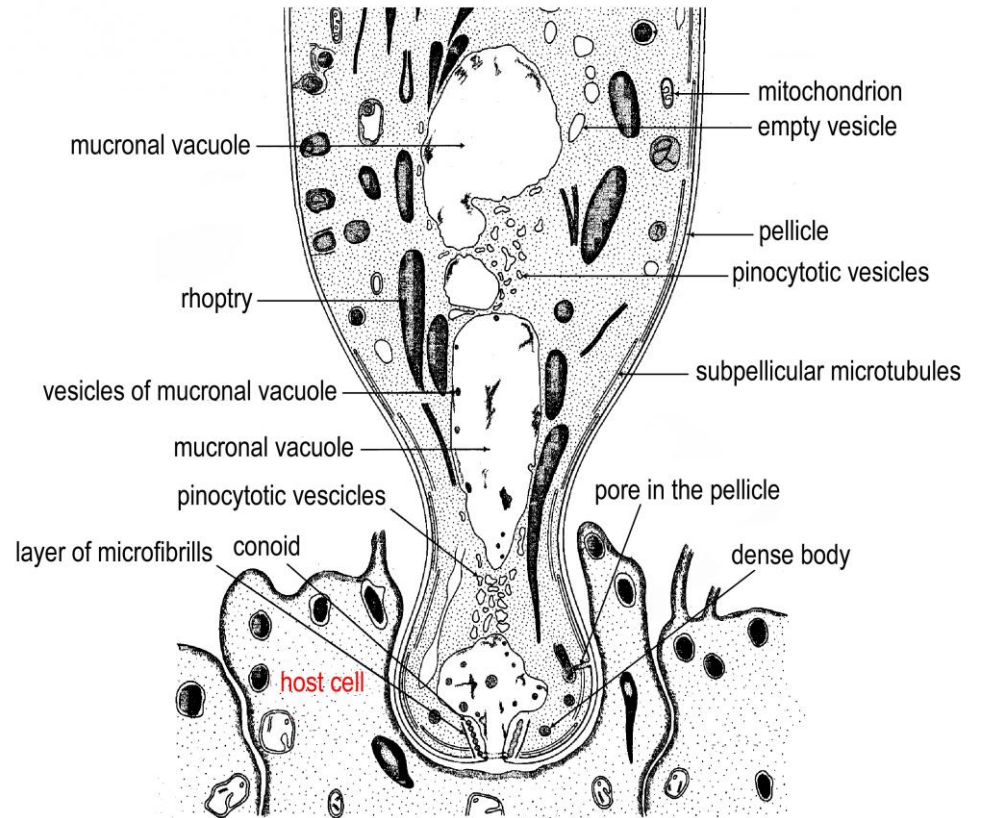


Host-parasite interactions in archigregarines

- **myzocytosis** via mucron - conoid, rhoptries + subpellicular microtubules = plesiomorphic features present in trophozoite/gamonts stage („hypersporozoite“)

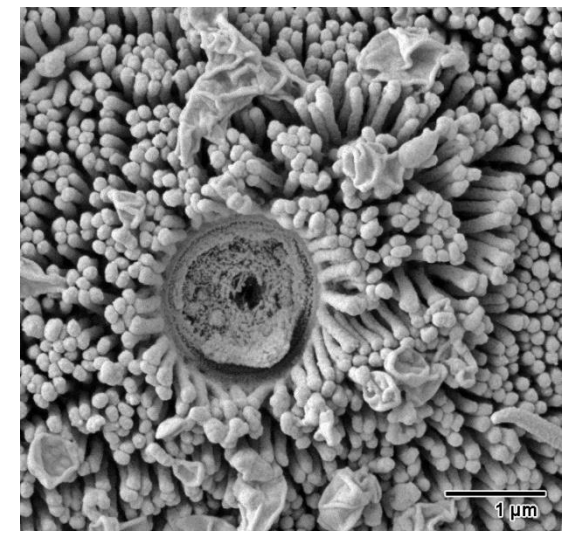
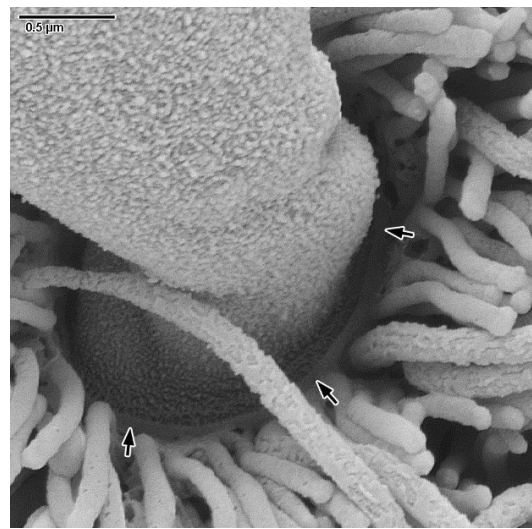
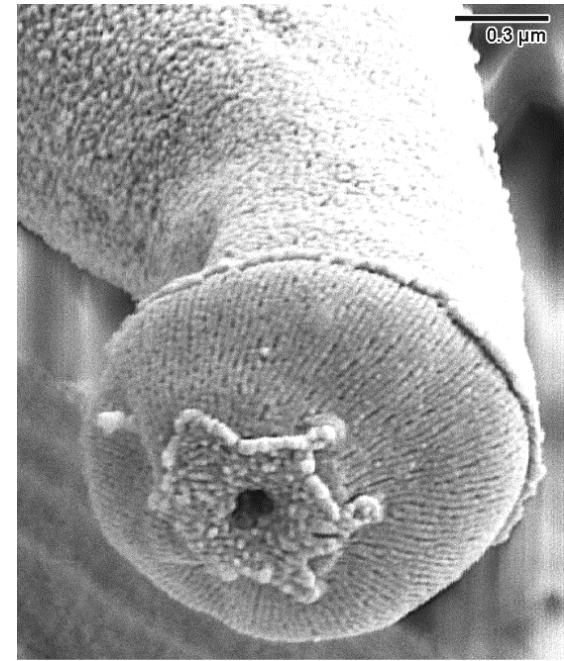

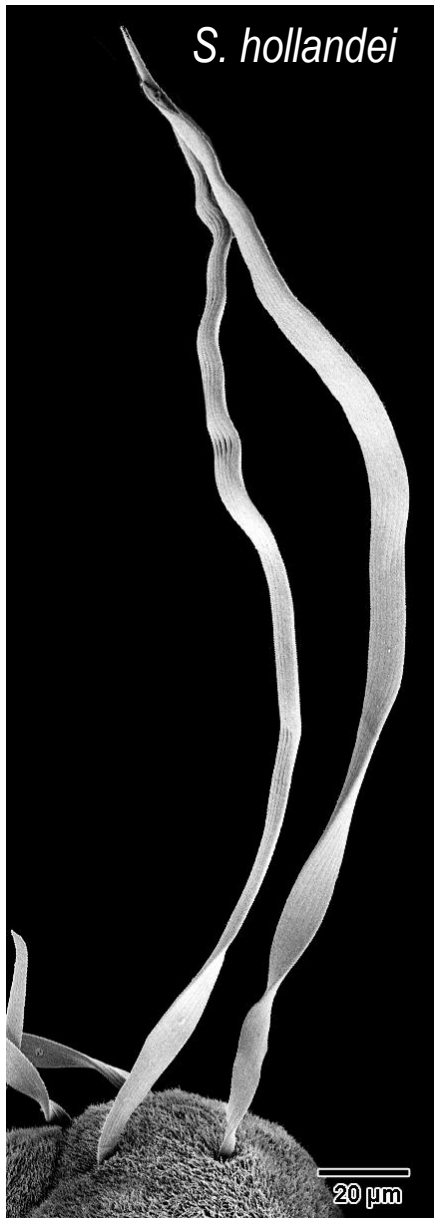


Apical pole of *Selenidium pendula*



Schematic view of anterior region of *Selenidium* trophozoite

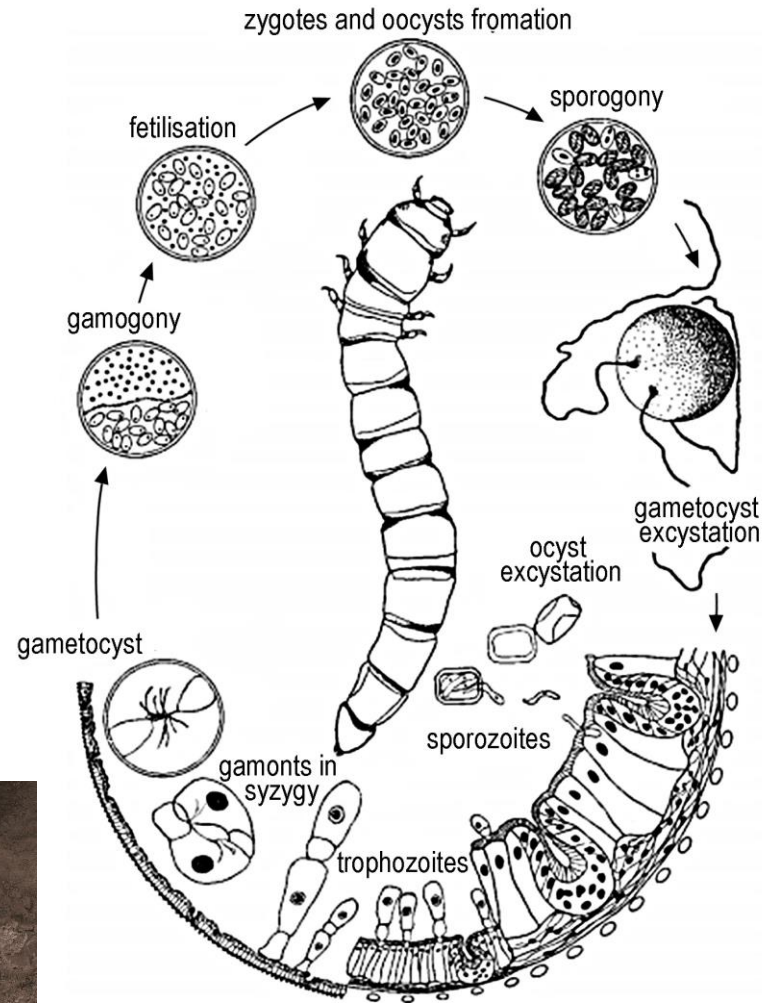
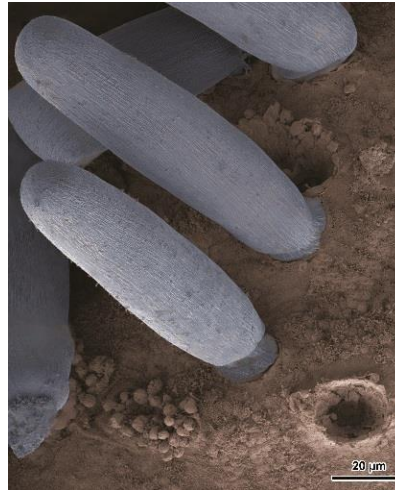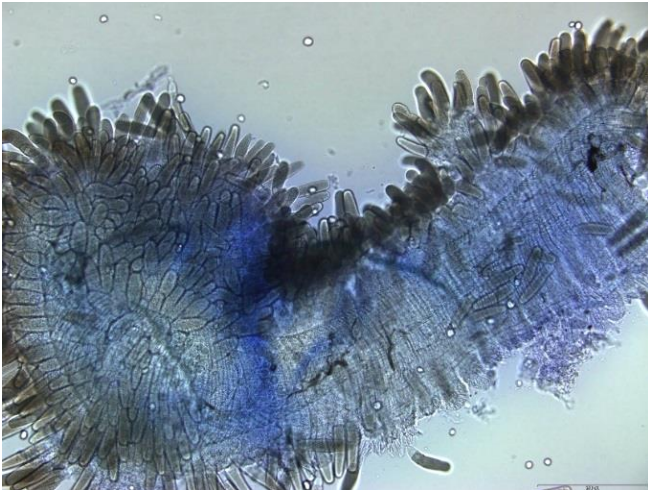
Host-parasite interactions in archigregarines



Eugregarinorida

- arthropods (mostly insects), polychaetes
- epicellular at brush border of enterocytes
- aseptate or septate trophozoites (epimerite, protomerite, deutomerite)
- apical complex present only in sporozoites
- merogony absent
- gliding motility, metaboly

Gregarina polymorpha

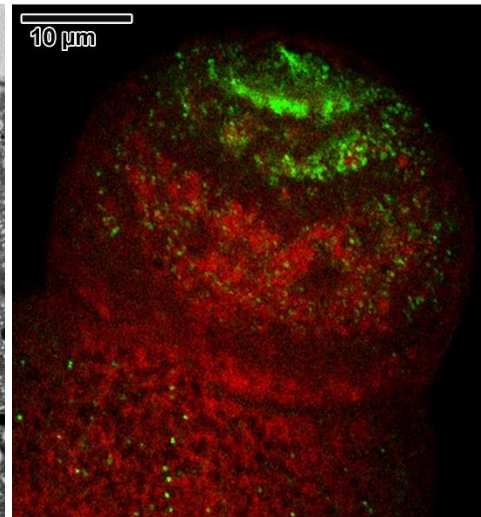
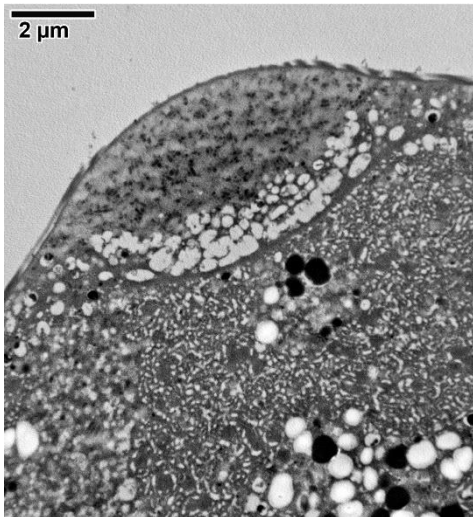
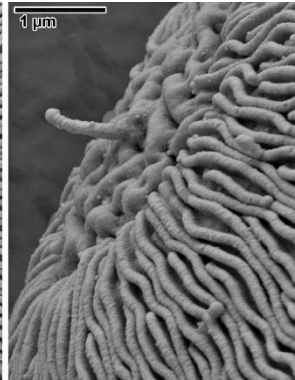
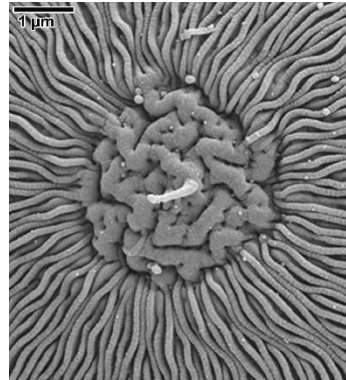
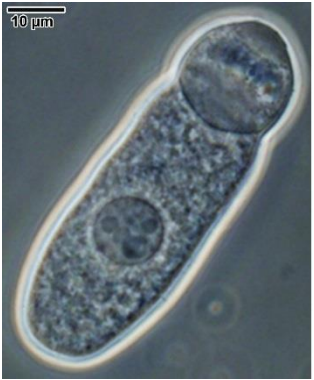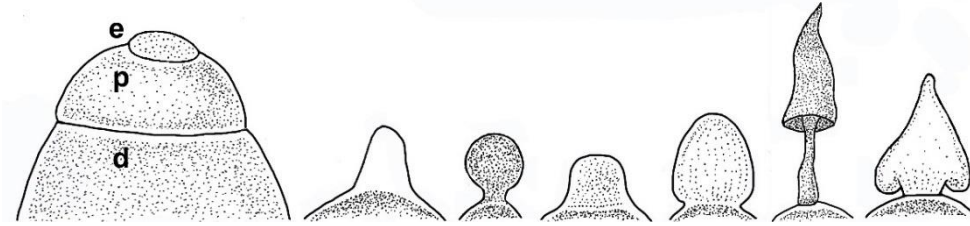


Life cycle of *G. cuneata*
in mealworm larvae

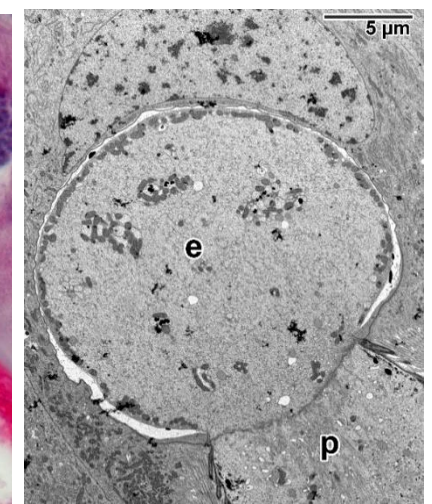
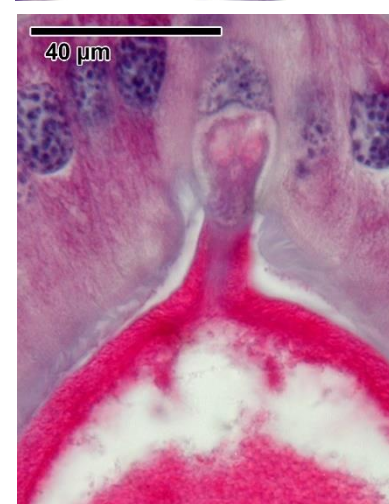
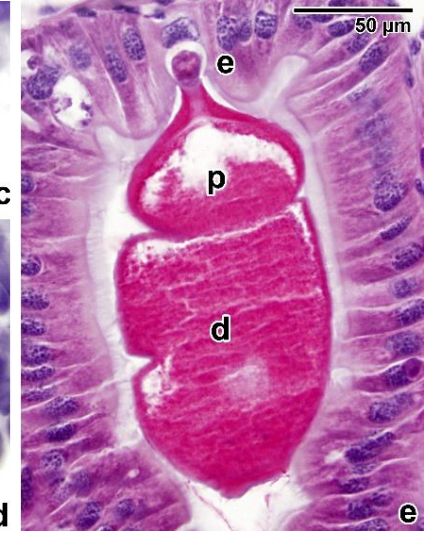
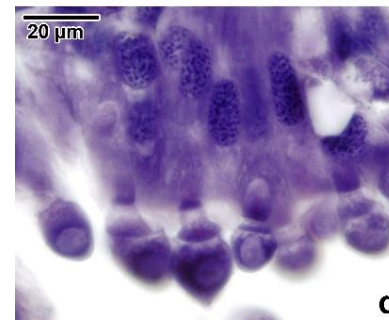
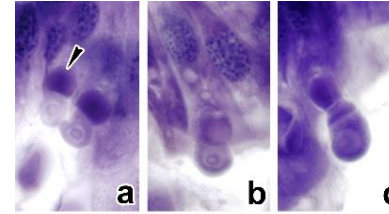
<https://doi.org/10.1371/journal.pone.0042606>

<https://doi.org/10.1016/j.ijpara.2009.04.009>

Host-parasite interactions in eugregarines: simple epimerite




Cephaloidophora communis from crustacean

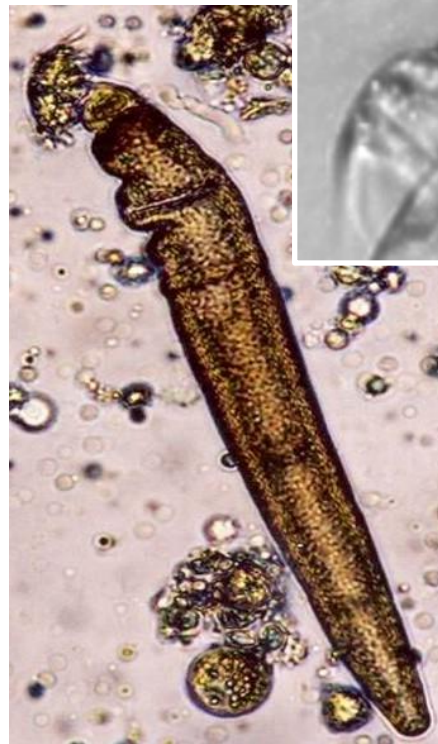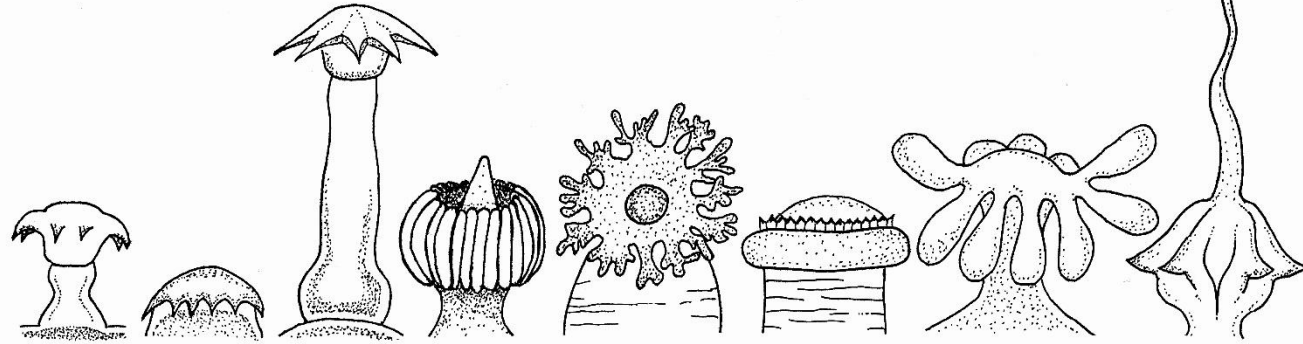

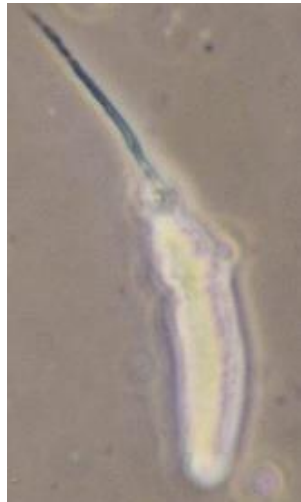
Gregarina garnhami from locust

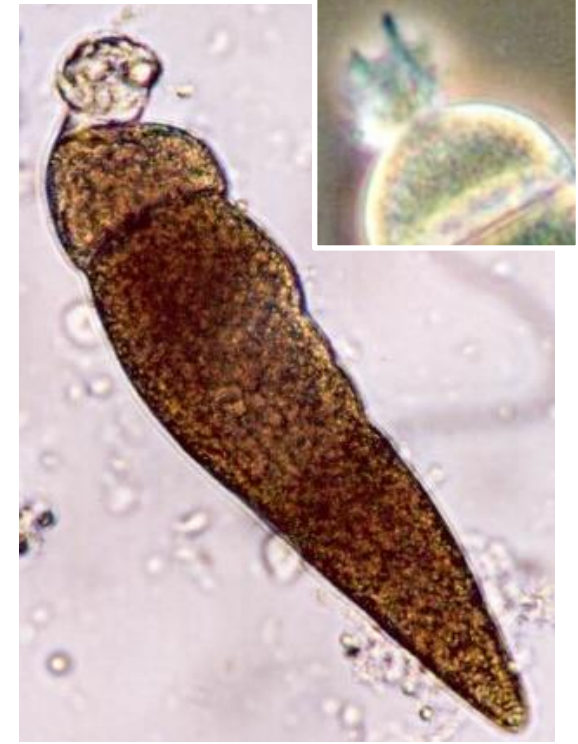Host-parasite interactions in eugregarines: complicated epimerite



Beloides tenius from skin beetle

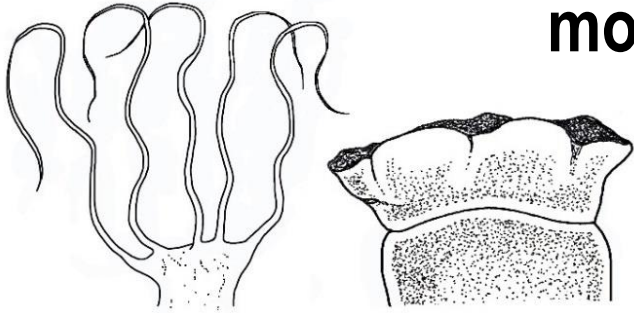


Actinocephalus dujardini
from centipede

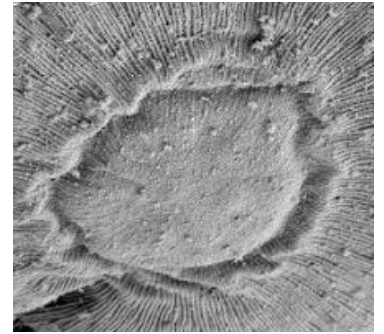
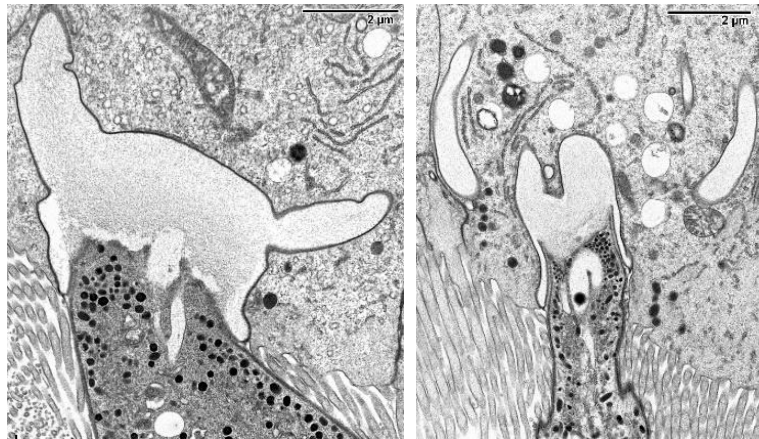
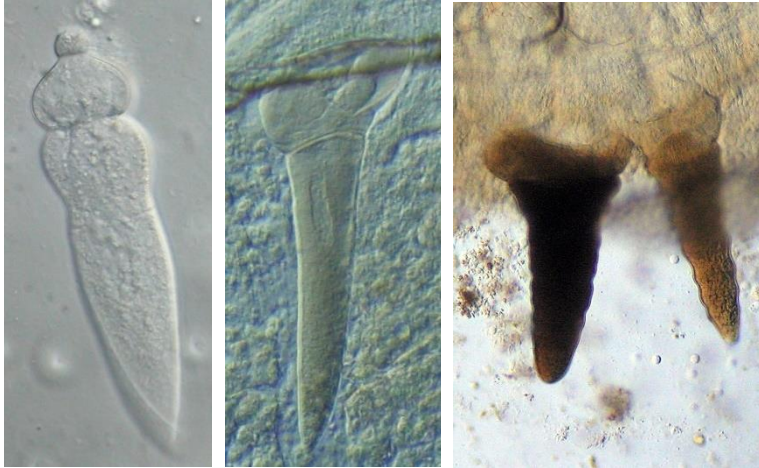

Ancyrophora stelliformis
from ground beetle

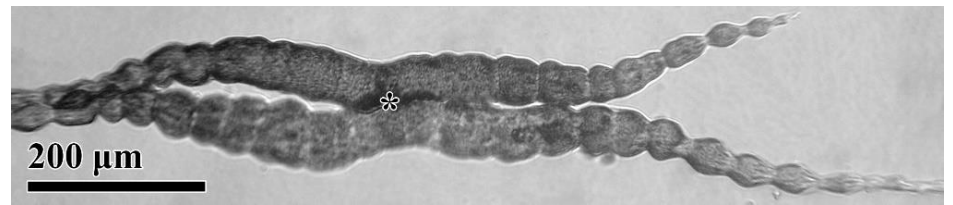
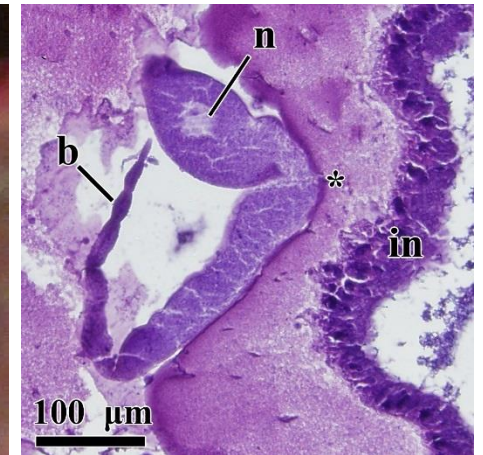
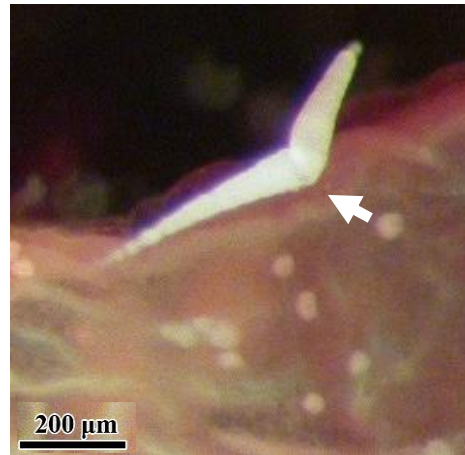
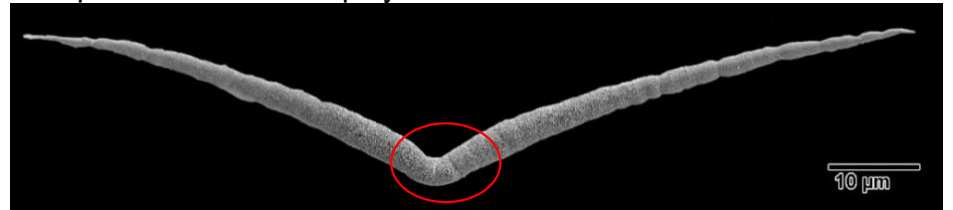
Host-parasite interactions in eugregarines: modified protomerite



Bothriopsis histrio from diving beetle

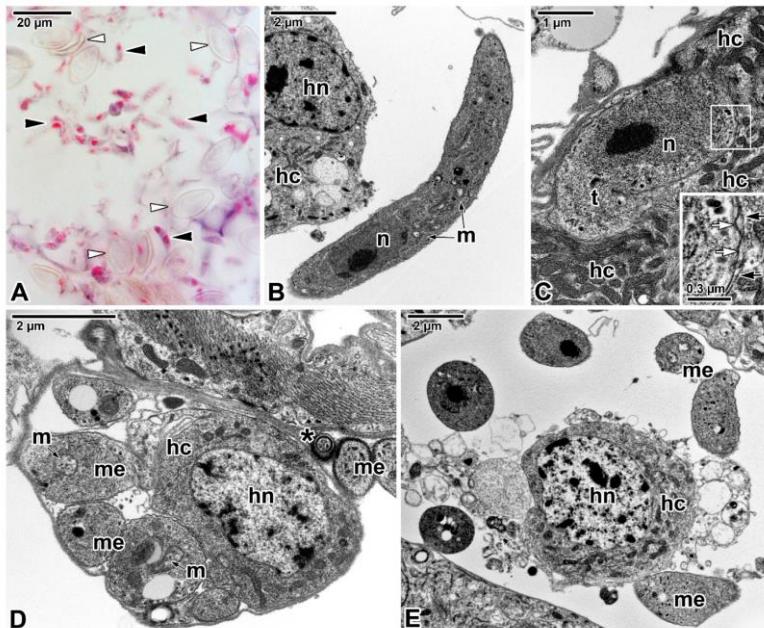


Urospora travisiae from polychaete

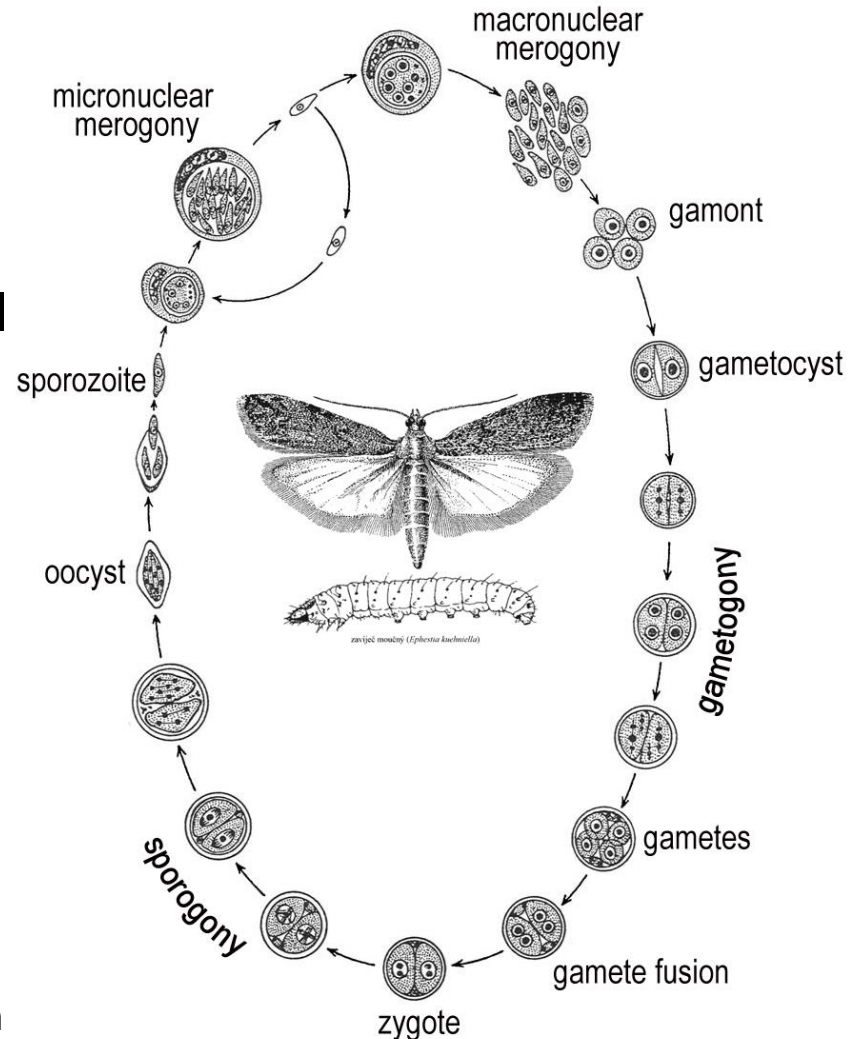


Neogregarinorida

- neogregarines derived from eugregarines, merogony (secondarily obtained)
- parasitising insects and are usually found in the fat body, haemolymph, hypodermis, intestine or Malpighian tubules
- intracellular, epicellular development
- apical complex present in later stages
- trophozoite with epimerite or mucron
- usually pathogenic for their hosts, even fatal



Mattesia dispора in fat body of larval Mediterranean flour moth

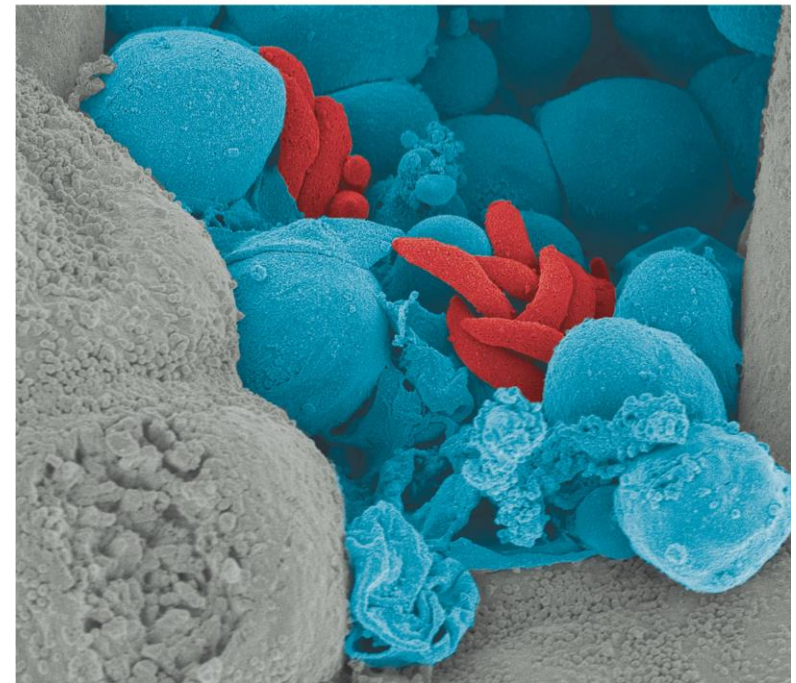


Apicomplexa

Cryptosporidium spp.

- single genus *Cryptosporidium*, currently more than 30 species
- cosmopolitan, mainly intestinal or gastric
- **monoxenous**
- **epicellular niche** - parasite attached to the host cell by a feeder organelle
- small oocysts (4,8-5,6 x 4,2-4,8 μm) with 4 naked sporozoites (no sporocysts)
- **autoinfective stages** - type I merozoites capable of forming new type I meronts and thin-walled oocysts that may liberate sporozoites to initiate new infections

<https://doi.org/10.1016/j.ijpara.2007.11.003>



Cryptosporidia: Epicellular parasites embraced by the host cell membrane

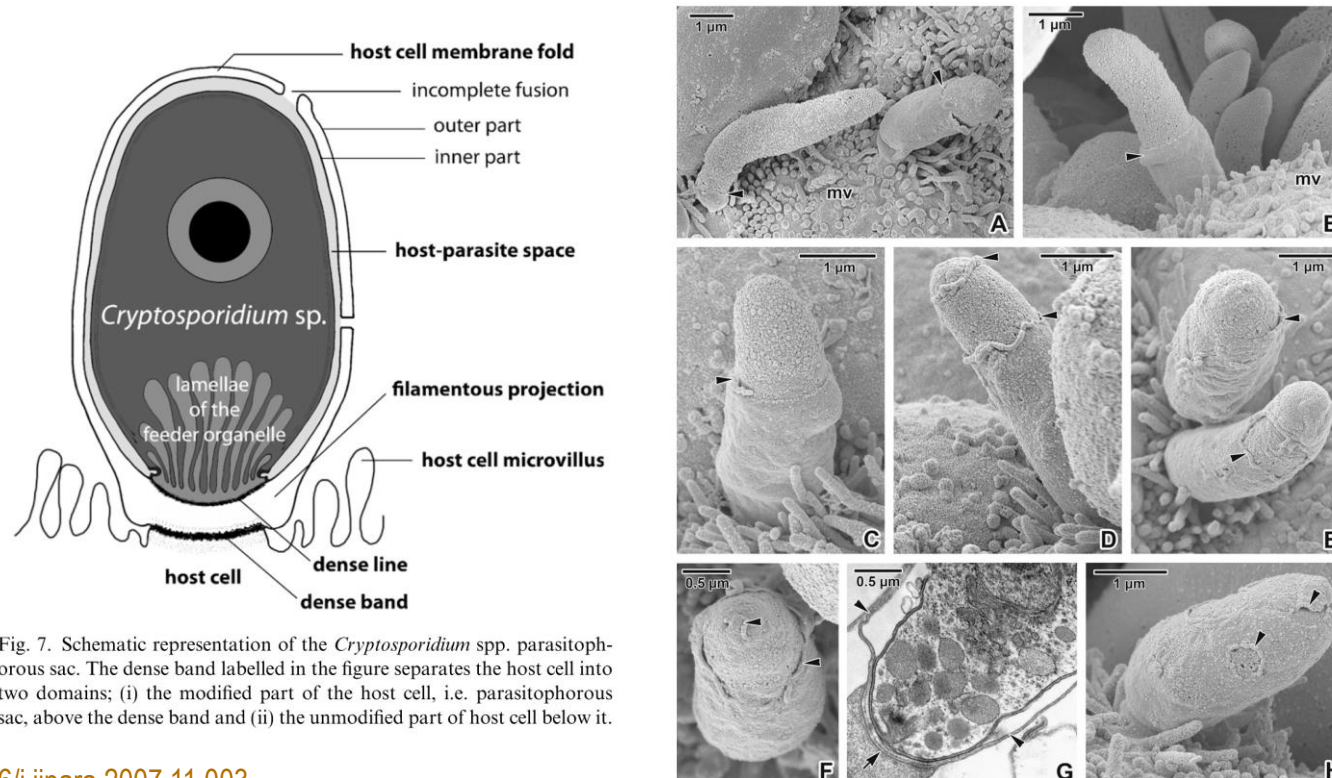
Andrea Valigurová ^{a,1}, Miloslav Jirků ^{b,c,1}, Břetislav Koudela ^{b,c},
Milan Gelnar ^a, David Modrý ^{b,c}, Jan Šlapeta ^{d,*}

^a Department of Botany and Zoology, Faculty of Science, Masaryk University, Kotlářská 2, 611 37 Brno, Czech Republic

^b Department of Parasitology, University of Veterinary and Pharmaceutical Sciences, Palackého 113, 612 42 Brno, Czech Republic

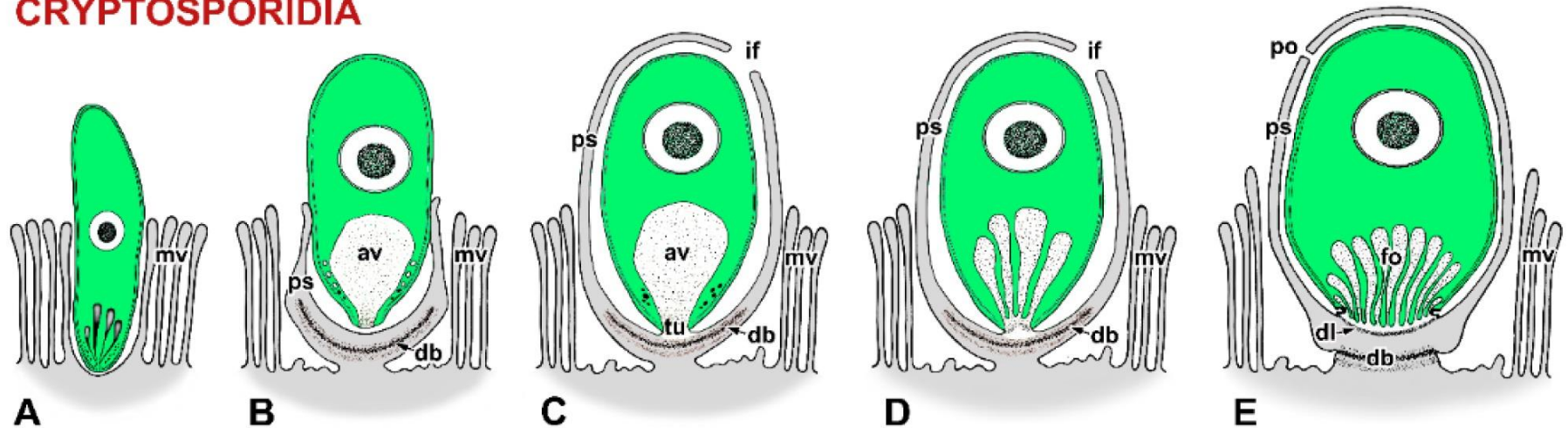
^c Institute of Parasitology, Biology Centre of the Czech Academy of Sciences, Branišovská 31, 370 05 České Budějovice, Czech Republic

^d Faculty of Veterinary Science, University of Sydney, NSW 2006, Australia



Formation of epicellular niche in cryptosporidia

CRYPTOSPORIDIA



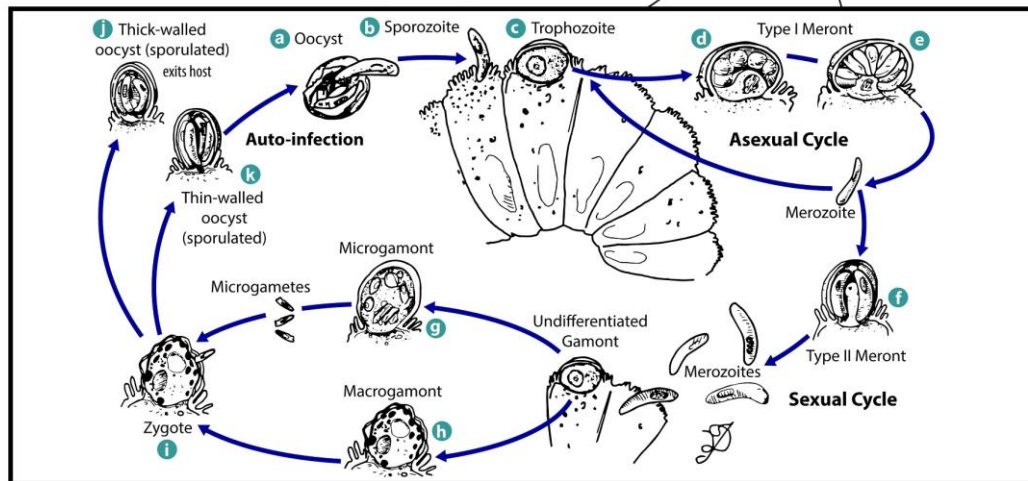
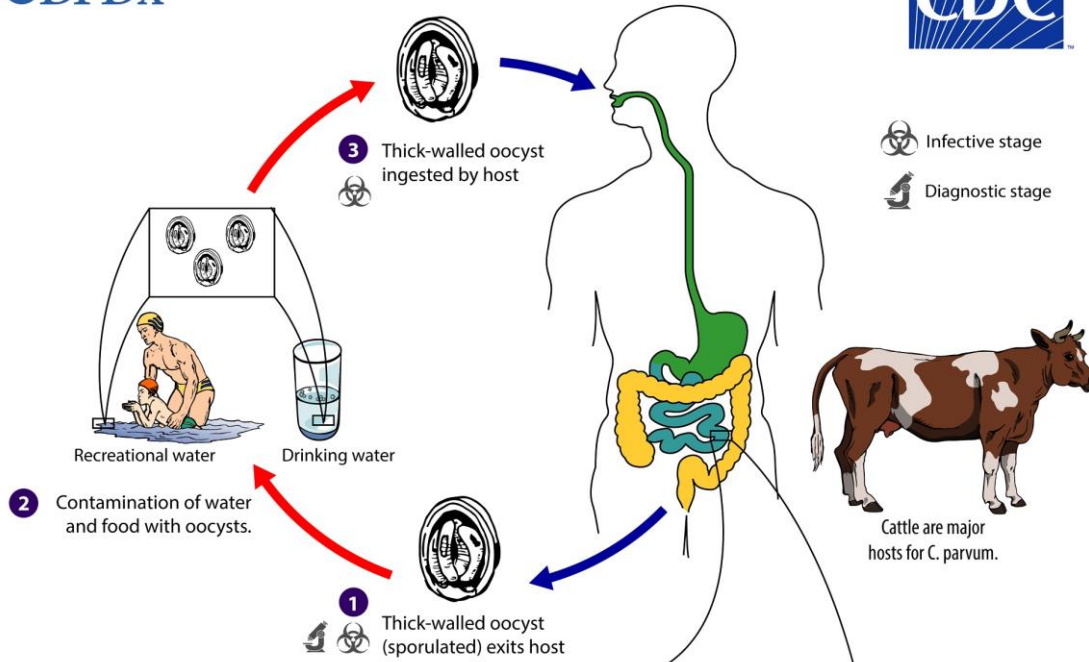
Schematic diagram of host-parasite interactions in cryptosporidia. 3 colours are used to distinguish between the parasite (in green), the host cell including its parts modified due to parasitisation (in grey), and the contact zone between the host and the parasite (in white with black dots) where the interactions of the two organisms become more intimate. (A) Invading zoite (either sporozoite or merozoite). (B) An early trophozoite partially enveloped by an incomplete parasitophorous sac (PS). (C) Young trophozoite almost completely enveloped by a PS. Note the tunnel connection between the interior of the anterior vacuole and the host cell cytoplasm that developed as the result of the Y-shaped membrane junction. (D) Almost mature trophozoite. Note the folding of the anterior vacuolar membrane during its transformation into the feeder organelle (FO). (E) Mature stage with a prominent filamentous projection at the base of the PS and with a fully developed FO, the lamellae of FO formed from the anterior vacuole membrane.

av - anterior vacuole, **db** - dense band, **dl** - dense line separating the feeder organelle from the filamentous projection of the PS, **if** - incomplete fusion of PS, **mv** - host microvilli, **po** - pore on the PS, **tu** - tunnel connection

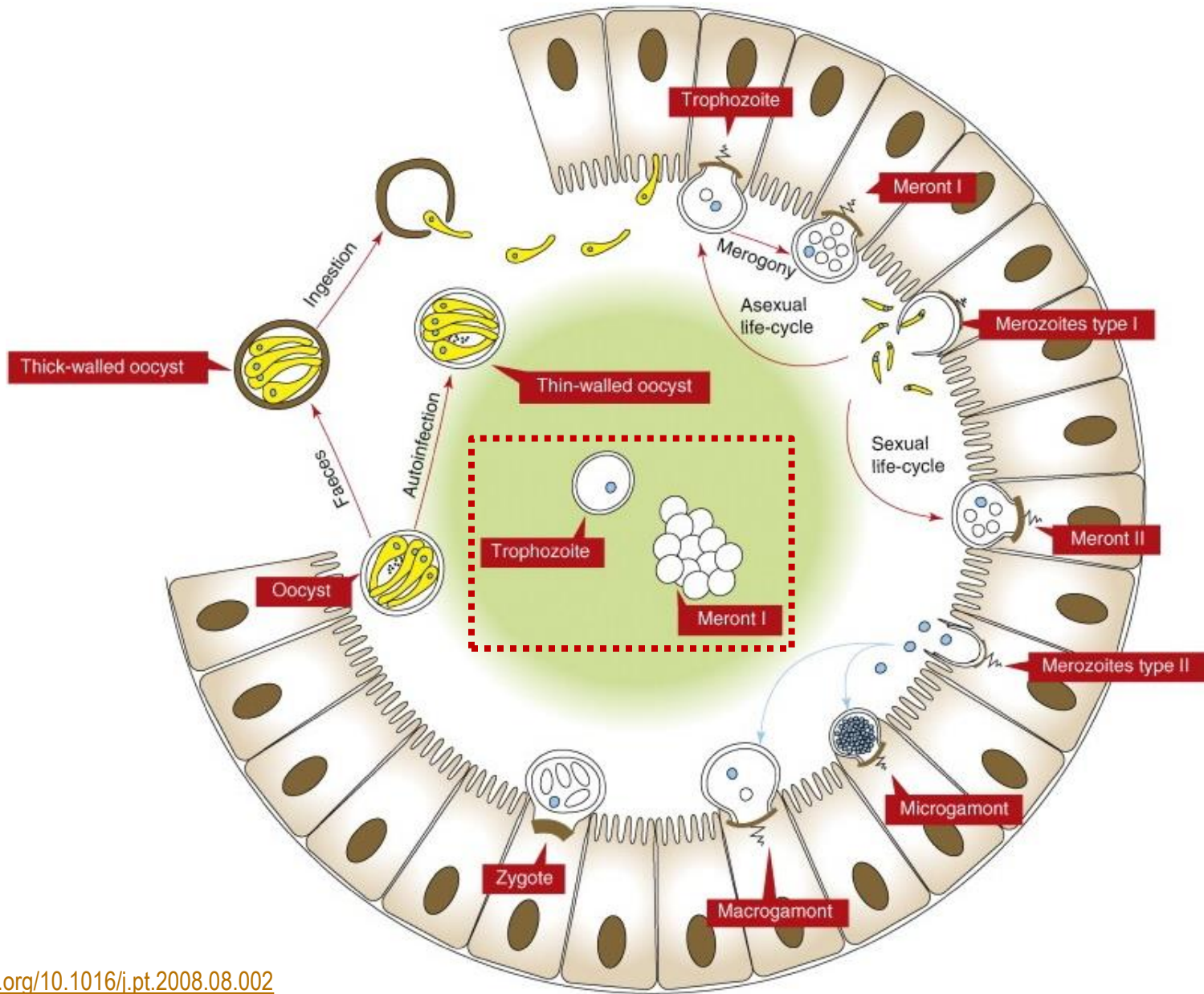
Life cycle of cryptosporidia



Cryptosporidium spp.



Extracellular stages in the life cycle of cryptosporidia ???





ELSEVIER

Contents lists available at ScienceDirect

Water Research

journal homepage: www.elsevier.com/locate/watres



Review

It's official – *Cryptosporidium* is a gregarine: What are the implications for the water industry?



Una Ryan ^{a, *}, Andrea Papparini ^a, Paul Monis ^b, Nawal Hijjawi ^c

^a School of Veterinary and Life Sciences, Murdoch University, Murdoch, Western Australia, 6150, Australia

^b Australian Water Quality Centre, South Australian Water, Adelaide, Australia

^c Department of Medical Laboratory Sciences, Faculty of Allied Health Sciences, The Hashemite University, PO Box 150459, Zarqa, 13115, Jordan

ARTICLE INFO

Article history:

Received 5 May 2016

Received in revised form

7 September 2016

Accepted 8 September 2016

Available online 9 September 2016

Keywords:

Cryptosporidium

Gregarine

Cell-free

Gamont-like extracellular stages

Water industry

ABSTRACT

Parasites of the genus *Cryptosporidium* are a major cause of diarrhoea and ill-health in humans and animals and are frequent causes of waterborne outbreaks. Until recently, it was thought that *Cryptosporidium* was an obligate intracellular parasite that only replicated within a suitable host, and that faecally shed oocysts could survive in the environment but could not multiply. In light of extensive biological and molecular data, including the ability of *Cryptosporidium* to complete its life cycle in the absence of a host and the production of novel extracellular stages, *Cryptosporidium* has been formally transferred from the Coccidia, to a new subclass, Cryptogregarina, with gregarine parasites. In this review, we discuss the close relationship between *Cryptosporidium* and gregarines and discuss the implications for the water industry.

© 2016 Elsevier Ltd. All rights reserved.

Current summary of *Cryptosporidium* spp.

Species Number	Valid species name	Public health significance	Host range	Human	Cattle	Genotype designation
Species I	<i>C. muris</i> Tyzzer, 1907	Minor	MB	Yes		<i>C. muris</i> B genotype
Species II	<i>C. parvum</i> Tyzzer, 1912	Minor	M	(Yes)		Mouse I genotype
Species III	<i>C. meleagridis</i> Slavin, 1955 (syn. <i>C. tyzzeri</i> Levine, 1961)	Moderate	MB	Yes	(Yes)	
Species IV	<i>C. wrairi</i> Vetterling, Jarvis, Merrill & Sprinz, 1971	None	M		(Yes)	
Species V	<i>C. agni</i> Barker & Carbonell, 1974 (syn. <i>C. xiaoi</i> Fayer & Santín, 2009)	None	M			<i>C. bovis</i> -like genotype
Species VI	<i>C. bovis</i> Barker & Carbonell, 1974	None	M		Yes	Bovine B genotype
Species VII	<i>C. cuniculus</i> Inman & Takeuchi, 1979	Moderate	M	Yes		Rabbit genotype
Species VIII	<i>C. felis</i> Iseki, 1979	Moderate	M	Yes	(Yes)	Cat genotype
Species IX	<i>C. serpentis</i> Levine, 1980	None	RM		(Yes)	
Species X	<i>C. nitoris</i> Hoover, Hoerr, Carlton, Hinsman & Ferguson, 1981	None	F			n/a
Species XI	<i>C. baileyi</i> Current, Upton & Haynes, 1986	None	B			
Species XII	<i>C. varanii</i> Pavlásek, Lávičková, Horák, Král & Král, 1995 (syn. <i>C. saurophilum</i> Koudela & Modrý, 1998)	None	R			Desert monitor genotype
Species XIII	<i>C. cichlidis</i> (Paperna & Vilenkin, 1996)	None	F			Piscine genotype 1
Species XIV	<i>C. reichenbachklinkei</i> (Paperna & Vilenkin, 1996)	None	F			Piscine genotype 2
Species XV	<i>C. galli</i> Pavlásek, 1999	None	B			Finch genotype
Species XVI	<i>C. andersoni</i> Lindsay, Upton, Owens, Morgan, Mead, & Blagburn, 2000	Minor	M	Yes	Yes	<i>C. muris</i> A genotype
Species XVII	<i>C. canis</i> Fayer, Trout, Xiao, Morgan, Lal & Dubey, 2001	Minor	M	Yes	(Yes)	Dog genotype
Species XVIII	<i>C. hominis</i> Morgan-Ryan, Fall, Ward, Hijjawi, Sulaiman, Fayer, Thompson, Olson, Lal & Xiao, 2002	Major	M	Yes	Yes	Human (I) genotype
Species XIX	<i>C. molnari</i> Alvarez-Pellitero & Sitjà-Bobadilla, 2002	None	F			
Species XX	<i>C. suis</i> Ryan, Monis, Enemark, Sulaiman, Samarasinghe, Read, Buddle, Robertson, Zhou, Thompson & Xiao, 2004	Minor	M	(Yes)	Yes	Pig genotype II
Species XXI	<i>C. scophthalmi</i> Alvarez-Pellitero, Quiroga, Sitjà-Bobadilla, Redondo, Palenzuela, Padrós, Vázquez & Nieto, 2004	None	F			n/a
Species XXII	<i>C. pestis</i> Šlapeta, 2006	Major	M	Yes	Yes	Bovine (II) genotype
Species XXIII	<i>C. fayeri</i> Ryan, Power & Xiao, 2008	Minor	M	(Yes)		Marsupial genotype I
Species XXIV	<i>C. ryanae</i> Fayer & Santín, Trout, 2008	None	M		Yes	Deer-like genotype
Species XXV	<i>C. fragile</i> Jirků, Valigurová, Koudela, Křížek, Modrý & Šlapeta, 2008	None	A			
Species XXVI	<i>C. macropodum</i> Power & Ryan, 2008	None	M			Marsupial genotype II
Species XXVII	<i>C. ducismarci</i> Traversa, 2010	None	R			
Species XXVIII	<i>C. ubiquitousum</i> Fayer, Santín & Macarisin, 2010	Minor	M	Yes	Yes	Deer genotype
Species XXIX	<i>C. viatorum</i> Elwin, Hadfield, Robinson, Crouch & Chalmers, 2012	Moderate	M	Yes		
Species XXX	<i>C. scrofarum</i> Kváč, Kestřánová, Pinková, Květoňová, Kalinová, Wagnerová, Kotková, Vítovec, Ditrich, McEvoy, Stenger & Sak, 2013	Minor	M	(Yes)	(Yes)	Pig genotype II

Host range: M, mammal; B, bird; R, reptile; F, fish. n/a, not applicable because the species has not been characterised using any DNA signature. (Yes), indicates extremely rare or experimental evidence.

Zoonotic potential of cryptosporidia

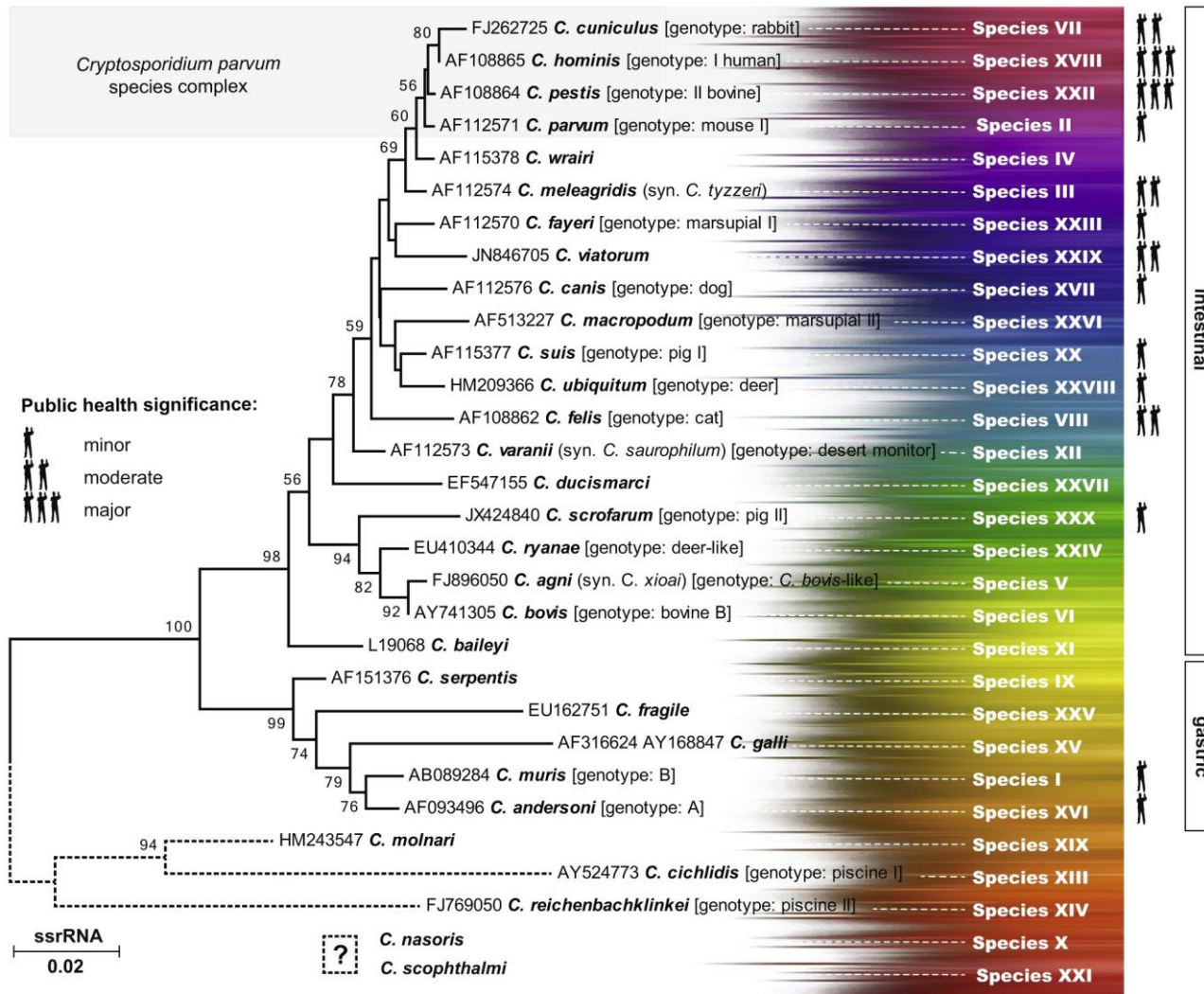


Fig. 1. Phylogeny of 28 named *Cryptosporidium* spp. using a reference dataset of ssrRNA sequences. The reference multiple sequence alignment consists of 1795 positions (Supplementary data S1). A Minimum Evolution tree was reconstructed with a bootstrap test (1,000 replicates). All ambiguous positions were removed for each sequence pair. The branch lengths represent evolutionary distances computed using the Maximum Composite Likelihood method in MEGA5 (Tamura et al., 2011). GenBank accession numbers accompany all species names, as well as public health significance and either intestinal or gastric development within its host. The species parasitising fish served as an outgroup (dotted line). There is no ssrRNA sequence available for *Cryptosporidium naboris* (Species X) and *Cryptosporidium scophthalmi* (Species XXI).

Cryptosporidium parvum

- intestinal pathogen of mammalian hosts

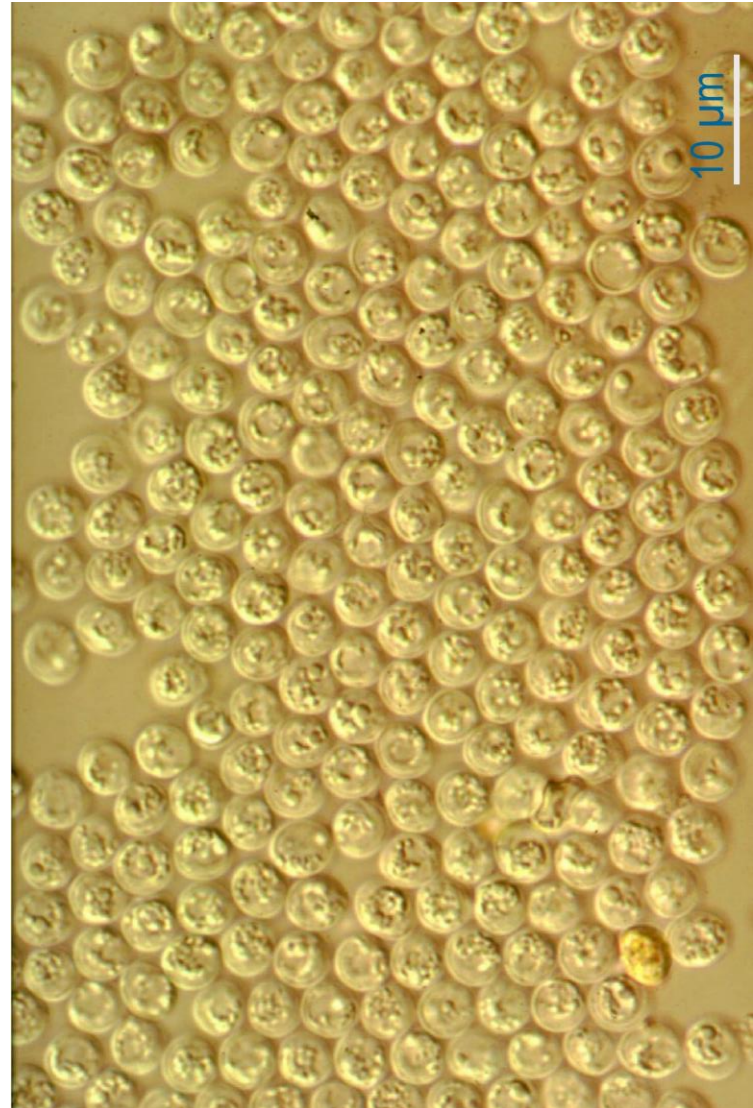
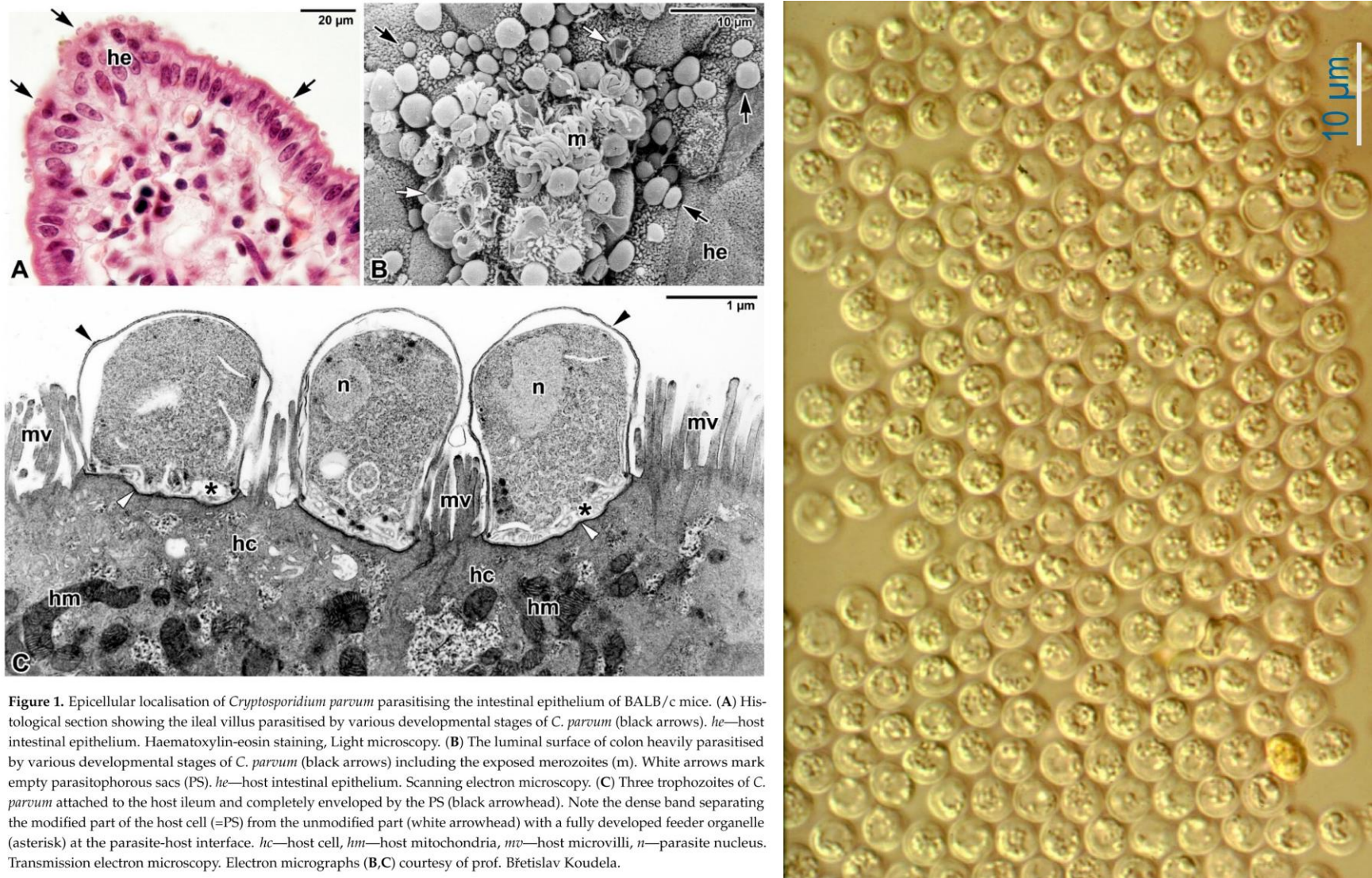
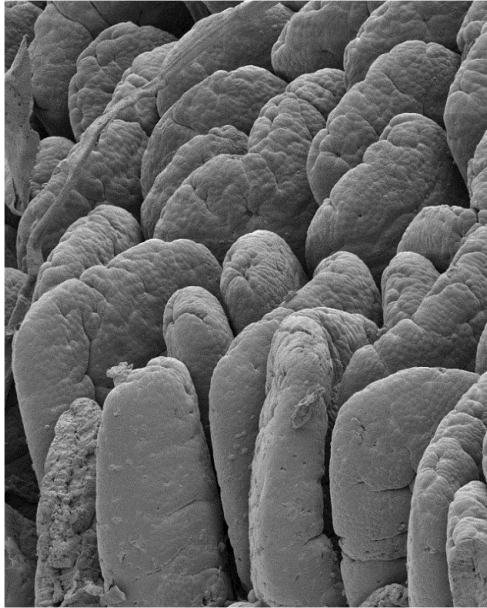
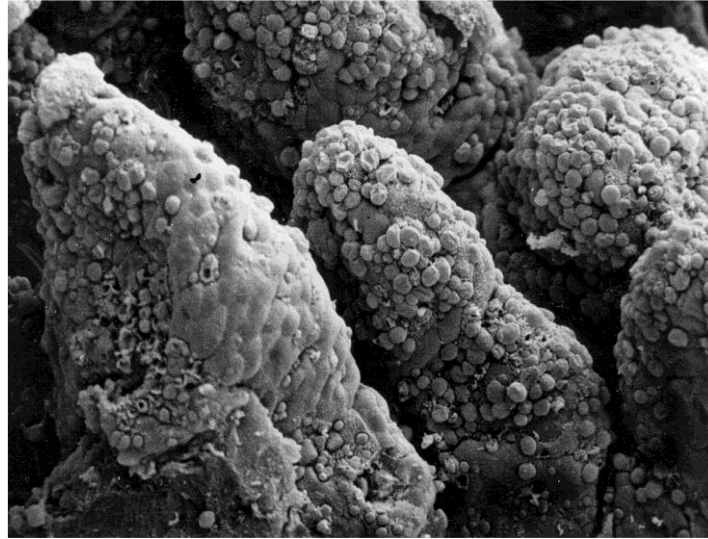
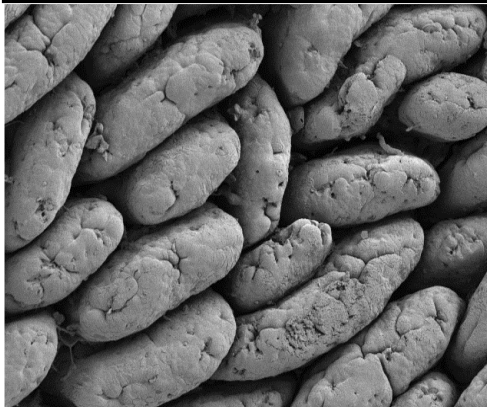


Figure 1. Epicellular localisation of *Cryptosporidium parvum* parasitising the intestinal epithelium of BALB/c mice. (A) Histological section showing the ileal villus parasitised by various developmental stages of *C. parvum* (black arrows). *he*—host intestinal epithelium. Haematoxylin-eosin staining, Light microscopy. (B) The luminal surface of colon heavily parasitised by various developmental stages of *C. parvum* (black arrows) including the exposed merozoites (m). White arrows mark empty parasitophorous sacs (PS). *he*—host intestinal epithelium. Scanning electron microscopy. (C) Three trophozoites of *C. parvum* attached to the host ileum and completely enveloped by the PS (black arrowhead). Note the dense band separating the modified part of the host cell (=PS) from the unmodified part (white arrowhead) with a fully developed feeder organelle (asterisk) at the parasite-host interface. *hc*—host cell, *hm*—host mitochondria, *mv*—host microvilli, *n*—parasite nucleus. Transmission electron microscopy. Electron micrographs (B,C) courtesy of prof. Břetislav Koudela.


Pathological changes in rodents with intestinal cryptosporidiosis



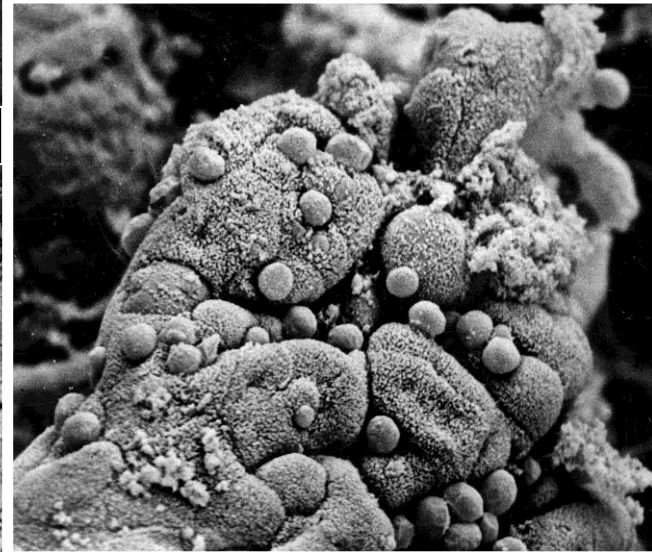
Healthy jejunum



Ileum (BALB/c) with *C. parvum*, villous atrophy

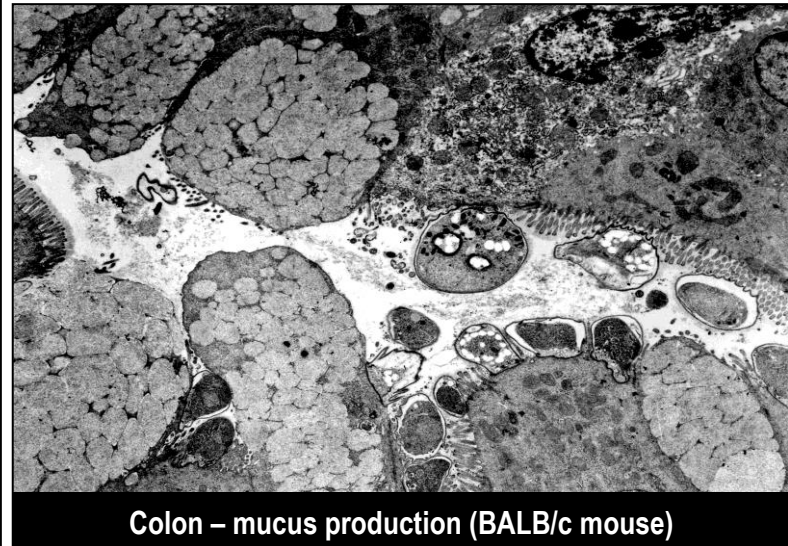
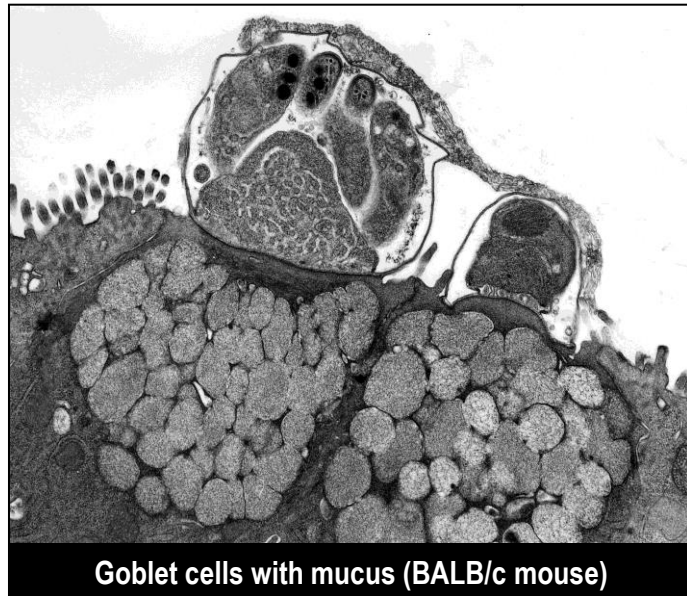
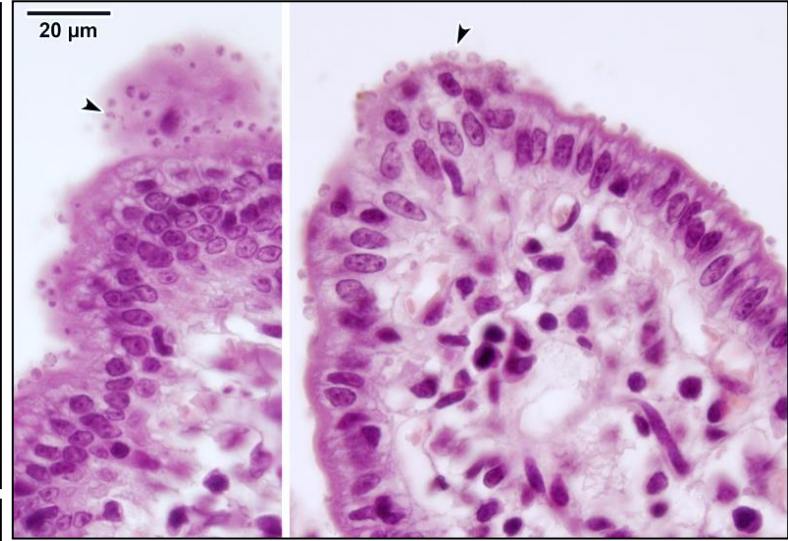
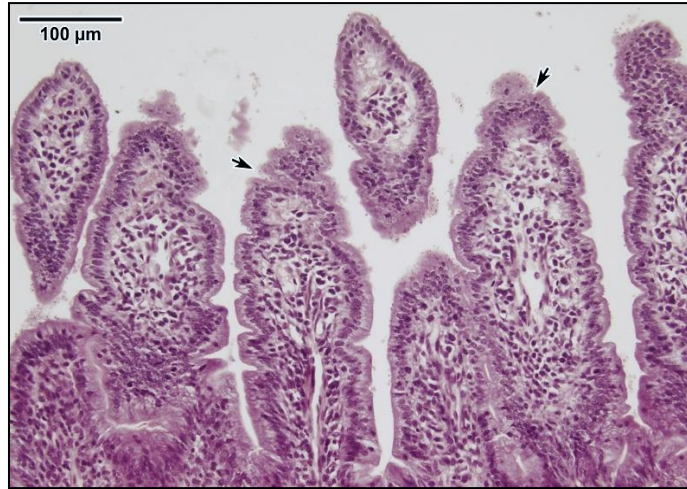


- epithelial cells lining intestinal tract, does not invade deeper layers of the intestinal mucosa
- **major pathological changes:** villous atrophy, shortening of microvilli and sloughing of enterocytes



Jejunum with *C. parvum*, absorptive cells exhibiting protuberances

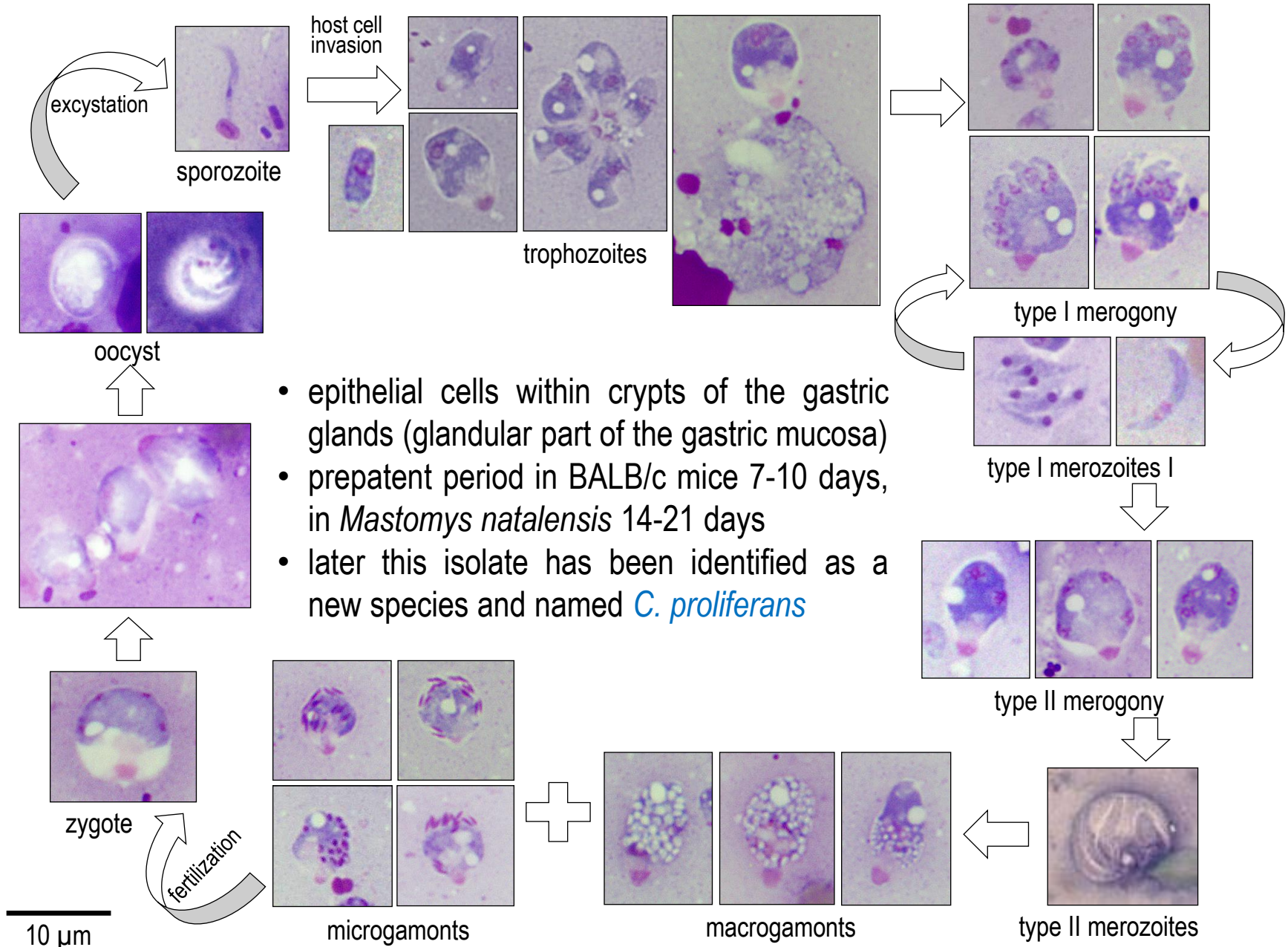
Pathological changes in rodents with intestinal cryptosporidiosis



- cryptosporidia on the surface of the intestinal mucosa
- villous atrophy of the small intestine, inflammatory infiltrate in the lamina propria

Cryptosporidium muris

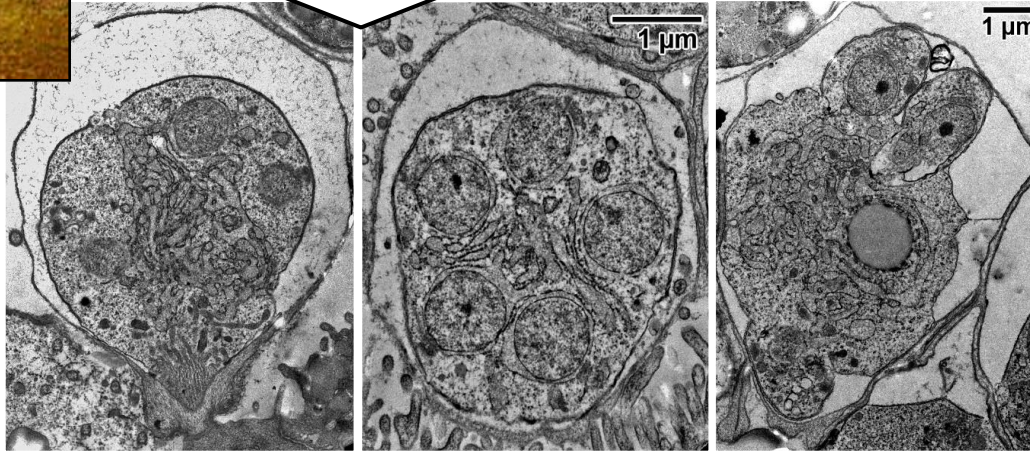
<https://doi.org/10.1017/S0031182013001637>




Life cycle of *C. muris* in rodent host



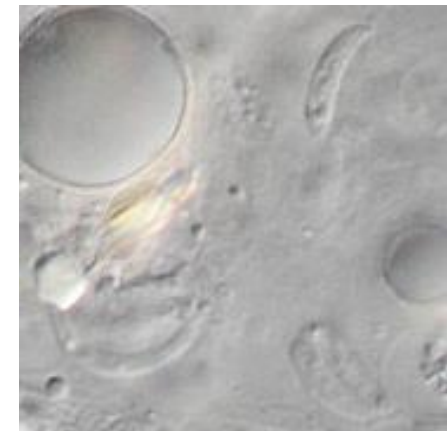
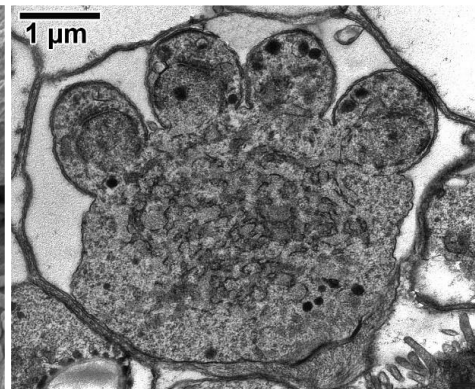
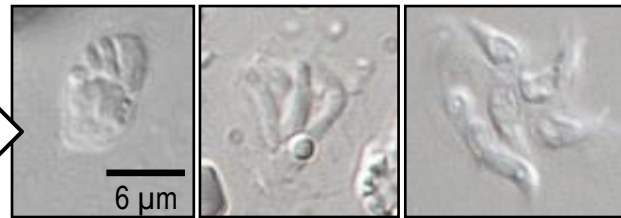
merogony



type I merogony

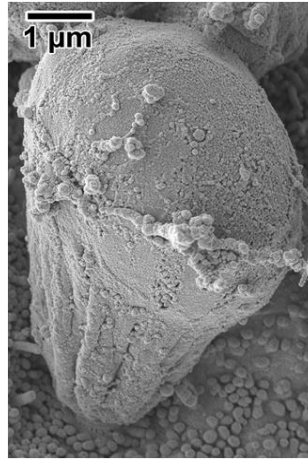
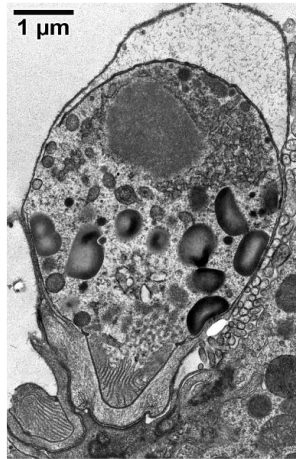
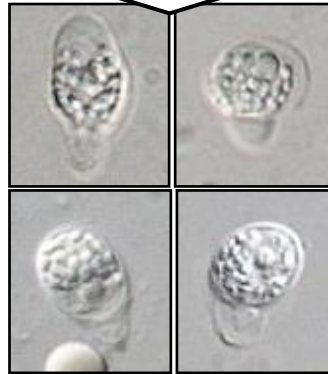

type II merogony

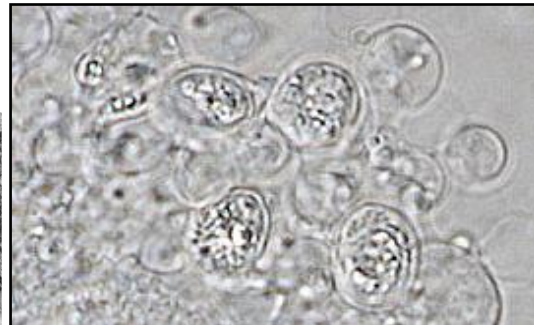
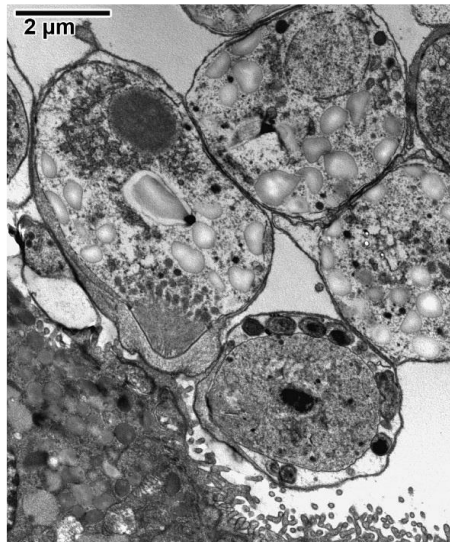
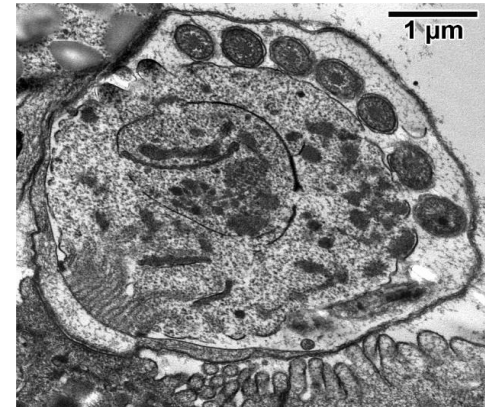
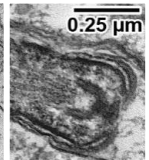
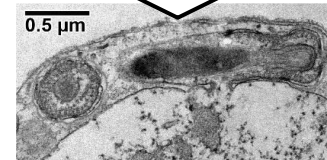
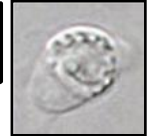Life cycle of *C. muris* in rodent host


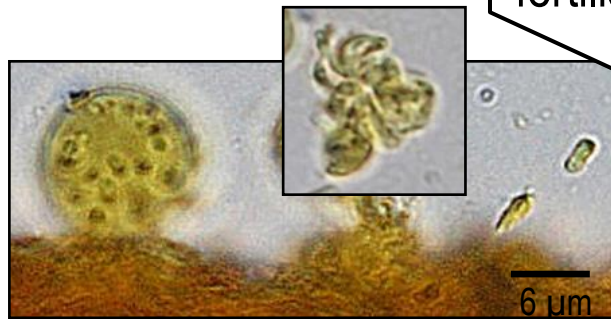
macrogamont



microgamont

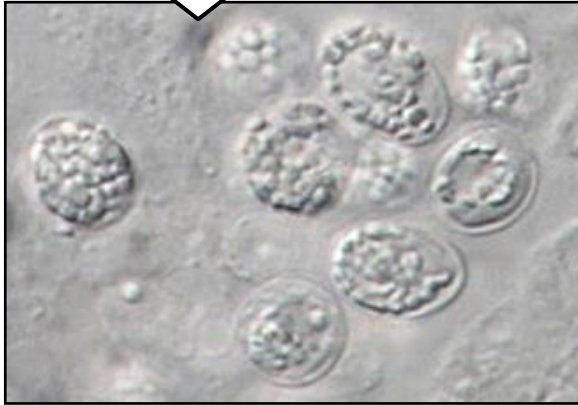

fertilisation

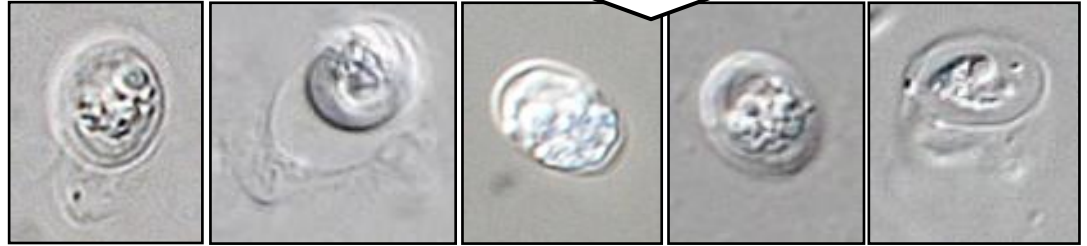


Life cycle of *C. muris* in rodent host

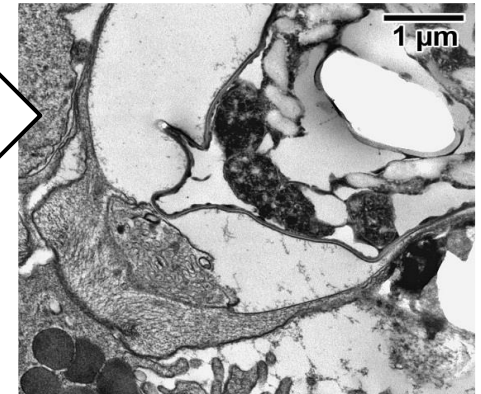
zygotes



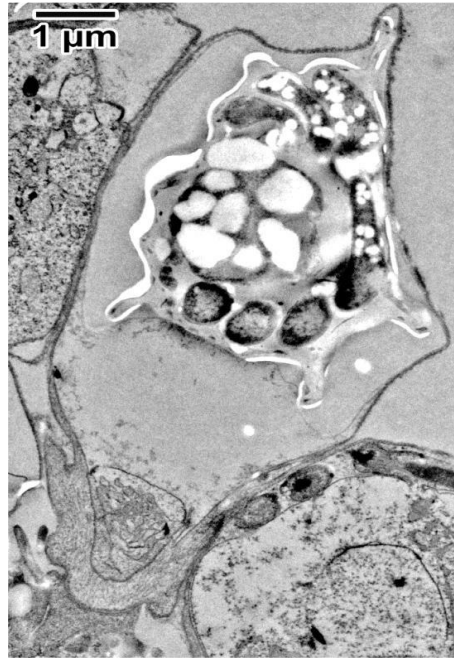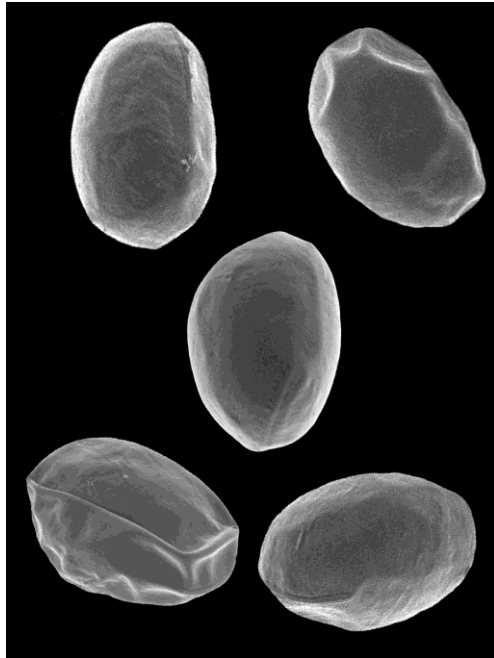
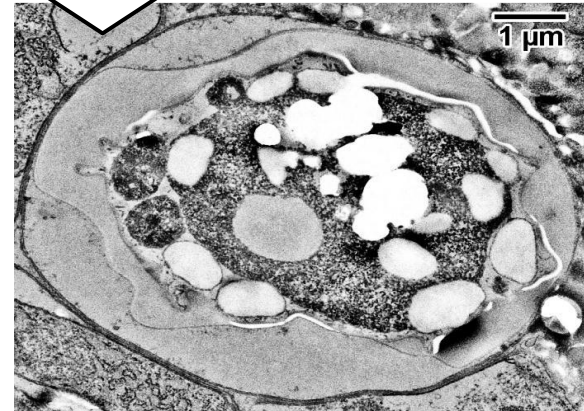
developing oocysts



thick-walled oocyst


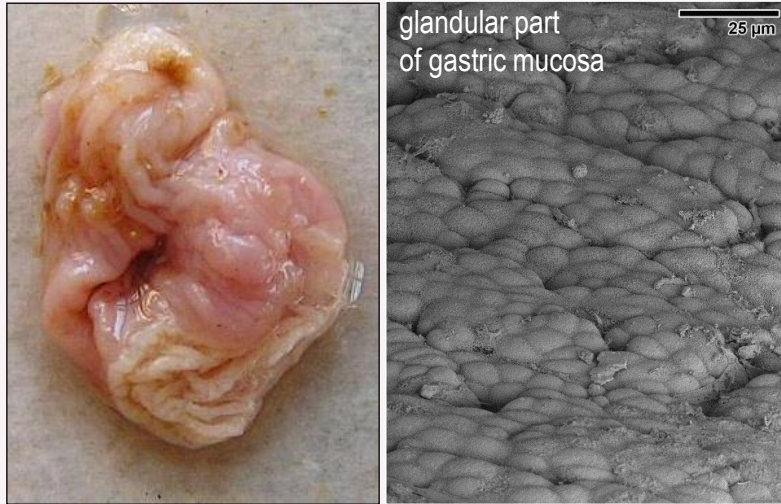


thin-walled oocyst

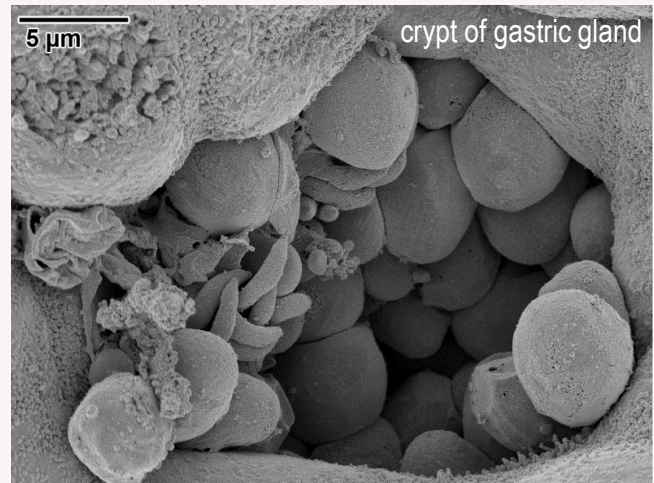
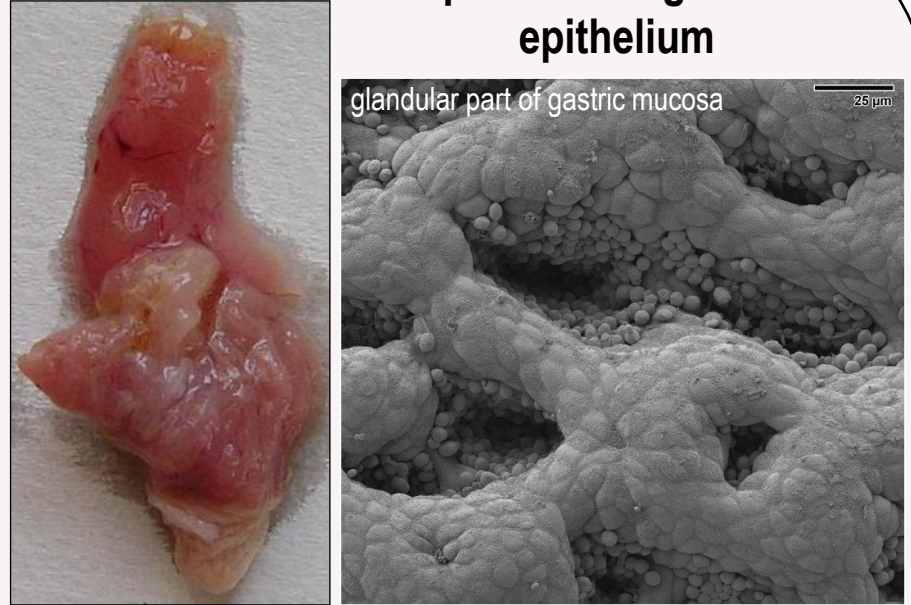


Pathological changes in rodents with gastric cryptosporidiosis

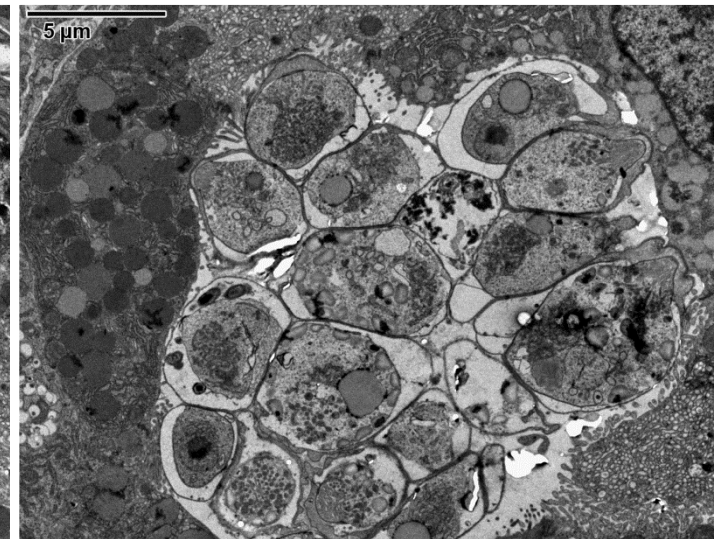
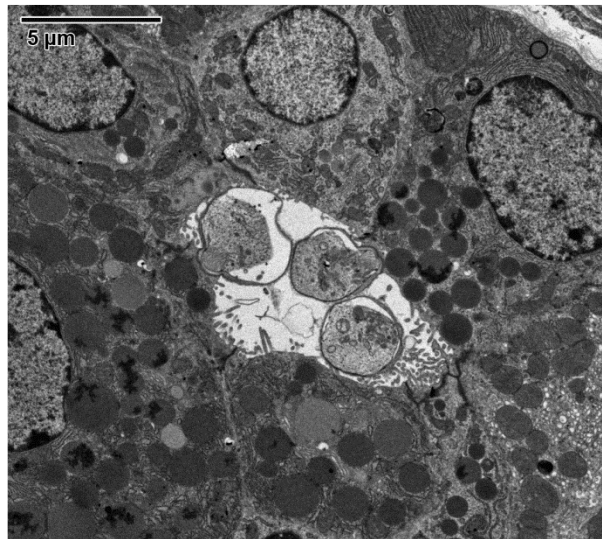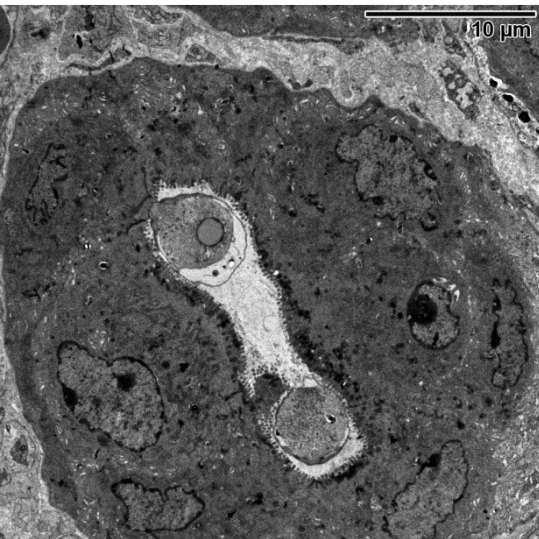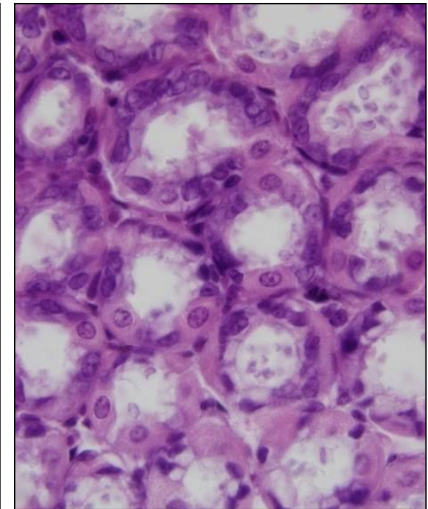
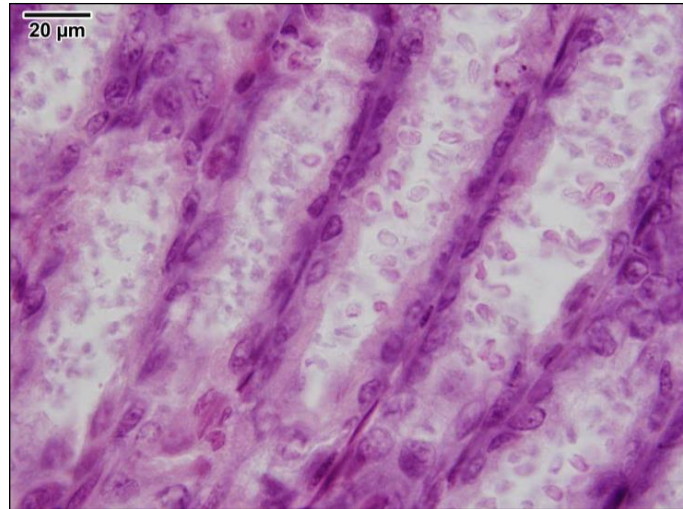
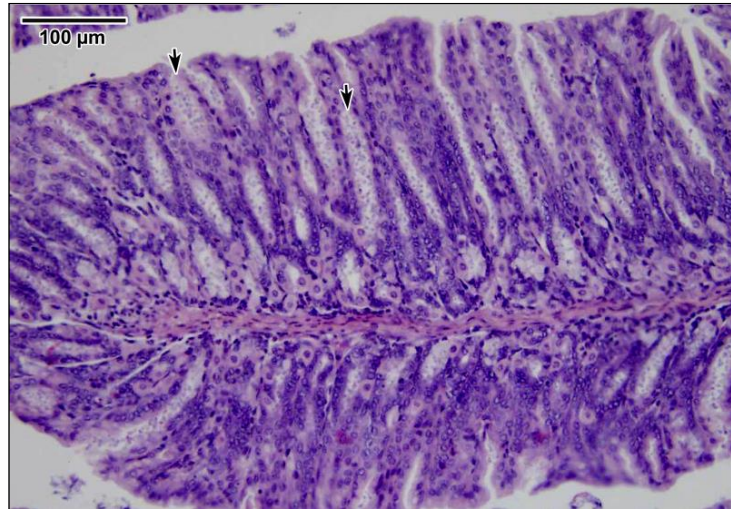
healthy gastric epithelium



parasitised gastric epithelium




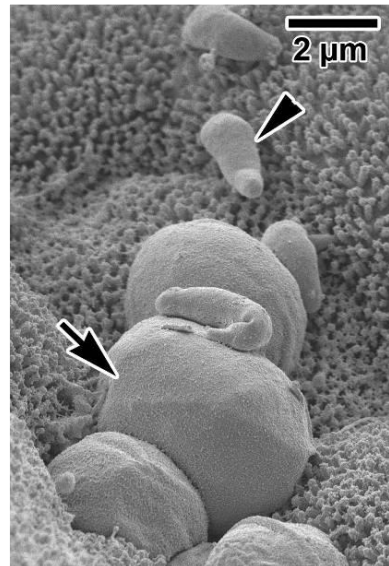
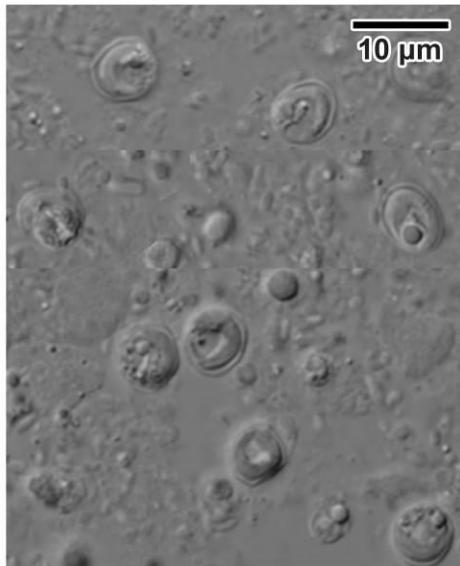
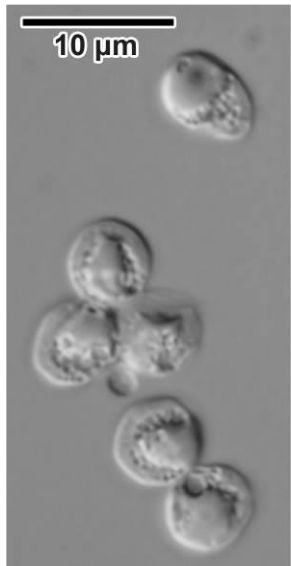
Pathological changes in rodents with gastric cryptosporidiosis



- ✓ obvious dilatation of gastric glands
- ✓ epithelial hyperplasia and mucosal hypertrophy without inflammatory exudate

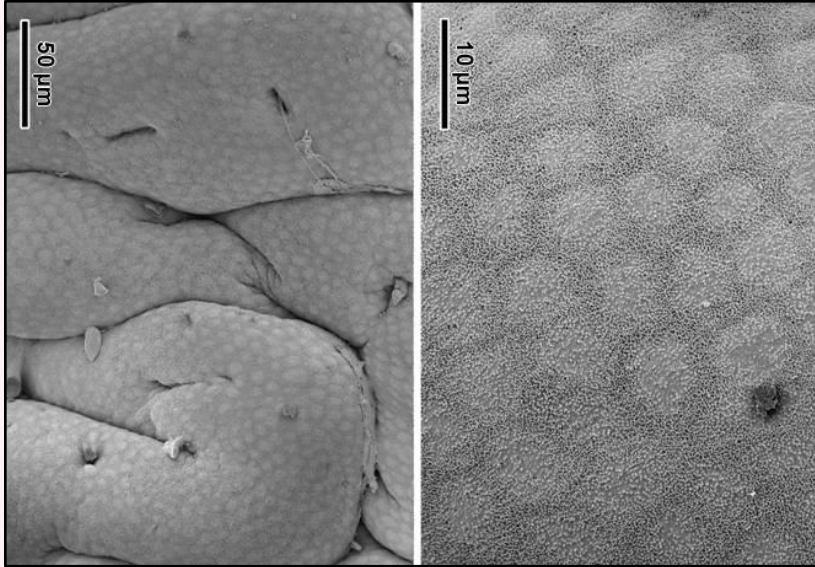
Cryptosporidium fragile

- luminal surface of gastric epithelium and the crypts of gastric glands
- from naturally infected black-spined toads *Duttaphrynus melanostictus* obtained via import of pet animals from the Malay Peninsula in 2006
- infection spontaneously disappeared 24–51 days after arrival

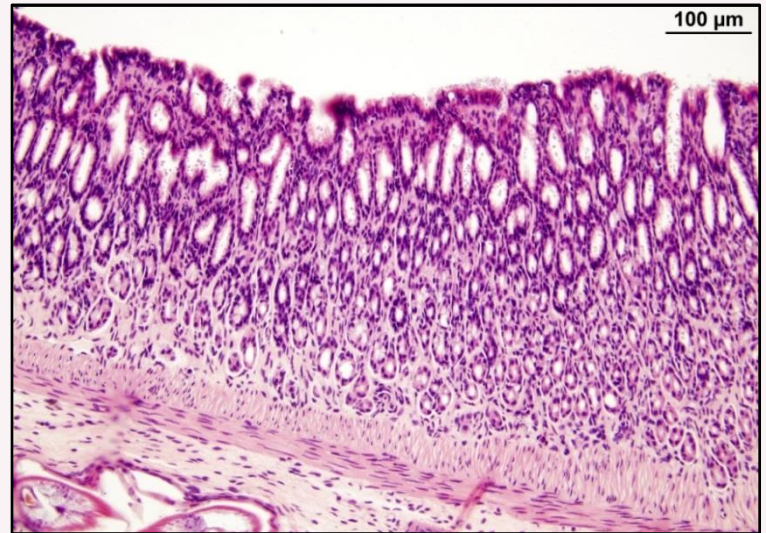
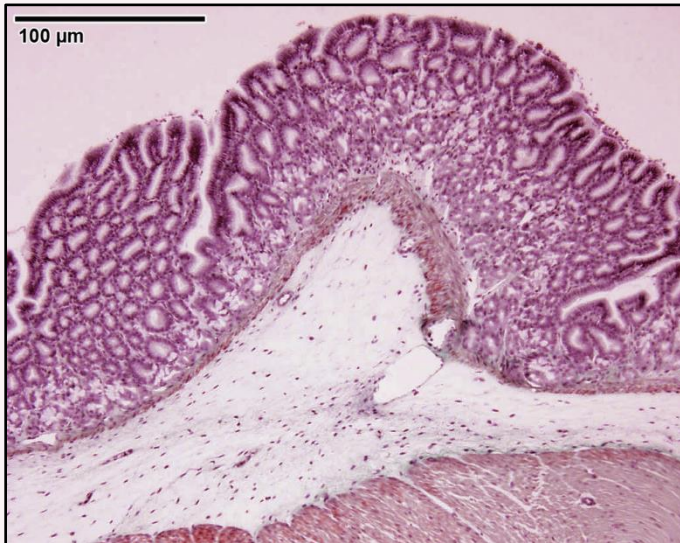


Pathological changes in toads with gastric cryptosporidiosis

healthy gastric epithelium



parasitised gastric epithelium



Cryptosporidiosis

- animal and human diseases
- significance: cattle++++, sheep++, goat++, poultry++, reptiles++, human+, horse+, pig+, dog+, cat+
- **no effective chemotherapy**
- **emerging infectious diseases, zoonotic character**, primary symptoms are acute, watery, and diarrhoea without blood
- other symptoms may include anorexia, nausea, vomiting and abdominal cramping/pain, weight loss, electrolyte imbalance
- self-limiting in immunocompetent people – parasite life-cycle ends when host immune response eliminates the reproductive cycle
- in immunosuppressed patients (diarrhoea can reach 10–15 times per day), such as those with AIDS or those undergoing immunosuppressive therapy, the parasite overwhelms its host due to recycling of type I meronts and infection may lead to dehydration and even death - **opportunistic parasites**
- extra-gastrointestinal sites include lung, liver and gall bladder, where it causes respiratory cryptosporidiosis, hepatitis, and cholecystitis, respectively

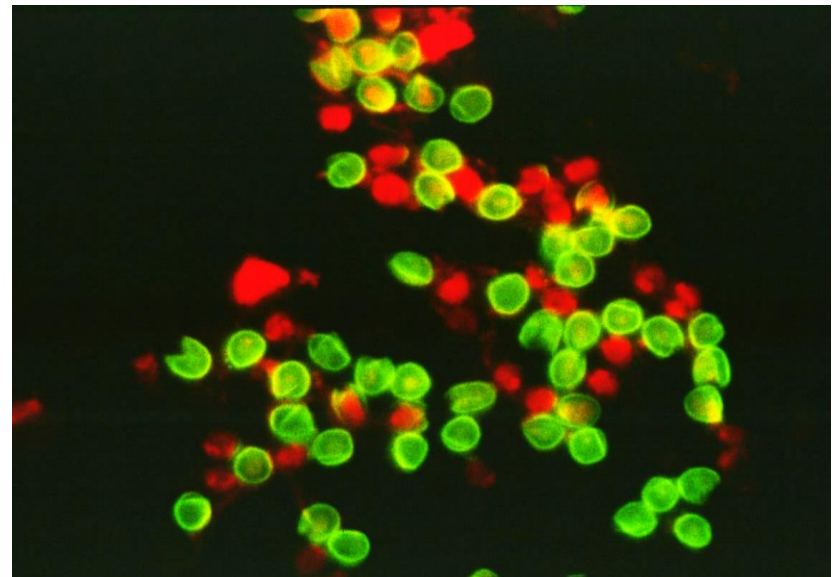
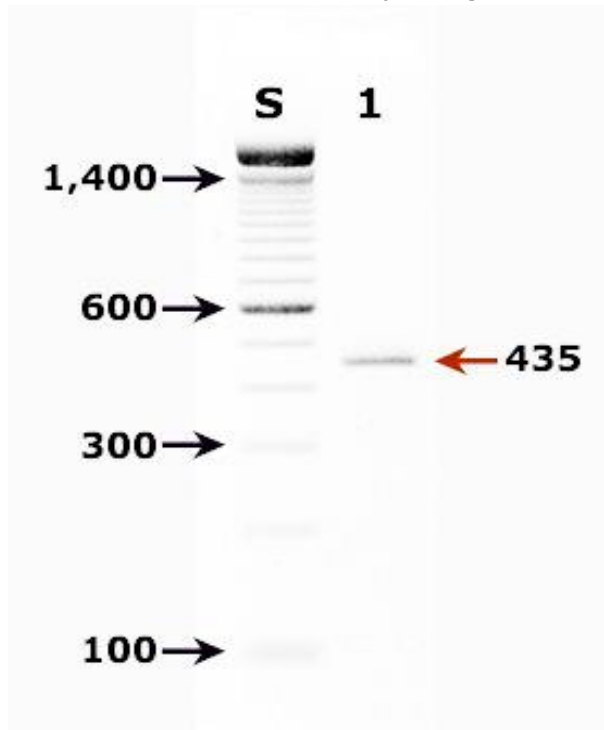
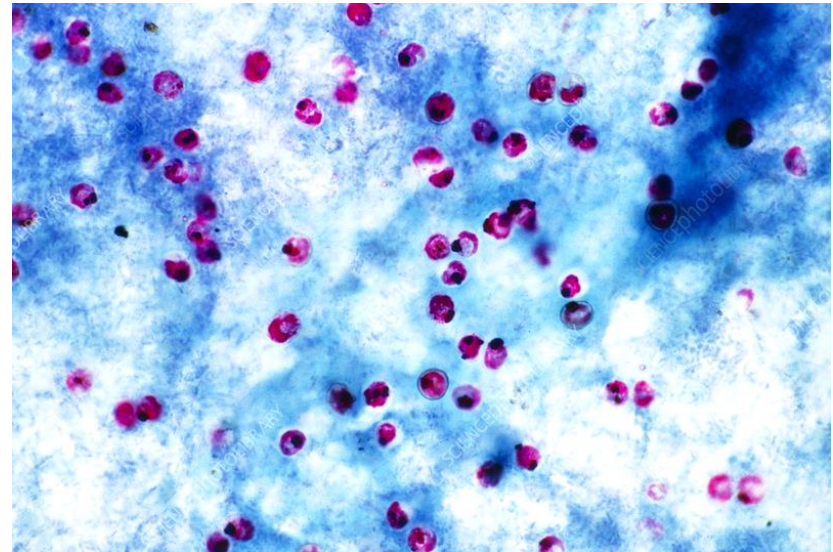
Clinical signs of human cryptosporidiosis

Diarrhea
Abdominal pain
Weight loss

	Normal host	Immunosuppressed host
Duration	3-12 days (1 month)	Months (chronic, progressive)
Stool volume	1-2 L/day	3-6 L/day (17 L)
Location	Ileal region	Small bowel, colon, bile ducts, gall bladder epithelium, respiratory tract

Diagnosis of cryptosporidiosis

- ✓ flotation methods
- ✓ stained smears
- ✓ immunoassays
- ✓ **molecular methods** – multipathogen molecular panels, molecular typing



Water-borne cryptosporidiosis in Milwaukee (1993)

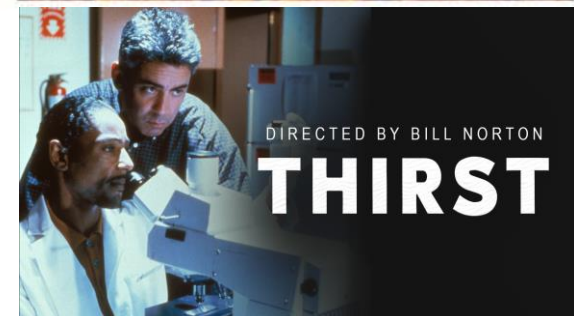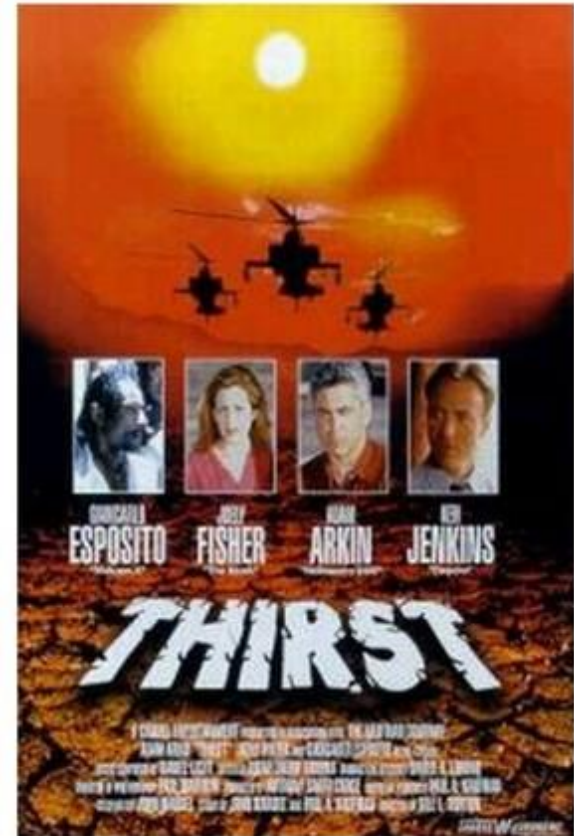The largest **waterborne disease** outbreak in documented US history (infection caused by *C. hominis*). It is suspected that The Howard Avenue Water Purification Plant was contaminated due to an ineffective filtration process.

This abnormal condition lasted from March 23 through April 8, after which, the plant was shut down. Over the span of approximately two weeks, **403,000** of an estimated 1.61 million residents in the Milwaukee area (of which 880,000 were served by the malfunctioning treatment plant) became ill with the stomach cramps, fever, diarrhoea and dehydration caused by the pathogen. **Over 100 deaths** were attributed to this outbreak, mostly among the elderly and immunocompromised people, such as AIDS patients. The total cost of the outbreak, in productivity loss and medical expenses, was **\$96 million**



Cryptosporidium starring in the movie THIRST (1998)

The town of San Paulo is suffering from a heatwave. Engineer Bob Miller turns up at work to learn that the new water filtration plant he has been building has been cancelled and that he is now unemployed. At the same time, Bob's wife Susan has to deal with a series of mystery deaths at the hospital where she works as a nurse. Bob realizes that the cause might be the water supply. Dr Lawrence Carver confirms that the water is infected with a **deadly bacteria *Cryptosporidium***. They discover that the ***Cryptosporidium*** is throughout the town's drinking water. The only choice is to turn the water plant off and for everybody to drink only bottled or boiled water. As the death toll grows, they realize that they are dealing with a mutated form of the bacteria that is resistant to boiling. Meanwhile, the state governor's office makes the decision to put a military quarantine around the town..... .



Water-borne cryptosporidiosis in Östersund (2010)

 Centers for Disease Control and Prevention
CDC 24/7: Saving Lives, Protecting People™

Search 

EMERGING INFECTIOUS DISEASES®

ISSN: 1080-6059

EID Journal > Volume 20 > Number 4—April 2014 > Main Article

Volume 20, Number 4—April 2014

Research

Large Outbreak of *Cryptosporidium hominis* Infection Transmitted through the Public Water Supply, Sweden

Micael Widerström¹, Caroline Schönning, Mikael Lilja, Marianne Lebbad, Thomas Ljung, Görel Allestam, Martin Ferm, Britta Björkholm, Anette Hansen, Jari Hiltula, Jonas Långmark, Margareta Löfdahl, Maria Omberg, Christina Reuterwall, Eva Samuelsson, Katarina Widgren, Anders Wallensten, and Johan Lindh

Author affiliations: Umeå University, Umeå, Sweden (M. Widerström, M. Lilja, M. Ferm, C. Reuterwall, E. Samuelsson); Jämtland County Council, Östersund, Sweden (M. Widerström, M. Omberg); Public Health Agency of Sweden, Solna, Sweden (C. Schönning, M. Lebbad, G. Allestam, B. Björkholm, A. Hansen, J. Långmark, M. Löfdahl, K. Widgren, A. Wallensten, J. Lindh); Mid Sweden University, Östersund, (T. Ljung,); Östersund Municipality, Östersund (J. Hitula); and Karolinska Institutet, Stockholm (J. Lindh)

[Cite This Article](#)

Abstract

In November 2010, ≈27,000 (≈45%) inhabitants of Östersund, Sweden, were affected by a waterborne outbreak of cryptosporidiosis. The outbreak was characterized by a rapid onset and high attack rate, especially among young and middle-aged persons. Young age, number of infected family members, amount of water consumed daily, and gluten intolerance were identified as risk factors for acquiring cryptosporidiosis. Also, chronic intestinal disease and young age were significantly associated with prolonged diarrhea. Identification of *Cryptosporidium hominis* subtype 1bA10G2 in human and environmental samples and consistently low numbers of oocysts in drinking water confirmed insufficient reduction of parasites by the municipal water treatment plant. The current outbreak shows that use of inadequate microbial barriers at water treatment plants can have serious consequences for public health. This risk can be minimized by optimizing control of raw water quality and employing multiple barriers that remove or inactivate all groups of pathogens.

<https://doi.org/10.3201/eid2004.121415>

2010-12-02-239 Cryptosporidiosis - Sweden: (JA)
To: (04) Food borne diseases

CRYPTOSPORIDIOSIS - SWEDEN: (JÄMTLAND)

A ProMED-mail post
[1]

Date: Tue 30 Nov 2010

Source: Swedish Institute for Infectious Disease Control [in Swedish, trans. Mod.EP, edited]

<<http://www.smi.se/nyhetsarkiv/2010/utbrott-av-cryptosporidium-i-ostersund/>>

The Swedish Institute for Infectious Disease Control, SMI, has Monday [29 Nov 2010] analyzed drinking water and samples from the water purification unit at Minnesgarde, Östersund municipality [Jämtland, Sweden]. The analysis found cryptosporidium in both drinking water samples and samples obtained from the purification unit.

[2]

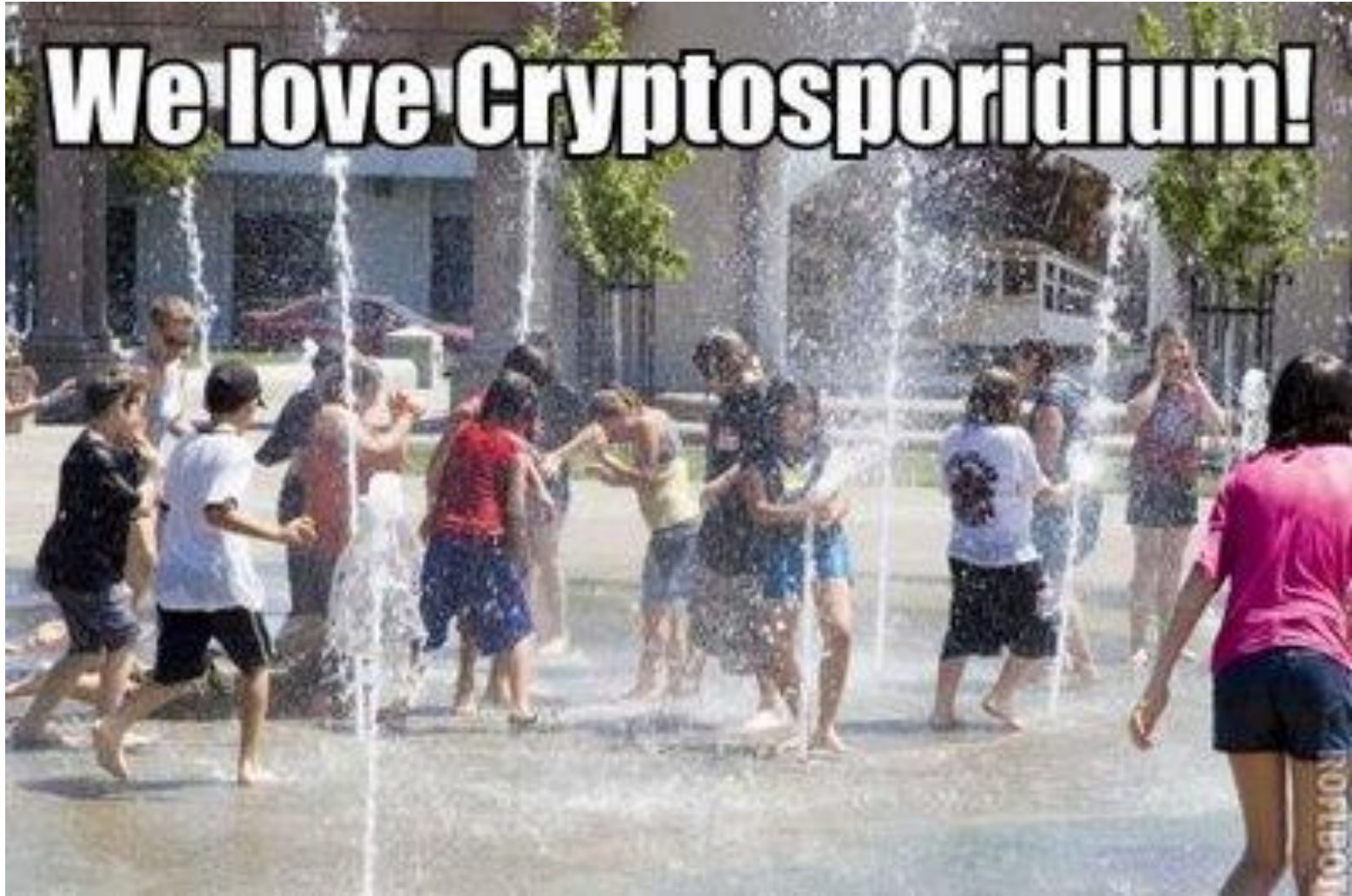Date: Mon 29 Nov 2010

Source: BeforeItsNews.com [edited]

<http://beforeitsnews.com/story/285/919/Cryptosporidium_outbreak_sickens_thousands_in_Sweden.html>

UPI reports that cryptosporidium in the water supply has sickened more than 2000 people in the city of Östersund, in northern Sweden. The source of the contamination is unknown. It is feared 3000 to 9000 people may be infected.

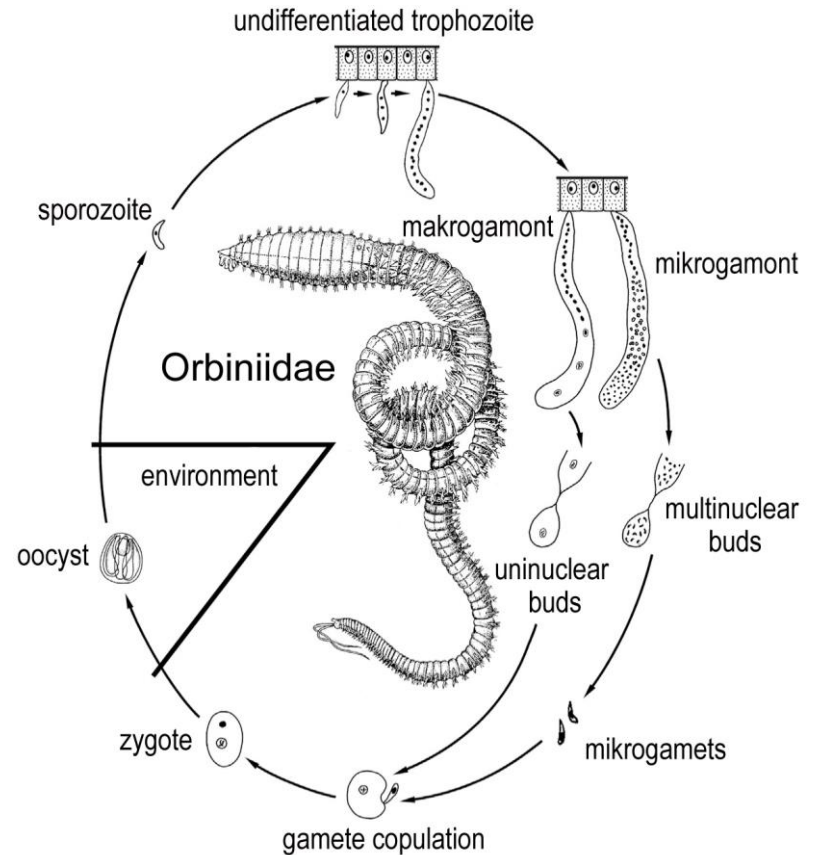
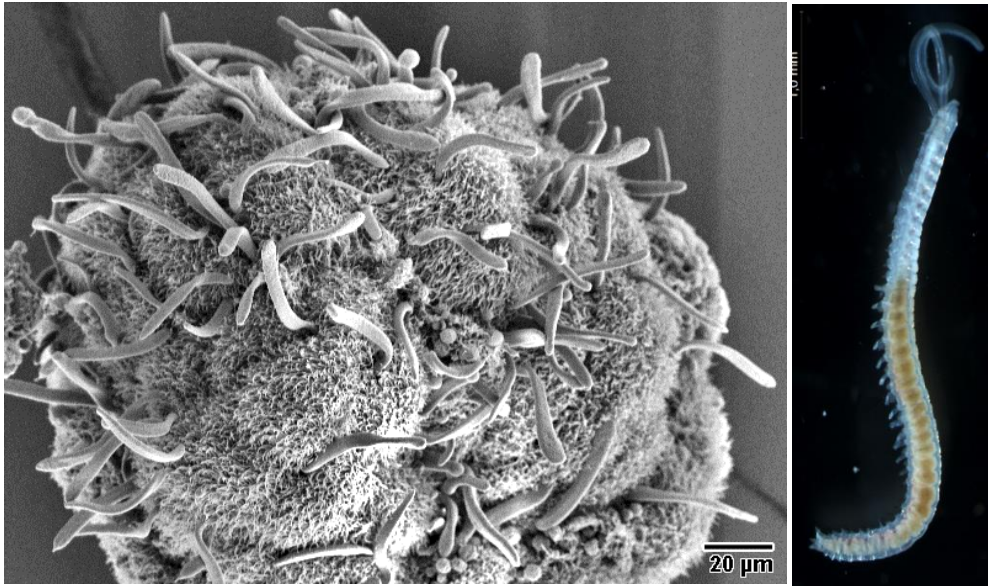
Water-borne cryptosporidiosis



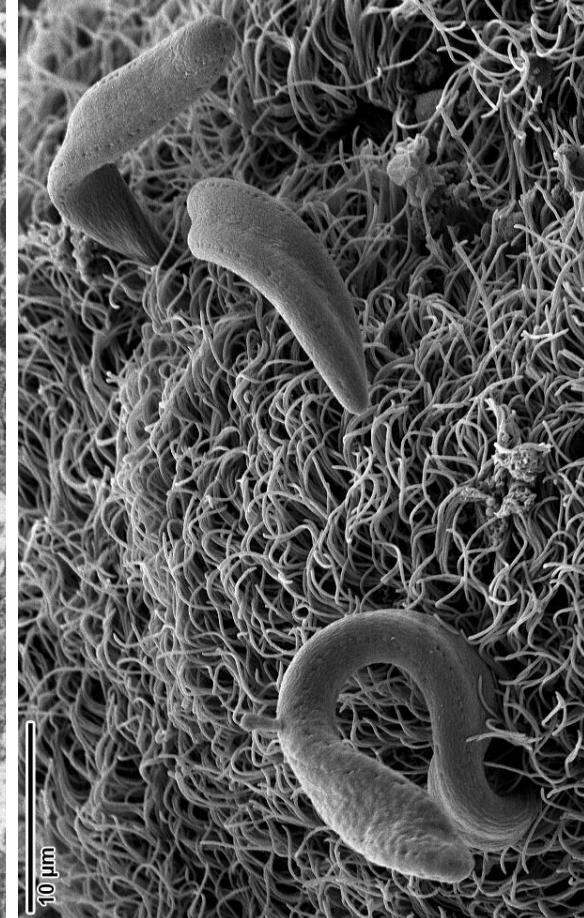
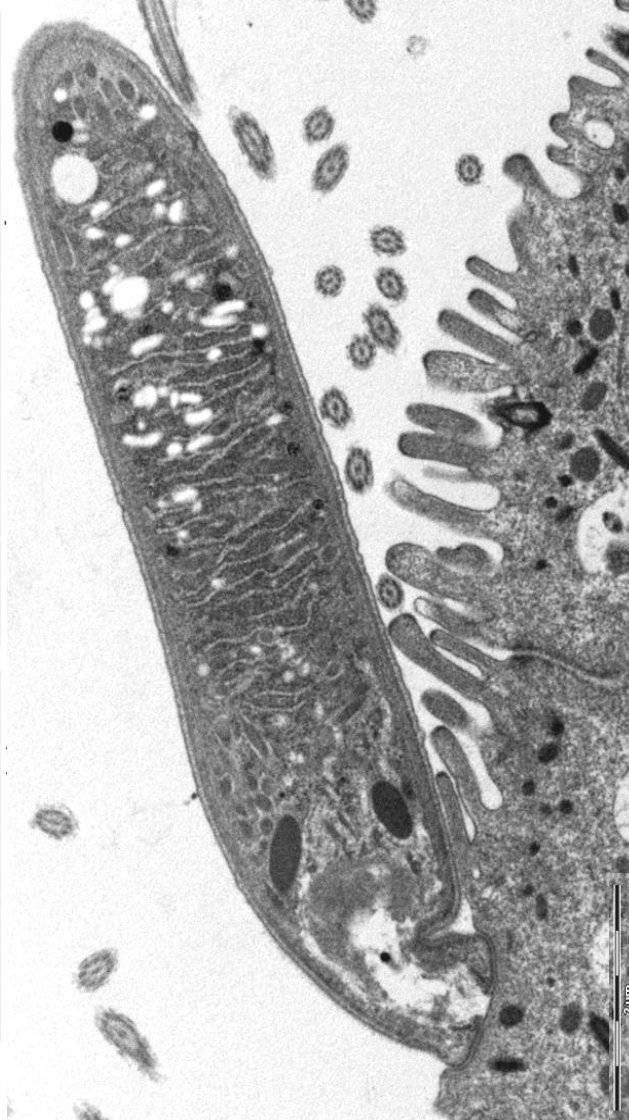
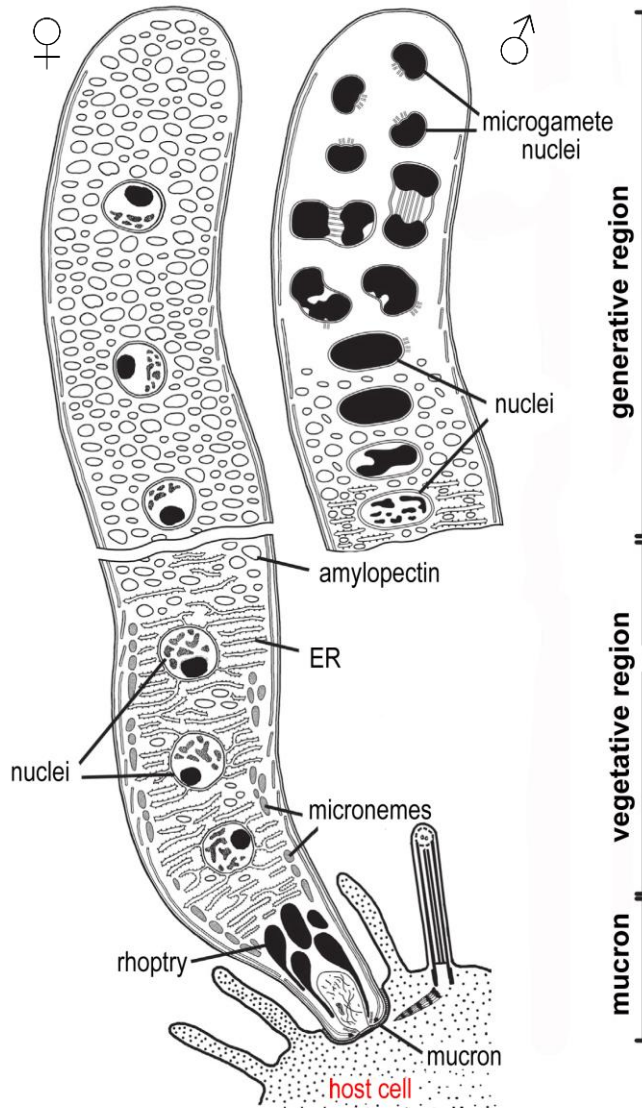
Blastogregarinea

- only two genera (*Chattonaria*, *Siedleckia*) known from polychaeta
- blastogregarines possess both gregarine and coccidian features
- permanent multinuclearity and gametogenesis (merogamont)
- epicellular development - brush border of enterocytes
- **myzocytosis** via mucron (conoid, rhoptries) + subpellicular microtubules = **plesiomorphic features** („hypersporozoite“)
- wavy and bending motility

Siedleckia nematoides



Cell organisation in blastogregarines

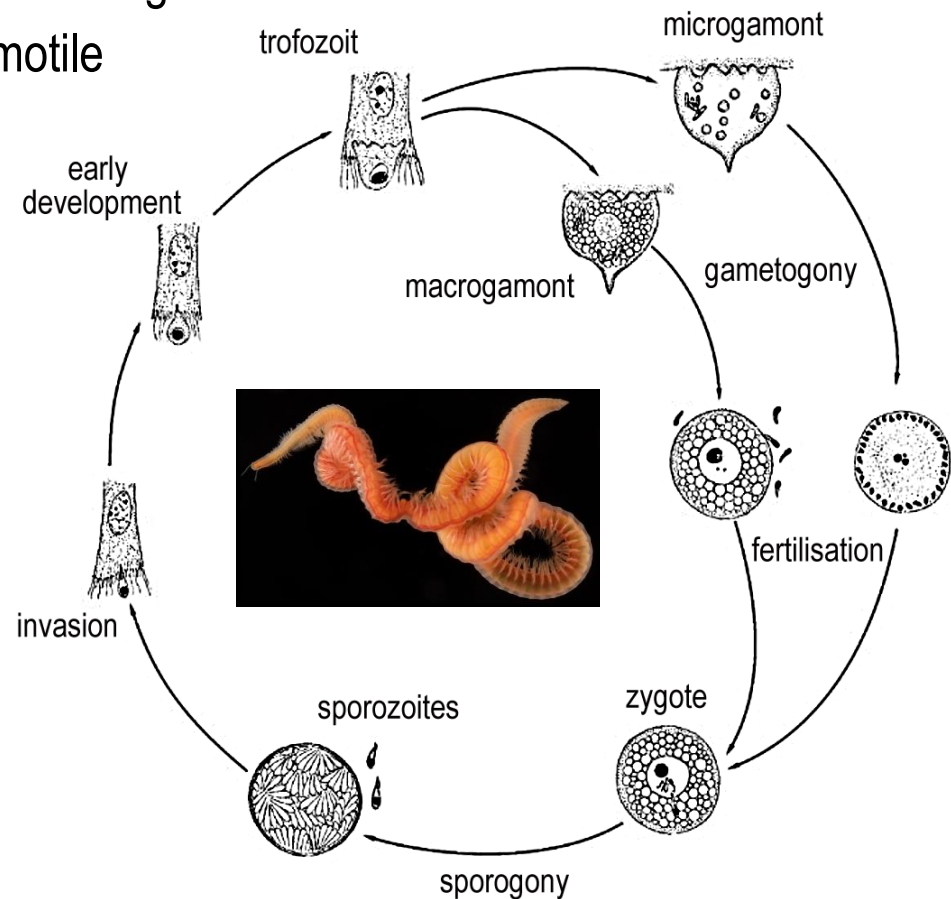
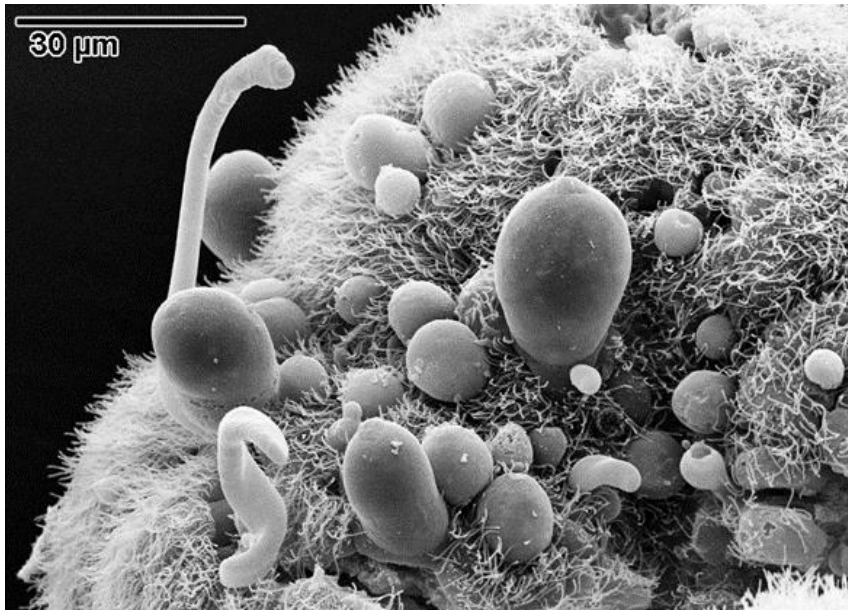


<https://doi.org/10.1016/j.protis.2018.04.006>

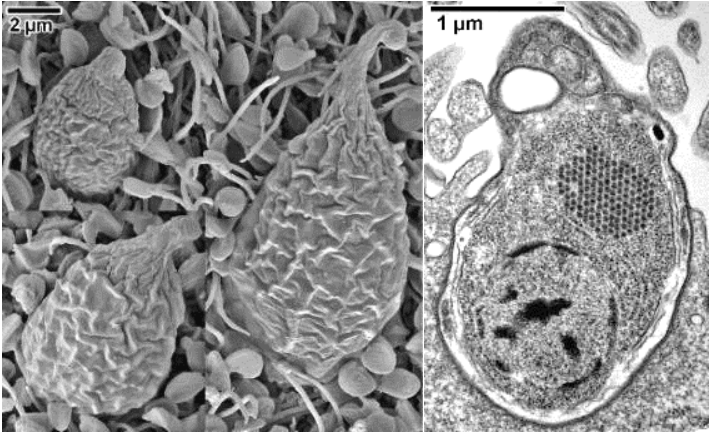
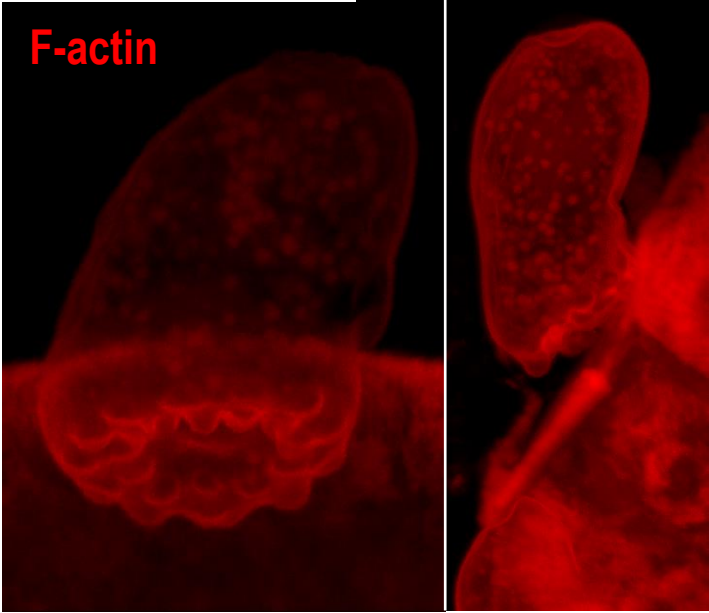Protococcidiorida

- *incertae sedis* Apicomplexa reported from polychaetes
- life cycle of protococcidia not completely understood
- epicellular within parasitophorous sac at the brush border of host enterocytes
- apical complex detected only at sporozoite stage
- trophozoites and gamonts appear nonmotile

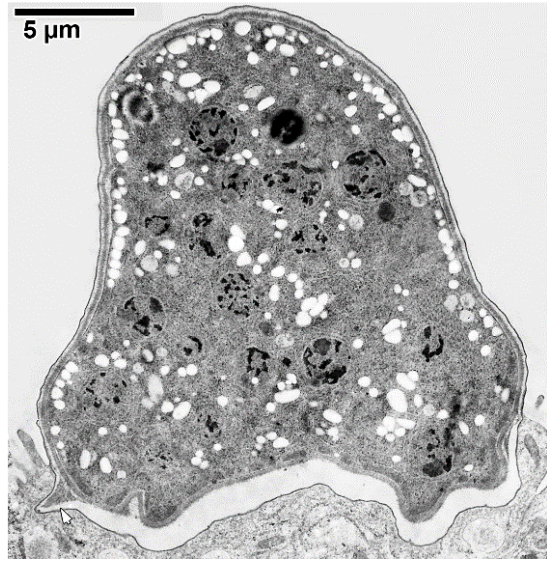
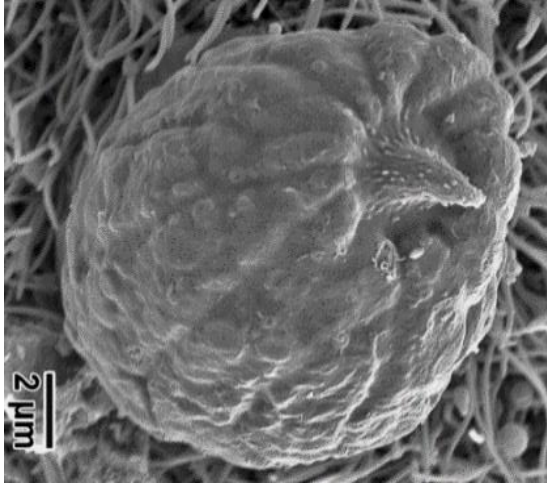
Eleutheroschizon duboscqi



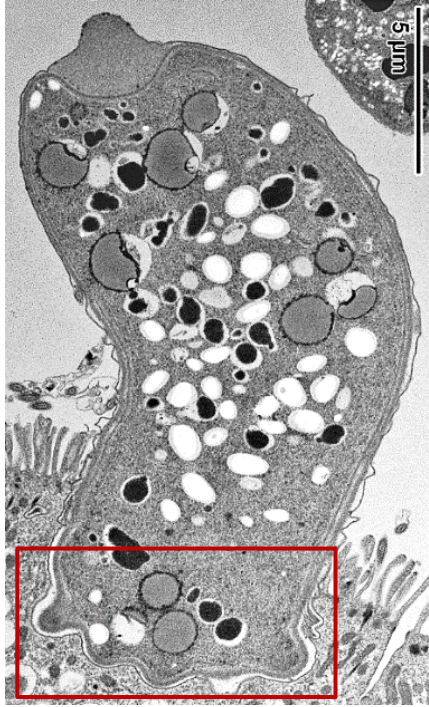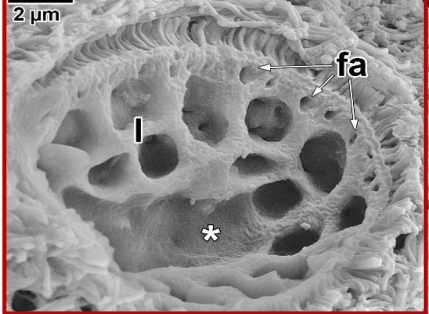
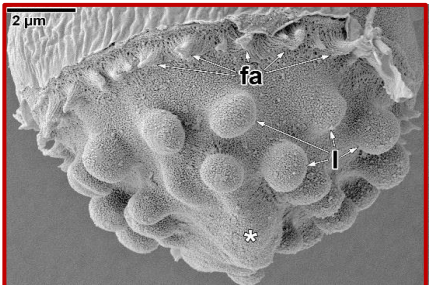
Epicellular niche of *Eleutheroschizon duboscqi*



young trophozoite



microgamont



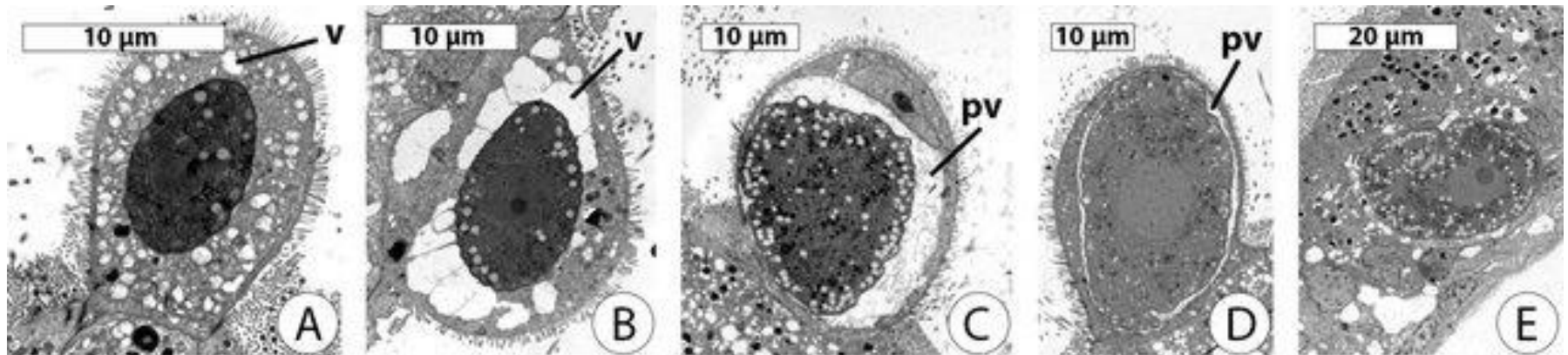
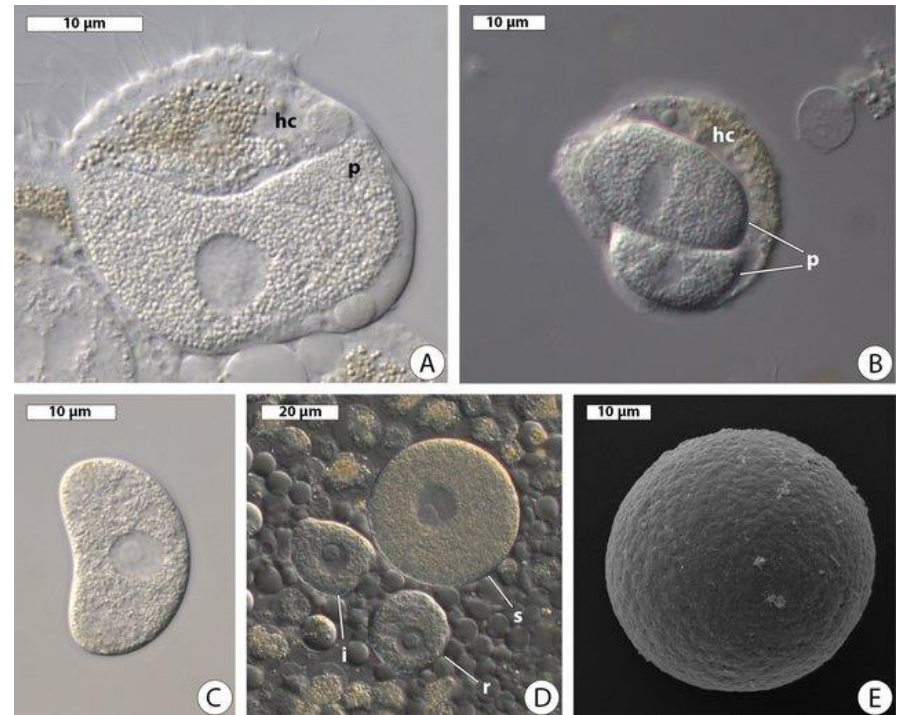macrogamont

Agamococcidiorida

<https://doi.org/10.1038/s41598-020-72287-x>

- agamococcidia
- *incertae sedis* Apicomplexa
- intracellular in polychaete enterocytes
- apical complex not seen in trophozoites
- trophozoites appear nonmotile
- merogony and gametogony not observed
- life cycle not known

Rhytidocystis pertsovi



Apicomplexa

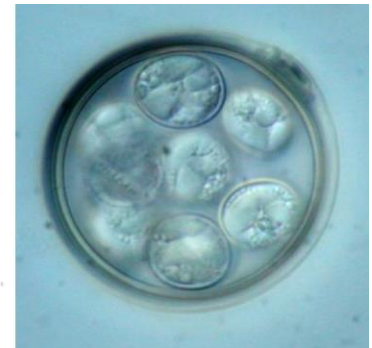
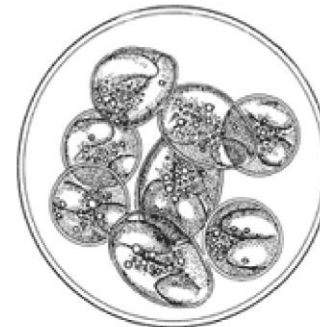Coccidia

- important parasites of humans and animals
- monoxenous or heteroxenous
- all endogenous stages are intracellular, no mucron or epimerite
- merogony, gamogony, and sporogony normally present
- mostly without syzygy - macrogamonts and microgamonts develop independently
- microgametocytes usually produce many microgametes (with 1 – 3 flagella)
- normally is zygote non-motile
- sporozoites in oocyst
- most coccidia develop resistant oocysts are passed in the faeces
 - **Adeleorina**
 - **Eimeriorina**

Apicomplexa

Adeleorina

- **monoxenous** in arthropods (often referred to as adelines) x **heteroxenous** cycling between blood-feeding invertebrates (definitive hosts) and various vertebrates (intermediate hosts), usually referred to as haemogregarines
- usually complex life cycle – 1 or more merogonies \Rightarrow gametogony \Rightarrow sporogony
- meronts often of morphologically distinct types: 1) meront producing large merozoites that initiate another round of merogony, 2) meront producing smaller merozoites that represent the gamonts progenitors
- microgamonts produce 1-4 microgametes that associate with macrogamete in syzygy
- endodyogony absent, sporozoites in sporocysts and/or oocysts

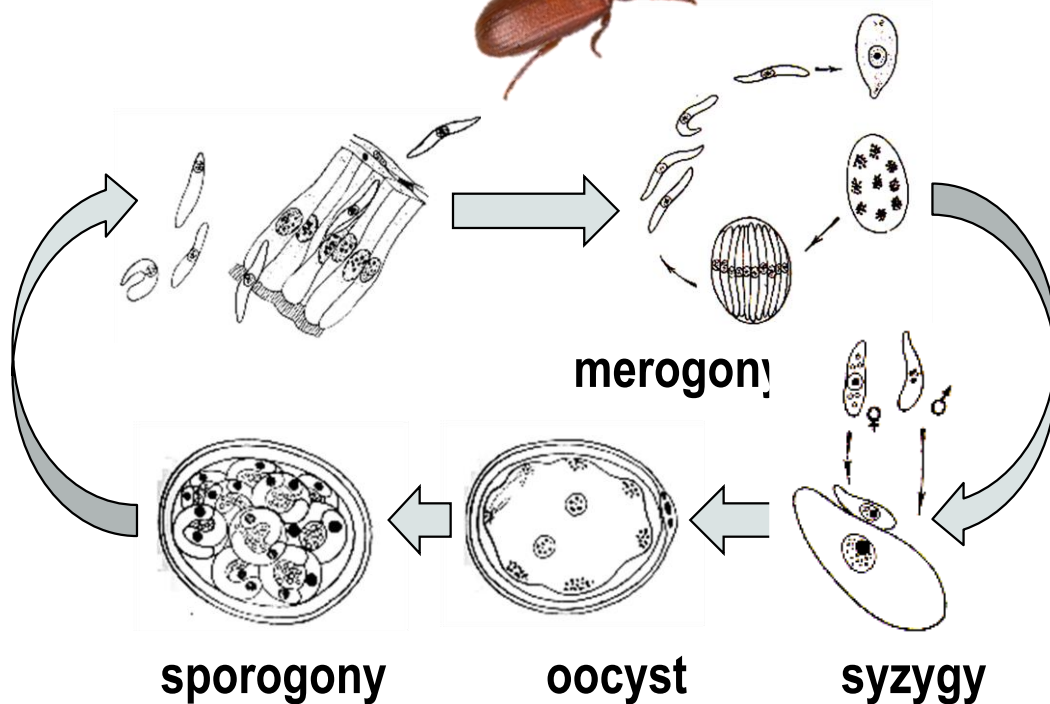


Apicomplexa

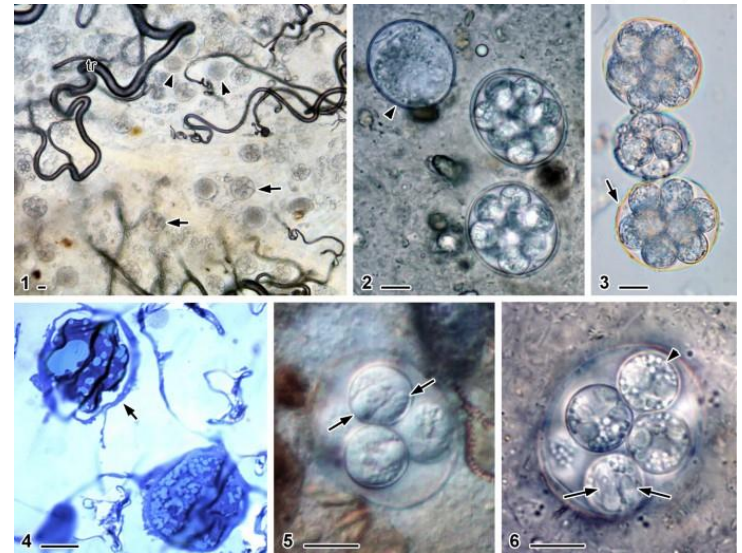
Monoxenous adelines

- e.g. *Adelina* and *Adelea* from insects, *Klossia* from kidney of molluscs, *Klossiella* from kidney of vertebrates, ...

Adelina tribolli



Adelina melolonthae



Apicomplexa

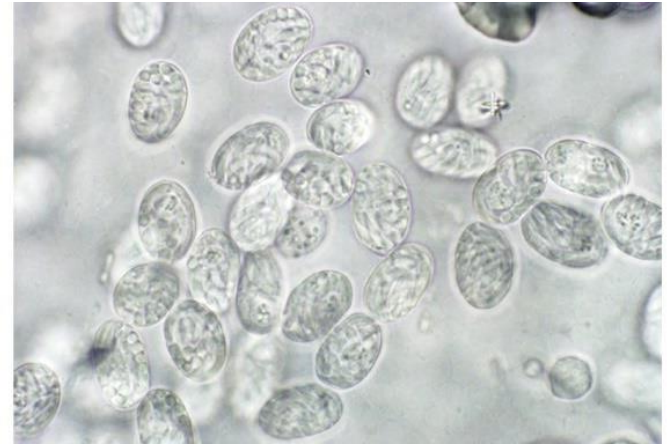
Monoxenous adelines

Klossia helicina

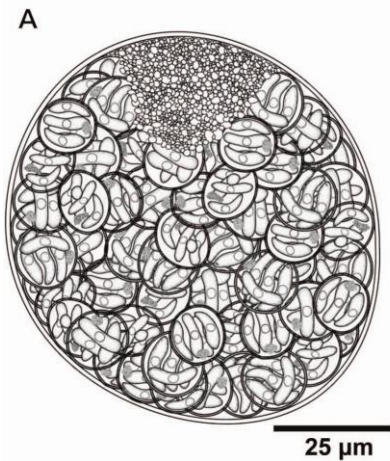
Klossia razorbacki



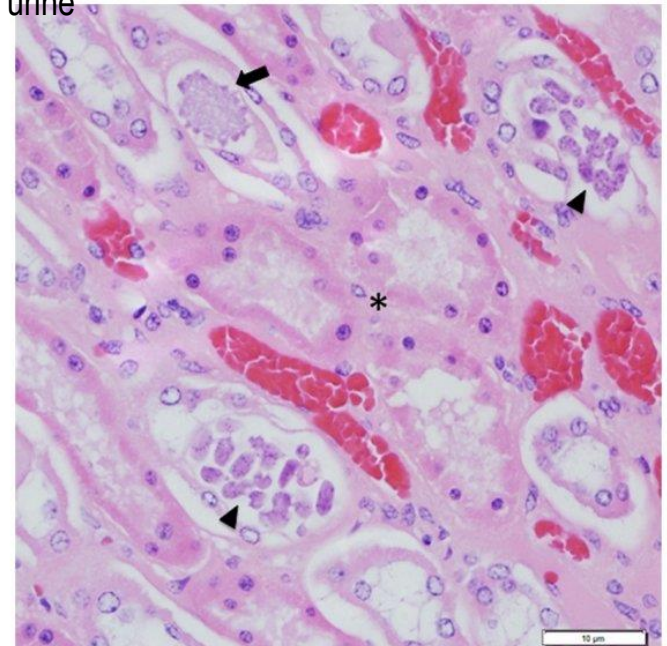

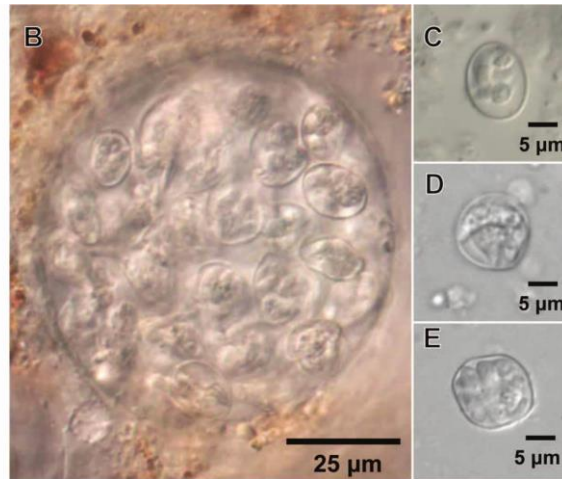
Klossiella equi



Sporocysts found on centrifugal flotation of horse urine



Polysporocystic oocysts from kidney of *Triodopsis hopetonensis*



K. equi multifocally expanding tubular epithelial cells (schizont - arrow; sporocysts - arrowheads)

Apicomplexa

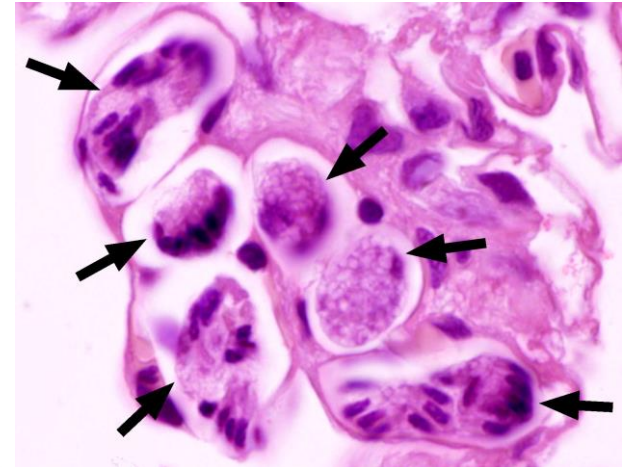
Heteroxenous haemogregarines

- Hepatozoidae, Haemogregarinidae and Dactylosomatidae comprising several genera, including pathogens of vertebrates:
 - ***Hepatozoon*** from carnivores and reptiles
 - ***Haemogregarina*** from fish and turtles
 - ***Dactylosoma*** from fish or amphibian (possibly also reptiles)
- in all of them, invertebrate plays role of the definitive host with gamogony in its digestive tract, and parasite transmission occurs in 2 modes:
 - 1) **inoculation** - infectious sporozoites enter the vertebrate host during blood feeding of vector (*Haemogregarina*, *Dactylosoma*)
 - 2) **ingestion** of infected definitive (invertebrate) host by vertebrate host – may involve a paratenic host when the next definitive host is infected exclusively via blood feeding (*Hepatozoon*, *Haemolivia*, *Karyolyssus*)

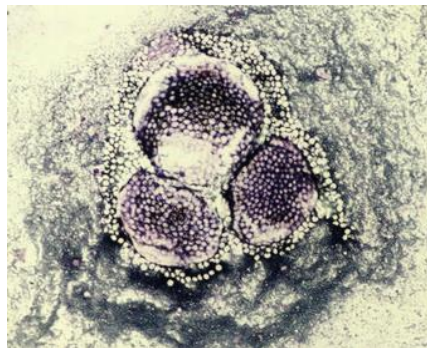
Apicomplexa

genus *Hepatozoon*

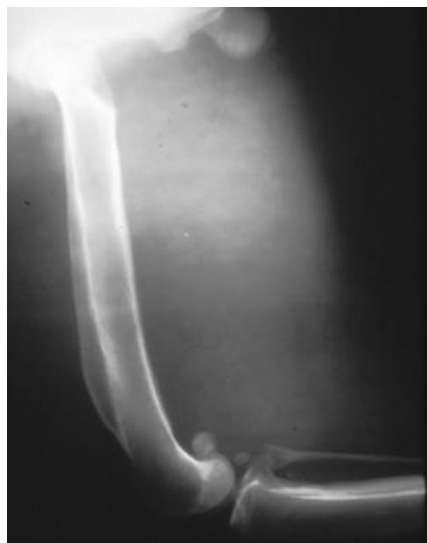- more than 300 species
- sporogony in invertebrate host \Rightarrow oocysts with large number of sporocysts with sporozoites
- sporozoites in liver of the vertebrate host (asexual reproduction) \Rightarrow merozoites
- merozoites in bloodstream \Rightarrow gametocytes = conspicuous organisms in erythrocytes / lymphocytes
- sexual reproduction in haemocoel of invertebrate host
- **hepatozoonosis** – when animal eats the invertebrate host (e.g. tick, disease is not spread by tick bites!), infection may cause polyostotic aggressive lesions



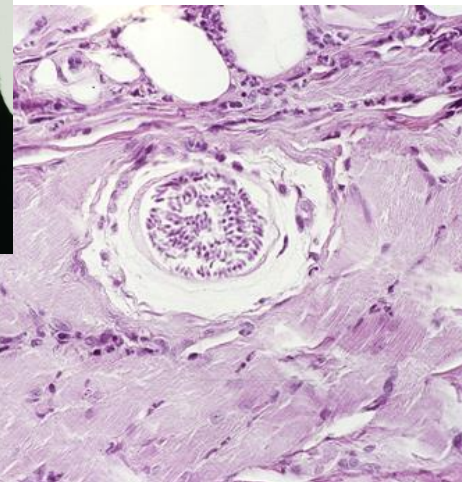

Hepatozoon americanum



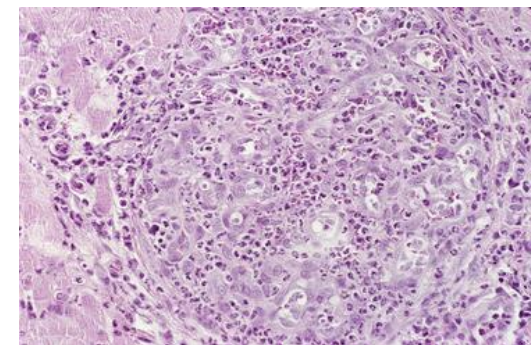
Oocysts in hemocoel of *Amblyomma maculatum* tick, each oocyst with hundreds of small round sporozoites containing 10-6 sporozoites.



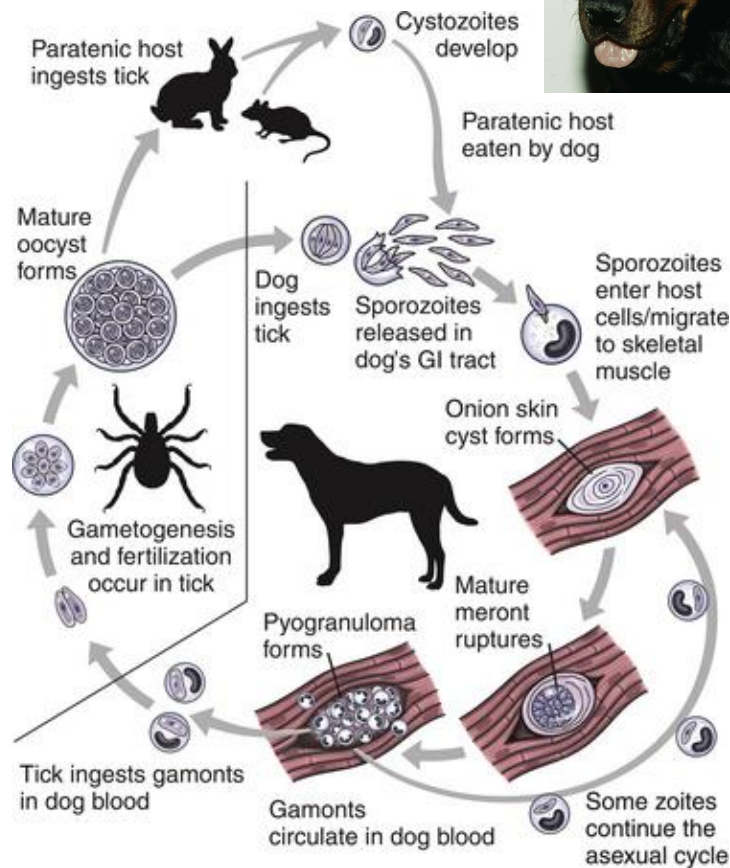
Pelvic limb of infected dog showing smooth periosteal proliferation on the cranial aspect of the femur.



Skeletal muscle containing a developing meront, mucopolysaccharide layers produced by host cell protect the developing organisms from the dog's immune system

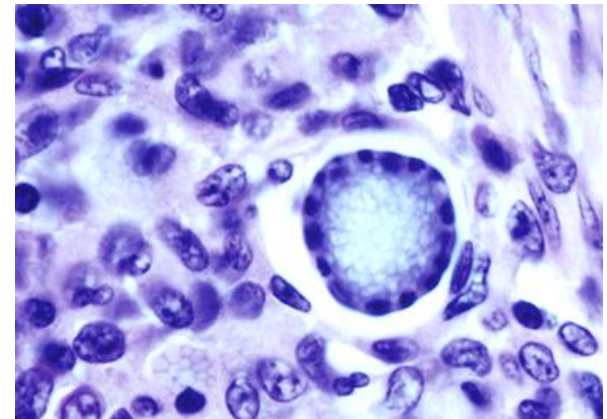
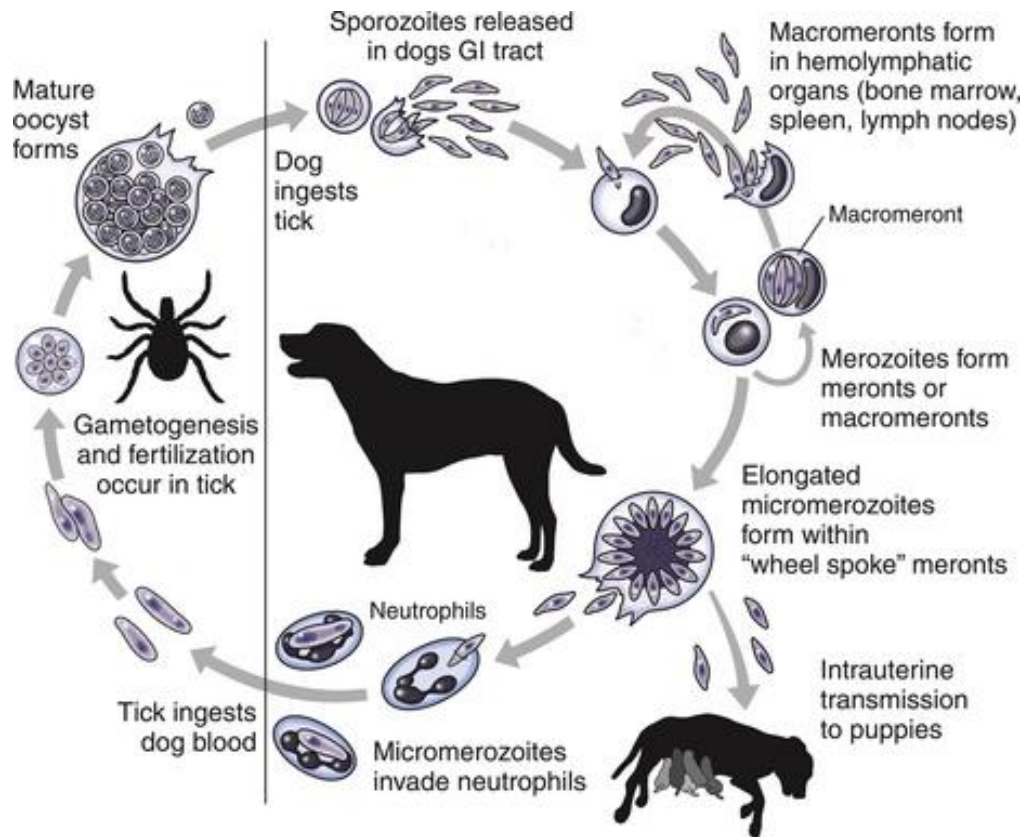


Pyogranuloma in skeletal muscle of an infected dog, zites displace the nucleus in several of the inflammatory cells

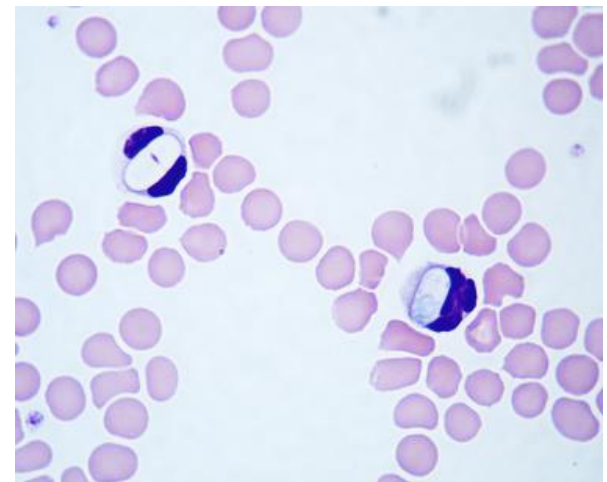


Moderate to severe illness: fever, lethargy, ↓ appetite, weight loss, muscle pain/weakness, reluctance to move, discharge from the eyes/nose, enlarged lymph nodes. Periods of illness and apparent resolution; without treatment ⇒ damage to the blood vessels and kidneys often with death within 1 year.

Hepatozoon canis



Meront in splenic tissue of a dog demonstrating the typical "wheel spoke" pattern

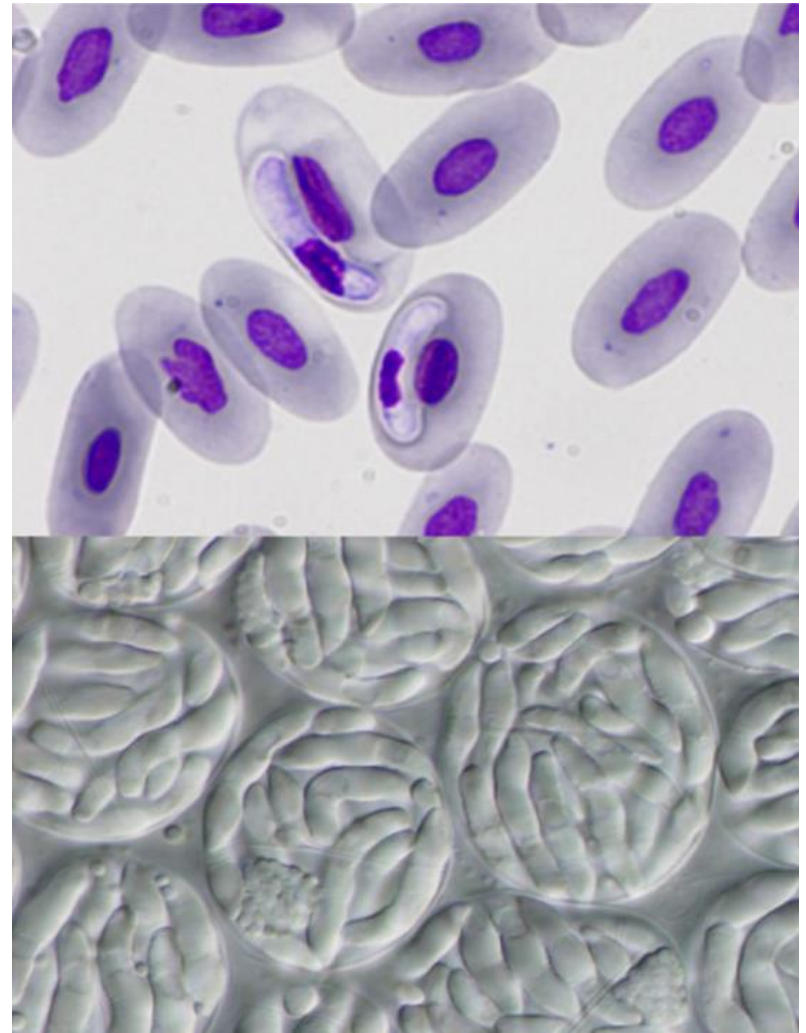
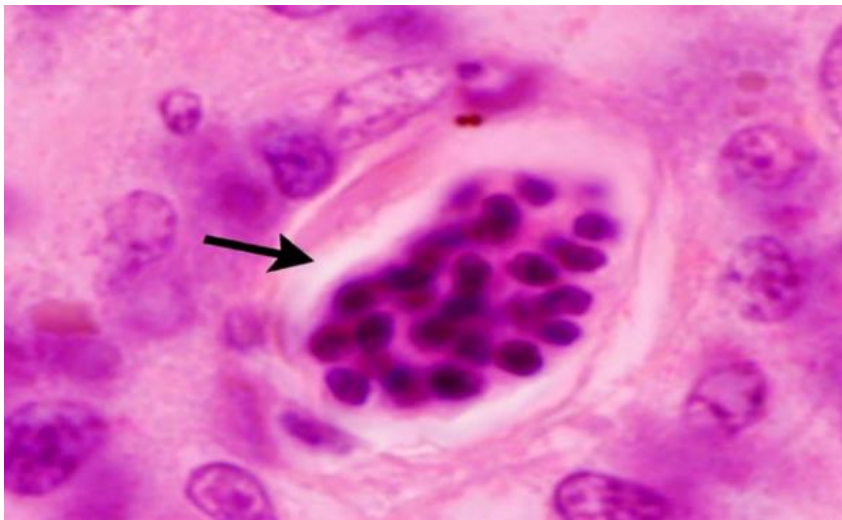


Gamonts in neutrophils on a blood smear

- most dogs infected show **no or only mild signs of illness**: fever, weight loss, lethargy, anaemia, enlarged spleen
- in some dogs with high parasite numbers, the disease can become more severe and may be potentially life-threatening
- immunosuppression or concurrent disease is an important factor in expression of illness in *H. canis* (but not in *H. americanum*)

Hepatozoon ayorgbor

- African *Python regius*
- merogony in liver and spleen, gametocytes in erythrocytes
- transmitted by *Culex quinquefasciatus*
- rodents as a reservoir



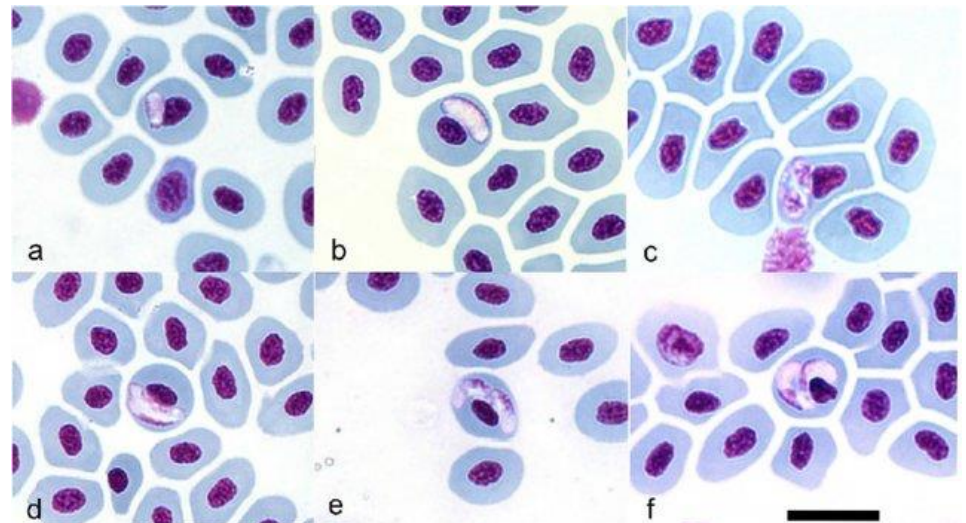
Apicomplexa

genus *Haemogregarina*

- infected leech feeding on a reptile or amphibian injects sporozoites into the bloodstream where they enter erythrocytes \Rightarrow trophozoites
- erythrocytes with trophozoites lodge in the capillaries of the bone marrow \Rightarrow macromeronts \Rightarrow merozoites infect new erythrocytes \Rightarrow micro-/macrogametocytes
- fusions of gametes \Rightarrow oocyst in the gut of leech where they hatch and sporozoites migrate through the intestinal wall into the circulatory system, sporozoites ending up in the proboscis are injected into the next host

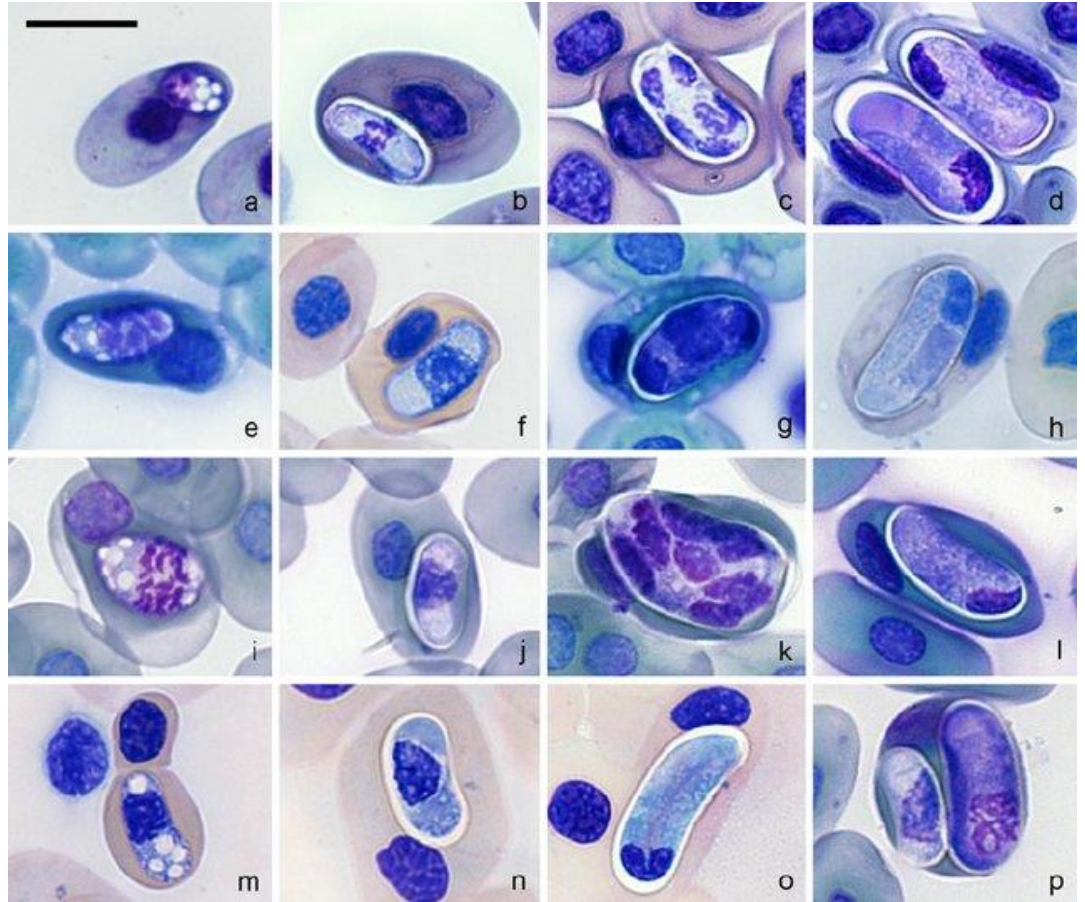
Haemogregarina bigemina

- ectoparasitic gnathiid isopods likely serve as vectors



Haemogregarina stepanowi

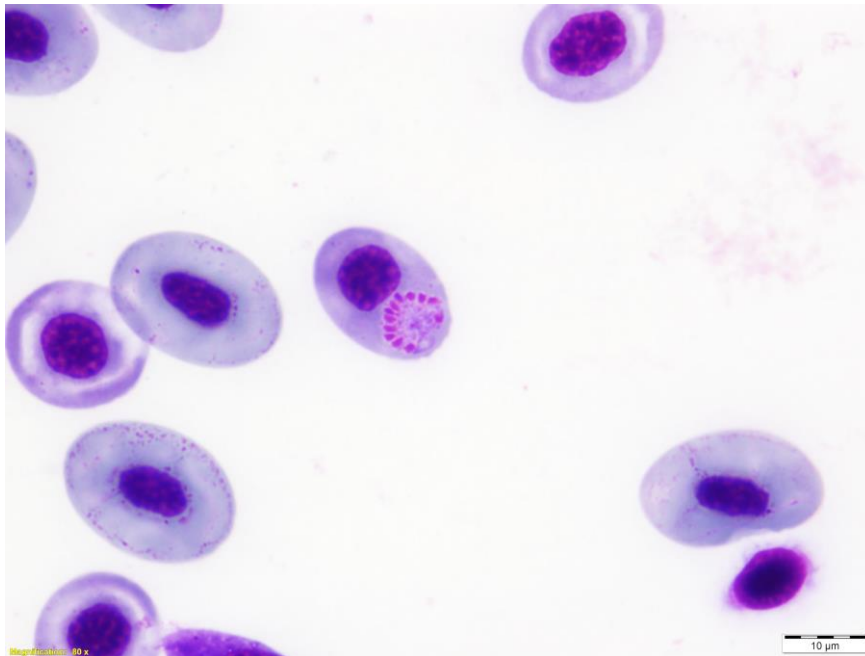
- turtle *Emys orbicularis* (not only)
- transmitted by leeches



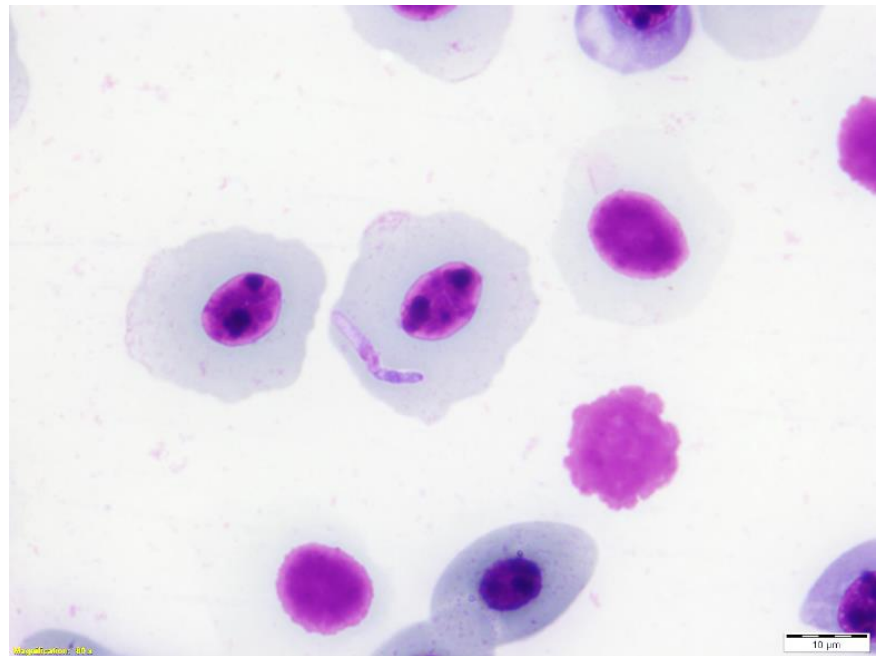
genus *Dactylosma*



- amphibians, fish
- transmitted by leeches and possibly mosquitos



Blood smear from *Pelophylax* frog with merogony (primary meront)

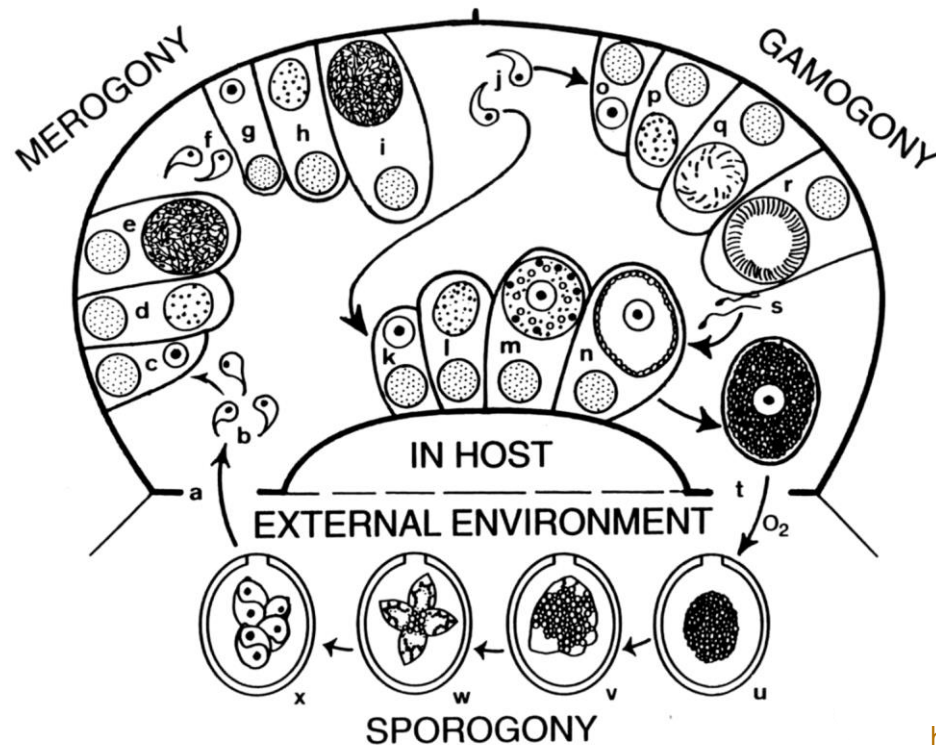


Blood smear from *Pelophylax* frog with gamont

Apicomplexa

Eimeriorina

- homoxenous or heteroxenous life cycles
- syzygy is absent - macrogametes and microgametes develop independently
- anisogamous microgamonts produce a large number of flagellated microgametes
- zygote is nonmotile, sporozoites enclosed in a sporocyst



Sporulation in coccidia

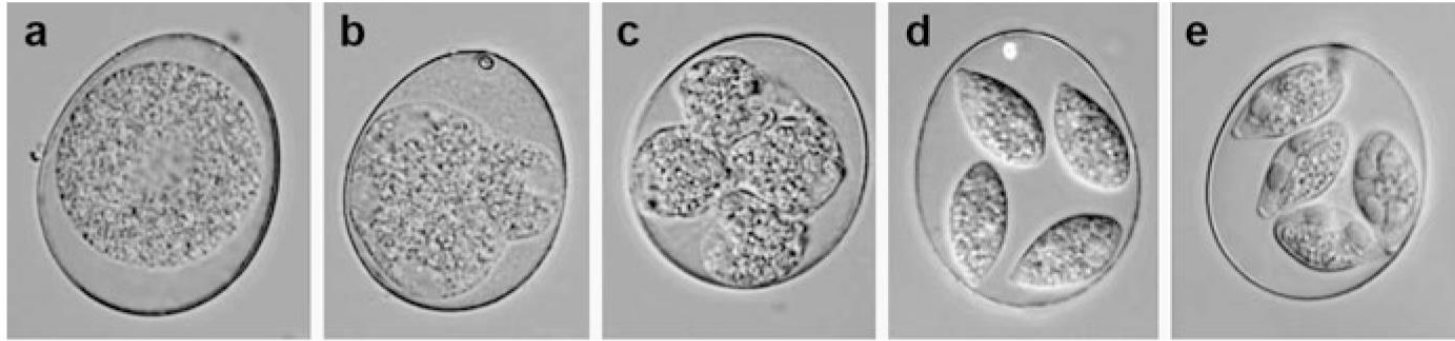
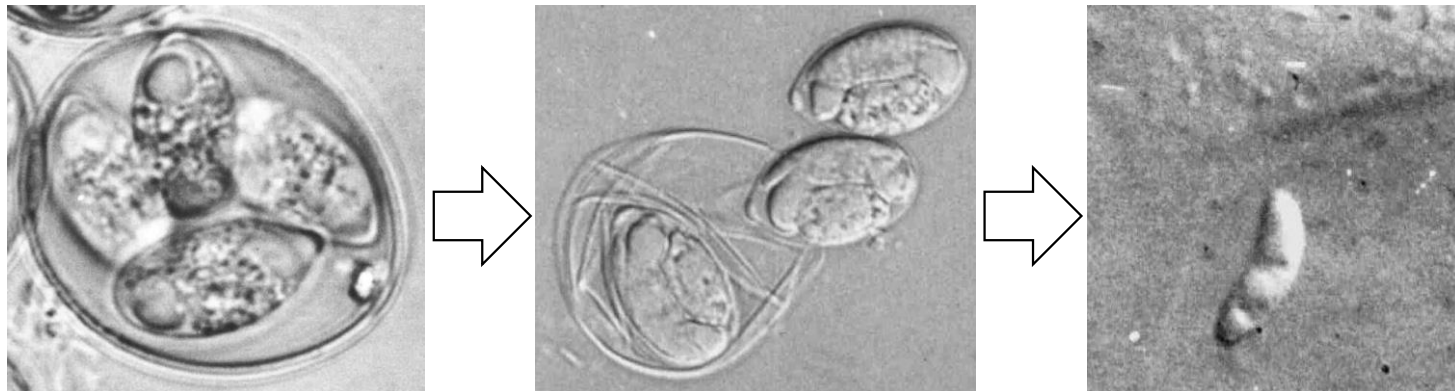

Fig. 7 Sporulation of *Eimeria maxima* from the intestine of a chicken. Unsporulated oocysts are shed with feces into the environment (a). When exposed to oxygen in an environment of appropriate humidity and suitable temperature, they undergo sporulation (it takes about 48 h at 25 °C before they become infectious). Upon asexual division through four sporoblasts (b, c), four sporocysts are formed initially full of granular material (d) that during sporulation wanes, until mature infectious sporozoites with remaining sporocyst residuum appear (e); note also process of formation of prominent Stieda bodies on poles of sporocysts (d, e)

Excystation of coccidian oocyst



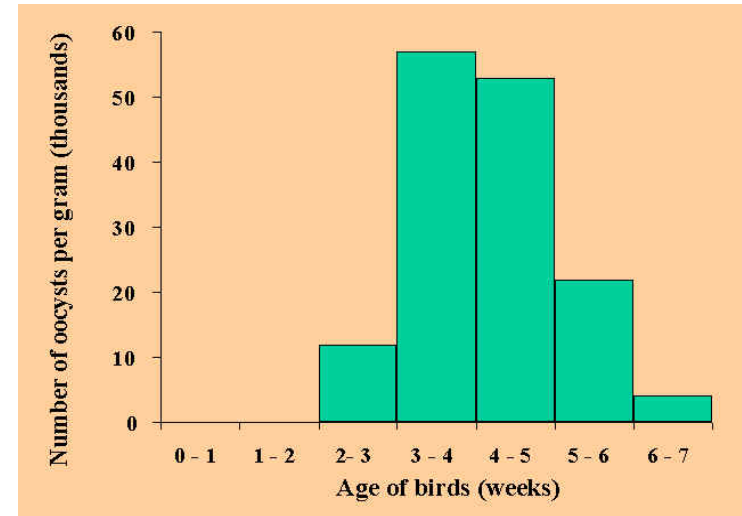
Factors affecting the significance of individual coccidian species

Factors affecting the host

- ✓ "technology" of animal breeding
- ✓ host immunity (age category)
- ✓ nutrition, other diseases

Factors of individual species of coccidia

- ✓ pre-patent period
- ✓ patent period
- ✓ number of merogonies
- ✓ size of developmental stages
- ✓ sporulation time
- ✓ extraintestinal development



Chicken coccidiosis (vaccination available)

<https://www.youtube.com/watch?v=NFh2aPmuYQE>

<https://www.youtube.com/watch?v=HnVCmZUoork>

https://www.youtube.com/watch?v=u1ilZQrB_B4

Taxonomy of coccidia

Eimeriorina

Eimeriidae - monoxenous

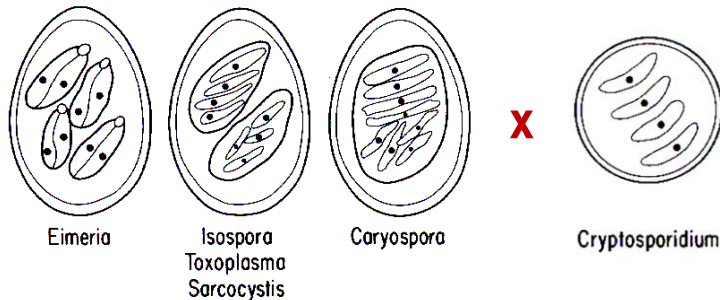
Eimeria (4-2)

Isospora (2-4)

Caryospora (1-8)

Tyzzeria (0-8)

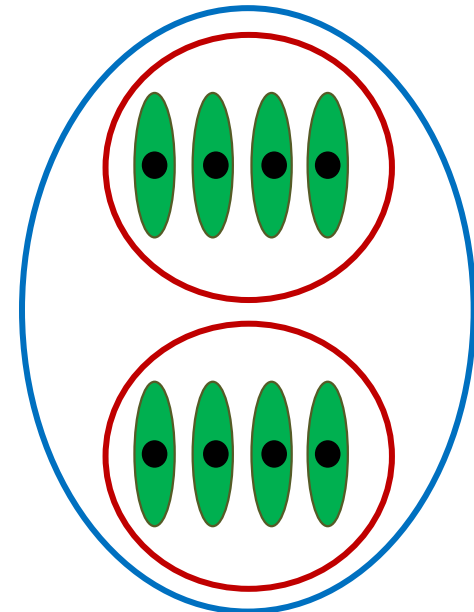
Wenyonella (4-4)...



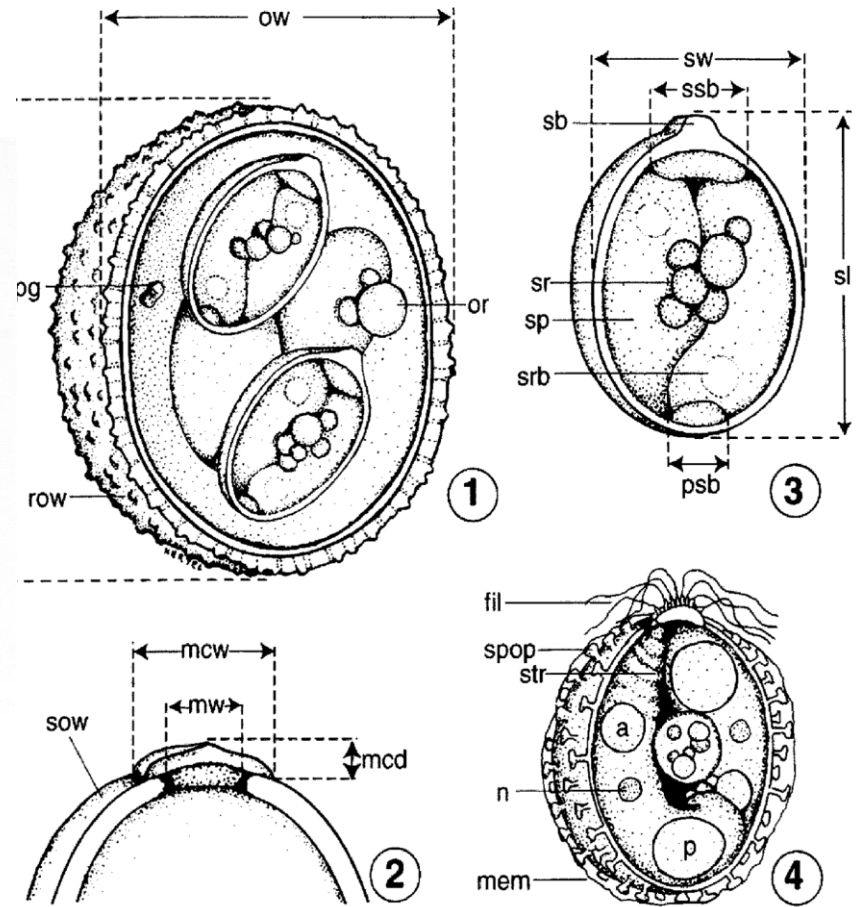
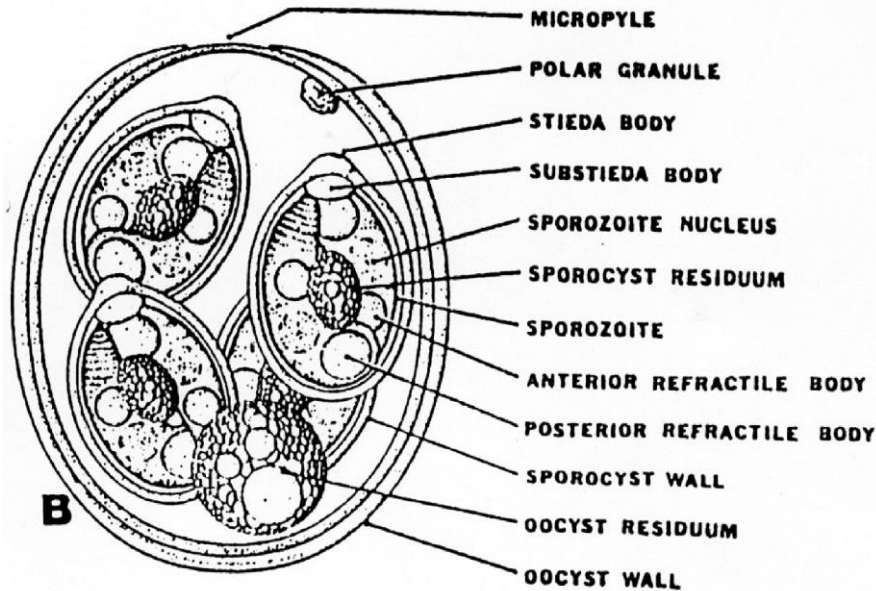
Sarcocystidae - heteroxenous

Sporocysts: 2

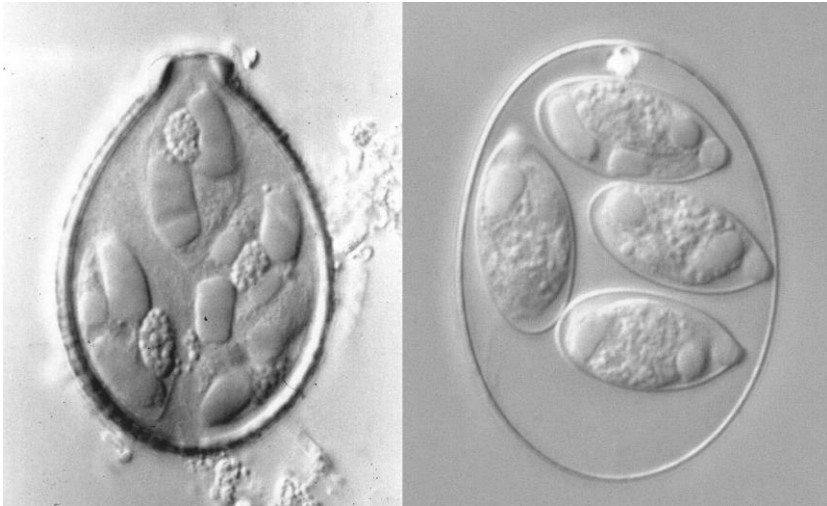
Sporozoites: 8



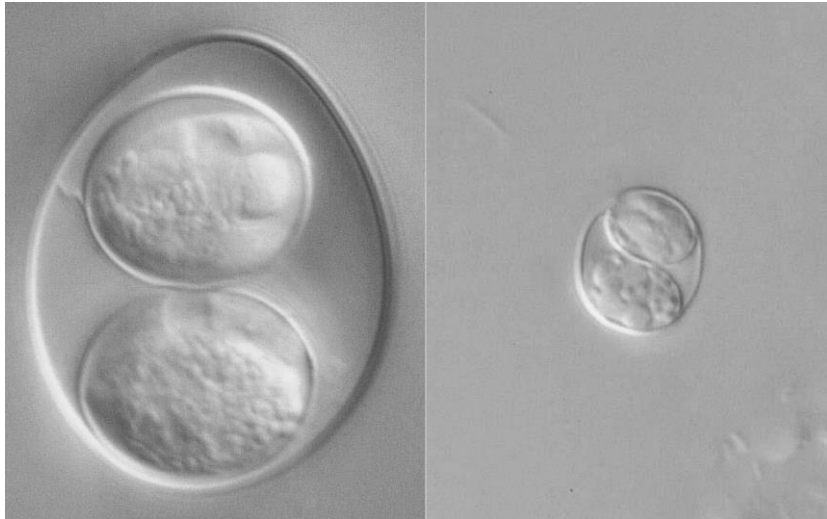Morphology of coccidian oocyst



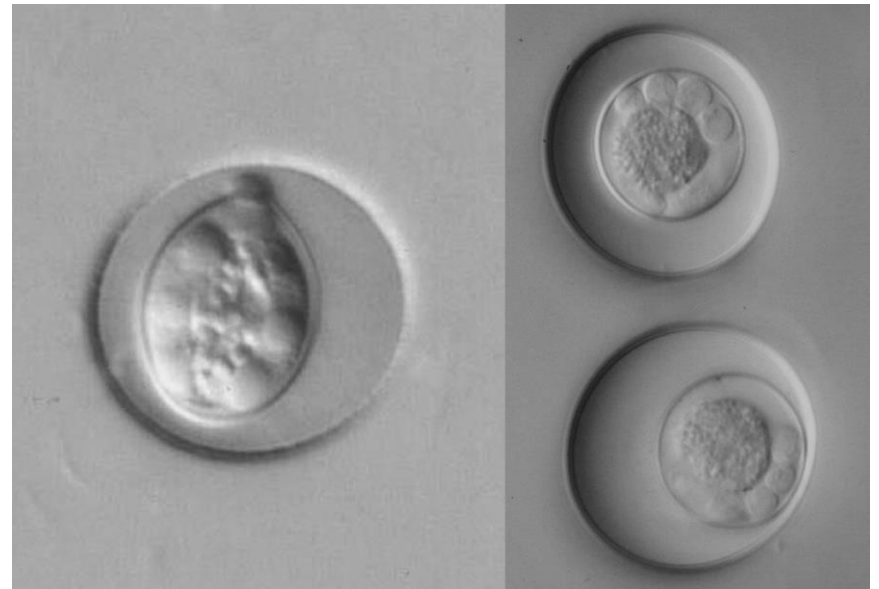
Oocyst of *Eimeria*



Oocyst of *Isospora*



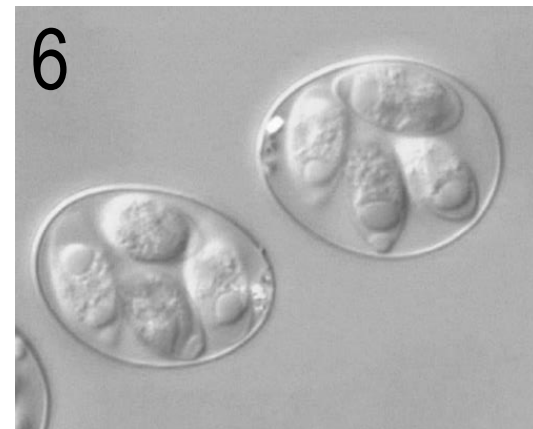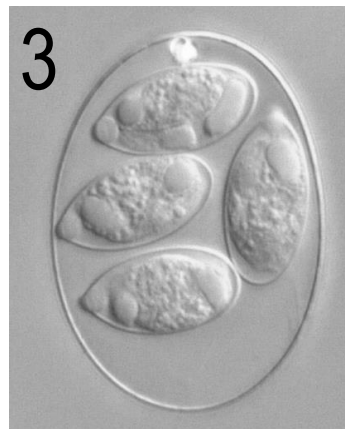
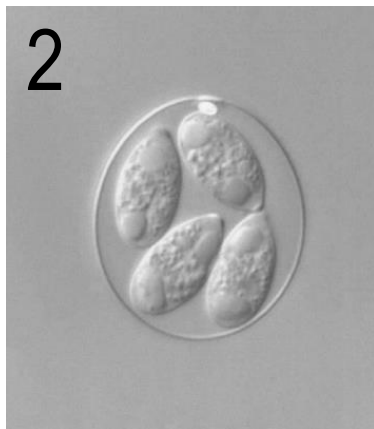Oocyst of *Caryospora*



Coccidia in poultry

9(7) *Eimeria* species - „pathogenicity top-ten“

1. *Eimeria necatrix* - small intestine
2. *Eimeria tenella* - ceca
3. *Eimeria maxima* - small intestine
4. *Eimeria brunetti* - small intestine, ceca, rectum
5. *Eimeria mitis* - small intestine, ceca, rectum
6. *Eimeria acervulina* (*E. mivati* ??) - duodenum
7. *Eimeria praecox* (*E. hagani* ??) - duodenum



Localisation of developmental cycle and pathological changes in the intestine

E. tenella



E. necatrix



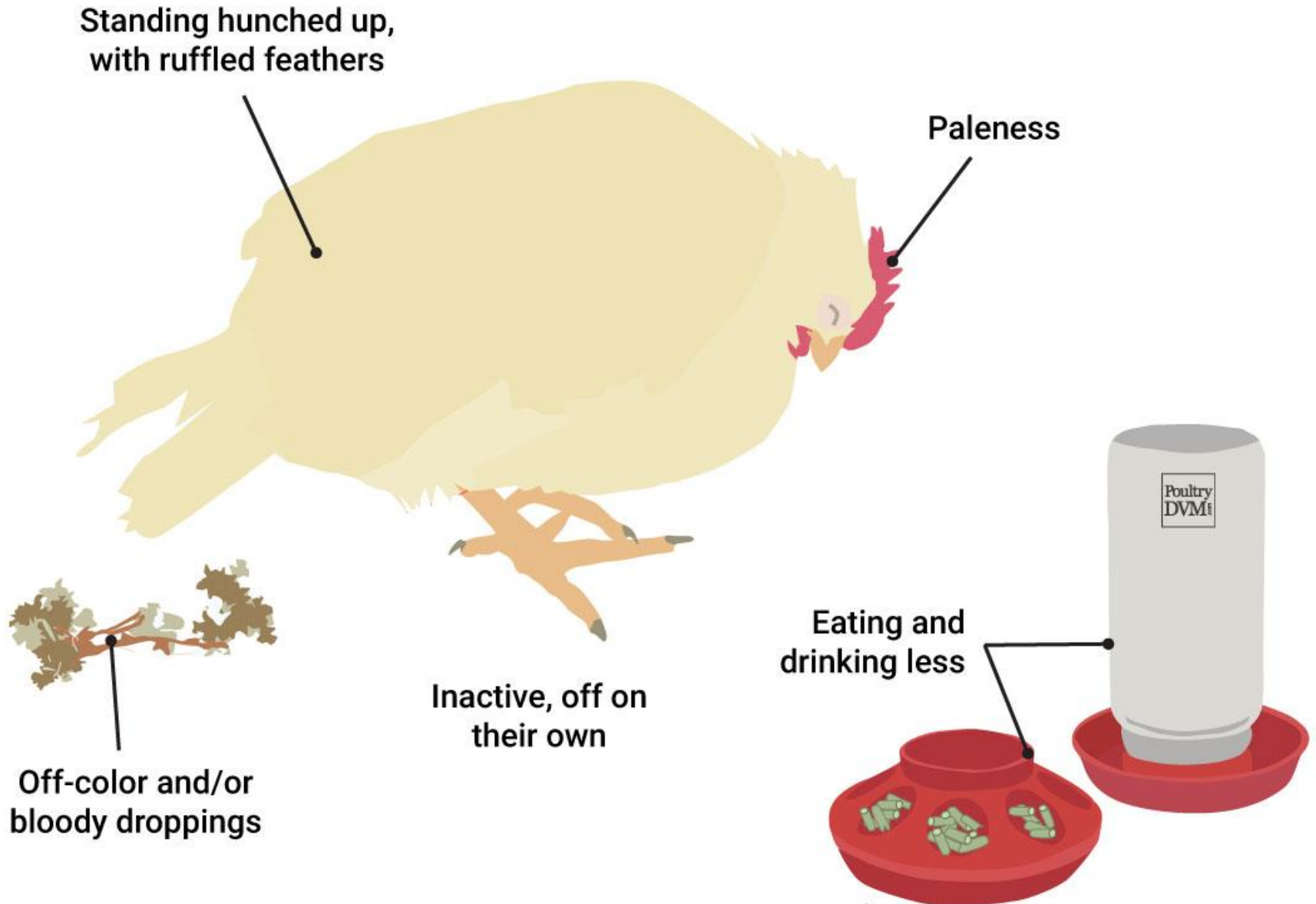
E. acervulina



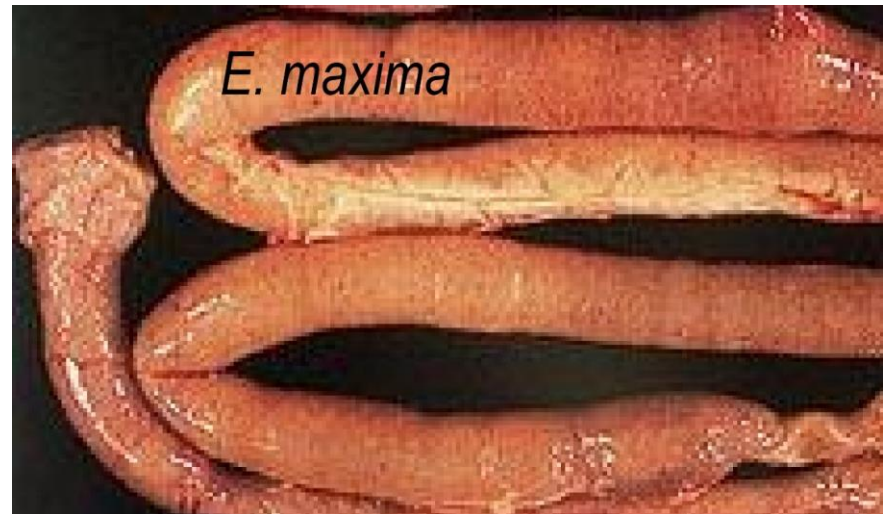
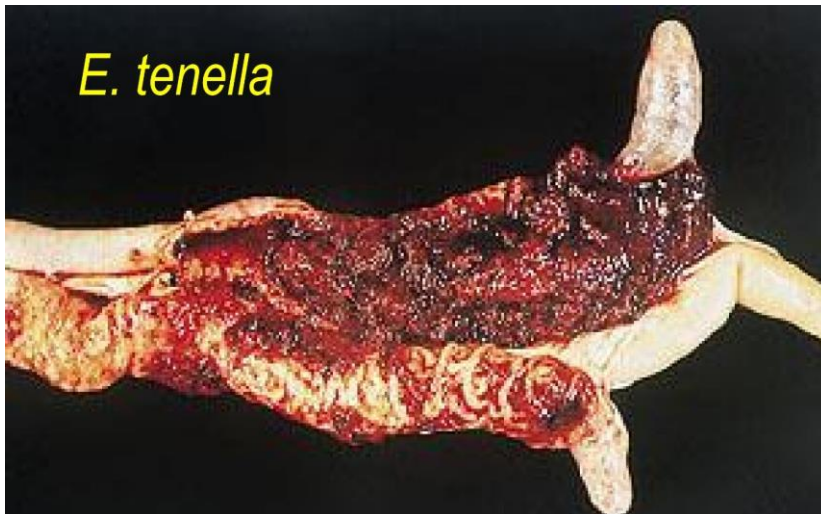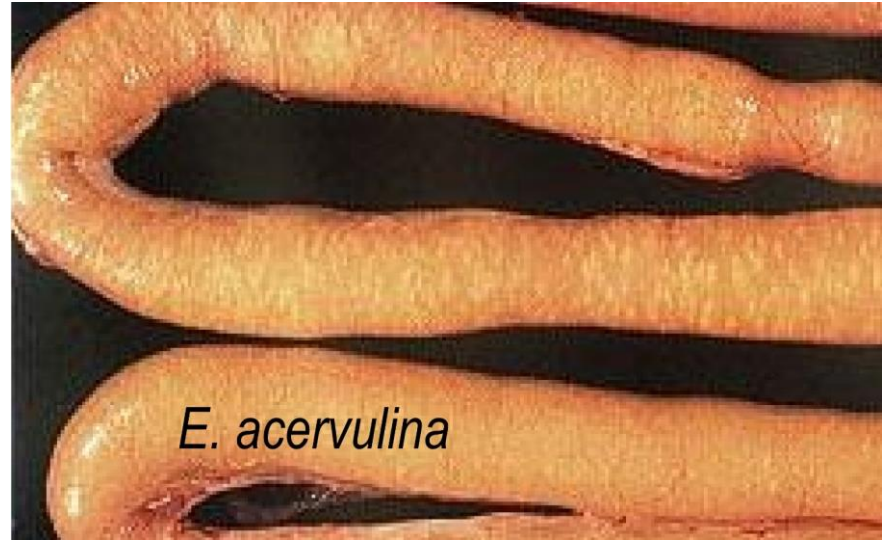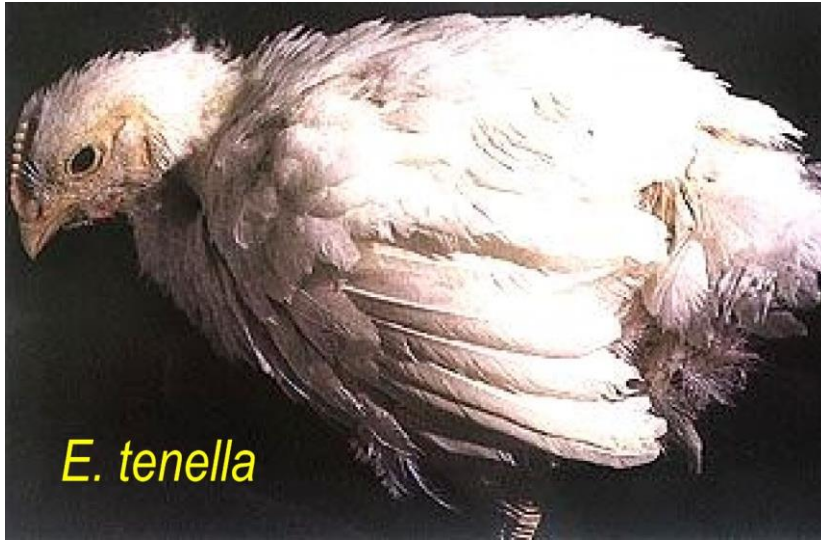E. maxima



Clinical signs of poultry coccidiosis



Pathology of poultry coccidiosis



Coccidia in rabbits

11 *Eimeria* species - „pathogenicity top-ten“

1. *Eimeria intestinalis* - jejunum, cecum, colon
2. *Eimeria flavescens* - jejunum, cecum, colon
3. *Eimeria stiedai* - liver
4. *Eimeria magna* - jejunum, cecum, colon
5. *Eimeria irresidua* - jejunum, ileum
6. *Eimeria media* - jejunum, ileum
7. *Eimeria piriformis* - jejunum, ileum
8. *Eimeria vej dovski* - jejunum, ileum
9. *Eimeria coecicola* - cecum
10. *Eimeria exigua* - ileum
11. *Eimeria perforans* - duodenum



Coccidia in rabbits

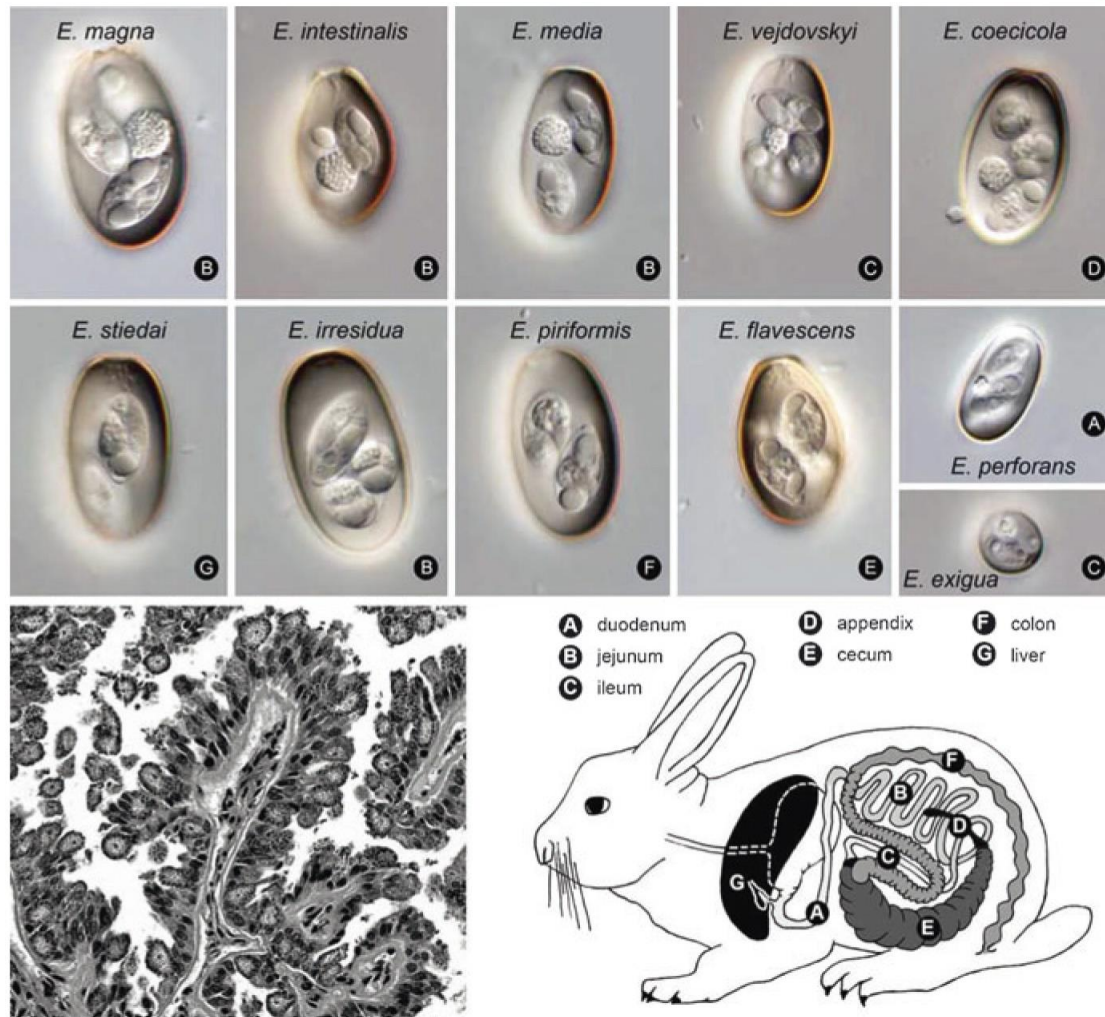


Fig. 3 Multiple *Eimeria* species infecting rabbit. Sporulated oocysts of 11 named *Eimeria* species parasitizing rabbits. Morphologically similar oocysts are distinguished by their size, shape, the presence of the micropyle, and the presence/absence and characteristic structure of the oocyst residuum. Individual species differ in the location in and pathogenicity for the host. The picture in the lower left corner shows proliferative changes in bile ducts with multiple gamogonial stages of *E. stiedae*

Coccidia in pigs

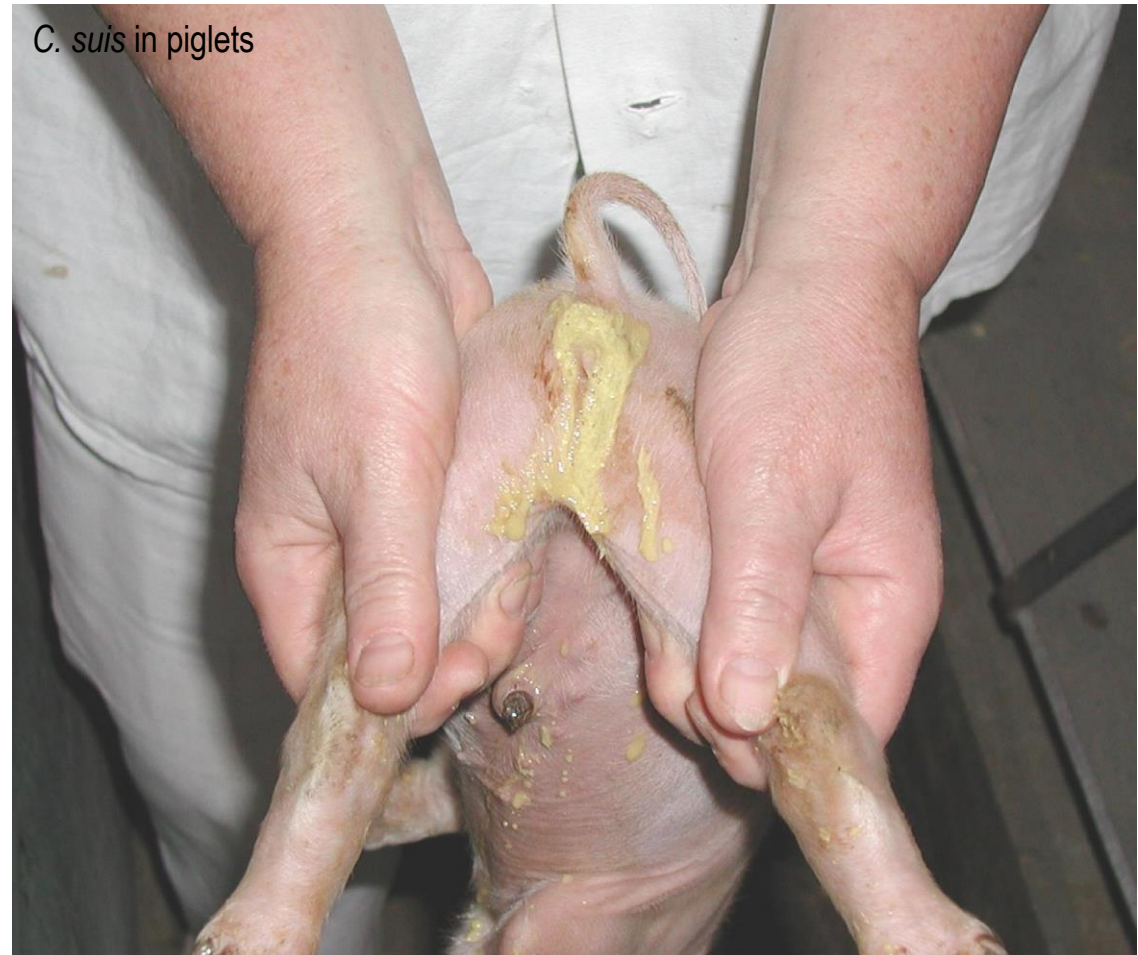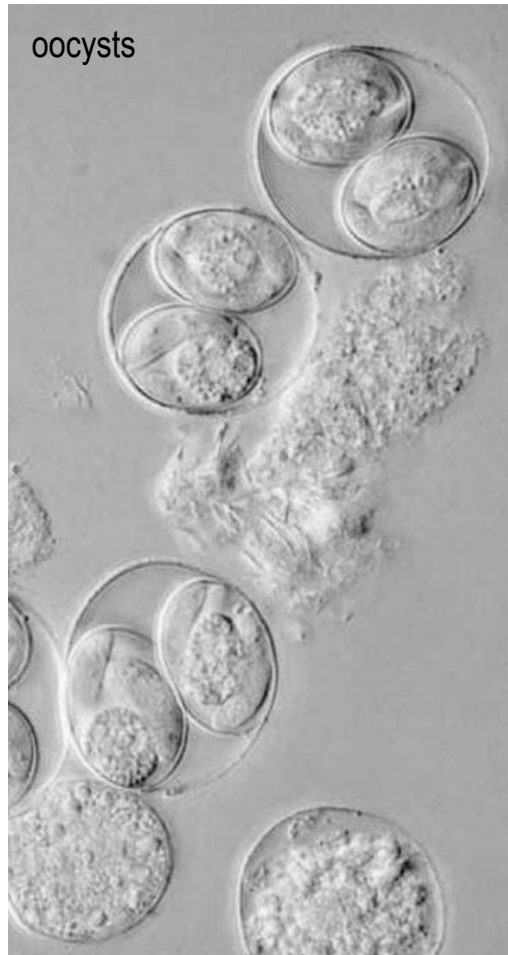7 *Eimeria* species - „pathogenicity top-ten“

1. *Eimeria scabra* - small intestine
2. *Eimeria polita* - small intestine
3. *Eimeria deblickei* - small intestine
4. *Eimeria spinosa* - small intestine
5. *Eimeria neodebliecki* - small intestine
6. *Eimeria porci* - ?
7. *Eimeria suis* - ?

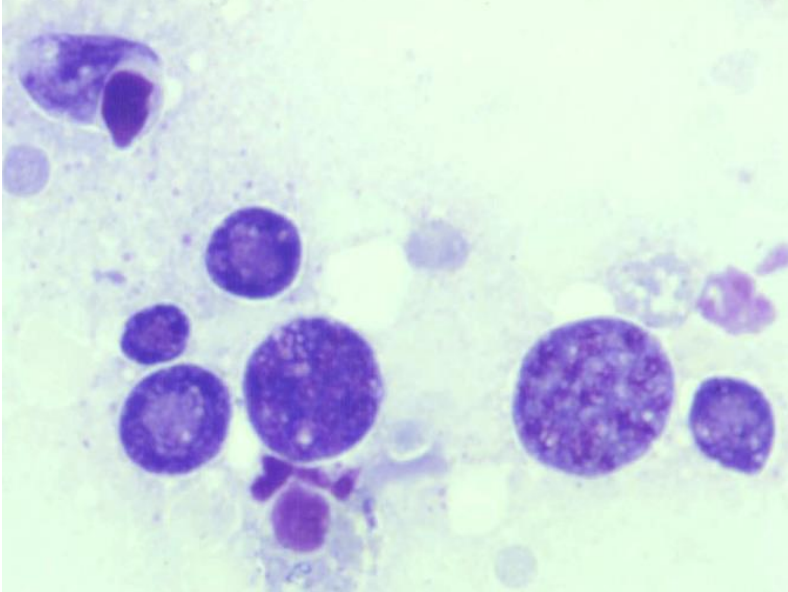
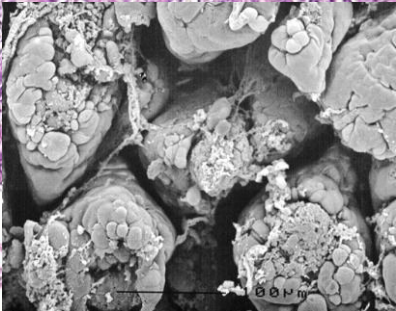
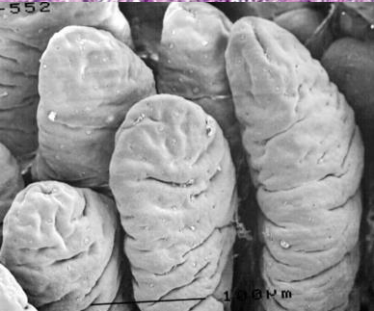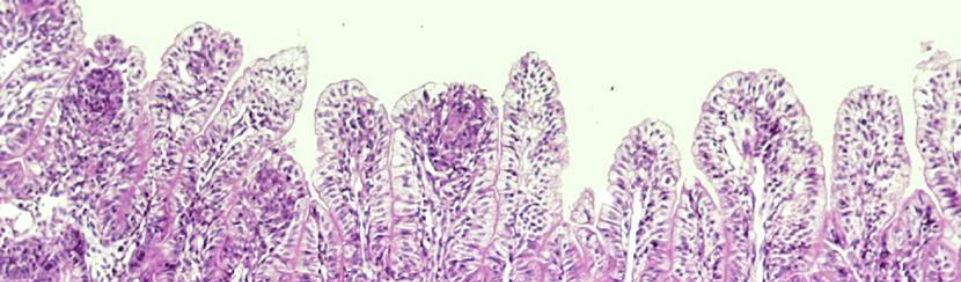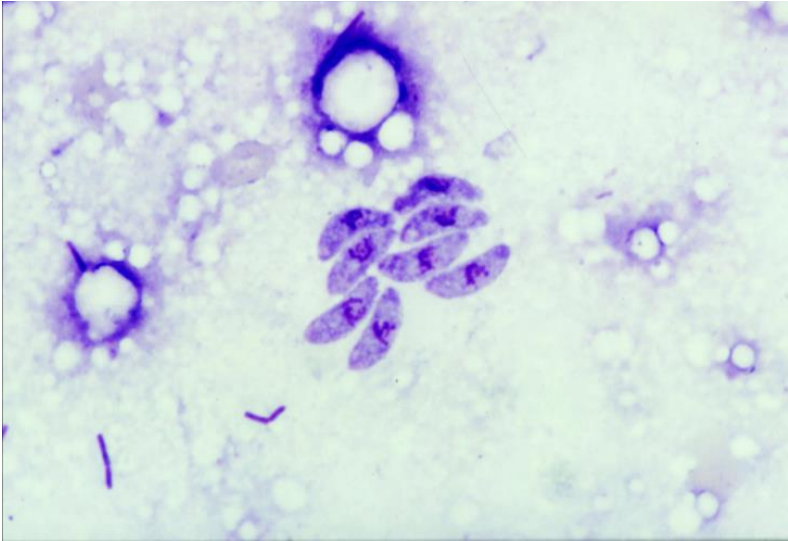
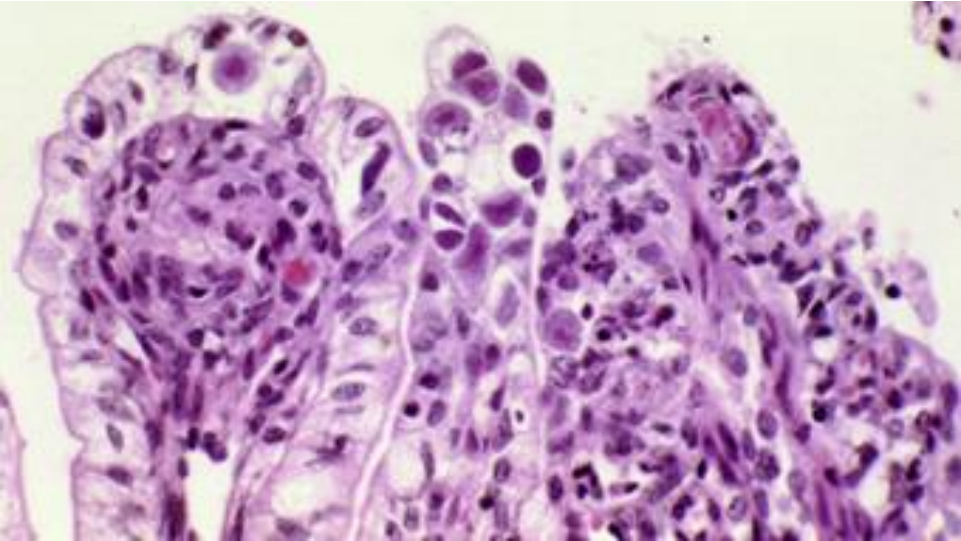


Cystoisospora suis

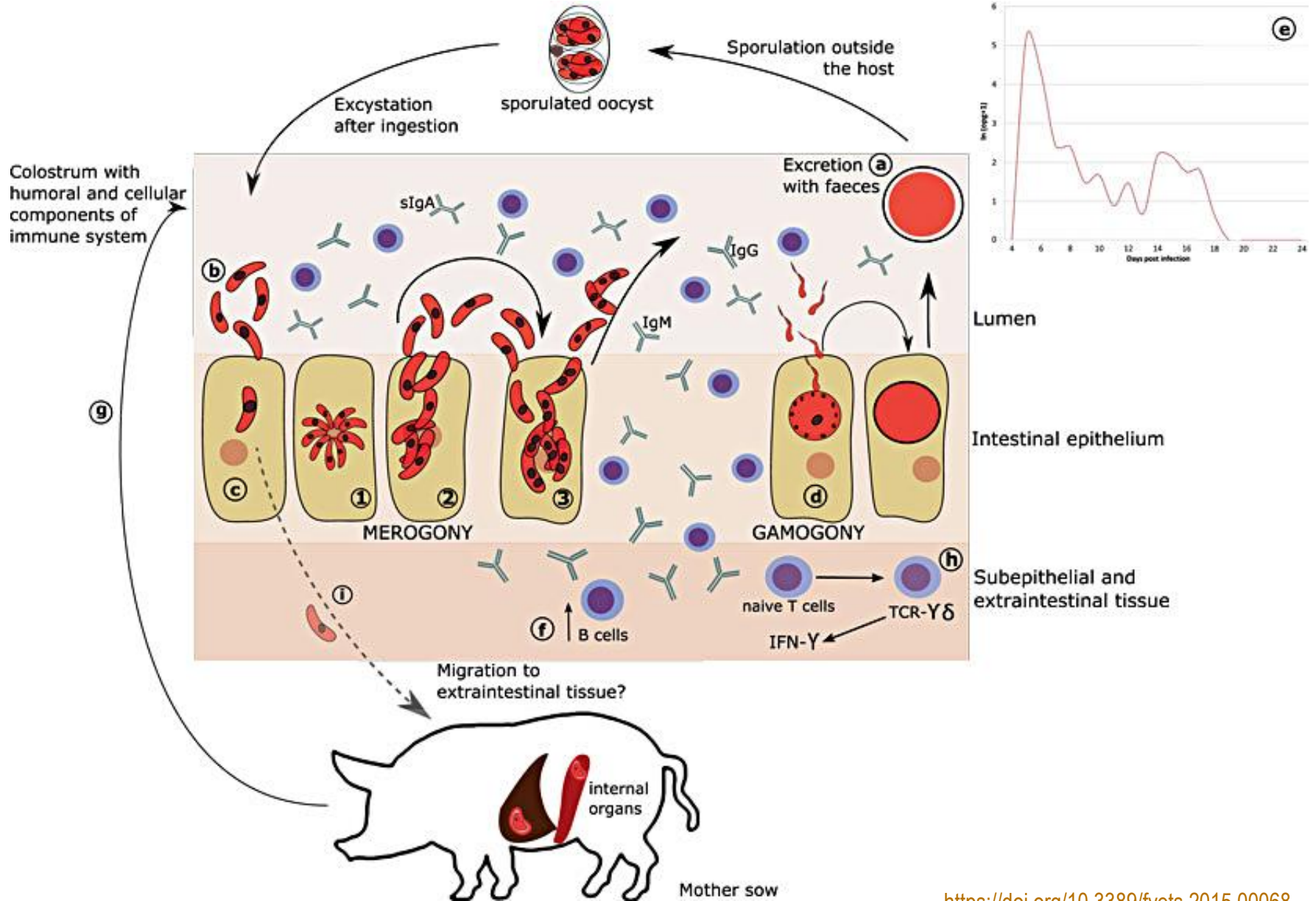
- non-haemorrhagic transient diarrhoea, resulting in poor weight gain
- it appears that primary immune responses against *C. suis* cannot readily be mounted by neonates, contributing to parasite establishment and rapid, while in older pigs, age-related resistance prevents disease development (morbidity +++++, mortality +)



Cystoisospora suis



Cystoisospora suis



Coccidia in ruminants

Cattle - 12 *Eimeria* species

Eimeria zuernii - pathogenic

Eimeria bovis - pathogenic

Both species responsible for severe clinical disease characterised by haemorrhagic diarrhoea with sometimes fatal outcome.

Eimeria alabamensis - also can cause clinical disease

Prevalence of *Eimeria* infection in cattle is generally high and can reach 100% in calves.

Eimeria ellipsoidal - bloody diarrhoea in calves and young cattle on pasture, „red dysentery of cattle,, "neurological coccidiosis"

Pathological changes in the small and large intestine - hyperaemia, haemorrhages, pseudomembranes.



Coccidia in ruminants

Sheep - 11 *Eimeria* species

Eimeria bakuensis - pathogenic

Eimeria ovinoidalis (*E. ninakohlyakimovae*) - middle pathogenicity

Eimeria crandalis - pathogenic

Eimeria ashata - pathogenic



Goat -13 *Eimeria* species

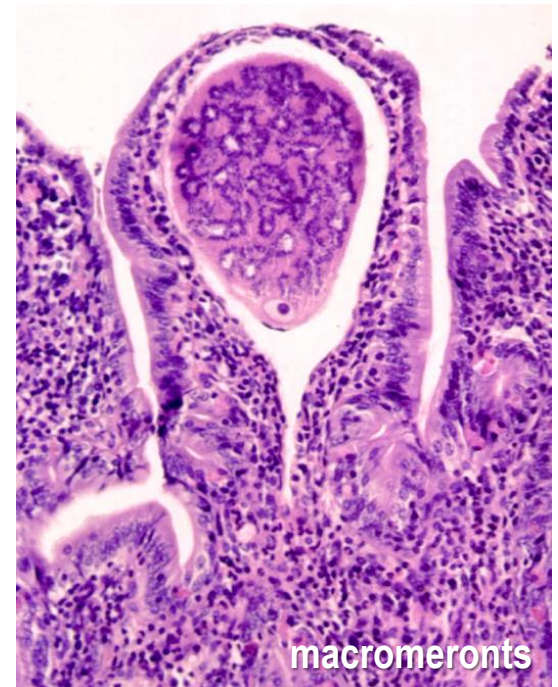
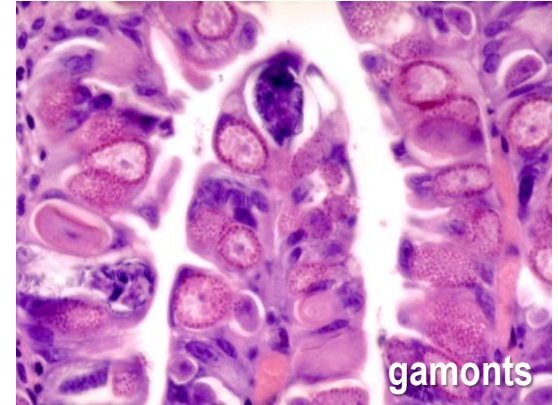
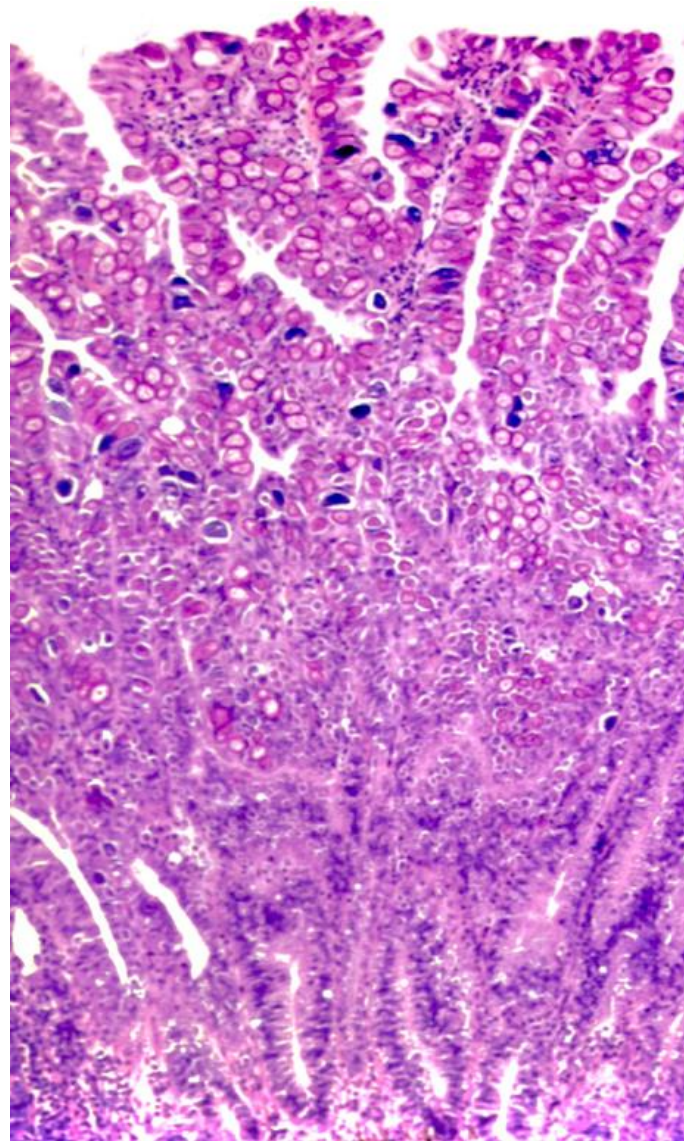
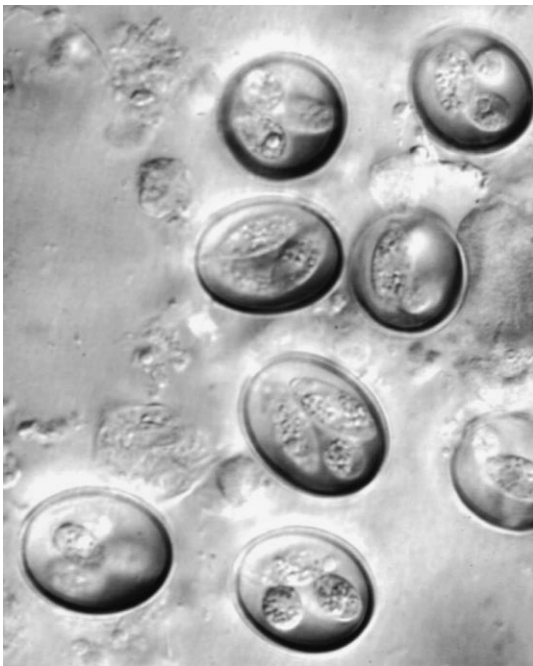- similar morphology of oocysts to sheep, different species

Eimeria ninakohlyakimovae - slightly pathogenic, high prevalence

Eimeria arloingi - most pathogenic



Eimeria arloingi



Coccidia in carnivores

Dog - 3 (5) *Isospora* species

Isospora canis

Isospora ohioensis

Isospora burrowsi

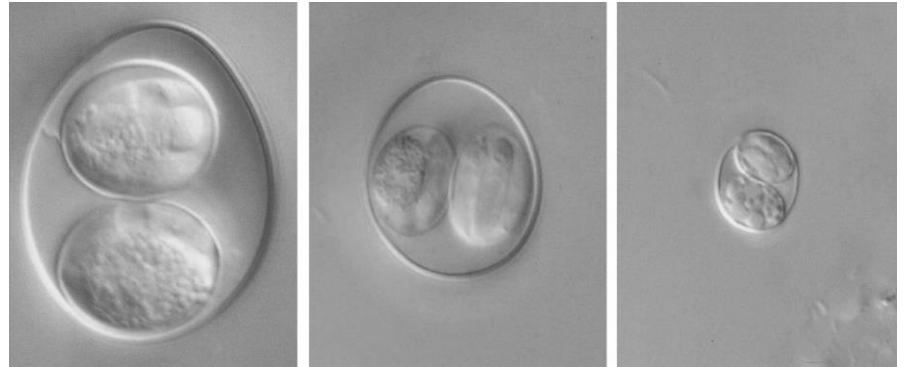
- cause of diarrhoea in young animals
- **dormozoites (hypnozoites)** in rodents
- *Neospora / Hammondia*

Cat - 3 (5) *Isospora* species

Isospora cati

Isospora rivolta

- cause of diarrhoea in young animals
- **dormozoites (hypnozoites)** in rodents
- *Toxoplasma / Hammondia*



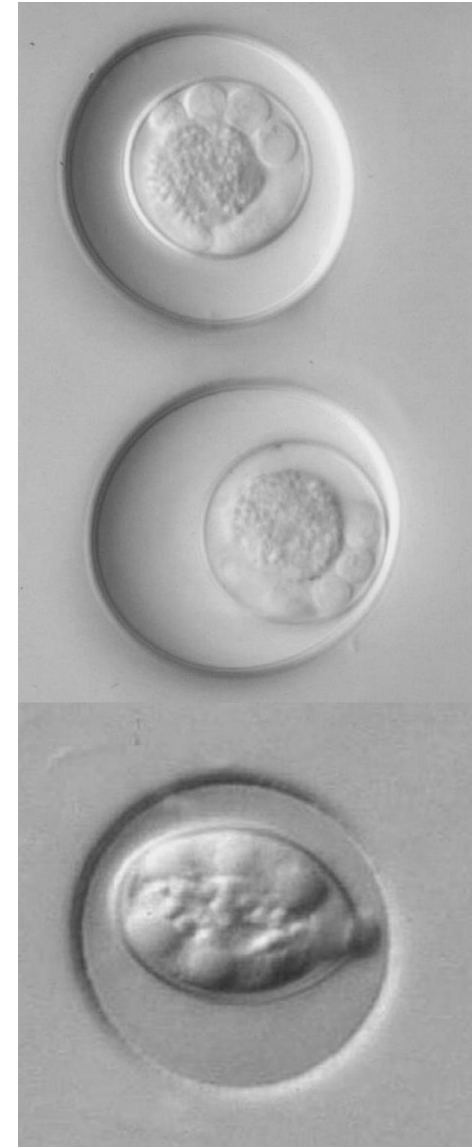
genus *Caryospora*

- mostly monoxenous
- oocyst with 1 sporocyst with 8 sporozoites inside
- parasites in snakes and raptors
- about 70 described species

Caryospora bigenetica

C. simplex

- facultatively heteroxenous
- primary and secondary hosts
- **caryocyst** (dormant stage) in secondary host
- dermal coccidiosis in secondary host
- potentially zoonotic



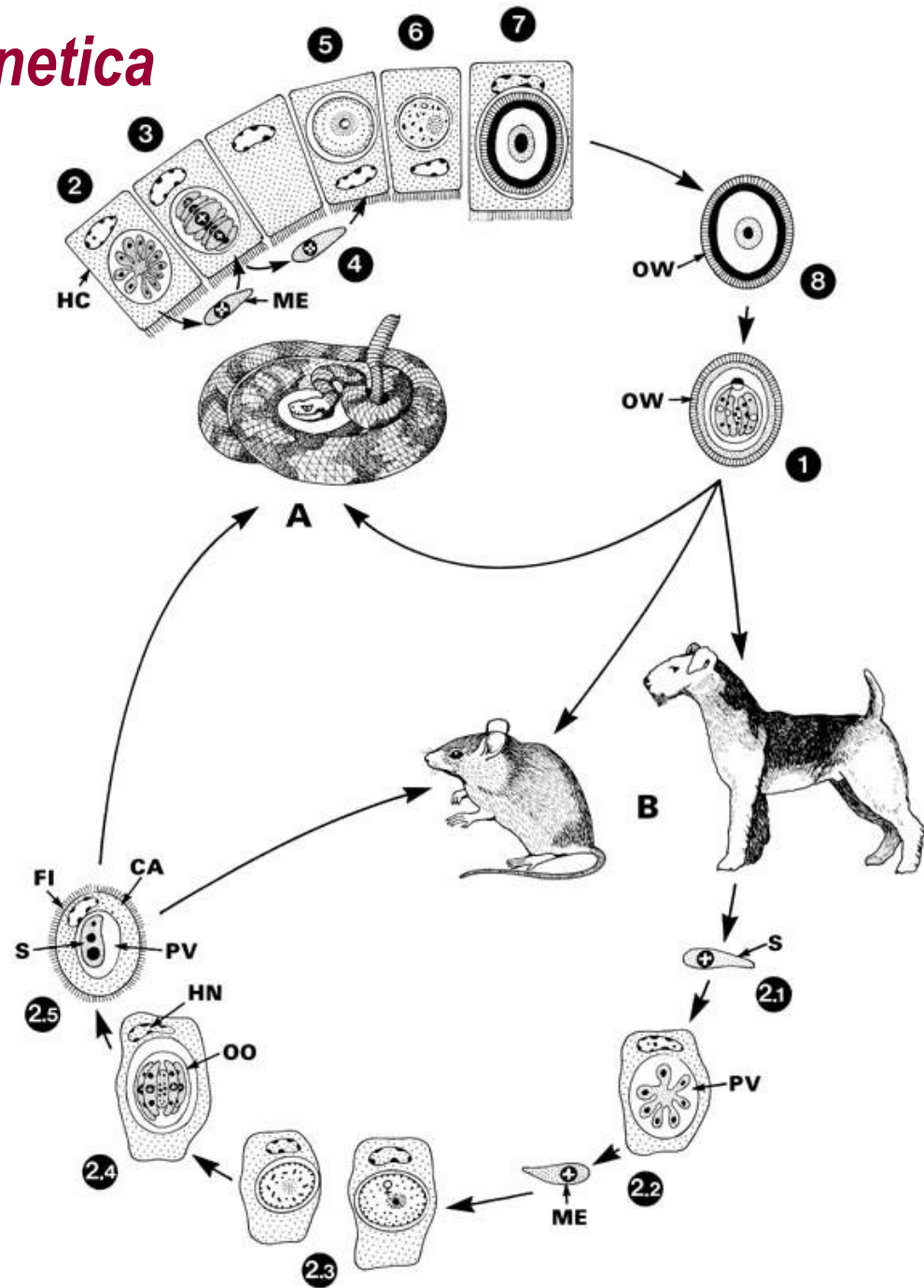
Life cycle of *Caryospora bigenetica*

A) First type of final host (rattlesnake)

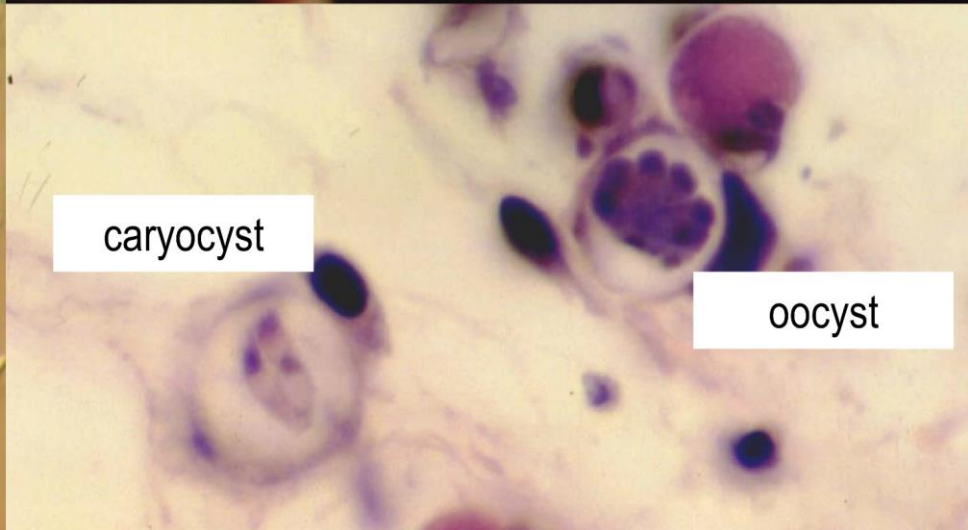
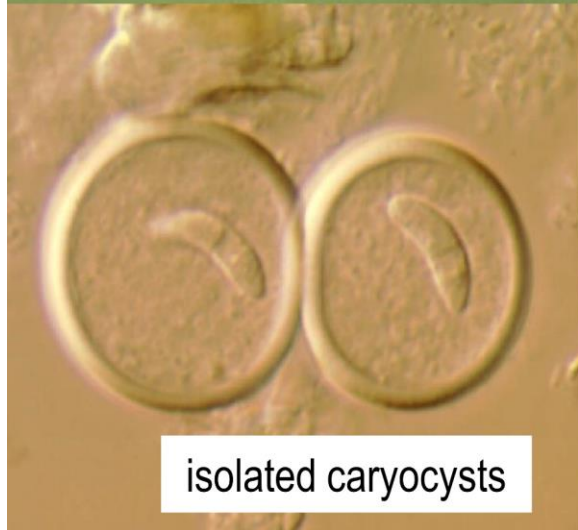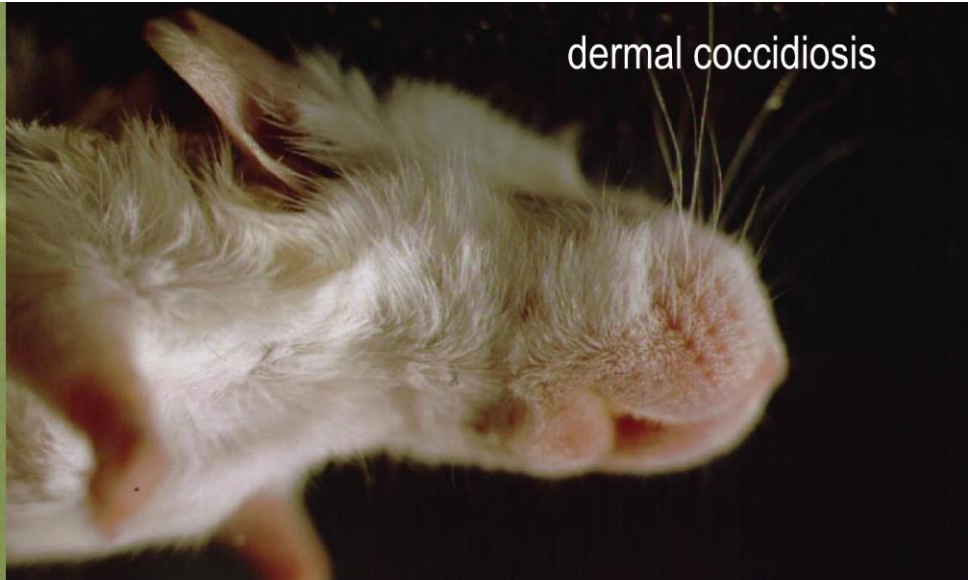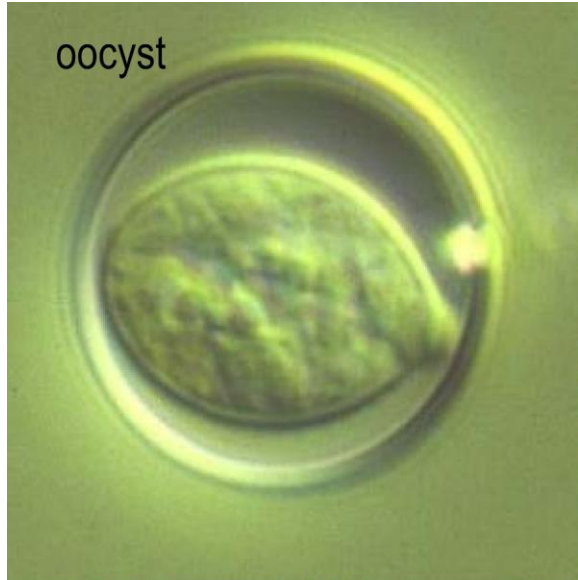1) The sporulated oocyst contains a single sporocyst with 8) sporozoites. 2-4) After oral infection with oocysts 2 generations of meronts are formed inside the intestinal epithelium. 5-6) Male and female gamonts are formed and later gametes occur. The male gamont (G) forms numerous gametes. 7-8) After fertilisation a thick-walled oocyst is formed inside the host cell and becomes free within the faeces. While sporulating on the ground a single sporocyst with 8 sporozoites is formed inside each oocyst.

B) Second type of final host (mice, cotton rats, dogs)

2.1-2.4) Repetition of the merogonic and gamogonic development (described in 1-8). The sporulation of oocysts may occur in skin regions (2.4). 2.5) Sporozoites that were set free from their sporocysts while still inside the skin of their hosts enter...

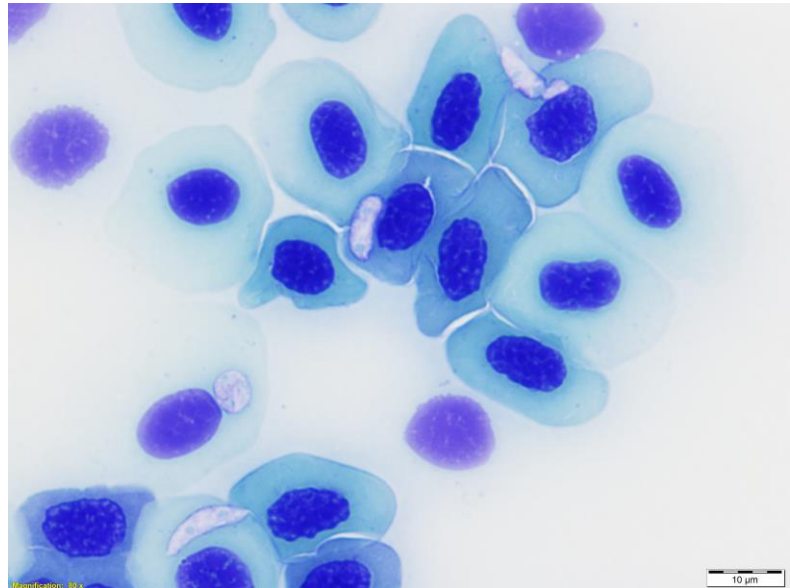
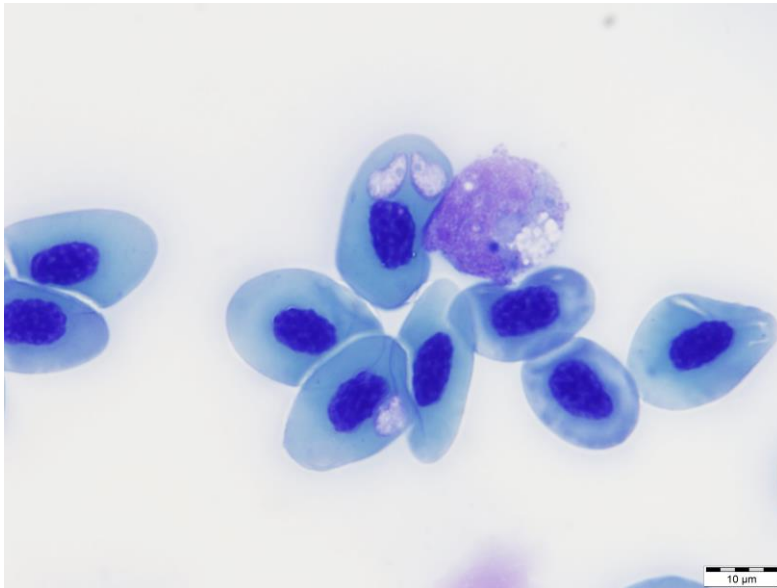


Caryospora simplex
Caryospora bigenetica

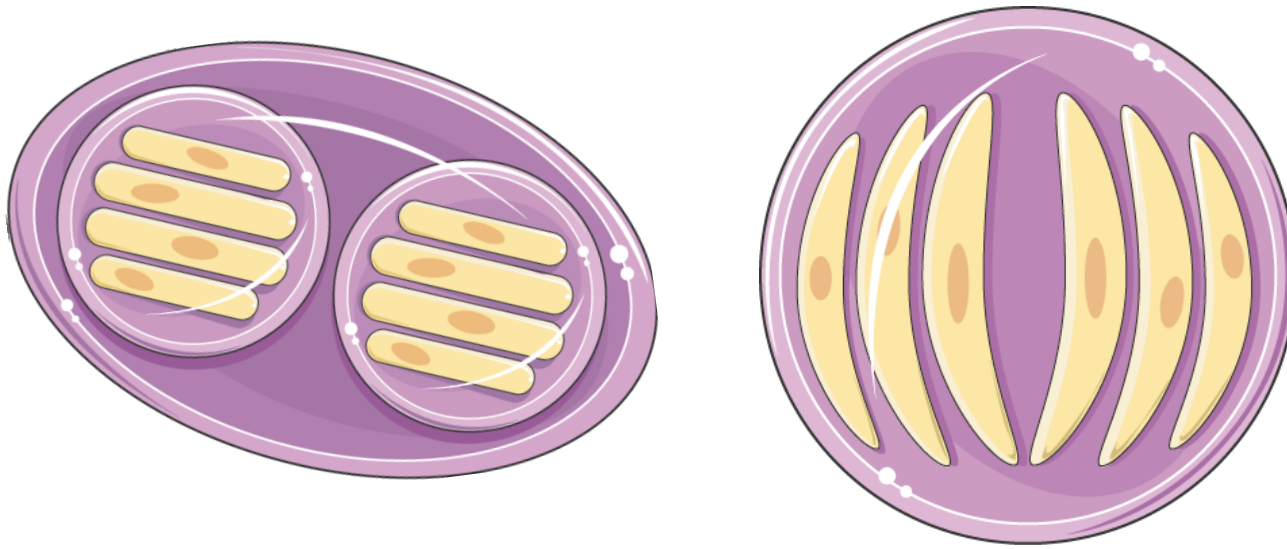


genus *Lankesterella*

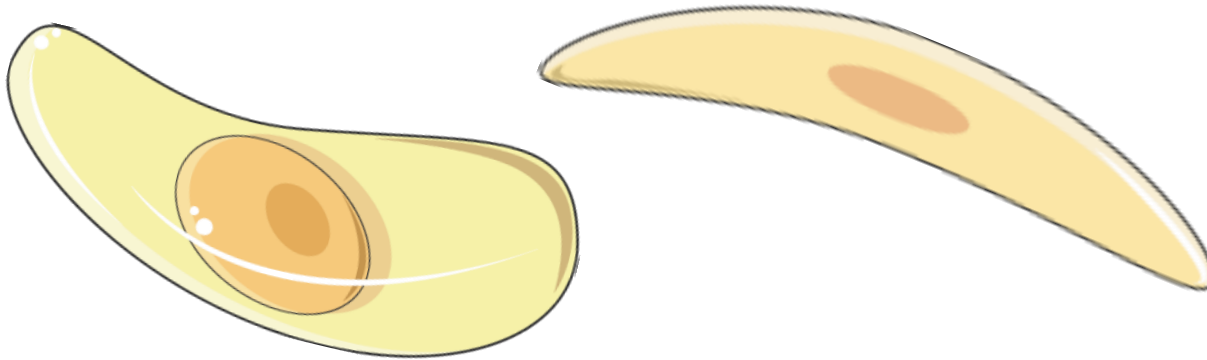
- parasites of amphibia reptiles, birds; transmission by a leeches
- heteroxenous with entire replicative process occurring in vertebrate host (connective tissue, visceral organs - liver, spleen, intestine, lung, kidney)
- absence of environmentally resistant oocysts
- thin-walled oocysts harbour variable numbers (usually more than 32) of naked sporozoites (no sporocysts) which after exiting the oocyst in situ enter blood cells and become dormant until they are ingested by leech vectors during a blood meal



Blood smear from *Pelophylax* frog with *Lankesterella* sporozoites



Thank you for your attention 😊



Lectures

- ✓ Introduction: BPP 2022 I
- ✓ Euglenozoa (Excavata): BPP 2022 II
- ✓ Fornicata / Preaxostyla / Parabasala (Excavata): BPP 2022 III
- ✓ Apicomplexa I (SAR): BPP 2022 IV
- ⇒ **Apicomplexa II (SAR): BPP 2022 V**
 - Amoebae (Excavata, Amoebozoa): BPP 2022 VI
 - Ciliophora, Opalinata (SAR): BPP 2022 VII

- *Pneumocystis* (Opisthokonta, Fungi): BPP 2022 VIII
- Microsporidia (Opisthokonta, Fungi): BPP 2022 IX
- Myxozoa (Opisthokonta, Animalia): BPP 2022 X