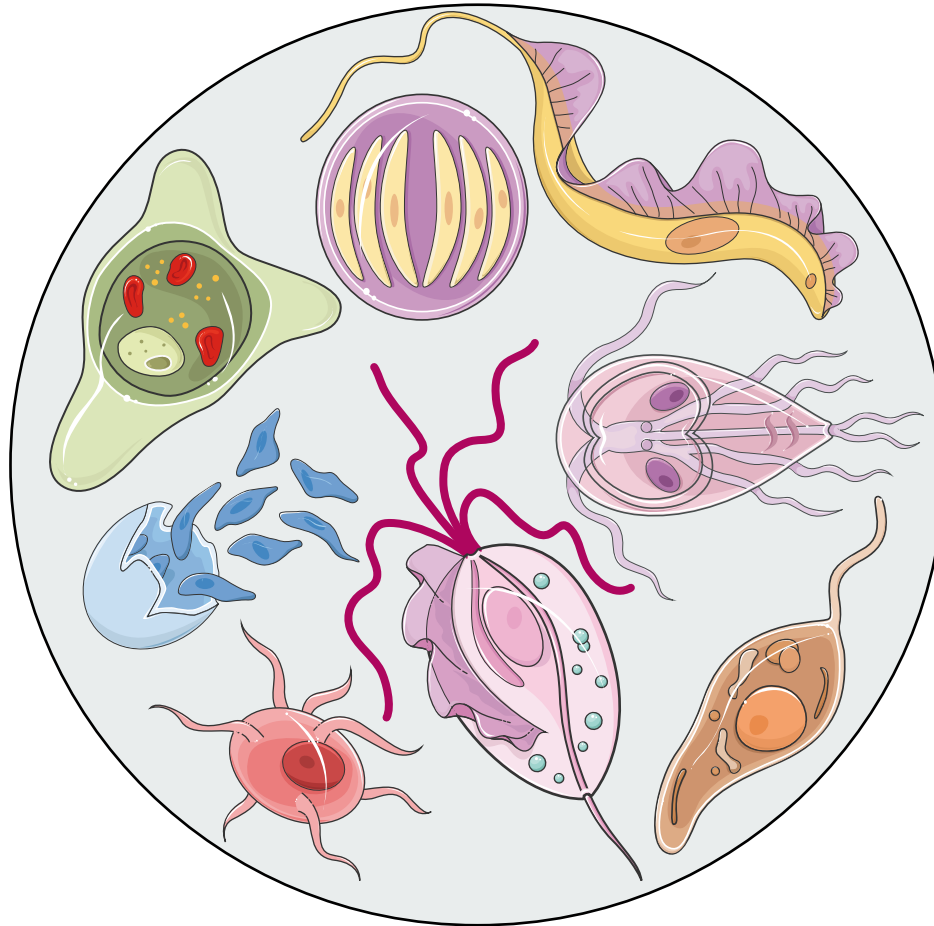


Biology of parasitic protozoa

VI. Amoebae: Heterolobosea (Excavata), Amoebozoa (Amoebozoa)



Andrea Bardůnek Valigurová

andreav@sci.muni.cz

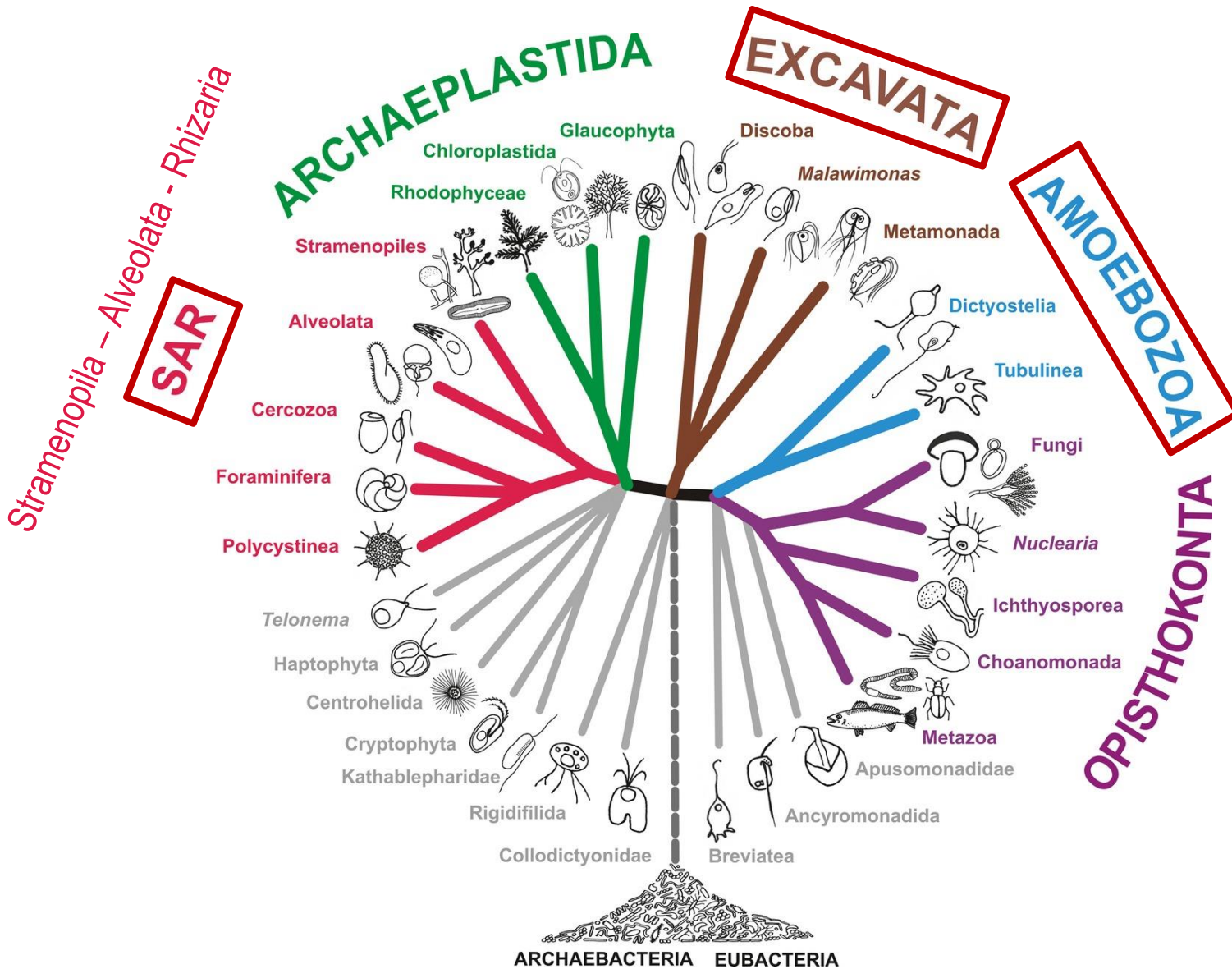
Notice

This presentation contains some material available on the web without the permission of the creator or the copyright owner. This presentation is to be used for educational purposes only. Educational purposes are defined as a communicating material for a particular course of instruction or for the administration of such course. Educational purposes do not cover the use of copyright material in PowerPoint for public lectures or other purposes.

Amoebae


- organisms which free-living alter its shape, primarily by extending and retracting pseudopodia
- pseudopodia extend and contract by the reversible assembly of actin monomers into microfilaments
- lobopodia, filopodia, reticulopodia, axopodia
- in older classification most amoebae were placed in the class/subphylum Sarcodina
- not a single taxonomic group = supergroups comprising amoebae: **Excavata**, **Amoebozoa**, **SAR**
- mostly free-living species - some are predatory and consume bacteria, others are detritivores and feed on dead organic material
- amoebae typically ingest the food by phagocytosis

5 supergroups = megagroups

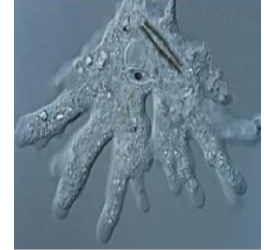

Pseudopodia (pseudopods) in Amoebae

Amoebozoa
(**Amoebozoa**)



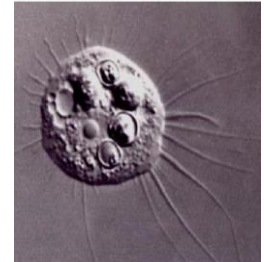
lobopodia



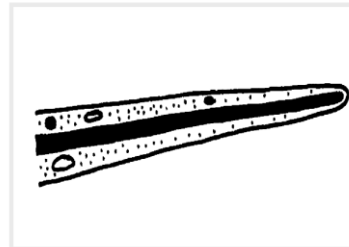
Heterolobosea
(**Excavata**)



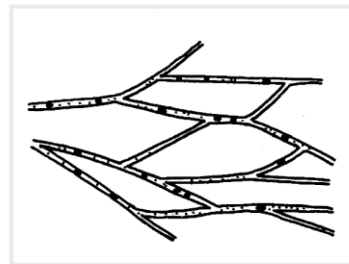
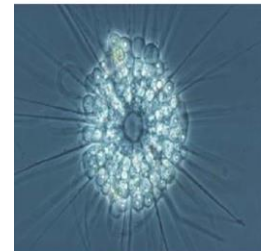
filopodia



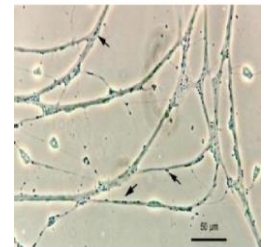
Rhizaria
(**SAR**)



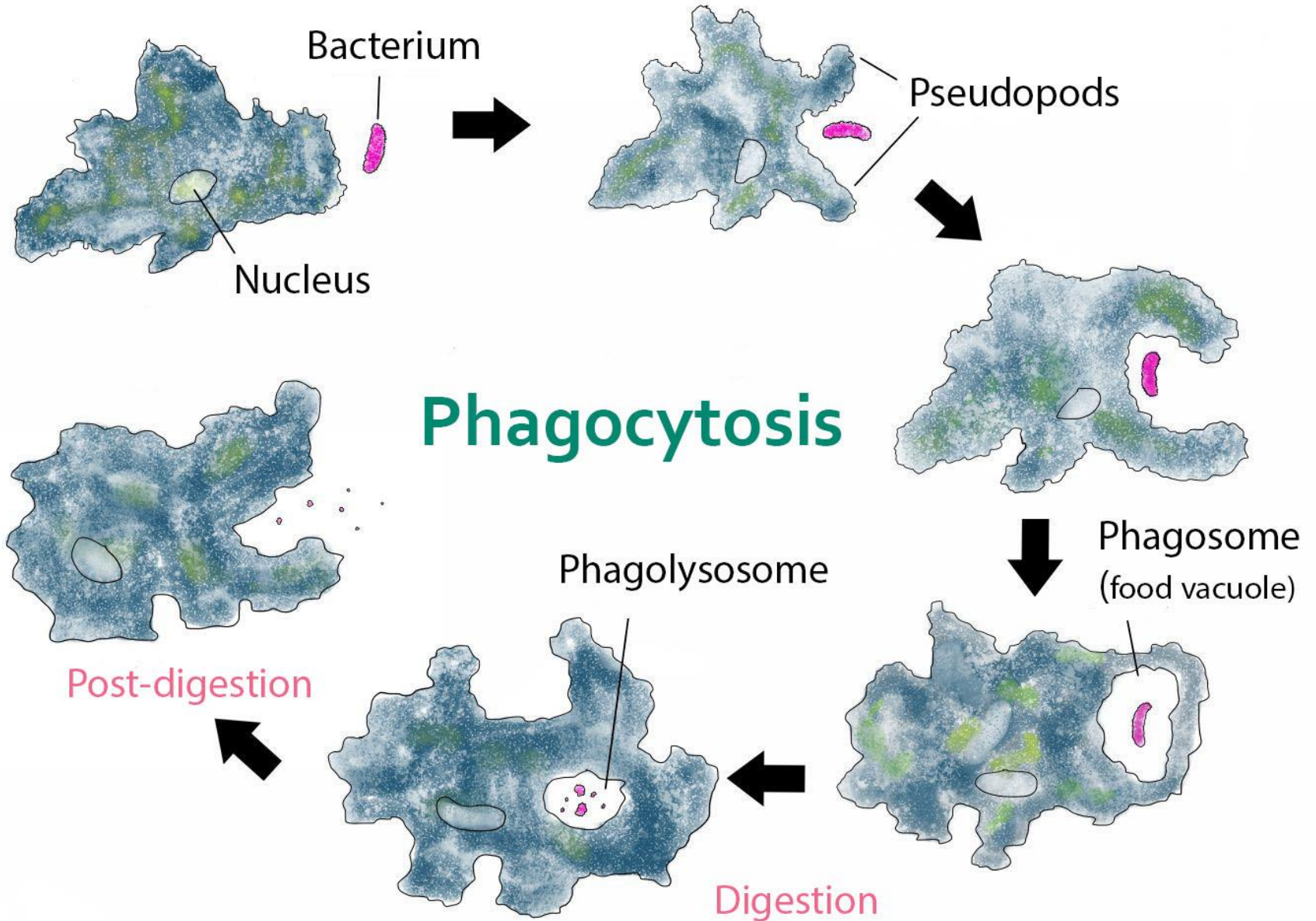
axopodia



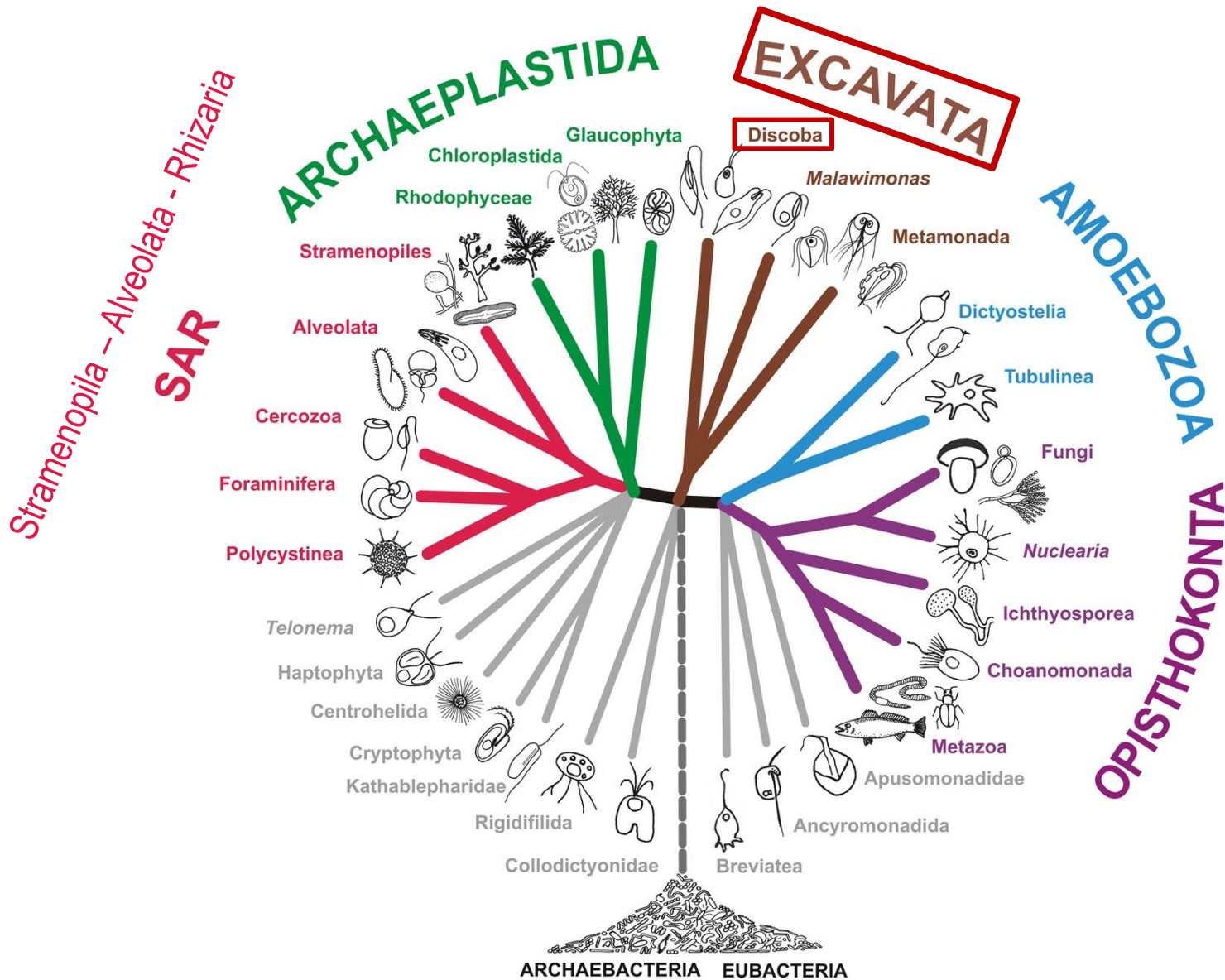
reticulopodia



Phagocytosis in Amoebae

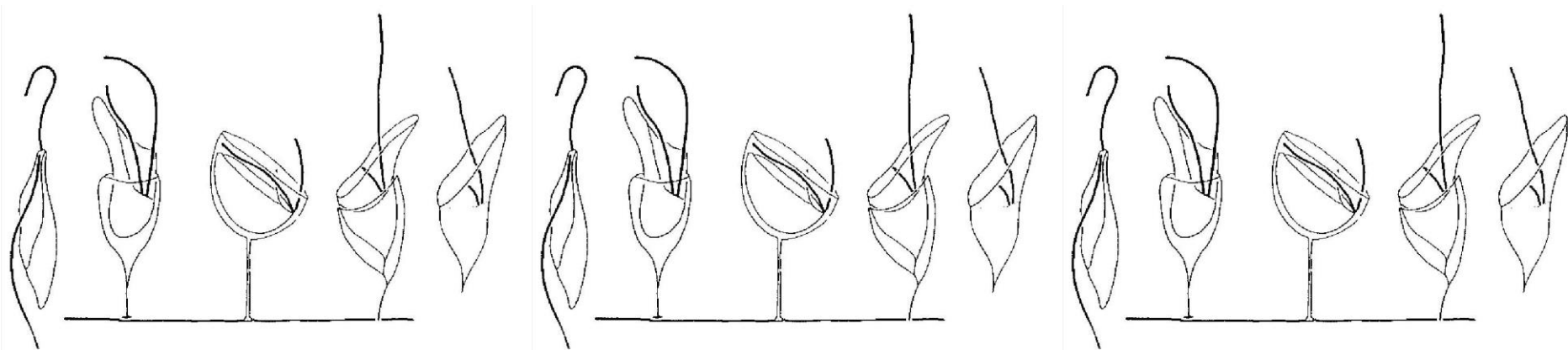


5 supergroups = megagroups



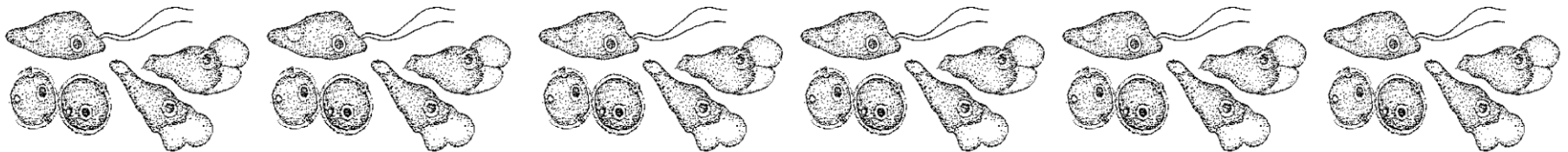
Excavata

- have a conspicuous **ventral feeding groove** that is “excavated” from one side, and through which pass one or more recurrent flagella; the ventral groove has characteristic ultrastructure and is supported by microtubules
- variety of free-living and symbiotic forms
- not a monophyletic group
- paraphyletic group with the ancestors of other living eukaryotes
- parasitic species in **Discoba**: **Heterolobosea**•••
- Heterolobosea have lost some of Excavata structures



Heterolobosea

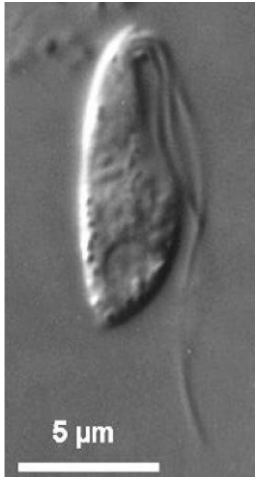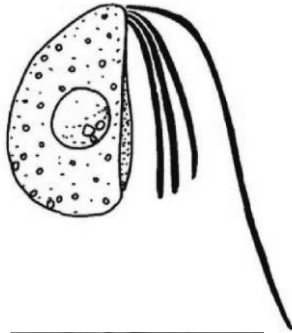
- about 140 described species
- amoebae with eruptive pseudopodia, alternating with flagellated phase - flagellated cells usually with 2 or 4 flagella
- amoeboid, flagellate and resting stage (cyst) = **amoeboflagellates**
- one or two stages are unknown and presumably have been reduced in many taxa
- remains unclear whether Heterolobosea represent sexual or asexual organisms
- representatives capable of feeding usually use a groove like cytostome
- flattened, often discoidal mitochondrial cristae
- most important heterolobosean taxon is the genus ***Naegleria*** comprising human parasite *Naegleria fowleri* and model organism *N. gruberi*



Heterolobosea

flagellates

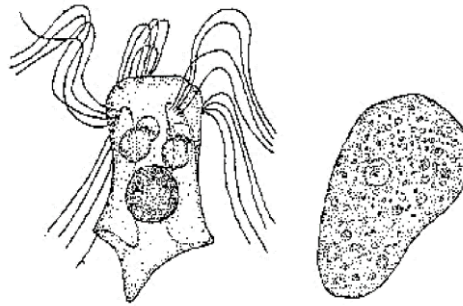
Percolomonas



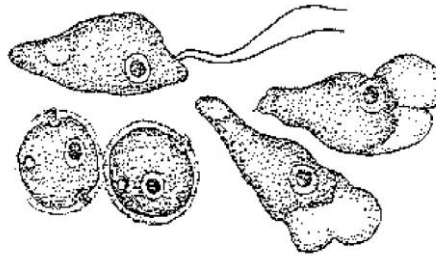
flagella permanently

amoeboflagellates

Psalteriomonas



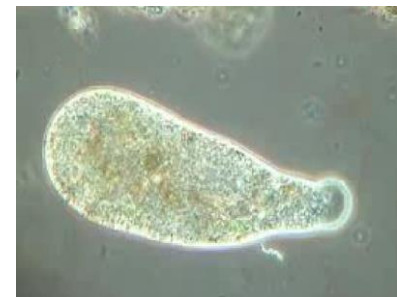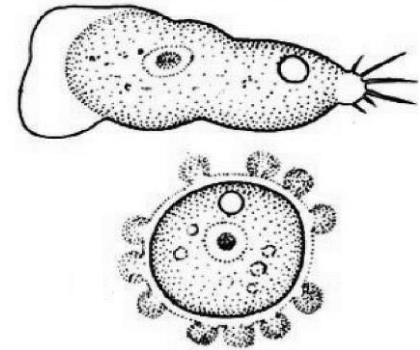
Naegleria



flagella temporarily

amoebae

Vahlkampfia



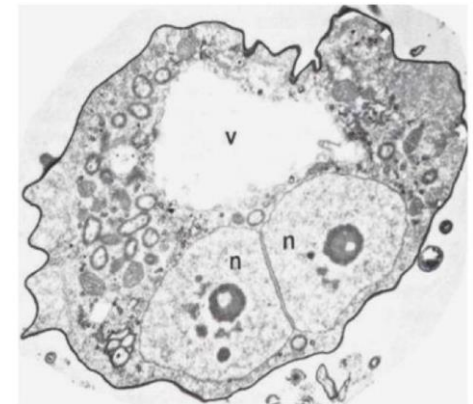
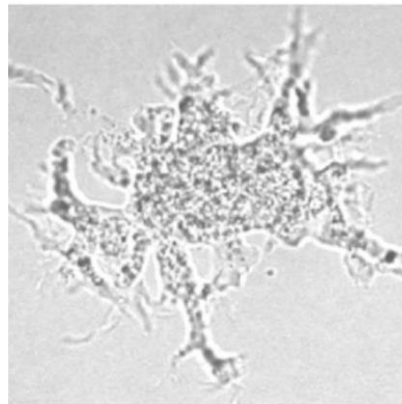
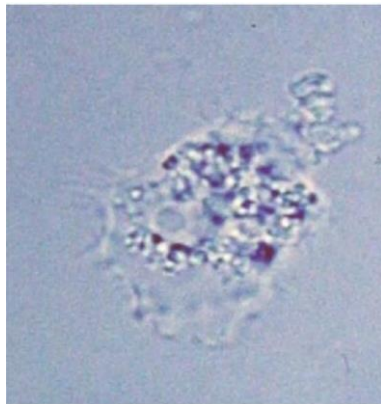
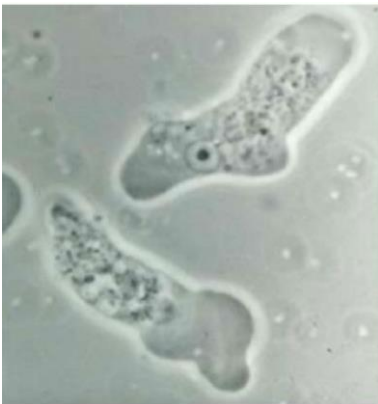no flagella

Heterolobosea - amphizoic amoebae

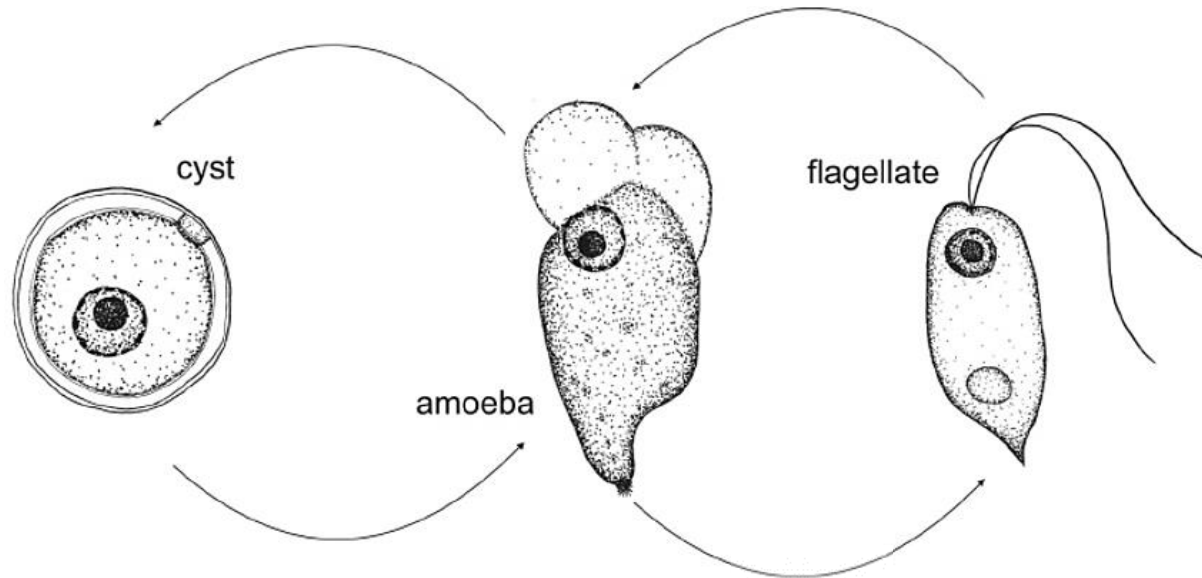
- also called **amphizoic amoebae** for their ability to exist as free-living organisms and only occasionally invade the host and live as parasites in its tissue
- important human pathogen: *Naegleria fowleri*

genus *Naegleria*

- about 300 cases of human **primary amoebic meningoencephalitis (PAM)**, while only 5 PAM patients survived

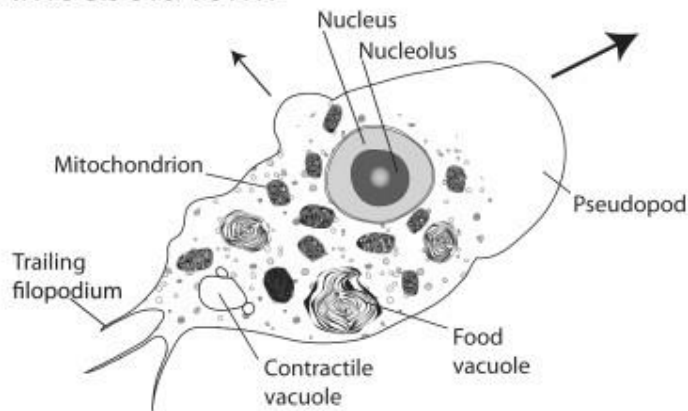


Life cycle in Heterolobosea

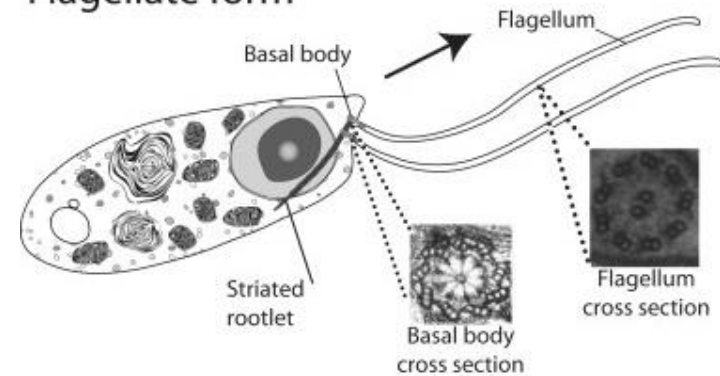


Life cycle of *Naegleria gruberi*

Amoeboid form



Flagellate form

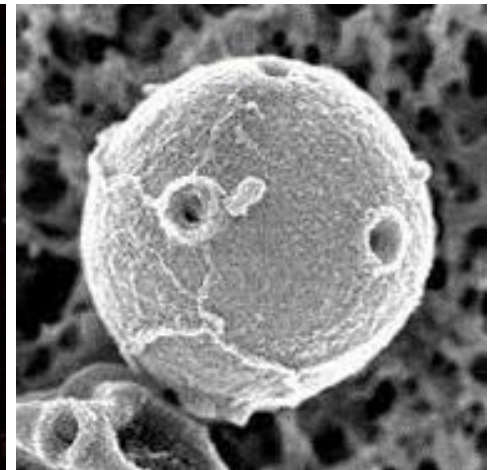
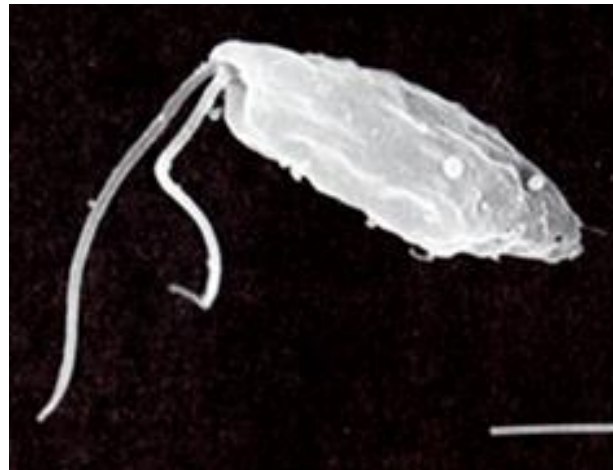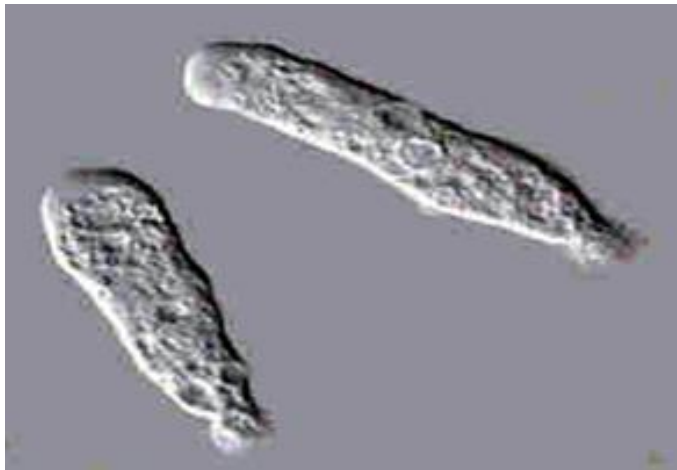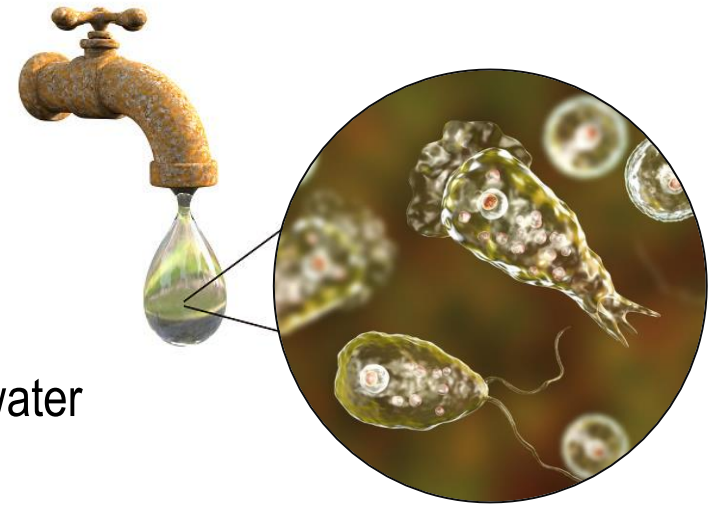


Schematic view of *Naegleria* amoeba and flagellate forms

Heterolobosea

Naegleria fowleri

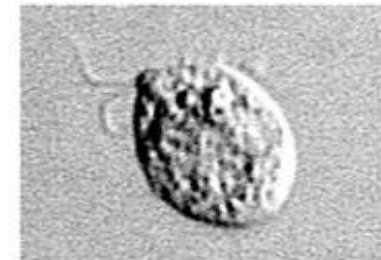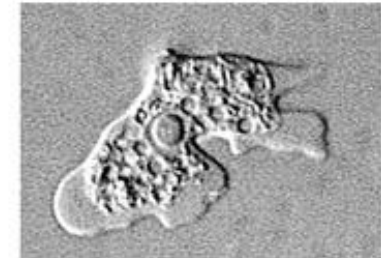
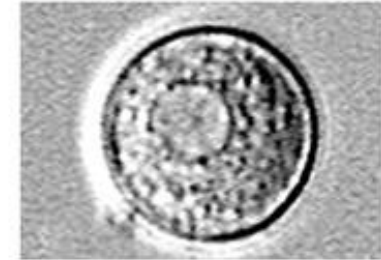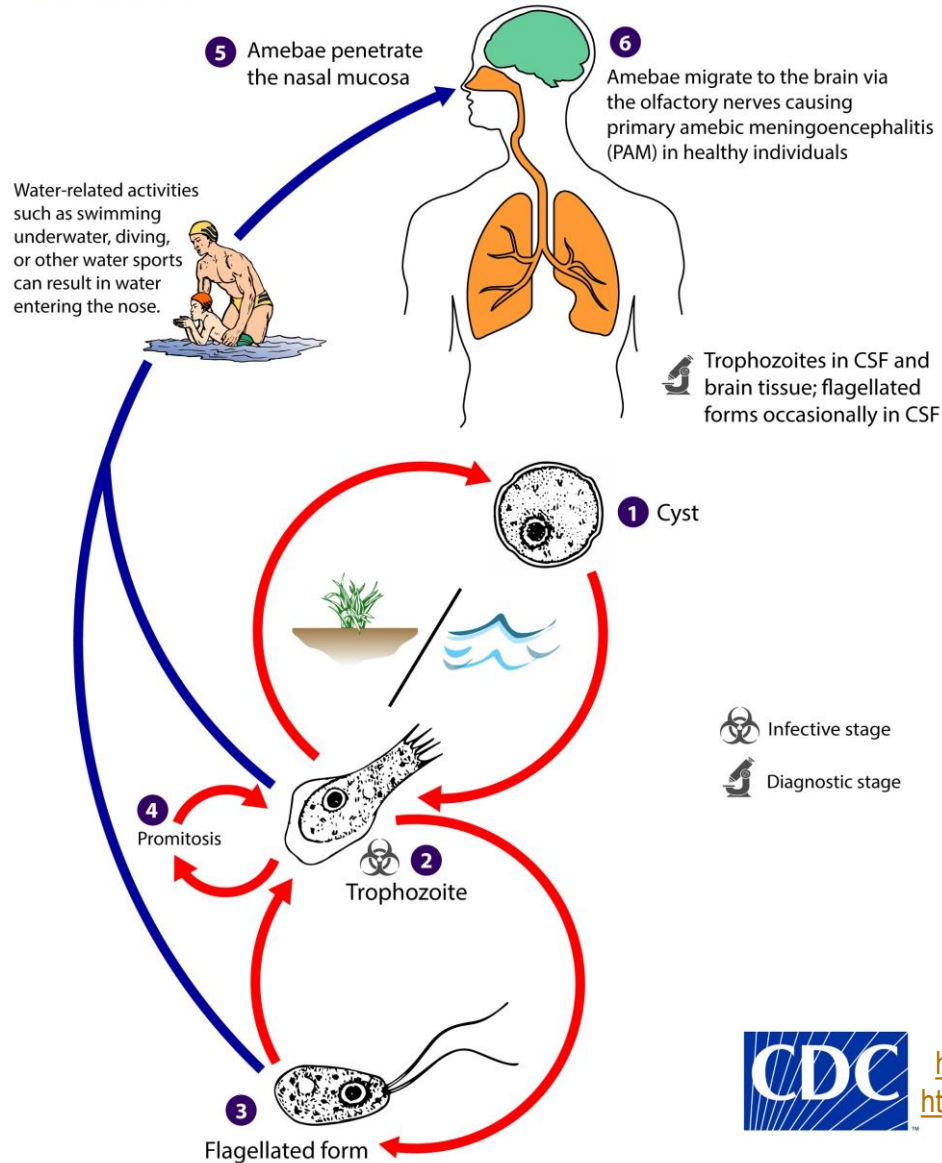
- thermophilic free-living amoeba
- surface of vegetation and mud
- pear shaped **motile stage with 2 flagella** - in surface water (usually not found in CSF)
- slug shaped **amoebic trophozoite** (10-25 μm) with rounded pseudopodia (lobopodia) - infective for humans and observed in CSF and brain tissue
- **uninucleated cysts** found on the surface of vegetation and in mud



Life cycle of *Naegleria fowleri*



Naegleria fowleri

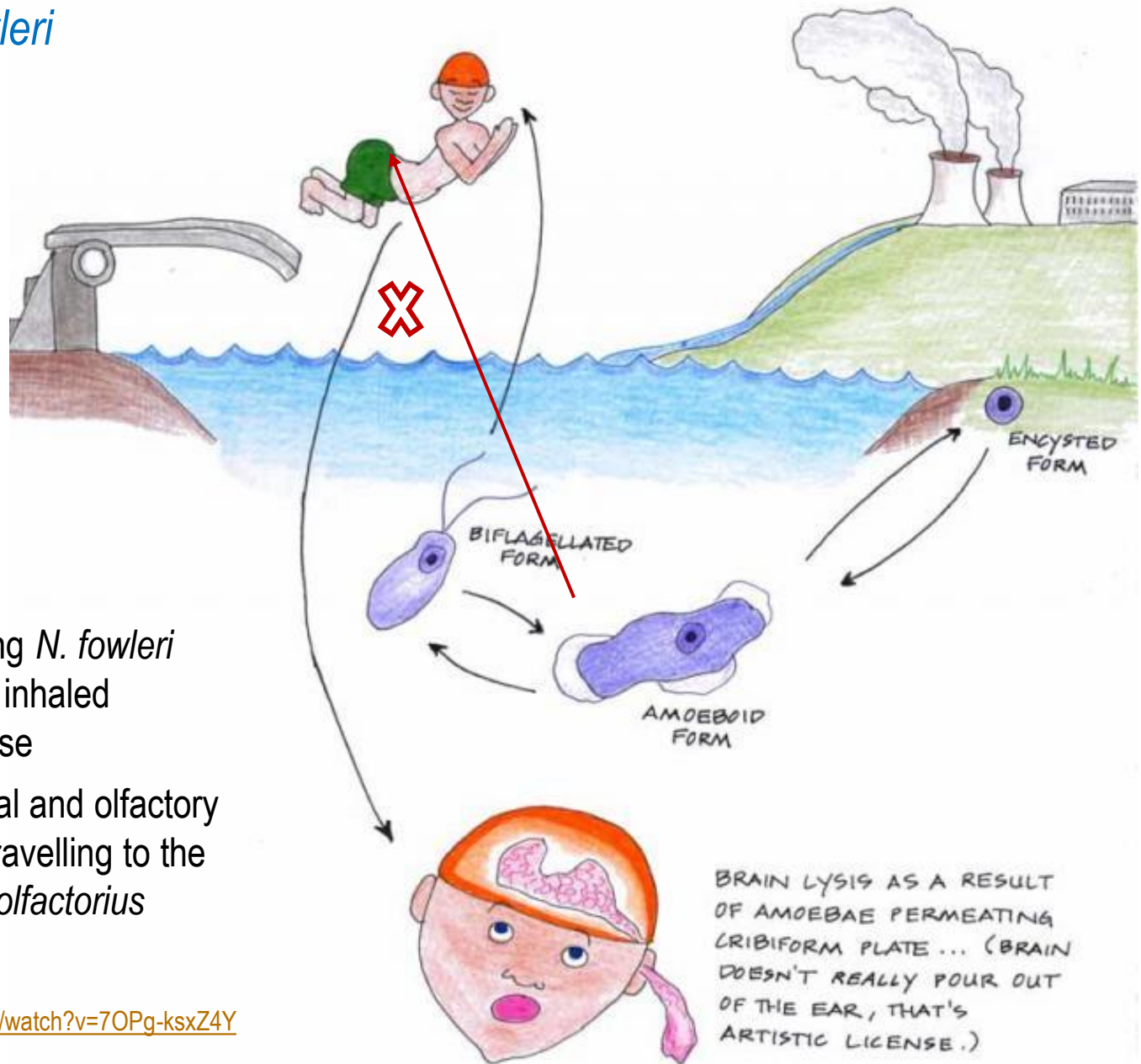


Infective stage
 Diagnostic stage



<https://www.youtube.com/watch?v=Thp5O-i7Sgc>
<https://www.youtube.com/watch?v=zFEXdnUbTZE>

Naegleria fowleri

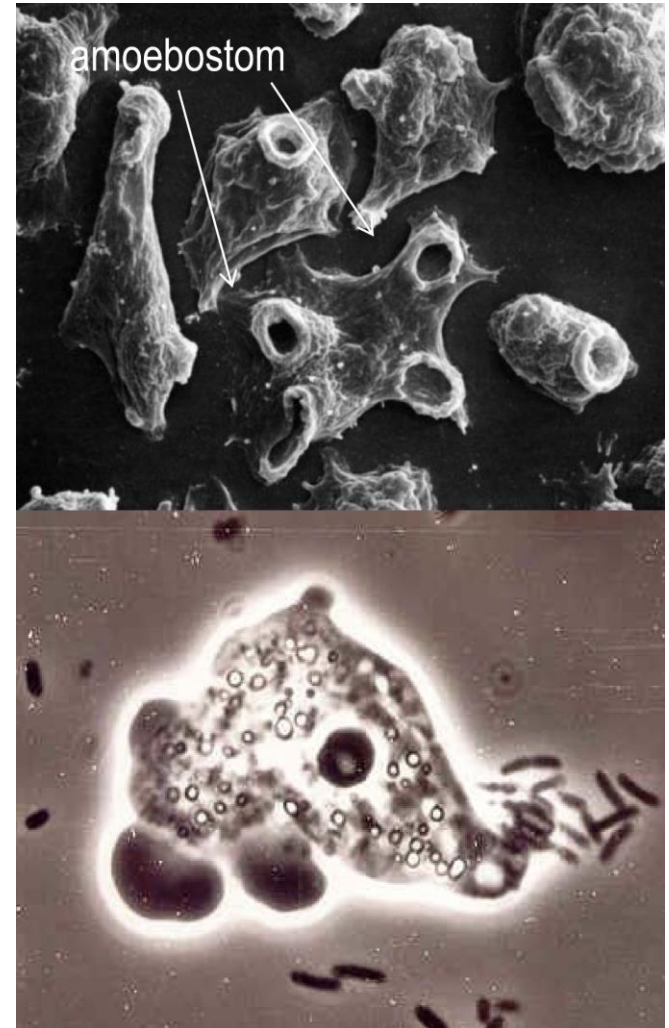


- water containing *N. fowleri* amoeba stage inhaled through the nose
- enters the nasal and olfactory nerve tissue, travelling to the brain - *bulbus olfactorius*

BRAIN LYSIS AS A RESULT OF AMOEBAE PERMEATING CRIBIFORM PLATE ... (BRAIN DOESN'T REALLY POUR OUT OF THE EAR, THAT'S ARTISTIC LICENSE.)

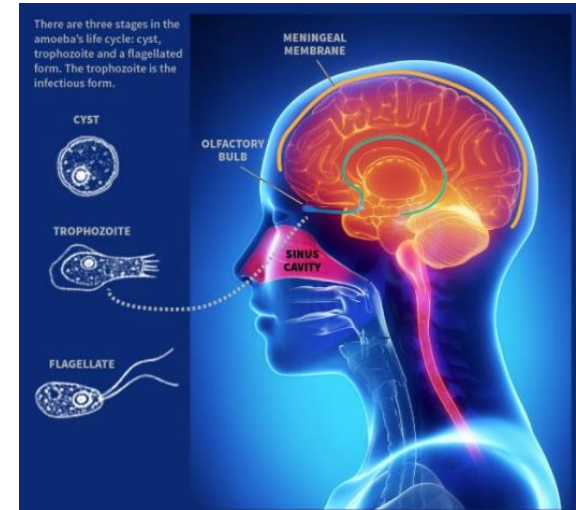
Naegleria fowleri

- acute, fulminating haemorrhagic meningoencephalitis in healthy children and young adults - **primary amoebic meningoencephalitis (PAM)**
- worldwide distribution in fresh and warm water (lakes, streams, spas, heated but unchlorinated swimming pools, hot springs, hydrotherapy and remedial pools, aquaria, sewage,...)
- thermophilic, tolerates temperatures of up to 45 °C (optimum 37 °C)
- abundant during summer
- reduction of osmotic pressure \Rightarrow formation of flagellar stages

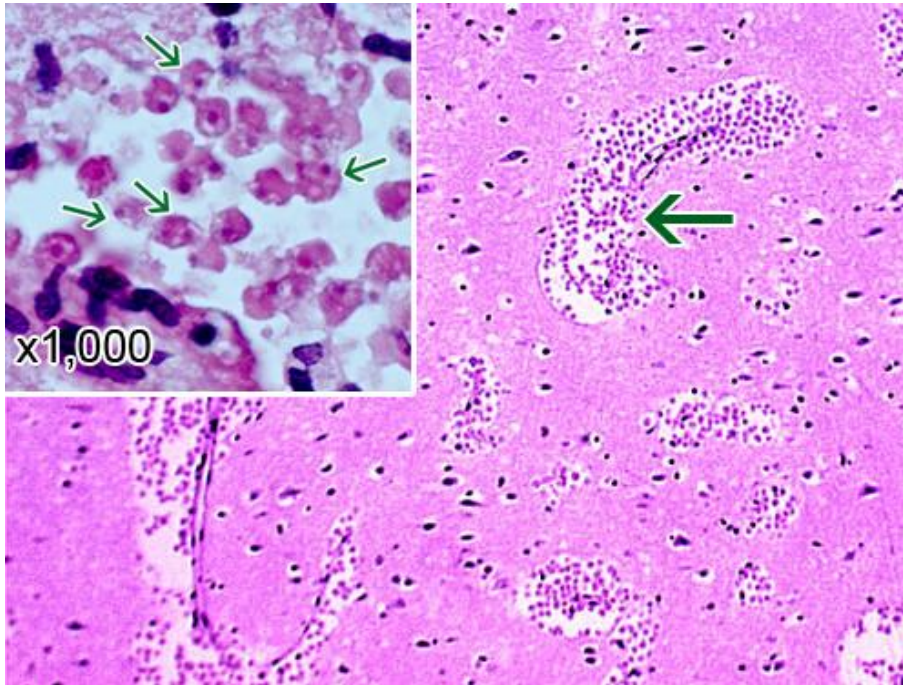


Course and clinical symptoms of naegleriasis

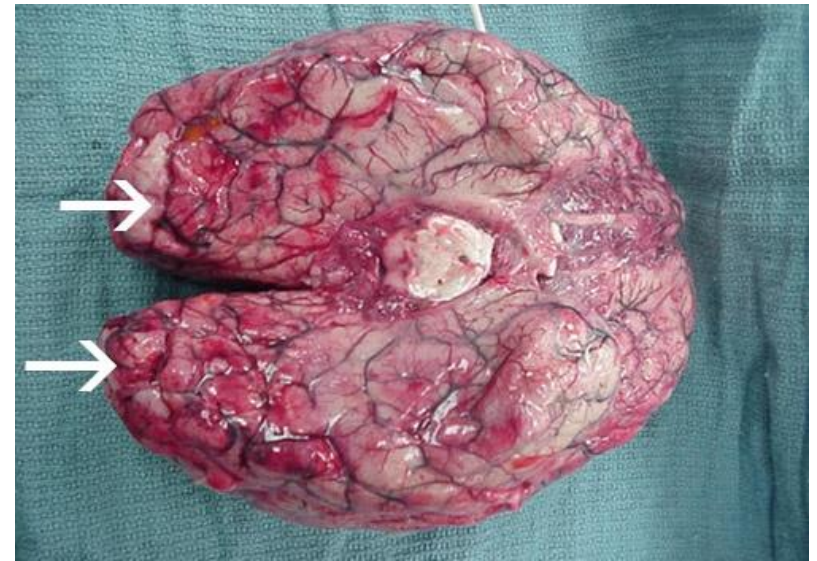
- amoebae enter the CNS following attachment to the olfactory nerve and migrate to the olfactory bulb (*bulbus olfactorius*) of the forebrain, invading the brain ⇒ widespread infections, haemorrhages and necrosis
- rapid onset of symptoms in 3-5 days after the exposure
- **stage 1**: severe frontal headache, fever, nausea, vomiting
- **stage 2**: stiff neck, seizures, altered mental, status, hallucinations, coma
- **death** in 1-18 days (median 5 days) after symptoms begin
- signs and symptoms of *N. fowleri* infection are similar to bacterial meningitis, which lowers the chances of diagnosing PAM at first
- the outlook for patients is poor; early diagnosis and new treatments can increase their chances for survival



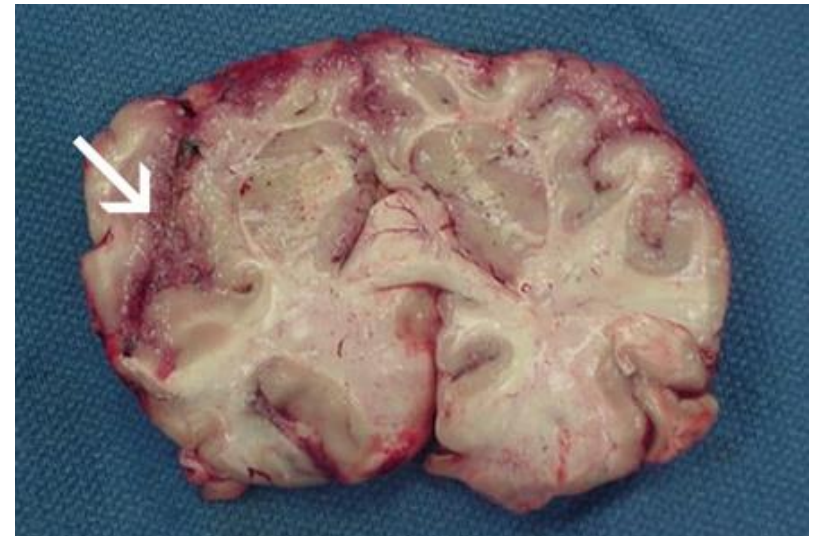
Pathology of PAM



A section of the cerebral portion of the brain from a PAM patient showing large clusters of *N. fowleri* trophozoites and the destruction of the normal brain tissue architecture. Inset: Higher magnification of *N. fowleri* trophozoites (arrows). HE.

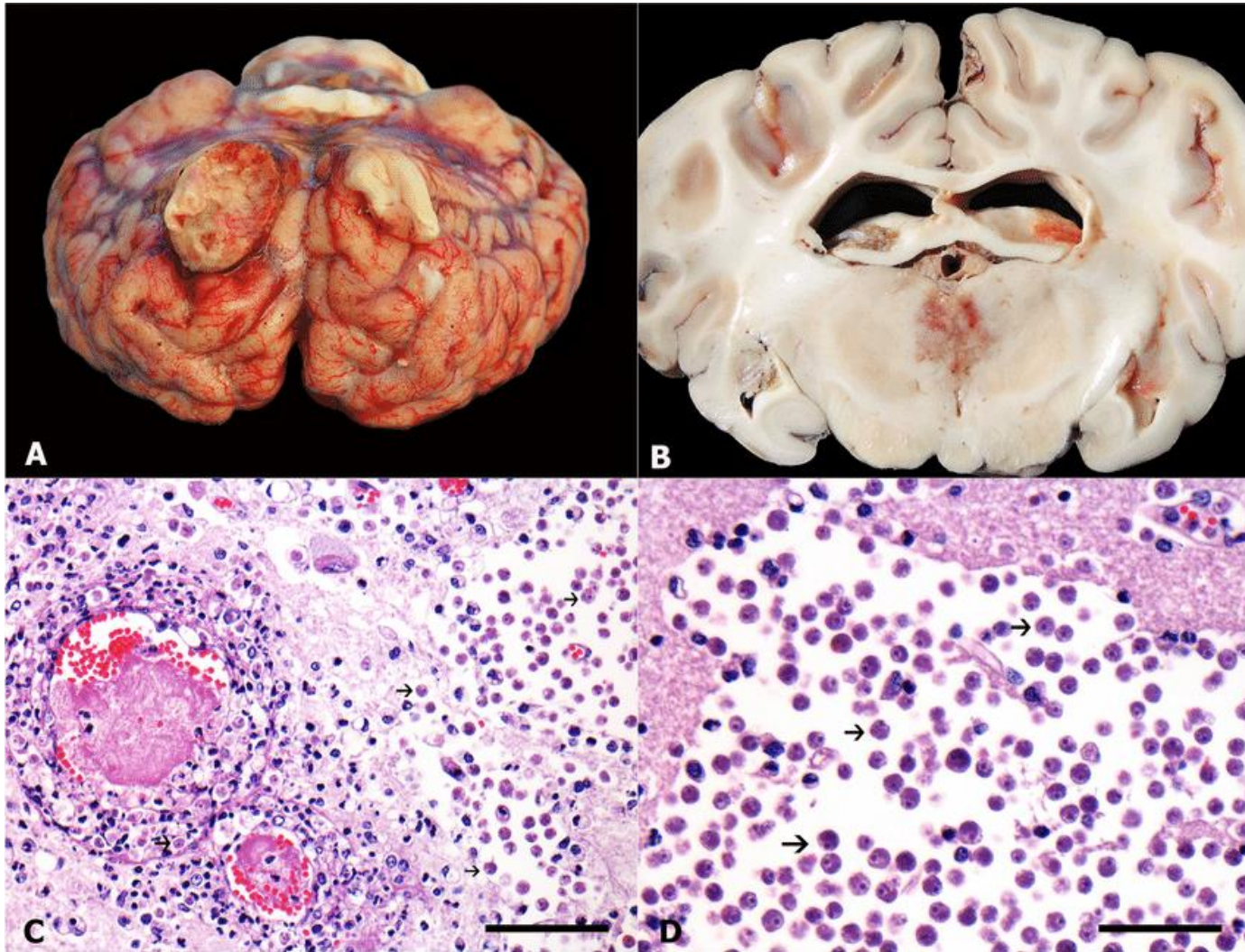


Extensive haemorrhage and necrosis is present in the brain, mainly in the frontal cortex.



Focal haemorrhage and necrosis in frontal cortex.

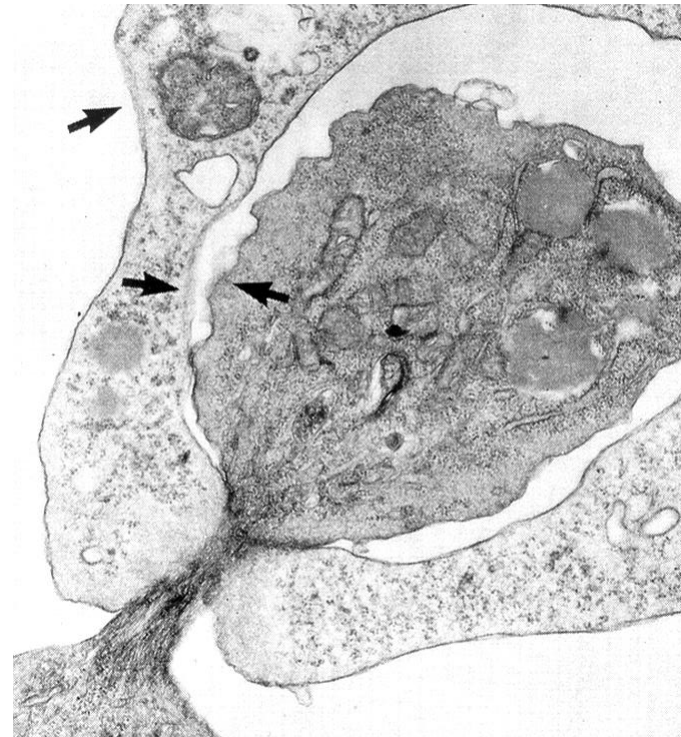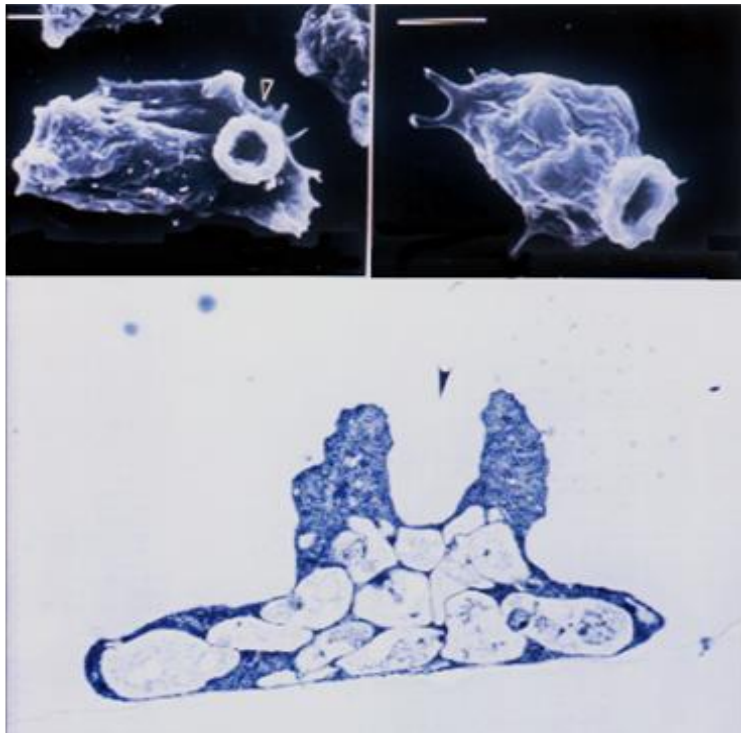
Pathology of PAM



***Naegleria fowleri*-associated disease in cattle.** **A)** Brain positioned upside-down. Left olfactory bulb shows marked enlargement and irregular surface. **B)** Cross-sectioned brain, Thalamus shows a focally extensive and poorly demarcated area of necrosis. **C-D)** Histological sections of brain. Blood vessels show marked fibrinoid necrosis of their wall and thrombosis. Rarefaction of adjacent neuropil (detail in **D**) with multiple *N. fowleri* trophozoites (arrows).

Pathogenesis of *Naegleria fowleri*

- forms sucker like appendages or **amoebostomes**
- nibbles away at the cells and tissues (**trogocytosis**)
- contact-dependent cytolysis of brain tissue by the amoeba
- secretion of cytolytic factors causing destruction of cell membrane, including a pore-forming protein similar to perforin



Diagnosis and treatment of naegleriasis

Microscopy

- ✓ wet mount examination of the CSF (actively moving amoebae)
- ✓ Giemsa or trichrome stained CSF smears

Cultivation

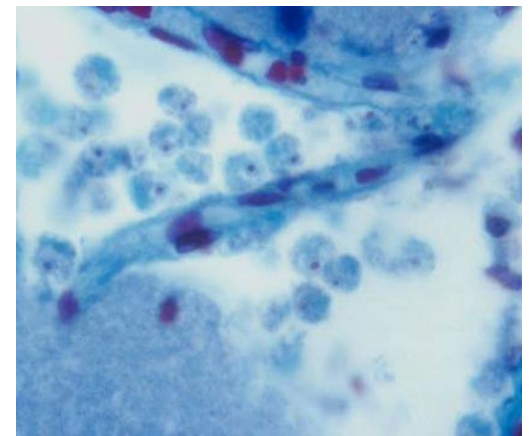
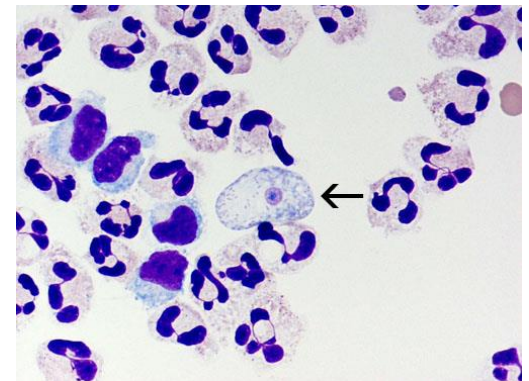
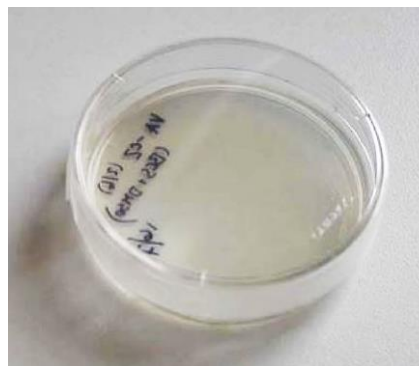
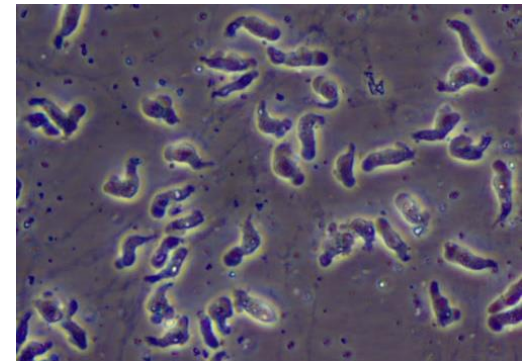

- ✓ at 37 °C on agar with killed bacteria (*Enterobacter*, *Escherichia*)

Histology (trichrome staining)

- ✓ amoebae with typical nuclear morphology
- ✓ located mostly perivascularly


Treatment

- **only 5 PAM patients survived** (permanent brain damage)
- amphotericin B i.v. + intrathecally
- rifampin p.o. + miconazol i.v. + intrathecally



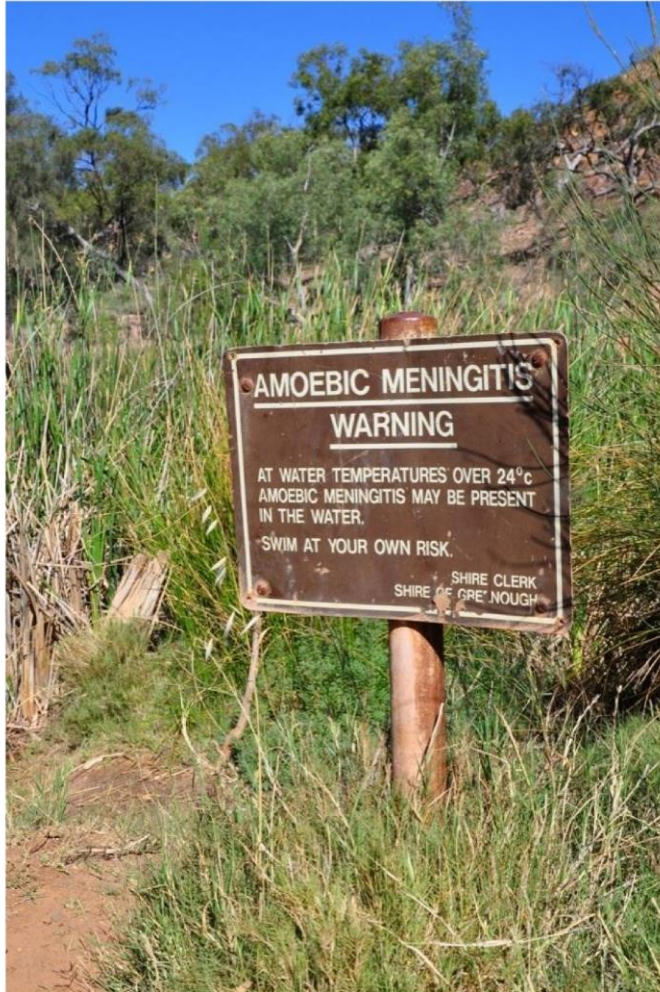
Epidemy of PAM in Czech Republic

- 18 cases of PAM in Czechia
- 1962-1965: 16 cases (biggest PAM epidemy)
- 8-25 years old patients
- swimming pool Ústí nad Labem:
 - VIII. 1962: 3 cases
 - VII. 1963: 6 cases
 - XI. 1964: 5 cases
 - IX. 1965: 2 cases
- 1968: 1 case: swimming poll in Most
- 1984: 1 case: stream with cooling water from power station



Vrbenský's swimming pool in Usti nad Labem

Prevention of *Naegleria fowleri* infection



WARNING

AMOEBIC MENINGITIS

In all thermal pools
KEEP YOUR HEAD ABOVE WATER
to avoid the possibility of
developing the serious illness
called **AMOEBIC MENINGITIS**.

This disease can be caught in
thermal pools if water enters the
nose, while swimming or diving.

ISSUED BY THE DEPARTMENT OF HEALTH

Prevention of *Naegleria fowleri* infection

- ii. **commercial geothermal pools** should comply with the New Zealand Standard for Swimming Pool Water Quality (NZ 5826:2010). The amoeba that causes amoebic meningitis is very unlikely to survive in pools that always meet these standards.

The safest geothermal pools are those which comply with the New Zealand Standard, or where:

- barriers such as concrete surrounds, floors, walls, roofs, etc, help keep soil away from the pool water and water source, and
- swimmers have to walk through a foot-bath before entering the pool, and
- the pool is chlorinated, and
- the water is filtered, or
- there is a constant flow of new water into the pool.

OTHER TYPES OF POOLS

Some swimming pool complexes may have both geothermal and non-geothermal pools. To comply with the New Zealand Standard, signs should show which pools are chlorinated and which are not.

Some warm pools may contain ordinary water that has been heated by geothermal water. In these pools the geothermal water does not mix with the ordinary water. These pools should be safe because they are required to meet the New Zealand Standard.

If you are unsure about the safety of a pool, ask the pool operator or local council to tell you how the pool is treated.

Whether you choose to swim in a natural, commercial or private geothermal pool, it is safest to keep your head out of the water at all times.

REMEMBER

Keep your head out of the water when in a geothermal pool.

No jumping, diving, splashing or ducking in a geothermal pool.

The risk of amoebic meningitis is greatest in natural outdoor geothermal pools where soil - or water running off the soil - can easily enter the water.

If you become sick with a headache, fever and vomiting after being in a geothermal pool, see your doctor immediately.

KEEP YOUR HEAD ABOVE WATER



New Zealand Government

April 2001. Reprinted November 2014.
Code HE1243

hpa health promotion agency

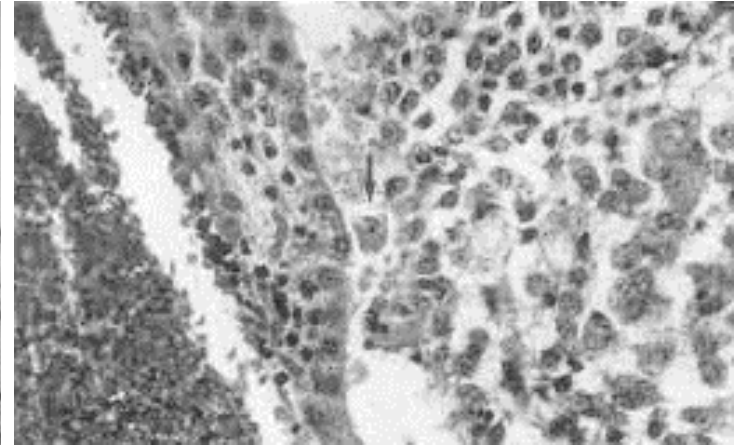
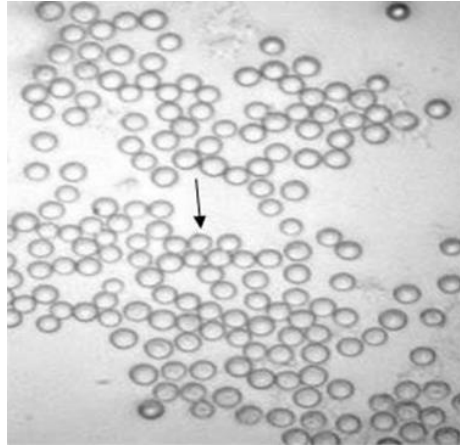
MINISTRY OF HEALTH
MANATU HAUORA

to prevent amoebic meningitis when using geothermal pools

Heterolobosea

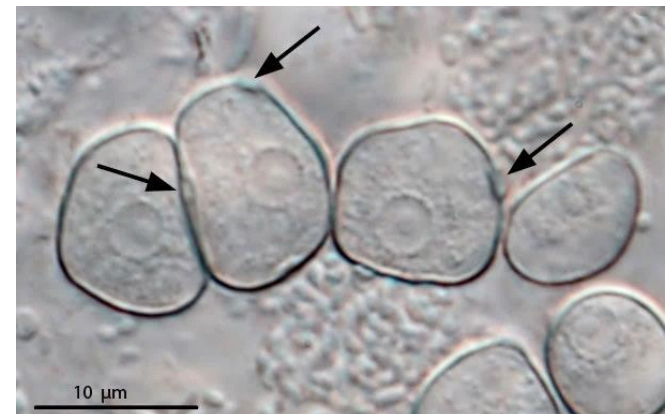

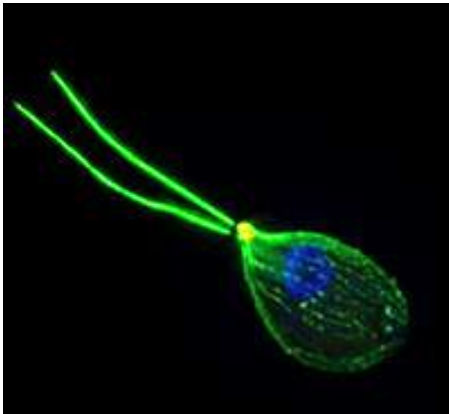
Naegleria australiensis

- pathogenic to laboratory mice

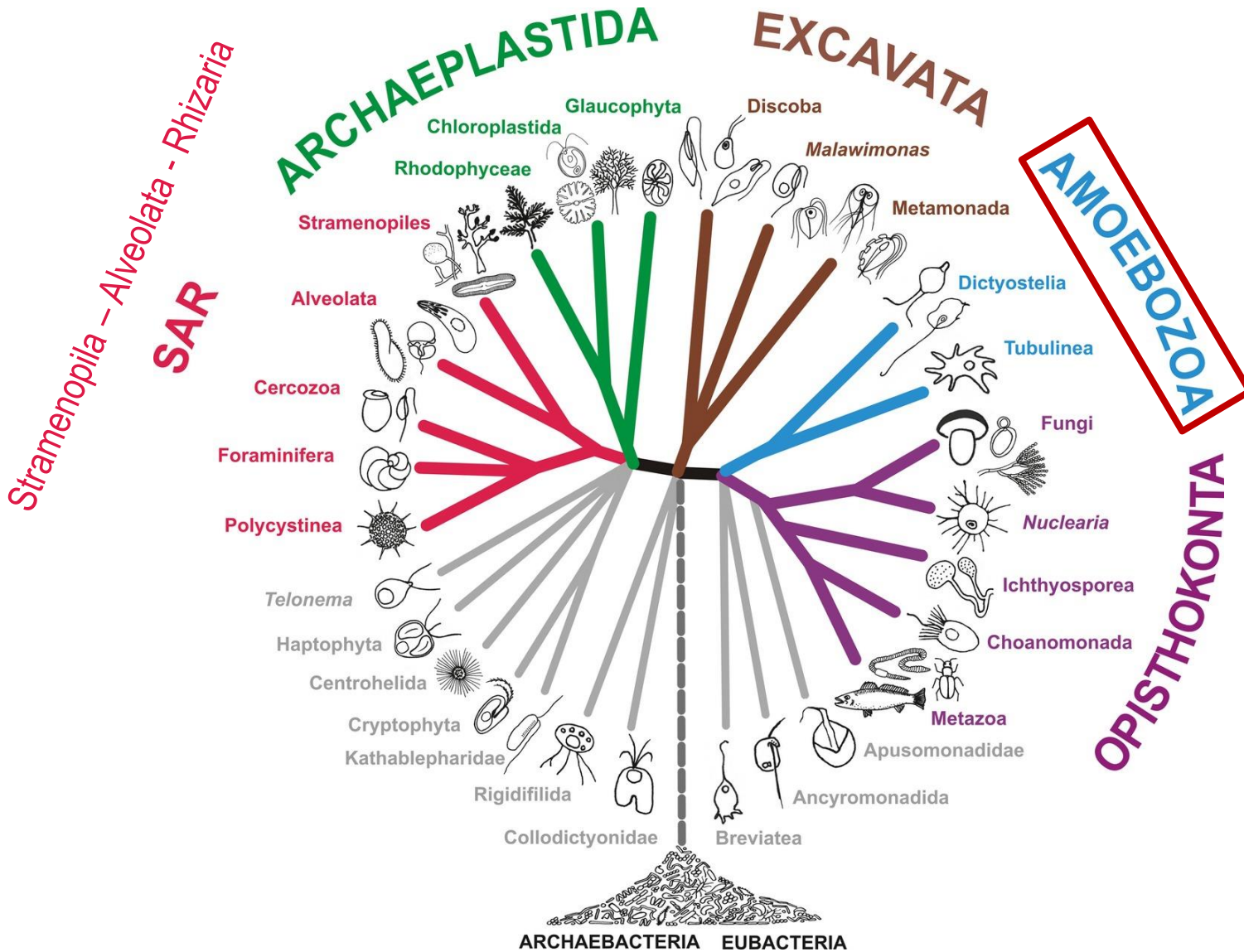


Naegleria gruberi

- non-pathogenic, free-living amoeba



5 supergroups = megagroups



Amoebozoa

- taxonomic group containing about 2,400 described species of amoeboid protozoa
- monophyletic supergroup
- blunt, finger-like, lobose pseudopodia
- phagocytosis as a primary mode of nutrition
- if present mitochondria with tubular cristae; many species secondarily lost mitochondria
- majority lack flagella
- some of them also called „**amphizoic amoebae**“
- two basic groups:
 - **Lobosa** - non flagellated amoebae with blunt, lobose pseudopodia
 - **Conosa** - both amoeboid and flagellated cells, characteristically with more pointed or slightly branching pseudopodia

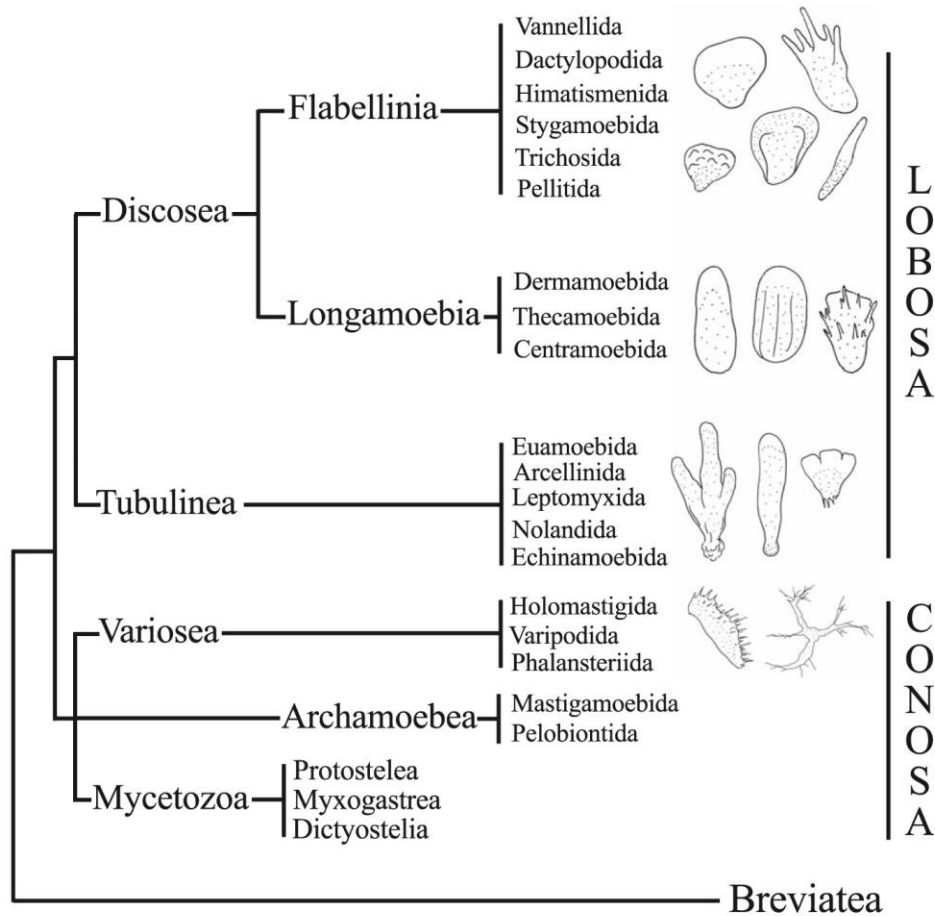
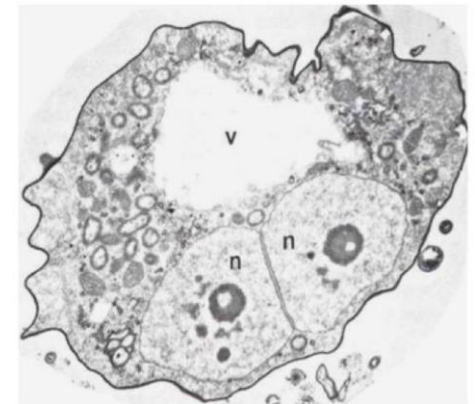
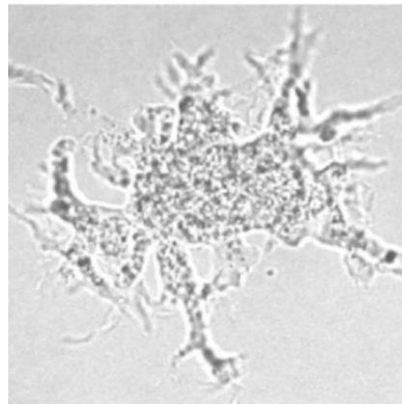
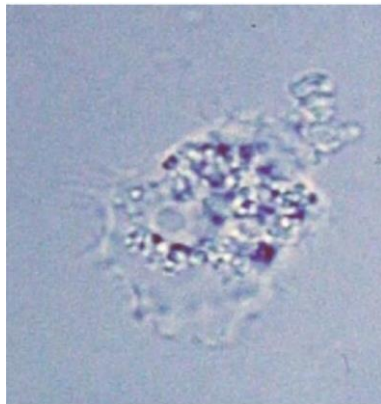


Figure 1. Proposed relationships among the major groups of Amoebozoa. Subphyla Lobosa and Conosa are each shown as holophyletic in conformity with multigene molecular trees and cytological considerations (Cavalier-Smith et al. 2004); however, on 18S rRNA trees either or both may appear paraphyletic or polyphyletic, probably because rapid radiation at the base of the tree makes it hard to resolve amoebozoan basal topology consistently using only relatively short sequences. Although core protostelids appear as four or five separate clades on a recent tree (Shadwick et al. 2009), its resolution does not allow to argue convincingly against their collective holophyly; at least three of them are probably more closely related to Macromycetozoa (Dictyostelea and Myxogastrea: Fiore-Donno et al. 2010) than to other Conosa. Orders shown only for non-Mycetozoa. Pelobiontida includes both Pelomyxididae and Entamoebidae. Mastigamoebida includes both Mastigamoebidae and Endolimacidae.

Lobosa: Acanthamoebidae - amphizoic amoebae

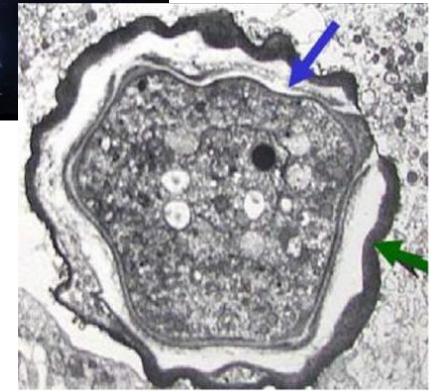
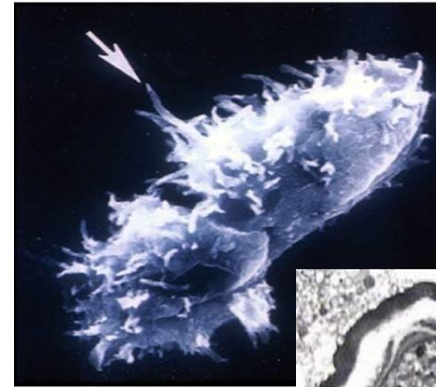
- invade a host and live as **parasites** within host tissue
- important pathogens:
 - *Acanthamoeba* spp. - about 130 cases of human **granulomatous amebic encephalitis (GAE)** , more than 3000 cases of human **amoebic keratitis (AK)**
 - *Balamuthia mandrillaris* - more than 100 cases of **GAE**
 - *Sappinia diploidea* - 1 or more cases (?) of human **amoebic encephalitis (AE)**



Amoebozoa - amphizoic amoebae

genus *Acanthamoeba*

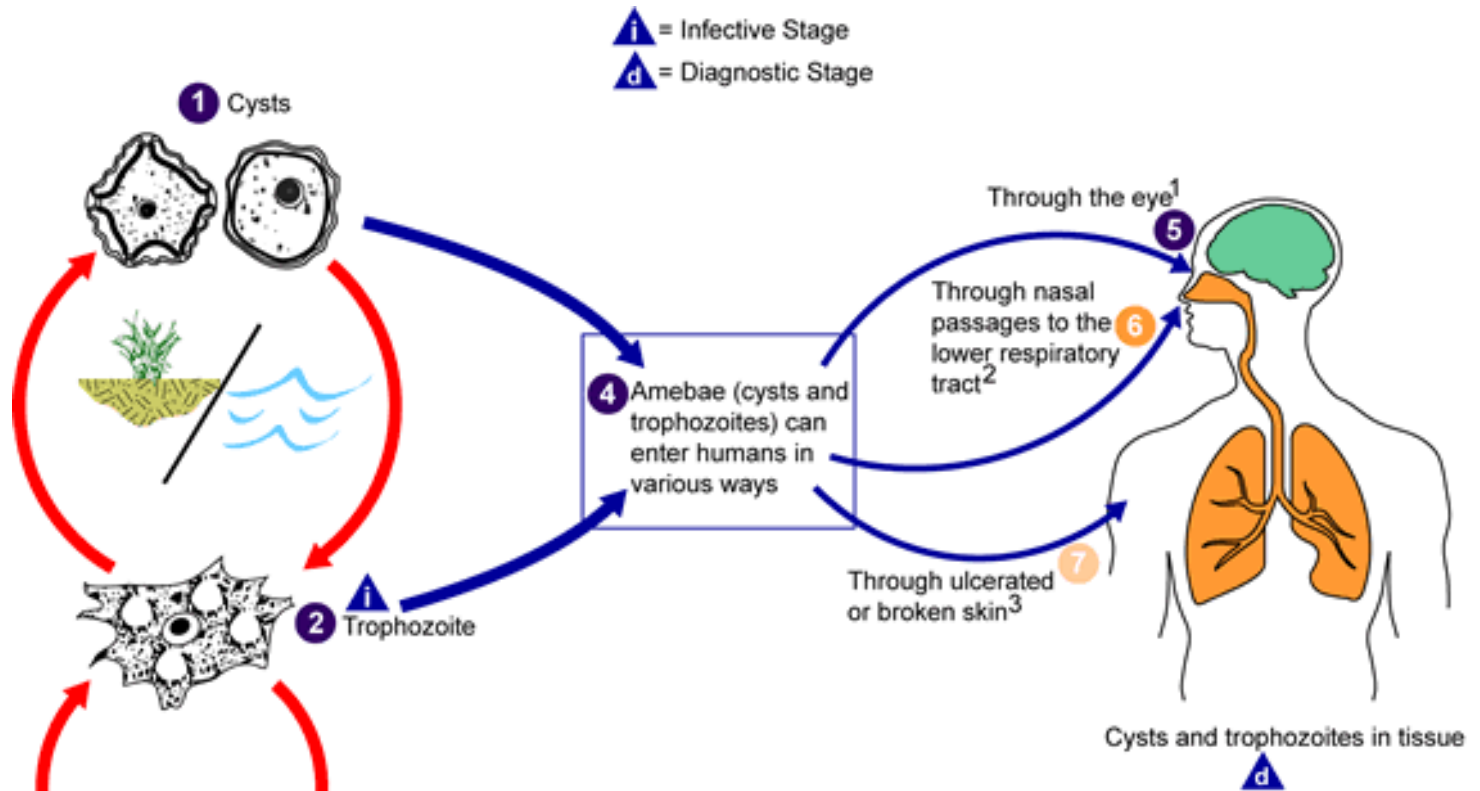
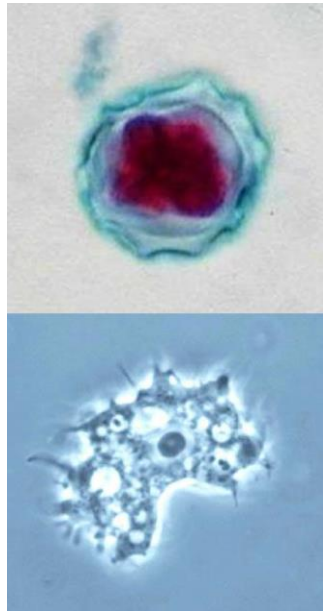
- thorn-like pseudopodial projections = **acanthopodia** („acanthus“ = spiny, thorny)
- **trophozoites** (15-30 μm) with slow movement, no flagellate stages
- **cyst with double-layered wall** - outer wrinkled **ectocyst** and inner **endocyst** (stellate, polygonal, oval or round), large nucleus with a central dense nucleolus
- cosmopolitan, ubiquitous occurrence in soil and water (fresh, brackish, and sea water) - commonly found in lakes, swimming pools, tap water, heating and air conditioning units, sewage, contact lens equipment
- can be also found in dental treatment units; dialysis machines; mammalian cell lines; vegetables; human nostrils and throats; human and animal brain, skin, lung tissues
- more than 24 species \Rightarrow **13 human species**: *Acanthamoeba culbertsoni*, *A. castelanii*, *A. astronyxis*, *A. hatchetti*, *A. rhyssodes*, *A. palestinensis*, *A. polyphaga*, ...
- 3 morphological groups based on size and character of trophozoites and cysts
- often harbouring pathogenic bacteria



<https://www.youtube.com/watch?v=pi2bElfM7hA>

<https://www.youtube.com/watch?v=qBldfJEMK0>

Life cycle of *Acanthamoeba* spp.



¹ Results in severe keratitis of the eye. **8**

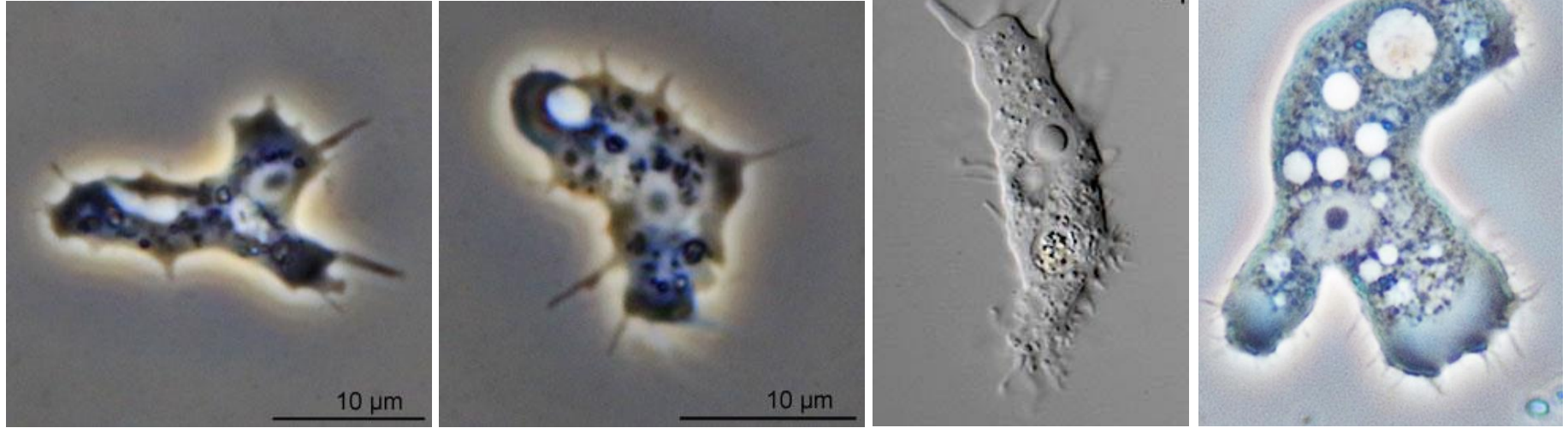
² Results in granulomatous amebic encephalitis (GAE) and/or disseminated disease **10** in individuals with compromised immune systems. **9**

³ Results granulomatous amebic encephalitis (GAE), disseminated disease **10**, or skin lesions **11** in individuals with compromised immune systems.

Life stages of *Acanthamoeba* spp.

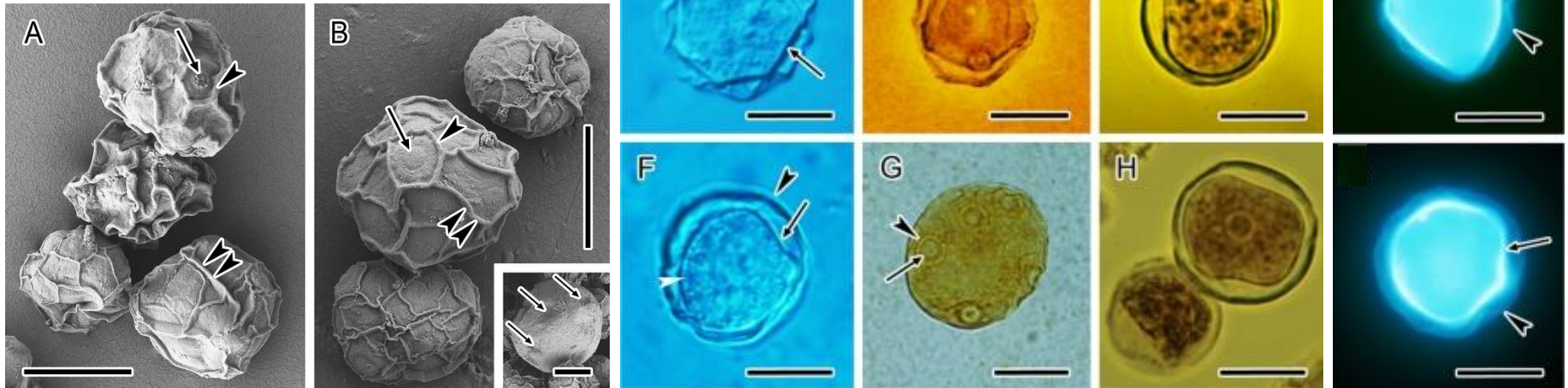
Trophozoites

<https://www.youtube.com/watch?v=yH4OrA7meio>
https://www.youtube.com/watch?v=08HqkXNNj_g&t=6s

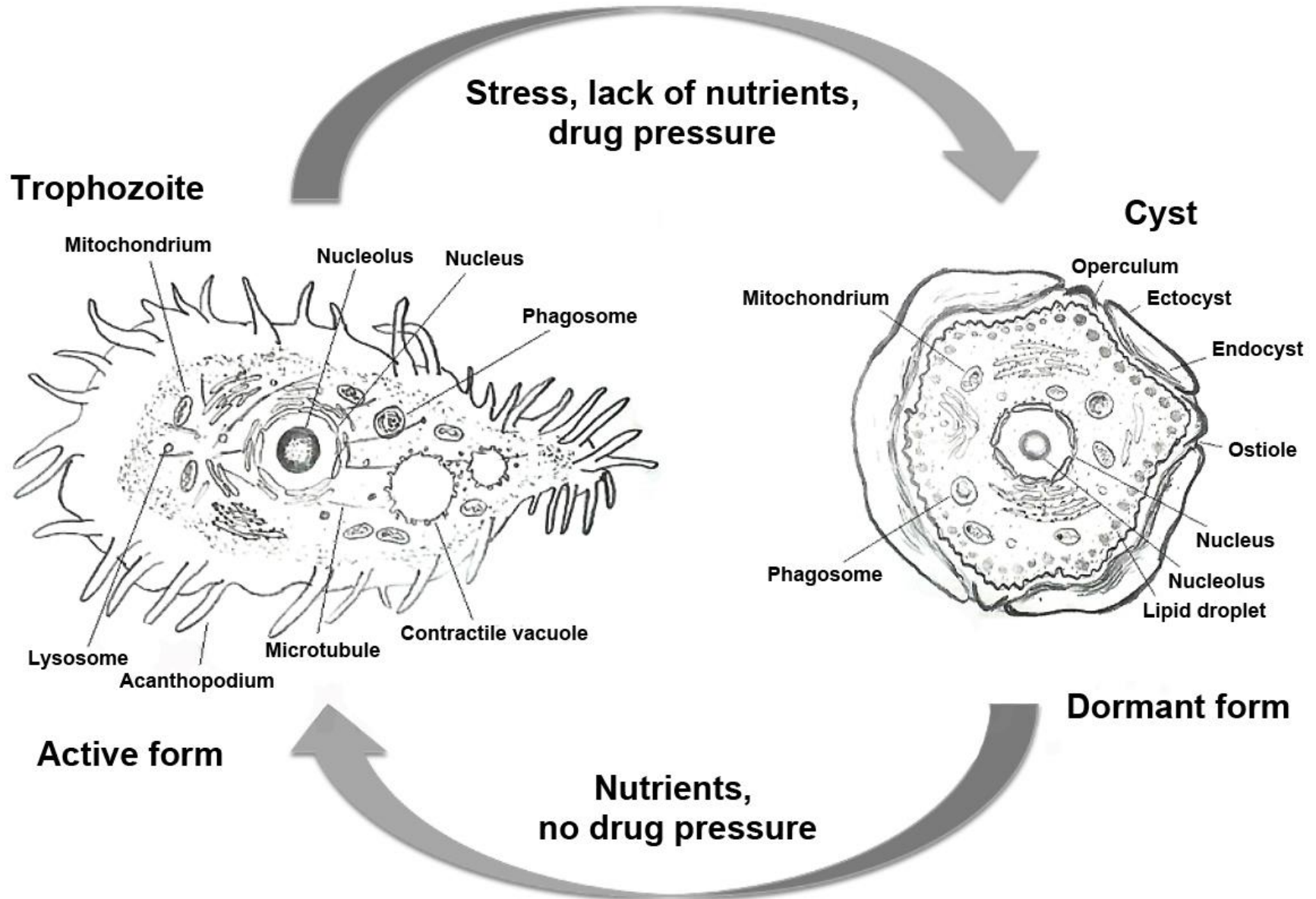


Cysts

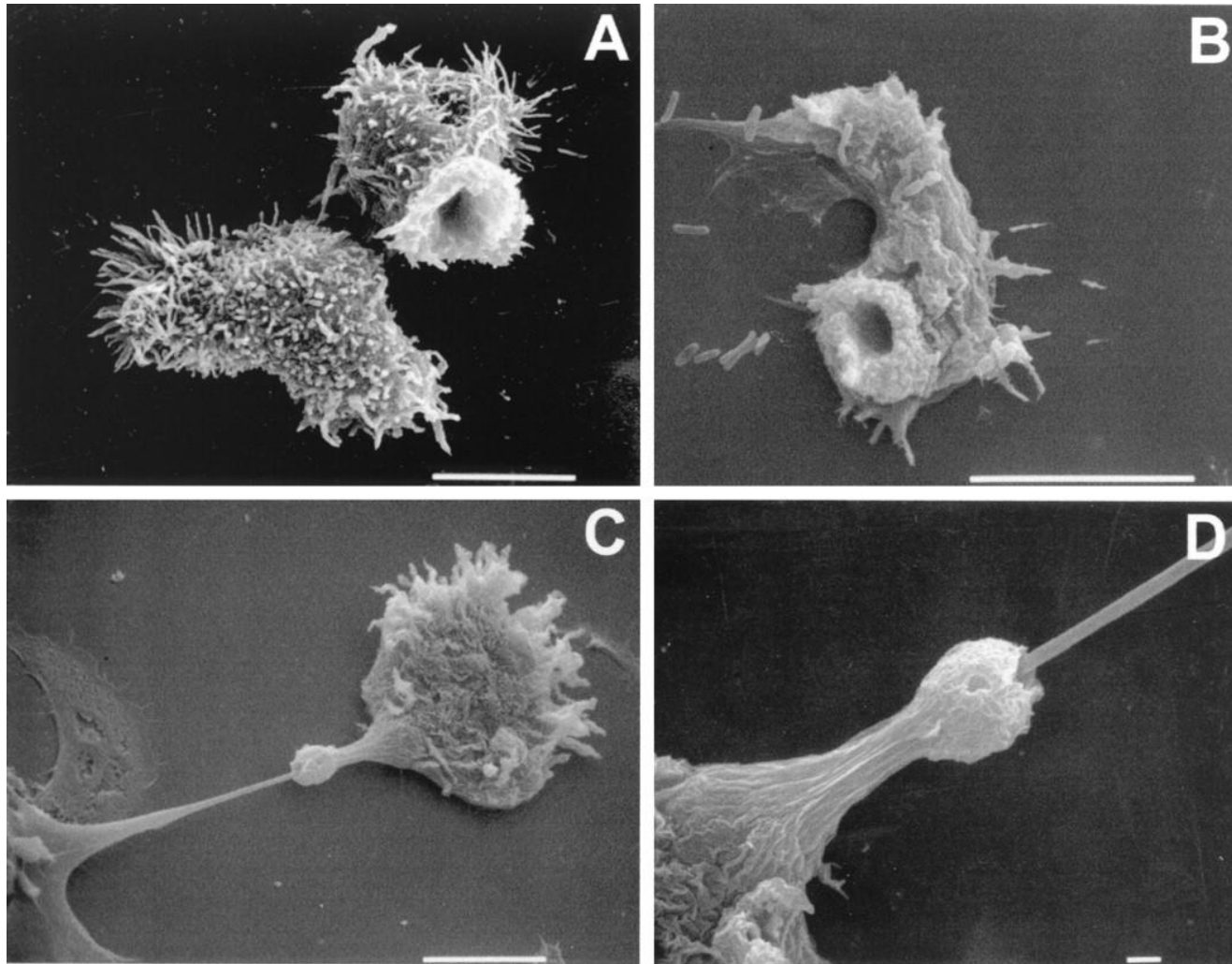
<https://doi.org/10.1038/s41598-019-41084-6>



Life stages of *Acanthamoeba* spp.

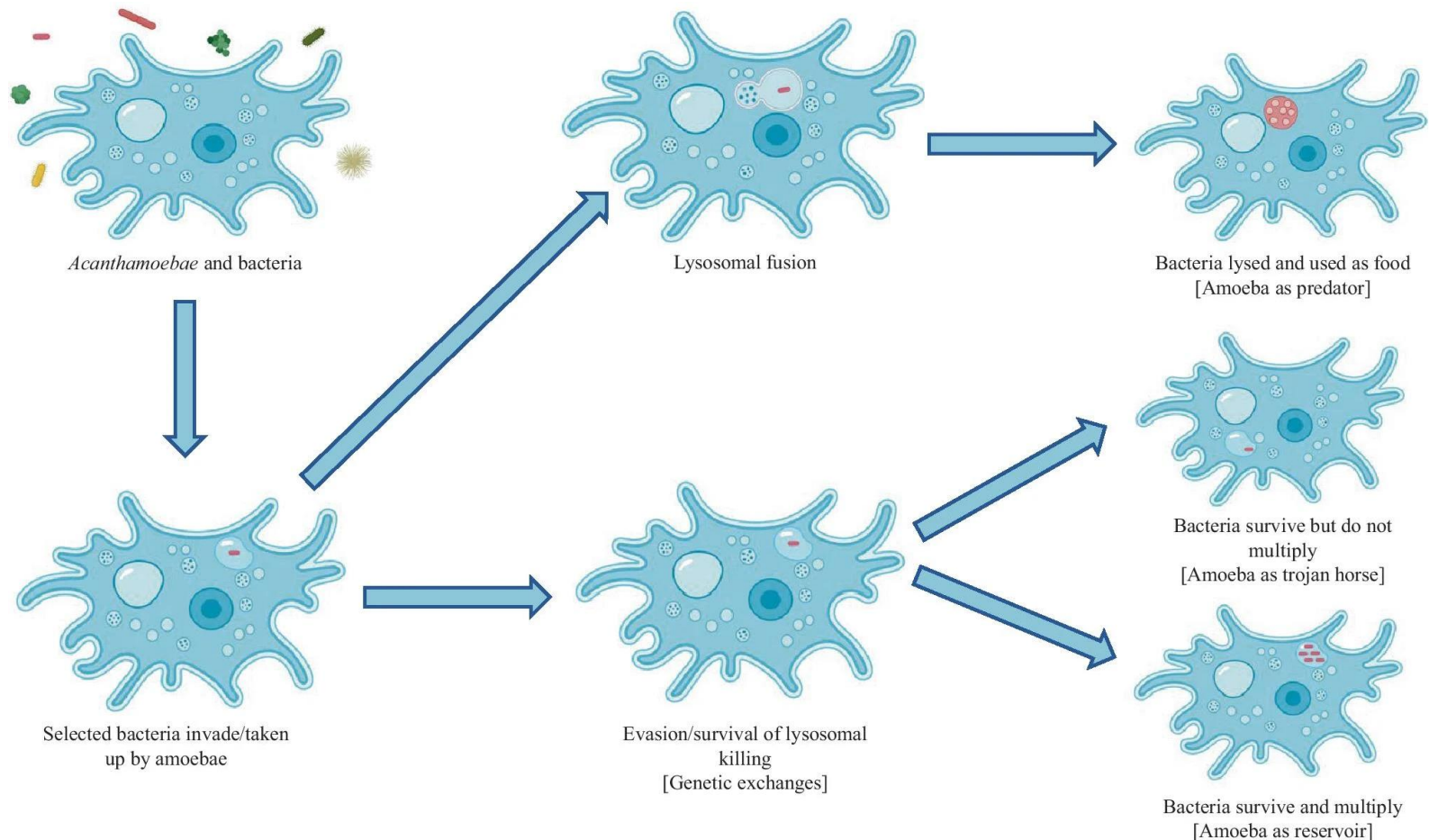


Active phagocytosis via amebostomes („food cups“)



SEM of trophozoites illustrating the presence of surface structures termed food cups. **A)** Food cups present on the surface of a trophozoite of *Acanthamoeba culbertsoni* are temporary structures that form and reform for the intake of bacteria, yeast, or cellular debris. **B)** Food cup present on the surface of *A. astronyxis* trophozoite used to ingest bacteria. **C)** Food cup present on the surface of an *A. castellanii* trophozoite in the apparent process of ingesting a cultured nerve cell. **D)** Higher magnification of trophozoite in C showing the food cup during putative ingestion.

Interaction of *Acanthamoeba* with bacteria



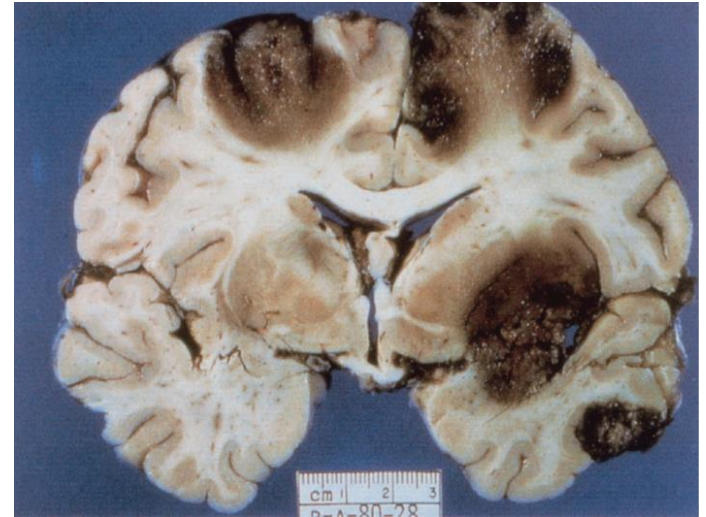
The figure describes how *Acanthamoeba* and bacteria interact, which may lead to the amoebae acting as predator, Trojan horse or reservoir. **Left:** *Acanthamoeba* in a bacteria-rich environment following which selected bacteria are taken up by the amoeba. **Middle section:** Two main options following intake of bacteria are depicted, namely, digestion or survival of the bacteria. **Right:** Bacteria surviving internalisation into *Acanthamoeba*, namely, using the amoeba as a transmission vehicle or replication site.

Diseases caused by *Acanthamoeba* infection

- *Acanthamoeba* can be spread to the eyes through contact lens use, cuts, or skin wounds or by being inhaled into the lungs
- most people are exposed to *Acanthamoeba* during their lifetime, but very few will become sick from this exposure
- forms of **acanthamoebiasis**:
 - ✓ **granulomatous amoebic encephalitis** (GAE)
 - ✓ *Acanthamoeba keratitis* (amoebic keratitis) (AK)
 - ✓ **disseminated form** = systemic opportunistic infection that can occur both with and without GAE (hematogenous dissemination, can affect the skin, sinuses, lungs, and other organs independently or in combination)
 - ✓ **cutaneous form** = skin infection
- GAE and disseminated forms are very rare and primarily affect immunocompromised humans, but disseminated infection can also affect healthy children and adults

Acanthamoeba granulomatous amoebic encephalitis (GAE)

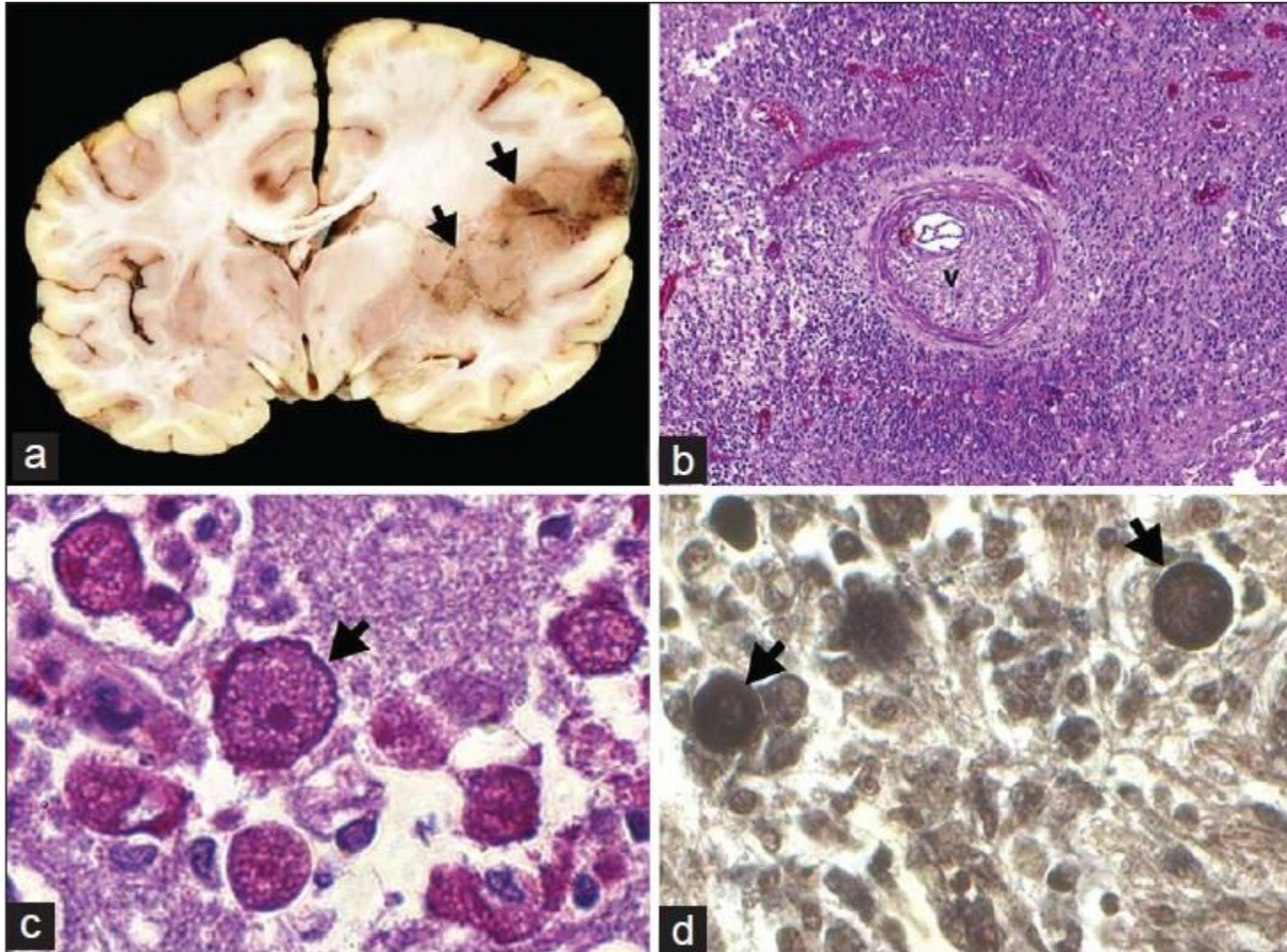
- rare form of *Acanthamoeba* infection (about 200 cases)
- chronic infection of brain and spinal cord
- spanning from several weeks to months
- humans with compromised metabolic, physiologic or immunologic functions



Clinical symptoms

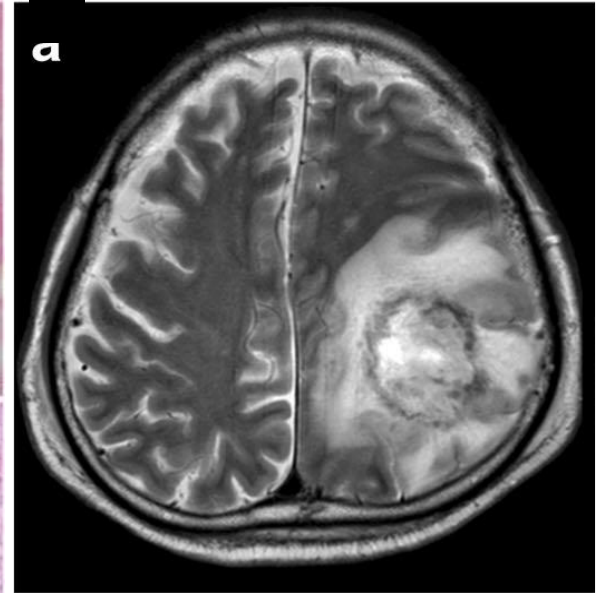
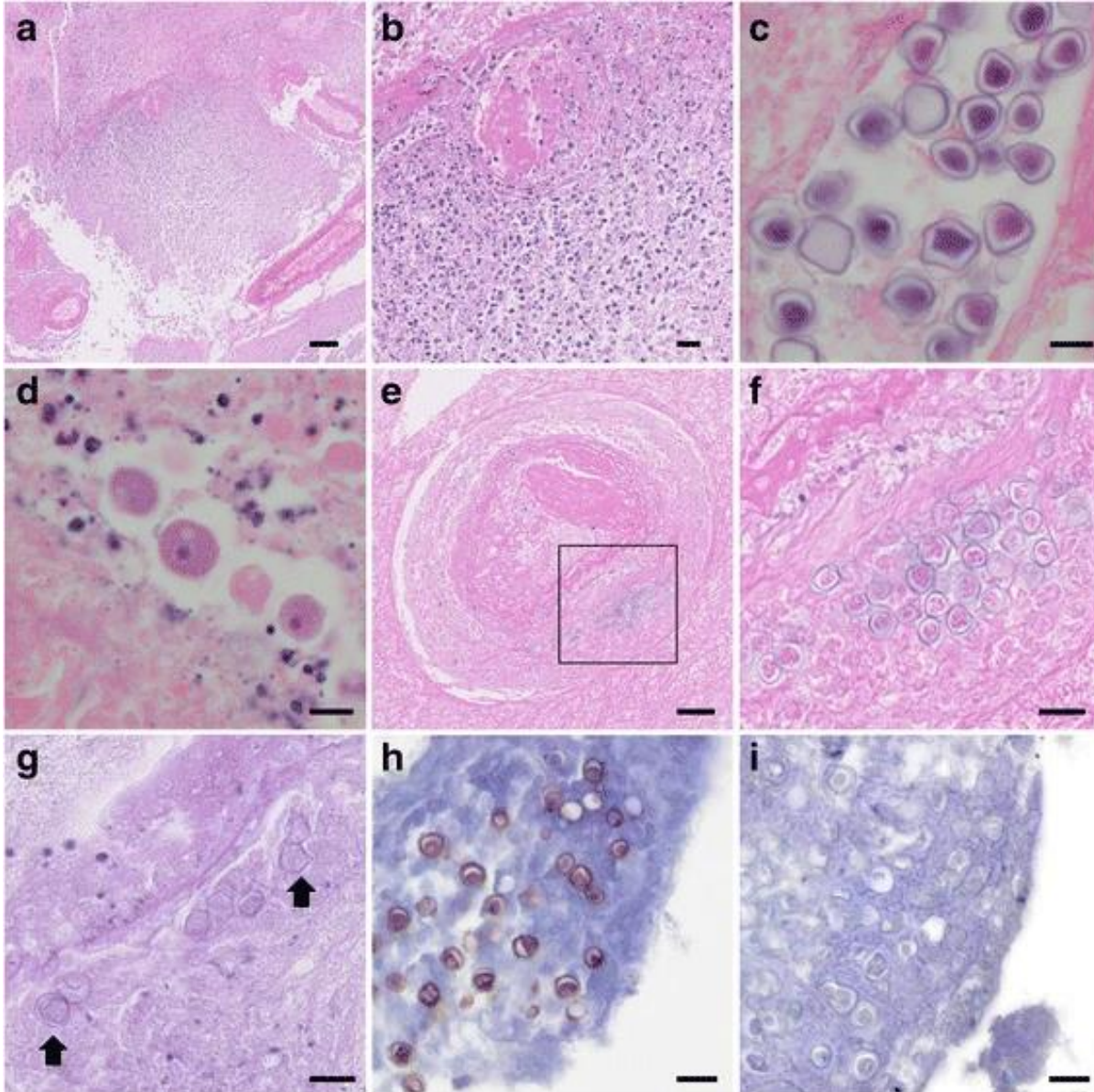
- **neurological manifestations and behavioural changes:**
 - ✓ mental status changes
 - ✓ loss of coordination
 - ✓ fever
 - ✓ muscular weakness or partial paralysis affecting one side of the body
 - ✓ double vision, sensitivity to light
 - ✓ other neurologic problems

Pathology of *Acanthamoeba* GAE



A) Large coalescing necrotizing hemorrhagic lesions involving the insular cortex and putamen with extensive perilesional oedema with compression of ipsilateral ventricle; **B)** dense vasculitis and inflammation; **C)** large trophozoites aggregating around vessels **D)** in addition to thick-walled cysts.

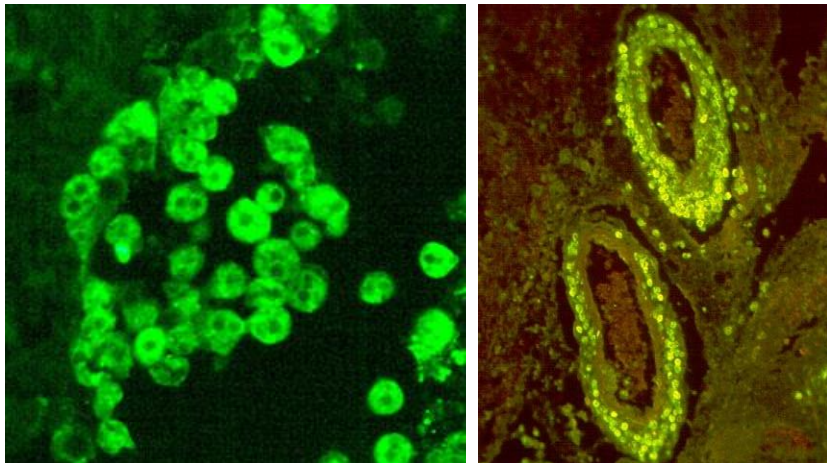
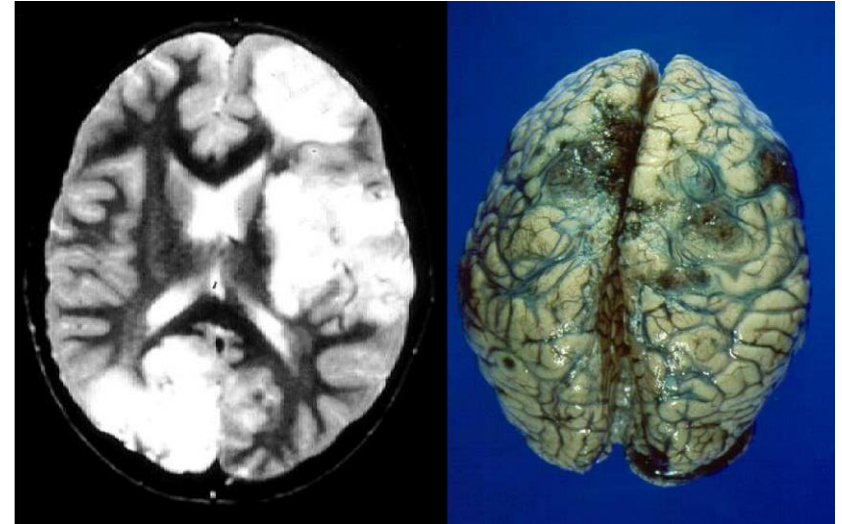
Pathology of *Acanthamoeba* GAE



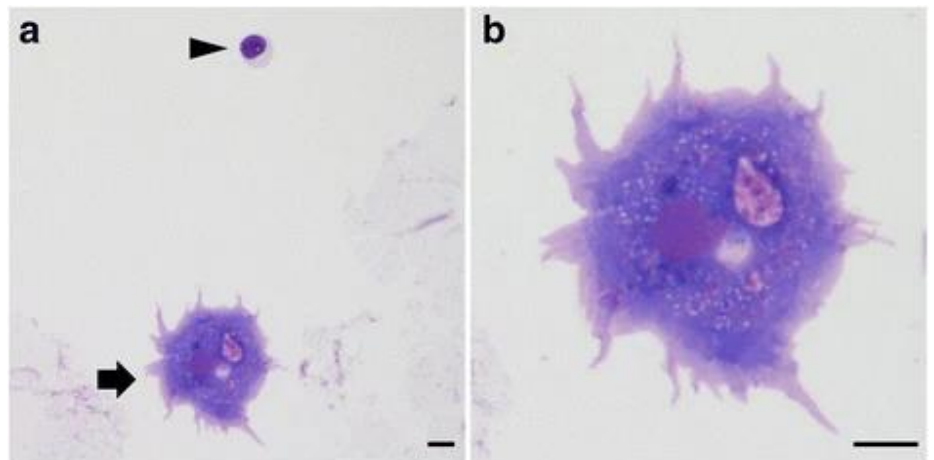
Histopathological findings of brain biopsy. **A-B)** Necrotic tissue with inflammatory cell infiltration and vessel hyalinization. HE. **C)** Amoebic cysts. HE. **D)** Trophozoites. HE. Both forms were observed in necrotic tissues. **E-F)** Cysts were also observed around blood vessels. **G)** Cysts showed faint positive in Periodic acid-Schiff stain (PAS) (arrows). **H-I)** Immunohistochemical staining of cysts – positive staining with antiserum against *Acanthamoeba* (**H**), but negative for *Balamuthia* (**I**).

Diagnosis of *Acanthamoeba* GAE

- ✓ localised necrotic foci of infection in brain tissue by neuroimaging
- ✓ definitive identification of amoebae upon brain biopsy or at autopsy and microscopic visualisation of trophozoites or cysts in tissue sections, cultivation of amoebae
- ✓ molecular methods

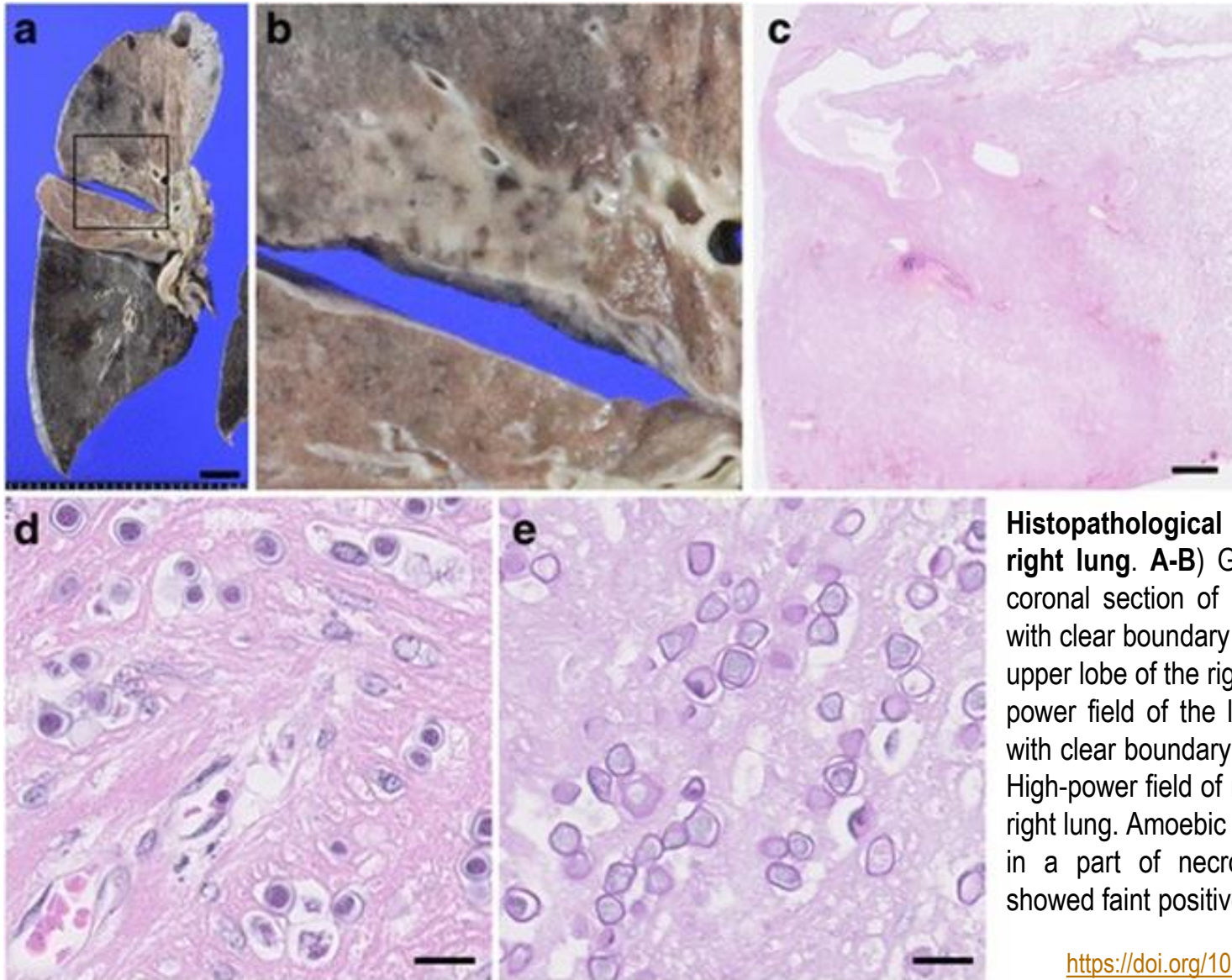


IFA of *Acanthamoeba*



Cytological findings of *Acanthamoeba* in CSF. Giemsa staining of a trophozoite (arrow), lymphocyte (arrowhead).

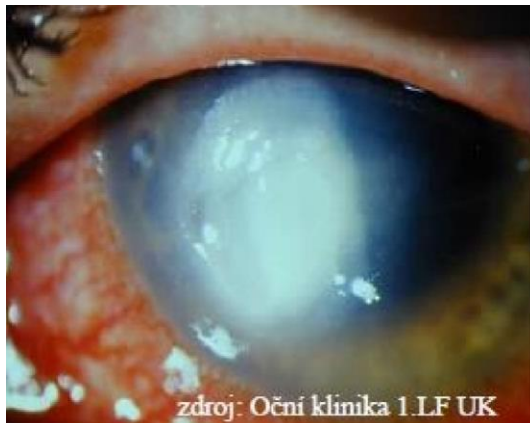
Pathology of disseminate acanthamoebiasis



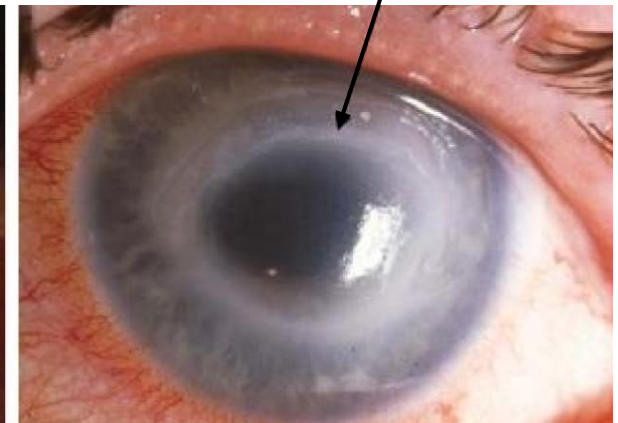
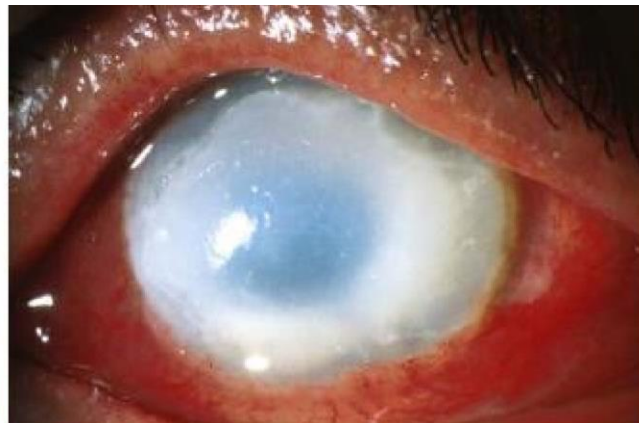Histopathological findings of the right lung. A-B) Gross appearance of coronal section of lung. Greyish lesion with clear boundary was observed in the upper lobe of the right lung. **C)** Very low-power field of the lung. Necrotic lesion with clear boundary was observed. **D-E)** High-power field of necrotic lesion in the right lung. Amoebic cysts were observed in a part of necrotic lesion (**D**) and showed faint positive in PAS (**E**).

Acanthamoeba keratitis (AK)

- acute localised infection of cornea
- in immunocompetent individuals following corneal trauma or as the result of poor hygiene in the care of contact lenses or contact lens cases
- typically, 1 eye infected
- 1974 UK and USA: 3 cases
- 2004 > 3000 cases
- 1995: first case in the Czech Republic
- therapy with variety of drugs



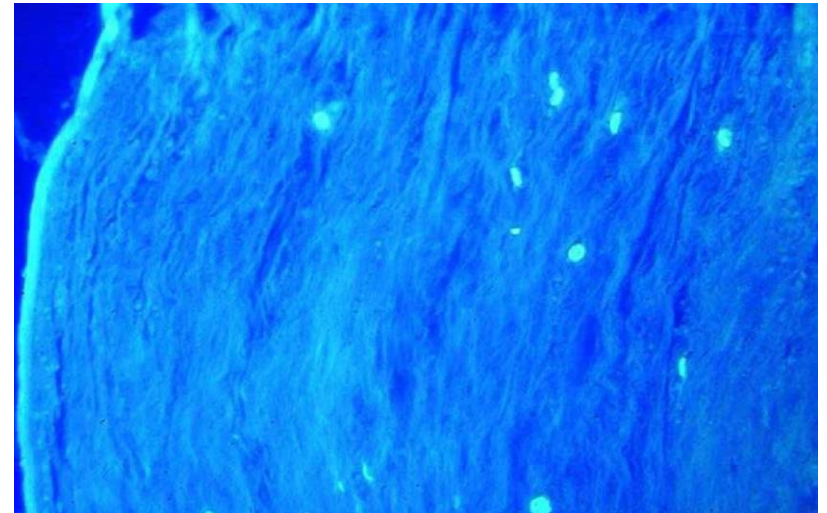
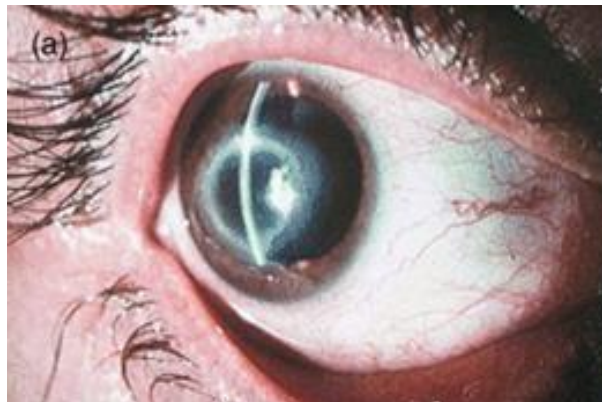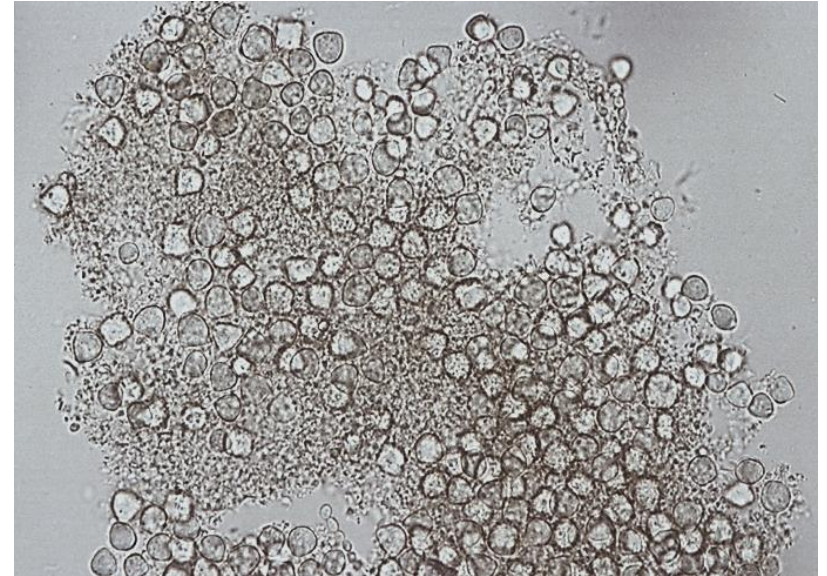
zdroj: Oční klinika 1.LF UK

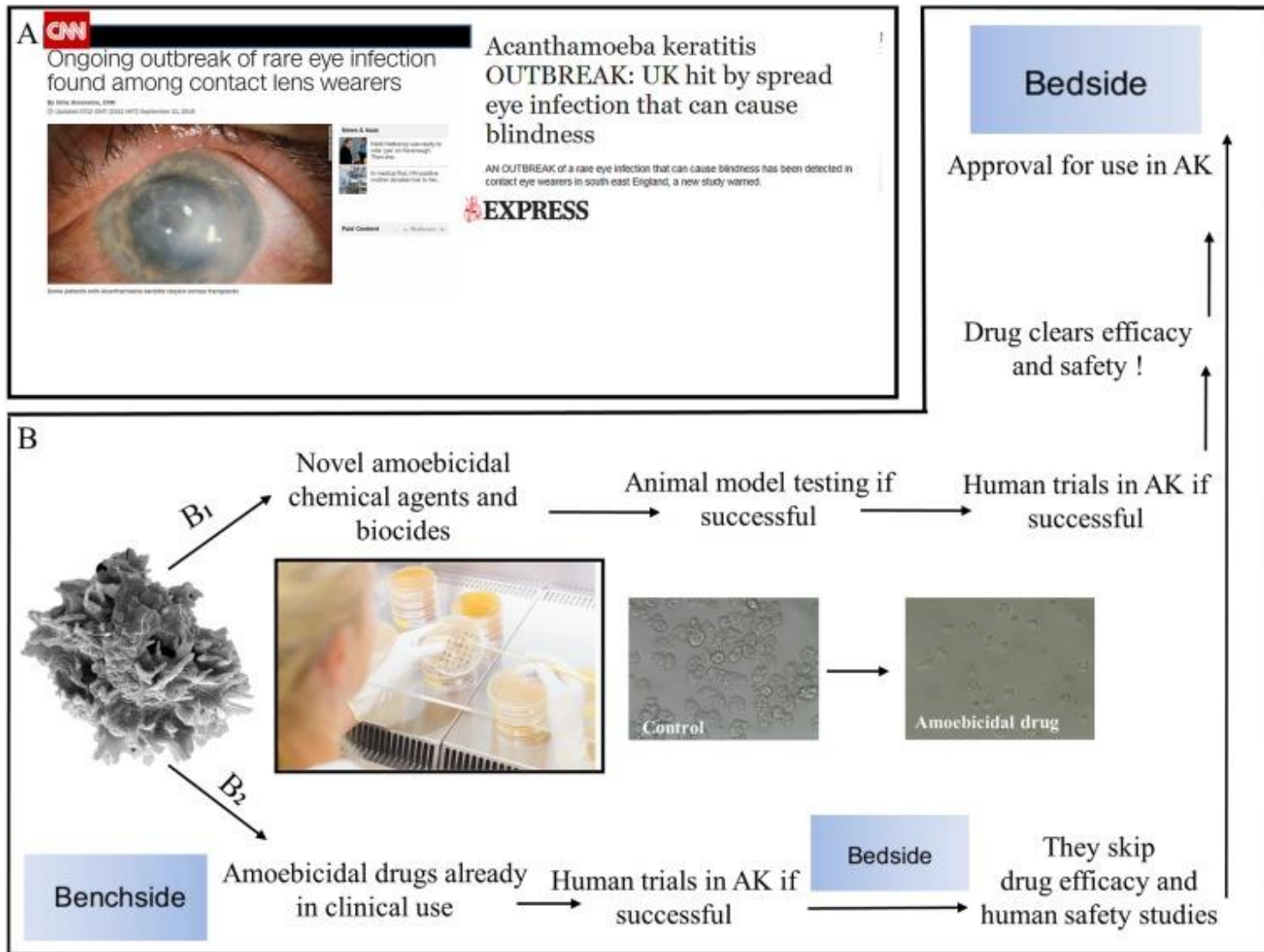


corneal ring infiltrate

Acanthamoeba keratitis (AK)

- 3 per 100,000 and around 85 % of cases occur in people who wear contact lenses
- exposure of the eye to contaminated water
- tap water should not be used to rinse contact contact lenses
- **corneal abrasion**
- **clinical symptoms:** watering of eyes, eye pain with photophobia, blurred vision and irritation are common
- cysts in cornea

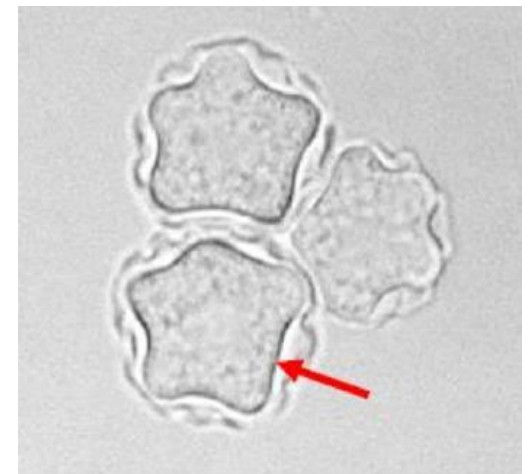
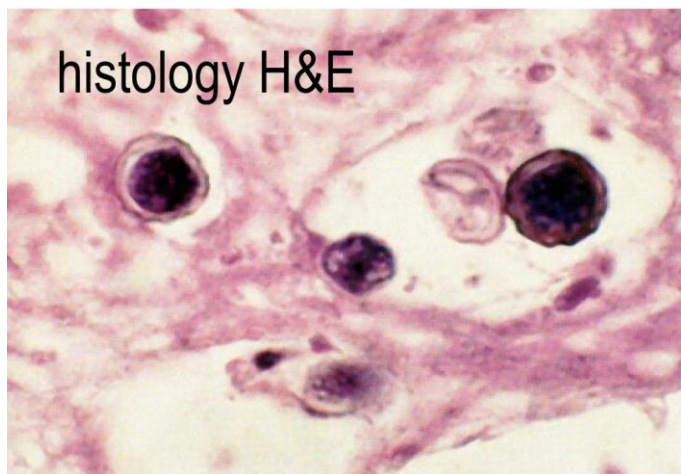
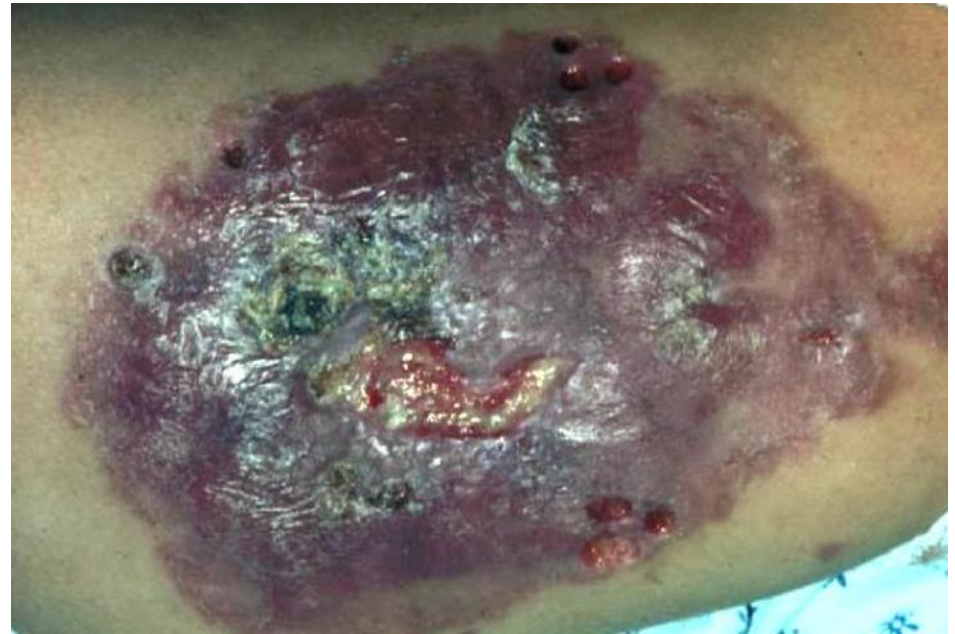


A) Recent mention of *Acanthamoeba* keratitis (AK) in leading news media and news outlets after an outbreak of AK in the UK. A similar epidemic of AK has occurred in the USA in the past. **B)** Superiority of FDA-approved drugs that have proven to kill amoeba trophozoites and cysts over novel chemicals and biocides (B1). The FDA-approved drugs would need to be tested only in human eye, as their safety studies have been completed in the past (B2). Note the effects of one of the FDA-approved drugs on *Acanthamoeba* trophozoites as compared to control.

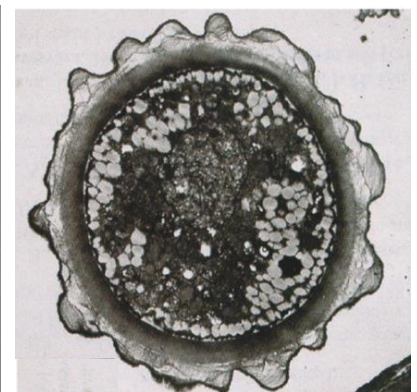
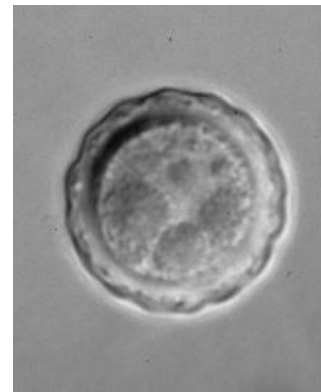
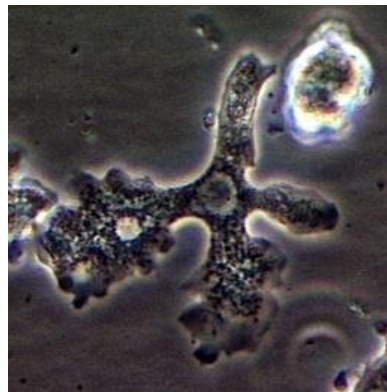
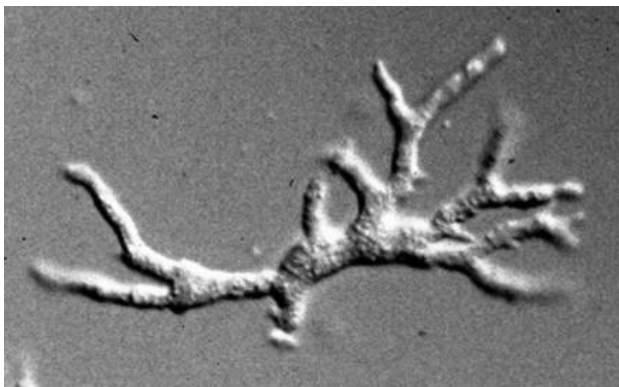

Cutaneous form of acanthamoebiasis

- nodular skin lesions
- HIV / AIDS patients
- disseminated skin form during GAE

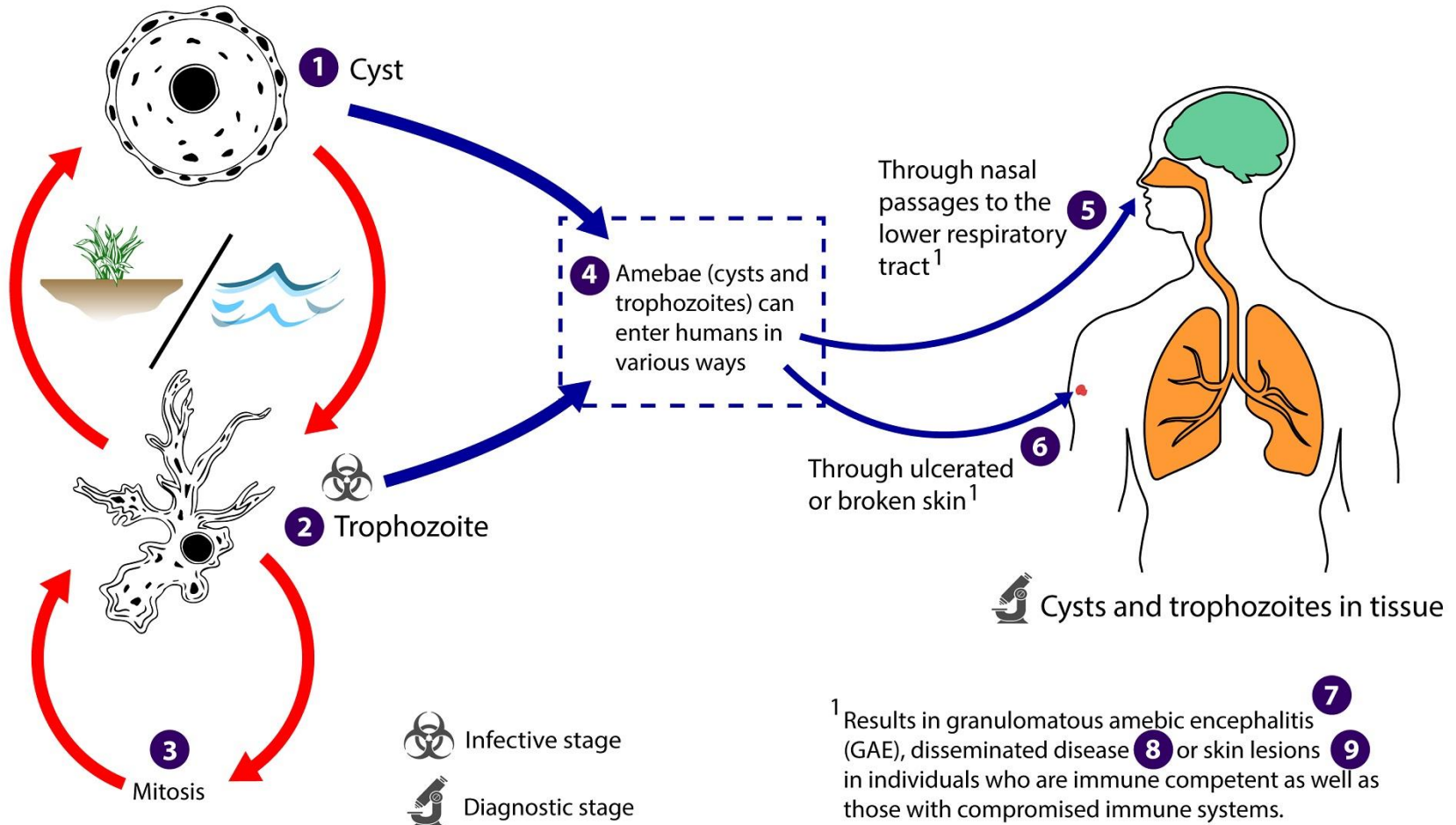


Balamuthia mandrillaris

- free-living amoeba naturally found in the environment
- 1986 first isolation from brain of a mandrill baboon that died in San Diego Wildlife Park
- larger than *Acanthamoeba* or *Naegleria*
- causing **GAE (BAE)** in humans and animals
- infection reports primarily originate from America, limited cases from Asia, Australia, and Europe
- pleomorphic **trophozoite** (30-120 μm) with **lobopodia** and a single nucleus
- **cyst** - wall formed by a thin, wavy **ectocyst**, fibrous **mesocyst** and a thick round **endocyst**; cytoplasm is filled with numerous pinocytotic vacuoles and/or vesicles



Life cycle of *Balamuthia mandrillaris*



¹ Results in granulomatous amebic encephalitis (GAE), disseminated disease ⁸ or skin lesions ⁹ in individuals who are immune competent as well as those with compromised immune systems.

https://www.youtube.com/watch?v=lwgZ_wECJ_4

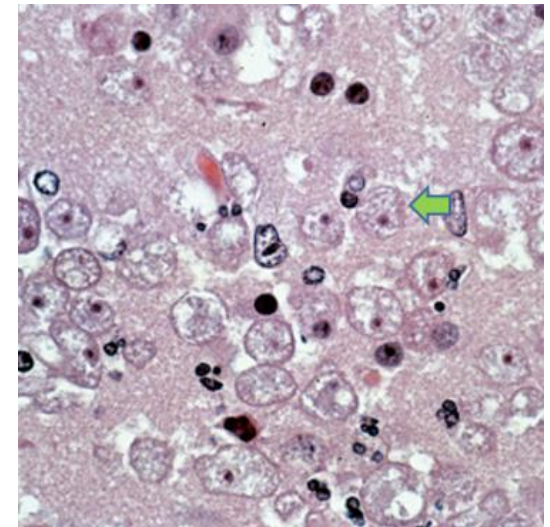
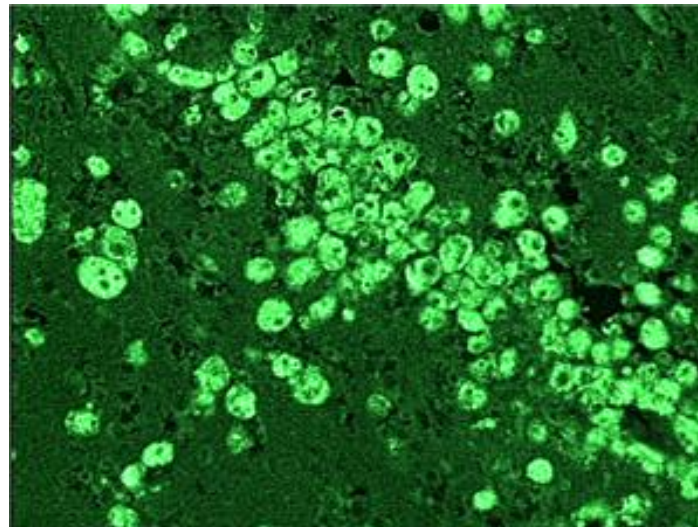
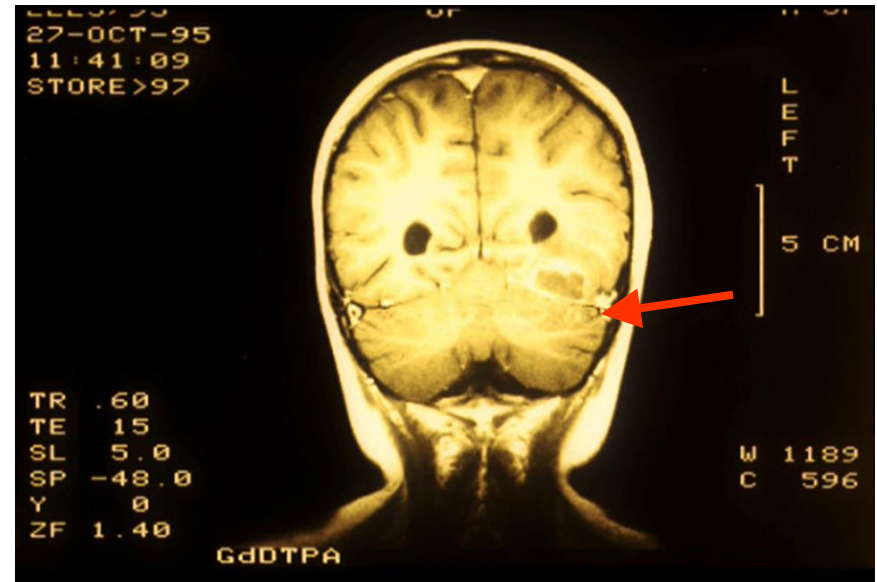
Symptoms of balamuthiasis

- immunocompromised people, including AIDS patients and intravenous drug users, but also immunocompetent patients
- **chronic disease** - weeks to as long 2 years, more than 200 cases worldwide
- can infect the skin, brain and other organs of the body
- disease can begin with a skin wound and can progress to the brain ⇒ **granulomatous amoebic encephalitis (GAE)**
- early symptoms of GAE: fever, headache, vomiting, lethargy, nausea
- other signs of GAE: mental health changes, seizures, weakness, confusion, partial paralysis, difficulty speaking or walking
- disease might appear mild at first but can become more severe over weeks to several months - often fatal, with a 90% death rate

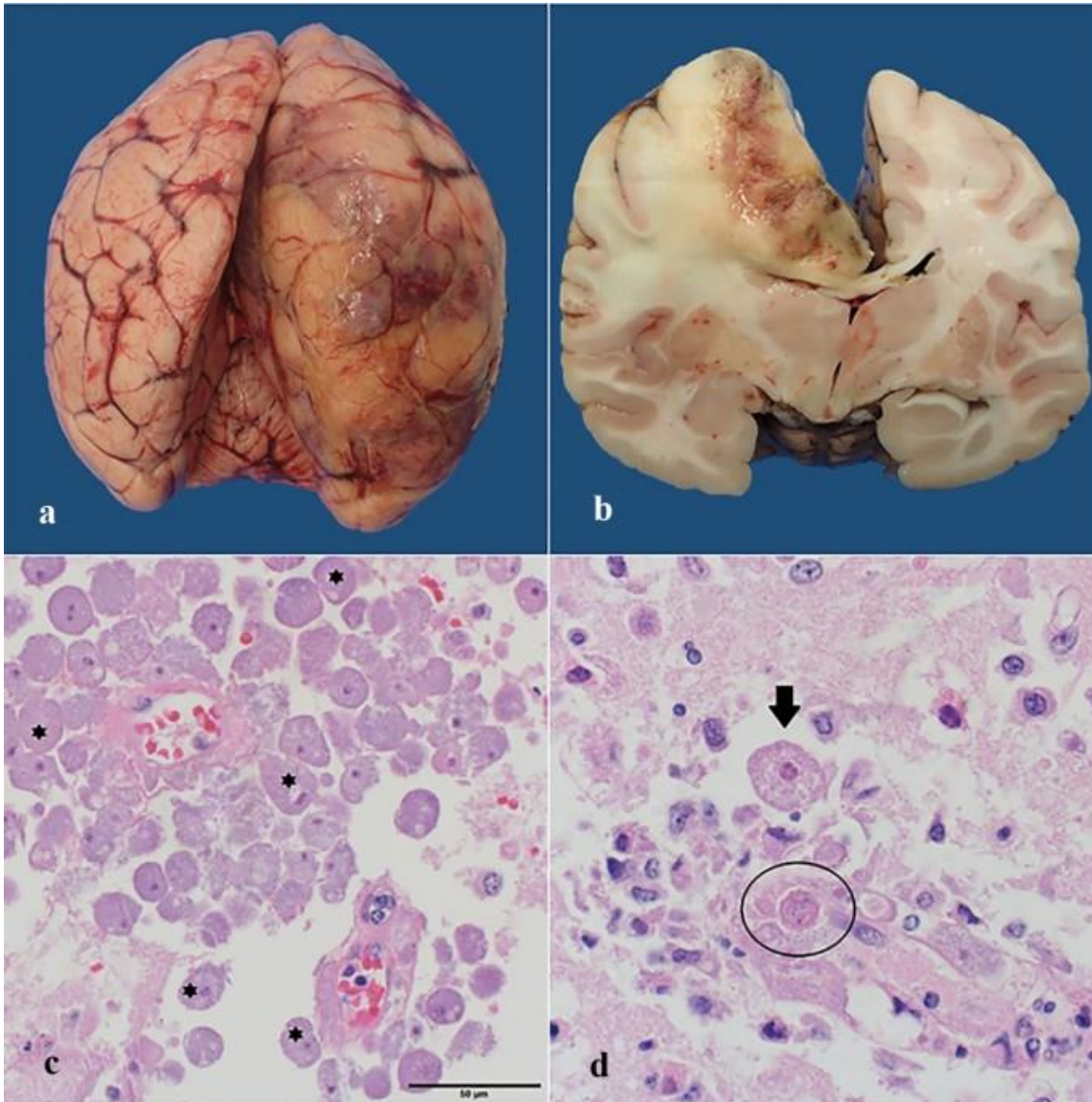
Diagnosis of balamuthiasis

- ✓ lesions in neuroimaging
- ✓ cultivation
- ✓ histology
- ✓ immunological detection
- ✓ molecular methods

Balamuthia GAE diagnosis can be **difficult** because symptoms are not specific to GAE



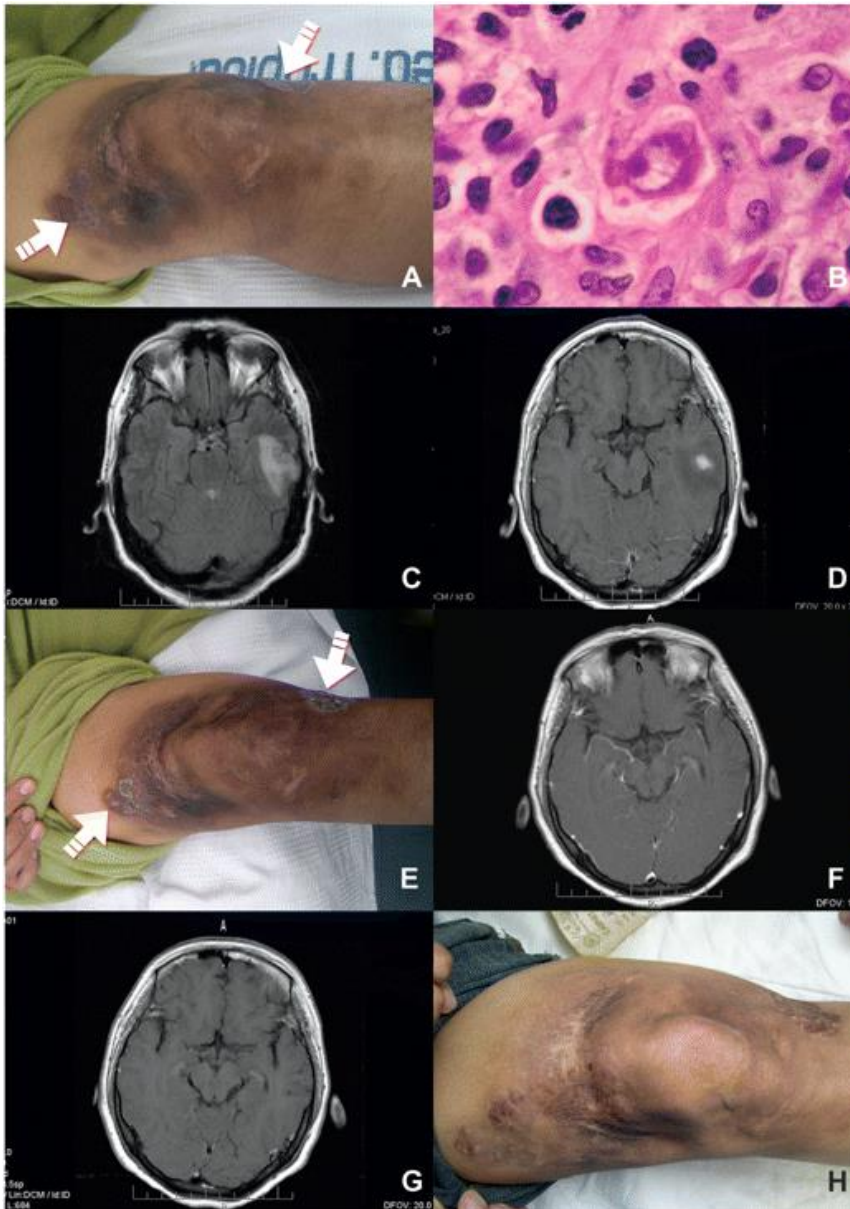
Pathology of *Balamuthia* GAE



Balamuthia mandrillaris in brain of Bornean orangutan. **A-B)** Right dorsomedial cerebral hemisphere is enlarged and distorted by oedema, haemorrhage, malacia and meningoencephalitis, that compresses the right lateral ventricle and abuts the corpus callosum. **C)** Intralésional, often perivascular, trophozoites (*) admixed with haemorrhage and oedema. **D)** Trophozoites have nuclei with up to four nucleoli (arrow), and there are rare amoeba cysts (circled). HE.

Pathology and treatment of *Balamuthia* GAE

Cutaneous and neurological involvement !!!



A) Cutaneous lesion on the right knee observed in February 2006 showing an indurated and violaceous plaque covering the entire knee with 2 papular lesions. **B)** Skin biopsy specimen showing a dense inflammatory infiltrate of the dermis with granulomas. An amoebic trophozoite is observed, with a nucleus that has a large, central nucleolus and vacuolated cytoplasm. HE. **C)** MRI obtained 7 days after the onset of neurologic symptoms (June 2007) showing hypersignal in the left temporal lobe. **D)** MRI (June 2007) showing a ring-enhancing lesion in the left temporal lobe. **E)** Follow-up of the left knee lesion 1 week after the patient had commenced treatment with miltefosine, albendazole, and fluconazole. Lesions abruptly changed, developing a scaly and crusty surface. **F)** MRI obtained 5 months after the start of treatment, showing significant improvement on the neurological lesions without evidence of contrast enhancing. **G)** MRI image 4 months after completion of treatment, showing the disappearance of the brain lesions. **H)** Follow-up of the healed left knee lesions (May 2008).

Comparative characteristics of free-living amoebae as etiological agents of amoebic encephalitis and keratitis

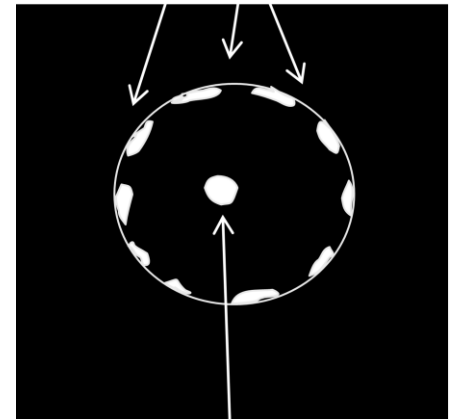
| | <i>Naegleria fowleri</i> | <i>Acanthamoeba</i> spp. (encephalitis) | <i>Acanthamoeba</i> spp. (keratitis) | <i>Balamuthia mandrillaris</i> | <i>Sappinia diploidea</i> * |
|------------------------------------|---|--|--|--|--|
| Life cycle | Three stages: amoeba, cyst and flagellate | Two stages: amoeba and cyst | | Two stages: amoeba and cyst | Two stages: amoeba and cyst |
| Distinctive morphological features | Vesicular nucleus; limacine movement of amoebae; flagellate stage; cyst with pores flush at the surface | Vesicular nucleus; finger-like pseudopodia projecting from surface; cyst wall with two layers and with pores | | Vesicular nucleus with single or multiple nucleoli; amoeboid and 'spider-like' movements in culture; cyst wall with three layers | Presence of two abutting nuclei in amoeba and cyst stages |
| <i>In vitro</i> cultivation | Axenic, bacterized and defined media; tissue culture cells; optimal growth at 37 °C and above | Axenic, bacterized, and defined media; tissue culture cells; growth at 37 °C (CNS isolates) or c. 30 °C (keratitis isolates) | | Axenic medium and tissue culture cells; optimal growth at 37 °C | Bacterized cultures |
| Disease | Primary amoebic meningoencephalitis (PAM) | Granulomatous amoebic encephalitis; cutaneous lesions; sinus infections | Amoebic keratitis | Granulomatous amoebic encephalitis; cutaneous lesions; sinus infections | Amoebic encephalitis; granuloma not seen |
| Prodromal period | Days | Weeks to months | Days | Weeks to months | Insufficient data |
| Epidemiology | Humans typically infected while recreating in warm fresh waters | Infection from soil, water, and air; present in hospital environment (water taps, hydrotherapy pools, air conditioning cooling towers) | Corneal trauma; contaminated lens solutions and lens cases | Infection from soil, water, and air | Present in soil, water and in air; originally identified from herbivore faeces. |
| Groups at risk | Children and young adults in good health | Typically, immunocompromised individuals | Mainly contact-lens wearers; low secretory IgA may contribute | Both immunocompetent (children and elderly) or immunocompromised individuals; Hispanic Americans | Insufficient data; single patient was immunocompetent |
| Disease at presentation | Headache, stiff neck, seizures, coma | Headache, stiff neck, behavioural changes, coma | Intense pain, photophobia, tearing | Headache, nausea, seizures, stiff neck, hydrocephalus; sinus infection; nodule formation in cutaneous infections | Headache, vomiting, photophobia, loss of consciousness; preceded by sinus infection |
| Clinical course | Fulminant disease; death within 1–2 weeks without treatment | Indolent subacute course; acute stage fatal in weeks | Penetration of amoebae into cornea; stromal ring due to PMN infiltrate | Indolent subacute course; once in acute stage, fatal in weeks | Patient recovered following treatment |
| Laboratory diagnostic methods | Amoebae present in CSF; no cysts seen in brain tissue; elevated PMNs in CSF | Cysts seen in brain tissue; IFA, IIF and PCR | Corneal scrapings or biopsy; confocal microscopy | Elevated CSF protein and pleocytic lymphocytosis, normal glucose; cysts seen in brain tissue; IFA. IIF and PCR | Binucleate amoebae in H&E-stained slides of brain tissue; PMNs and lymphocytes; immunostaining not available |
| Neuroimaging (CT and/or MRI) | Unremarkable; not helpful diagnostically | Presence of space-occupying or ring-enhancing lesions | Not relevant | Presence of space-occupying or ring-enhancing lesion | Mass seen in MRI; slight ring enhancement |
| Humoral reaction | Typically weak but titre rises with length of infection | Usually strong; protective value uncertain | IgA at corneal surface may be protective | Usually strong; protective value uncertain | Insufficient data |

Conosa: Archamoebidae

genus *Entamoeba*



- small amoebae, with a single nucleus and typically a single lobose pseudopodium
- flagella and centrioles absent
- reduced Golgi
- mitosomes instead of classical mitochondria
- uninucleated **trophozoites** convert into **cysts = encystation**
- number of nuclei in the cyst varies from 1 to 8 among species
- one of the characteristics used to distinguish species
- several species are found in humans and animals

morphology of nuclei in cysts
peripherally distributed chromatin



karyosom = endosom

Morphological characteristics of *Entamoeba* cyst

| | | | | | |
|-----------------------|------------------|------------------------------|---|--------------------------|----------|
| <i>E. coli</i> | <i>Homo</i> | 8 nuclei |  | | |
| <i>E. dispar</i> | } | } | | | |
| <i>E. histolytica</i> | | | | <i>Homo</i> | |
| <i>E. hartmani</i> | } | } | | | |
| <i>E. moshkovskii</i> | | | | free-living, <i>Homo</i> | 4 nuclei |
| <i>E. invadens</i> | | | | reptiles | |
| <i>E. ranarum</i> | | | | frogs | |
| <i>E. gingivalis</i> | <i>Homo</i> | no cyst, originally 4 nuclei | | | |
| <i>E. chattoni</i> | apes | 1 nucleus |  | | |
| <i>E. polecki</i> | <i>Homo, Sus</i> | | | | |

Morphological characteristics of *Entamoeba* cyst

group „*histolytica*“ - nucleolus centrally

E. histolytica

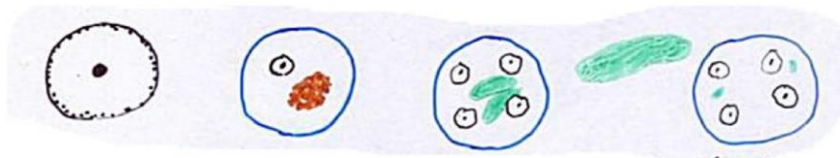
E. dispar

E. moshkovskii

E. hartmani

E. invadens

E. ranarum



group „*gingivalis*“

- nucleus „*histolytica*“
- no cysts
- originally 4 nuclei

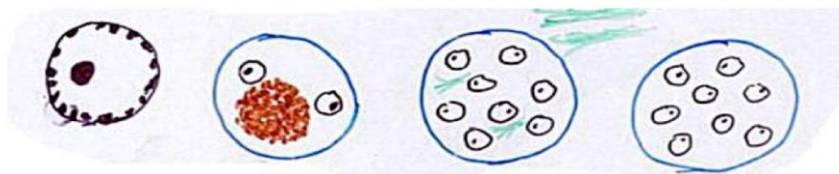
group „*coli*“ - nucleolus eccentric

E. coli

E. muris

E. gallinarum

E. cuniculi



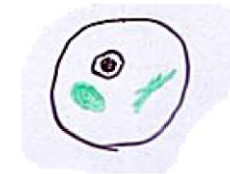
group „*bovis*“

E. bovis

E. ovis

E. polecki

E. chattoni



genus *Entamoeba* – group „*histolytica*“

- intestinal **trophozoites** (10-60 μm vs. 4-12 μm in *E. hartmanni*)
 - ✓ eruptive lobopodia
 - ✓ ring of peripheral granules at inner surface of nuclear membrane
- **cysts** (10-20 μm) with 4 nuclei

E. dispar

- non-pathogenic
- formerly "non-pathogenic strains of *E. histolytica*"

E. moshkovskii

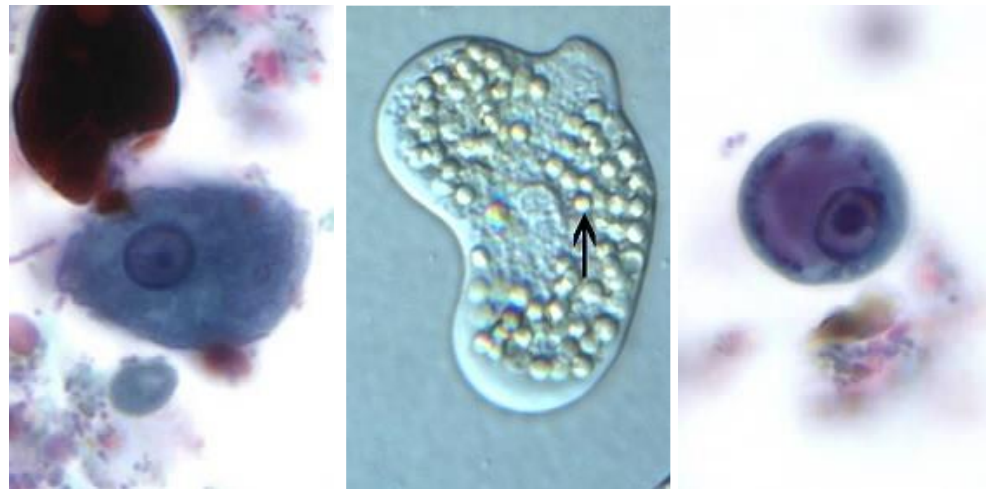
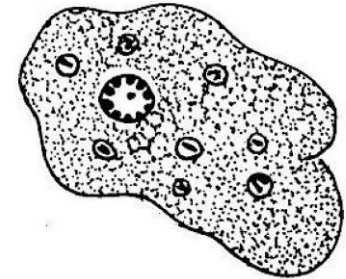
- non-pathogenic

E. hartmanni

- non-pathogenic

E. histolytica

- potentially **pathogenic**

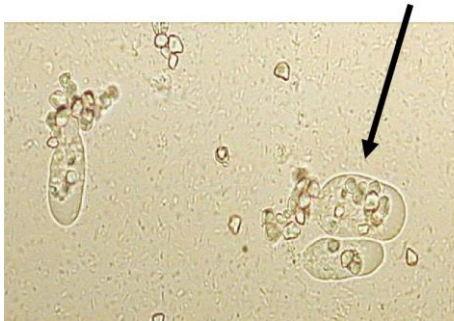

<https://www.youtube.com/watch?v=d5b4eNhlhgQ>

<https://www.gettyimages.ae/detail/video/entamoeba-histolytica-parasites-stock-video-footage/618597219>

Amoebic dysentery due to *Entamoeba histolytica*

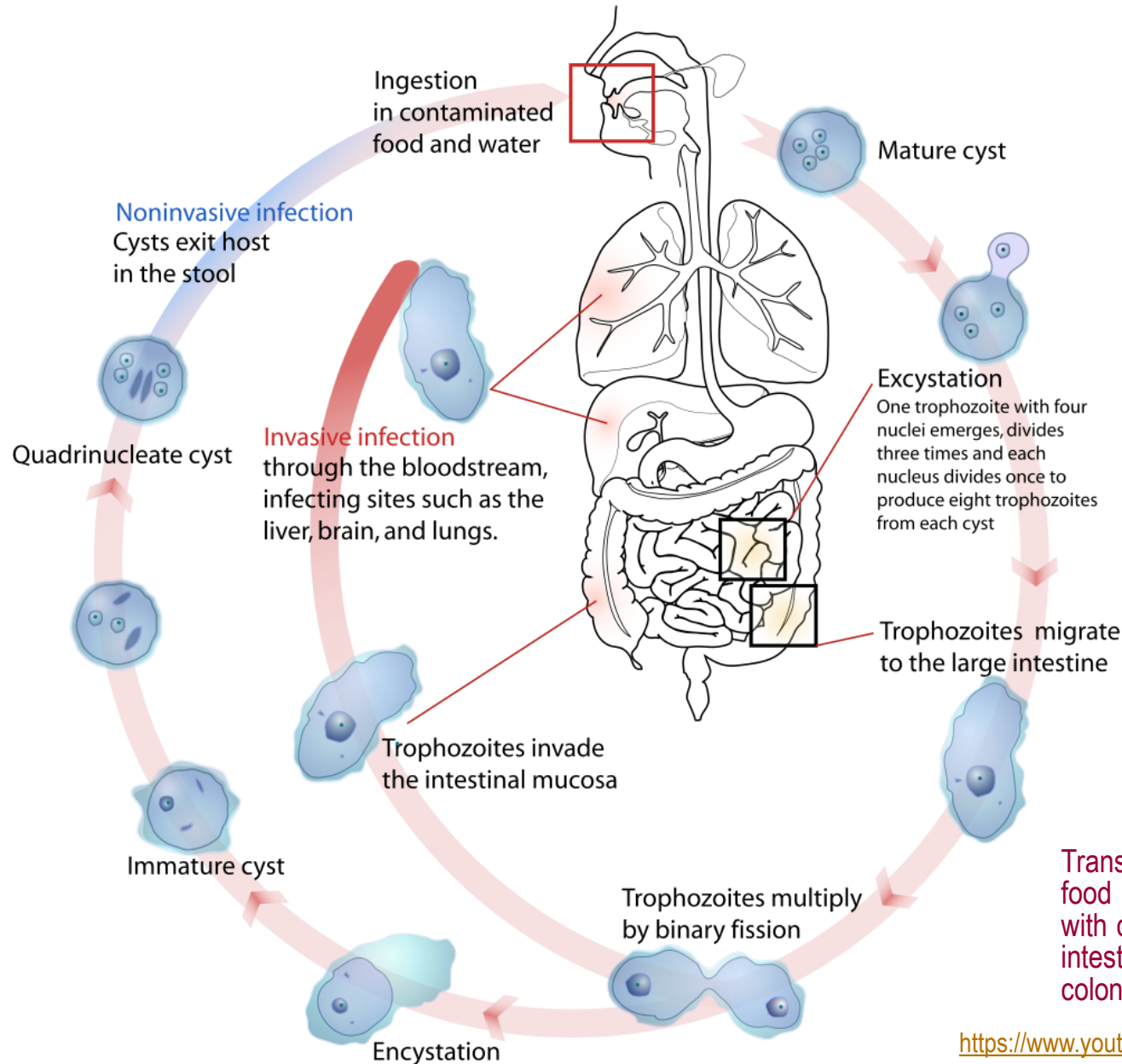
- infecting humans (about 50 million people worldwide) and other primates
- mammals such as dogs and cats can become infected transiently
- previously, 10 % of the world's population was thought to be infected, but these estimates preceded the discovery that at least 90% of these infections were caused by *E. dispar*
- about 10-20 % of infection with *E. histolytica* causes disease - in response to unknown stimuli, trophozoites move through the mucus layer and start the pathological process
- trophozoites - **forma minuta** x **forma magna** (erythrophagocytosis)



- ✓ heat stress, physical exertion
- ✓ constriction of visceral vessels
- ✓ abnormal function of intestinal mucosal cells
- ✓ disruption of intestinal biocenosis
- ✓ hypoxia
- ✓ change in the redox potential of the intestinal mucosa



Amoebic dysentery due to *Entamoeba histolytica*

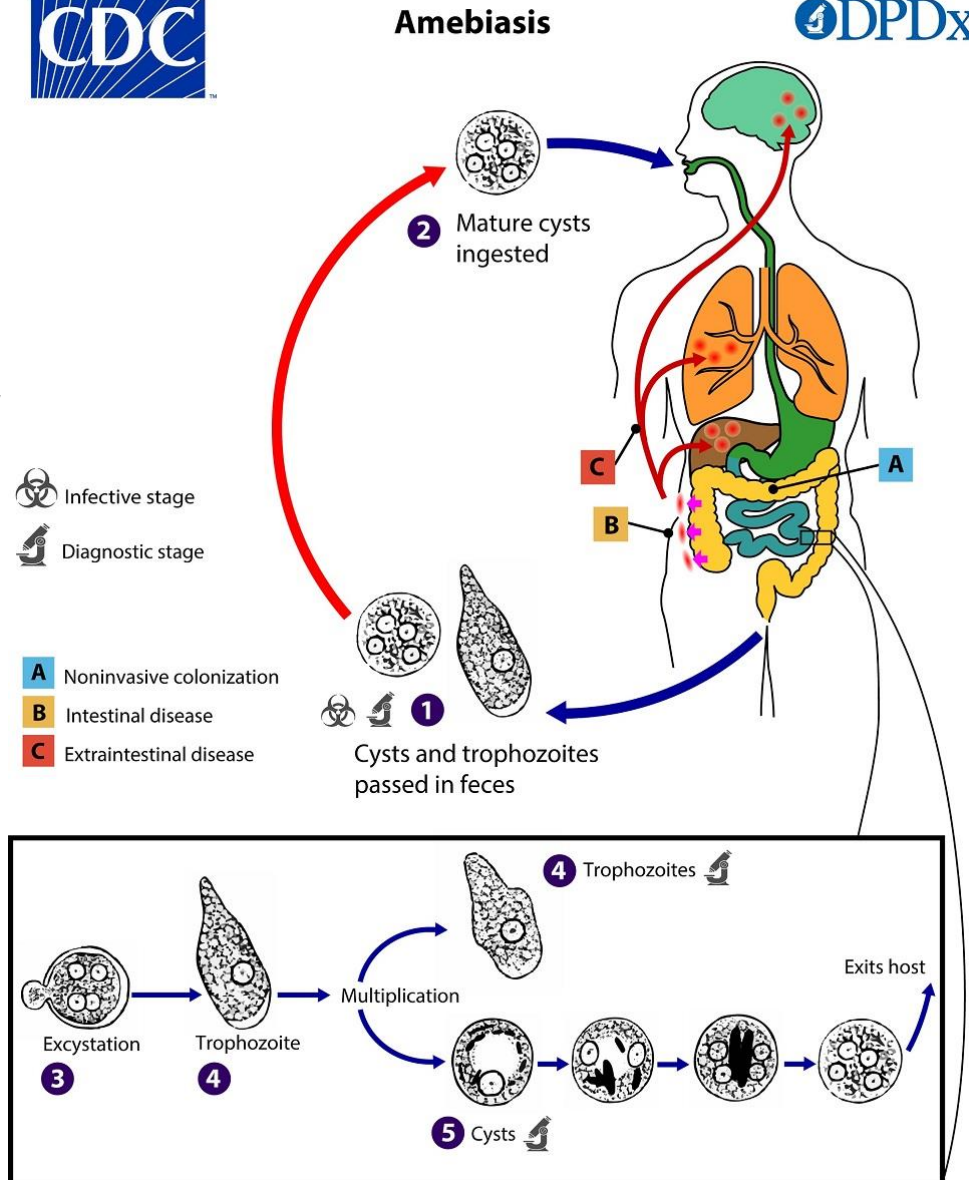


Transmission via ingestion of food and water contaminated with cysts, which excyst in small intestine to the trophozoites that colonise the large intestine

New concept of amoebic dysentery due to *E. histolytica*

- *Entamoeba histolytica*, is the causative agent of amoebic dysentery and amoebic liver abscess (entamoebiasis)
- one of the leading causes of death from parasitic diseases
- closely related *E. dispar* is morphologically indistinguishable
- *E. dispar* is a commensal - not causing disease in humans, even in immunocompromised individuals
- highly prevalent in areas of poor sanitation

Morphologically-identical species of *Entamoeba*, including *E. dispar*, *E. moshkovskii* and *E. bangladeshi*, are generally not associated with disease although investigations into pathogenic potential are ongoing.

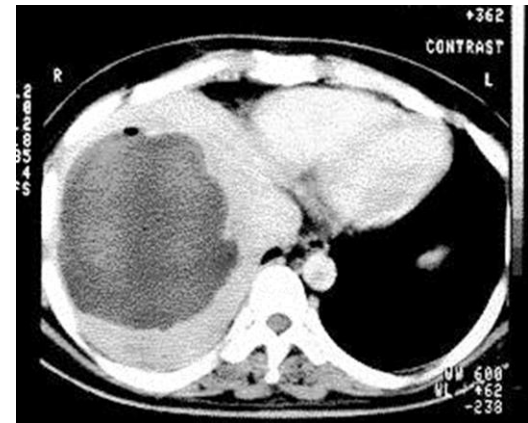
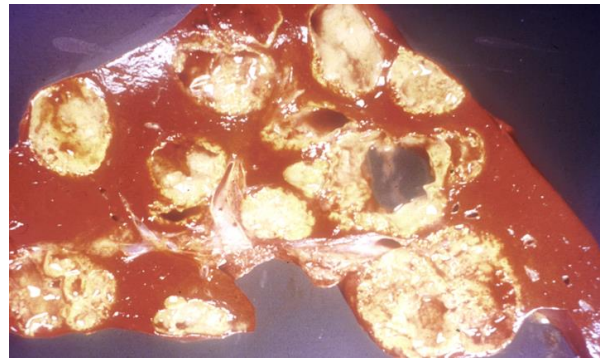


Amoebic dysentery due to *Entamoeba histolytica*

- about 10-20 % of people infected with *E. histolytica* become sick from infection
- majority of infections restricted to intestinal lumen (“luminal amebiasis”) are asymptomatic

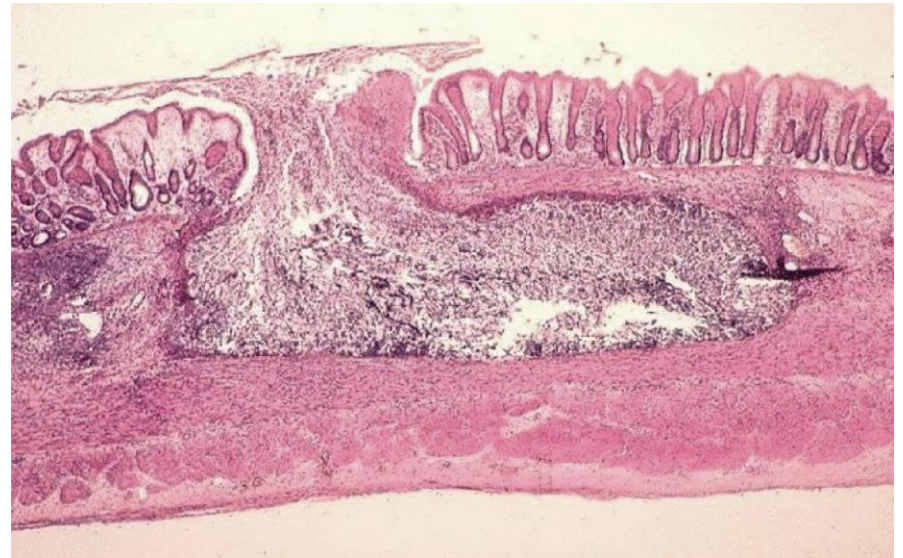
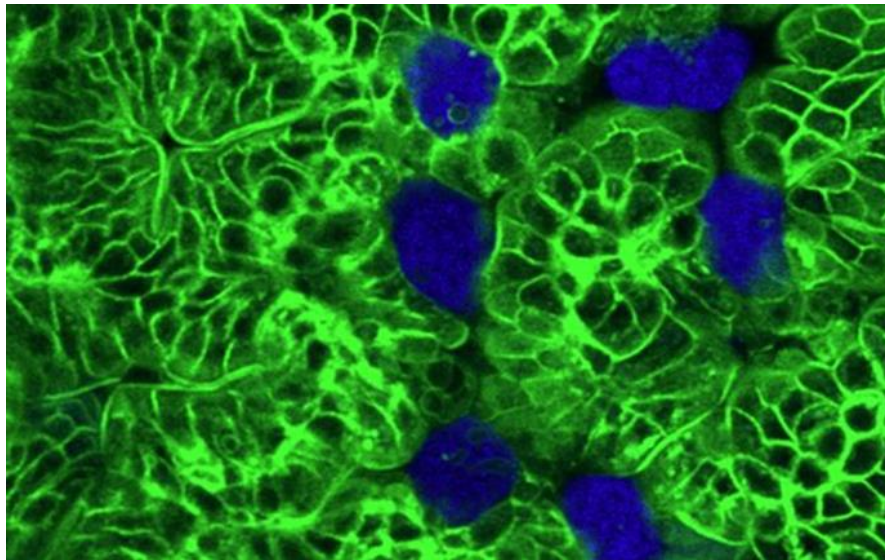
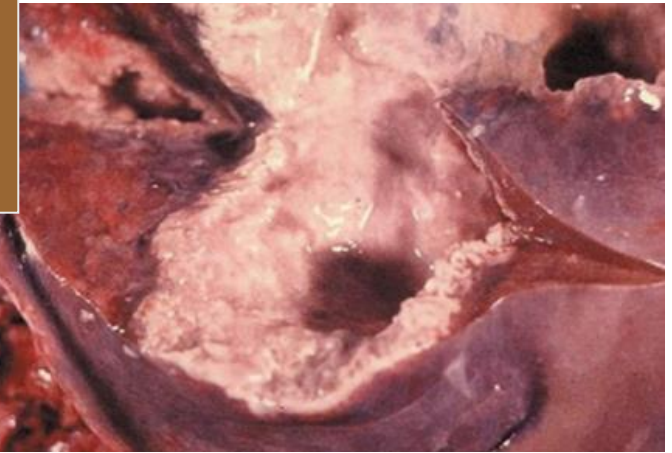
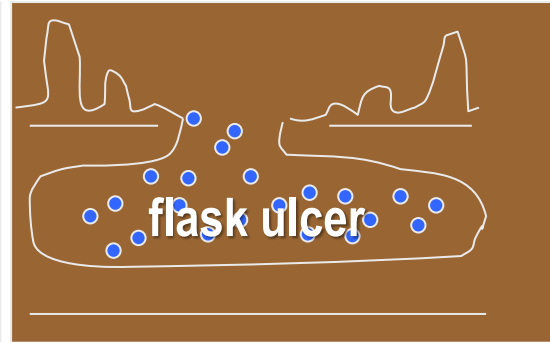
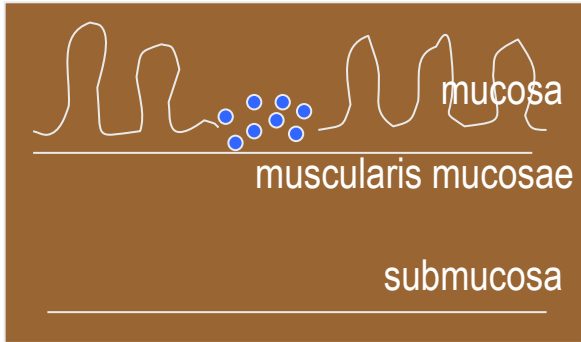
Clinical symptoms

- severe dysentery, stomach pain and cramping, bloody stools, fever
- amoebic colitis, or invasive intestinal amebiasis, occurs when the mucosa is invaded
- severe chronic infections may lead to further complications - peritonitis, perforations, formation of amoebic granulomas (ameboma)
- rarely, *E. histolytica* invades other organs - **liver abscesses** are the most common manifestation of extraintestinal amebiasis



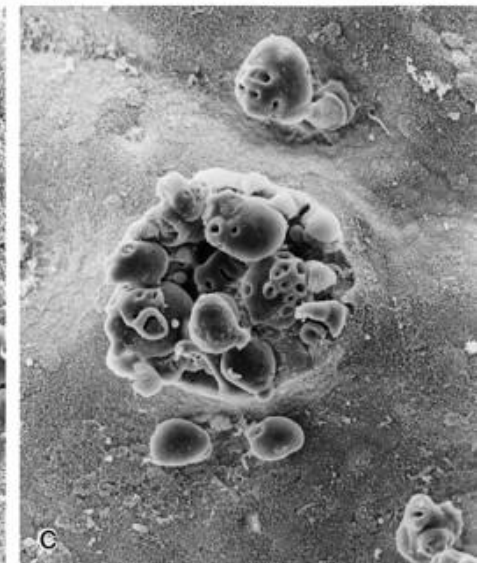
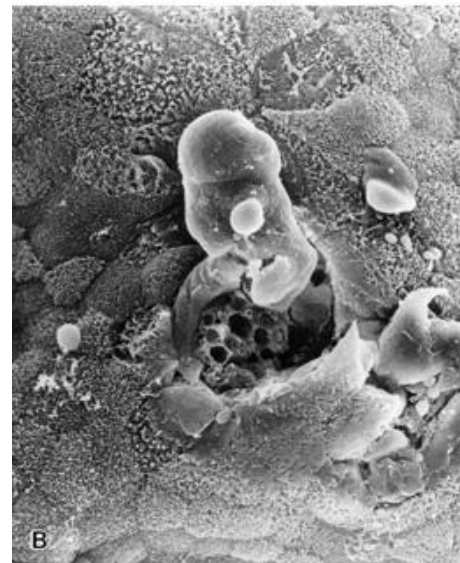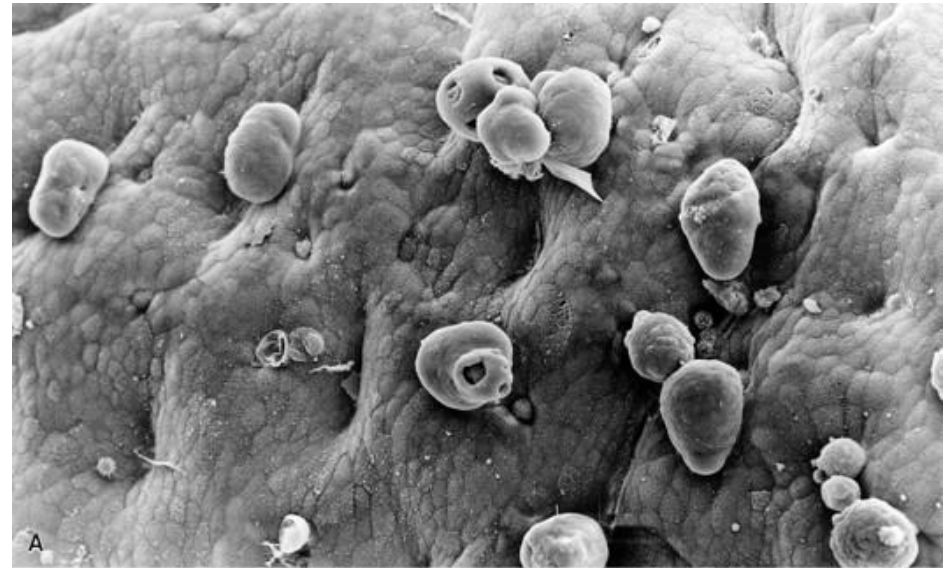
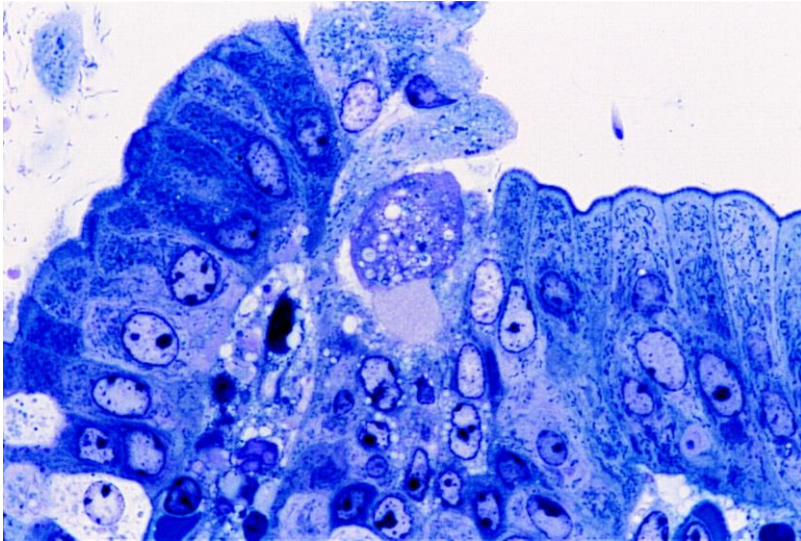
- pleuropulmonary abscess, brain abscess, and necrotic lesions on the perianal skin and genitalia have also been observed

Mucosa invasion by *Entamoeba histolytica*



Amoebas (blue) in the intestinal tissue of mice (green). Amoebas destroy the intestinal cells in order to penetrate further into the body. If they get into the bloodstream, they attack other organs. If left untreated, the infection is fatal. The parasites can be fought with antibiotics.

Invasion of the colonic and caecal mucosa by *E. histolytica*

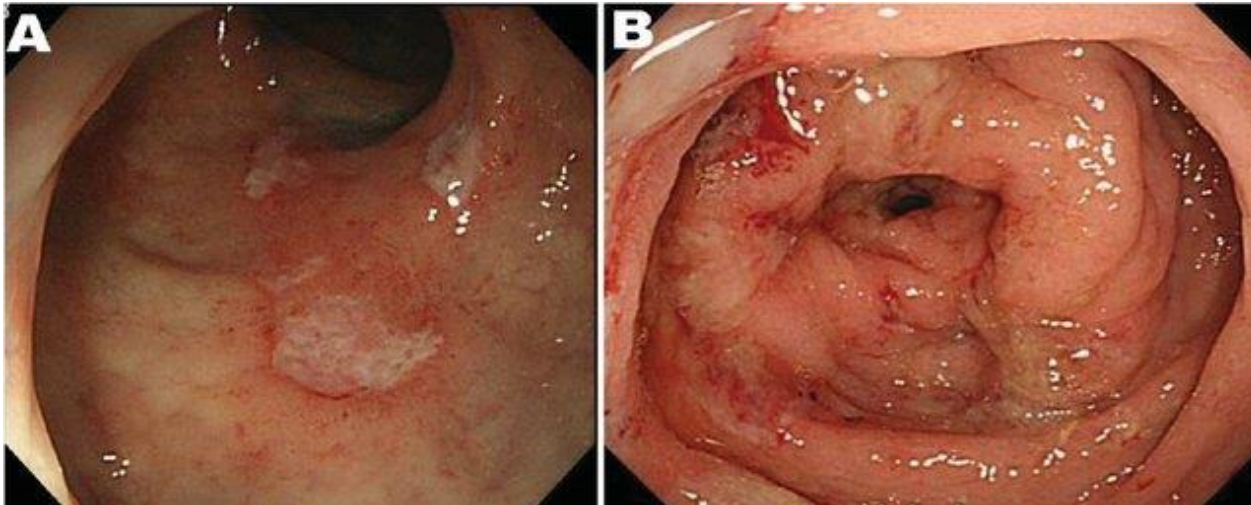


Experimental intestinal amebiasis in a guinea pig. An invading *E. histolytica* trophozoite proceeds through the interglandular epithelium. A large pseudopod is extended by the parasite during penetration to the lamina propria. A semithin section stained with toluidine blue is shown.

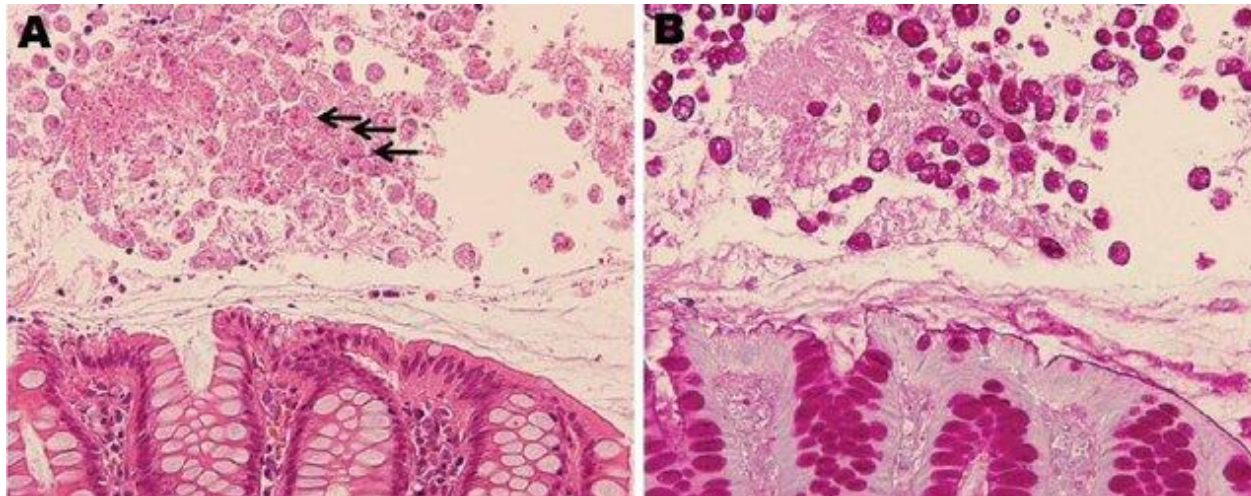
SEM of intestinal amebiasis in a guinea pig. A) Trophozoites of *E. histolytica* adhere preferentially to the elevated interglandular epithelium. B) Note the small interglandular region of microinvasion in the early invasive lesion with superficial ulceration. C) In a more advanced stage of invasion, numerous trophozoites penetrate a colonic ulcer.

<https://doi.org/10.1128/CMR.13.2.318>

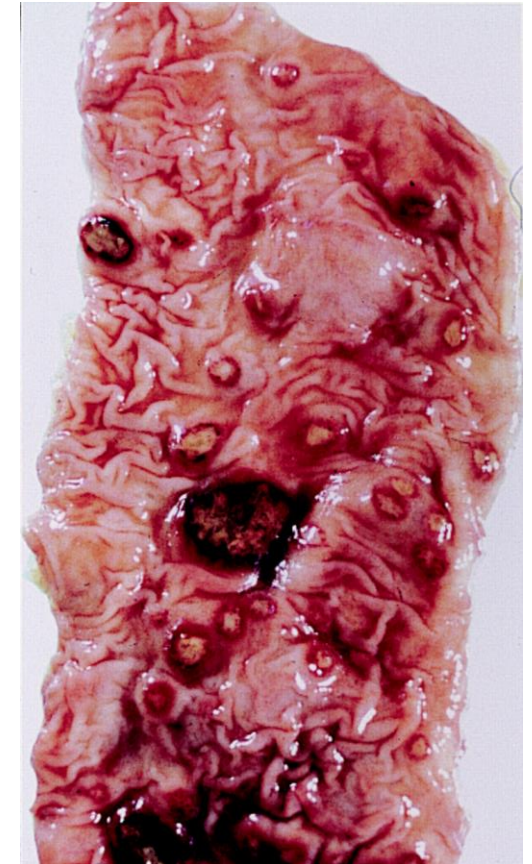Pathology of intestinal amoebiasis due to *E. histolytica*



Endoscopic features of amoebic colitis. A) Ulcers in the rectum. B) Multiple erosions with exudates surrounded by oedematous mucosa in the sigmoid colon.

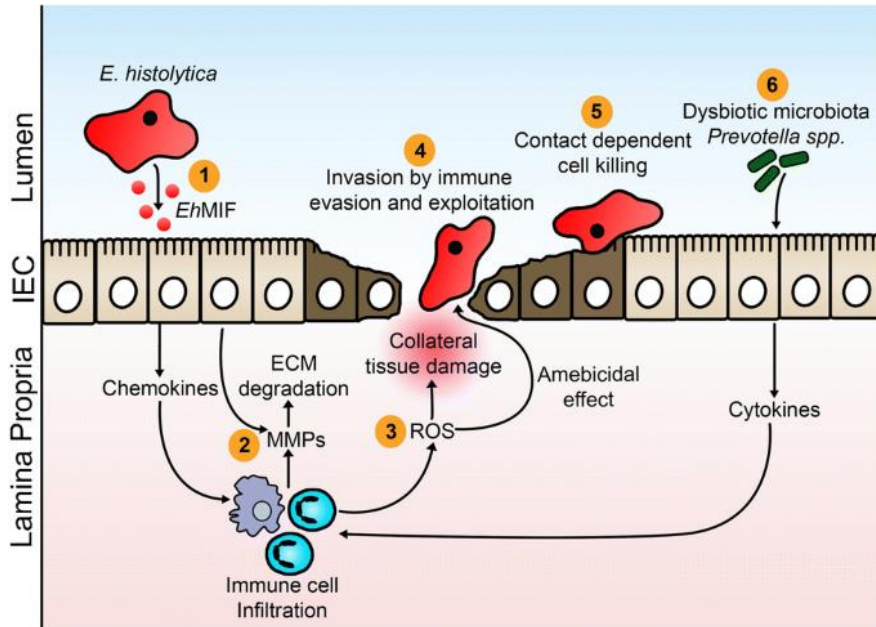


Histologic analysis of amoebic colitis. A) Trophozoites of *E. histolytica* ingesting erythrocytes (arrows). HE. B) Numerous amoebic trophozoites on the mucosal surface. PAS.

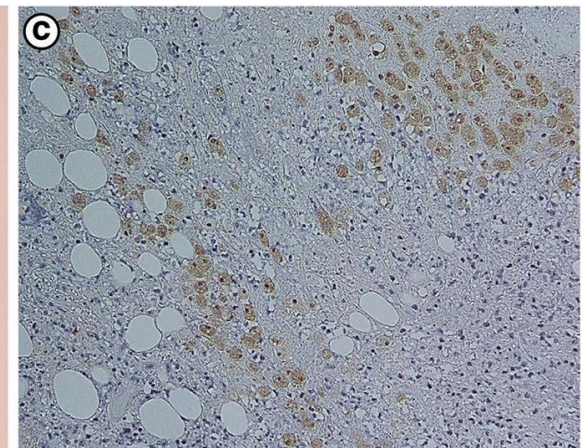
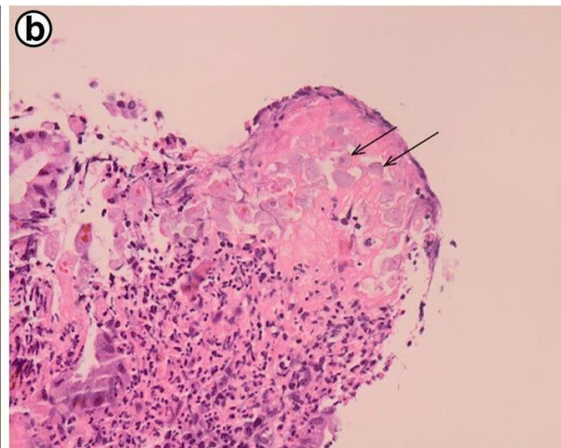
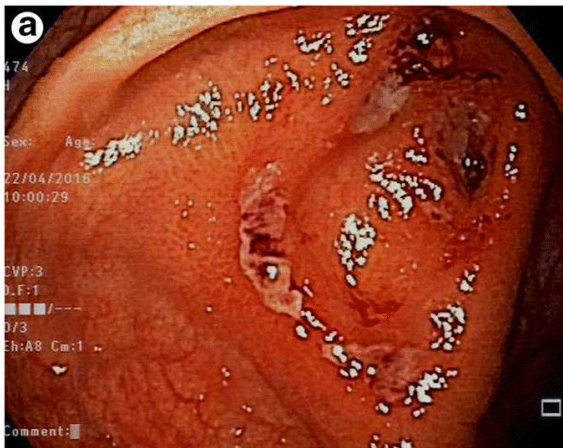

Human intestine with acute amoebic colitis.

Pathogenesis of intestinal amoebiasis due to *E. histolytica*




1. Secreted *E. histolytica* macrophage migration inhibitory factor (*EhMIF*) promotes mucosal inflammation.
2. *E. histolytica*-induced inflammation results in increased production in matrix metalloproteinases (*MMPs*) which break down extracellular matrix (*ECM*) in gut to promote cell migration.
3. Infiltrating inflammatory cells generate oxygen free radicals (*ROS*) which are capable of killing parasites. *ROS* are also responsible for collateral tissue damage during the inflammatory period.
4. Amoeba invades the intestinal mucosa by evading and exploiting the host immune system.
5. Contact-dependent cell killing by *E. histolytica*.
6. Elevated levels of *Prevotella copri* (associated with gut inflammation) increases the risk of colitis.



Patient with amoebic colitis. A) Intestinal ulcers. **B)** Amoebas within the lamina propria (arrows) surrounded by inflammatory infiltrate of neutrophils. **C)** Invasion of intestinal mucosa by trophozoites. IHC of trophozoites (brown) using anti-*E. histolytica* macrophage migration inhibitory factor antibodies.

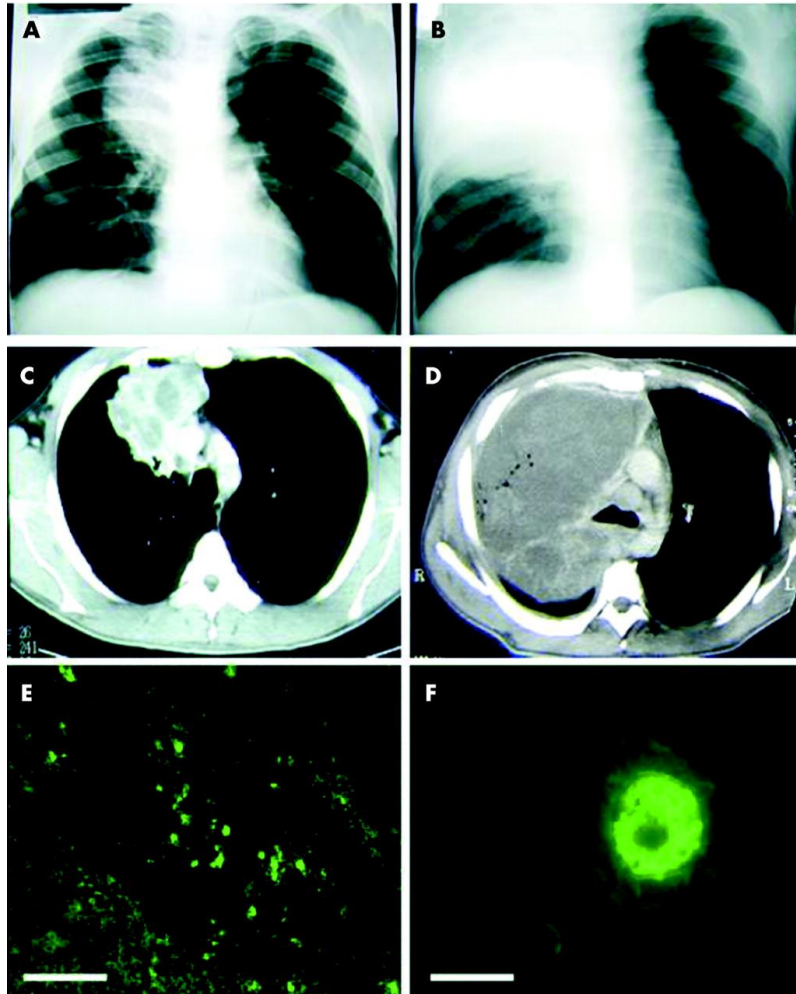
Pathogenesis of intestinal amoebiasis due to *E. histolytica*

- adherence - lectin binding to galactose and N-acetylgalactosamine sugars on the surface of the epithelial cells
- loosening of the epithelial layer - several enzymes such as pore forming proteins, lipases, and cysteine proteases
- normally used to digest bacteria in food vacuoles
- causing lysis of epithelial cells by inducing cellular necrosis and apoptosis
- phagocytosis via **amoebostome**



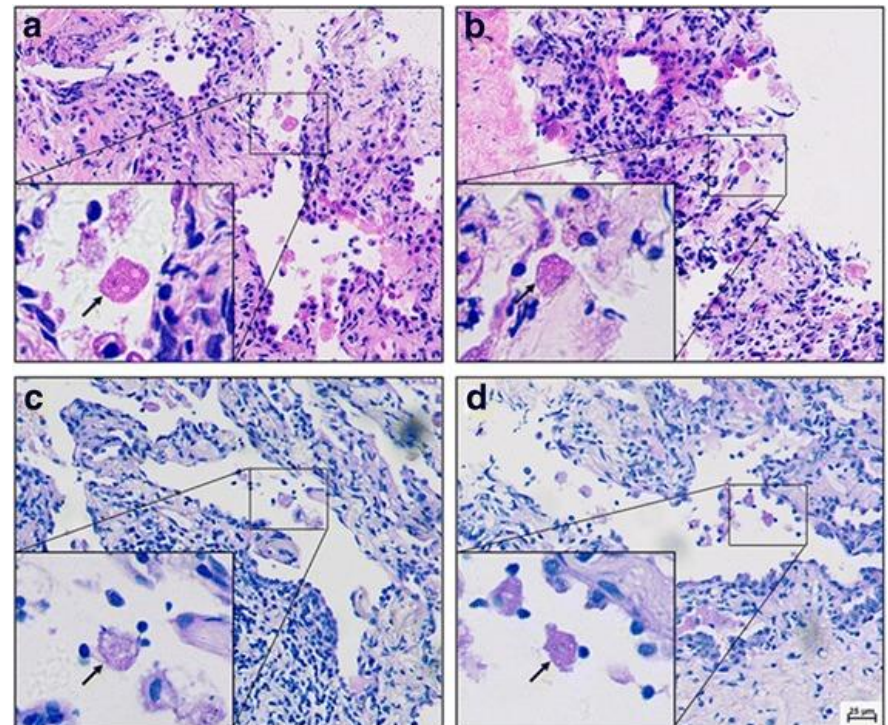
<https://doi.org/10.1016/j.pt.2004.10.009>

Thoracic entamoebiasis



Primary pulmonary amoebiasis presenting as superior vena cava syndrome due to large mass in superior lobe of the right lung. A-B) Postero-anterior radiographs and C-D) high resolution computed tomographic scans of the thorax showing significant enlargement of the mass in one day (B, D compared to A, C). E-F) Lung section showing necrotic tissue which reacted with anti-*E. histolytica* antibodies (IFA). Note a small number of amoebae with green fluorescence. F shows a single amoeba.

Pleuropulmonary amebiasis is common, while pericardial amebiasis the rare form of thoracic form. Malnutrition, chronic alcoholism and atrial septal defect with left to right shunt contribute to development of pulmonary amoebiasis.



Primary pulmonary amoebic abscess in a patient with pulmonary adenocarcinoma. Pathological examination of the lung showing trophozoites (arrows) of *E. histolytica*. A-B) HE. C-D) PAS.

<http://dx.doi.org/10.1136/thx.2004.021014>

[https://doi.org/10.1016/S0272-5231\(01\)00008-9](https://doi.org/10.1016/S0272-5231(01)00008-9)

<https://doi.org/10.1186/s40249-018-0419-2>

The underlying cellular immune pathology of *Entamoeba histolytica*-induced hepatic amoebiasis

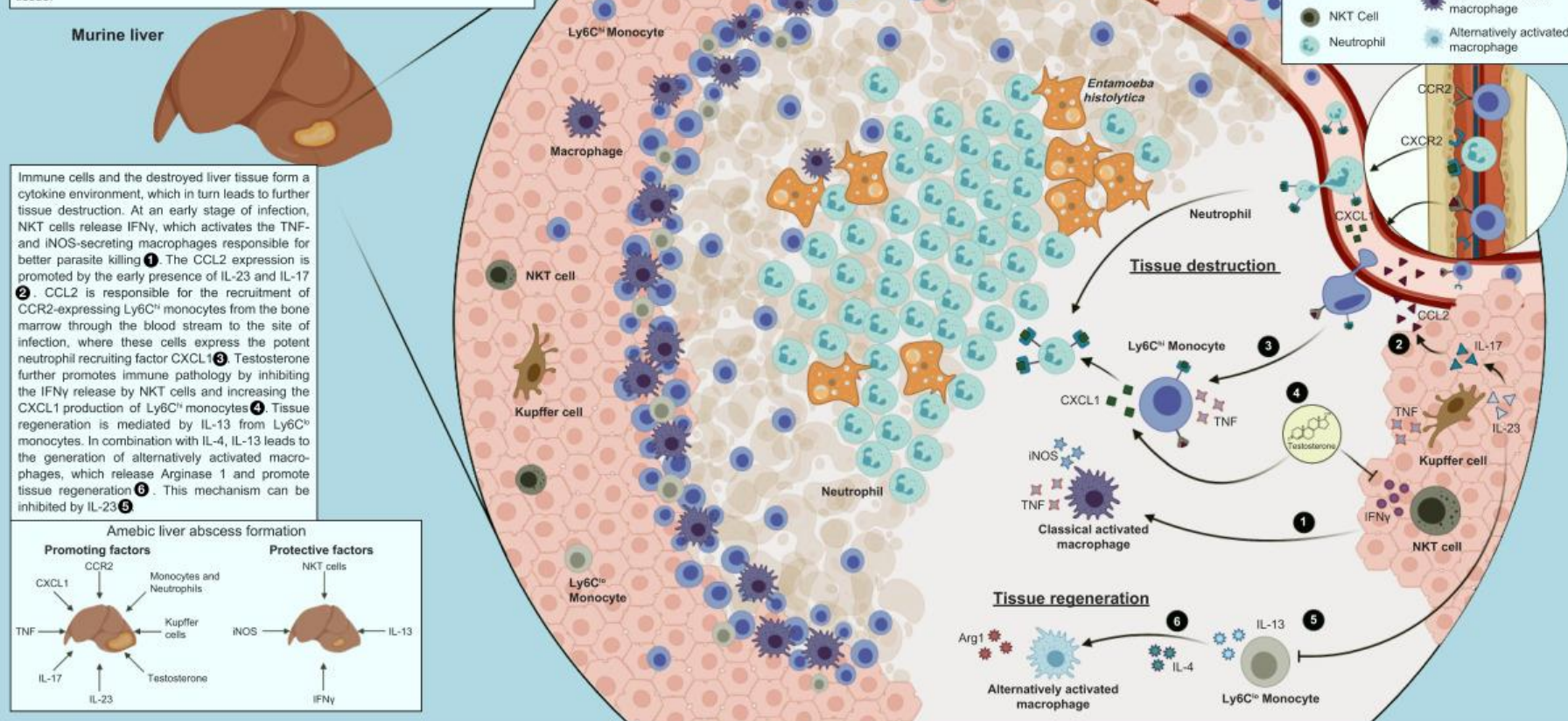
Julie Sellau^{1*}, Marie Groneberg¹, Stefan Hoenow¹, Hannelore Lotter^{1*}

¹Department of Molecular Biology and Immunology, Bernhard Nocht Institute for Tropical Medicine, Hamburg, Germany

*Corresponding Authors. Address: Department of Molecular Biology and Immunology, Bernhard Nocht Institute for Tropical Medicine, Hamburg, Germany; Tel.: (+49) 42818-475 or -443; fax: (+49) 42818-512

E-mail addresses: sellau@bnitm.de (J. Sellau) lotter@bnitm.de (H. Lotter) Twitter: @LotterLab

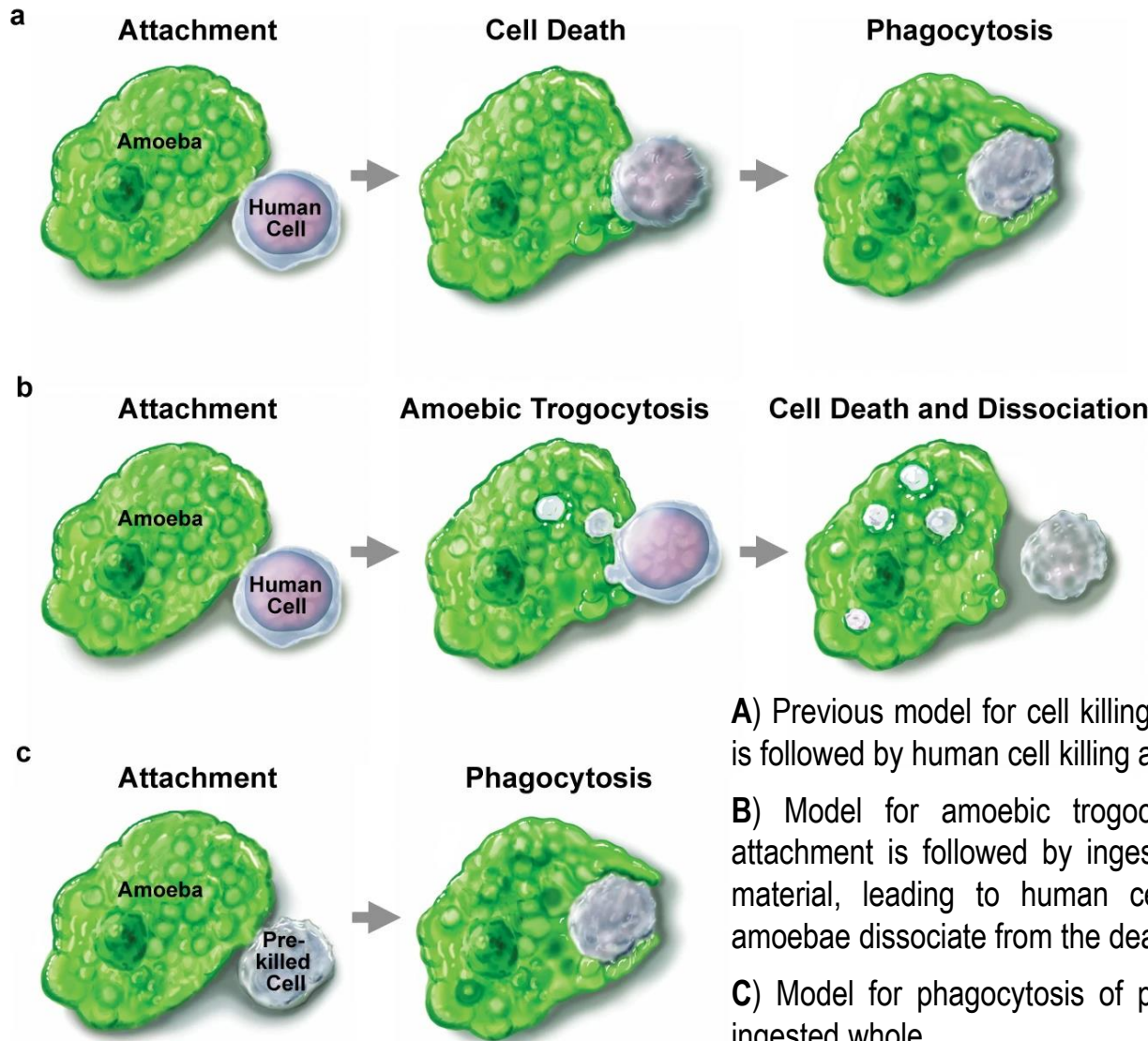
Characteristic histological organization resulting from the immune reactions caused by *Entamoeba (E.) histolytica*-induced liver abscess formation, with a detailed view on immune-cell-mediated tissue destruction and regeneration. Here, *E. histolytica* trophozoites are surrounded by neutrophils and lysed liver tissue. Monocytes and macrophages are mainly localized at the edge of the abscess adjacent to healthy liver tissue.



Keywords: *Entamoeba histolytica*, amebic liver abscess, immune pathology, inflammation, testosterone.

Received 11 December 2020; received in revised form 11 March 2021; accepted 22 March 2021.

Trogocytosis in *Entamoeba histolytica*



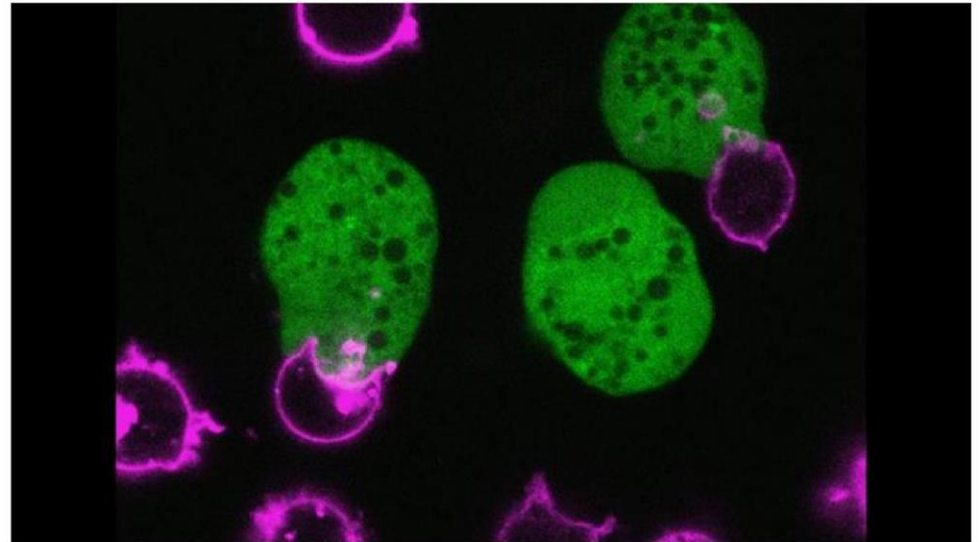
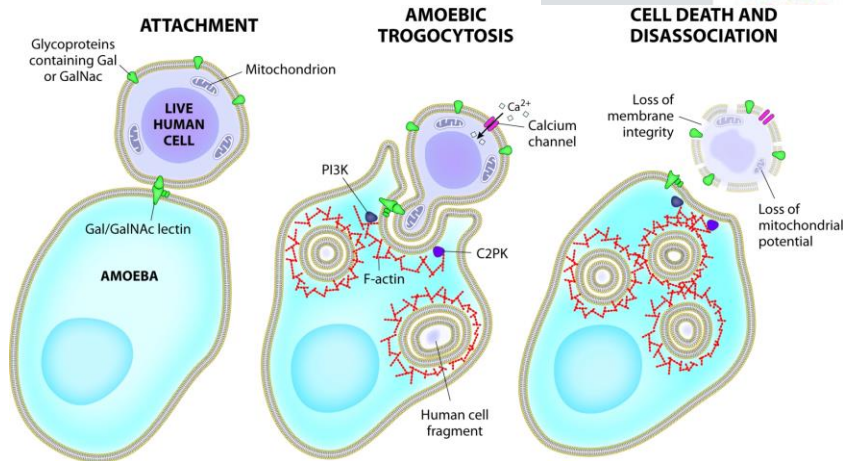
<https://doi.org/10.1038/nature13242>

A) Previous model for cell killing, in which human cell attachment is followed by human cell killing and ingestion.

B) Model for amoebic trogocytosis in cell killing, in which attachment is followed by ingestion of fragments of human cell material, leading to human cell death. Following cell killing, amoebae dissociate from the dead cells.

C) Model for phagocytosis of pre-killed human cells, which are ingested whole.

Trogocytosis in *Entamoeba histolytica*



Big gulp. The amoeba *E. histolytica* (in green) takes a bite out of a human cell (outlined in pink).

Katherine Ralston

Death by Amoeba, a Nibble at a Time

By Gisela Telis | Apr. 9, 2014, 1:00 PM

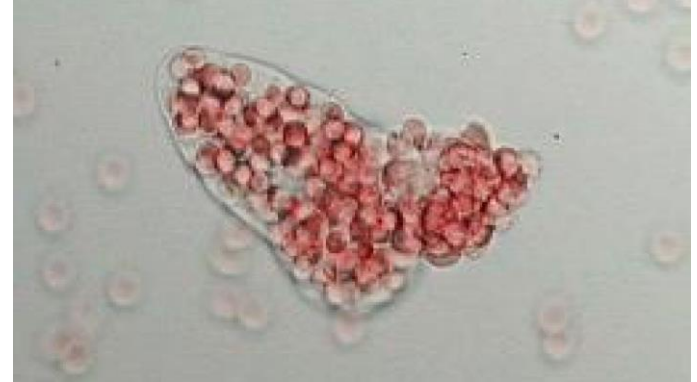<https://www.youtube.com/watch?v=wT5xqFm359I>

<https://www.youtube.com/watch?v=2JGKGXrja5o&t=11s>

Amoebic dysentery due to *Entamoeba histolytica*

Diagnosis

- ✓ differential diagnostic
- ✓ clinical signs, imaging methods
- ✓ direct faecal smear (DFS) and staining (but does not allow identification to species level)
- ✓ enzyme immunoassay (EIA)
- ✓ indirect hemagglutination (IHA)
- ✓ antigen detection - monoclonal antibody
- ✓ PCR for species identification
- ✓ cultivation

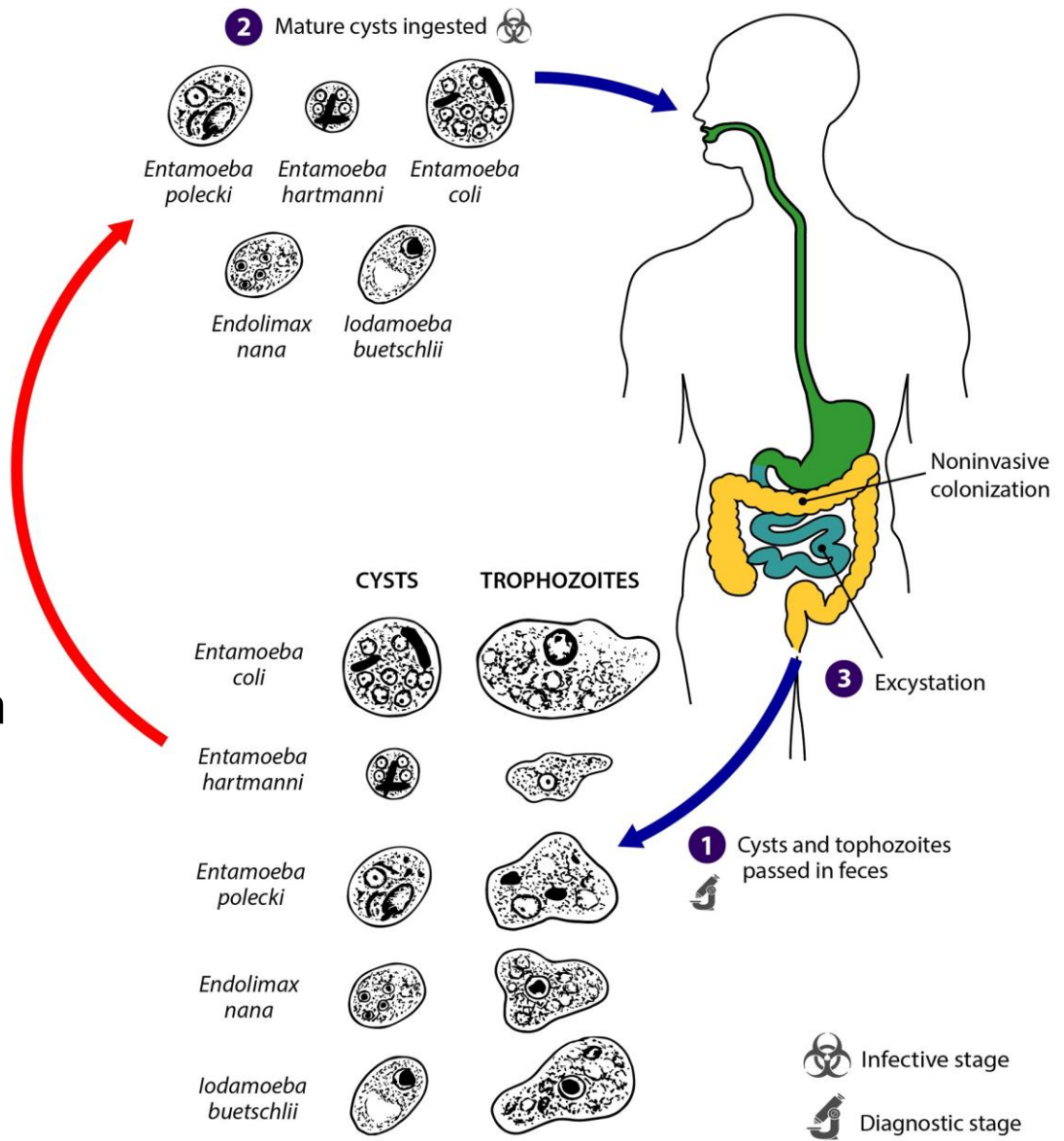
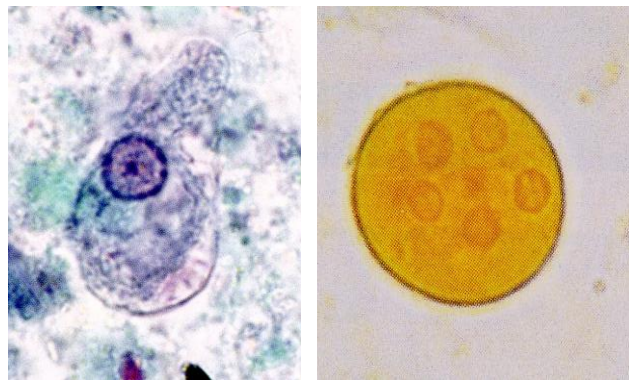


Therapy

- ✓ metronidazole, paramomycin, diloxanide fluroate

Entamoeba coli

- most common human amoeba, also in primates and dogs
- about 15 % of Czech population

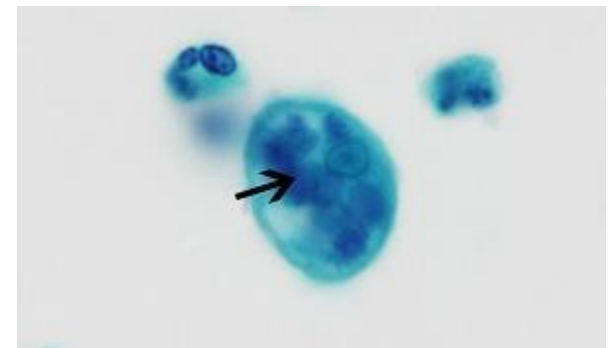
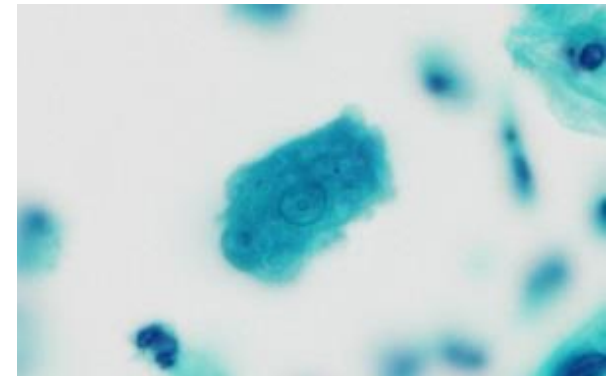
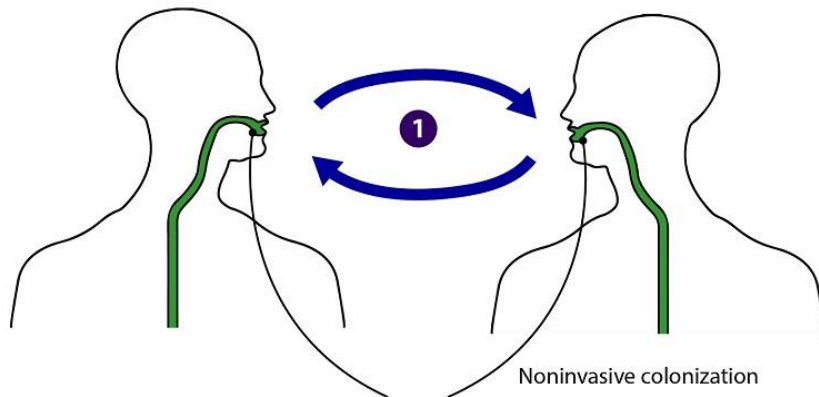


Entamoeba gingivalis

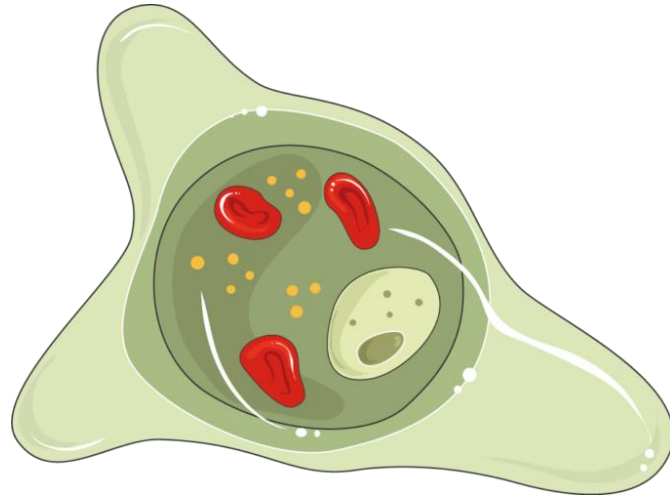
- non-pathogenic, inhabiting human oral cavity
- common in individuals with poor oral hygiene or periodontal disease
- occasionally other sites (female genital tract with use of intrauterine device)
- often found in conjunction with periodontal disease, but no causative association so far identified

DPD_x

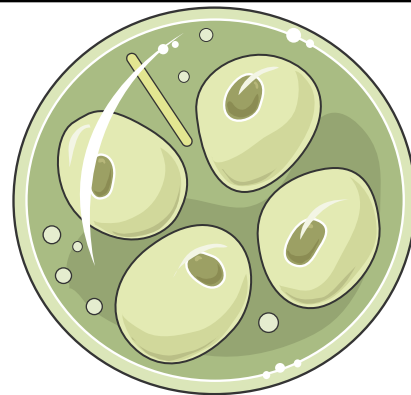
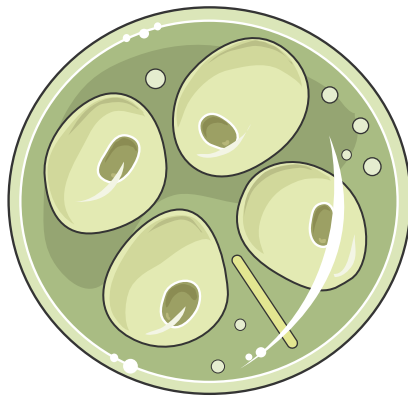
Entamoeba gingivalis



Trophozoites of *E. gingivalis*. Note the ingested host material - epithelial cells and leukocytes (arrow). Papanicolaou's stain



Thank you for your attention 😊



Lectures

- ✓ Introduction: BPP 2022 I
- ✓ Euglenozoa (Excavata): BPP 2022 II
- ✓ Fornicata / Preaxostyla / Parabasala (Excavata): BPP 2022 III
- ✓ Apicomplexa I (SAR): BPP 2022 IV
- ✓ Apicomplexa II (SAR): BPP 2022 V
- ✓ Amoebae (Excavata, Amoebozoa): BPP 2022 VI
- ⇒ **Ciliophora, Opalinata (SAR): BPP 2022 VII**

- *Pneumocystis* (Opisthokonta, Fungi): BPP 2022 VIII
- Microsporidia (Opisthokonta, Fungi): BPP 2022 IX
- Myxozoa (Opisthokonta, Animalia): BPP 2022 X