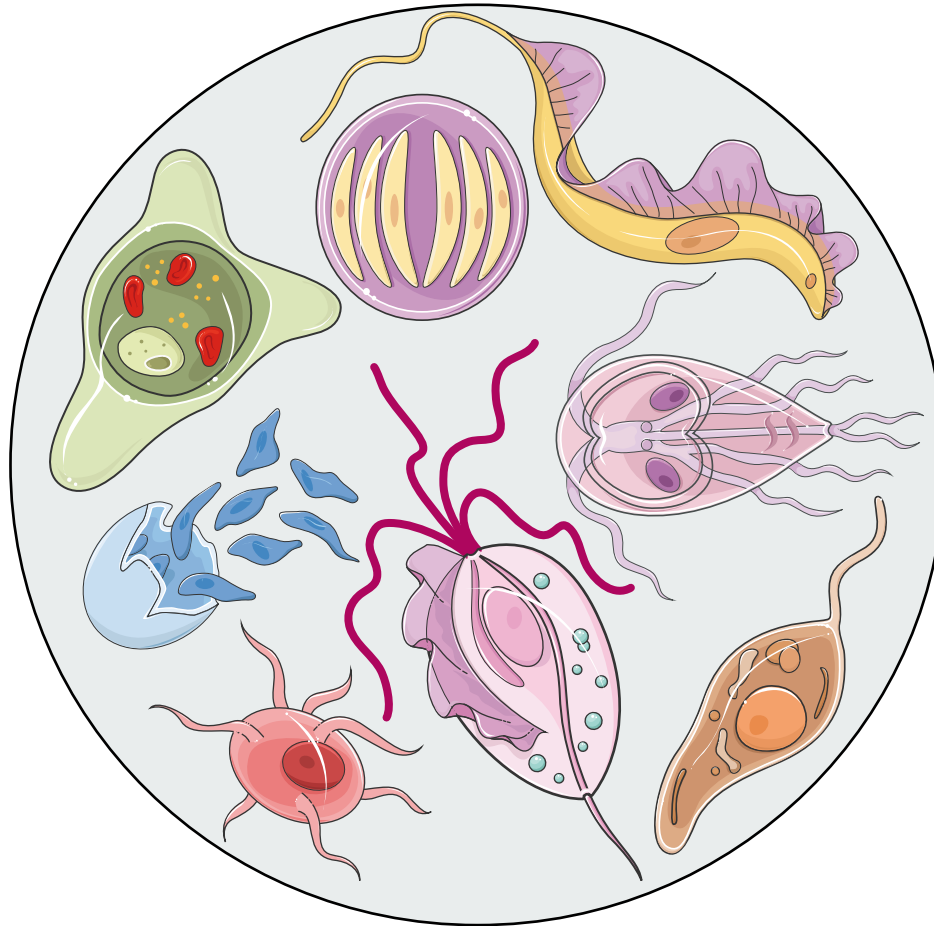


# Biology of parasitic protozoa

## V. Apicomplexa II (SAR)



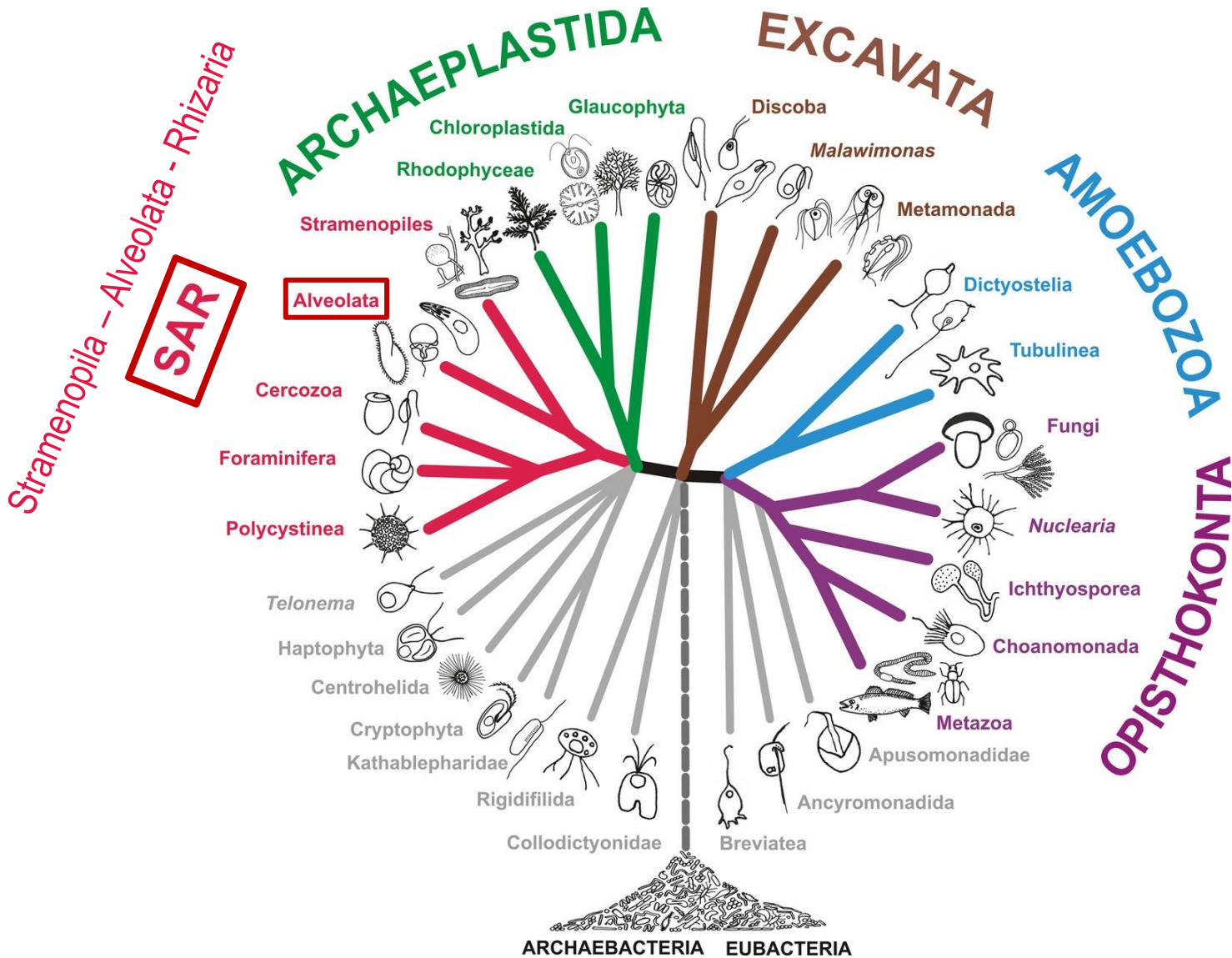
Andrea Bardůnek Valigurová

[andreav@sci.muni.cz](mailto:andreav@sci.muni.cz)

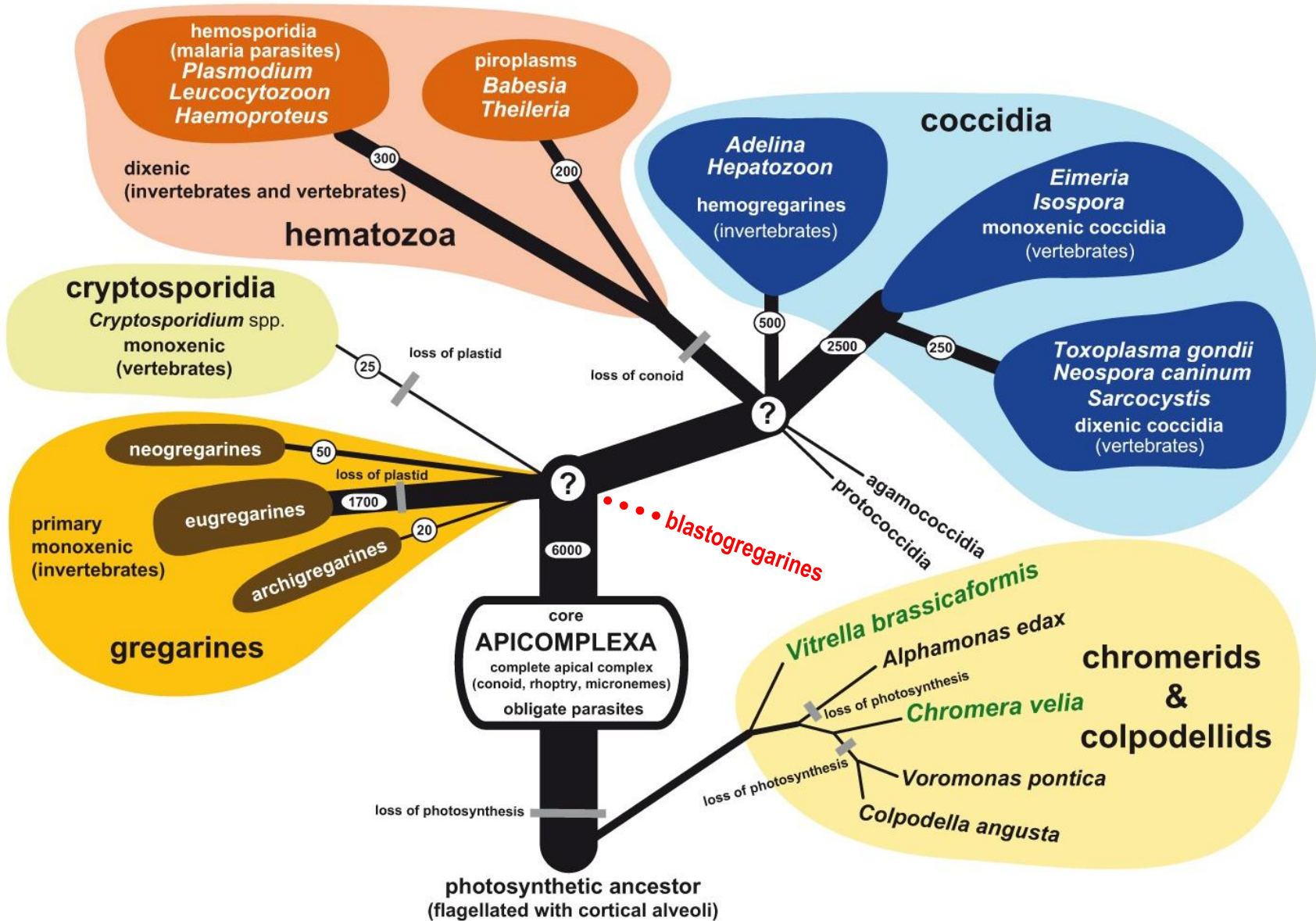
# Notice

This presentation contains some material available on the web without the permission of the creator or the copyright owner. This presentation is to be used for educational purposes only. Educational purposes are defined as a communicating material for a particular course of instruction or for the administration of such course. Educational purposes do not cover the use of copyright material in PowerPoint for public lectures or other purposes.

# 5 supergroups = megagroups



# Apicomplexa





# Apicomplexa

**Aconoidasida**••• .....this lecture

- apical complex lacking conoid in asexual motile stages; some diploid motile zygotes (ookinetes), with conoid; macrogametes and microgametes forming independently; heteroxenous

**Haemospororida**••••

**Piroplasmorida**••••

**Conoidasida**••• .....previous/ this lecture

- complete apical complex, including a conoid in all or most asexual motile stages

**Gregarinasina**••••

***Cryptosporidium***••••

**Coccidia**••••

Adeleorina•••••

Eimeriorina•••••

# Apicomplexa

## Conoidasida•••

- complete apical complex, including a conoid in all or most asexual motile stages

## Gregarinasina••••

- mature gamonts usually develop extracellularly; syzygy of gamonts generally occurring with production of gametocyst; similar numbers of macrogametes and microgametes maturing from paired gamonts in syzygy within the gametocyst
- syngamy of mature gametes leading to gametocyst that contains few to many oocysts

## Cryptosporidium••••

- oocysts and meronts with attachment “feeder” organelle; microgametes non ciliated; oocysts without sporocysts, with 4 naked sporozoites
- extracytoplasmic localisation in host cell

## Coccidia••••

- mature gametes develop intracellularly; microgamont typically produces numerous microgametes
- syzygy absent; zygote rarely motile; sporocysts usually form within oocysts

# Apicomplexa

## Aconoidasida•••

- apical complex lacking conoid in asexual motile stages; some diploid motile zygotes (ookinetes); macrogametes and microgametes forming independently; heteroxenous

## Haemospororida••••

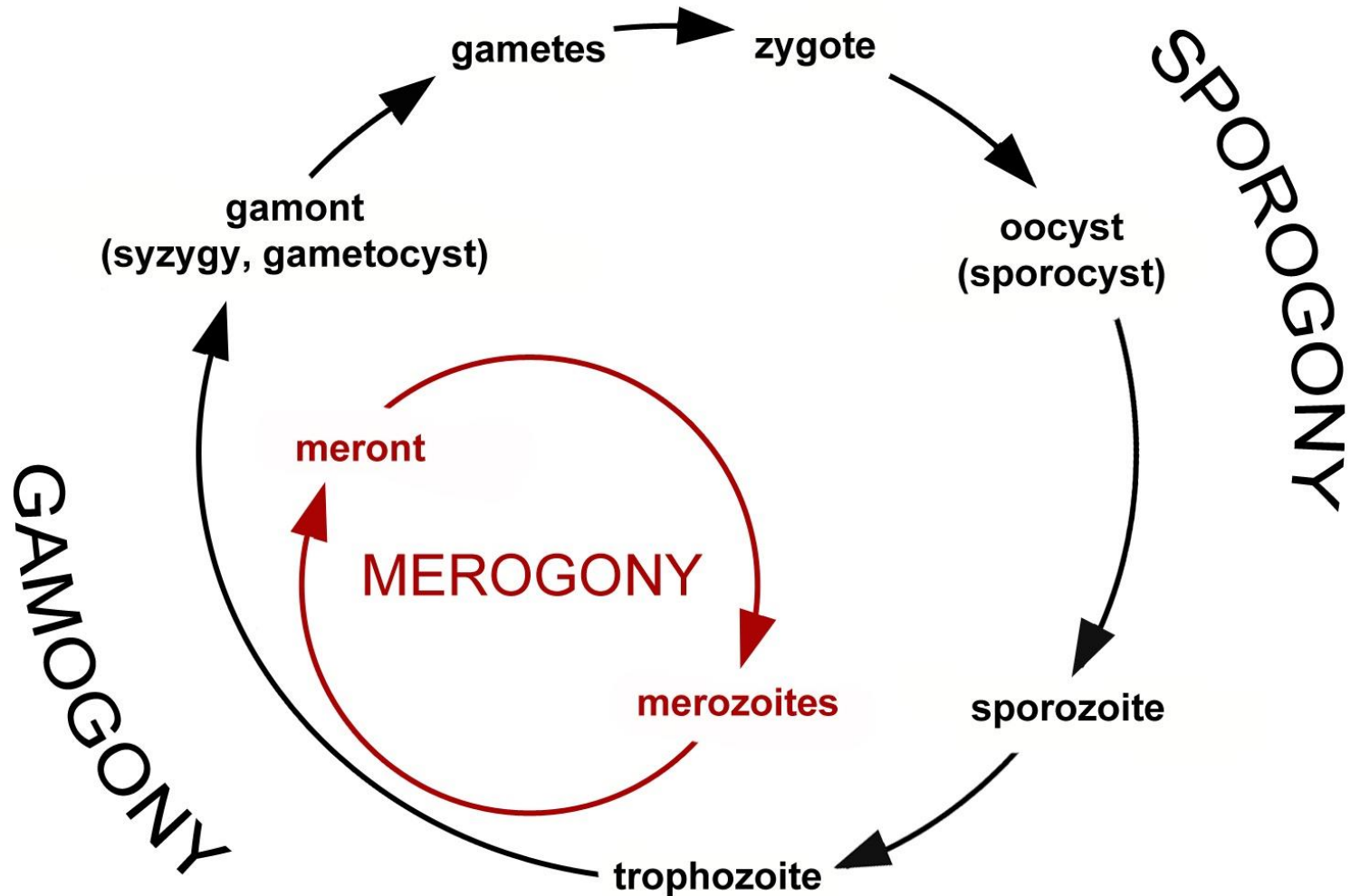
- zygote motile as ookinete with conoid; ciliated microgametes produced by merogony; oocyst formed in which sporozoites develop
- *Haemoproteus*, *Leucocytozoon*, *Mesnilium*, *Plasmodium*

## Piroplasmorida••••

- piriform, round, rod-shaped or amoeboid; conoid and cilia absent in all stages; polar ring present; without oocyst
- *Babesia*, *Theileria*

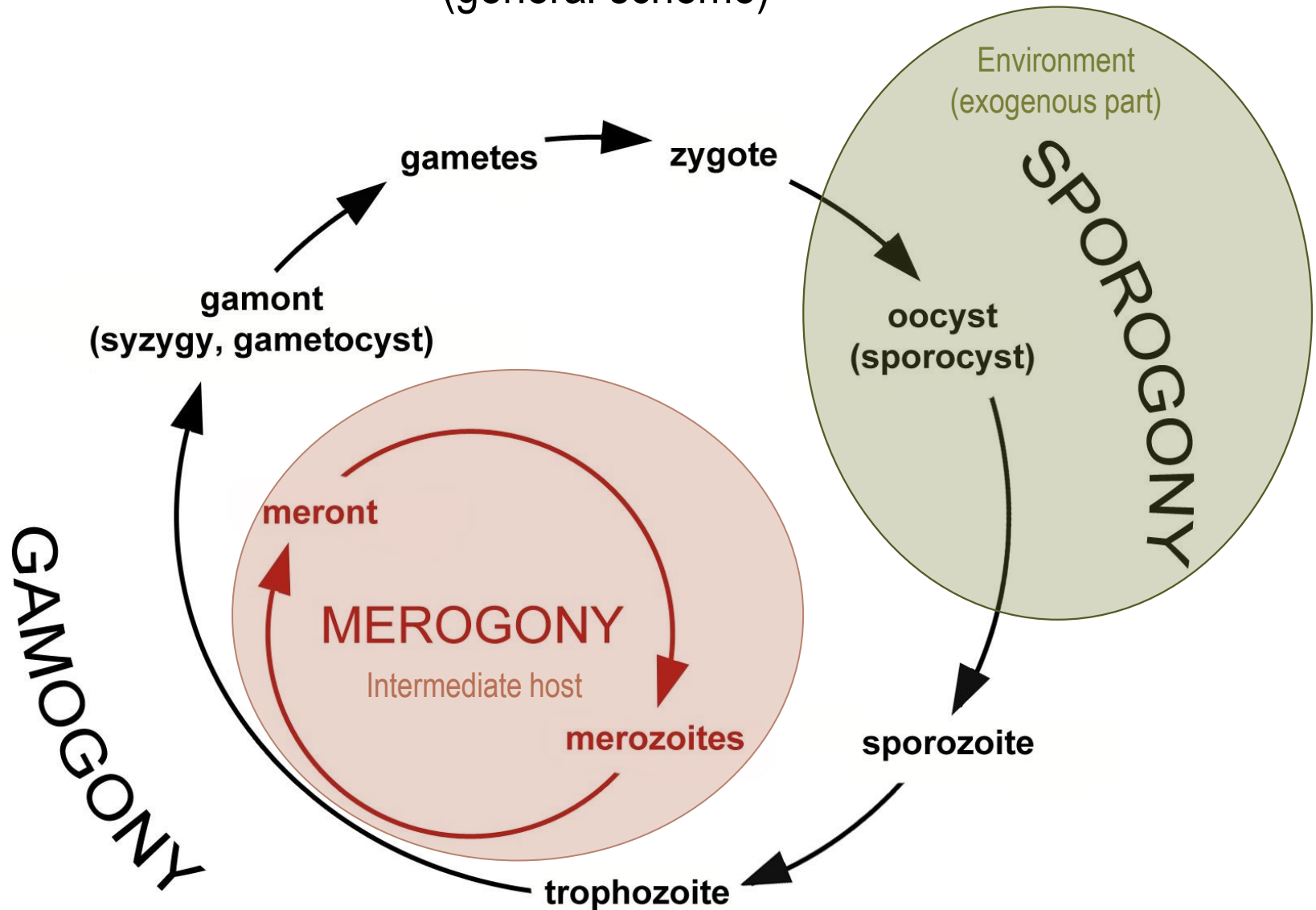
# Apicomplexan life cycle

(general scheme)



# Apicomplexan life cycle

(general scheme)





# Apicomplexa

## Sarcocystidae

### Sarcocystinae

- obligatory heteroxenous

#### ***Sarcocystis*, *Frenkelia* *Toxoplasma***

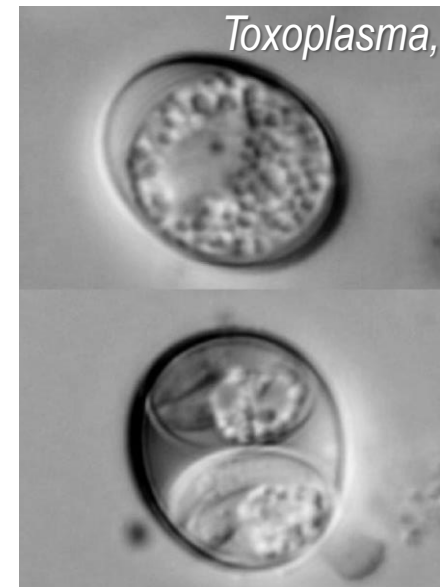
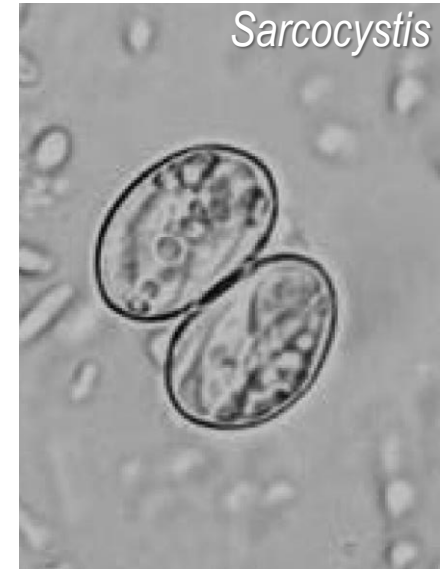- *Isospora*-like oocysts
- fully sporulated oocysts in the fresh faeces/in situ

### Toxoplasminae

- facultatively heteroxenous

#### ***Toxoplasma*, *Neospora*, *Besnoitia*, *Hammondia***

- *Isospora*-like oocysts
- unsporulated in the fresh faeces



# Apicomplexa

## Sarcocystidae

### Sarcocystinae

*Sarcocystis*

*Frenkelia*

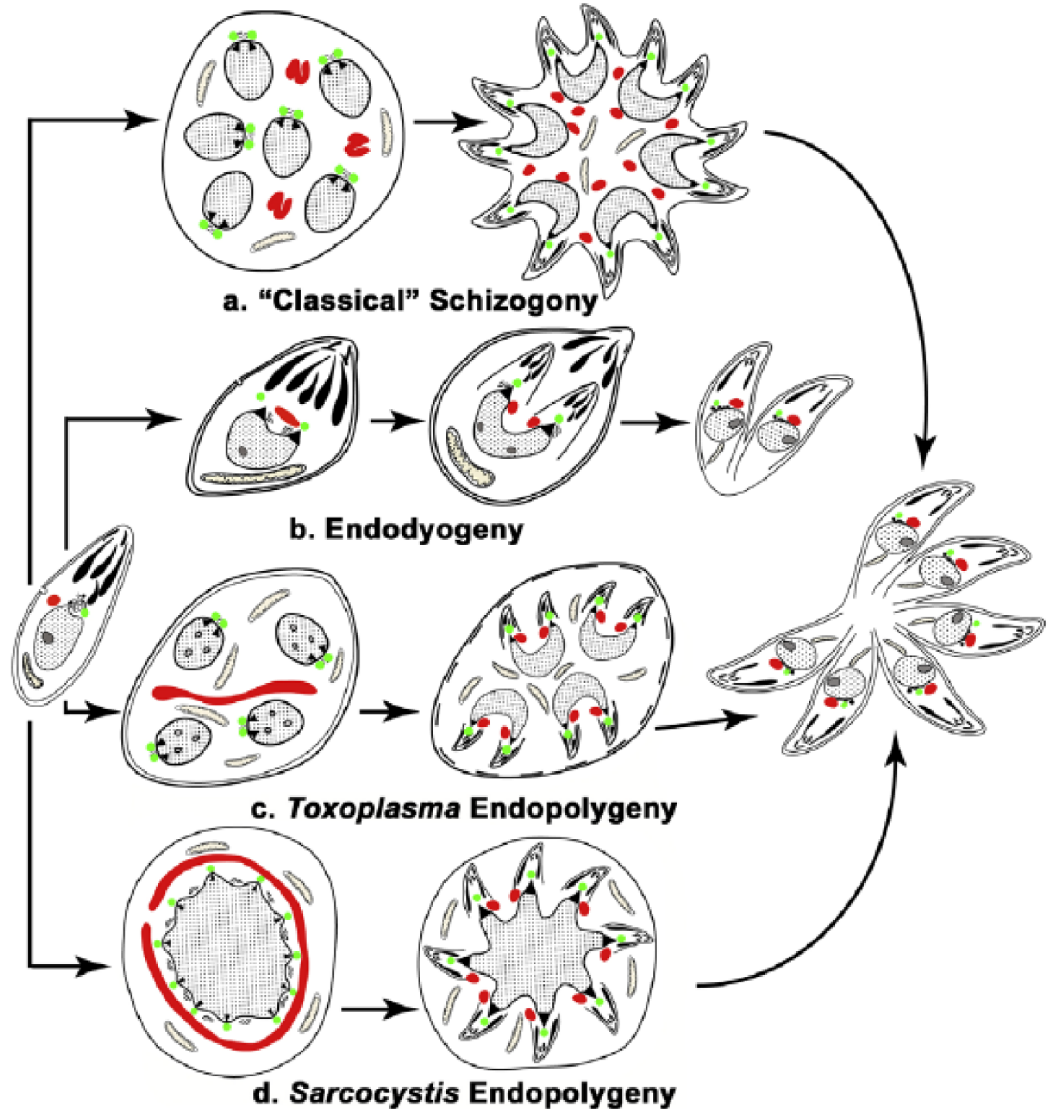
### Toxoplasminae

*Toxoplasma*

*Neospora*

*Besnoitia*

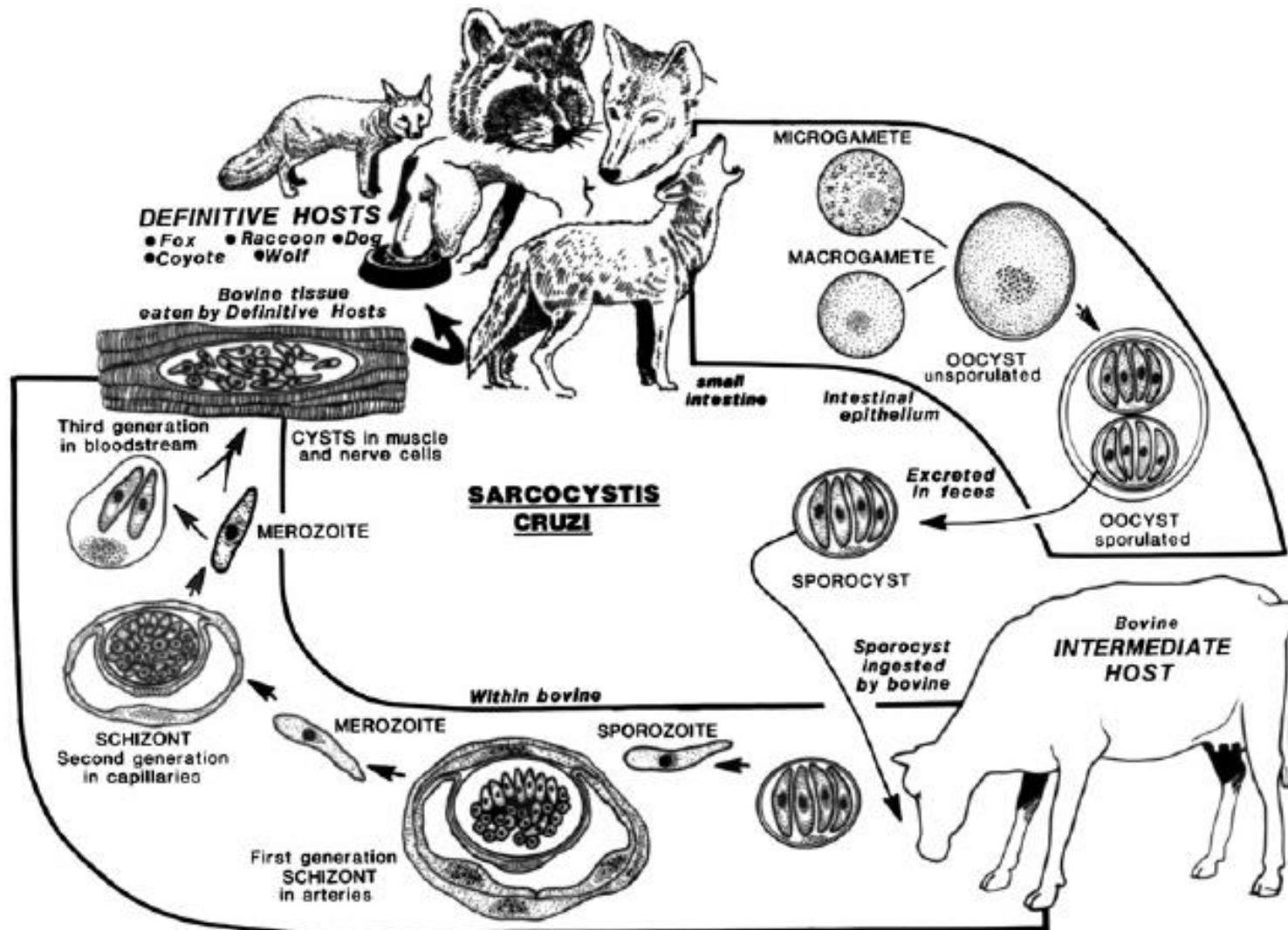
*Hammondia*



## genus ***Sarcocystis***

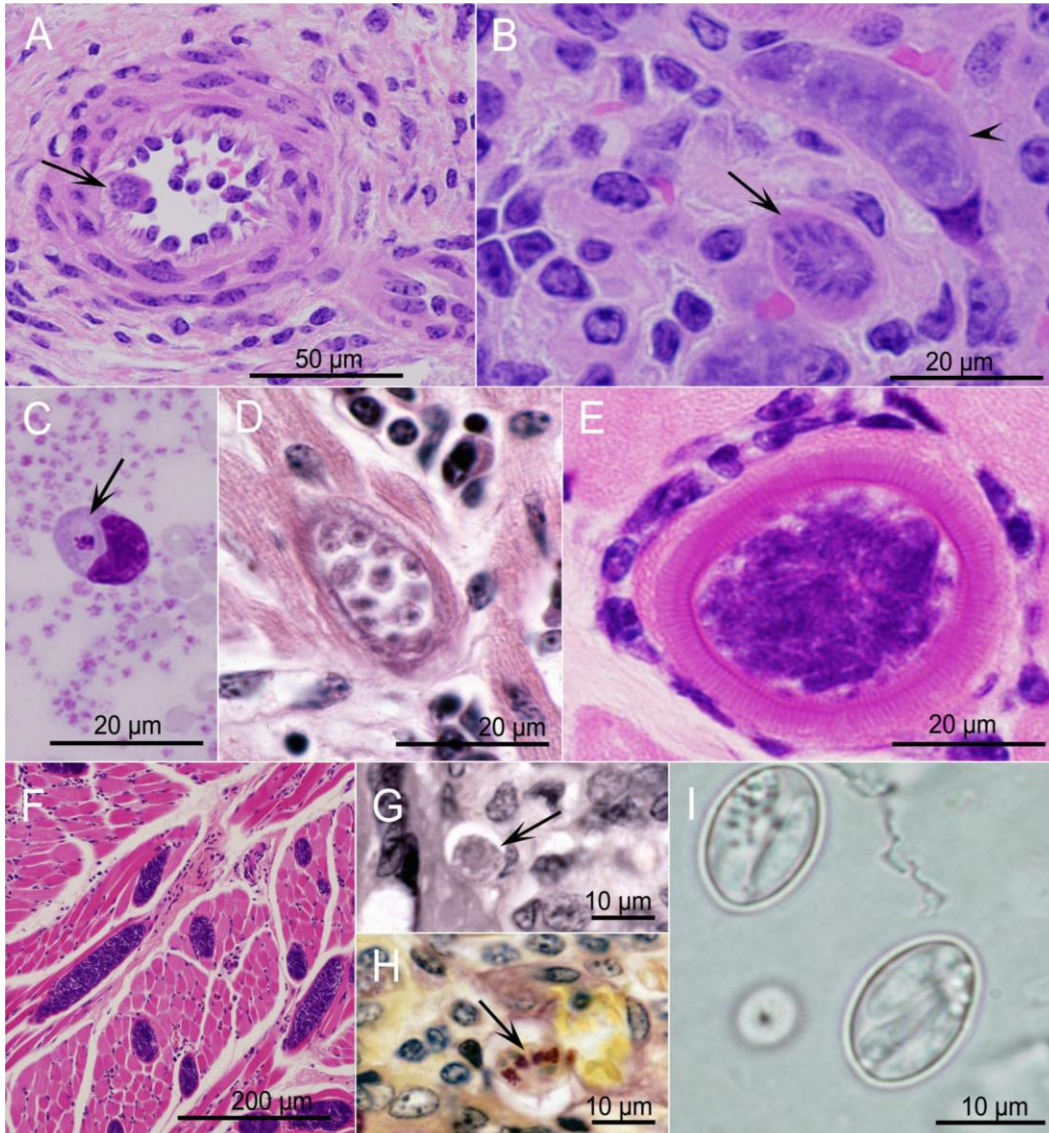
- about 200 recognised species in this genus
- cyst-forming coccidia
- obligatory heteroxenous
- host specific or infect closely related host species
- IH: vertebrates
- DH: carnivorous and omnivorous vertebrates
- prey-predator relation of definitive and intermediate hosts
- extraintestinal merogony: in endothelial cells, RES cells or hepatocytes
- muscle tissue cysts - **sarcocysts**, zoites in sarcocysts - **cystozoites**
- *Isospora*-like oocysts, sporulation in situ
- terminology *Sarcocystis bovicanis* / *Sarcocystis cruzi*

# Life cycle of *Sarcocystis cruzi*





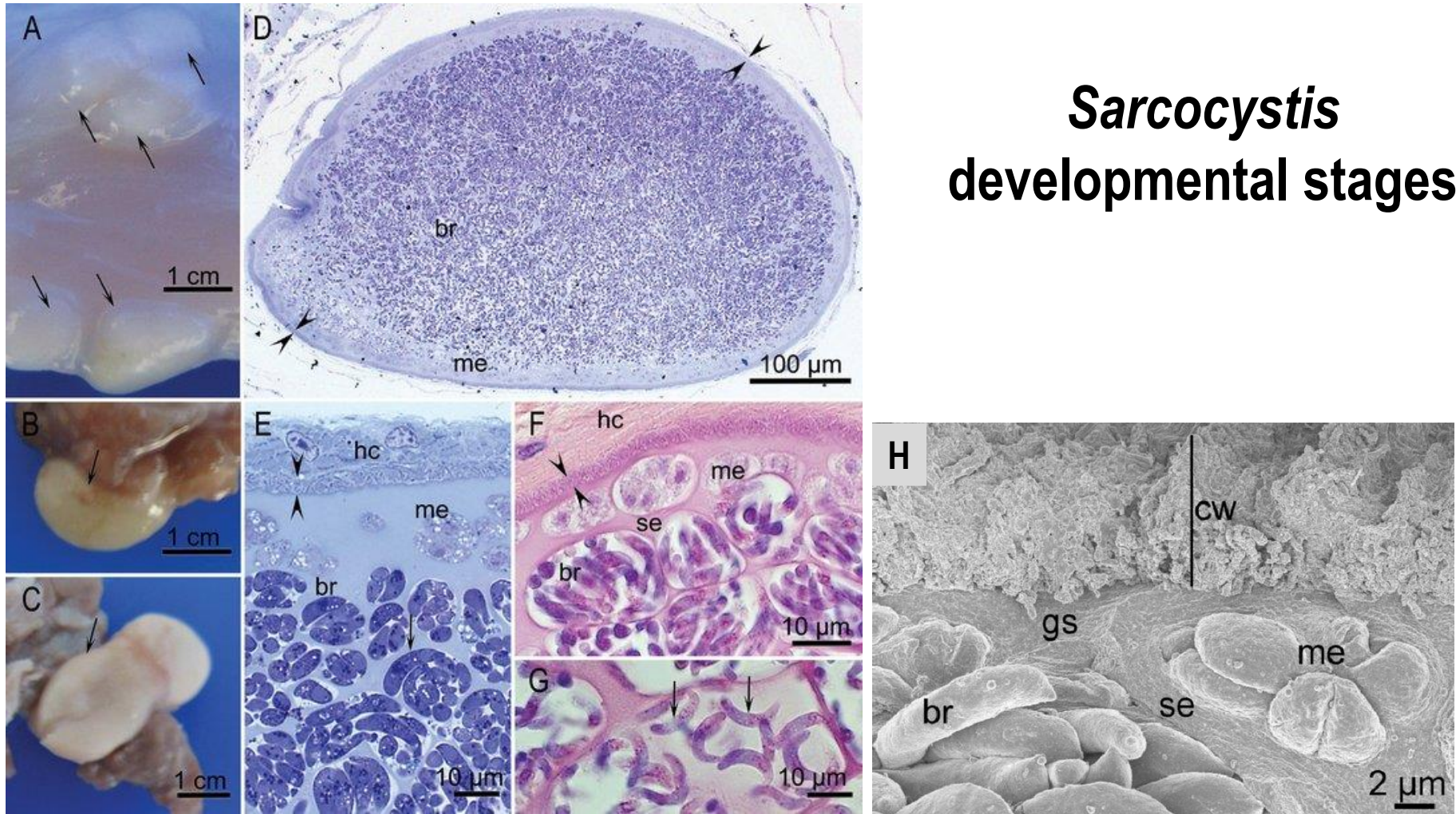
# Sarcocystis developmental stages



**Sarcocystis stages in intermediate hosts (A-F) and definitive hosts (G-I).** All micrographs show *S. cruzi*, except **E**, which is an image of *S. hominis*. **A)** Artery with a first-generation multinucleate meront (arrow) in an endothelial cell. **B)** Kidney glomerulus with immature (arrowhead) and mature (arrow) second-generation schizonts. **C)** Blood smear with a merozoite in a mononuclear cell. **D)** Heart with an immature sarcocyst containing globular metrocytes. **E)** Skeletal muscle with a cross section of a mature sarcocyst with a thick striated wall surrounded by a mononuclear cell infiltrate. **F)** Skeletal muscle with longitudinal and cross sections of sarcocysts. There was no inflammatory response. HE. **G)** Lamina propria of small intestine with a macrogametocyte (arrow). **H)** Small intestine with sporulated sporocysts (arrow). Whipf's polychrome stain. **I)** Two sporocysts in a faecal float.



# *Sarcocystis* developmental stages

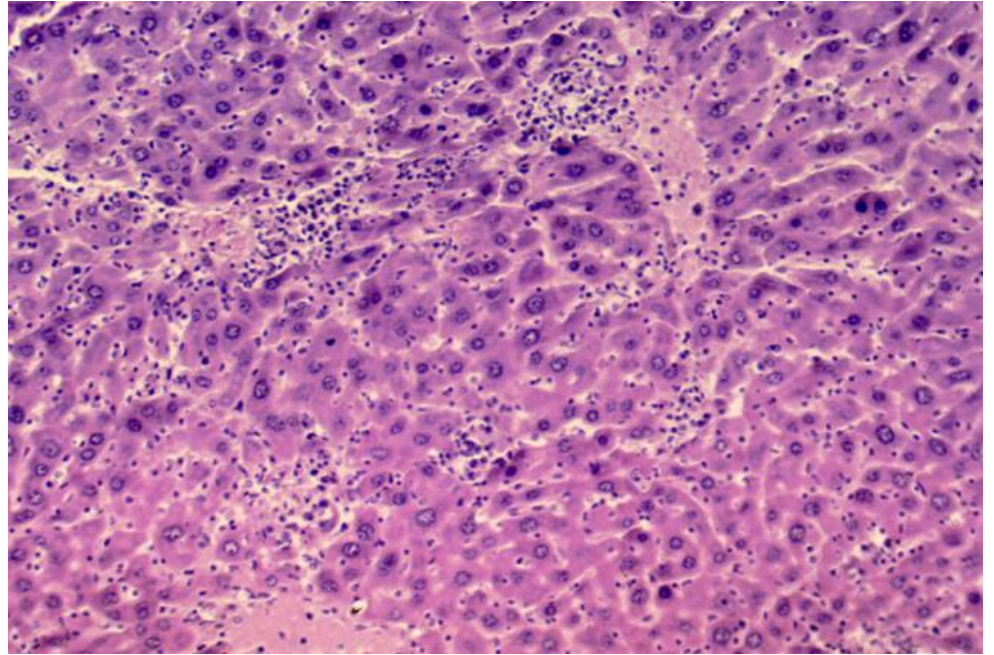


**Sarcocysts of *Sarcocystis cafferi* from African buffalo.** A-C) Unstained macrocysts (arrows). Sarcocysts are covered with connective tissue in A. D-E) Sarcocysts in section stained with Toluidine blue. Note thin sarcocyst wall (opposing arrowheads) with a pale staining outer zone with metrocytes (me), and intensely stained bradyzoites (br). F-G) Section of sarcocyst. HE. Note septa (se) separating groups of bradyzoites (br), and pale staining metrocytes (me). Arrows point to longitudinally cut bradyzoites. H) SEM of sectioned part of a sarcocyst revealing the cyst wall (cw), bradyzoites (br) and metrocytes (me) arranged in sacks enclosed by thick septa (se).

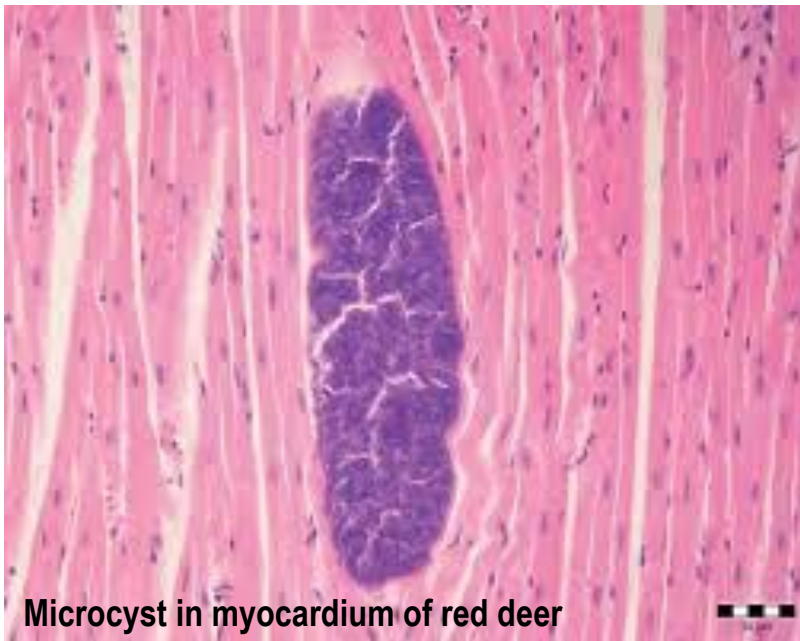

# Pathology of sarcocystosis in intermediate hosts

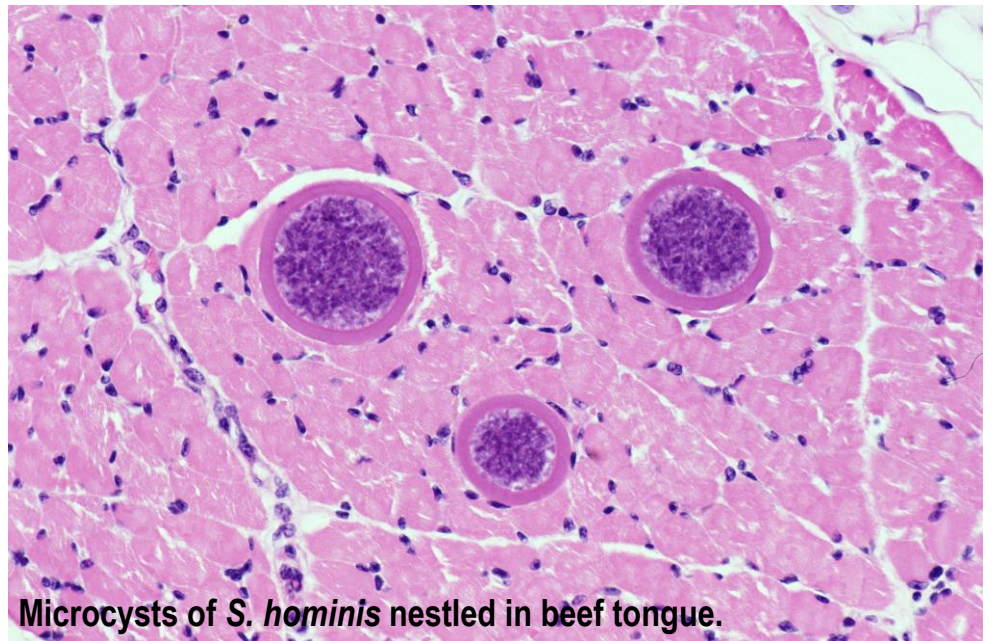
hepatitis



myositis



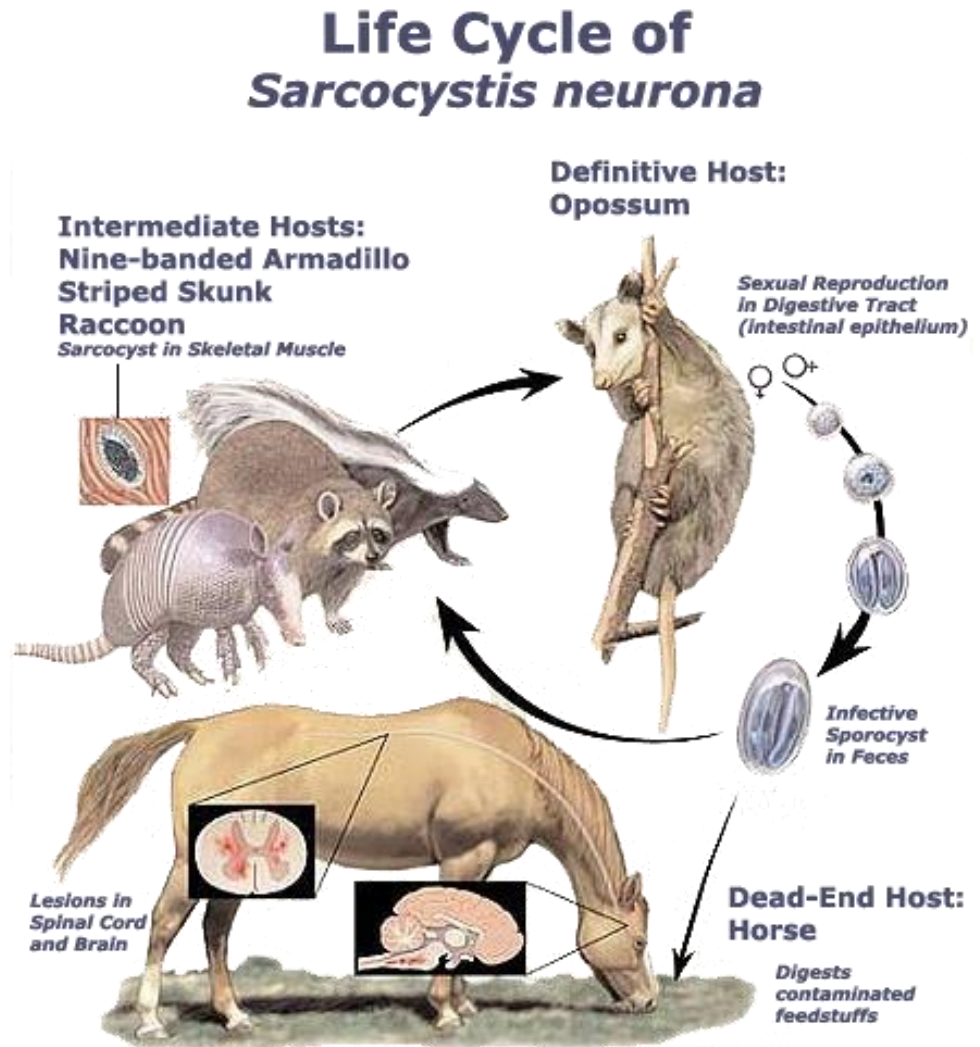
Microcyst in myocardium of red deer



Microcysts of *S. hominis* nestled in beef tongue.

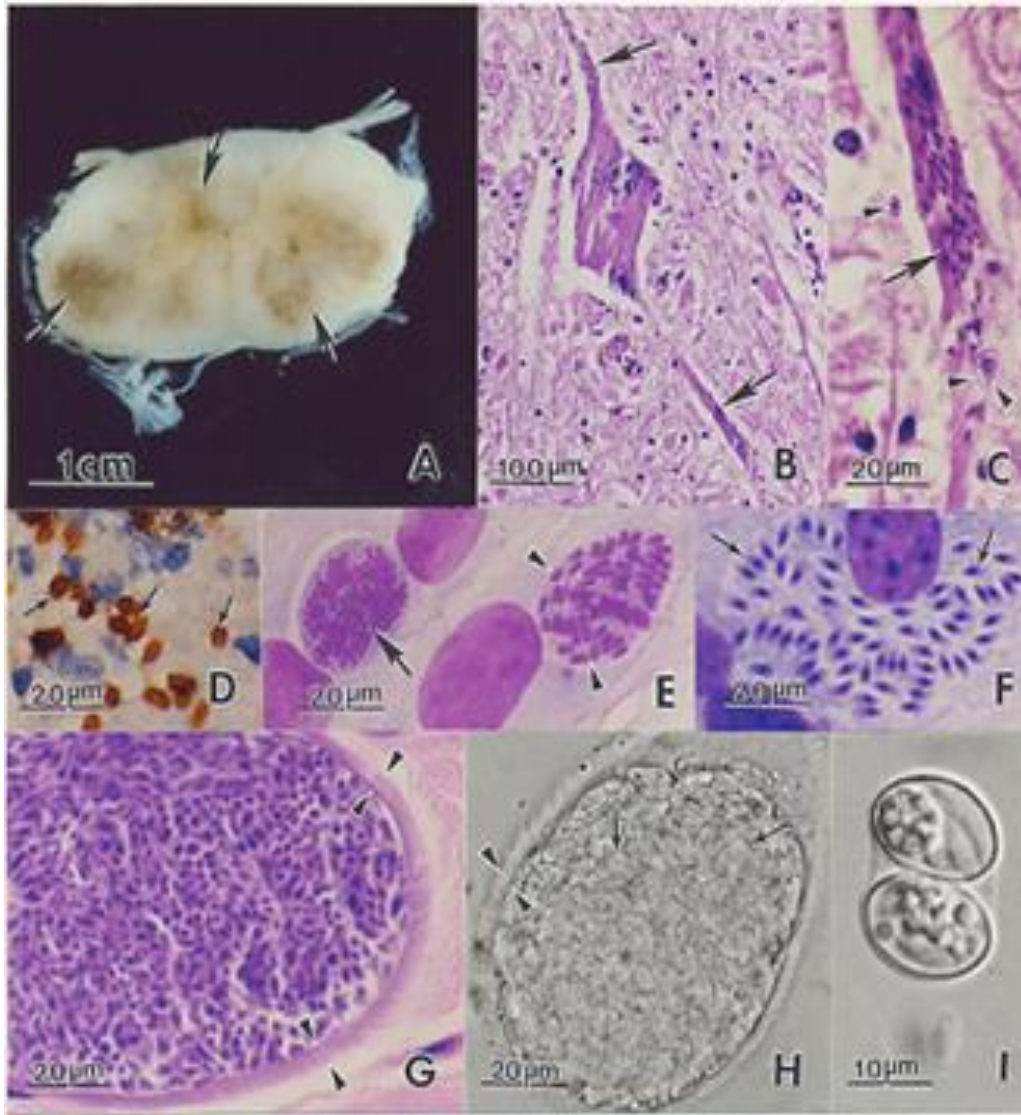
## *Sarcocystis neurona*

- equine protozoal myeloencephalitis (EPM) of horses in America
- DH: opossum (*Didelphis virginiana*, *D. albiventris*)
- relatively small sporocysts (10×8 μm)
- IH: horse (aberrant host, “dead-end,“)
- **sarcocysts** (asexual stages, about 700 μm) in horse nervous tissue
- in any part of the central nervous system CNS (brain, spinal cord)
- clinical signs of EPM, dependent on the area of the CNS parasitised, include ataxia, hypoalgesia, complete sensory loss, facial nerve paralysis, depression
- gradual progression of clinical signs





# *Sarcocystis neurona* developmental stages and lesions



**A)** Cross section of spinal cord of horse with focal areas of discoloration (arrows) indicative of necrosis. Unstained.

**B)** Section of spinal cord of a horse with severe EPM. Necrosis, and a heavily infected neuron (arrows), all dots (arrows) are merozoites. HE.

**C)** Higher magnification of a dendrite with numerous merozoites (arrows). One extracellular merozoite (arrowhead) and a young schizont (double arrowhead).

**D)** Section of brain of an experimentally-infected mouse stained with anti-*S. neurona* antibodies. Note numerous merozoites (arrows).

**E)** Immature meronts in cell culture: meront with multilobed nucleus (arrow) and a meront with differentiating merozoites (arrowheads). Giemsa.

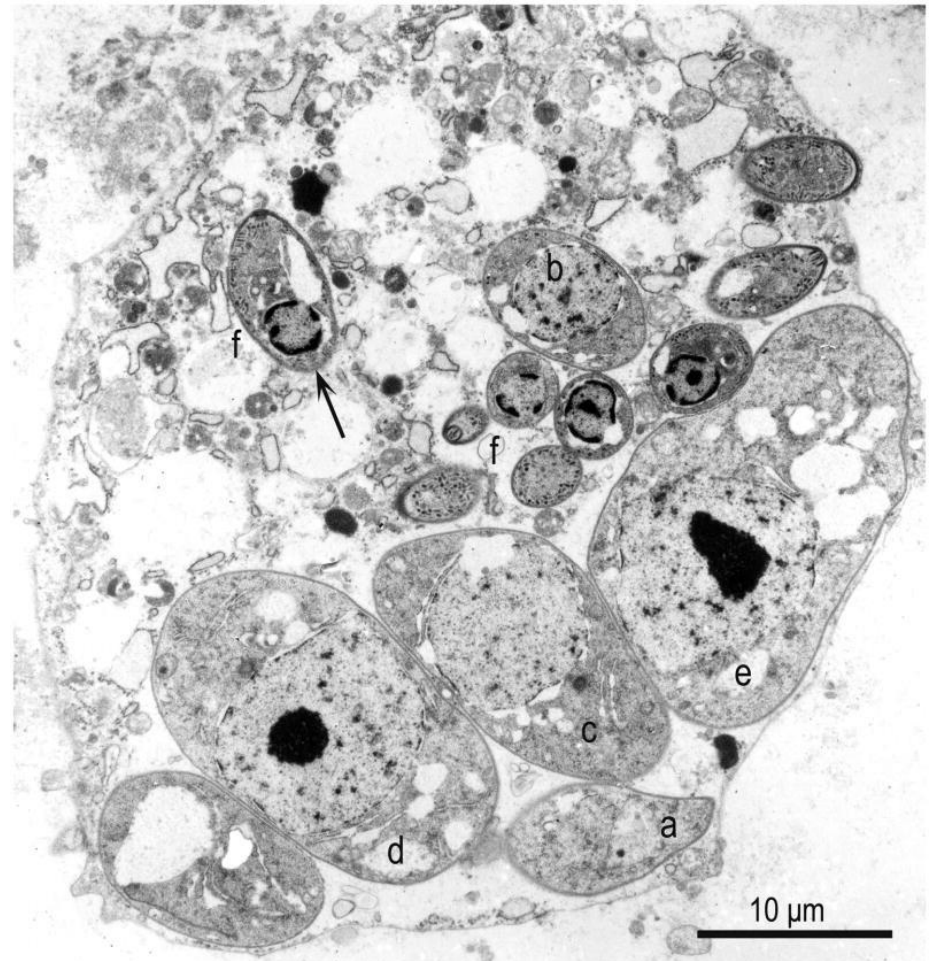
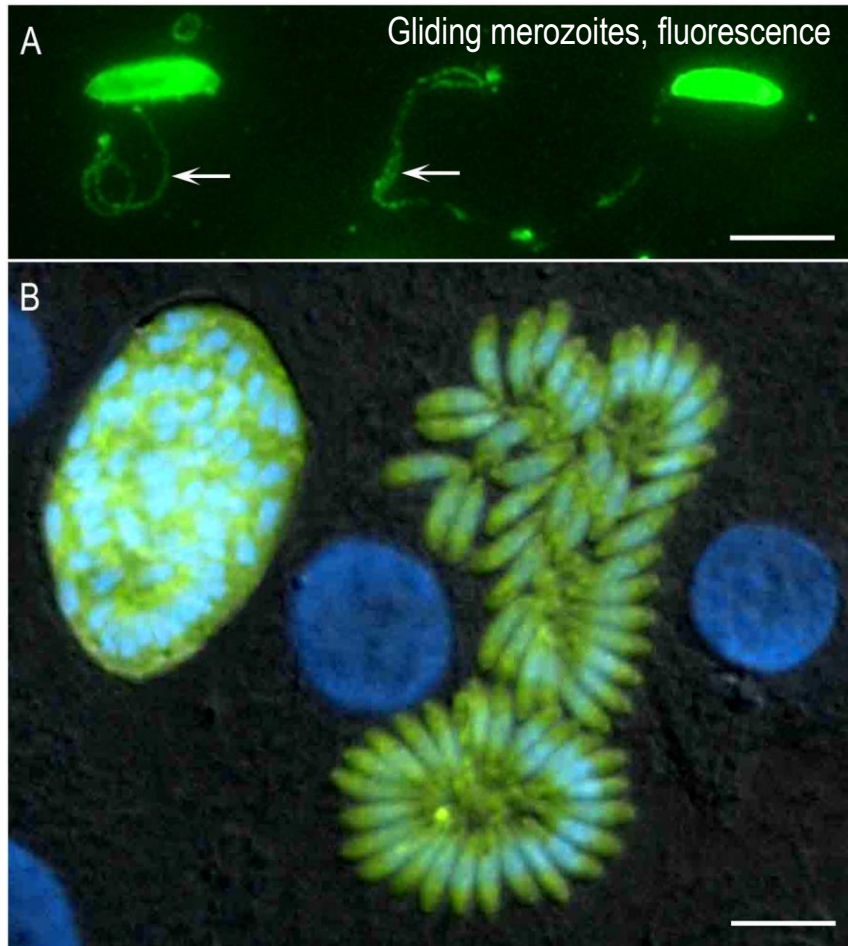
**F)** Meronts with merozoites. Giemsa.

**G)** Mature sarcocysts with hairlike villar protrusions (double arrowheads) on the sarcocyst wall. HE.

**H)** Mature live sarcocyst with numerous septa (arrows) and hairlike protrusions on the sarcocyst wall (double arrowheads). Unstained.

**I)** An oocyst with two sporocysts each with banana-shaped sporozoites. Unstained.

# Merogony in *Sarcocystis neurona*



Asynchronous merogony in neural cell in the brain of a raccoon naturally infected with *S. neurona*



# Sarcocystis and meat hygiene

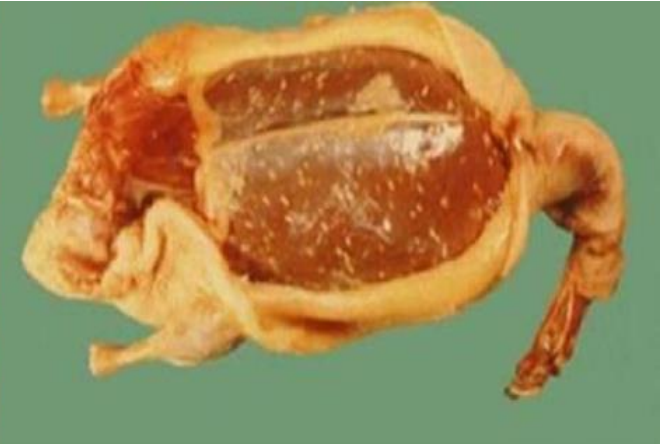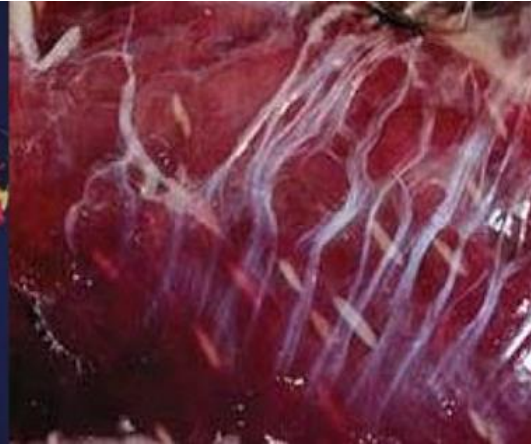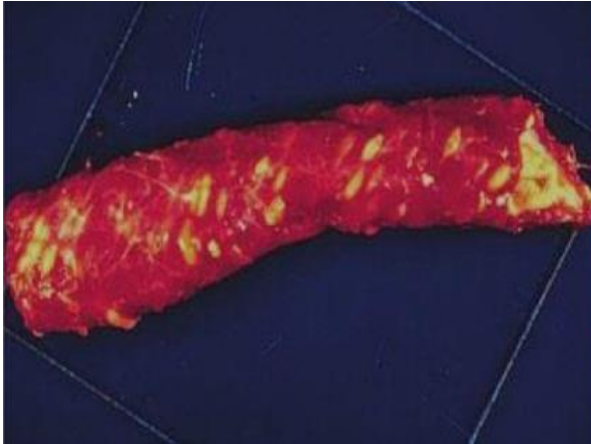
## Macroscopic meat changes

### *S. gigantea*

- ovine oesophagus

### *S. miescheriana (suicanis)*

- wild boars

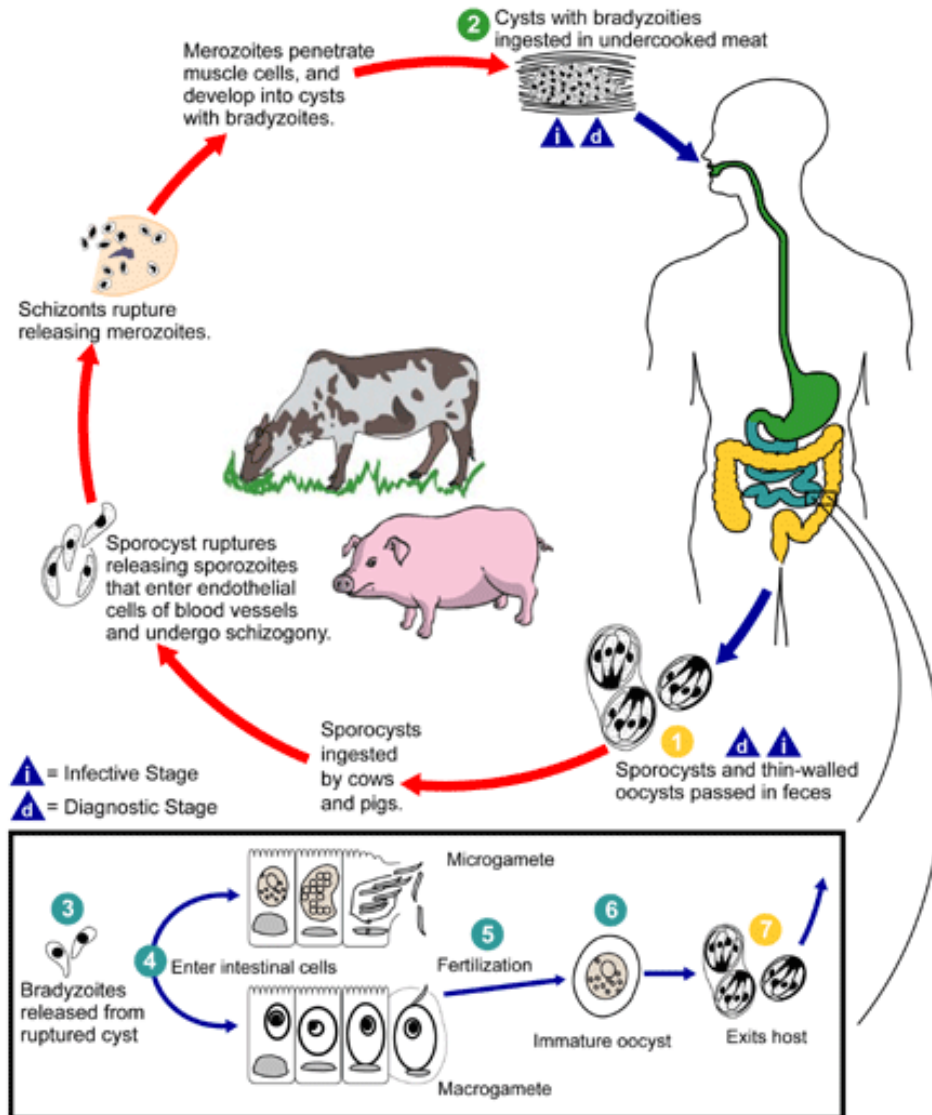


### *Sarcocystis rileyi*

- new parasite in Europe
- wild duck
- water fowls "rice breast disease",
- Orava in Slovakia (January 8, 2011)




# Life cycle *Sarcocystis hominis* and *S. suis*



Both species use **humans as definitive hosts** and are responsible for **intestinal sarcocystosis in the human host**.

Humans may also become dead-end hosts for non-human *Sarcocystis* spp. after the accidental ingestion of oocysts.



Contents lists available at ScienceDirect

# Research in Veterinary Science

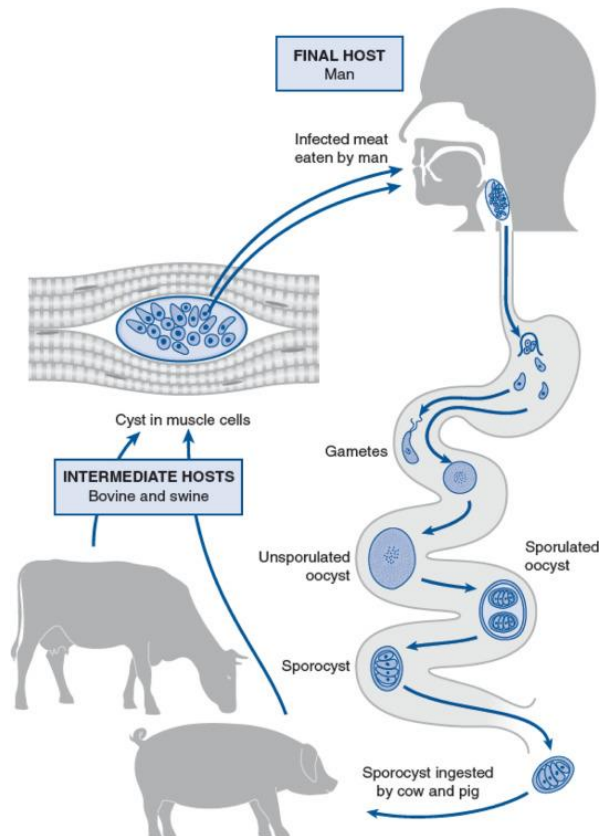
journal homepage: [www.elsevier.com/locate/rvsc](http://www.elsevier.com/locate/rvsc)



## Zoonotic Sarcocystis

Benjamin M. Rosenthal\*

Animal Parasitic Disease Laboratory, United States Department of Agriculture- Agricultural Research Service, 10300, Baltimore Avenue, Beltsville, MD 20705, United States of America

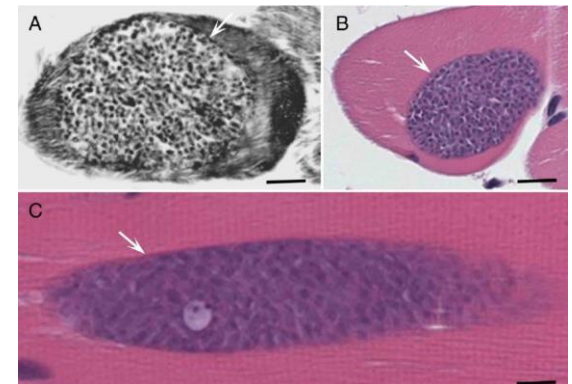


### ABSTRACT

Apicomplexan species in the genus *Sarcocystis* form tissue cysts, in their intermediate hosts, similar to those established in chronic toxoplasmosis. More than 200 species are known, but just a few are known to threaten human health owing to infection in livestock species. Intestinal sarcocystosis occurs when people consume raw or undercooked beef contaminated with *Sarcocystis hominis* or *S. heydorni* or undercooked pork contaminated with *S. suis/hominis*. Those infections may cause mild enteritis, but most infections are thought to be asymptomatic. People also become dead-end (intermediate) hosts for non-human *Sarcocystis* spp. after accidentally ingesting sporocysts, leading to extraintestinal sarcocystosis. The clinical spectrum may range from asymptomatic muscle cysts to a severe, acute, eosinophilic myositis associated with systemic symptoms with peripheral eosinophilia. Most human cases have been described from Southeast Asia, but *Sarcocystis* parasites have a worldwide distribution, especially where livestock is raised, and human infections in other areas have been described but may be underrecognized.

### Highlights

- *Sarcocystis* parasites are a rare cause of eosinophilic enteritis, subcutaneous nodules, and eosinophilic myositis.
- Human intestinal infections derive from *Sarcocystis hominis* *S. suis/hominis*, and *S. heydorni*
- Eating undercooked beef or pork may cause mild enteritis, but most infections are asymptomatic.
- People also can contract muscular sarcocystosis by ingesting parasite oocysts.
- Muscle cysts may cause severe acute eosinophilic myositis, systemic symptoms, and peripheral eosinophilia.
- Most human cases have been documented in Southeast Asia.





# Human muscle sarcocystosis

OPEN ACCESS Freely available online

<https://doi.org/10.1371/journal.pntd.0002876>

PLOS | NEGLECTED TROPICAL DISEASES

## *Sarcocystis nesbitti* Causes Acute, Relapsing Febrile Myositis with a High Attack Rate: Description of a Large Outbreak of Muscular Sarcocystosis in Pangkor Island, Malaysia, 2012



Claire M. Italiano<sup>1</sup>, Kum Thong Wong<sup>2</sup>, Sazaly AbuBakar<sup>3</sup>, Yee Ling Lau<sup>4</sup>, Norlisah Ramli<sup>5</sup>, Sharifah Faridah Syed Omar<sup>1</sup>, Maria Kahar Bador<sup>6</sup>, Chong Tin Tan<sup>1\*</sup>

**1** Department of Medicine, Faculty of Medicine, University of Malaya, Kuala Lumpur, Malaysia, **2** Department of Pathology, Faculty of Medicine, University of Malaya, Kuala Lumpur, Malaysia, **3** TIDREC, Department of Medical Microbiology, Faculty of Medicine, University of Malaya, Kuala Lumpur, Malaysia, **4** Department of Parasitology, Faculty of Medicine, University of Malaya, Kuala Lumpur, Malaysia, **5** Department of Medical Imaging, Faculty of Medicine, University of Malaya, Kuala Lumpur, Malaysia, **6** Department of Medical Microbiology, Faculty of Medicine, University of Malaya, Kuala Lumpur, Malaysia

### Abstract

**Background:** From the 17<sup>th</sup> to 19<sup>th</sup> January 2012, a group of 92 college students and teachers attended a retreat in a hotel located on Pangkor Island, off the west coast of Peninsular Malaysia. Following the onset of symptoms in many participants who presented to our institute, an investigation was undertaken which ultimately identified *Sarcocystis nesbitti* as the cause of this outbreak.

**Methodology/Principal Findings:** All retreat participants were identified, and clinical and epidemiological information was obtained via clinical review and self-reported answers to a structured questionnaire. Laboratory, imaging and muscle biopsy results were evaluated and possible sources of exposure, in particular water supply, were investigated. At an average of 9–11 days upon return from the retreat, 89 (97%) of the participants became ill. A vast majority of 94% had fever with 57% of these persons experiencing relapsing fever. Myalgia was present in 91% of patients. Facial swelling from myositis of jaw muscles occurred in 9 (10%) patients. The median duration of symptoms was 17 days (IQR 7 to 30 days; range 3 to 112). Out of 4 muscle biopsies, sarcocysts were identified in 3. *S. nesbitti* was identified by PCR in 3 of the 4 biopsies including one biopsy without observed sarcocyst. Non-Malaysians had a median duration of symptoms longer than that of Malaysians (27.5 days vs. 14 days,  $p = 0.001$ ) and were more likely to experience moderate or severe myalgia compared to mild myalgia (83.3% vs. 40.0%,  $p = 0.002$ ).

**Conclusions/Significance:** The similarity of the symptoms and clustered time of onset suggests that all affected persons had muscular sarcocystosis. This is the largest human outbreak of sarcocystosis ever reported, with the specific *Sarcocystis* species identified. The largely non-specific clinical features of this illness suggest that *S. nesbitti* may be an under diagnosed infection in the tropics.

# Human sarcocystosis

## Muskuläre Sarkozystose nach Malaysiareise: eine Fallserie aus Deutschland

### Muscular sarcocystosis after travel to Malaysia: a case series from Germany

#### Autoren

G. Slesak<sup>1</sup> D. Tappe<sup>2</sup> C. Keller<sup>3</sup> J. Cramer<sup>3,4</sup> W. Güthoff<sup>5</sup> P. Zanger<sup>6</sup> M. Frank<sup>6</sup> K. Ernestus<sup>7</sup>  
S. Rauthe<sup>7</sup> A. Stich<sup>8</sup> J. Schäfer<sup>1</sup>

#### Institut

- <sup>1</sup> Tropenlinik Paul-Lechler-Krankenhaus, Tübingen
- <sup>2</sup> Institut für Hygiene und Mikrobiologie, Universität Würzburg
- <sup>3</sup> Bernhard-Nocht-Institut für Tropenmedizin, Hamburg
- <sup>4</sup> Sektion Tropenmedizin, I. Medizinische Klinik, Universitätsklinikum Hamburg-Eppendorf
- <sup>5</sup> Klinikum Ernst von Bergmann, Potsdam
- <sup>6</sup> Institut für Tropenmedizin, Tübingen
- <sup>7</sup> Pathologisches Institut, Universität Würzburg
- <sup>8</sup> Missionsärztliche Klinik, Würzburg

#### Infektiologie, Reisemedizin

##### Schlüsselwörter

- Muskuläre Sarkozystose
- Sarcocystis
- Tioman
- Malaysia
- klinischer Verlauf

##### Keywords

- muscular sarcocystosis
- sarcocystis
- Tioman
- Malaysia
- clinical course of disease

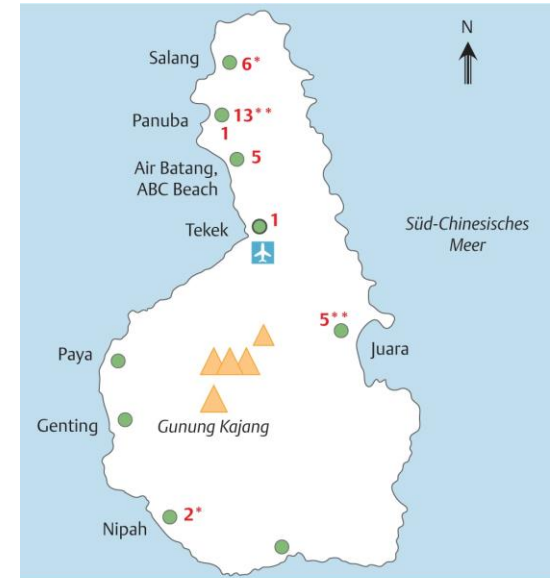
#### Zusammenfassung

**Hintergrund:** Seit 2011 wurde weltweit bei ca. 100 Besuchern der Insel Tioman, Malaysia, die Verdachtsdiagnose einer muskulären Sarkozystose gemeldet, einer bislang nur sporadisch beobachteten parasitären Erkrankung. Ausbruchursache sowie Therapie sind unklar. Die Diagnosesicherung erfordert den mikroskopischen Zysten-Nachweis im Muskelbiopsat. Studienziel war die systematische Beschreibung der diagnostisch wegweisenden Symptome, Laboruntersuchungen und des Therapieansprechens.  
**Methodik:** Systematische Fallserie.

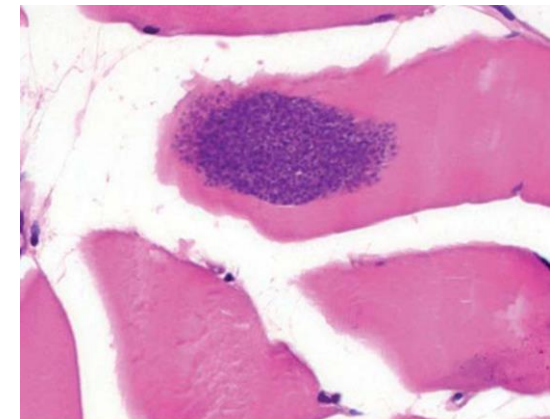
**Ergebnisse:** Die 26 Fälle aus fünf tropenmedizinischen Zentren Deutschlands zeigen einen charakteristischen zweiphasigen Krankheitsverlauf: zwei Wochen nach Urlaubsmitte (min. 7,5/ max. 22 Tage) tritt uncharakteristisches knapp einwöchiges Fieber mit Kopfschmerz auf, nach zweiwöchiger überwiegender Beschwerdefreiheit folgen ca. 6 Wochen andauernde (min. 7/ max. 207 Tage), starke Myalgien (6,5, Skala 0–10), Fieber, Erhöhung der Kreatinkinase (CK; bis 3,5-fach)

und Eosinophilie (2,9-fach). Eine von zwei Muskelbiopsien zeigte eine Sarkozystose-typische Zyste, bei 6 von 7 untersuchten Patienten war mittels ELISA ein Anstieg Sarcocystis-spezifischer Antikörper nachweisbar. Behandlungsversuche mit systemischen Glukokortikoiden und Albendazol, oder Ivermectin erbrachten zumeist deutliche Beschwerdeverbesserungen. Bei einem Patienten entwickelte sich nach frühzeitiger Cotrimoxazol-Therapie keine zweite Erkrankungsphase. Alle Patienten hatten Aufenthalte im Nordwesten der Insel Tioman.

**Folgerungen:** Die Muskelsarkozystose verläuft zweiphasig mit initialem Fieber und später prolongierten Myalgien, Eosinophilie und CK-Erhöpfung. Eine Steroidstherapie ist in der Spätphase beschwerdelindernd. Frühzeitige Cotrimoxazol-Gabe verhindert möglicherweise die parasitäre Muskelinvasion. Bei Fieber nach Malaysia-Aufenthalt sollte Sarkozystose differenzialdiagnostisch bedacht werden. Die Infektionsquelle erscheint konzentriert auf den Nord-Westen Tiomans. Weitere Untersuchungen, inklusive zur Früh-Diagnostik und Therapie sind notwendig.



**Abb.5:** Karte der Insel Tioman mit Übernachtungsorten der Touristen. Nummern beschreiben die Personenzahl pro Übernachtungsort.  
\* Übernachtungen anfangs in Nipah, dann in Salang.  
\*\* 5 Patienten übernachteten zuerst in Juara, dann Panuba.  
14 Übernachtungen erfolgten um Panuba, davon 13 im selben Resort.



**Abb.3** Histologischer Muskelbiopsiefund (M. tibialis anterior eines 31-jährigen Patienten, 8 Wochen nach Symptombeginn, HE, 1000 ×) mit intrazellulärer Sarcocystis-typischen, dünn-bewandeten Zyste mit innenliegenden Bradyzoiten. © American Society for Microbiology [29].



# Human sarcocystosis



RESEARCH ARTICLE

## Examination of *Sarcocystis* spp. of giant snakes from Australia and Southeast Asia confirms presence of a known pathogen – *Sarcocystis nesbitti*

Marion Wassermann<sup>1</sup>, Lisa Raisch<sup>1</sup>, Jessica Ann Lyons<sup>2</sup>, Daniel James Deans Natusch<sup>3</sup>, Sarah Richter<sup>4</sup>, Mareike Wirth<sup>1</sup>, Piyarat Preeprem<sup>4</sup>, Yuvaluk Khoprasert<sup>4</sup>, Sulaiman Ginting<sup>5</sup>, Ute Mackenstedt<sup>1</sup>, Thomas Jäkel<sup>1,4\*</sup>

**1** Department of Zoology, Division of Parasitology, University of Hohenheim, Stuttgart, Germany, **2** Resource Evaluation and Development, Bamaga, Queensland, Australia, **3** School of Life and Environmental Sciences, University of Sydney, Sydney, NSW, Australia, **4** Plant Protection Research and Development Office, Department of Agriculture, Bangkok, Thailand, **5** Islamic University of North Sumatra, Medan, Indonesia

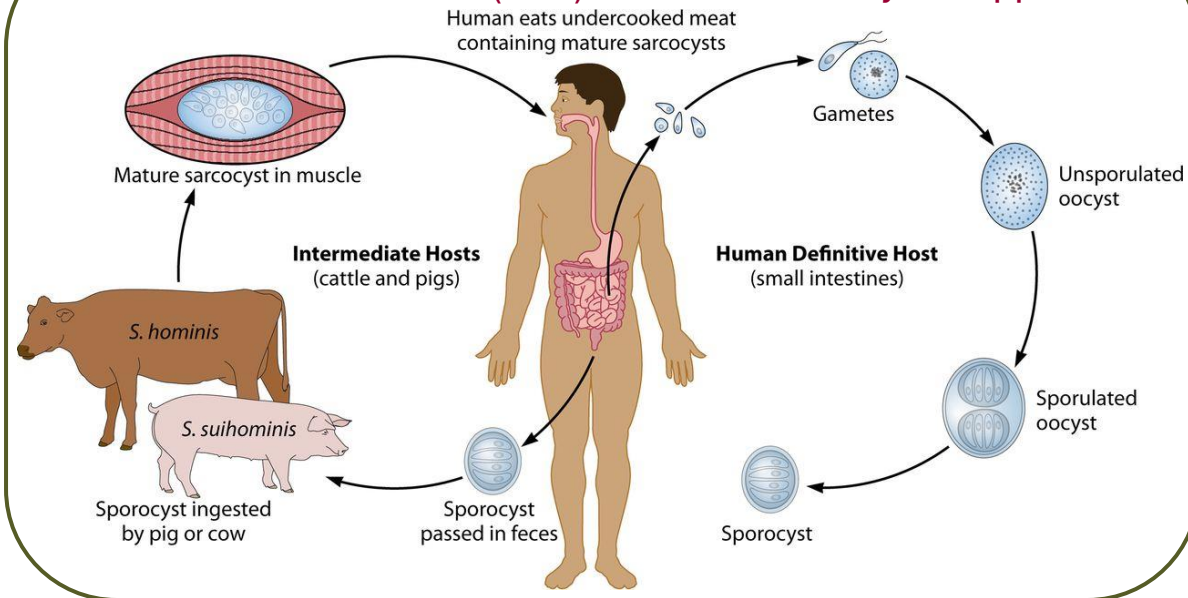
\* thom.jaekel@t-online.de

### Abstract

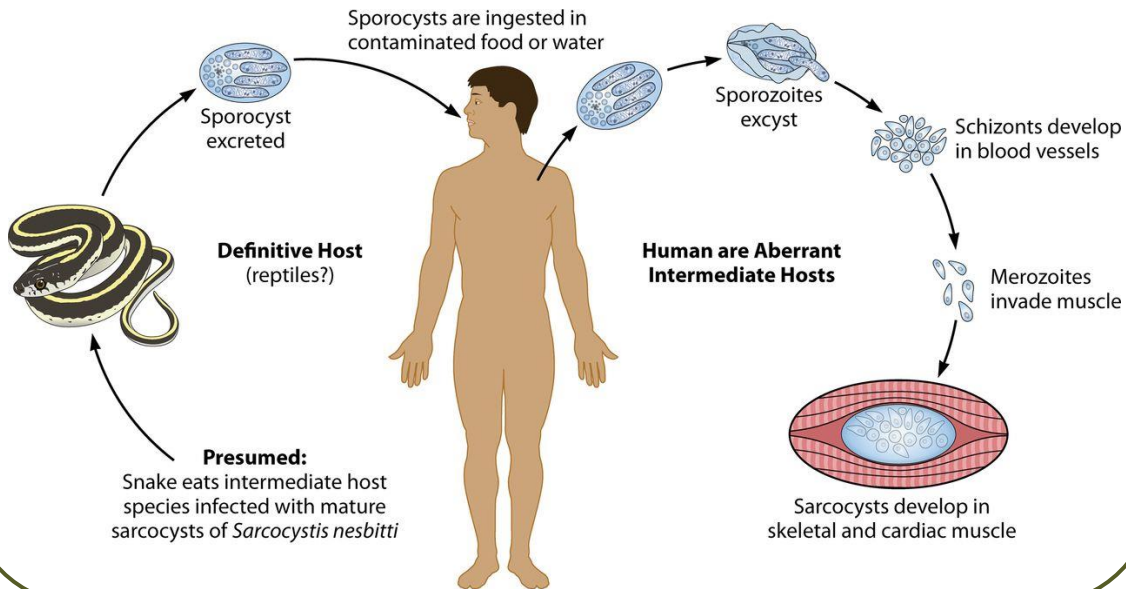
We examined *Sarcocystis* spp. in giant snakes from the Indo-Australian Archipelago and Australia using a combination of morphological (size of sporocyst) and molecular analyses. We amplified by PCR nuclear 18S rDNA from single sporocysts in order to detect mixed infections and unequivocally assign the retrieved sequences to the corresponding parasite stage. *Sarcocystis* infection was generally high across the study area, with 78 (68%) of 115 examined pythons being infected by one or more *Sarcocystis* spp. Among 18 randomly chosen, sporocyst-positive samples (11 from Southeast Asia, 7 from Northern Australia) the only *Sarcocystis* species detected in Southeast Asian snakes was *S. singaporensis* (in reticulated pythons), which was absent from all Australian samples. We distinguished three different *Sarcocystis* spp. in the Australian sample set; two were excreted by scrub pythons and one by the spotted python. The sequence of the latter is an undescribed species phylogenetically related to *S. lacertae*. Of the two *Sarcocystis* species found in scrub pythons, one showed an 18S rRNA gene sequence similar to *S. zamani*, which is described from Australia for the first time. The second sequence was identical/similar to that of *S. nesbitti*, a known human pathogen that was held responsible for outbreaks of disease among tourists in Malaysia. The potential presence of *S. nesbitti* in Australia challenges the current hypothesis of a snake-primate life cycle, and would have implications for human health in the region. Further molecular and biological characterizations are required to confirm species identity and determine whether or not the Australian isolate has the same zoonotic potential as its Malaysian counterpart. Finally, the absence of *S. nesbitti* in samples from reticulated pythons (which were reported to be definitive hosts), coupled with our phylogenetic analyses, suggest that alternative snake hosts may be responsible for transmitting this parasite in Malaysia.



## Humans as definitive (final) hosts for *Sarcocystis* spp.

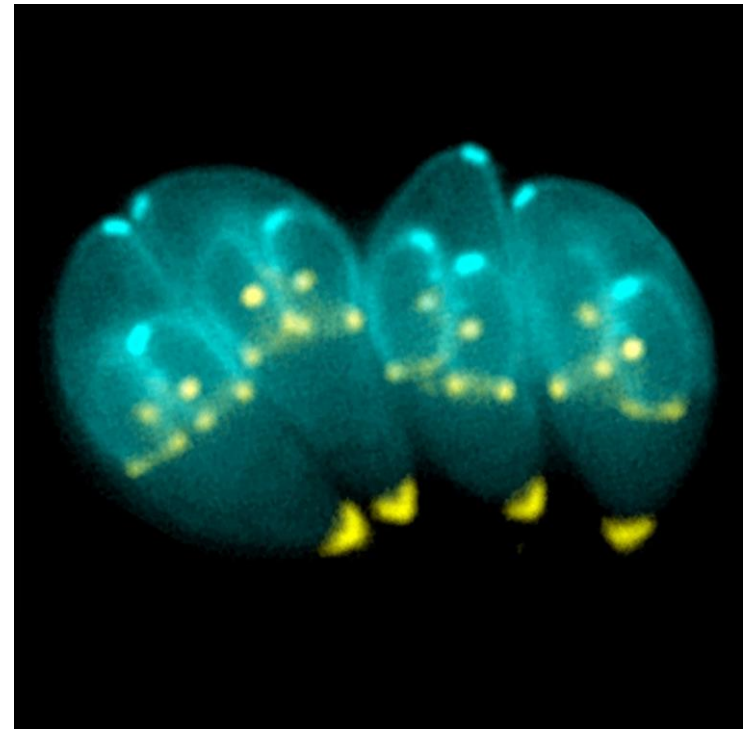
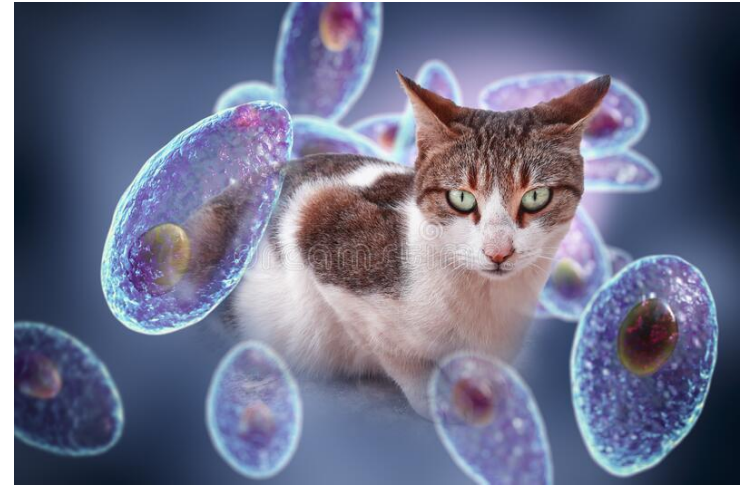


## Humans as aberrant intermediate hosts for *Sarcocystis* spp.

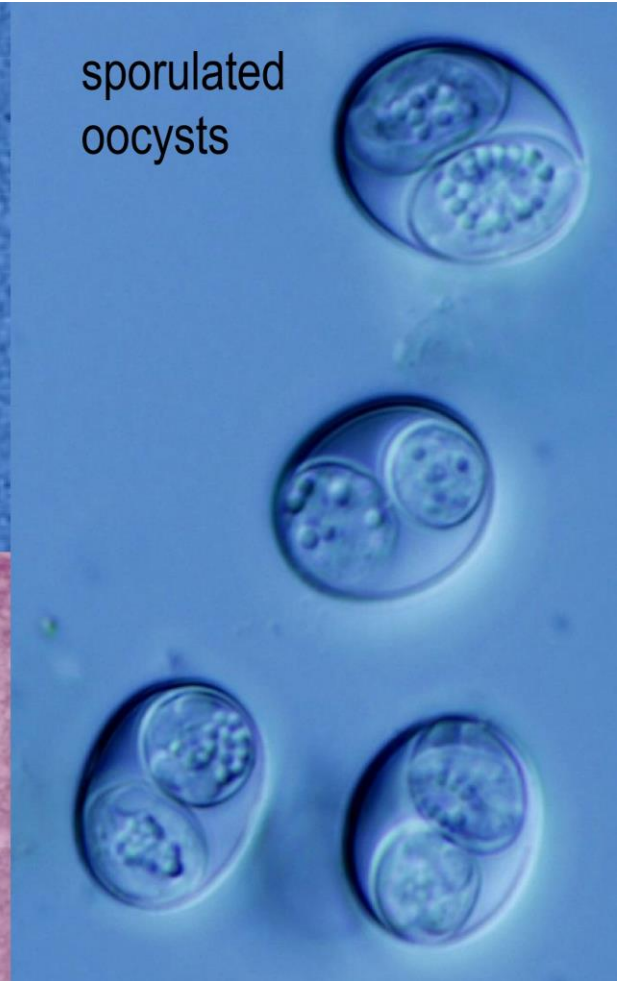
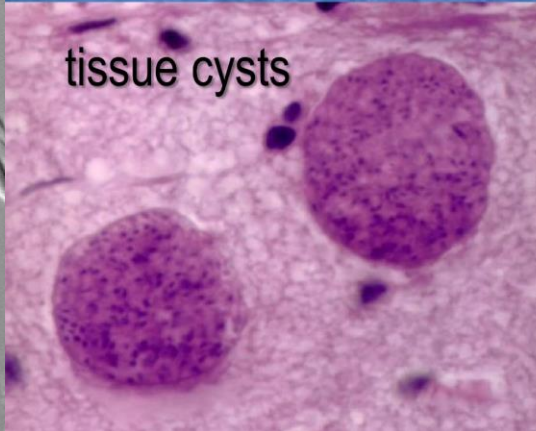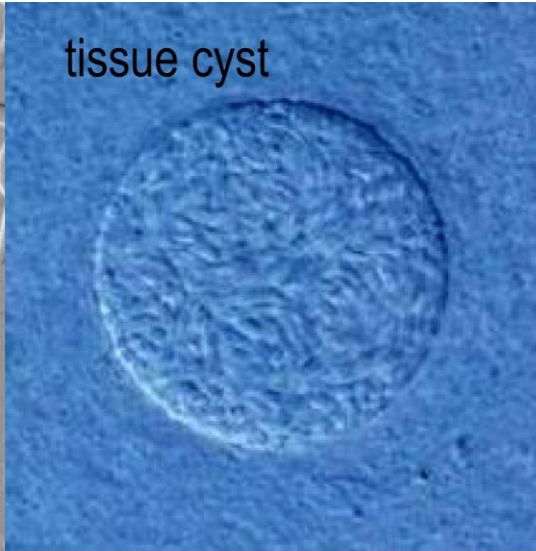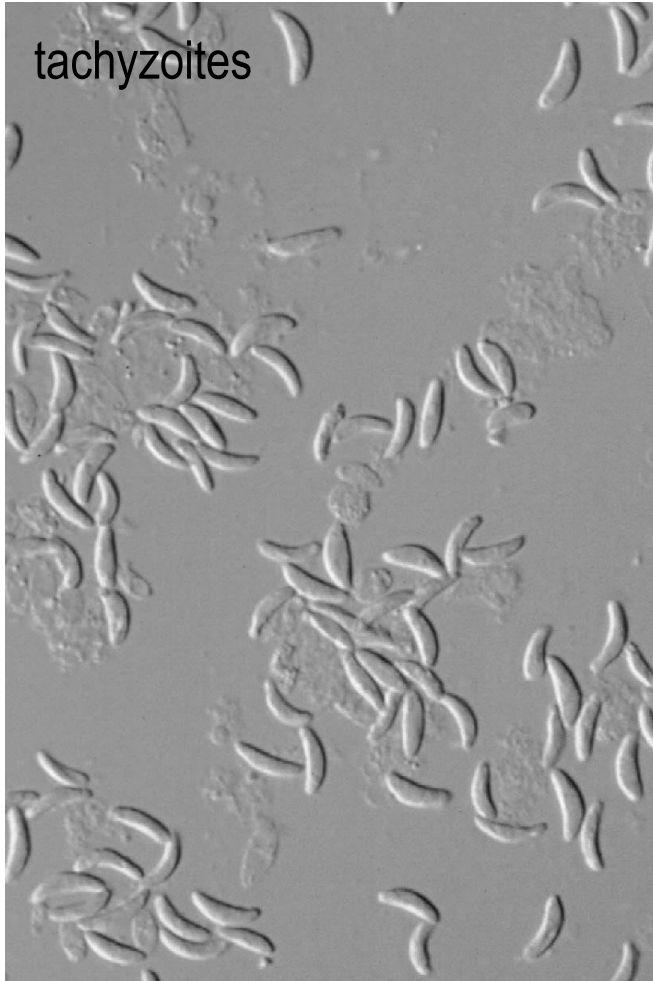


## *Toxoplasma gondii*

- DH: Felidae
- IH: birds and mammals (warm-blooded vertebrates)
- 3 types of infectious stages:
  - tachyzoites** - tachos = rapid, endodyogeny
  - bradyzoites** - brady = slow, endopolygeny
  - sporozoites** in fully sporulated oocyst
- bradyzoites ⇔ tachyzoites - immunologically mediated (IFN- $\gamma$ ) <https://doi.org/10.1080/08830180213279>
- *in vitro* cultivation
- **toxoplasmosis = zoonosis**
- nearly one-third of humans has been exposed
- abortions in animals (small ruminants, antelopes, marine mammals, ...)



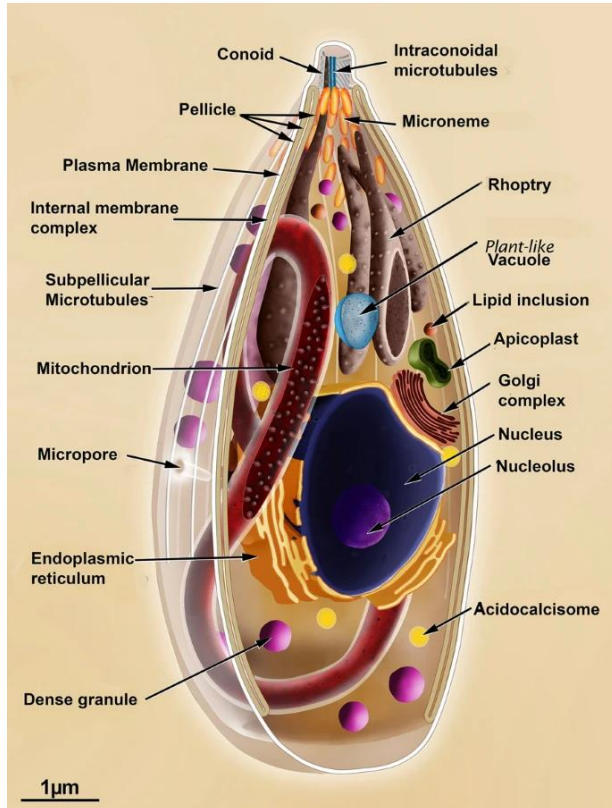
# Developmental stages of *Toxoplasma gondii*



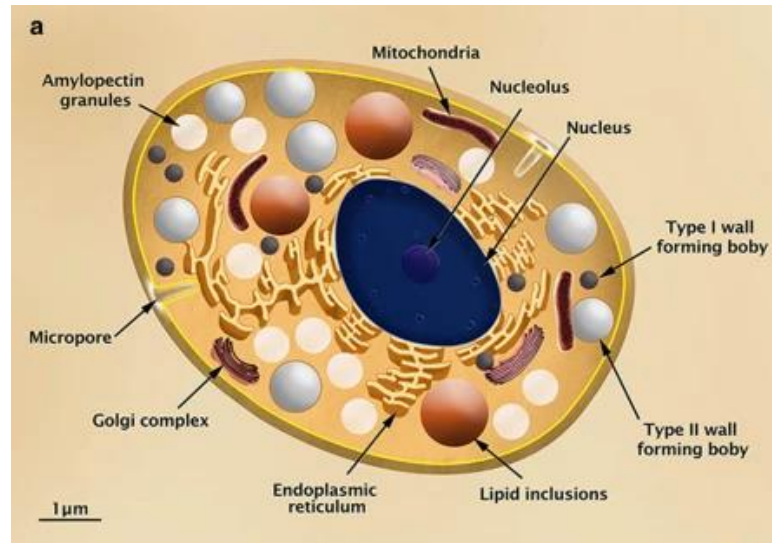


# Subcellular organisation of *Toxoplasma gondii*

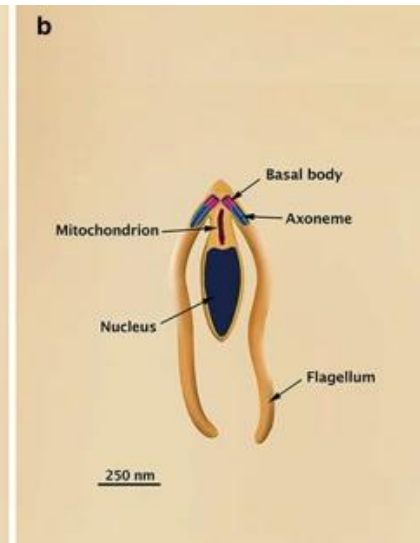
## Tachyzoite



## Macrogamete

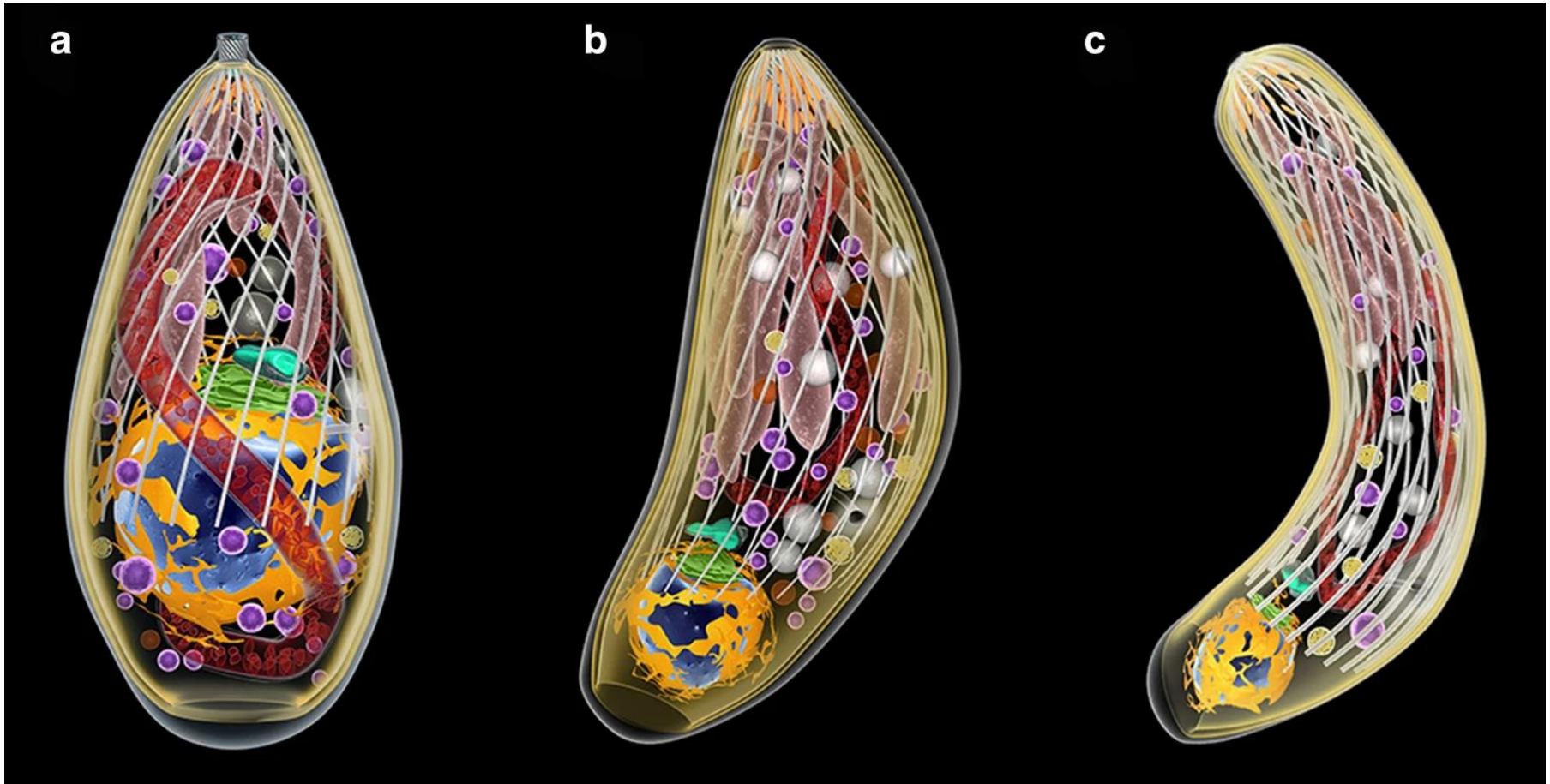


## Microgamete



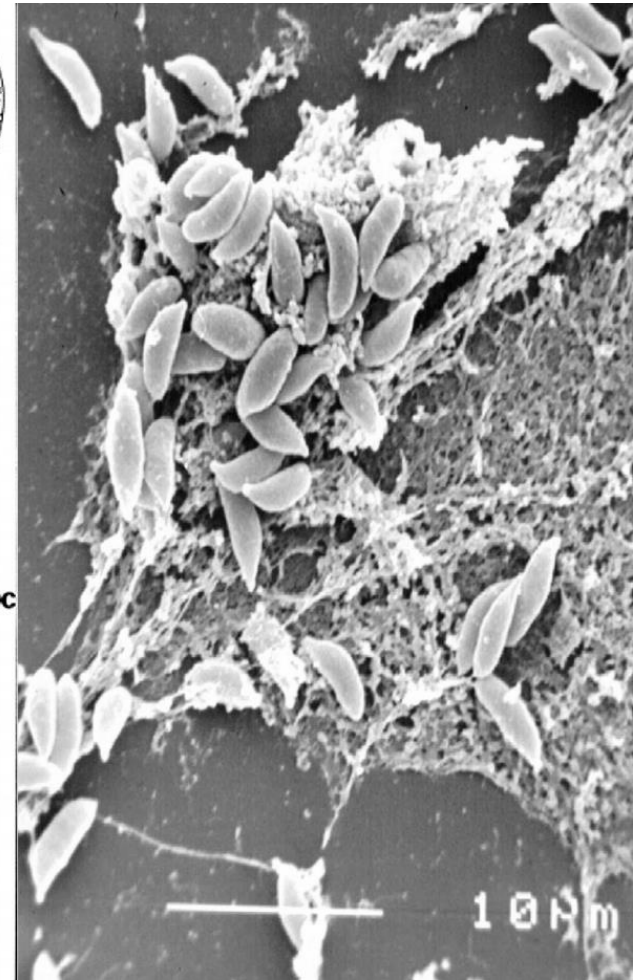
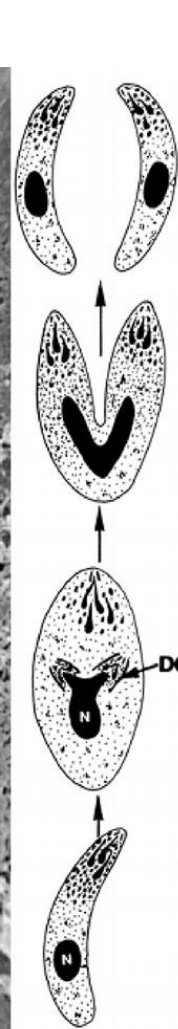
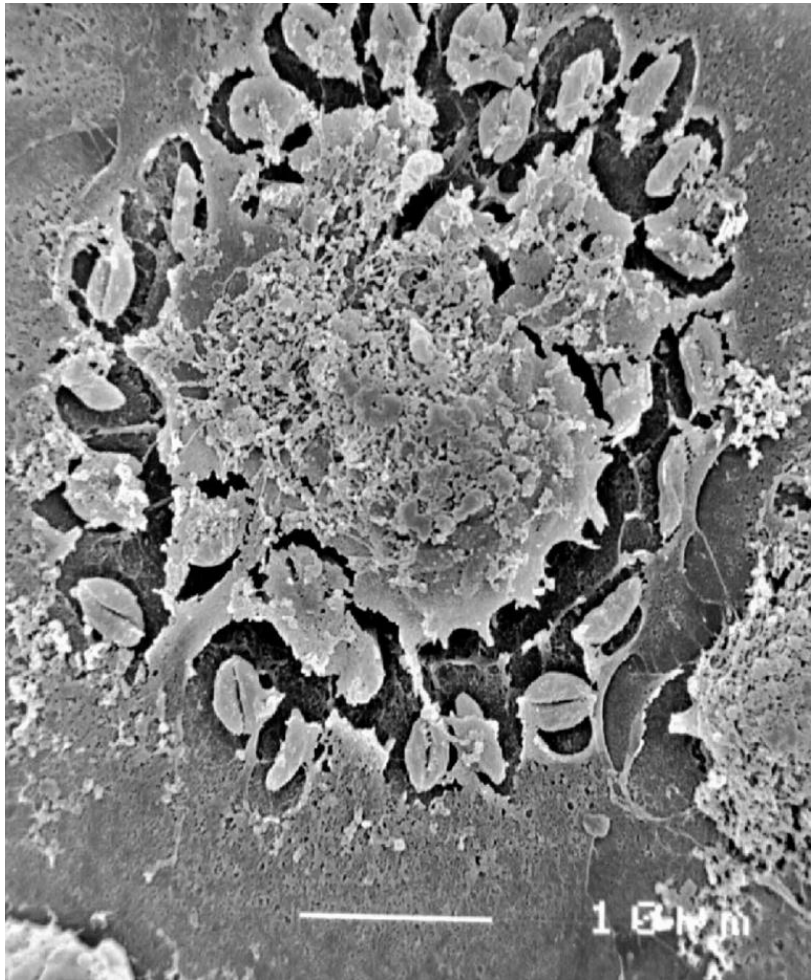


# Subcellular organisation of *Toxoplasma gondii*

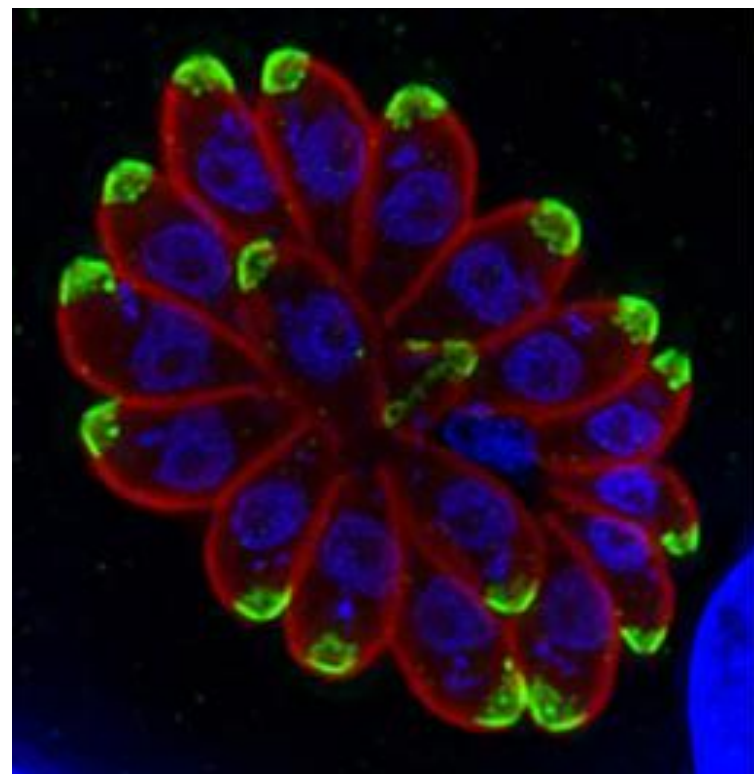
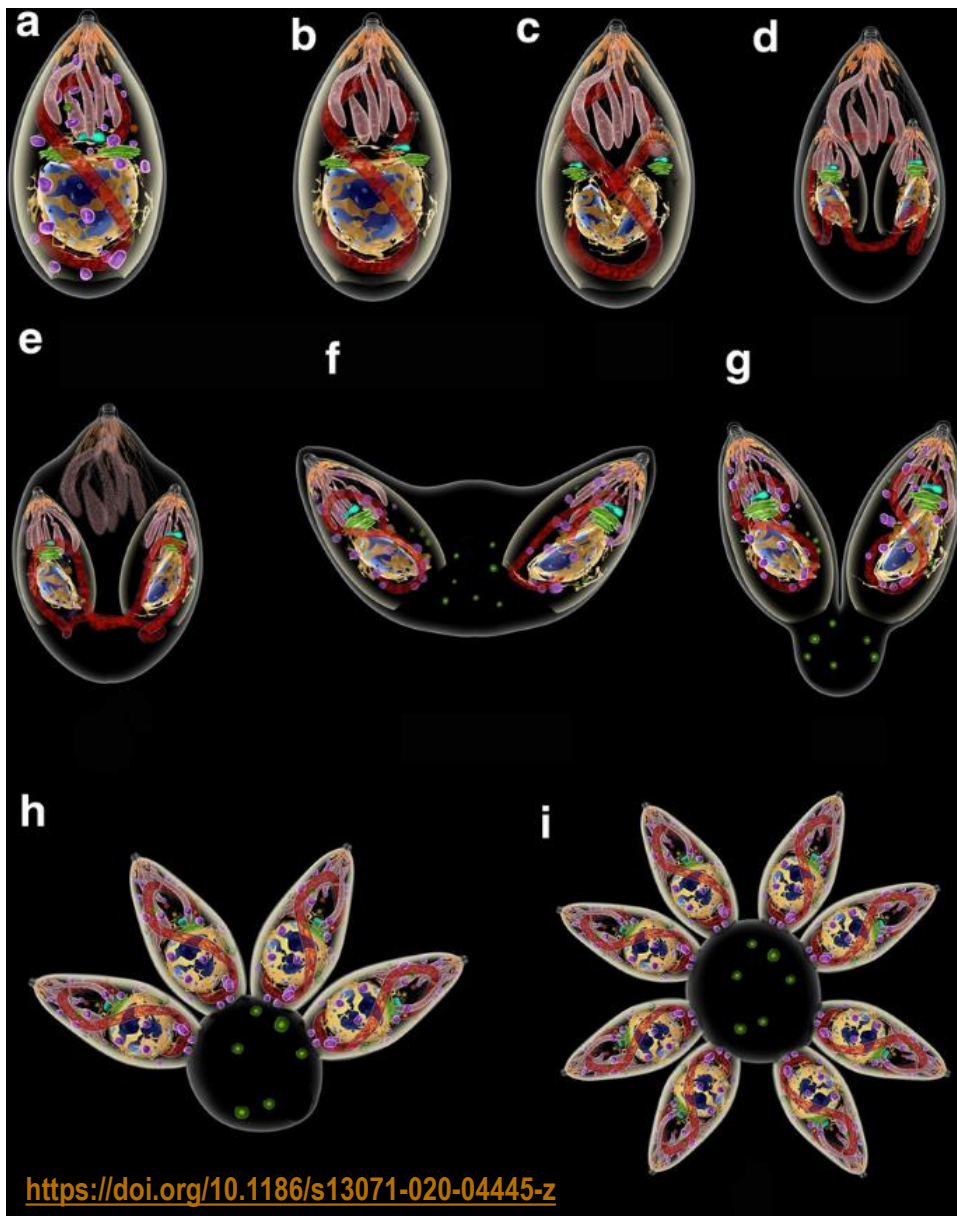


Tachyzoite (a), bradyzoite (b), and sporozoite (c)

# Endodyogeny in *Toxoplasma gondii* (in vitro)



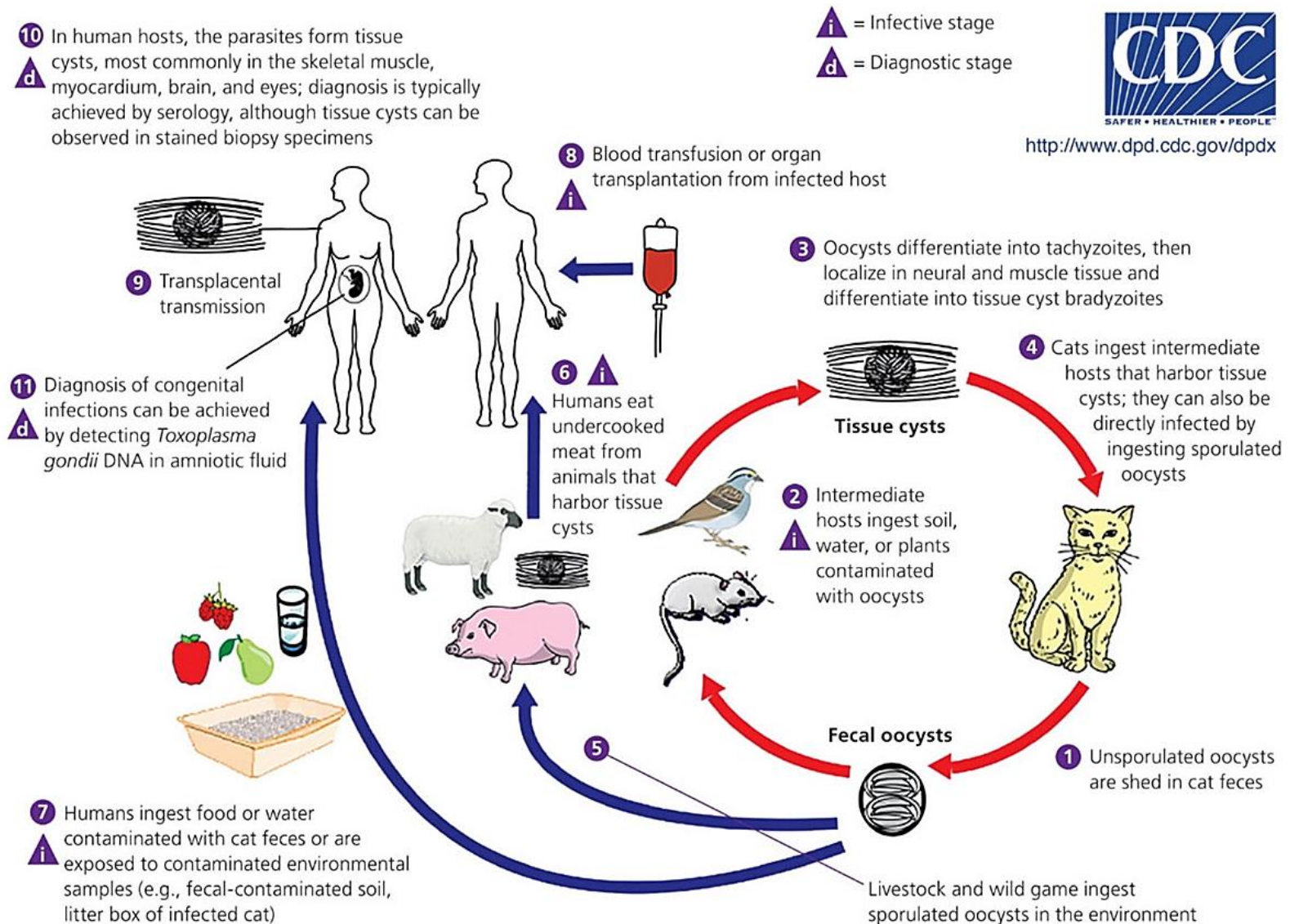
# Endodyogeny in *Toxoplasma gondii*

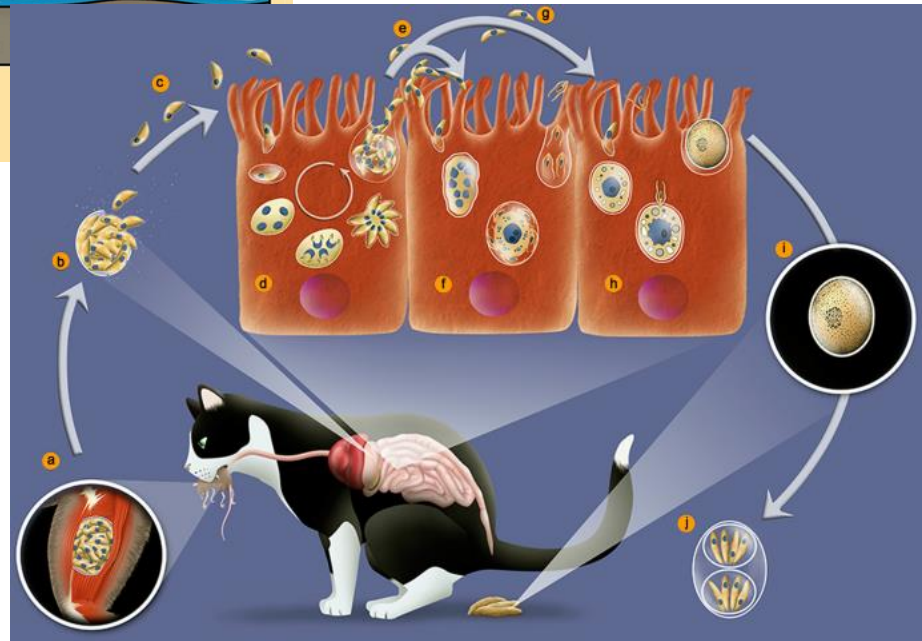
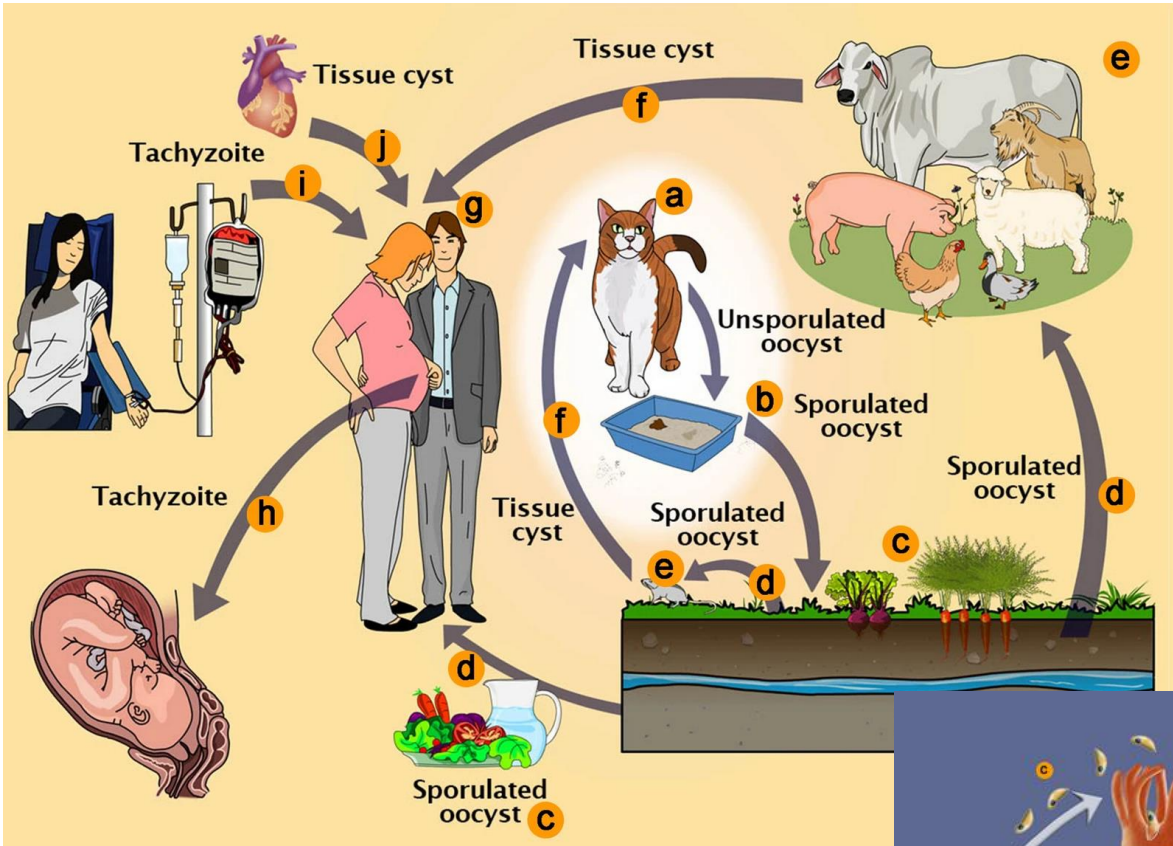


- a-b)** The first to divide is the Golgi complex and the apicoplast.  
**c)** Nucleus assumes a horse-shoe shape. Two new apical complexes start to form.  
**d)** Inner pellicle grows and embraces the structures of the daughter cells, including nucleus.  
**e)** The last to be separated between the daughter cells is the mitochondrion. Apical complex of mother cell is still maintained.  
**f)** Two daughter cells emerge, and the outer membrane of the mother cell is incorporated. Apical complex of the mother cell disappears.  
**g)** Two daughter cells remain linked to the residual body where acidocalcisomes (green) start to accumulate.  
**h)** Process is repeated until a parasite rosette is formed (i)

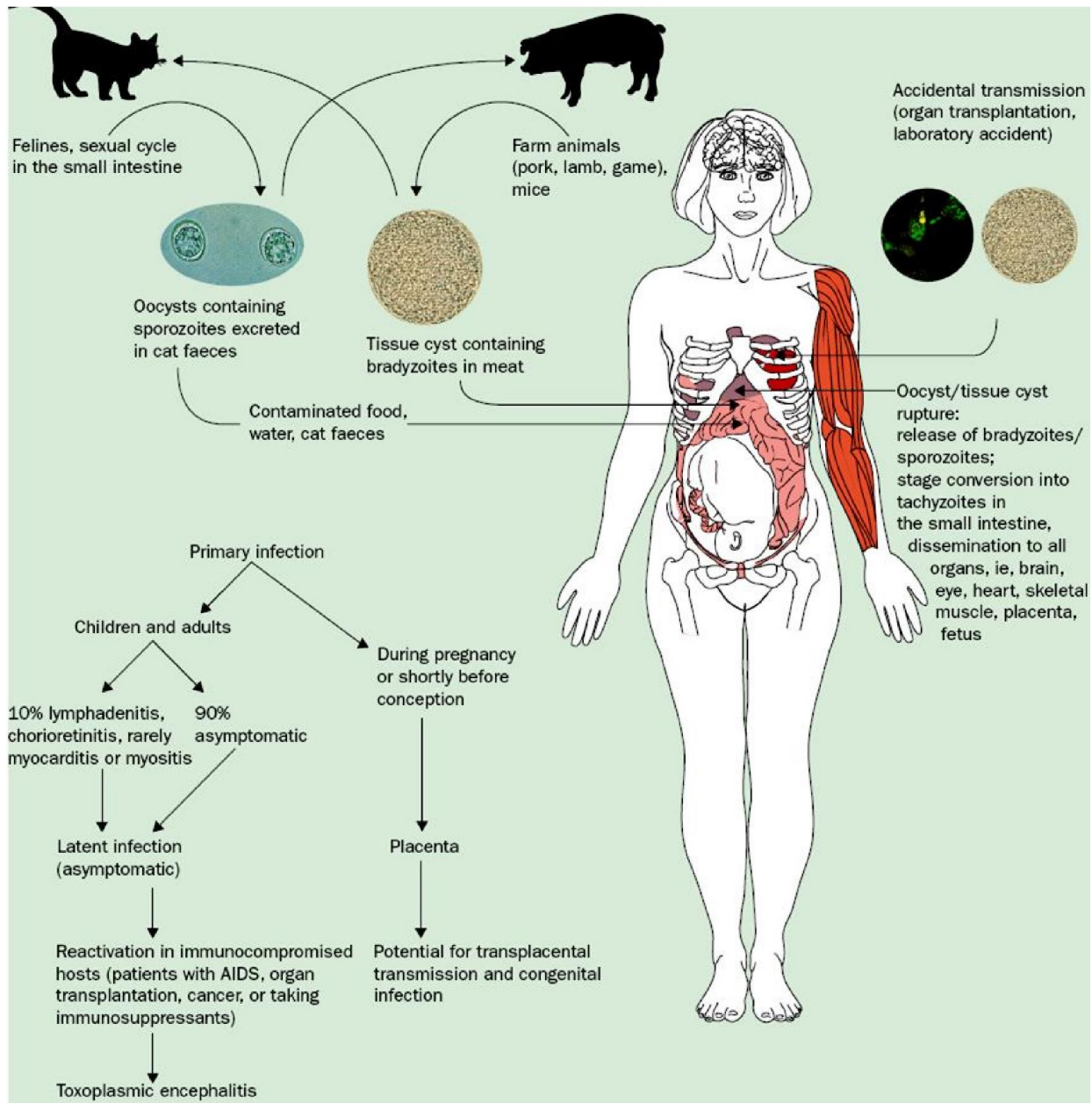


# Life cycle of *Toxoplasma gondii*



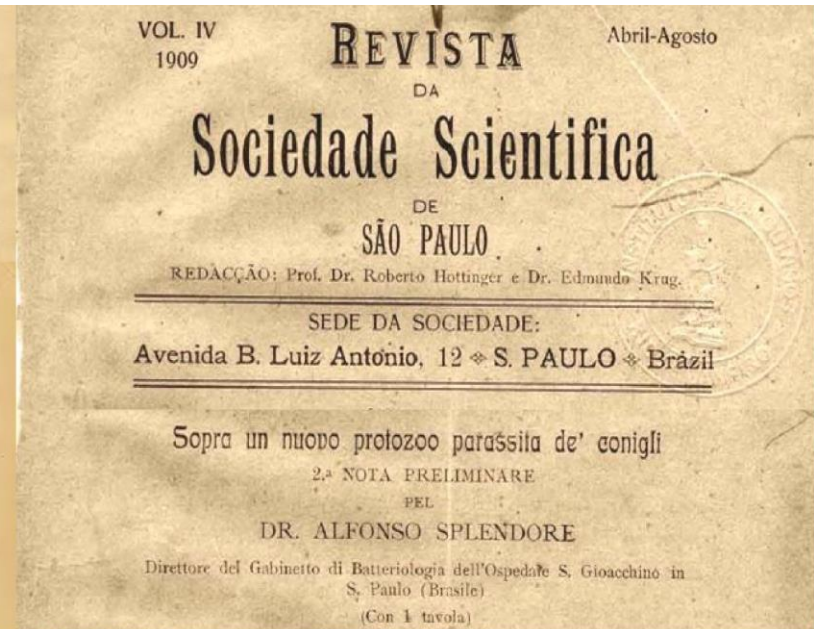
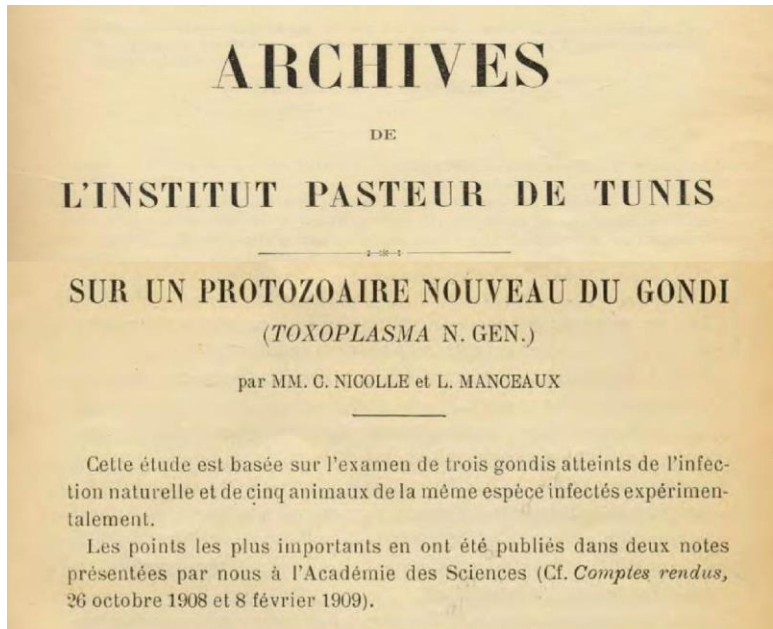


- a) Feline definitive host (cat).
- b) Unsporulated oocysts in cat faeces.
- c) Food contaminated with sporulated oocysts.
- d) Oocysts may be ingested by intermediate hosts via water or raw vegetables.
- e) Intermediate hosts (e.g. cattle, sheep, poultry and swine).
- f) Ingestion of tissue cysts in uncooked meat.
- g) Intermediate hosts (humans).
- h) Tachyzoites transmitted through the placenta to the foetus.
- i) Transmission by blood transfusion and organ transplant (j)





# History of *Toxoplasma gondii*



Charles Nicolle  
(1866-1936)



*Ctenodactylus gundi* Rothmann, 1776



Alfonso Splendore  
(1871-1953)

# Biological and epidemiological characteristics of the main *Toxoplasma* genotypes

## **Type I**

Rarely isolated (10% of strain collections in Europe and USA, mainly from human origin)

Highly virulent for mice: death of all mice inoculated with less than 10 tachyzoites

*In vitro*: high rate of multiplication, reduced interconversion tachyzoite-bradyzoite

## **Type II**

The most commonly isolated (human, sheep, pigs) (80% of strain collections in Europe and USA)

Non-virulent for mice: chronic infection with persistence of tissue cysts

*In vitro*: slow rate of multiplication, easier interconversion tachyzoite-bradyzoite and formation of cysts

## **Type III, recombinant genotypes and unusual genotypes with atypical alleles**

Rare among *Toxoplasma* isolates originating from Europe and USA

More frequent among isolates originating from wild animals, from remote areas and from unusual human disease

Usually more virulent for mice than type II isolates

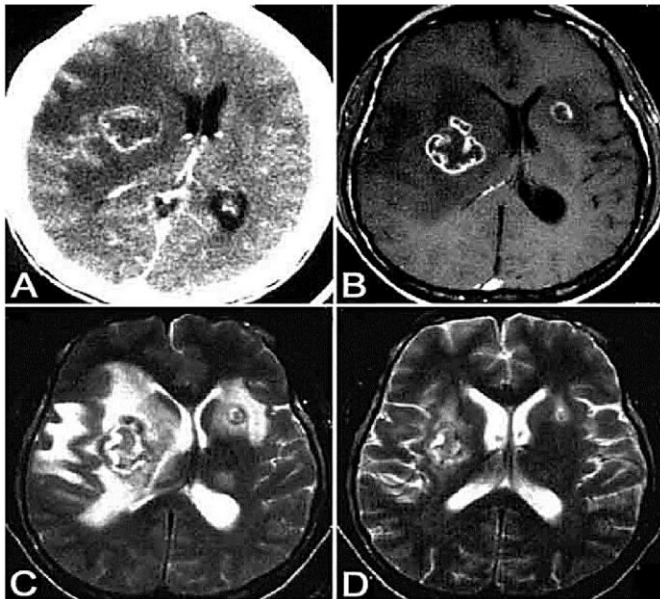
# Human toxoplasmosis

- ✓ most common parasitic infections of man
- ✓ worldwide from Alaska to Australia
- ✓ nearly 1/3 of humanity has been exposed
- ✓ in most adults it does not cause serious illness
- ✓ devastating disease in immunocompromised / immunosuppressed individuals = toxoplasmosis in immunocompromised patients
- ✓ it can cause blindness and mental retardation in congenitally infected children = congenital toxoplasmosis
- ✓ in approx. 10 % of postnatally infected immunocompetent persons = clinical human toxoplasmosis
- ✓ manipulation of host behaviour = **manipulation hypothesis**

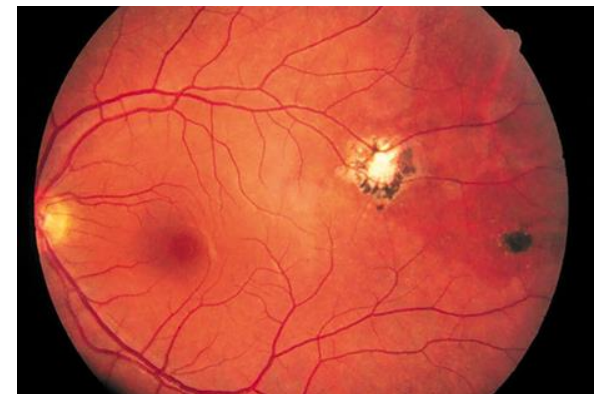

# Toxoplasmosis in immunocompromised patients

- **encephalitis** - most important manifestation in immunosuppressed patients (in 40% of AIDS patients)
- exacerbation of infection (from bradyzoites to tachyzoites)
- disseminated toxoplasmosis, leads to death of patients with AIDS
- prophylactic TMX-sulfa (trimethoprim-sulfamethoxazole) treatment



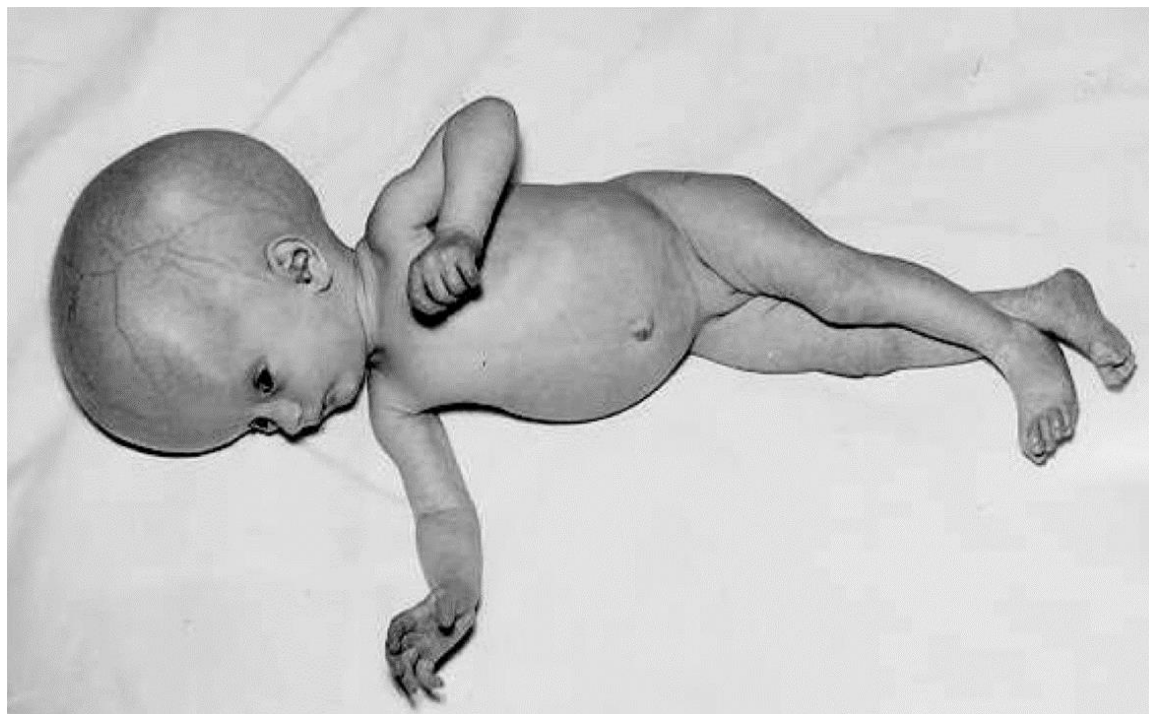⊗ Toxoplasmosis in a 44-year-old man with AIDS. Serial studies are shown before and after antibiotic therapy. (A-C) Initial scans, pre-treatment. Note the relatively poor sensitivity of CT vs. MRI for the lesions in the left hemisphere. After contrast administration on both CT (A) and MRI (B), avid ringlike and nodular enhancement is noted. (D) shows marked improvement in each of the lesions 2 weeks after the completion of anti-toxoplasmosis medical therapy.



# Congenital toxoplasmosis

- **occurring only when a woman becomes infected during pregnancy**
  - ✓ if *T. gondii* infection occurs 4-6 months before pregnancy – mother's protective immunity protects against transplacental (vertical) infection of the foetus
  - ✓ if infection occurs during pregnancy - multiplication of tachyzoites in the placenta and subsequent infection of the foetus
- mother rarely has symptoms of infection ⇒ testing of all pregnant women for *T. gondii* infection is compulsory in some European countries (France, Austria)
- acquired during the first trimester is more severe than that acquired in the second and third trimester
- incidence of congenital toxoplasmosis **1-10 / 10 000 new-born children**
- wide spectrum of clinical diseases occur in congenitally infected children
- **hydrocephalus** is the least common but most dramatic lesion of toxoplasmosis

# Congenital toxoplasmosis



## Infection acquired

	First trimester	Second trimester	Third trimester
<b>Outcome in offspring</b>			
Congenital toxoplasmosis	9.0%	27.0%	59.0%
Subclinical	22.2%	74.4%	89.8%
Clinically apparent	77.8%	15.6%	10.2%
Perinatal death or stillbirth	5.0%	2.0%	0%

Table adapted and modified from Desmonts G, Couvreur J. Congenital toxoplasmosis: a prospective study of the offspring of 542 women who acquired toxoplasmosis during pregnancy. In: Thalhammer O, Baumgarten K, Pollak A, eds. Pathophysiology of congenital disease: perinatal medicine, 6th European congress. Stuttgart: Georg Thieme Verlag, 1979: 51–60. With permission of Georg Thieme Verlag.



# Congenital toxoplasmosis

**Table 1** Recommendations for lowering the risk of primary toxoplasmosis infection among pregnant women

---

1. Avoid consumption of undercooked meat. Cook all meat until it is no longer pink and the juices run clear.
  2. Always use gloves while, and wash hands thoroughly after, handling raw meat.
  3. Thoroughly wash all utensils that are in contact with undercooked meat.
  4. Wash all uncooked vegetables thoroughly.
  5. Wear gloves when gardening or working in soil. Wash hands immediately after contact with soil.
  6. If possible, keep cats indoors throughout pregnancy and do not feed cats uncooked meat.
  7. Use gloves while, and wash hands immediately after, changing cat litter.
-

# Manipulation of host behaviour by *Toxoplasma gondii*

Opinion

<https://doi.org/10.1016/j.pt.2013.01.004>

Cell  
PRESS

## Adaptive host manipulation by *Toxoplasma gondii*: fact or fiction?

Amanda R. Worth, Alan J. Lymbery, and R.C. Andrew Thompson

School of Veterinary and Biomedical Science, Murdoch University, South Street, Murdoch 6150, Australia

It is widely accepted that behavioural changes induced by *Toxoplasma gondii* are an adaptation of the parasite to enhance transmission to its cat definitive host. In our opinion, this explanation requires a rethink. We argue that the experimental evidence that observed behavioural changes will enhance transmission to cats is not convincing. We also argue that cats and sexual reproduction may not be essential for transmission and maintenance of this parasite. Thus, the selection pressure to infect a cat may not be sufficiently strong for the evolution of adaptive host manipulation to have occurred in order to enhance predation by cats.

## Decrease of psychomotor performance in subjects with latent ‘asymptomatic’ toxoplasmosis

J. HAVLÍČEK<sup>1</sup>, Z. GAŠOVÁ<sup>2</sup>, A. P. SMITH<sup>3</sup>, K. ZVÁRA<sup>4</sup> and J. FLEGR<sup>1\*</sup>

<sup>1</sup> Department of Parasitology, Faculty of Science, Charles University, Viměná 7, 128 44 Prague, Czech Republic

<sup>2</sup> Institute of Haematology and Blood Transfusion, U nemocnice 1, 120 00 Prague, Czech Republic

<sup>3</sup> Centre for Occupational and Health Psychology, School of Psychology, Cardiff University, UK

<sup>4</sup> Department of Probability and Statistics, Faculty of Mathematics and Physics, Charles University, Sokolovská 83, 186 00, Prague 8, Czech Republic

(Received 24 July 2000; revised 13 November 2000; accepted 15 November 2000)

### SUMMARY

*Toxoplasma gondii* is known to induce specific behavioural changes in its intermediate hosts. This is usually considered to be an evolutionary adaptation aimed to increase the probability of transmission of the parasite into its definitive host, the cat, by predation. In rodents an increase of reaction time as well as many other specific behavioural patterns have been observed. Here we report the results of our double blind study showing the significantly longer reaction times of 60 subjects with latent toxoplasmosis in comparison with those of 56 controls. Moreover, the existence of a positive correlation between length of infection and mean reaction time suggested that slow and cumulative effects of latent toxoplasmosis rather than a one-step (and possibly transient) effect of acute toxoplasmosis disease are responsible for the decrease of psychomotor performance of infected subjects. To our knowledge, this is the first study confirming the existence of such parasite-induced changes in human behaviour that could be considered in evolutionary history of the human species as adaptive from the point of view of parasite transmission.

Key words: manipulation hypothesis, parasite, human, reaction times, *Toxoplasma gondii*, behaviour, evolution.

<https://doi.org/10.1017/S0031182001007624>

OPEN ACCESS Freely available online

## The Distribution of *Toxoplasma gondii* Cysts in the Brain of a Mouse with Latent Toxoplasmosis: Implications for the Behavioral Manipulation Hypothesis

Miroslava Berenreiterová, Jaroslav Flegr\*, Aleš A. Kuběna, Pavel Němec

Biology Section, Faculty of Science, Charles University in Prague, Praha, Czech Republic

### Abstract

**Background:** The highly prevalent parasite *Toxoplasma gondii* reportedly manipulates rodent behavior to enhance the likelihood of transmission to its definitive cat host. The proximate mechanisms underlying this adaptive manipulation remain largely unclear, though a growing body of evidence suggests that the parasite-entrained dysregulation of dopamine metabolism plays a central role. Paradoxically, the distribution of the parasite in the brain has received only scant attention.

**Methodology/Principal Findings:** The distributions of *T. gondii* cysts and histopathological lesions in the brains of CD1 mice with latent toxoplasmosis were analyzed using standard histological techniques. Mice were infected per orally with 10 tissue cysts of the avirulent HIF strain of *T. gondii* at six months of age and examined 18 weeks later. The cysts were distributed throughout the brain and selective tropism of the parasite toward a particular functional system was not observed. Importantly, the cysts were not preferentially associated with the dopaminergic system and absent from the hypothalamic defensive system. The striking interindividual differences in the total parasite load and cyst distribution indicate a probabilistic nature of brain infestation. Still, some brain regions were consistently more infected than others. These included the olfactory bulb, the entorhinal, somatosensory, motor and orbital, frontal association and visual cortices, and, importantly, the hippocampus and the amygdala. By contrast, a consistently low incidence of tissue cysts was recorded in the cerebellum, the pontine nuclei, the caudate putamen and virtually all compact masses of myelinated axons. Numerous perivascular and leptomeningeal infiltrations of inflammatory cells were observed, but they were not associated with intracellular cysts.

**Conclusion/Significance:** The observed pattern of *T. gondii* distribution stems from uneven brain colonization during acute infection and explains numerous behavioral abnormalities observed in the chronically infected rodents. Thus, the parasite can effectively change behavioral phenotype of infected hosts despite the absence of well targeted tropism.

<https://doi.org/10.1371/journal.pone.0028925>

# Manipulation of host behaviour by *Toxoplasma gondii*

## New Study Shows How Dormant *Toxoplasma* Parasites Manipulate Neurons to Survive

Dec 27, 2021 by News Staff / Source

« Previous | Next »

### Published in

Biology  
Medicine

### Tagged as

Bradyzoite  
Brain  
Cell  
Human  
Immune system  
Interferon  
Neuron  
Parasite  
Protein  
*Toxoplasma gondii*  
Toxoplasmosis

### Follow



### You Might Like

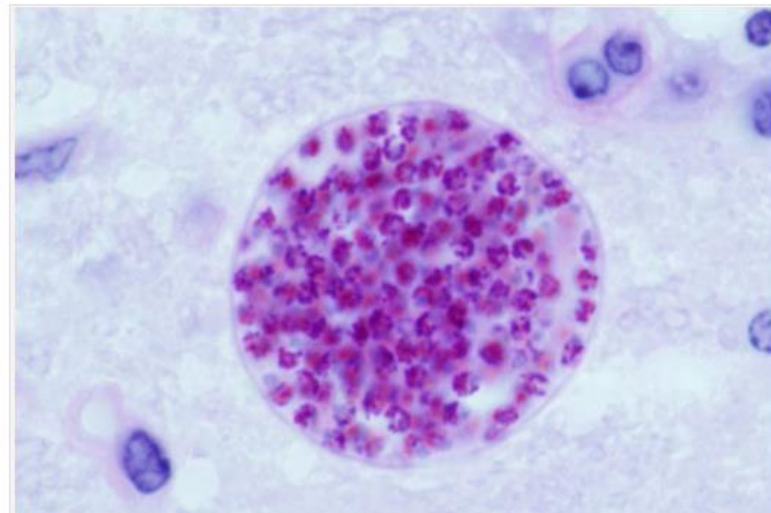


Study:  
Bumblebees'  
Memories  
Operate  
Differently to  
Humans'



New Deep-Sea  
Snailfish Species  
Discovered in  
Atacama Trench

*Toxoplasma gondii* develops a latent infection in the muscle and central nervous system that acts as a reservoir for acute-stage reactivation in vulnerable patients. Until now little is understood about how these parasites manipulate host cells during latent infection and the impact this has on survival. New research led by the Walter and Eliza Hall Institute of Medical Research, the University of Melbourne and the Wellcome Center for Anti-Infectives Research shows that *Toxoplasma gondii* is able to lay dormant and undetected inside neurons and muscle cells by releasing proteins that switch off the cells' ability to alert the immune system. This discovery could pave the way for new drug targets to treat patients suffering from chronic toxoplasmosis infections.



Microscopic cysts containing *Toxoplasma gondii* develop in the tissues of many vertebrates. Here, in mouse brain tissue, thousands of bradyzoites (stained red) are enveloped by a thin parasite cyst wall.

Image credit: Jitinder P. Dubey.

<https://www.sci.news/biology/dormant-toxoplasma-10407.html>

Original research paper:

<https://doi.org/10.1016/j.chom.2021.11.012>



# Manipulation of host behaviour by *Toxoplasma gondii*

LEADERSHIP STRATEGY

## House Cats Said to Lead to Car Crashes, Suicides, and Mental Disorders

Frederick E. Allen Former Staff  
*I am the Leadership Editor of Forbes.*

Feb 9, 2012, 06:53pm EST



A monster?

<https://www.forbes.com/sites/frederickallen/2012/02/09/house-cats-said-to-lead-to-car-crashes-suicides-and-mental-disorders/?sh=2130abbc5a1b>

In one of the oddest articles I've seen in a mainstream magazine in a long time, Kathleen McAuliffe writes in the new issue of *The Atlantic* about a Czech scientist named Jaroslav Flegr with a very serious theory about the potentially devastating effects of a parasite, *Toxoplasma gondii*, found in the feces of ordinary house cats.

..“if Flegr is right, the “latent” parasite may be quietly tweaking the connections between our neurons, changing our response to frightening situations, our trust in others, how outgoing we are, and even our preference for certain scents. And that’s not all. He also believes that the organism contributes to car crashes, suicides, and mental disorders such as schizophrenia. When you add up all the different ways it can harm us, says Flegr, “*Toxoplasma* might even kill as many people as malaria, or at least a million people a year.”

Popular Latest Newsletters


*The Atlantic*

Sign In

## How Your Cat Is Making You Crazy

Jaroslav Flegr is no kook. And yet, for years, he suspected his mind had been taken over by parasites that had invaded his brain. So the prolific biologist took his science-fiction hunch into the lab. What he’s now discovering will startle you. Could tiny organisms carried by house cats be creeping into our brains, causing everything from car wrecks to schizophrenia?

By Kathleen McAuliffe



<https://www.theatlantic.com/magazine/archive/2012/03/how-your-cat-is-making-you-crazy/308873/>

# Source of postnatally acquired *Toxoplasma gondii* infection

Three infectious stages: tachyzoites, bradyzoites and sporozoites

Humans become infected by ingesting:

- ✓ tachyzoites in unpasteurized milk (?)
- ✓ tissue cysts in under cooked or uncooked meat
- ✓ food and water contaminated with oocysts from infected cat faeces

**Facultatively heteroxenous**  
character of *T. gondii*:

- ✓ can spread without DH
- ✓ can spread without MH

**Toxoplasma gondii is a very  
successful parasite**

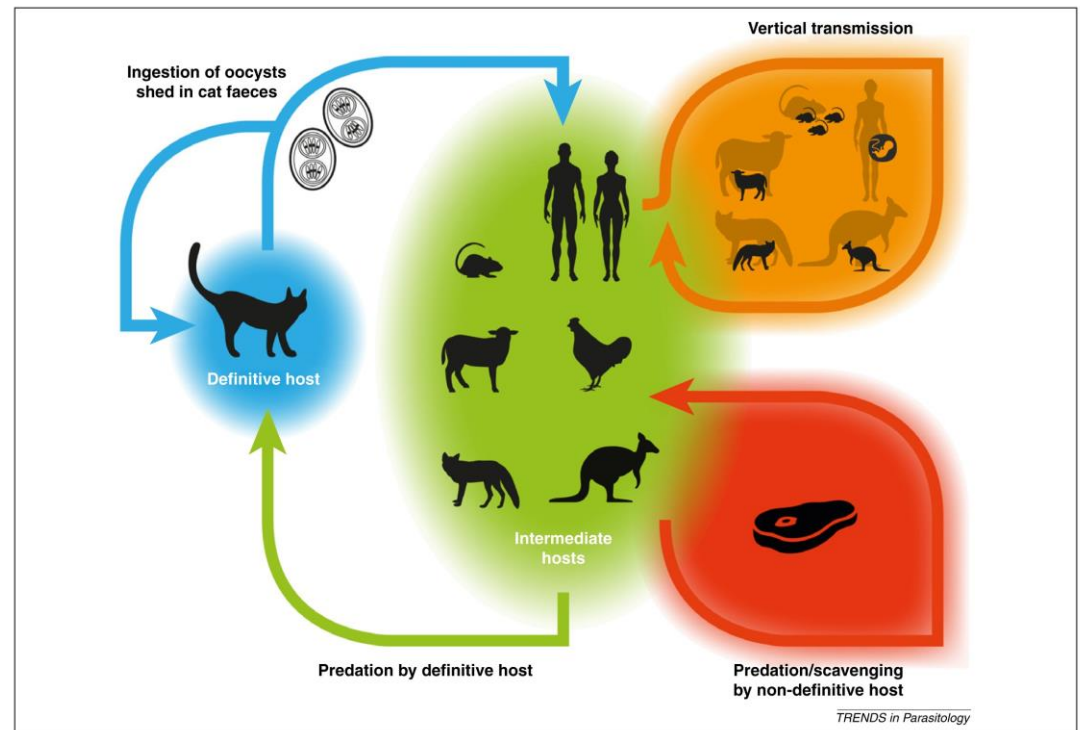


Figure 1. The life cycle of *Toxoplasma gondii*. The flow chart shows a variety of intermediate hosts and three routes of transmission to intermediate hosts: ingestion of oocysts from cat faeces, ingestion of tissue cysts via predation/scavenging, and vertical transmission from mother to offspring.

# Meat as a source of *Toxoplasma gondii* infection

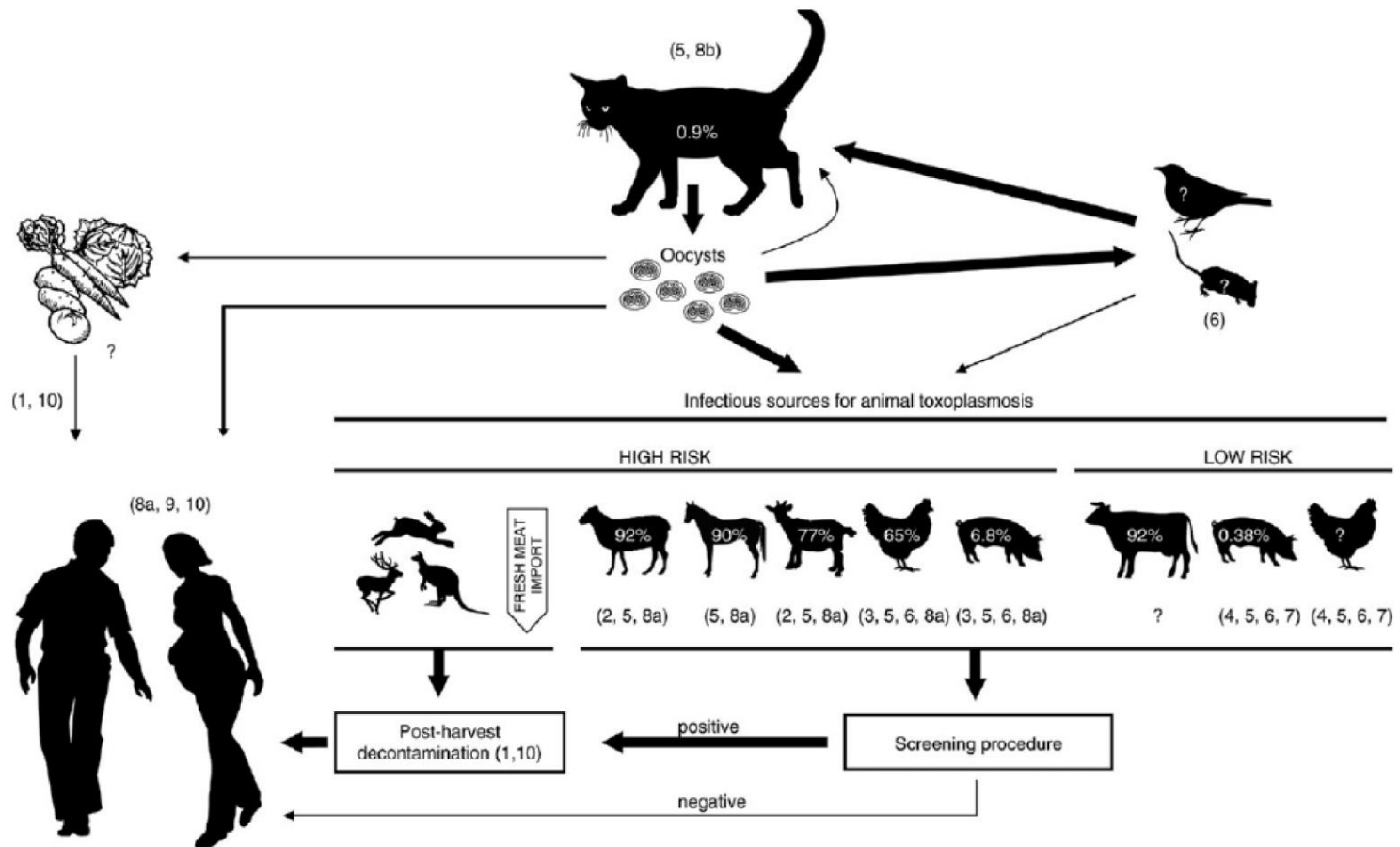


Fig. 1. Pre- and post-harvest risk management for the control of infectious sources of animal and human toxoplasmosis. (1) Freezing and/or heating. (2) Heating of milk products. (3) Animal friendly production system. (4) Indoor production system. (5) Cat control. (6) Rodent control. (7) Animal feed & bedding decontamination by heating. (8) Vaccination against tissue cyst formation (a) or oocyst shedding (b). (9) Serological monitoring of people at risk. (10) Consumer education on food hygiene and decontamination procedures. Percentages indicate highest observed seroprevalence per species. Thickness of arrows represents the likeliness of transmission without risk management procedure. Percentages indicate the highest observed seroprevalence per animal species or the percentage of cats actively shedding oocysts.



# Sources of toxoplasma infection in pregnant women: European multicentre case-control study

A J C Cook, R E Gilbert, W Buffolano, J Zufferey, E Petersen, P A Jenum, W Foulon, A E Semprini, D T Dunn on behalf of the European Research Network on Congenital Toxoplasmosis

## Abstract

**Objective** To determine the odds ratio and population attributable fraction associated with food and environmental risk factors for acute toxoplasmosis in pregnancy.

**Design** Case-control study.

**Setting** Six large European cities.

**Participants** Pregnant women with acute infection (cases) detected by seroconversion or positive for anti-*Toxoplasma gondii* IgM were compared with pregnant women seronegative for toxoplasma (controls).

**Main outcome measures** Odds ratios for acute infection adjusted for confounding variables; the population attributable fraction for risk factors.

**Results** Risk factors most strongly predictive of acute infection in pregnant women were eating undercooked lamb, beef, or game, contact with soil and travel outside Europe and the United States or Canada. Contact with cats was not a risk factor. Between 30% and 63% of infections in different centres were attributed to consumption of undercooked or cured meat products and 6% to 17% to soil contact.

**Conclusions** Inadequately cooked or cured meat is the main risk factor for infection with toxoplasma in all centres. Preventive strategies should aim to reduce prevalence of infection in meat, improve labelling of meat according to farming and processing methods and improve the quality and consistency of health information given to pregnant women.

Naples  
Lausanne  
Copenhagen  
Oslo  
Brussels  
Milan

## What is already known on this topic

Eating undercooked meat or cured meat is a risk factor for toxoplasma infection

Contact with cats is not a risk factor for infection as excretion of oocysts is limited to only a few weeks

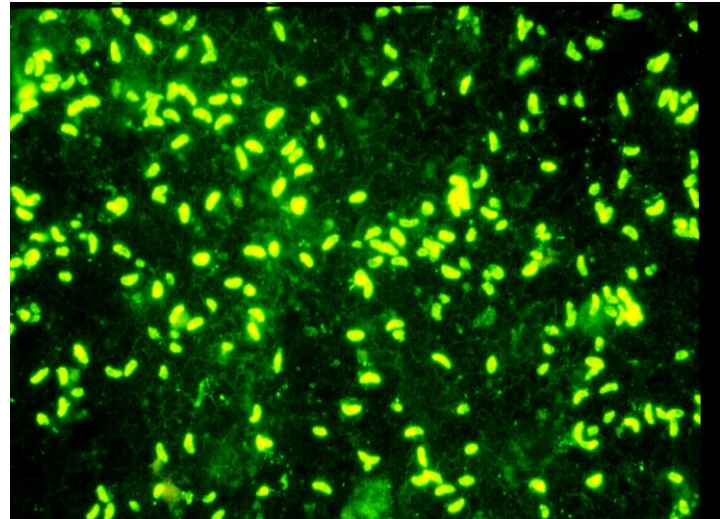
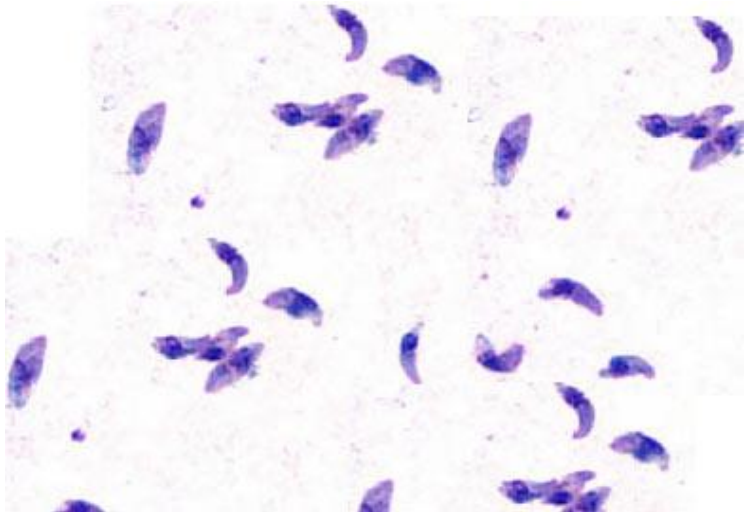
## What this study adds

In six European centres eating undercooked, raw, or cured meat contributed to between 30% and 63% of infections, with soil contact contributing to up to 17% of infections

Action to reduce infection rates should include improved information about the risk associated with undercooked or cured meat, labelling of meat according to farming and processing methods, and measures to reduce infection in domestic animals

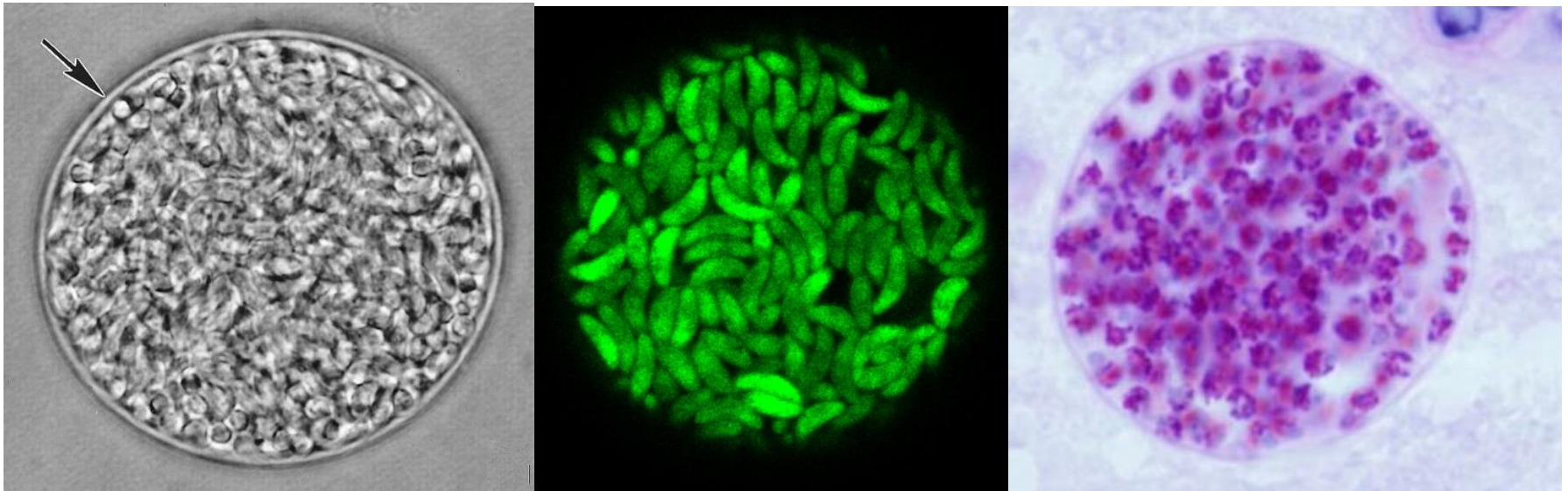
# Tachyzoites of *Toxoplasma gondii*

- tachyzoites demonstrated in the milk of sheep, goats and cows in the acute phase of infection
- **prerequisites for toxoplasmosis after ingestion of milk with tachyzoites:**
  - ✓ acute infection (parasitaemia)
  - ✓ temperature-sensitive tachyzoites - unpasteurised milk
  - ✓ tachyzoites are sensitive to low pH and pepsin - penetration of the mucous membrane of the oral cavity and oesophagus
  - ✓ importance of tachyzoite infection in milk is minimal (only few publications)



# Bradyzoites of *Toxoplasma gondii*

- cysts develop as early as a week after infection and are infectious throughout the lifetime of the IH
- in different IH, different localisation of cysts and different number of cysts
- ranking according to the frequency of *T. gondii* cysts:
  1. pig, sheep, goat
  2. rabbit, burrowing fowl
  3. horses
  4. cattle





# **Bradyzoites of *Toxoplasma gondii***

## **Survival of tissue cysts in meat - low temperatures:**

- ✓ at a temperature of 1 to 4 °C for 3 weeks
- ✓ at a temperature of -1 to - 8 °C for 1 week
- ✓ at a temperature of -12 °C, bradyzoites in tissue cysts die immediately

## **Survival of tissue cysts in meat - high temperatures:**

- ✓ at a temperature of 67 °C, bradyzoites in tissue cysts die immediately
- ✓ at a temperature of 60 °C, bradyzoites in tissue cysts die in 4 minutes
- ✓ at a temperature of 50 °C, bradyzoites in tissue cysts die in 10 minutes

## **Survival of tissue cysts in meat - salting**

- ✓ 6% NaCl solution - bradyzoites in tissue cysts die immediately
- ✓ 3% NaCl solution - bradyzoites in tissue cysts die in 3-7 days

## **Survival of tissue cysts in meat - smoking**

- ✓ they survive "cold" smoking

## **Survival of tissue cysts in meat - irradiation (USA)**

- ✓  $\gamma$  radiation - 1 kGy - bradyzoites in tissue cysts die immediately

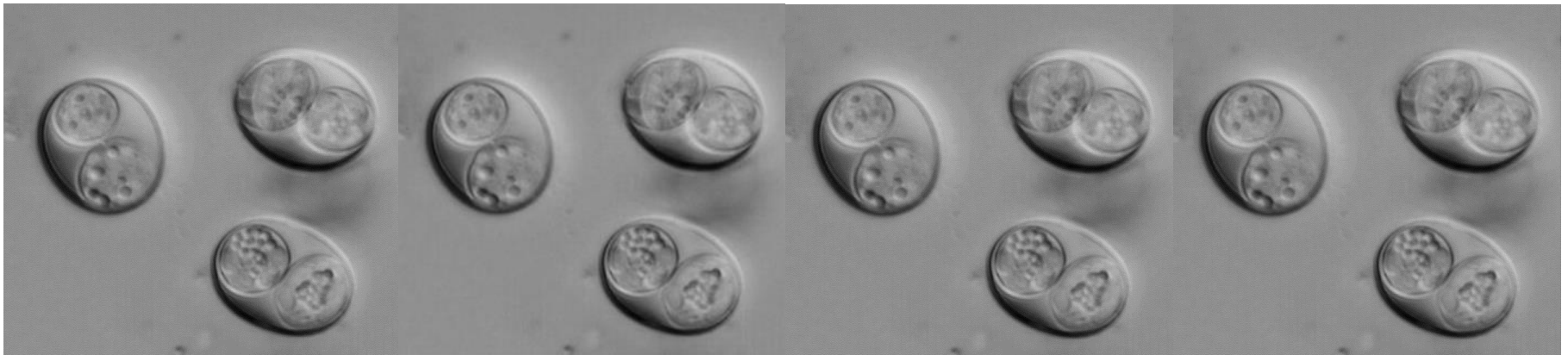# Oocysts of *Toxoplasma gondii*

- asymptomatic shedding of *T. gondii* oocysts
- only about 1 % of cats in a population are found to be shedding oocysts at any given time
- oocysts are shed for only a short period (1-2 weeks) in the life of the cat
- sporulation finished in 2-5 days, importance of burying of faeces



# Oocysts of *Toxoplasma gondii*

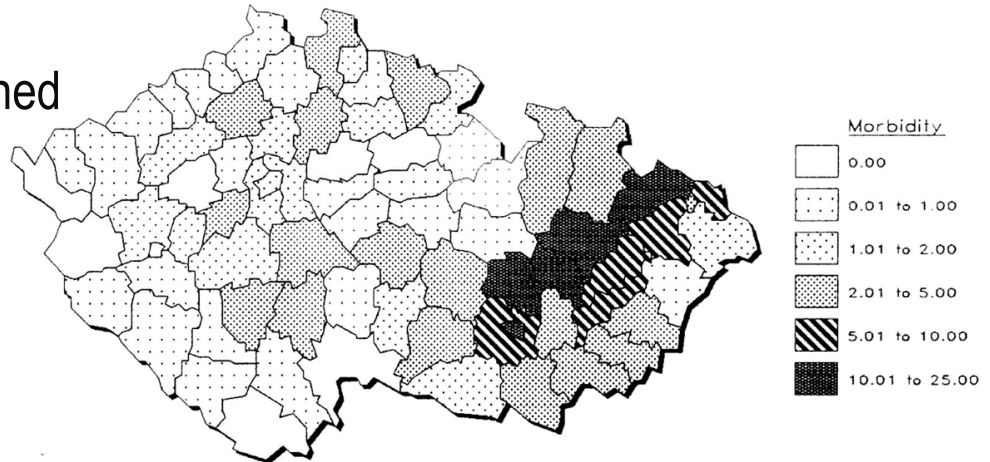
- ✓ sporulated oocysts survive for long periods under most ordinary environmental conditions
- ✓ sporulated oocysts survive in moist soil for years
- ✓ sporulated oocysts survive in 4 °C for 54 months
- ✓ sporulated oocysts survive in -10 °C for 106 days
- ✓ sporulated oocysts die at 55 - 60 °C in 1-2 minutes
- ✓ flies, cockroaches, dung beetles, earthworms, etc. can mechanically spread oocysts





# Toxoplasmosis epidemic in Moravia 1994

- started simultaneously in several districts of Moravia at the beginning of 1994 (December 1993) and lasted until April 1994, **distinctly local character**
- detected **722 cases of clinical toxoplasmosis** (lymphadenopathy, prolonged angina) during the first 3 months of 1994
- total number of infected not determined

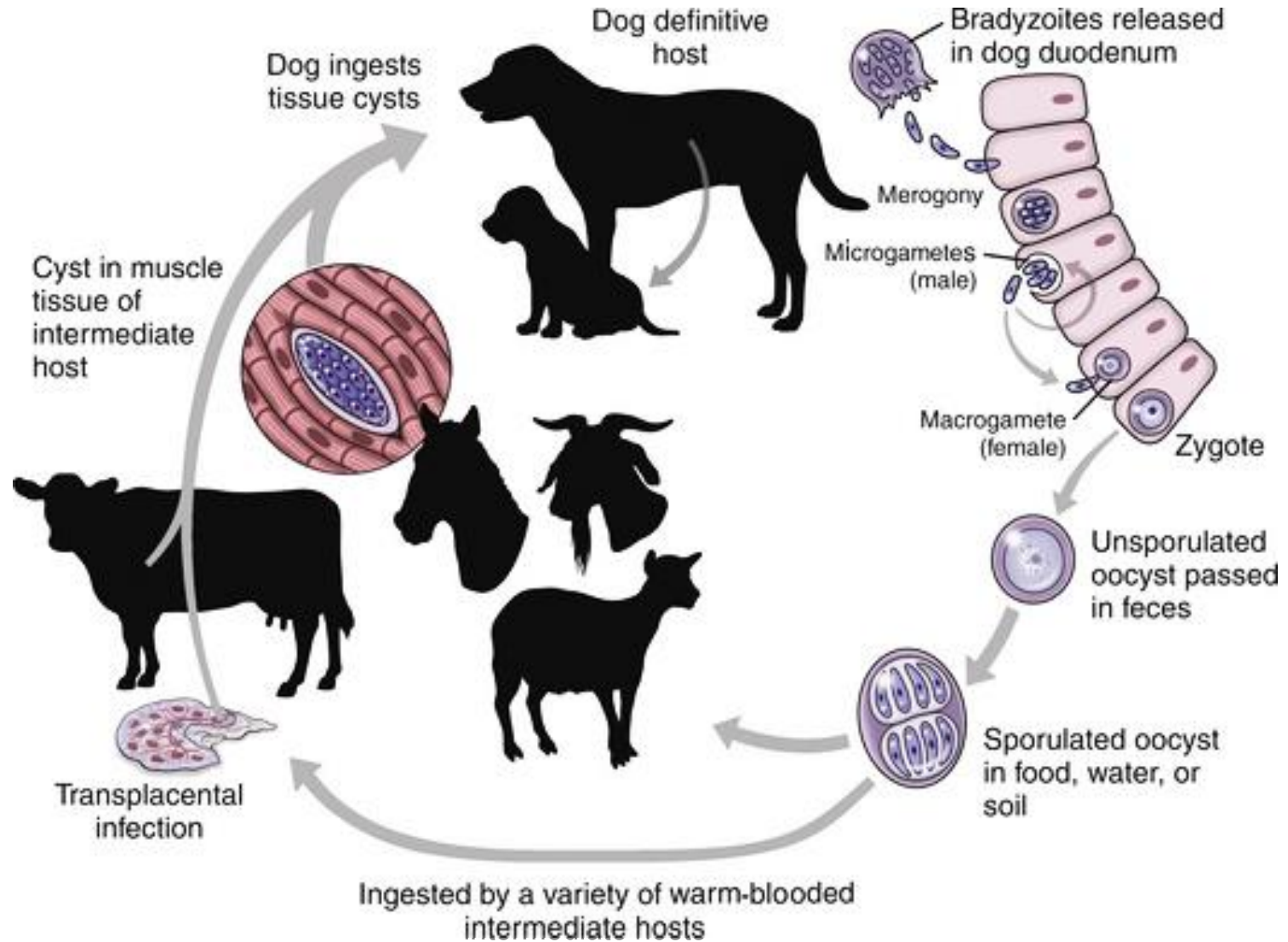


- **source of infection not proven**
- **hypothesis** - the source of infection is raisins, nuts... contaminated with cat feces with *Toxoplasma gondii* oocysts
  - ✓ especially in the city
  - ✓ Christmas season
  - ✓ local occurrence (1-2 distribution companies)
- **the second largest proven epidemic** (larger epidemic was the water-borne toxoplasmosis in Canada with 2 900-7 700 cases in 1995 )

## *Neospora caninum*

- DH: Canidae
- IH: birds and mammals = warm-blooded vertebrates (no human infection)
- structural and antigenic similarity to *Toxoplasma gondii*
- 3 types of infectious stages:
  - **tachyzoites** - endodyogeny
  - **bradyzoites** - endopolygeny
  - **sporozoites** in fully sporulated oocyst
- bradyzoites ⇔ tachyzoites - immunologically mediated (IFN- $\gamma$ )
- *in vitro* cultivation
- **neosporosis** - clinical disease of dogs and cattle
- transmitted from infected cows to offspring by congenital infection
- major cause of abortion in dairy cattle worldwide
- important cause of reproductive failure in cattle

# Life cycle of *Neospora caninum*



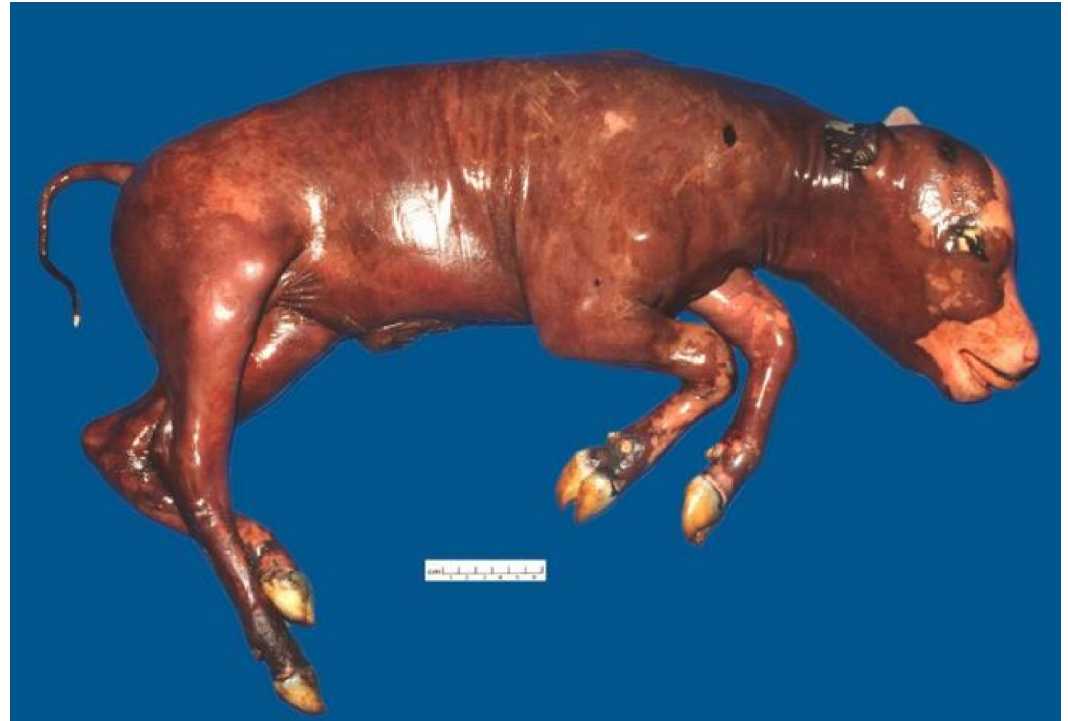

# Clinical signs of neosporosis

- DH: dogs mostly asymptomatic, clinical signs in congenitally infected dogs, most severe cases in young puppies – ataxia, partial but progressive paralysis of hind legs; in adult dogs - inflammation of brain, spinal cord, liver and heart, dermatitis with sores, pneumonia
- IH: abortion (mostly in 5 and 6 months of pregnancy; stillbirth or premature calf; clinical signs in congenitally infected calves (neurological deficits)

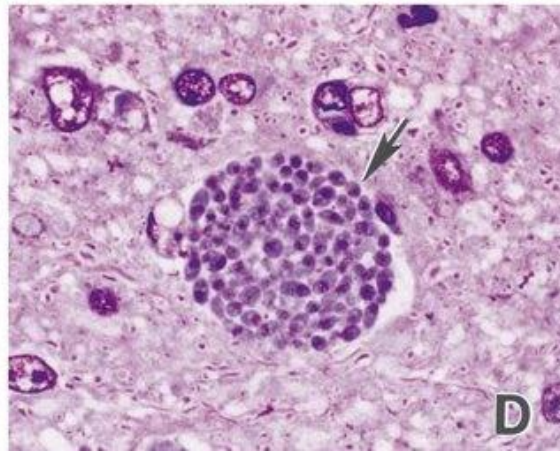
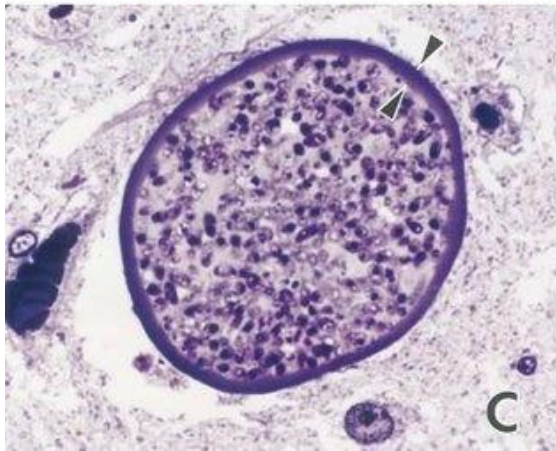
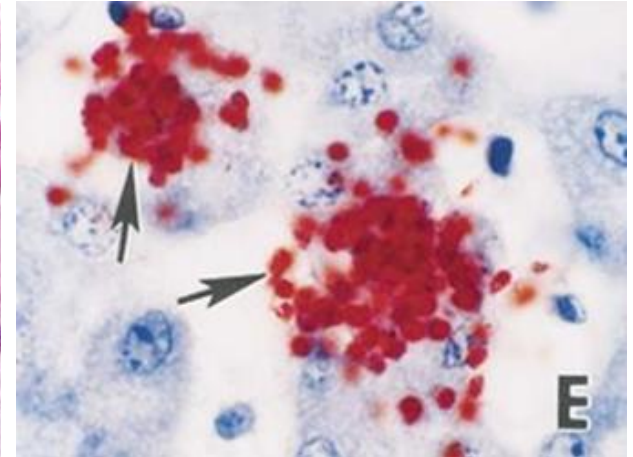
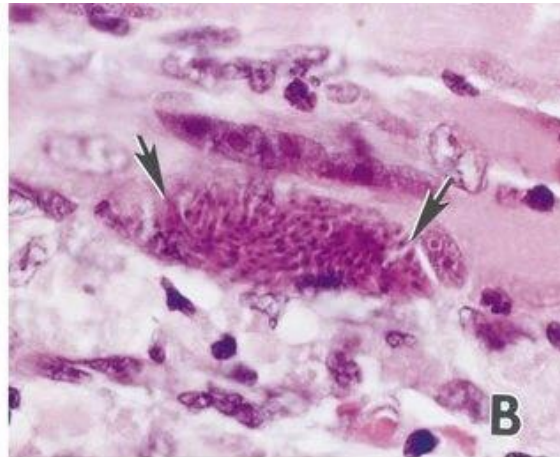
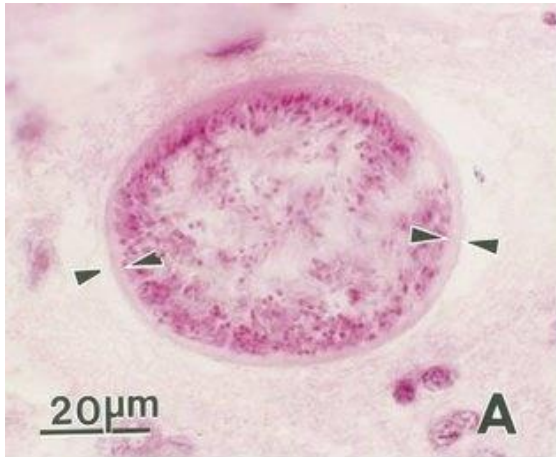


Pelvic limb hyperextension in a young dog with neosporosis



Bovine abortion of neosporosis

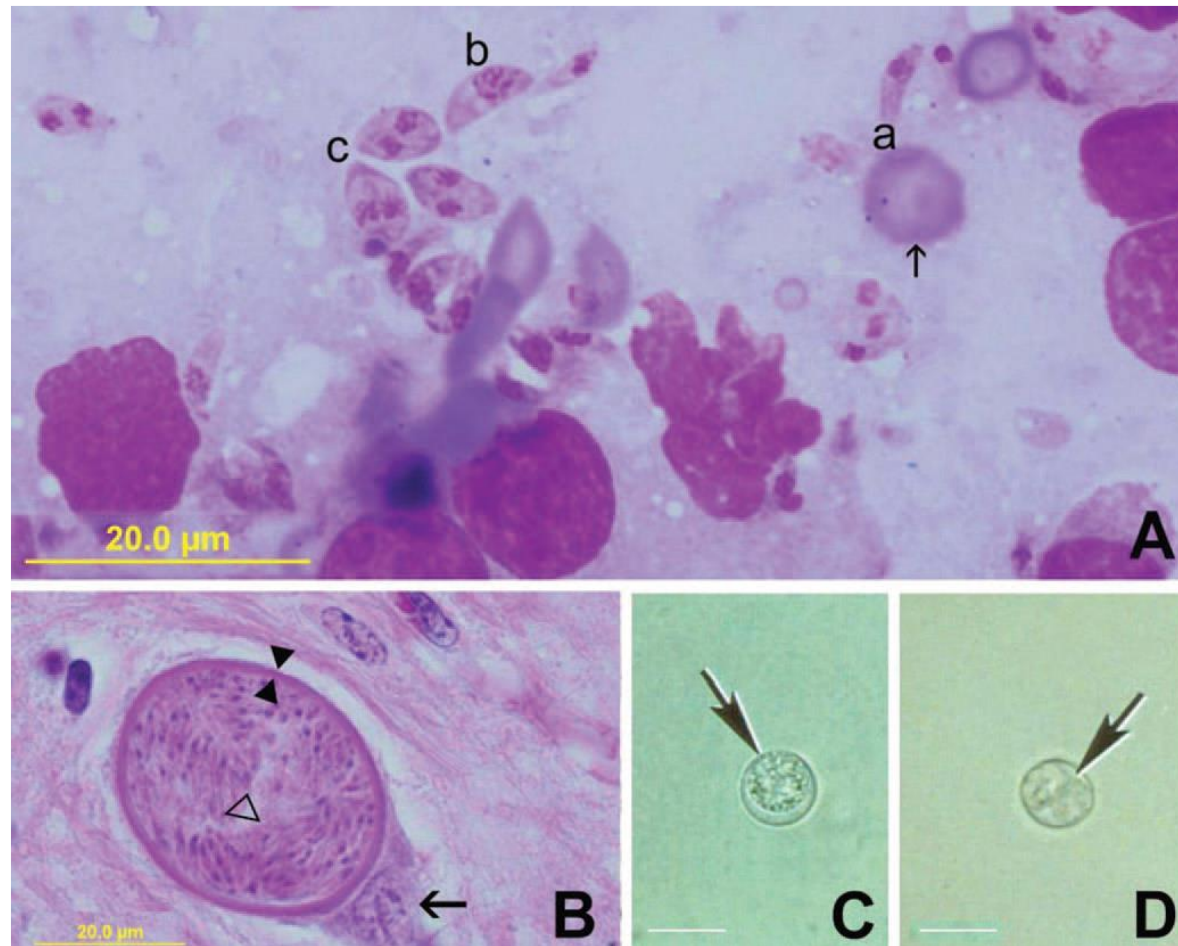
# Developmental stages of *Neospora caninum*



**Tachyzoites and tissue cysts in naturally infected dogs.** **A)** Tissue cyst from the cerebellum of a dog. HE. **B)** Large group of tachyzoites (arrows) in skeletal muscle of the same dog. HE. **C)** Tissue cyst from the brain. Toluidine blue. **D)** A group of tachyzoites (arrow) in the brain. Giemsa stain. **E)** Tachyzoites (arrows) from the liver of dog stained with polyclonal antibodies to *N. caninum*.



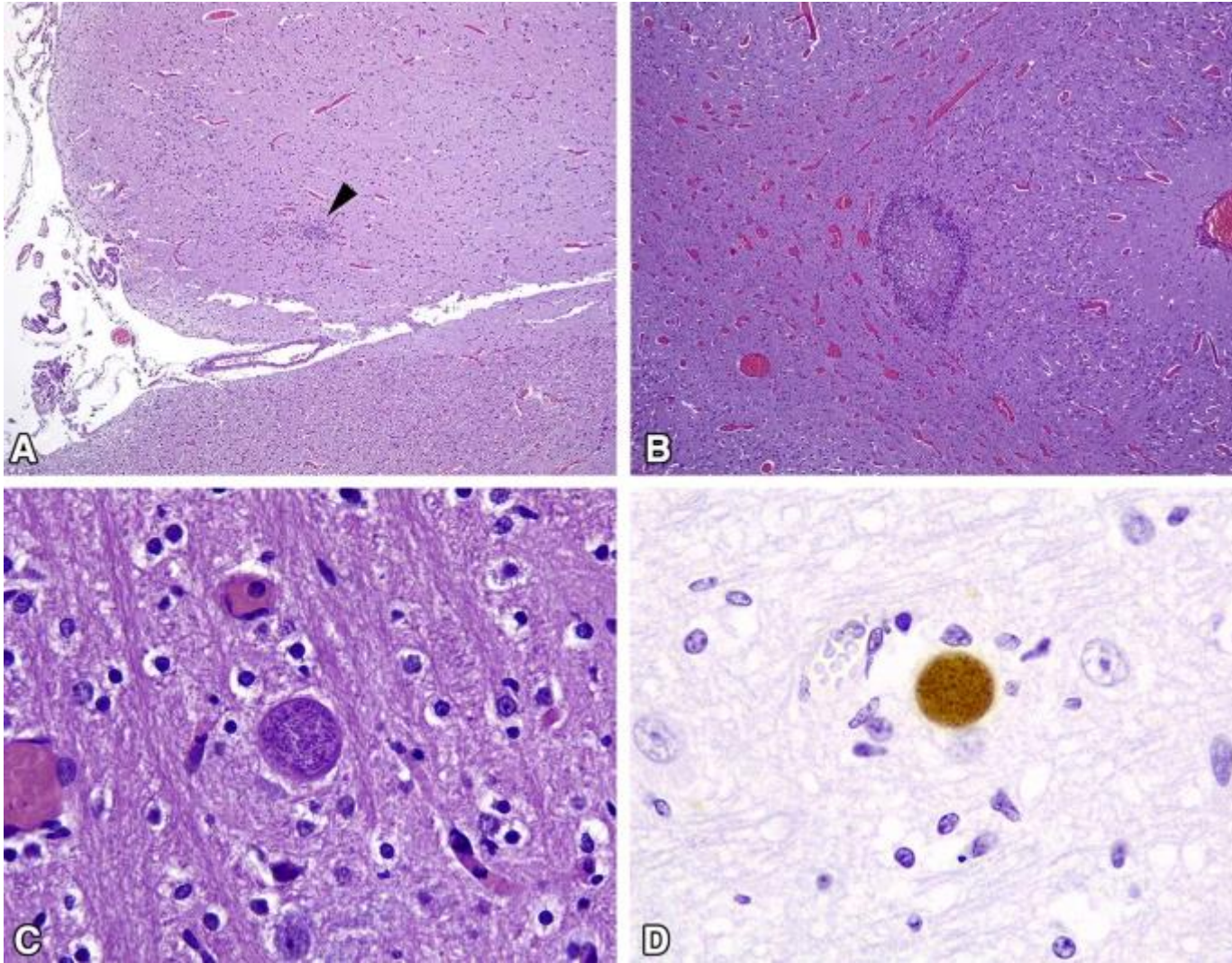
# Developmental stages of *Neospora caninum*



**A)** Impression smear of the liver of an experimentally infected mouse with tachyzoites varying in dimension, depending on the stage of division. **a** - slender tachyzoite, **b** - tachyzoite before division, **c** - 3 dividing tachyzoites, **arrow** - red blood cell. Giemsa. **B)** Sectioned tissue cyst inside a neuron in the spinal cord of a congenitally infected calf. HE. Thick cyst wall (opposing arrowheads) encloses slender bradyzoites (open triangle). **C)** Unsporulated oocyst in the dog faeces. **D)** Sporulated oocyst with 2 sporocysts.



# Pathology of neosporosis



**Microscopic lesions in brain of lambs naturally infected with *N. caninum*.** A) Focus of gliosis (arrowhead) at the cerebral cortex. HE. B) Diffuse congestion, mainly seen at the white matter of the corona radiata and a focus of necrosis with peripheral gliosis. HE. C) Tissue cyst containing structures compatible with bradyzoites. HE. D) Positive labelling of tissue cyst. IHC.

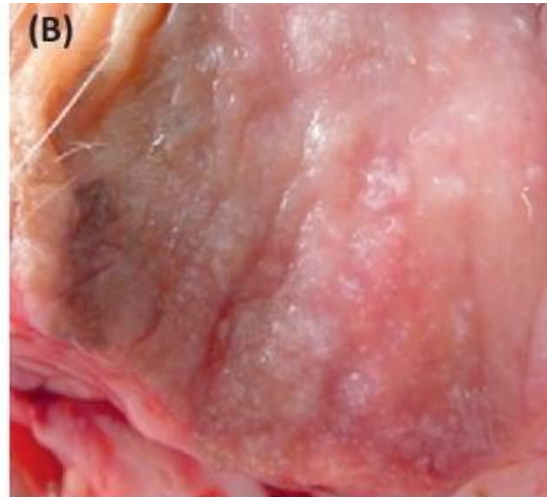
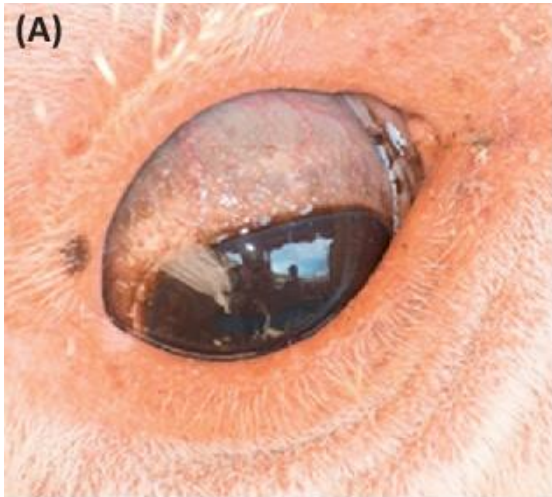## genus *Besnoitia*

- cause of pedunculated lesions in the skin, nasal cavity and larynx of animals
- 10 described species

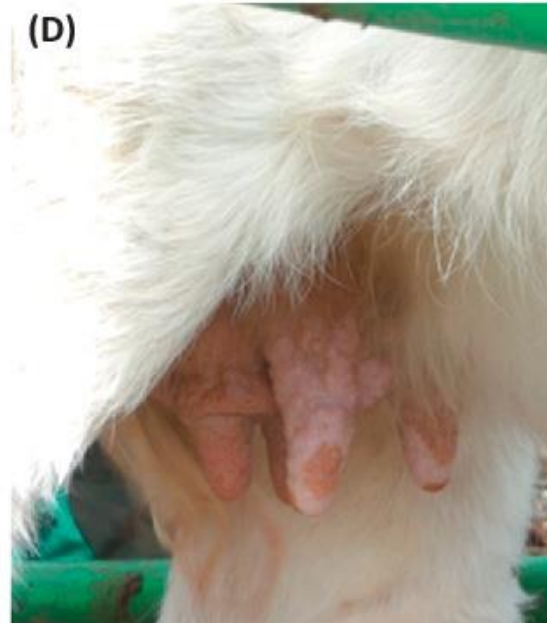### *Besnoitia besnoiti*

- new emerging parasitic disease in Europe, responsible for significant losses in the cattle industry of Africa and Mediterranean countries
- DH and infection source unknown
- **acute disease** - fever, subcutaneous oedema, conjunctivitis, nasal discharge, salivation, lameness, and depression
- **chronic bovine besnoitiosis** - parasite cysts in connective tissues, especially the dermis and the non-intestinal mucosa; superficially located cysts in the scleral conjunctivae, mucous membranes in nasal cavity and vestibulum vaginae = pin-head sized white protuberances are pathognomonic for bovine besnoitiosis
- chronic non-reversible besnoitiosis - hyper-scleroderma, hyperkeratosis, alopecia; in bulls - atrophy, sclerosis and focal necrosis causing irreversible lesions in testis
- no vaccines and chemotherapeutical drugs available

# Clinical signs and pathology in chronic bovine besnoitiosis



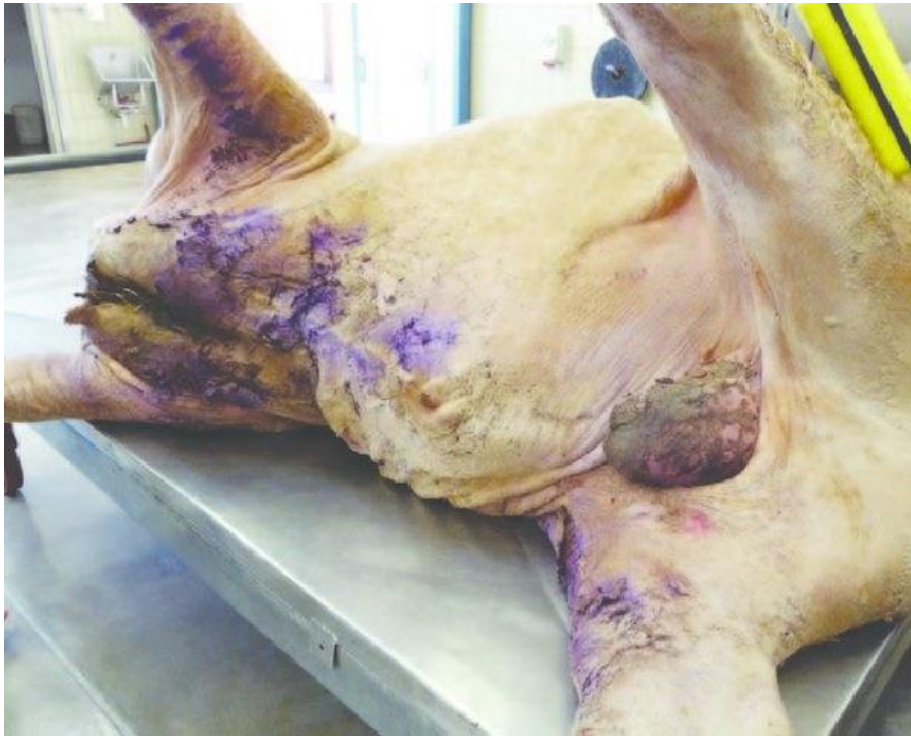- A) tissue cysts in scleral conjunctiva
- B) tissue cysts in a vulvar biopsy
- C) elephant skin and alopecia
- D) nodules in udder and teats



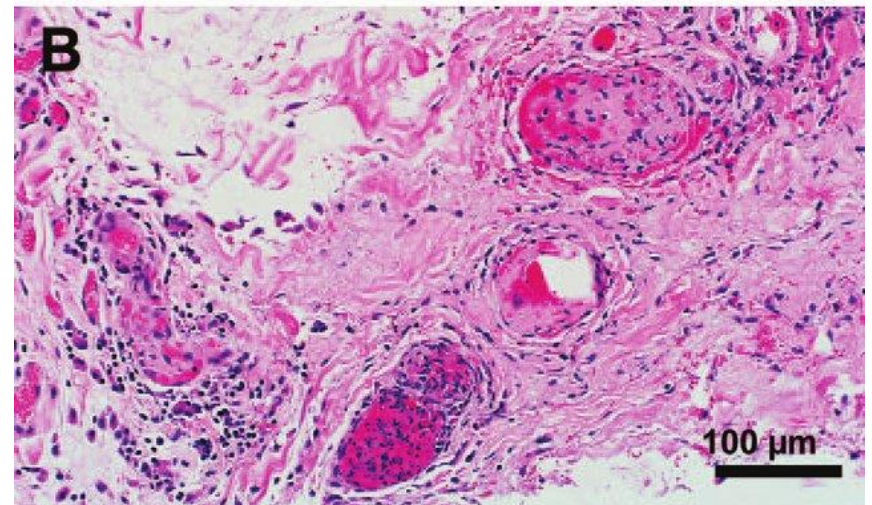
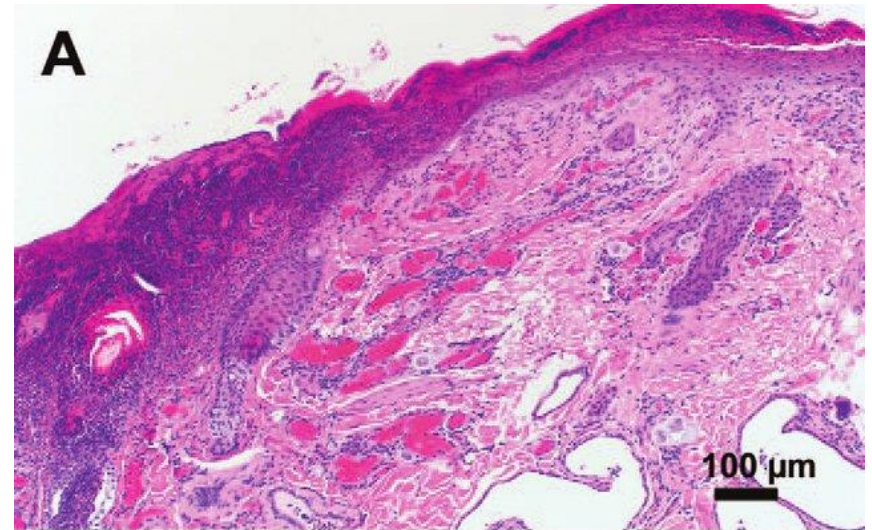
Chronology of disease progression:  
<https://doi.org/10.1186/s12917-015-0344-6>



# Pathology in chronic bovine besnoitiosis



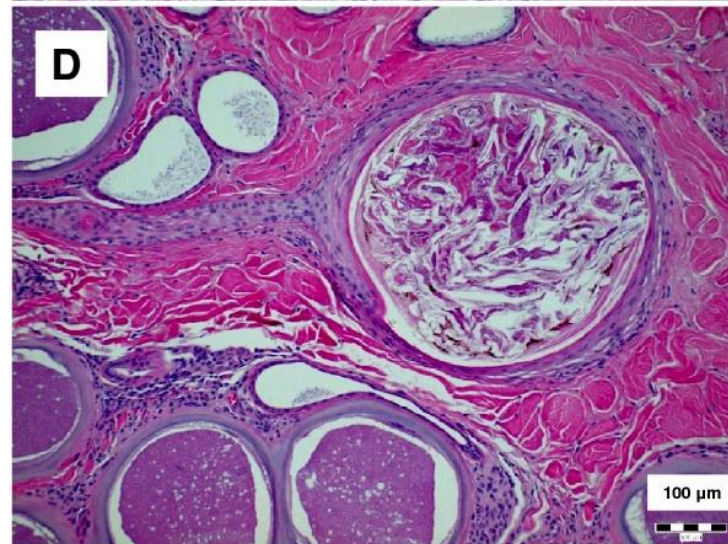
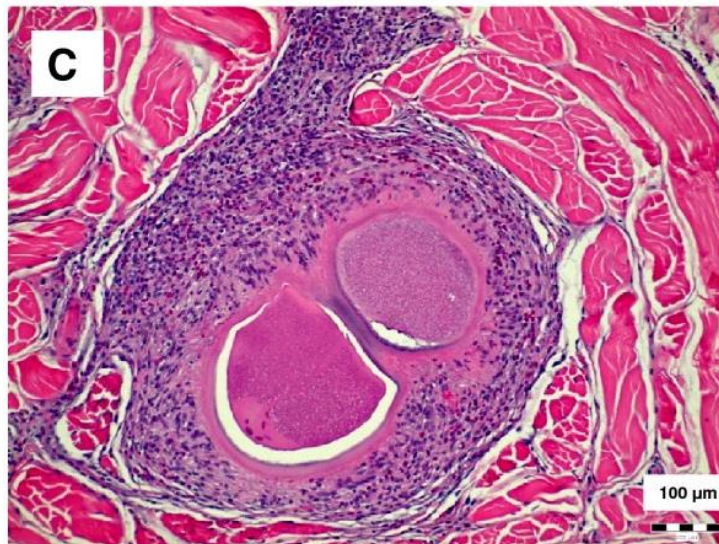
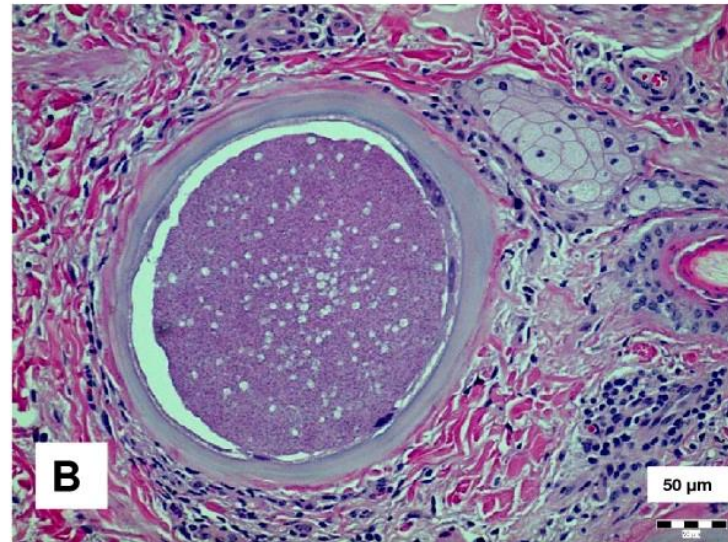
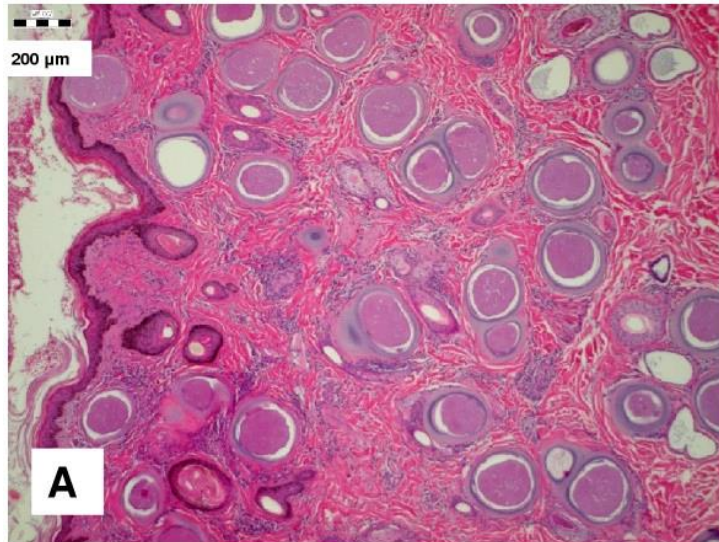
Ventral view of the bull with skin and scrotal lesions



Histological sections of skin. A) Scrotal skin transition from more normal to area of epidermal and dermal necrosis. B) Deep subcutaneous vessels containing thromboses. HE.



# Cyst morphology and pathology of besnoitiosis

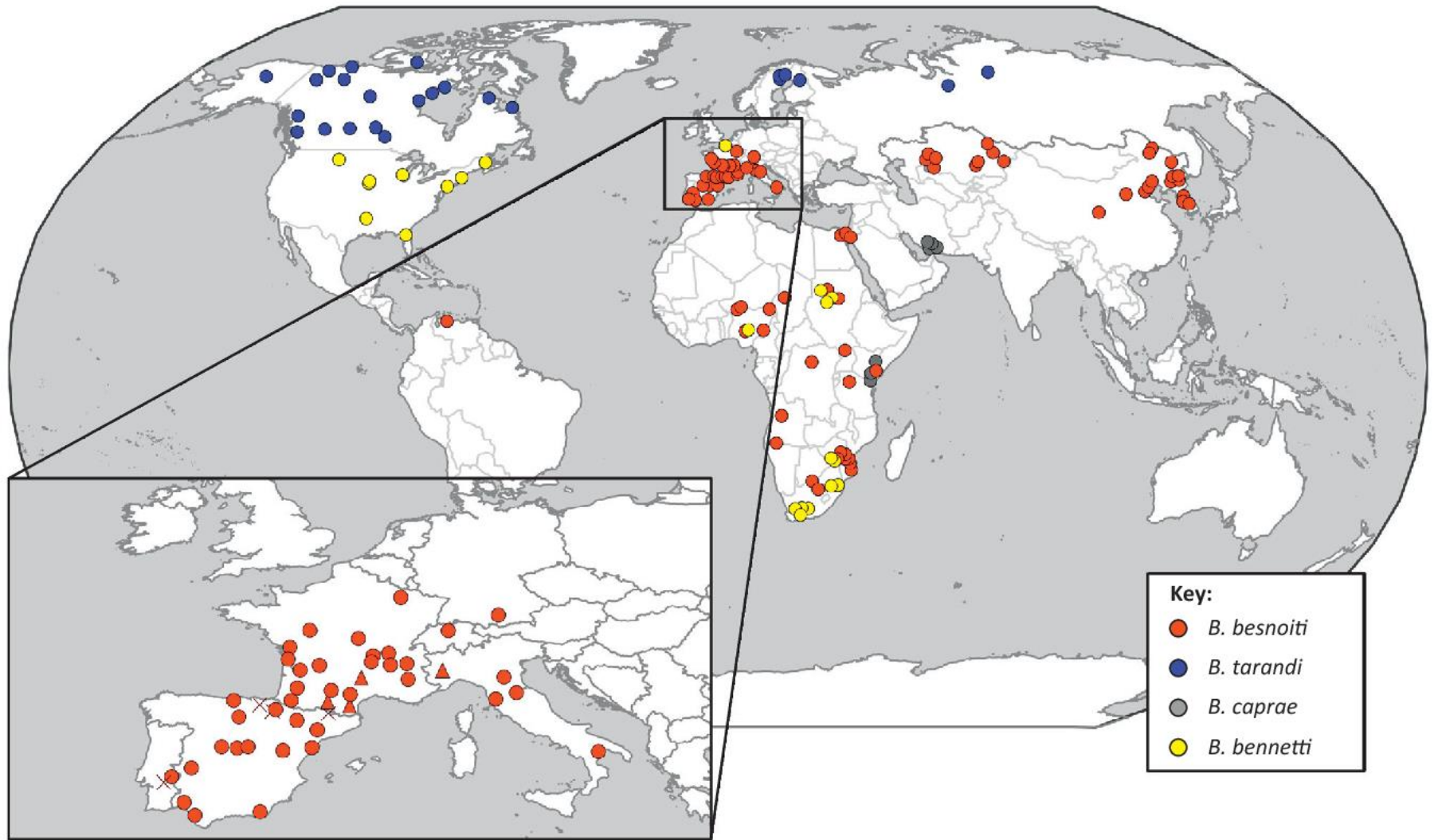


**A)** numerous tissue cysts in the dermis and epithelial desquamation; **B)** cyst with three-layered wall: outermost connective tissue, middle layer containing host cell nuclei and inner parasitophorous vacuole membrane surrounding the bradyzoites; **C)** infiltration with histiocytes and eosinophilic granulocytes around cysts; **D)** occlusion of sebaceous gland duct





# World-wide distribution of *Besnoitia* spp. infections in ungulates



TRENDS in Parasitology

Inlay: chronological expansion of *B. besnoiti* in Europe. Crosses: before 1900; triangles: 1991–2000; circles: 2001–2012

# Apicomplexa

## Aconoidasida•••

- apical complex lacking conoid in asexual motile stages; some diploid motile zygotes (ookinetes); macrogametes and microgametes forming independently; heteroxenous

## Haemospororida••••

- zygote motile as ookinete with conoid; ciliated microgametes produced by merogony; oocyst formed in which sporozoites develop
- *Haemoproteus*, *Leucocytozoon*, *Mesnilium*, *Plasmodium*

## Piroplasmorida••••

- piriform, round, rod-shaped or amoeboid; conoid and cilia absent in all stages; polar ring present; without oocyst
- *Babesia*, *Theileria*

# Apicomplexa

## Aconoidasida (previously Hematozoa)

- dixenous parasites – vertebrate host and arthropod vector
- merogony in vertebrate erythrocytes (with some exceptions)
- development of gametocytes in vertebrate blood cells
- gamogony and sporogony in arthropod vectors
- sporozoite inoculation with vector saliva
- small number of microgamonts
- motile elongated zygote - ookinete



# Haemospororida

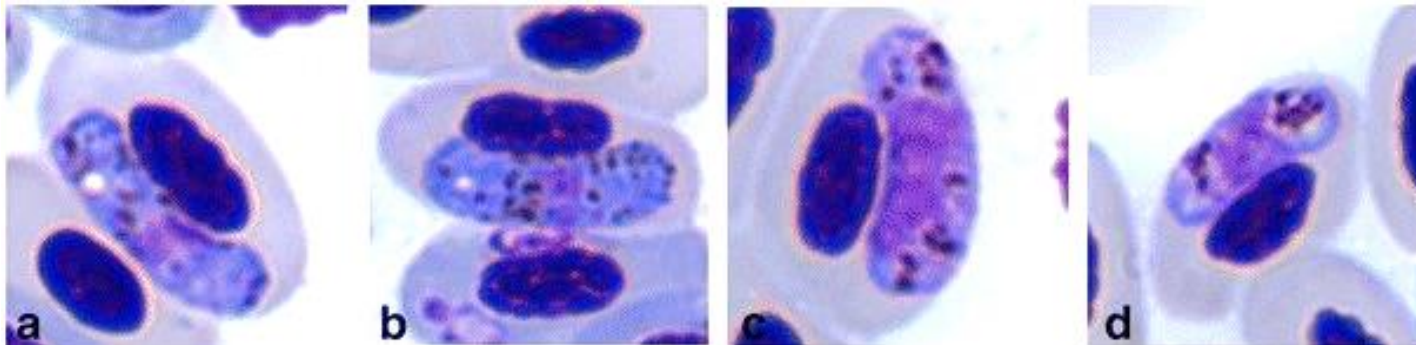
## Plasmodiidae

### genus *Haemoproteus*

- merogony not in erythrocytes but in endothelial cells of blood vessels
- “halter-shaped” gamocytes  $\Rightarrow$  displacement of the host nucleus
- gamogony and sporogony in blood sucking insects - sporozoites in their salivary glands

### *Haemoproteus columbae*

- transmitted by pigeon louse fly *Pseudolynchia canariensis*
- heavy infection  $\Rightarrow$  cell granuloma and massive destruction of the parenchyma of liver and lungs leading to severe illness or even death of the pigeons



Gametocytes from the blood of *Columba livia*. a-b) macrogametocytes, c-d) microgametocytes

# Haemospororida

## Plasmodiidae

### genus *Leucocytozoon*

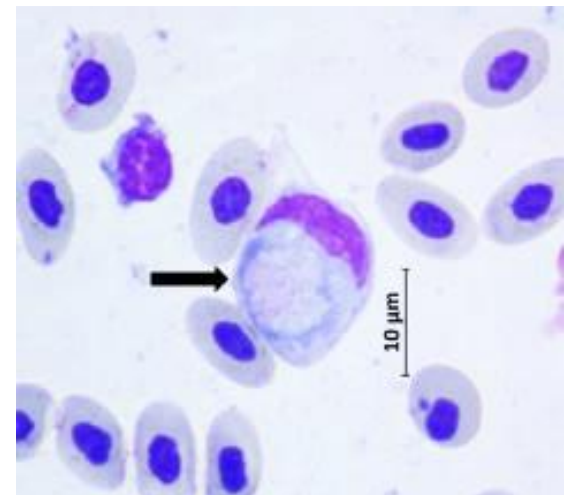
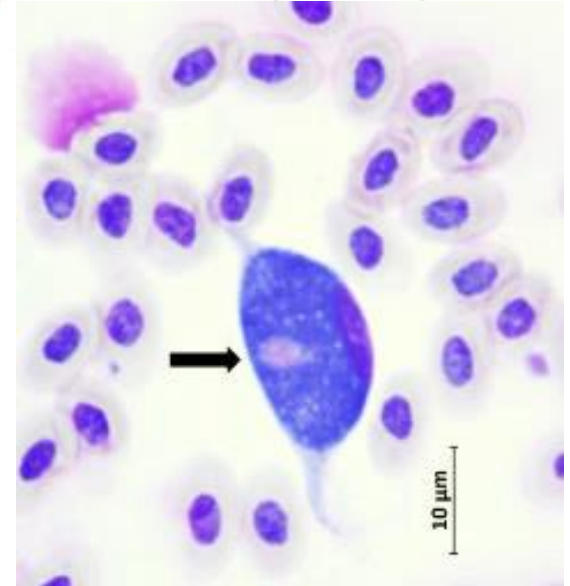
- about 60 species in various birds
- transmitted by black flies (*Simulium*), biting midges (*Culicoides*)
- no merogony in erythrocytes, but in endothelial cells of blood vessels of parenchymatous organs
- development of gamonts in leucocytes
- gamonts mostly elongated with long tapering extremities, in some species round

#### *Leucocytozoon simondi*


- duck, geese

#### *L. smithi*

- turkeys



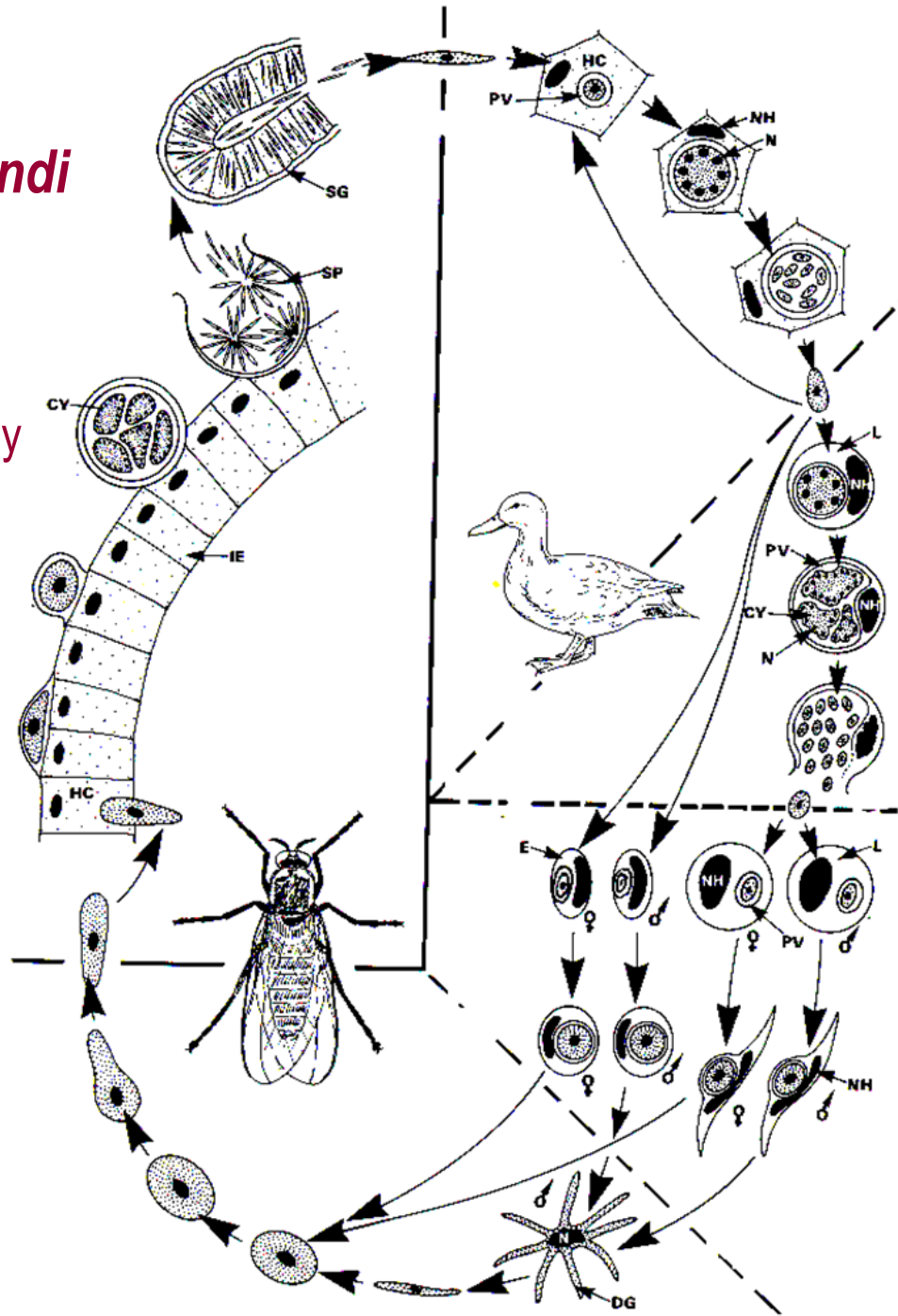
# Life cycle of *Leucocytozoon simondi*



sporogony

merogony

gamogony



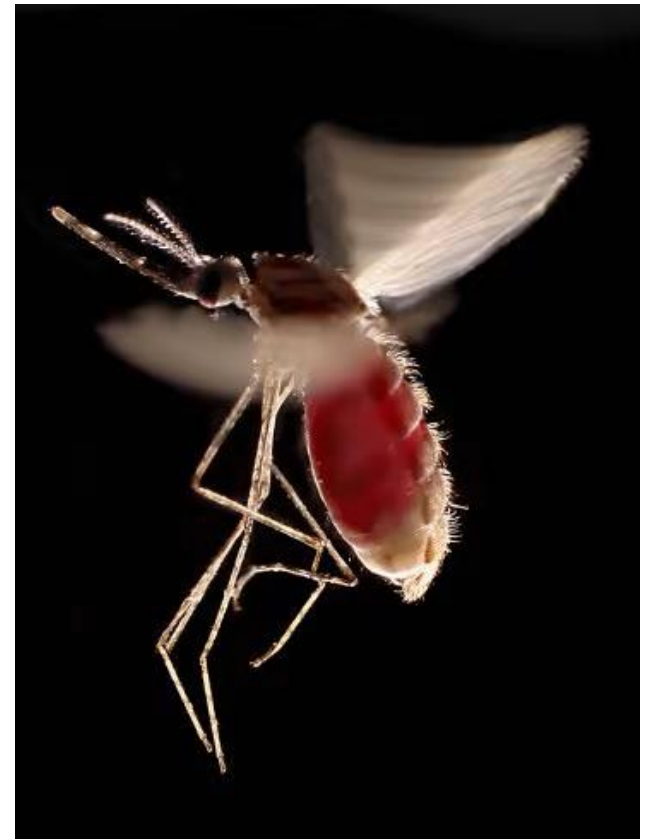
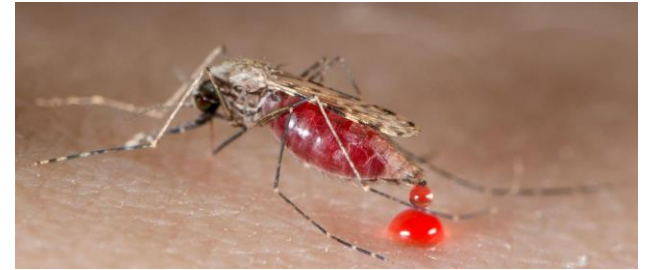
# Haemospororida

## Plasmodiidae

### genus *Plasmodium*

- about 200 species (birds 45 species, mammals 55 species, reptiles 70 species)
- sporozoites in vector salivary glands
- first exoerythrocytic merogony:
  - birds - endothelial cells of blood vessels
  - mammals - hepatocytes
- merogony in erythrocytes
- gamogony and sporogony in mosquitoes
  - birds - *Aedes*, *Culex*, *Mansonia*
  - mammals - *Anopheles*
- „mal-aria“ = bad air in swamp (mosquito biotope)
- first evidence of malaria found in mosquitoes preserved in amber from Palaeogene period (cca 30 million years old)



# Avian malaria

## *Plasmodium gallinaceum*

- poultry

## *P. lophurae*

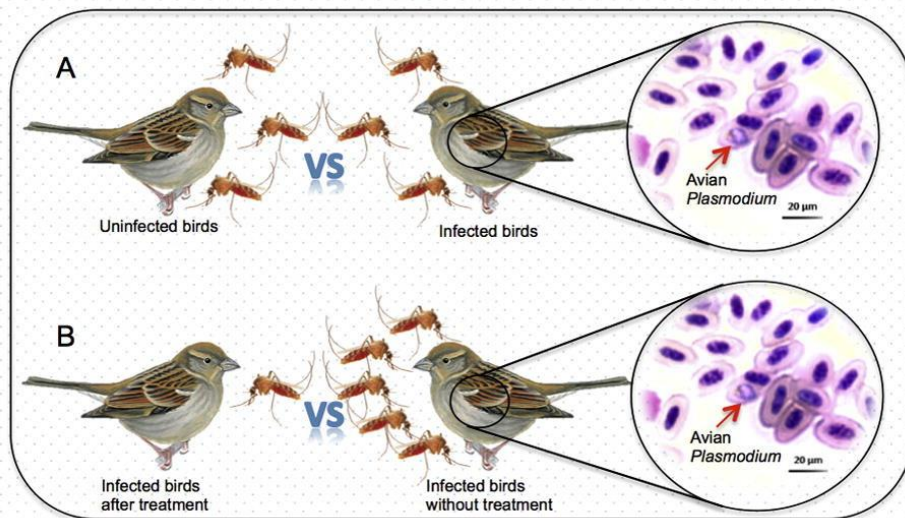
- chickens, ducks

## *P. cathemerium*

- passerine, pathogenic for canaries

## *P. relictum*

- passerine, pathogenic for pigeons



<https://doi.org/10.1016/j.ijpara.2017.09.005>

## Highlights

- Mosquitoes fed randomly on uninfected and avian *Plasmodium*-infected birds.
- Mosquitoes preferably bit infected birds than anti-malaria treated infected birds.
- Malaria parasite load instead of infection itself affects mosquito blood feeding.
- A positive link between parasitaemia and biting rate supports the parasitic manipulation hypothesis.

# Rodent malaria

## *Plasmodium berghei*

- rodents, originally isolated from thicket rats *Grammomys surdaster*
- laboratory model
- vector: *Anopheles durenii*



## *P. vinckei*

## *P. chabaudi*

## *P. yoelli*

- laboratory model
- vector. *Anopheles stephensi*





# Malaria in non-human primates

- 7 species can be experimentally transferred to humans

## *Plasmodium brasilianum*

- platyrrhine monkeys of South and Central America



## *P. cynomolgi*

- macaques, capuchin monkeys, transferable to human

## *P. knowlesi*

- macaques, transferable to human

## *P. swetzi*

- chimpanzee, gorilla

## *P. rodhaini*

- chimpanzee



# Plasmodium species infecting humans

## *Plasmodium falciparum*

- malignant tertian malaria
- single generation of hepatic merogony
- recrudescence ⇨ reinfection
- attacked erythrocytes adhere to vessel walls

## *Plasmodium vivax*

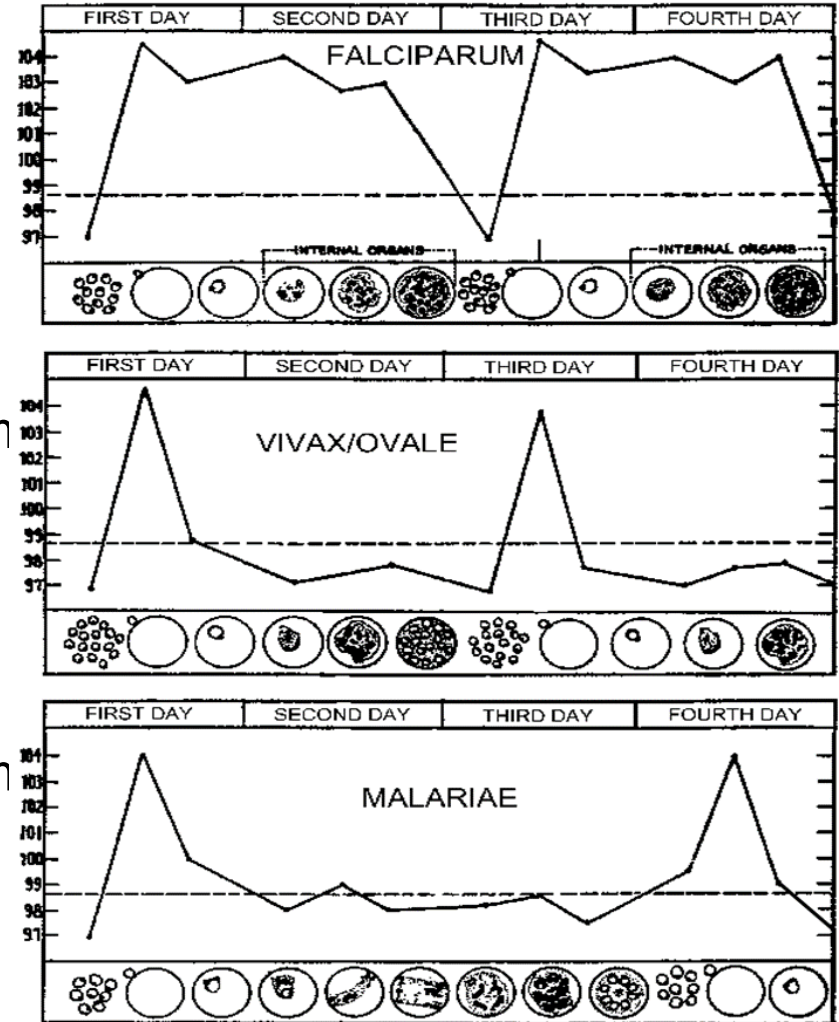
- most frequent cause of benign tertian malaria
- multiple generations of hepatic merogony, hypn formation
- frequent relapses even after several years

## *Plasmodium ovale*

- less frequent cause of benign tertian malaria
- multiple generations of hepatic merogony, hypn formation
- long prepatent period - up to 4 years

## *Plasmodium malariae*

- benign quartan malaria
- low parasitaemia, attacking only mature erythrocytes



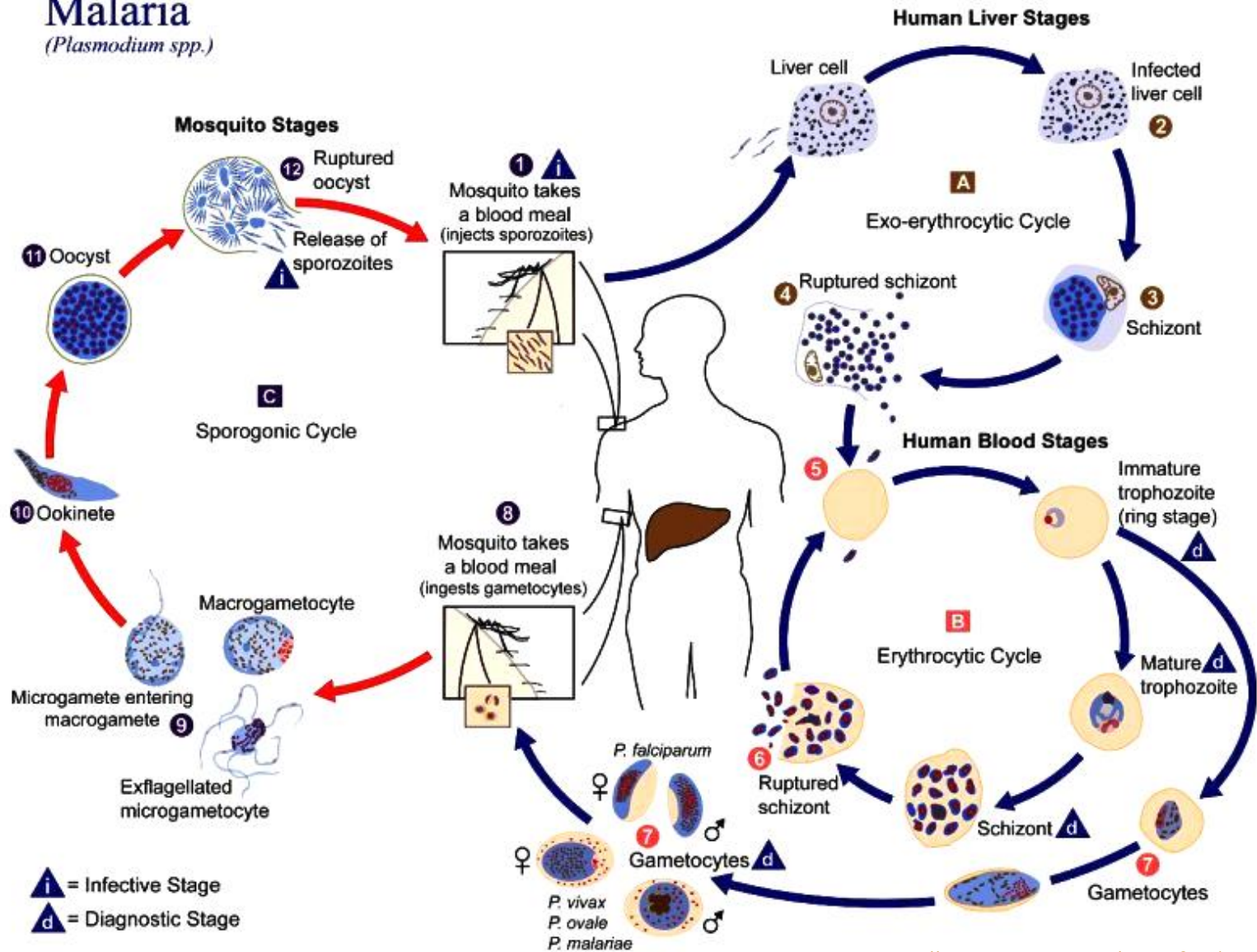
# **Plasmodium species infecting humans**

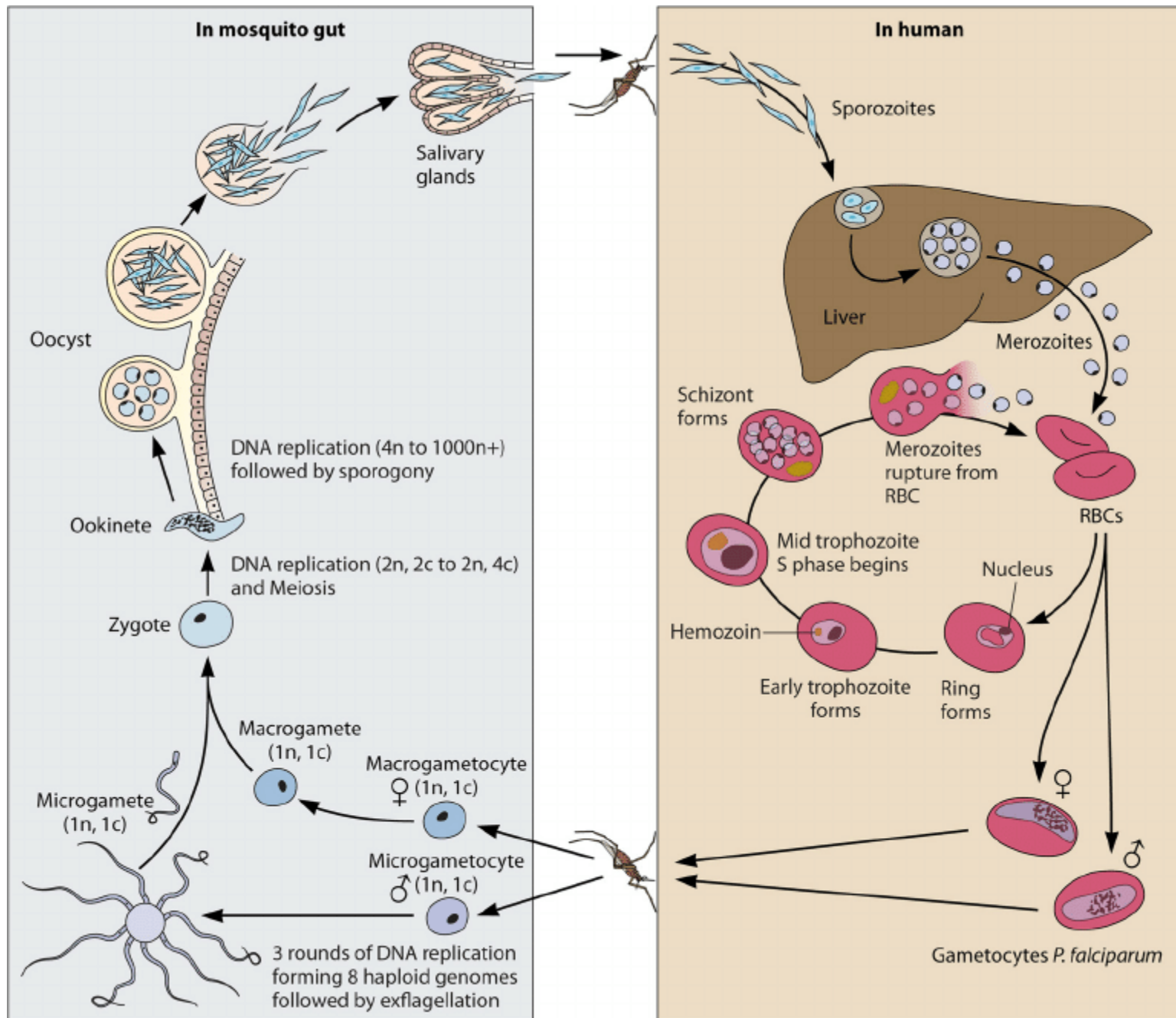
- ***P. falciparum***, which is found worldwide in tropical and subtropical areas. It is estimated that every year approximately 1 million people are killed by *P. falciparum*, especially in Africa where this species predominates. *P. falciparum* can cause severe malaria because it multiplies rapidly in the blood, and can thus cause severe blood loss (anemia). In addition, the infected parasites can clog small blood vessels. When this occurs in the brain, cerebral malaria results, a complication that can be fatal.
- ***P. vivax***, which is found mostly in Asia, Latin America, and in some parts of Africa. Because of the population densities especially in Asia it is probably the most prevalent human malaria parasite. *P. vivax* (as well as *P. ovale*) has dormant liver stages ("hypnozoites") that can activate and invade the blood ("relapse") several months or years after the infecting mosquito bite.
- ***P. ovale*** is found mostly in Africa (especially West Africa) and the islands of the western Pacific. It is biologically and morphologically very similar to *P. vivax*. However, differently from *P. vivax*, it can infect individuals who are negative for the Duffy blood group, which is the case for many residents of sub-Saharan Africa. This explains the greater prevalence of *P. ovale* (rather than *P. vivax*) in most of Africa.
- ***P. malariae***, found worldwide, is the only human malaria parasite species that has a quartan cycle (three-day cycle). (The three other species have a tertian, two-day cycle.) If untreated, *P. malariae* causes a long-lasting, chronic infection that in some cases can last a lifetime. In some chronically infected patients *P. malariae* can cause serious complications such as the nephrotic syndrome.
- ***P. knowlesi*** is found throughout Southeast Asia as a natural pathogen of long-tailed and pig-tailed macaques. It has recently been shown to be a significant cause of zoonotic malaria in that region, particularly in Malaysia. *P. knowlesi* has a 24-hour replication cycle and so can rapidly progress from an uncomplicated to a severe infection; fatal cases have been reported.



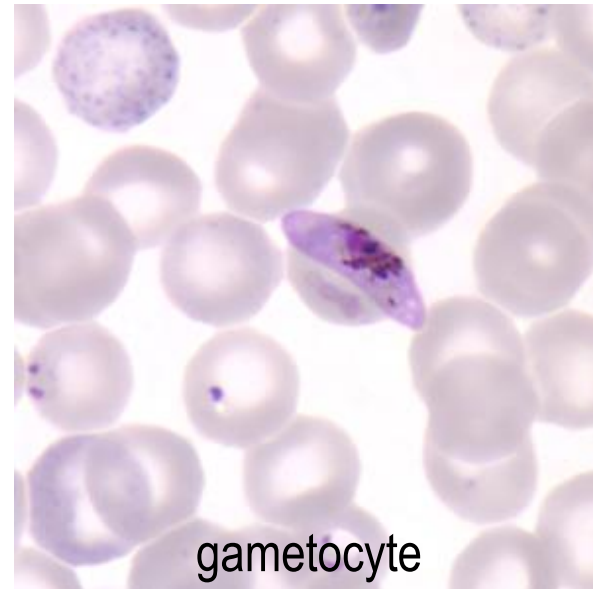
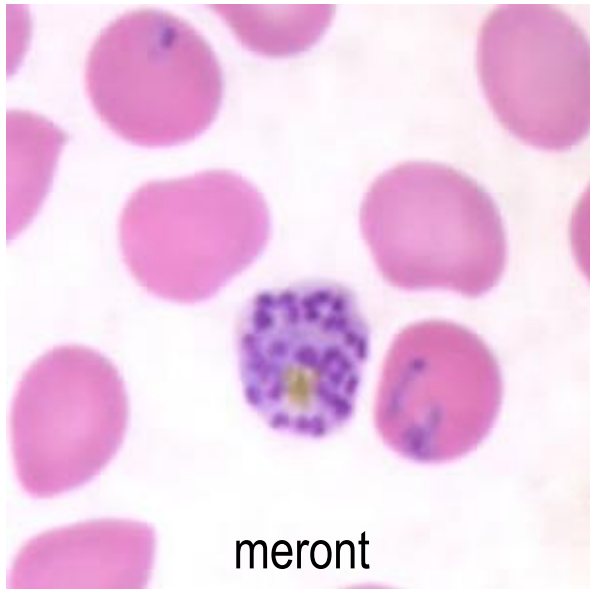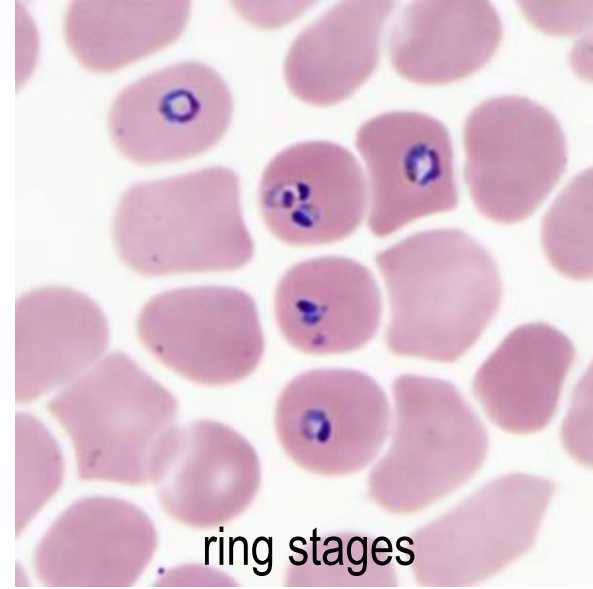
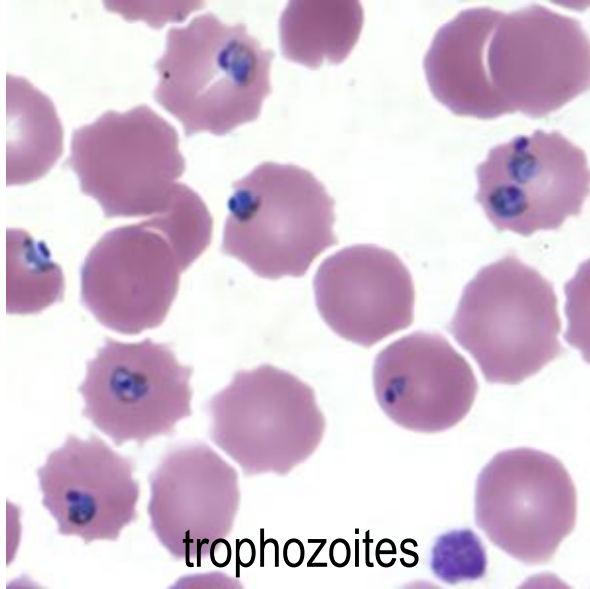# Life cycle of human *Plasmodium* spp.

## Malaria (*Plasmodium* spp.)



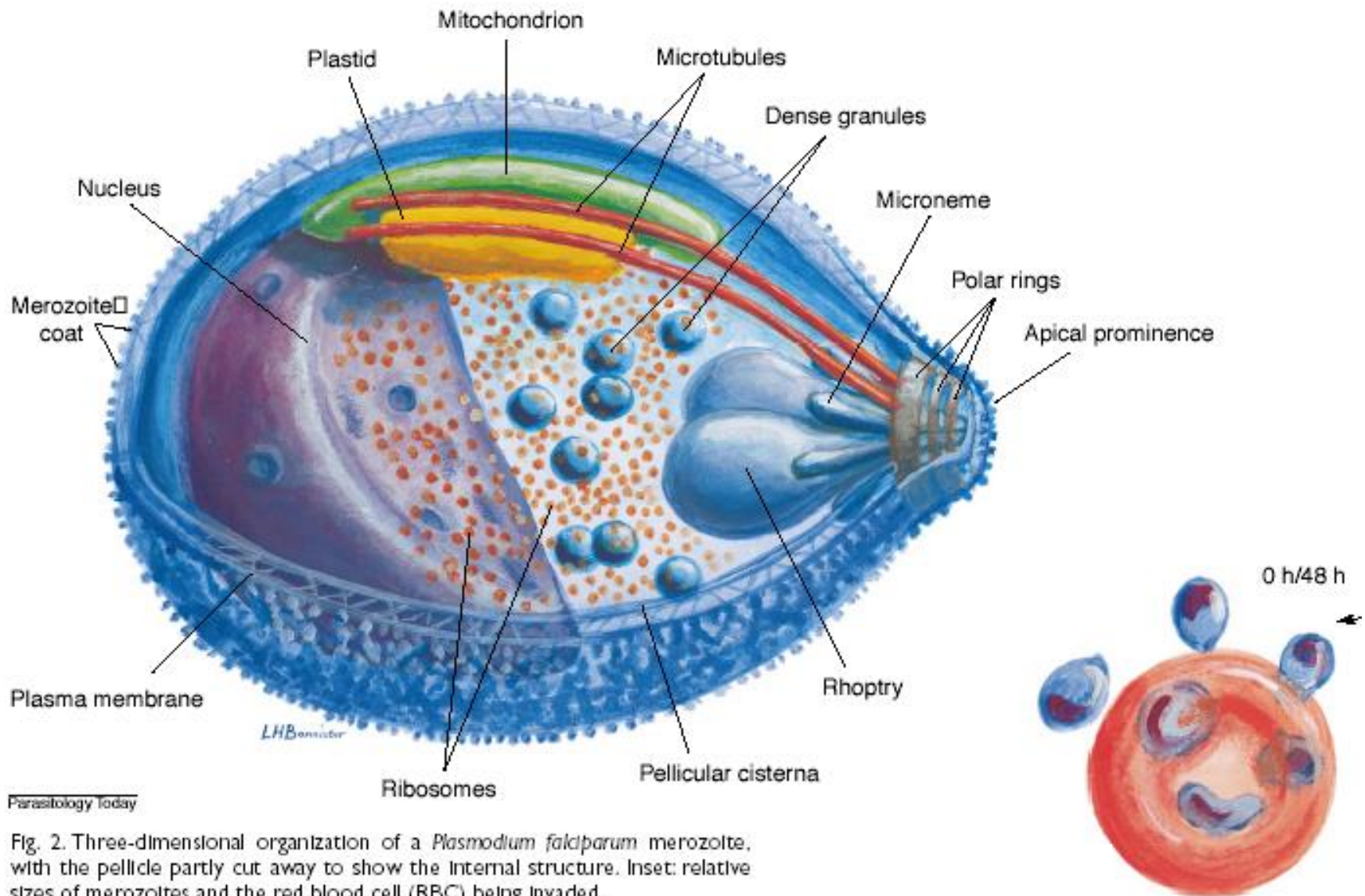


# Morphology of *Plasmodium falciparum* stages





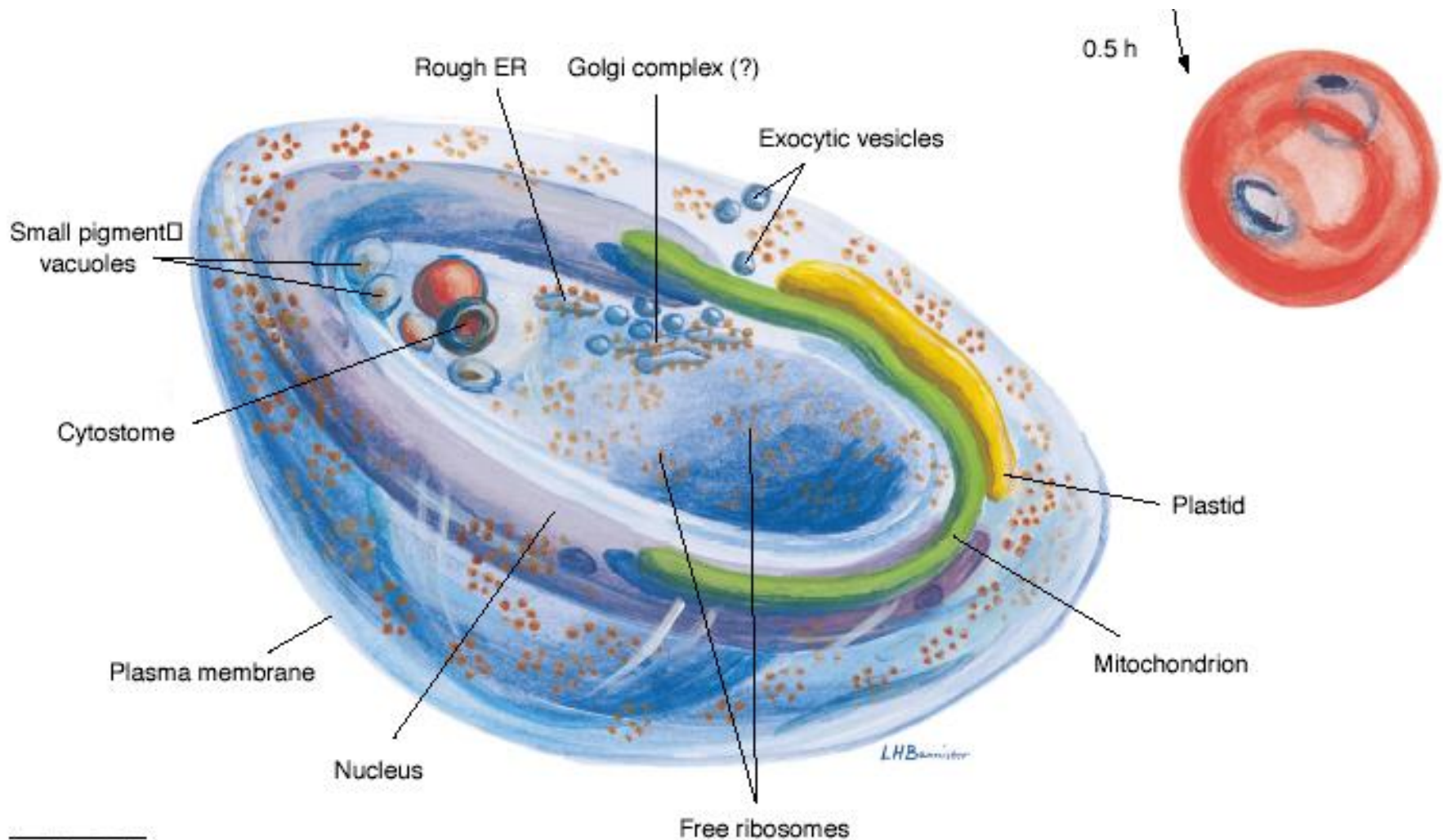
# Morphology of *Plasmodium falciparum* merozoite



Parasitology Today

Fig. 2. Three-dimensional organization of a *Plasmodium falciparum* merozoite, with the pellicle partly cut away to show the internal structure. Inset: relative sizes of merozoites and the red blood cell (RBC) being invaded.

# Morphology of *Plasmodium falciparum* early ring stage



Parasitology Today

Fig. 3. Three-dimensional organization of a *Plasmodium falciparum* early ring stage, a cup-like form in this example. For clarity, the host red blood cell (RBC) and parasitophorous vacuole membrane (PVM) are not shown. Inset: ring stage as seen in a Giemsa-stained film by light microscopy, including two forms, one flat and discoidal (above) and the other cup-shaped. ER, endoplasmic reticulum.



# Morphology of *Plasmodium falciparum* trophozoite

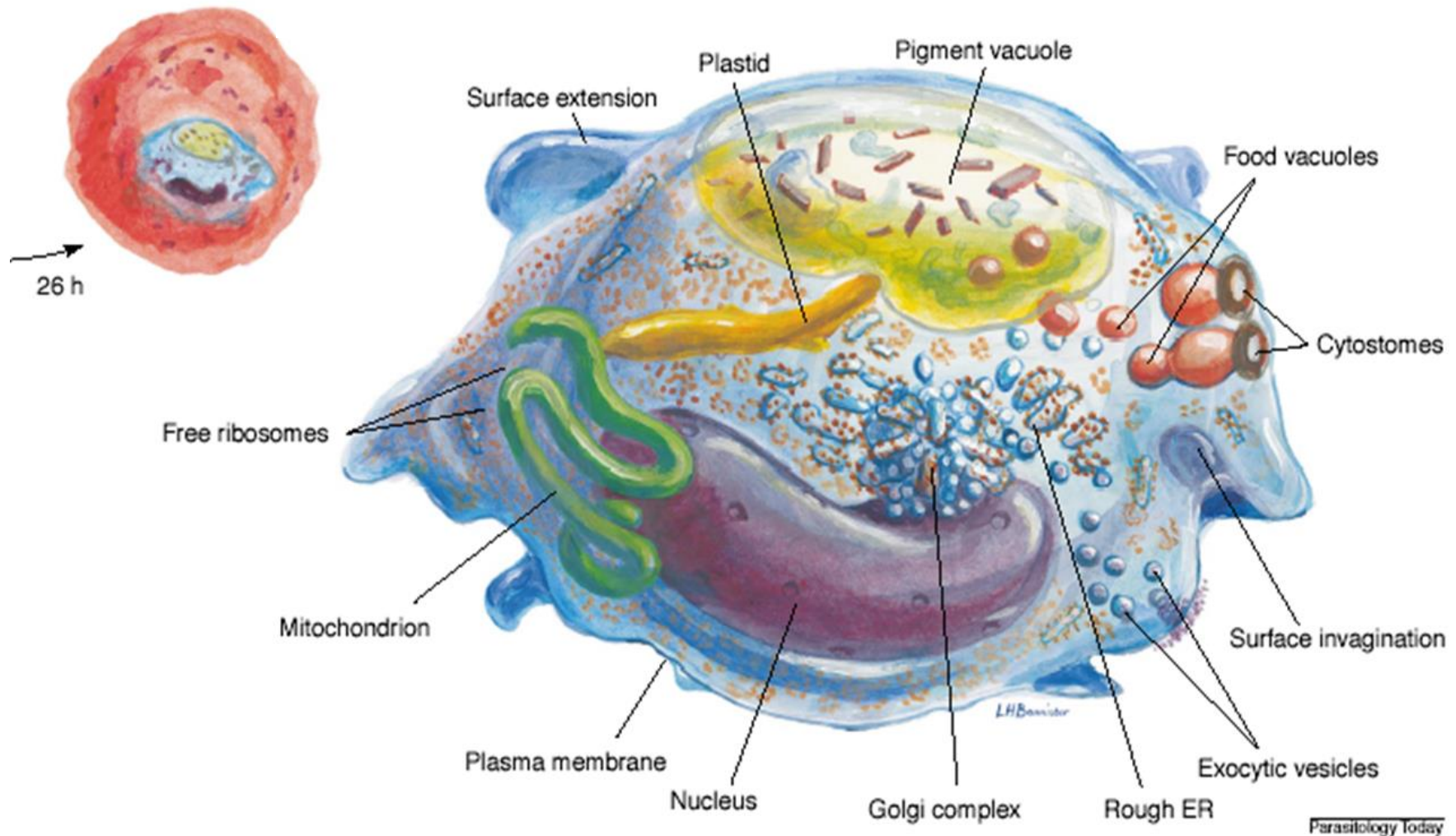
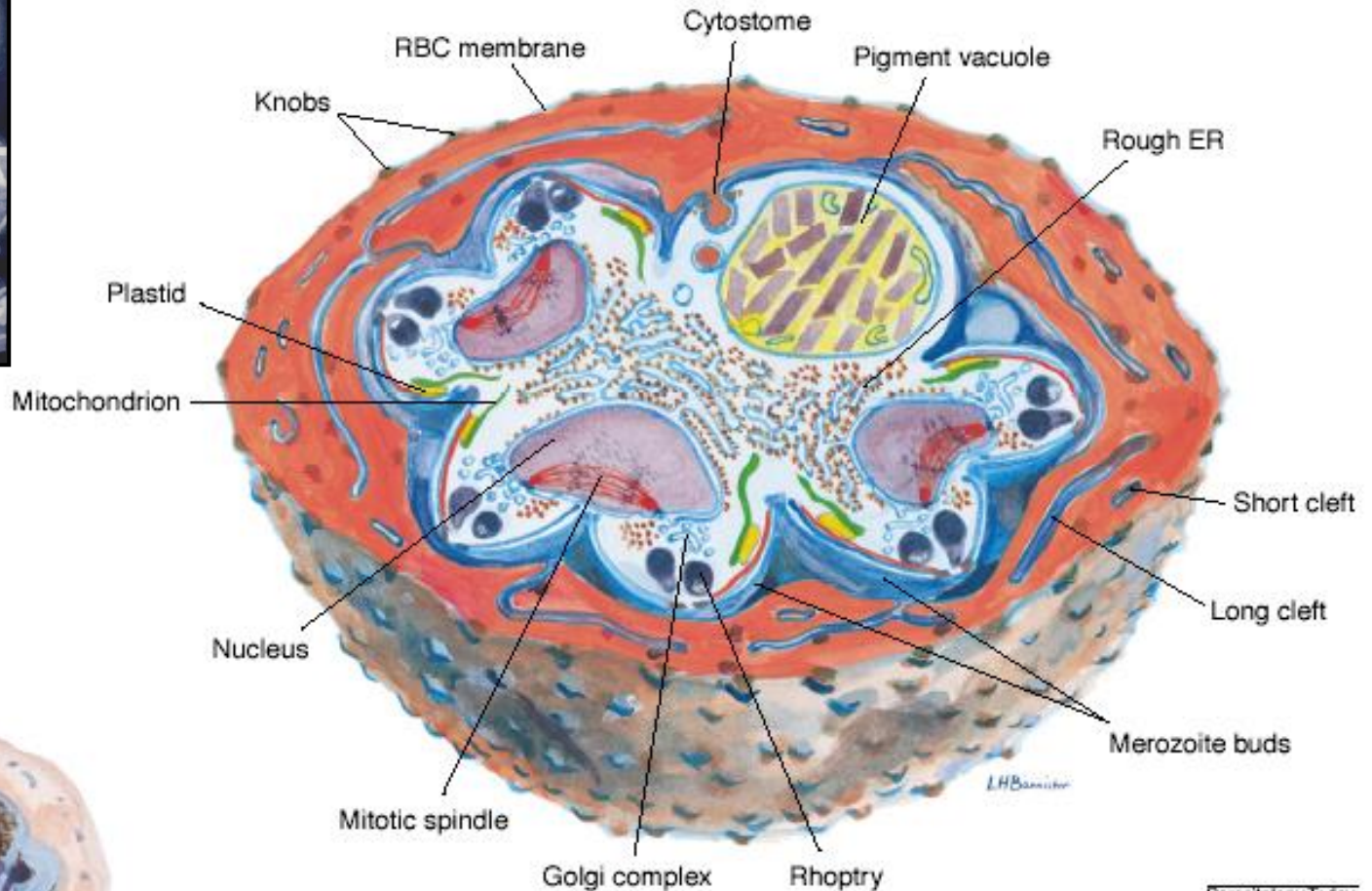
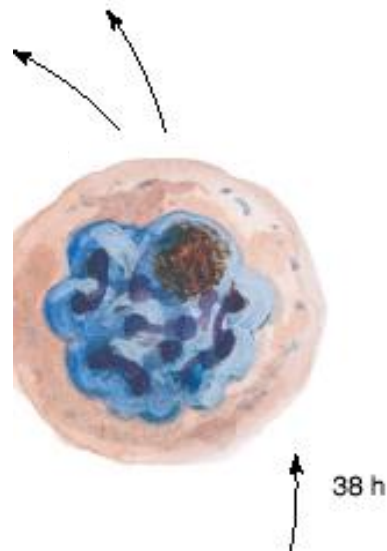
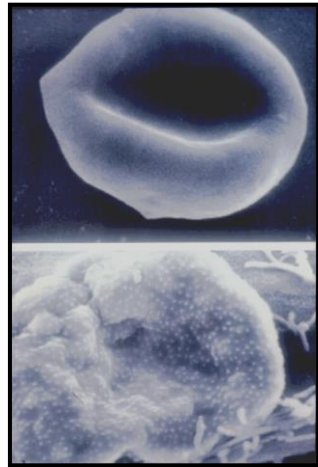


Fig. 4. Mid-trophozoite stage of *Plasmodium falciparum*, characterized by its irregular outline, the increase in protein-synthesizing apparatus, increased feeding through multiple cytostomes, growth of the pigment vacuole, and structures associated with export of parasite proteins (Golgi body, exocytic vesicles). Inset: relative sizes of trophozoite and red blood cell (RBC) as seen by light microscopy. ER, endoplasmic reticulum.



# Morphology of *Plasmodium falciparum* meront



Parasitology Today

Fig. 5. Organization of a *Plasmodium falciparum* schizont towards the end of that stage, depicted in a schizont-infected red blood cell (RBC) cut transversely to show parasite and RBC structure, including Maurer's clefts (designated here as long and short clefts) and surface knobs. Merozoites are budding from the surface of the schizont. In the apex of each merozoite bud the apical organelles are developing, and mitochondria (green) and plastids (yellow) are migrating into the buds. Inset: relative sizes of schizont and RBC. ER, endoplasmic reticulum.

# Symptoms of uncomplicated malaria



Headache



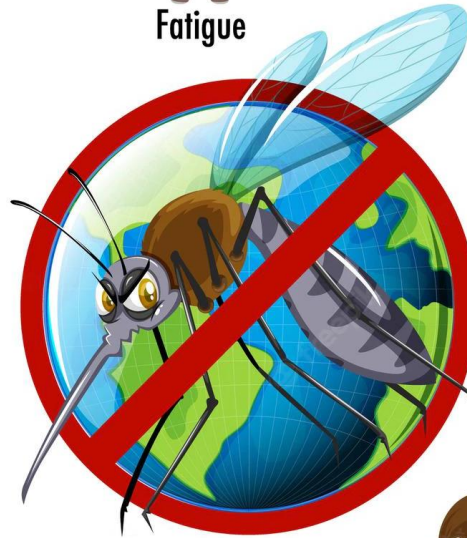Fatigue



Nausea



Chills



Muscle Aches

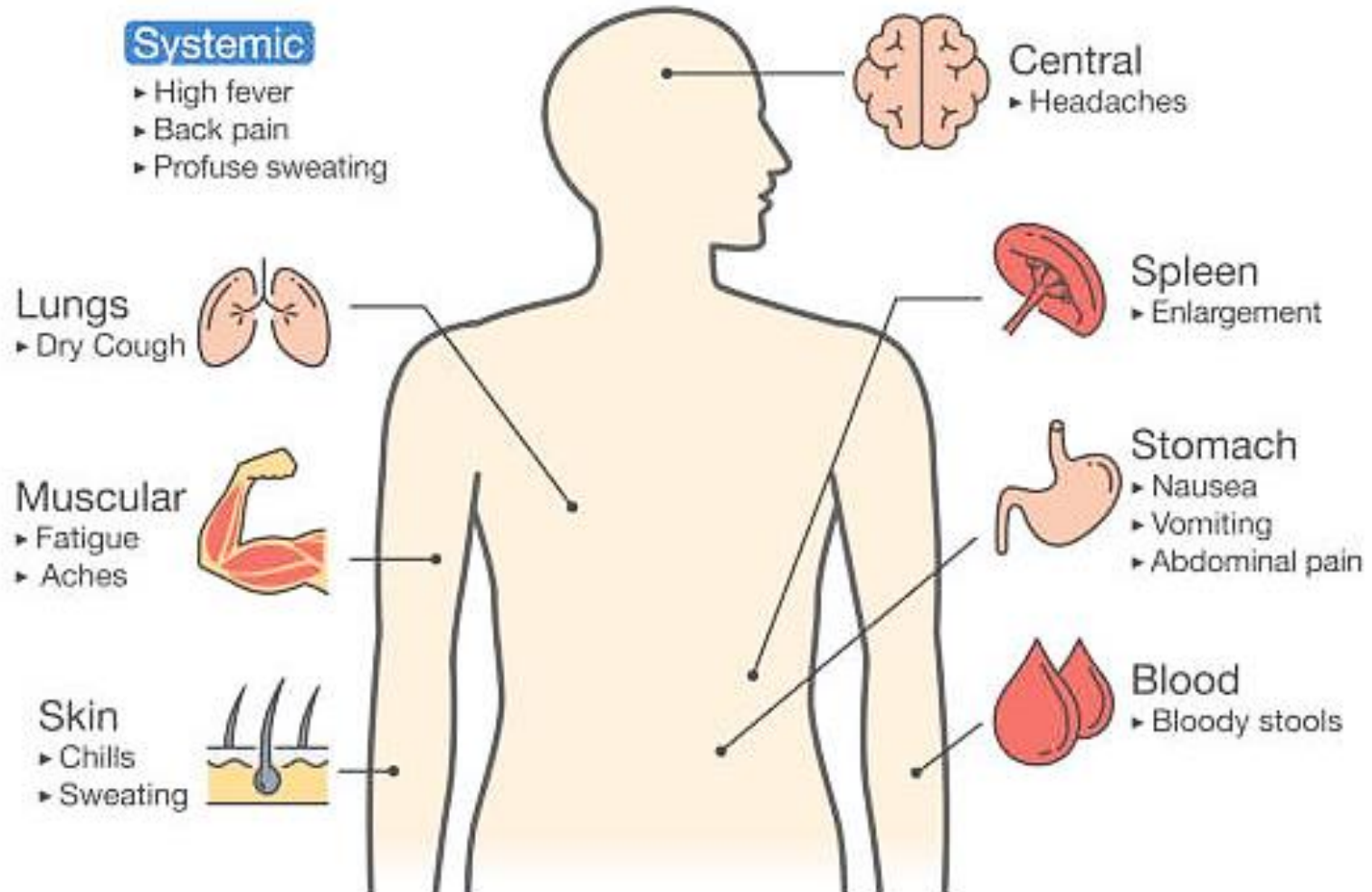


Fever



Vomiting

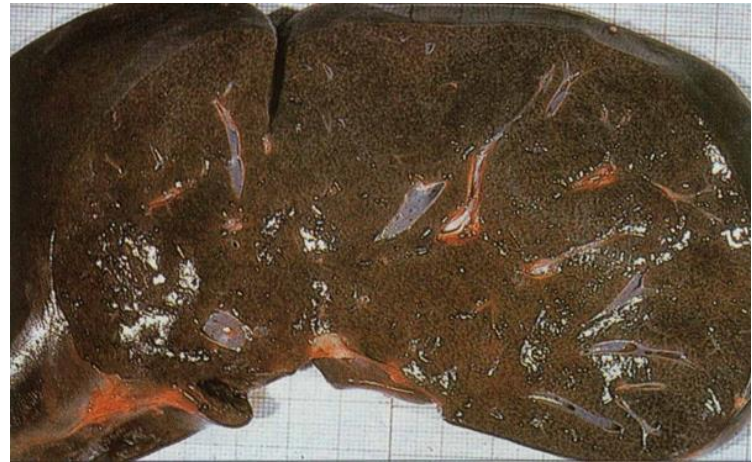# Symptoms and physical findings in uncomplicated malaria





# Manifestations of severe malaria

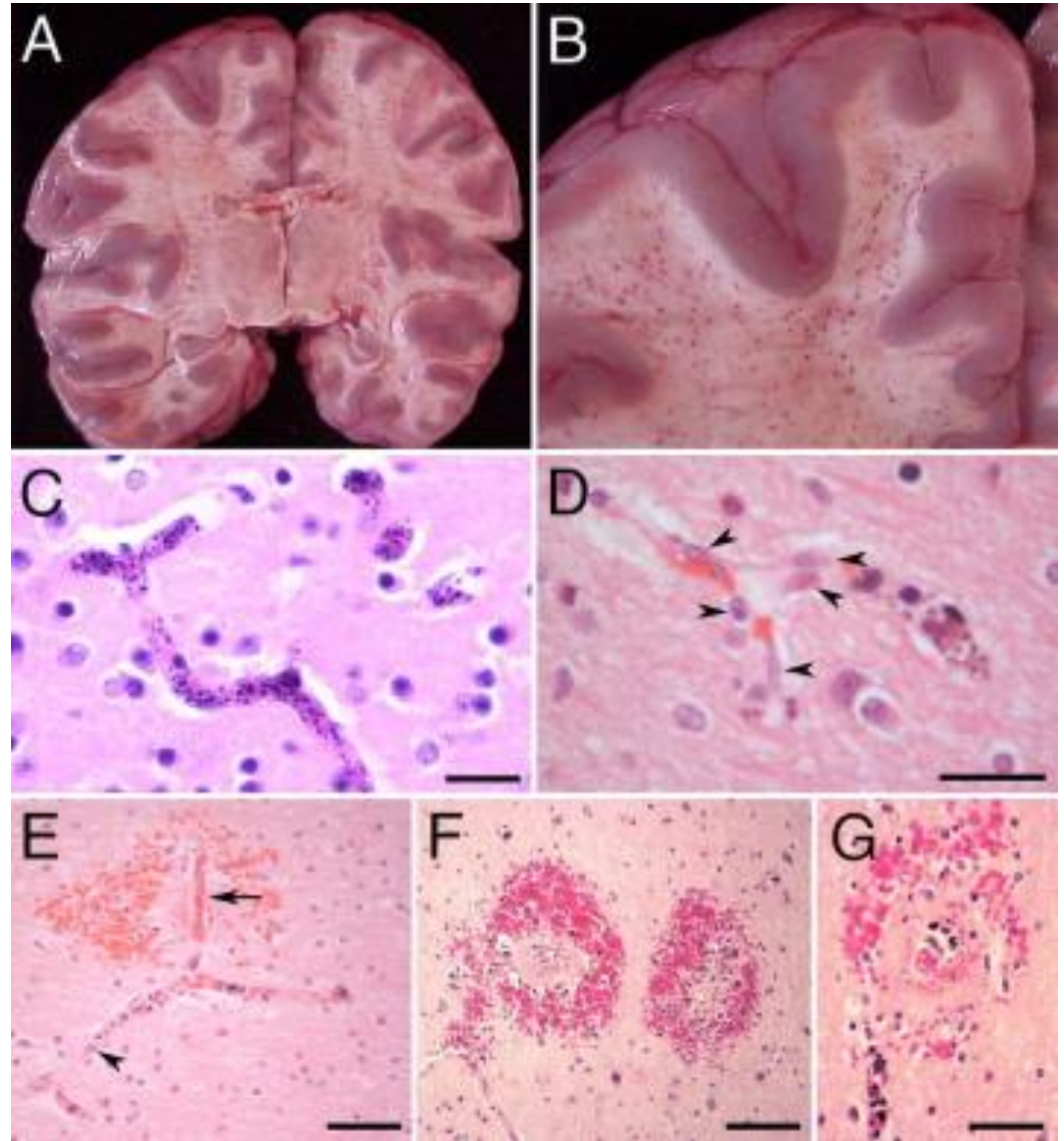
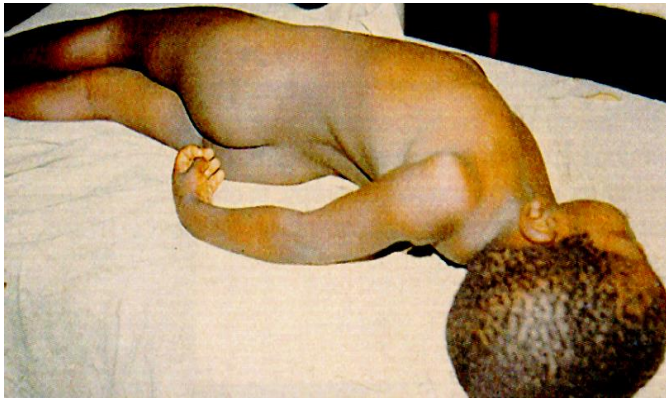
- host is repeatedly exposed to the effects of toxins, metabolic products and antigens (immunogens)  $\Rightarrow$  cascade of indirect pathological reactions leading to circulatory disorders, pathological immune reactions and a general disruption of metabolism
- immunocomplexes
- cerebral malaria - coma
- anaemia due to haemolysis
- abnormalities in blood coagulation
- haemoglobinuria
- acute kidney injury
- hepatosplenomegaly
- acute respiratory distress syndrome
- low blood pressure caused by cardiovascular collapse
- metabolic acidosis often in association with hypoglycemia



# Cerebral malaria

## *Plasmodium falciparum*

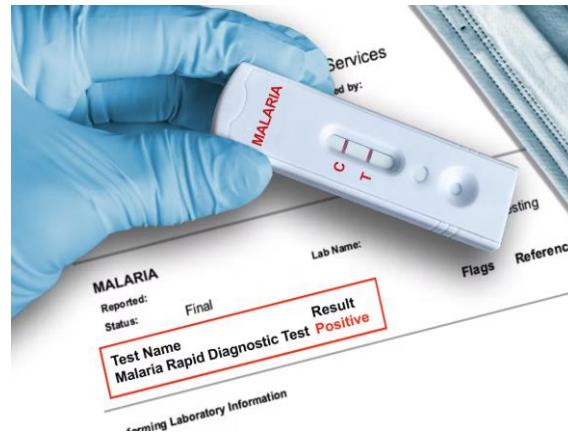- abnormal behaviour
- impairment of consciousness
- seizures, coma, or other neurologic abnormalities
- opisthotonus (opisthotonos)



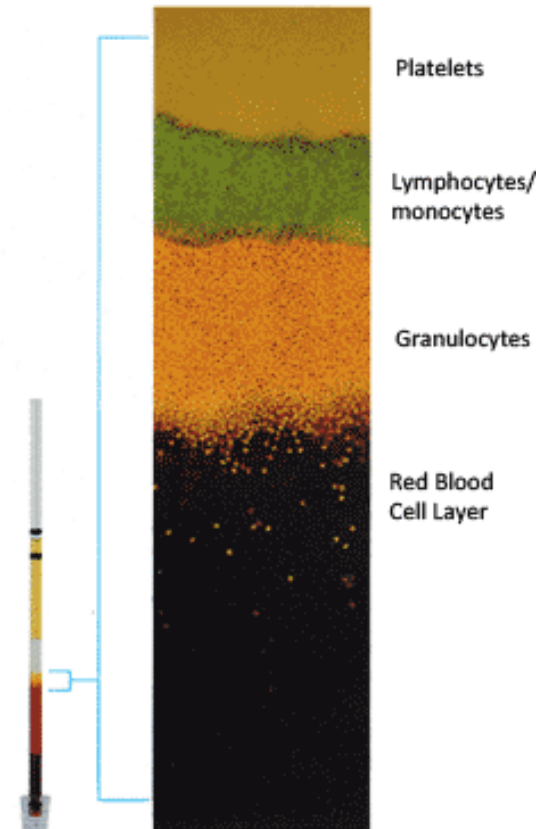
Petechial hemorrhages in white matter, compression of lateral and third ventricles due to edema, vascular changes and thrombus

# Diagnosis of malaria

- ✓ clinical symptoms
- ✓ microscopic detection
- ✓ QBC (quantitative buffy coat) capillary tube test
- ✓ antigen detection – rapid diagnostic tests



- ✓ PCR - malaria species identification
- ✓ serology (IFA, ELISA) - does not detect current infection but measures past exposure
- ✓ drug resistance tests







# Malaria

26 July 2022

## Key facts

- Malaria is a life-threatening disease caused by parasites that are transmitted to people through the bites of infected female *Anopheles* mosquitoes. It is preventable and curable.
- In 2020, there were an estimated 241 million cases of malaria worldwide.
- The estimated number of malaria deaths stood at 627 000 in 2020.
- The WHO African Region carries a disproportionately high share of the global malaria burden. In 2020, the region was home to 95% of malaria cases and 96% of malaria deaths. Children under 5 accounted for about 80% of all malaria deaths in the Region.

## Overview

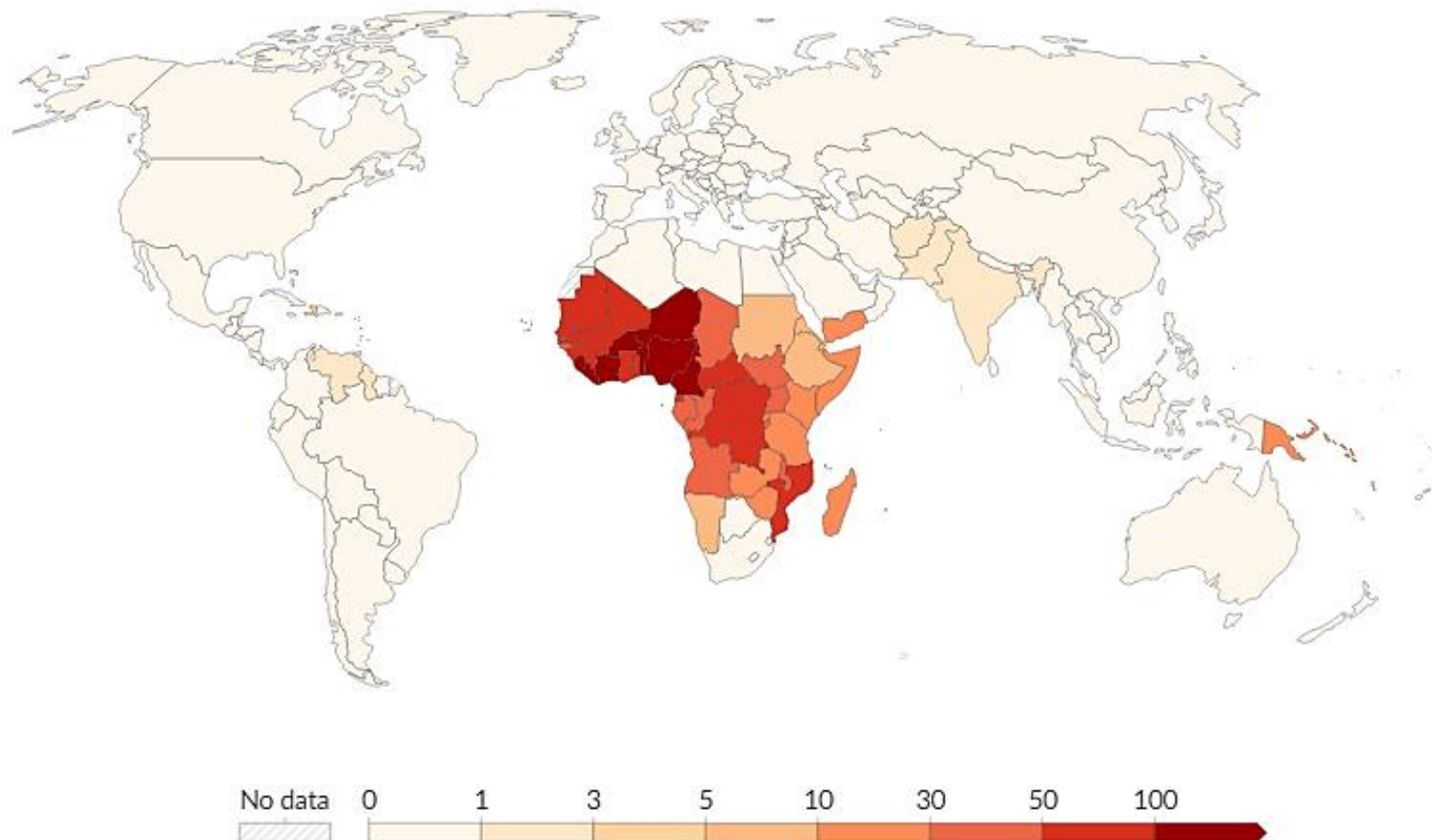
Malaria is an acute febrile illness caused by *Plasmodium* parasites, which are spread to people through the bites of infected female *Anopheles* mosquitoes. There are 5 parasite species that cause malaria in humans, and 2 of these species – *P. falciparum* and *P. vivax* – pose the greatest threat. *P. falciparum* is the deadliest malaria parasite and the most prevalent on the African continent. *P. vivax* is the dominant malaria parasite in most countries outside of sub-Saharan Africa.

The first symptoms – fever, headache and chills – usually appear 10–15 days after the infective mosquito bite and may be mild and difficult to recognize as malaria. Left untreated, *P. falciparum* malaria can progress to severe illness and death within a period of 24 hours.

In 2020, nearly half of the world's population was at risk of malaria. Some population groups are at considerably higher risk of contracting malaria and developing severe disease: infants, children under 5 years of age, pregnant women and patients with HIV/AIDS, as well as people with low immunity moving to areas with intense malaria transmission such as migrant workers, mobile populations and travellers.

# Death rate from malaria, 2019

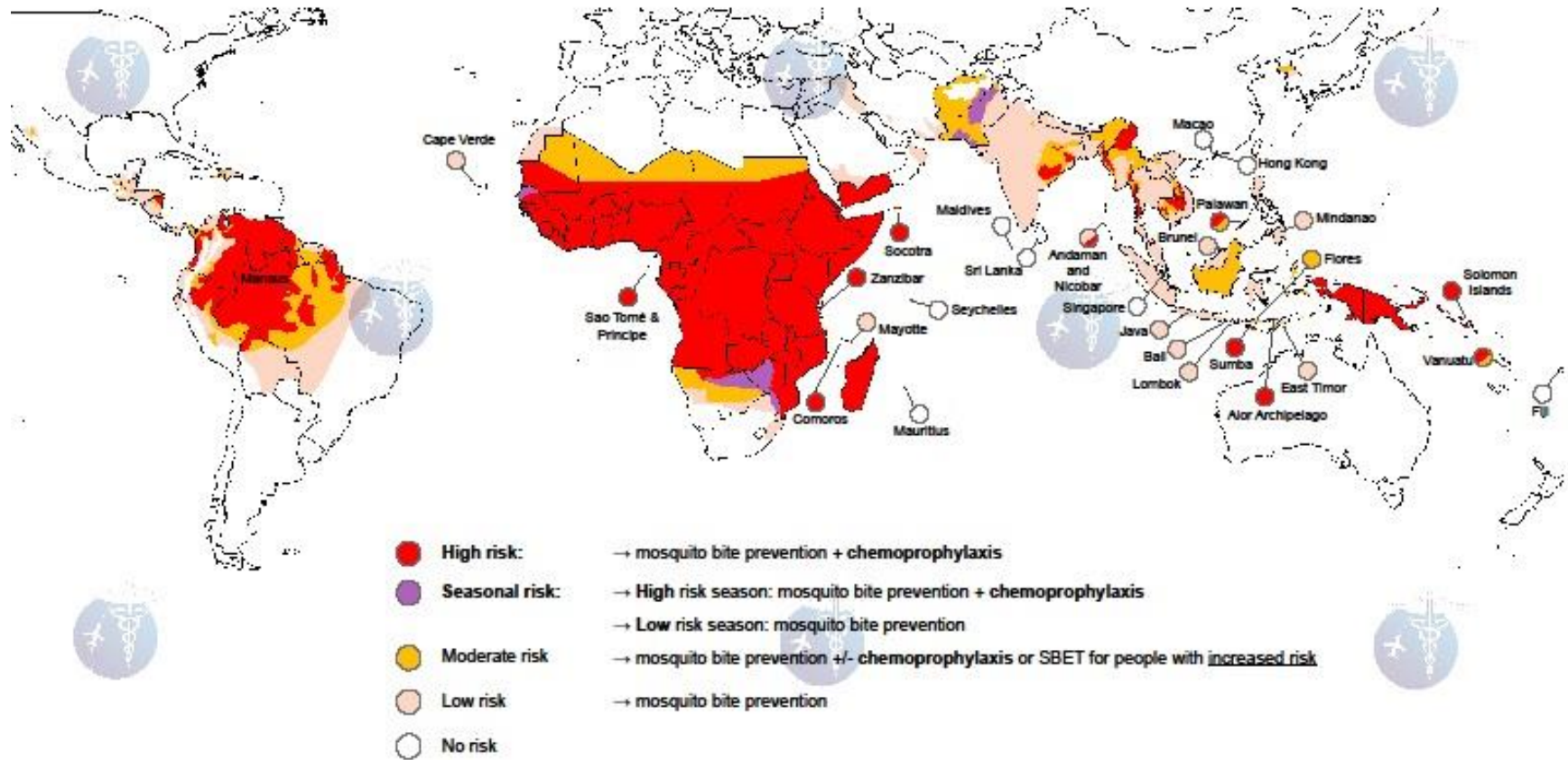
The number of deaths from malaria per 100,000 people.



Source: IHME, Global Burden of Disease (2019)

Note: To allow comparisons between countries and over time this metric is age-standardized.

# Malaria risk 2022



© ECTM

Source: World Malaria Reports 2018, 2019, 2020, adapted by Olivia Velt, ECTM and Ula Maniewski, ITM

The boundaries, names and designations used are not intended as a legal status of the countries, territories or cities and their authorities or on the course of their geographical and political boundaries.



Belgische Studiegroep  
Reizigersgeneeskunde  
Groupe d'Etude Belge  
de la Médecine des Voyages



Société Française de Médecine des Voyages  
Créer l'expertise pour les professionnels de voyage  
Conseils à l'étranger, par la médecine du voyage  
Expert conseil en santé publique









Wooden huts on a river in Siem Reap, Cambodia  
Photograph by Nic Cleave Photography/Alamy





Bed nets in a boy's dormitory in Kafue, Zambia  
Photograph by John Stanmeyer





Man spraying pesticide in Kolkata (Calcutta), India  
Photograph by John Stanmeyer



World Health Organization

Tweety 39,5 tis.

Sledování 1 740

Sledující 4,74 mil.

Lajky 9 185

Seznamy 22

Okamžiky 9

Sledovat

### World Health Organization (WHO) ✓

@WHO

We are the #UnitedNations' health agency. We are committed to achieve better health for everyone, everywhere - #HealthForAll

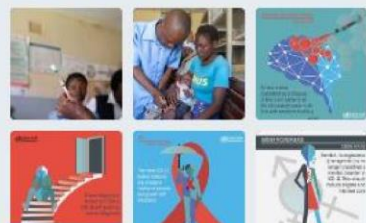Geneva, Switzerland

who.int

Připojil se duben 2008

Tento účet pomáhá v nouzových situacích sdílet důležité informace prostřednictvím twitterových upozornění. Buďte připraveni

8 767 fotek nebo videí



### Tweety Tweety a odpovědi Média

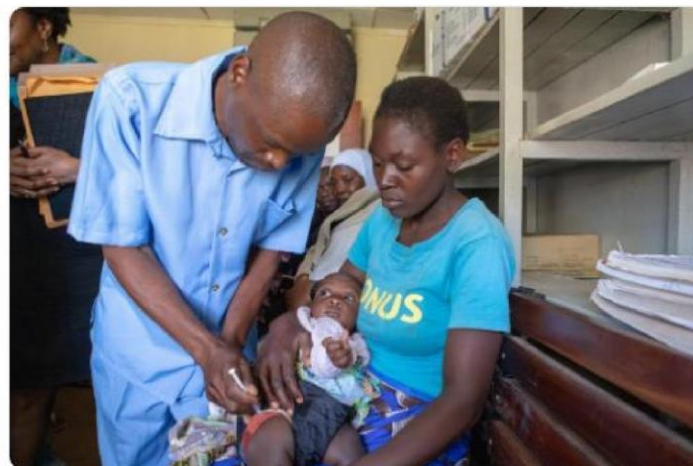Podívejte se na 1 nový Tweet

Připnutý tweet



World Health Organization (WHO) ✓ @WHO · 3 hod.

's first #Malaria vaccine pilot is launched in #Malawi, the first country in Africa to roll out this landmark vaccine, known as RTS,S. The vaccine will be available to children from 5 months old to 2 years. bit.ly/2ZpASGN



Uživatelé WHOMalawi, WHO African Region, Tedros Adhanom Ghebreyesus a další (4)

12 167 273

### Poprvé na Twitteru?

Zaregistrujte se a získáte vlastní přizpůsobenou časovou osu.

Zaregistrovat se

### Také by se vám mohlo líbit.

Aktualizovat



United Nations ✓ @UN



UNICEF ✓ @UNICEF



UN Human Rights ✓ @UNHumanRights



Human Rights Watch ✓ @hrw



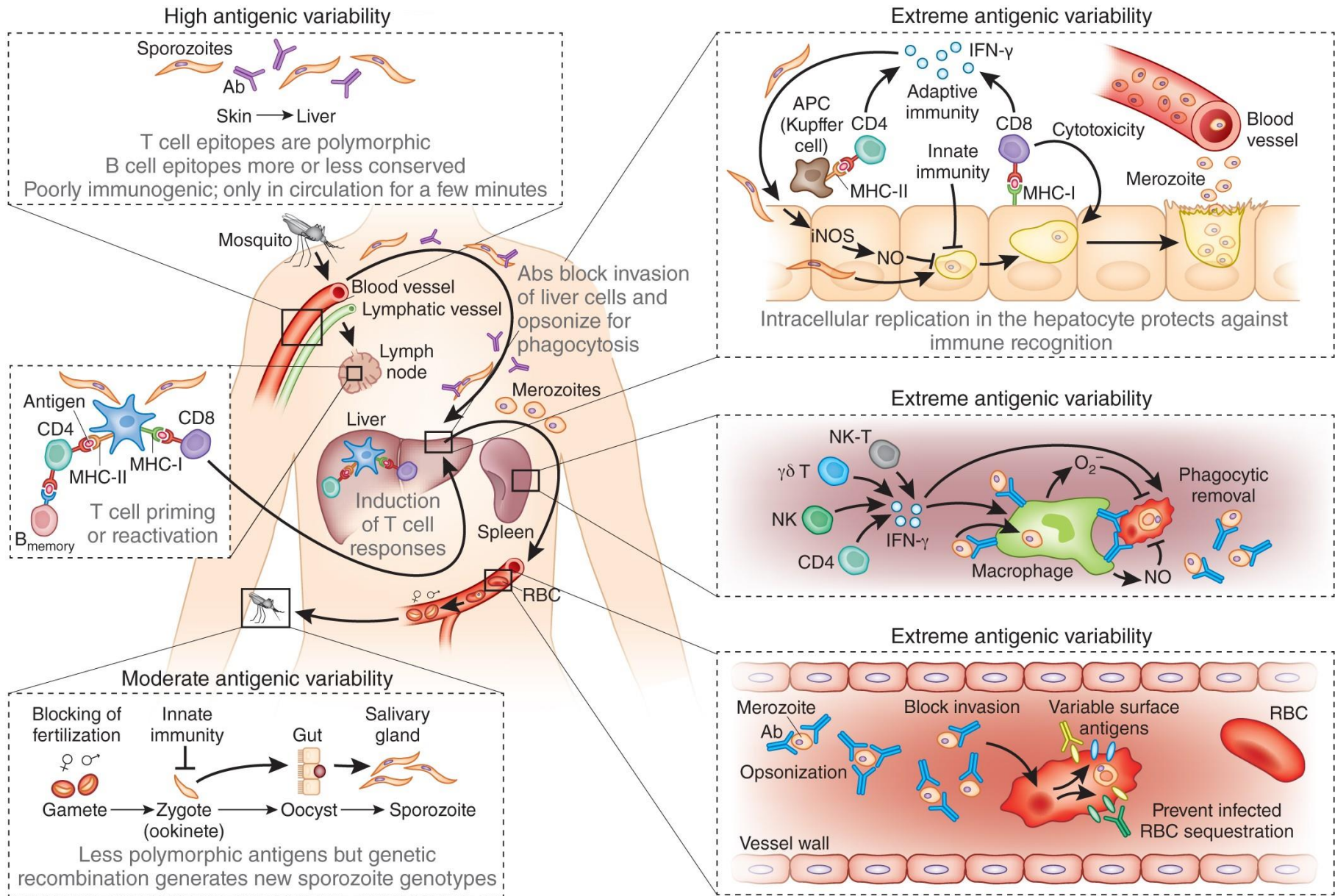
CNN ✓ @CNN

### Trendy pro Celosvětově

#22Nisa

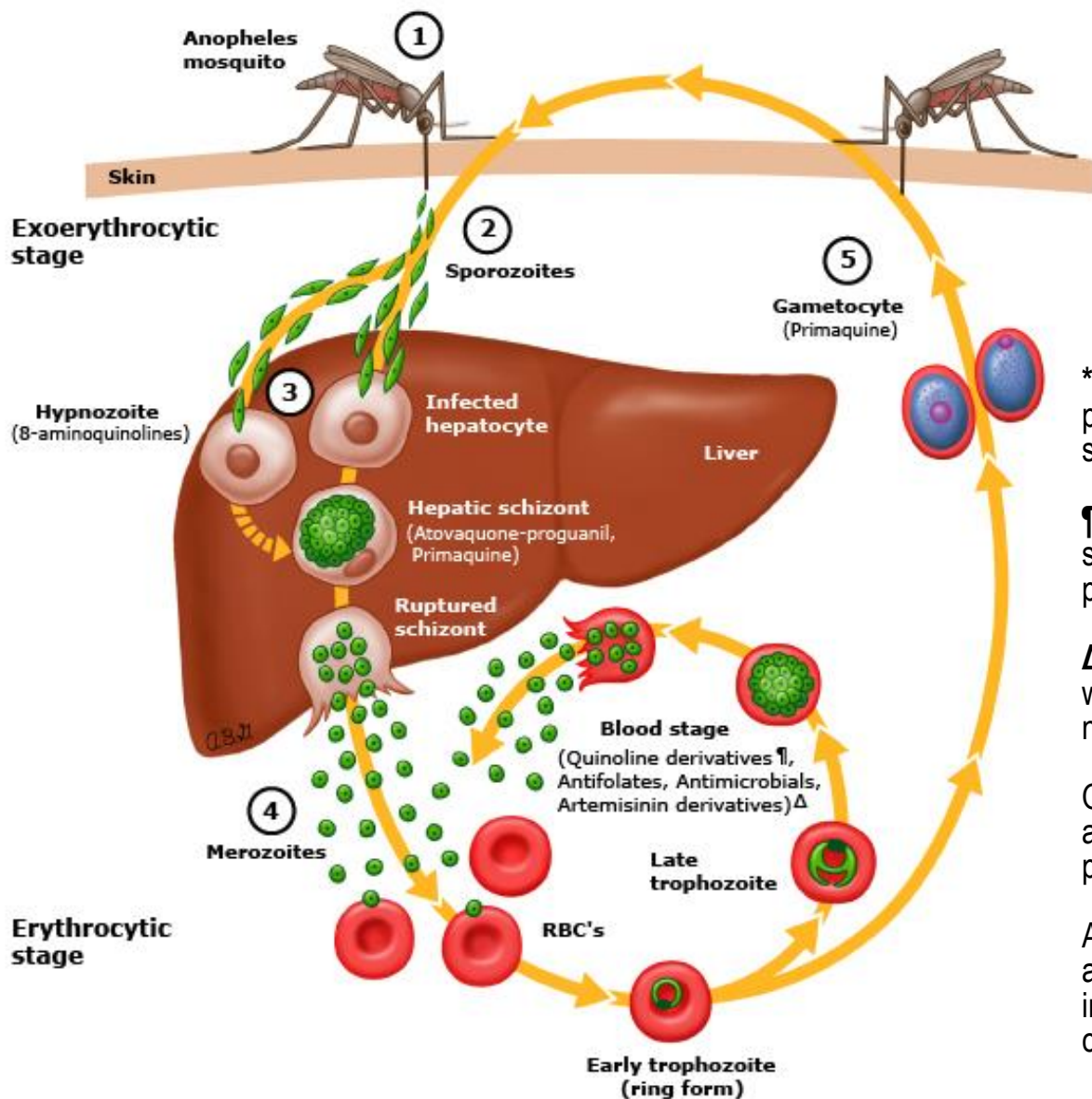


# Immune mechanisms in malaria





# Plasmodium life cycle drug targets



\* There is strong evidence that drugs listed in parentheses are active against designated stage of parasite life cycle.

¶ Quinoline derivatives are blood stage schizonticides with the exception of primaquine.

Δ Primaquine is a blood stage schizonticide with activity against schizonts of *P. vivax* but not those of *P. falciparum*.

Quinoline derivatives include chloroquine, amodiaquine, quinine, quinidine, mefloquine, primaquine, lumefantrine, and halofantrine.

Antifolates include sulfadoxine-pyrimethamine and atovaquone-proguanil. Antimicrobials include tetracycline, doxycycline, and clindamycin.

# Drugs used for malaria chemoprophylaxis

Drug	Areas	Mode of intake	Adult dose	Pediatric dose	Pregnancy	Contraindications
<b>Atovaquone-Proguanil<sup>2</sup></b> (ATV/PGN)	All malarious areas	Start 1 day before entering malarious areas. Continue up to 7 days after leaving such areas	250/100 mg daily orally	Pediatric tablets (ped. tabs) containing 62.5 mg atovaquone and 25 mg proguanil hydrochloride: 11-20 kg: 1 ped. tab/die; 21-30 kg: 2 ped. tabs/die 31-40 kg: 3 ped. tabs/die 40 kg: 1 adult tab/die Not recommended under 11 kg because of limited data	Not recommended	Hypersensitivity, severe renal impairment (creatinine Cl < 30 mL/min), children < 11 kg
<b>Chloroquine</b> (CLQ)	<i>P. vivax</i> , <i>P. ovale</i> , <i>P. malariae</i> and CLQ-sensitive <i>P. falciparum</i> areas	Start 1 week before entering malarious areas. Continue up to 4 weeks after leaving such areas. If daily doses: start 1 day before departure	300 mg base/weekly (also when proguanil is associated)	5 mg/kg/weekly	Recommended	Hypersensitivity, epilepsy, psoriasis, retinal diseases, severe hepatic failure
<b>Doxycycline</b> (DOXY)	All malarious areas	Start 1 day before entering malarious areas. Continue up to 4 weeks after leaving such areas	100 mg/die	Contraindicated under 8 years of age	Not recommended	Cutaneous hypersensitivity, hepatic diseases, hypersensitivity to tetracyclines
<b>Mefloquine<sup>3</sup></b> (MFQ <sup>1</sup> )	Prophylaxis in areas with mefloquine-sensitive malaria	Start 1 week before entering malarious areas (preferably 2-3 weeks). Continue up to 4 weeks after leaving such areas	250 mg base (1 tab)/week	Not recommended under 5 kg because of lack of data.	Not recommended in the first trimester of pregnancy because of lack of data	Hypersensitivity, seizures, psychiatric disorders, cardiac conduction abnormalities

## **Piroplasmorida**

- apical complex without conoid and pellicular microtubules
- zygote = motile stage – kinete
- parasites of vertebrate erythrocytes and lymphocytes (IH)
- vectors are ticks belonging to Ixodidae and Argasidae (DH)

## **Babesiidae**

- development restricted to vertebrate erythrocytes
- transovarial transmission in vectors
- more than 100 species

## **Theileriidae**

- development in vertebrate erythrocytes and in lymphocytes = Koch's bodies
- transstadial transmission in vectors only



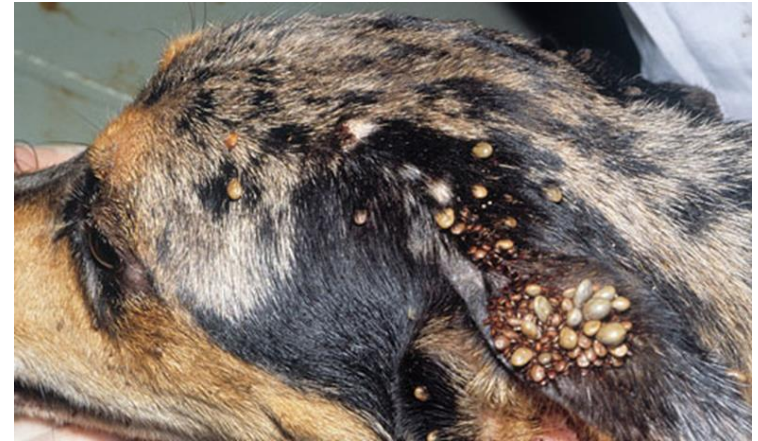# Babesiidae

## genus *Babesia*

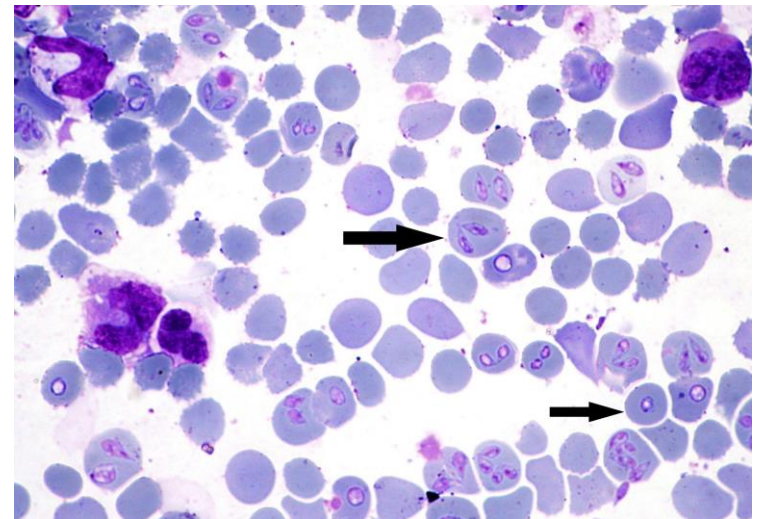
- infecting livestock worldwide, wild and domestic vertebrate animals, and occasionally humans
- transmitted by ticks

### *Babesia canis*

- IH: Canidae
- DH: hard ticks - *Dermacentor reticulatus* for subspecies *B. canis canis* (Europe), *Rhipicephalus sanguineus* for *B. canis vogeli* (subtropics, tropics), *Haemaphysalis leachi* for *B. canis rossi* (south Africa)
- clinical signs - lethargy, weakness, vomiting, anorexia, fever, pale mucous membranes, and dark discoloration of urine
- incubation period 10-20 days, mortality to 100% in untreated dogs
- imported / autochthonous cases in Czechia

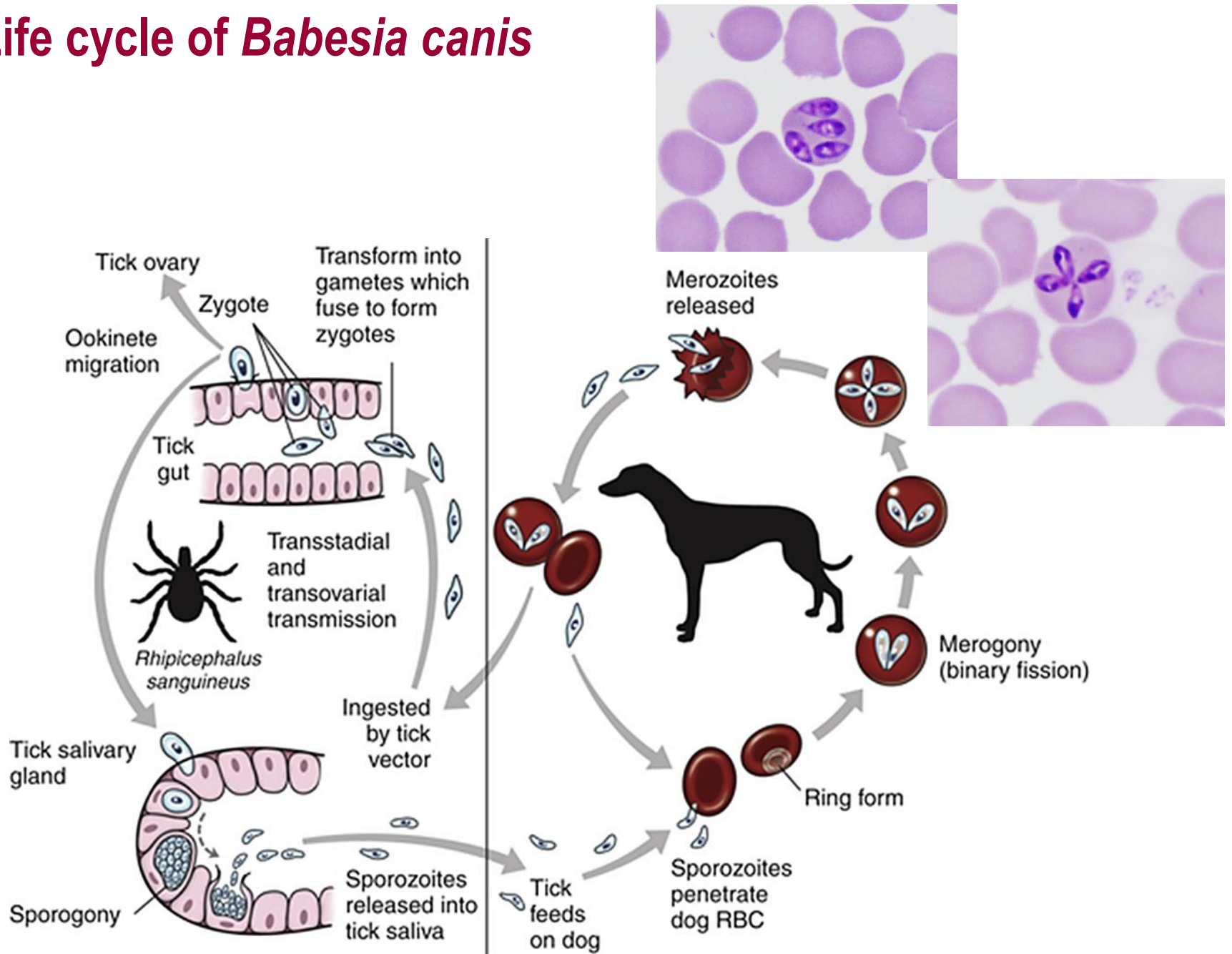


*Rhipicephalus sanguineus*



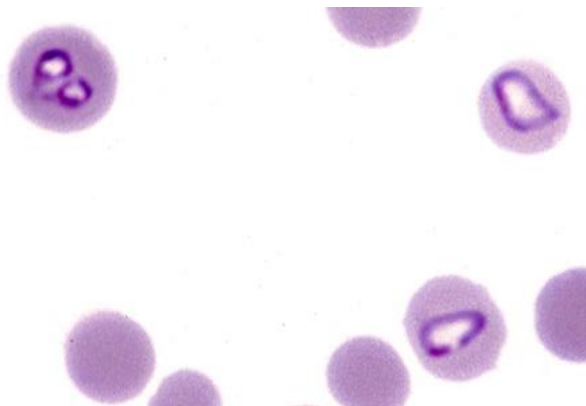
*Babesia canis* in erythrocytes of a dog (Giemsa)

# Life cycle of *Babesia canis*

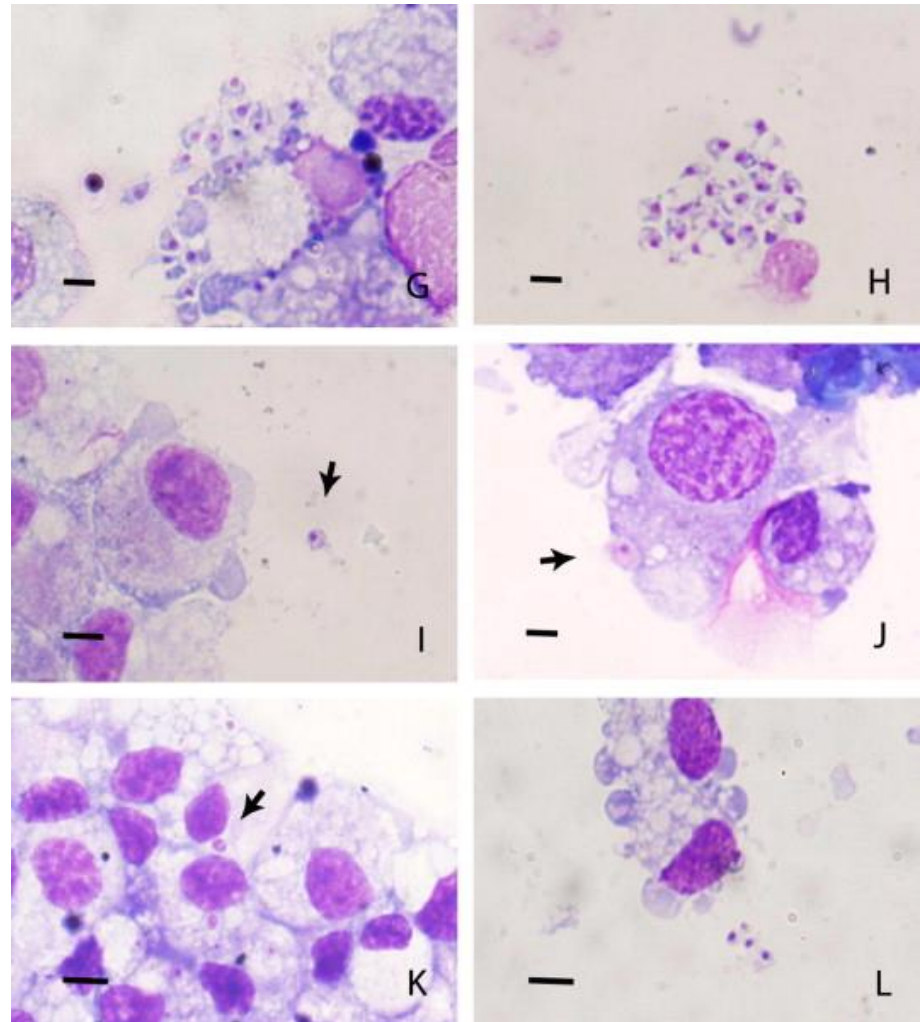


## *Babesia bigemina*

- IH: Bovidae
- DH: *Rhipicephalus* ticks
- **Texas cattle fever** - mortality in acute untreated cattle 50-90 %
- rapid rise in temperature, fever persisting for a week or more ⇒ loss of appetite, dull, listless ⇒ severe anaemia due to rapid loss of erythrocytes ⇒ infected erythrocytes adhere to vasculature of organs
- cattle may die within 3-8 days



*Babesia bigemina* in cattle blood




**Developmental stages of *B. bigemina* in *Ixodes scapularis* tick cell line. G-H) Masses of uninucleated sporokinets. I-J) Extracellular ring form adhered to the cell. K-L) Intra- and extracellular degeneration of sporokinets. Giemsa.**



# Clinical signs of livestock babesiosis

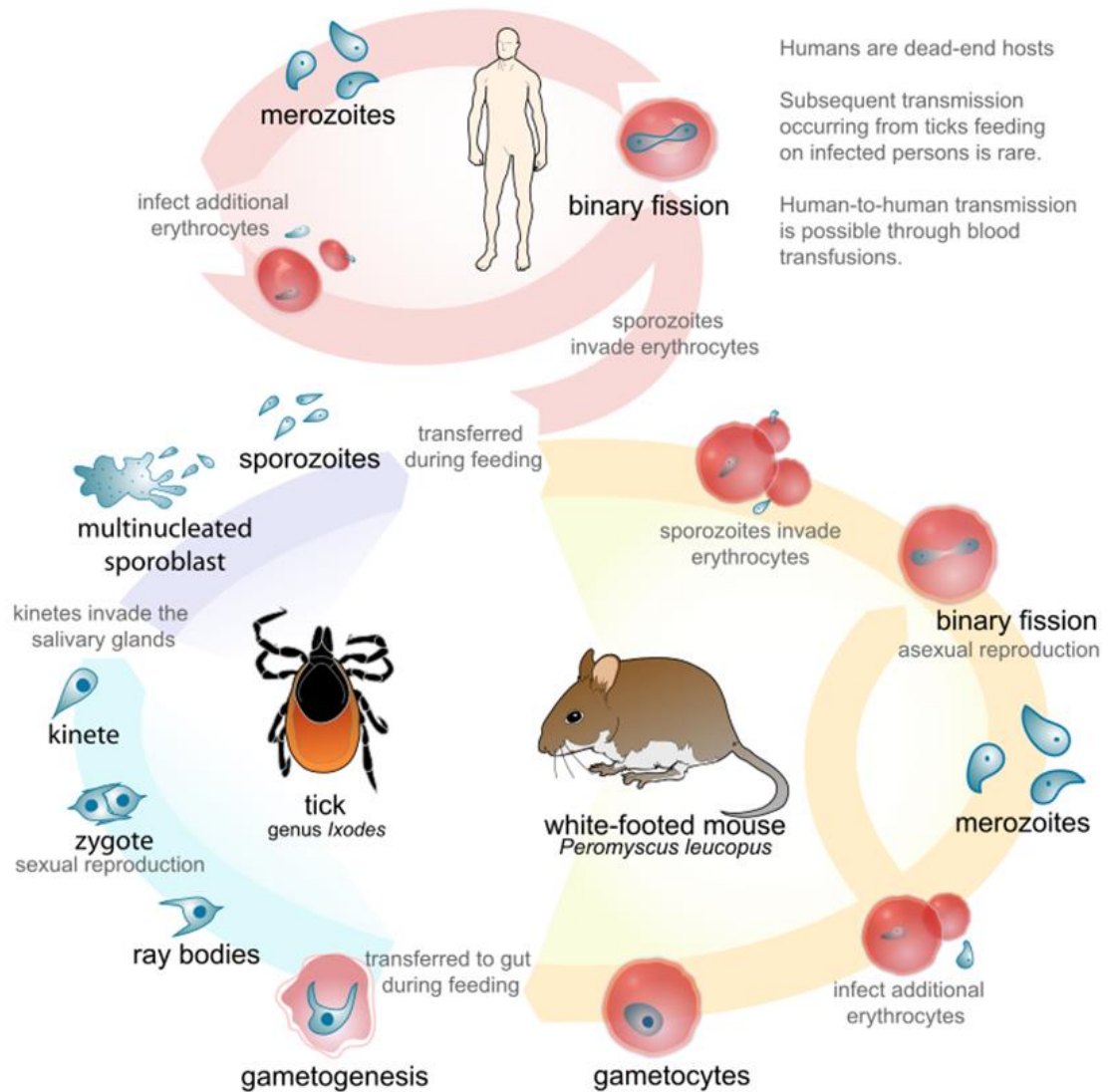
- infections with *B. bovis*, *B. bigemina*, *B. divergens*, and *B. ovis*, mainly adult animals showed intense pathogenic effects, which lead often to death
- some *Babesia* species (e.g. *B. ovis*, *B. bigemina*, *B. bovis*, *B. divergens*) may introduce mortality rates of up to 50 %
- leading symptom is **bloody urine**, since reproduction of the parasites inside the red blood cells leads to the destruction of the host cell
- infection mostly starts with fever (40–42 C), diarrhoea, apathy, nonfeeding, paresis, and spasms followed by anaemia, icterus and often severe haemoglobinuria, erythropenia, and leucocytosis



Urine of uninfected animals (left) and *Babesia*-infected animals showing haematuria

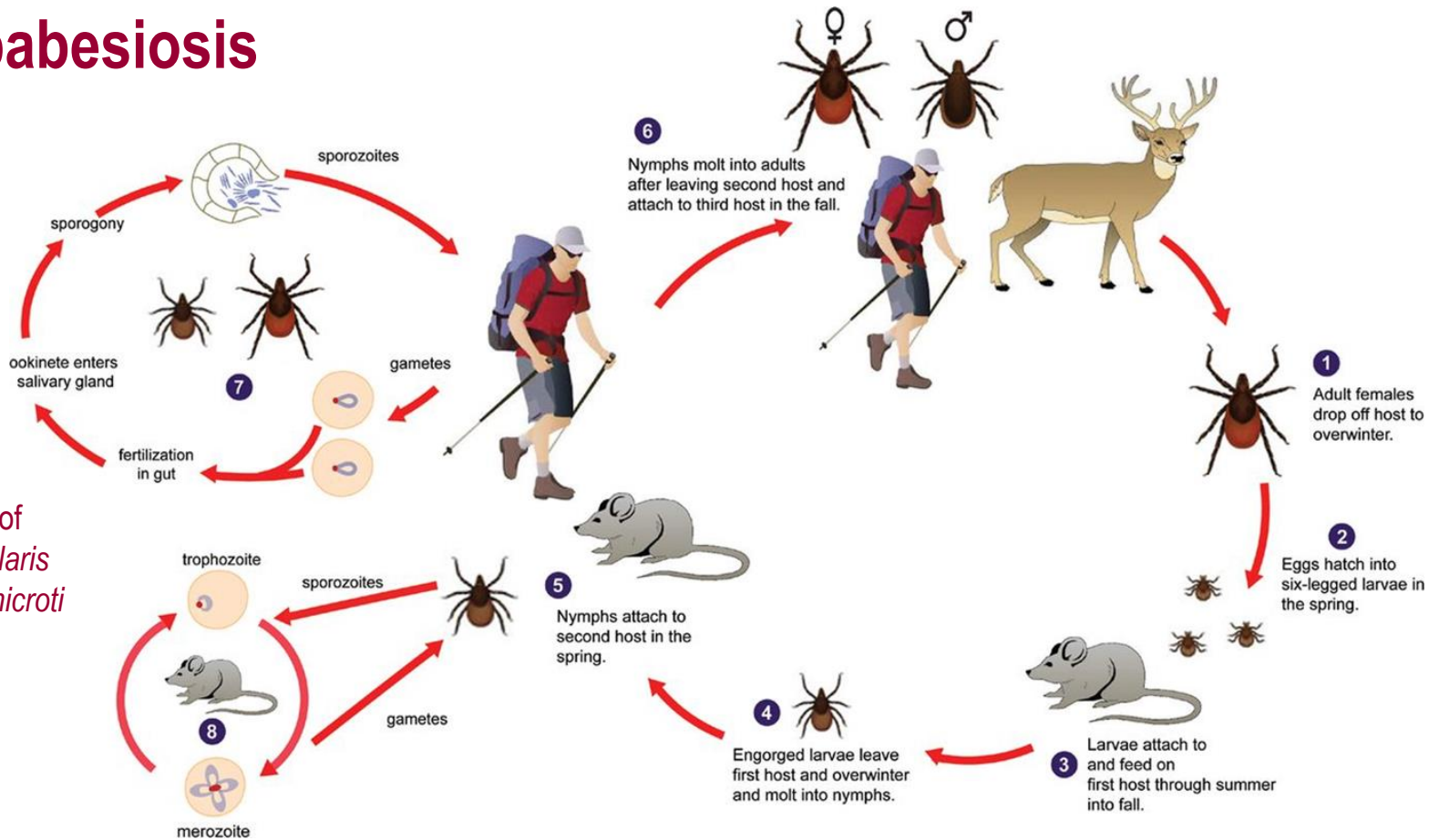
## *Babesia microti*

- IH: rodents (primarily *Peromyscus leucopus*)
- DH: *Ixodes* ticks
- **possible misidentification** - also classified as *Theileria microti*
- genome sequencing showed that it does not belong to either *Babesia* or *Theileria*, but to a separate genus
- zoonosis



# Human babesiosis

Life cycles of *Ixodes scapularis* and *Babesia microti*



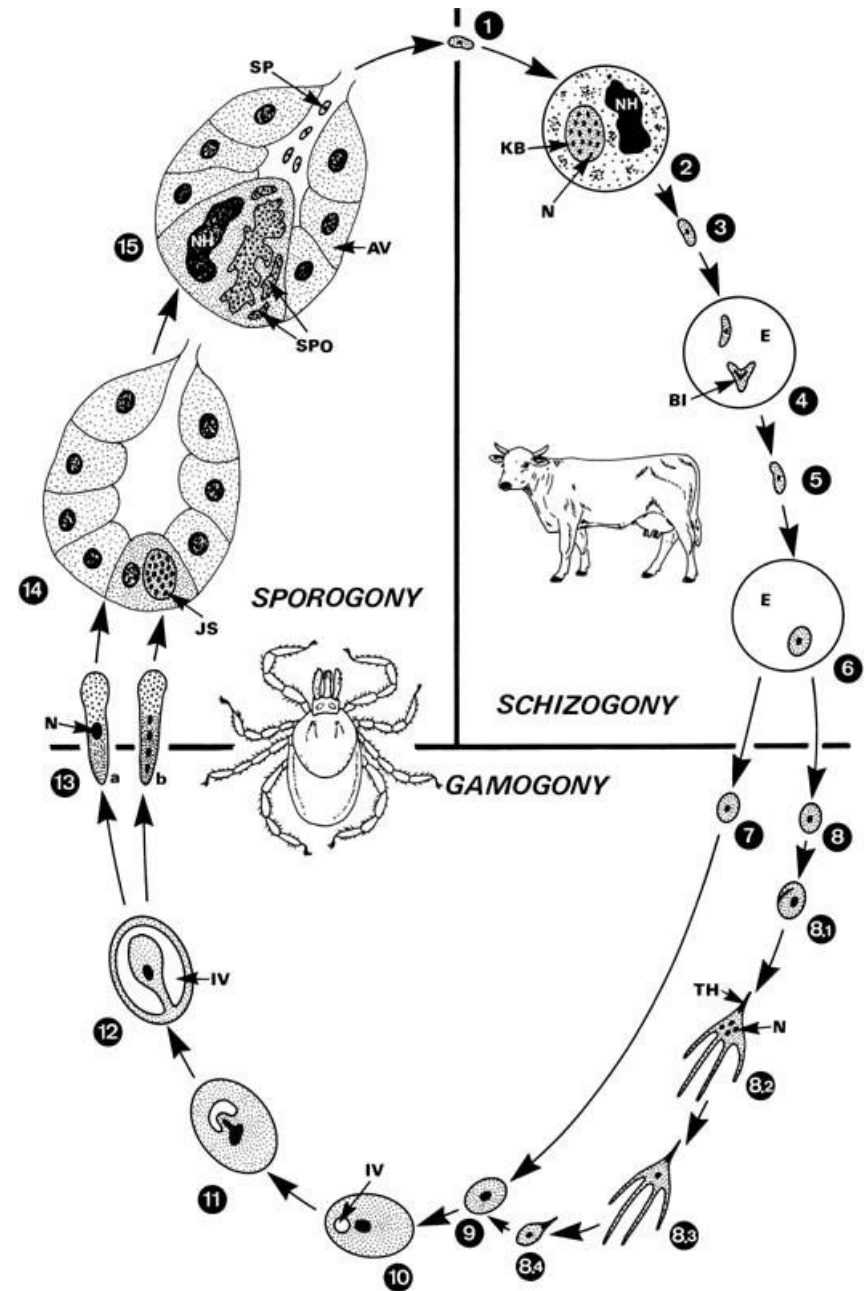

- primary species infecting humans: *Babesia microti*, *B. divergens*, *B. duncani*, *B. venatorum*
- hallmarks of babesiosis - fever and fatigue
- infection can be asymptomatic or range from an influenza-like illness to severe disease (depending on host immune status) with end-organ compromise (renal failure, acute respiratory distress syndrome, disseminated intravascular coagulation, or splenic infarction or rupture), might be fatal
- relapsing disease and treatment failures are primarily observed among patients with asplenia and/or other immune deficits



# Theileriidae

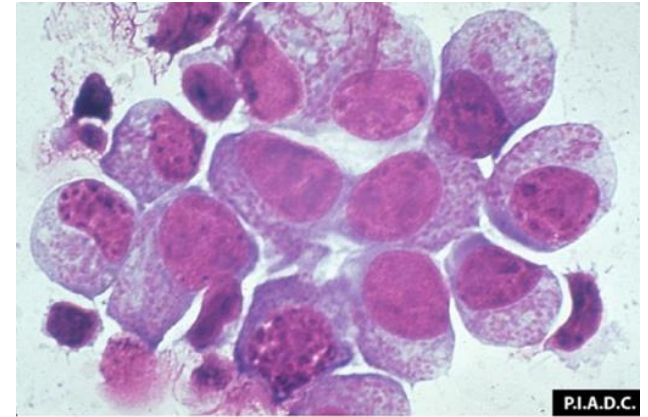
## genus *Theileria*


- infecting cattle and ungulates
- theileriosis transmitted by ticks

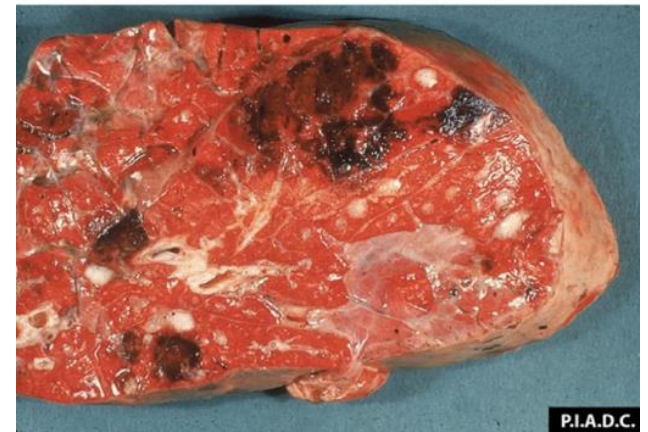

## *Theileria parva*

- IH: Bovidae
- DH: *Rhipicephalus appendiculatus*
- „East Coast Fever“ of cattle in sub-Saharan Africa
- meronts in lymphocytes (Koch's blue bodies)  
circular or irregularly shaped
- rod-shaped stages in erythrocytes
- high mortality (in imported stock mortality up to 100%)
- zebu (*Bos indicus*) is naturally resistant
- vaccination with attenuated strains



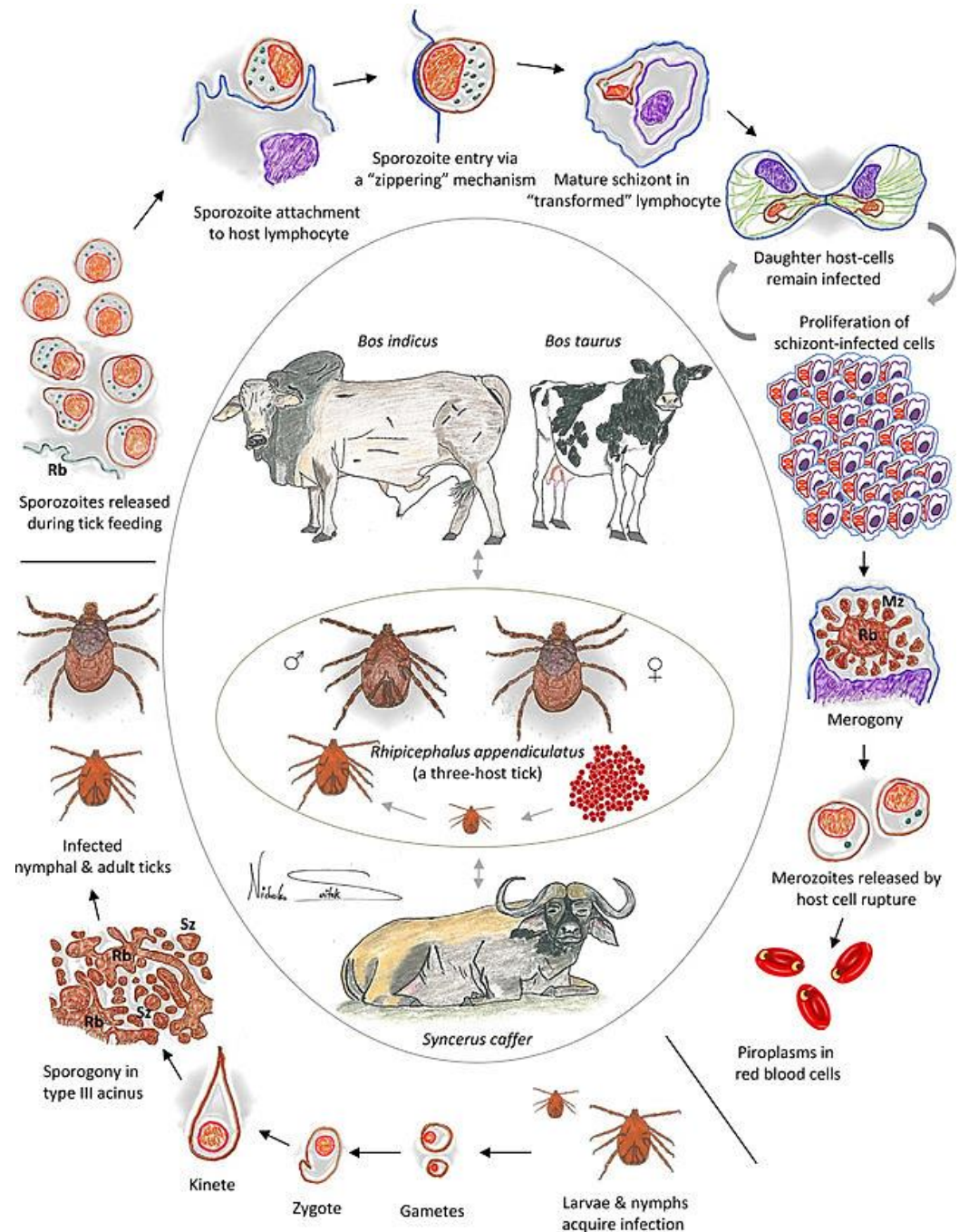
 *Theileria parva* (1.5µm)





# Symptoms and life cycle of *Theileria parva*

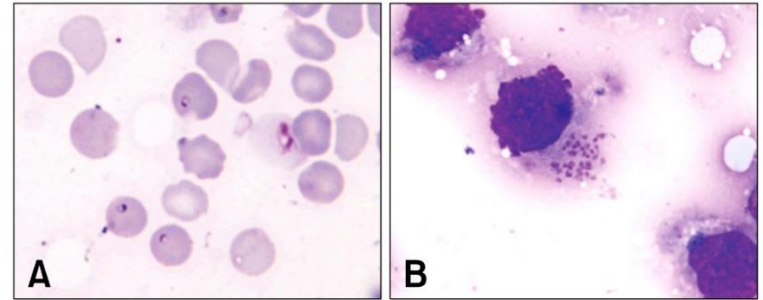
- East Coast fever results from infected lymphocytes
- **symptoms** include anorexia, fever, enlarged lymph nodes near the tick bites (or even lymphadenopathy), diarrhoea, laboured breathing due to pulmonary oedema, corneal opacity, nasal discharge and anaemia
- rarely a "turning sickness" disorder develops - when the parasites in cells block blood vessels in brain and cause brain damage – usually results in death
- respiratory failure and death of African cattle



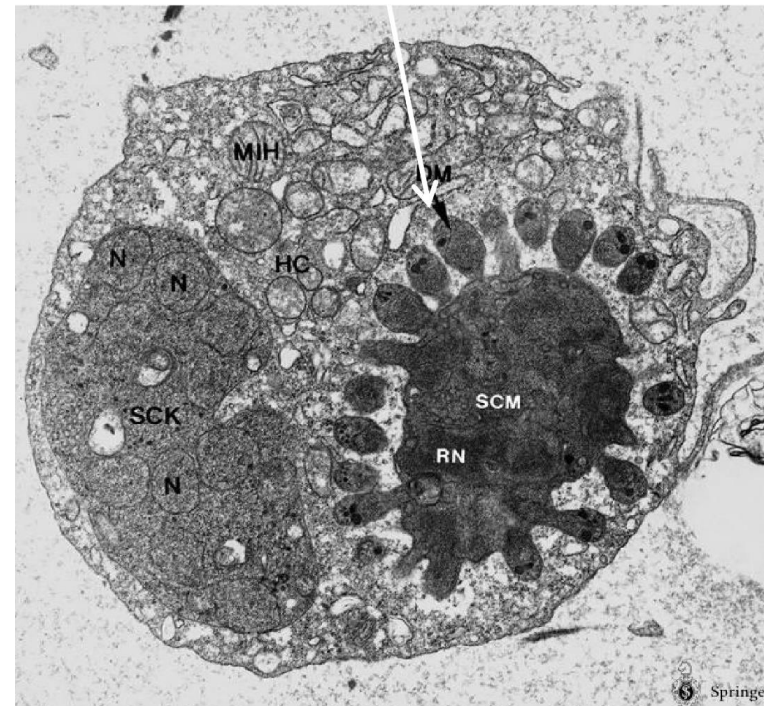


## *Theileria annulata*

- IH: Bovidae
- DH: *Hyalomma* ticks
- causal agent of tropical theileriosis
- indistinguishable from *T. parva*
- north Africa, Mediterranean coastal area, Middle East, India, former USSR, Asia
- incubation period 9-25 days
- infects mainly bovine B-cells and macrophages
- lymphoproliferative disease with clinical features similar to some human leukaemia
- acute disease in all breeds and all age group of cattle, including buffalo and zebu
- fever, depression, lacrimation, nasal discharge, swelling of superficial lymph nodes
- rapid emaciation and haemoglobinuria
- mortality of up to 90 %

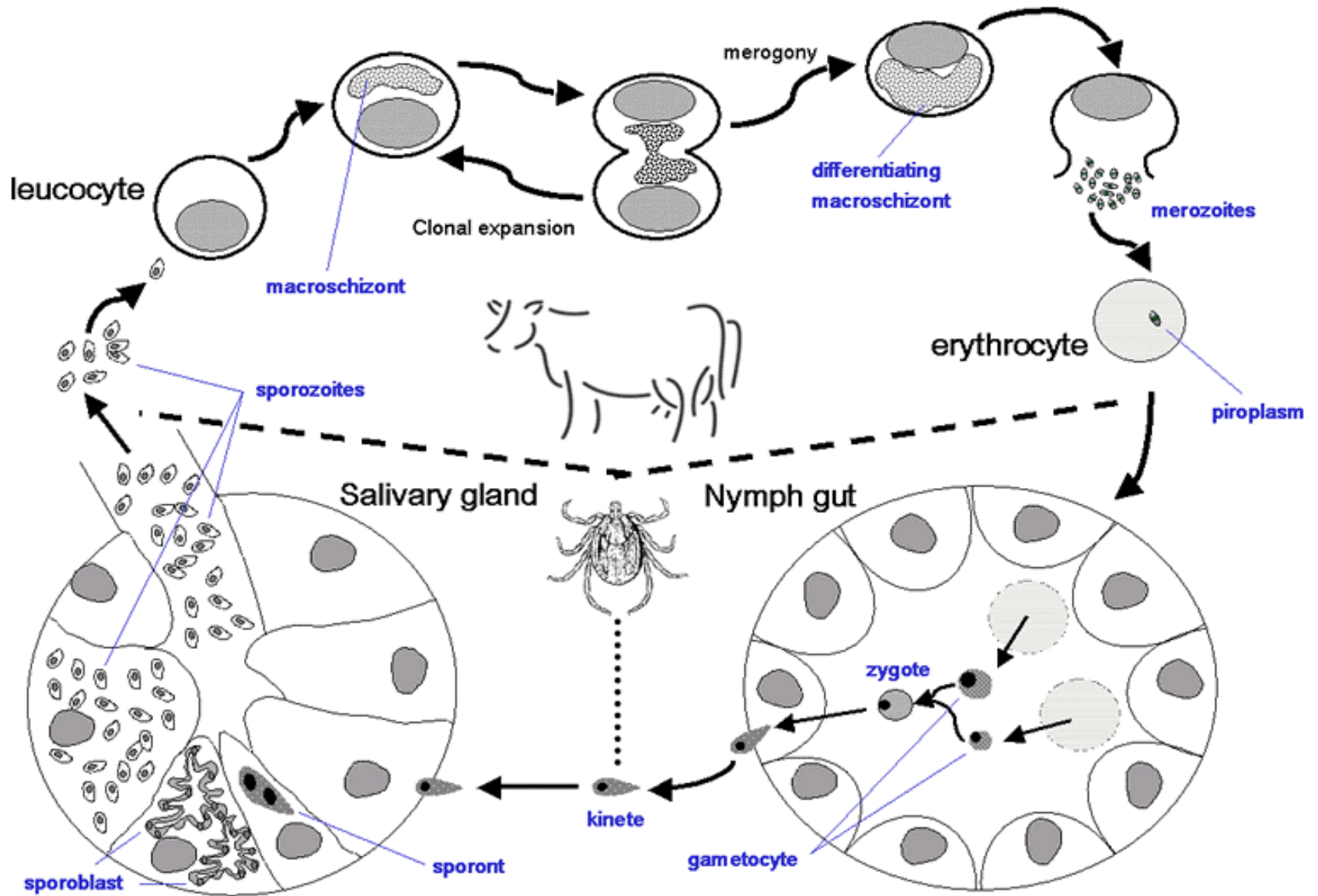


A) Blood smear showing three ring forms of *T. annulata* in red blood cells. B) Lymph node smear showing a meront in mononuclear cell. Giemsa.



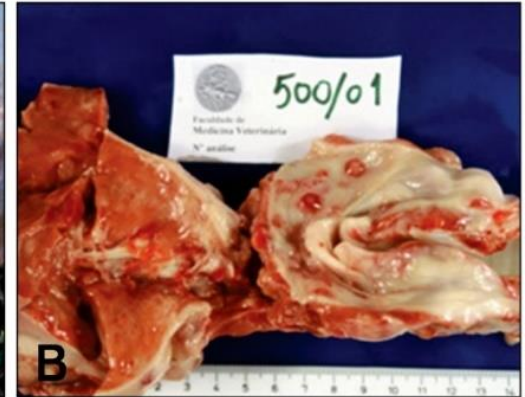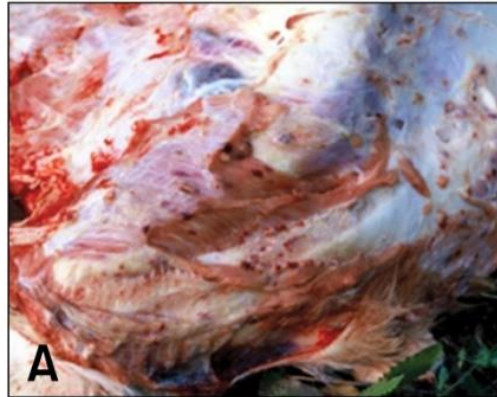Koch's bodies

# Life cycle of *Theileria annulata*

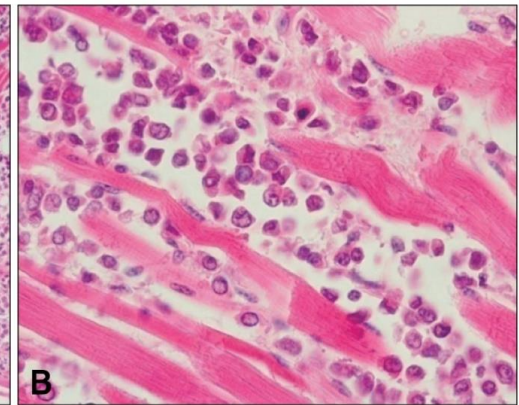
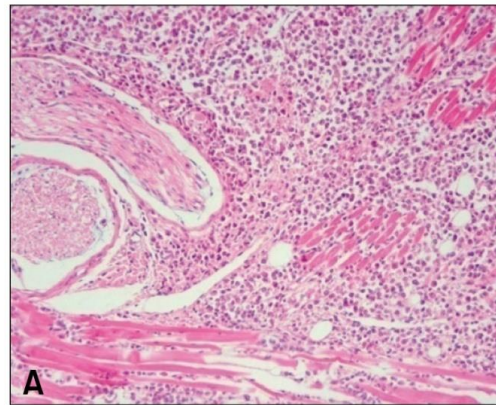


# Pathology of *Theileria annulata*

- acute lethal infection of calves ( $\leq 4$  months of age) - calves had enlarged lymph nodes and developed multifocal to coalescent nodular skin lesions, similar to multicentric malignant lymphoma
- at necropsy, haemorrhagic nodules or nodules with haemorrhagic halo were found, particularly in the skin, subcutaneous tissue, skeletal and cardiac muscles, pharynx, trachea and intestinal serosa



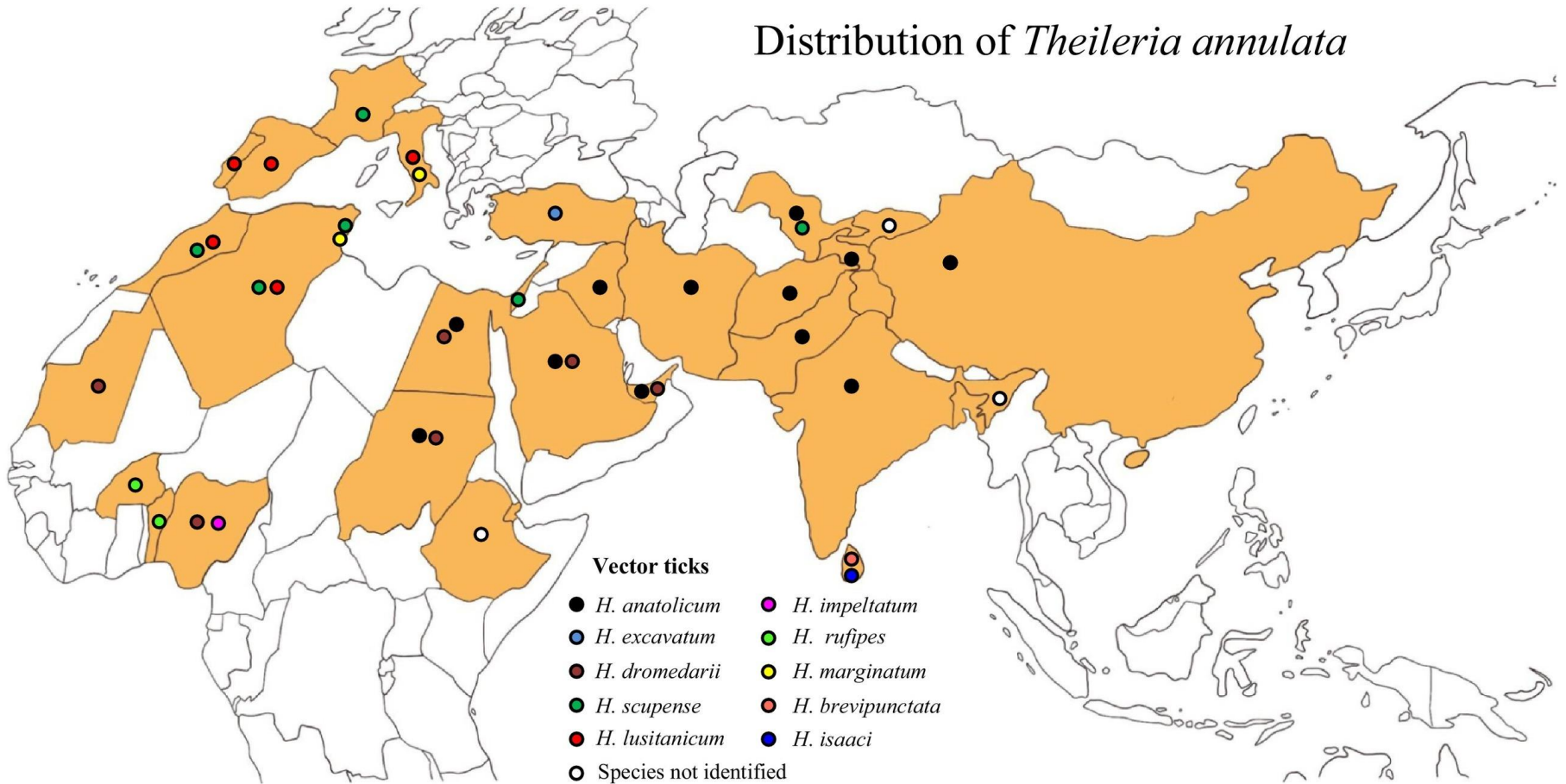
**A)** Widespread haemorrhagic nodules in subcutaneous tissue and abdominal muscles of calf. **B)** Pale and haemorrhagic nodules are inserted in the tongue and the laryngeal and pharyngeal mucosa.



**Lymphoid neoplastic-like cells (A)** in a nodule infiltrating the skeletal muscle (HE), with indistinct cell-membrane, high nuclear/cytoplasmic ratio and occasionally indented nuclei **(B)** (HE).

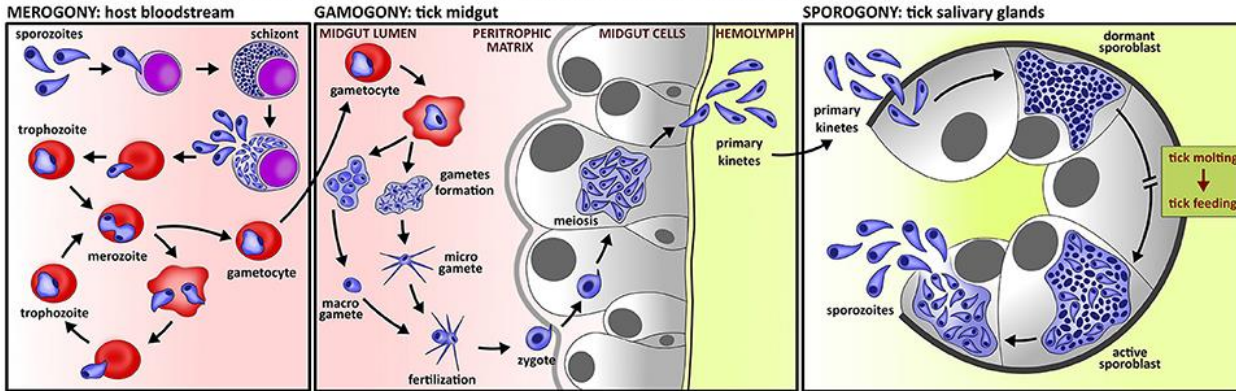


## Distribution of *Theileria annulata*

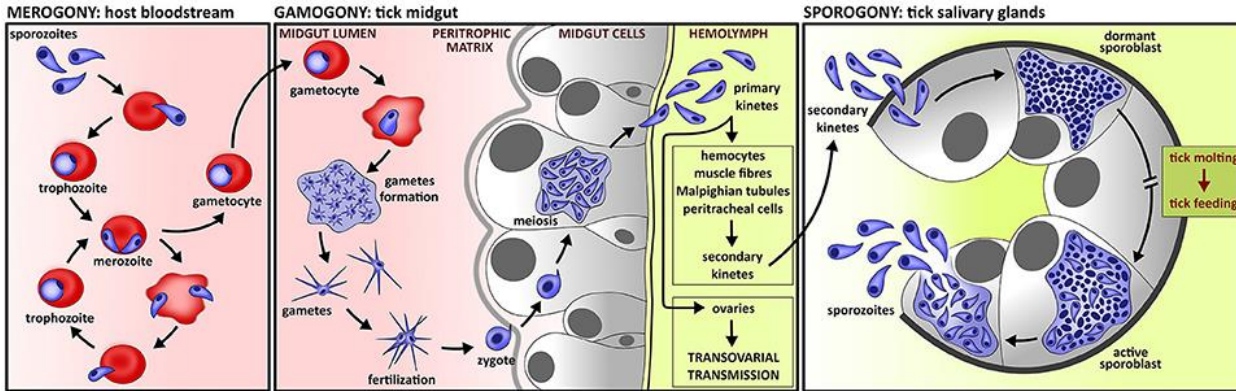


Trends in Parasitology

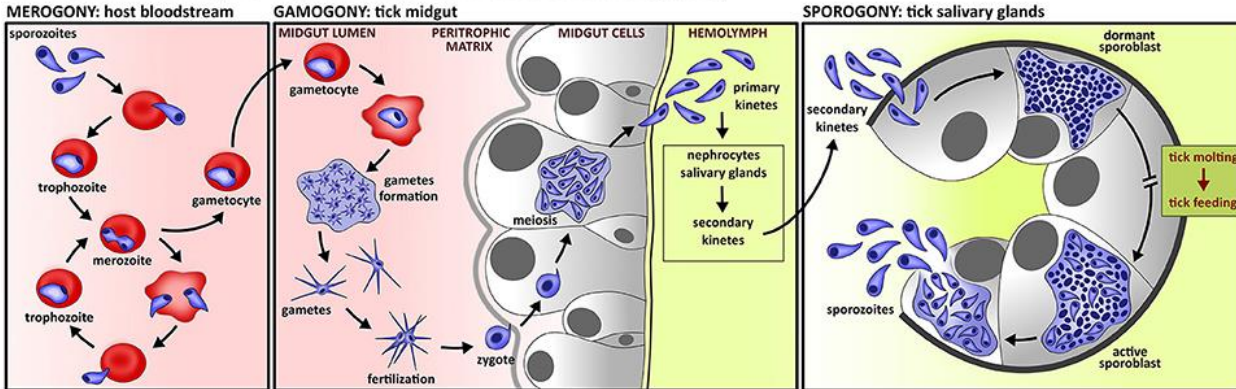
**A Transmission cycle of *Theileria sensu stricto* and *Theileria equi* parasites**

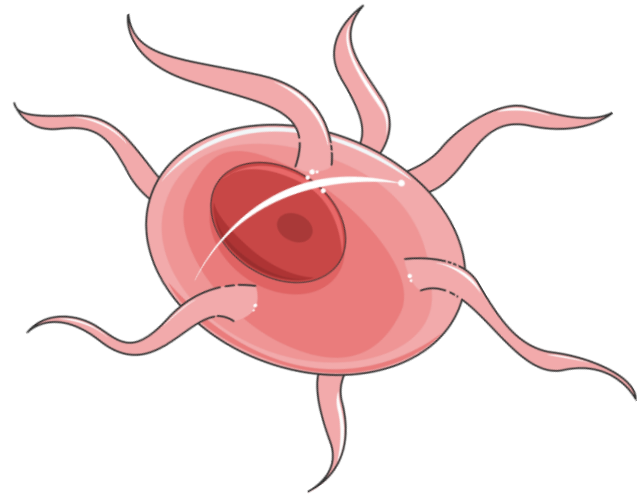
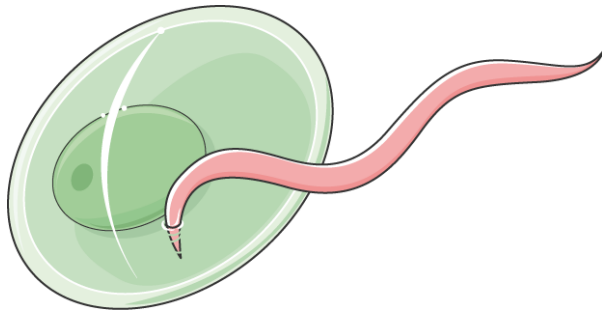


**B Transmission cycle of *Babesia sensu stricto* parasites**




**C Transmission cycle of parasites from *Babesia microti* group**





Thank you for your attention 😊





## Lectures

- ✓ Introduction: BPP 2022 I
- ✓ Euglenozoa (Excavata): BPP 2022 II
- ✓ Fornicata / Preaxostyla / Parabasala (Excavata): BPP 2022 III
- ✓ Apicomplexa I (SAR): BPP 2022 IV
- ✓ Apicomplexa II (SAR): BPP 2022 V
- ⇒ **Amoebae (Excavata, Amoebozoa): BPP 2022 VI**
- Ciliophora, Opalinata (SAR): **BPP 2022 VII**

- *Pneumocystis* (Opisthokonta, Fungi): **BPP 2022 VIII**
- Microsporidia (Opisthokonta, Fungi): **BPP 2022 IX**
- Myxozoa (Opisthokonta, Animalia): **BPP 2022 X**